AfraTafreeh.com

CELL (CHROMATIN AND EPIGENETIC)

Organization of DNA 00:00:05

- DNA Double Helix is wrapped nearly Twice (Exactly 1.75times) over a histone octamer is left-handed helix to forms disc like structure called Nucleosome.
- Individual Nucleosomes are linked by 30bp segment called linker; Giving a bead on string appearance on electron microscopy

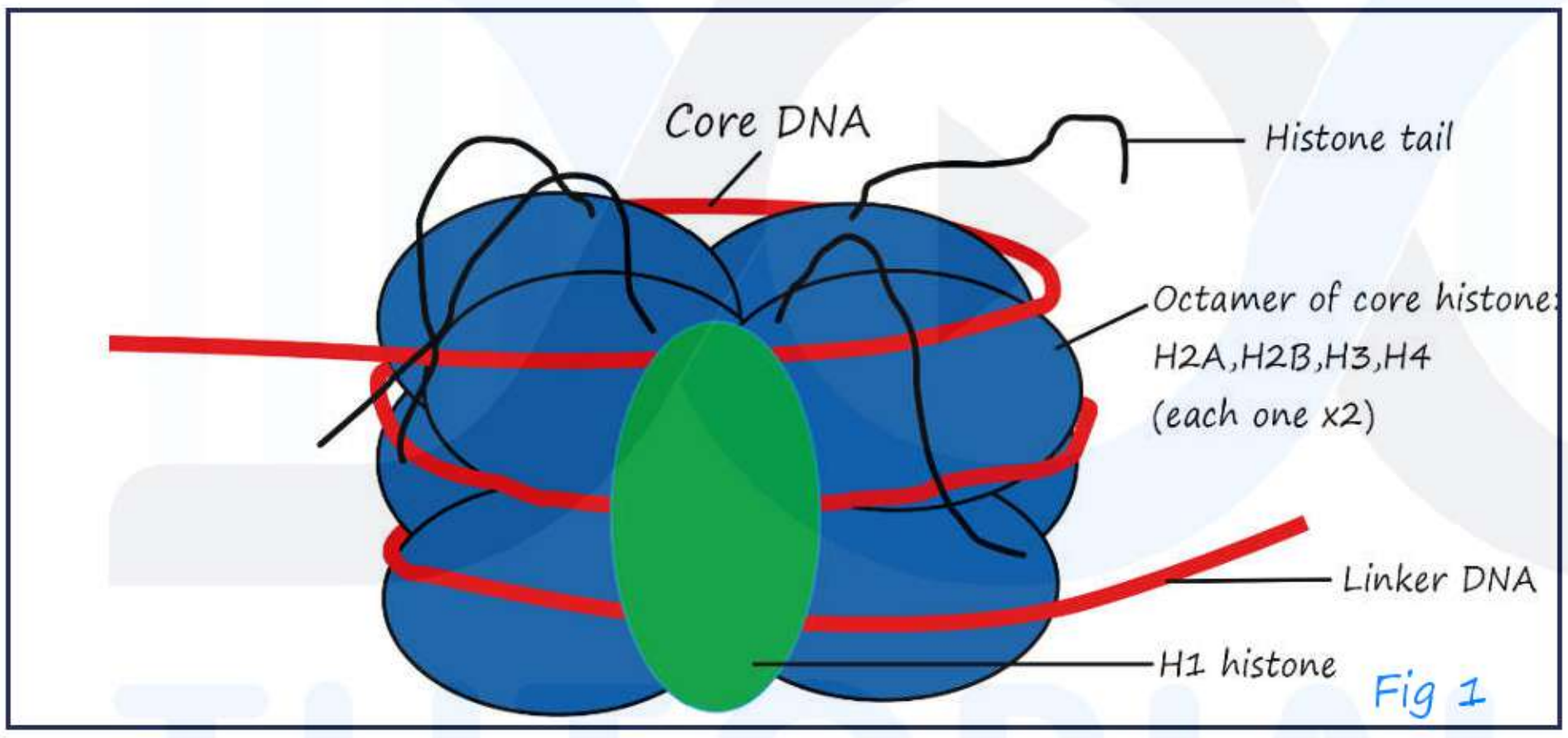

Fig 1

Histones

- Most abundant chromatin protein
- Basic protein (Positively charged)
- Core histones are H2A, H2B, H3 and H4 forming histone octamer
- H1 histone is seen in the linker region

Euchromatin and heterochromatin euchromatin

00:08:50

- Chromatin is less densely packed
- Transcriptionally active, Gene Rich (Higher GC Content)
- Stains less densely
- Also called primitive chromatin

Heterochromatin

- Silenced Genes (methylated)
- Densely packed chromatin
- Transcriptionally inactive, Gene poor (High AT content)
- Stains densely
- Also called repressive chromatin

AfraTafreeh.com

Types heterochromatin	
Constitutive Heterochromatin	**Facultative Heterochromatin**
Always condensed	At times condensed, but at other times uncondensed and actively transcribed Example: X Chromosome in Mammalian female
Inactive	
Seen in centromere and telomere	

AfraTafreeh.com

Epigenetics 00:11:32

- Reversible Heritable chemical modifications of DNA or histone that does not alter DNA sequence itself epigenetics means "above genetics"
- Study of inherited chemical modifications that alter the expression of the gene

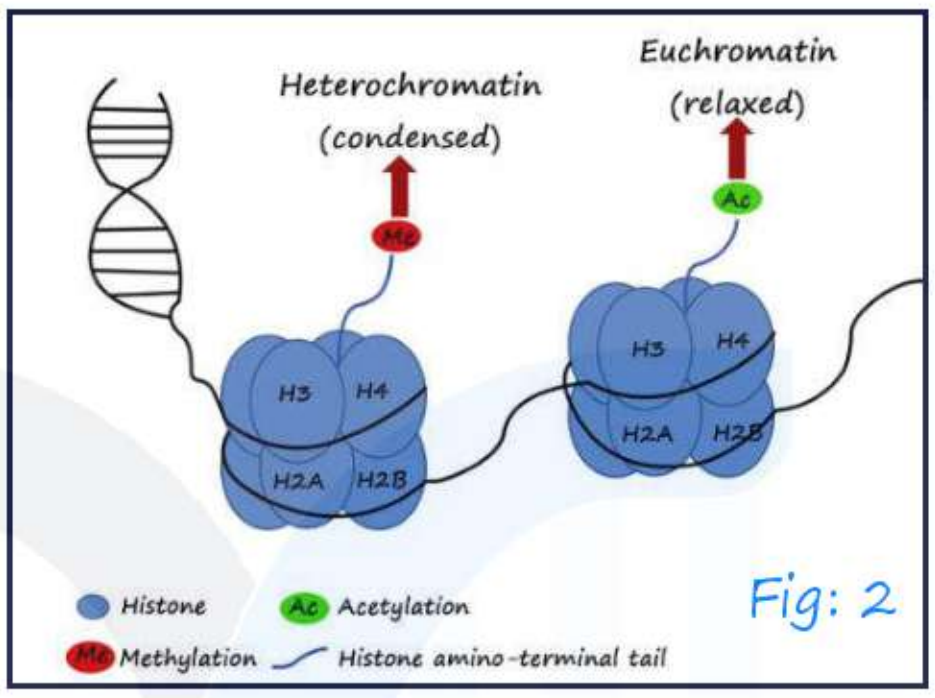

Fig: 2

Epigenetics modifications

I. Methylation and demethylation

II. Acetylation and deacetylation

I. Methylations and demethylations

- DNA Methylation is usually restricted to CG islands
- Methylation decreases gene expression while demethylation increases the rate of transcription
- Works on condensation of chromatin → making it inactive

II. Acetylation and deacetylation

- Acetylation increases gene transcription
- Histone Acetylation reduces the positively charged there by decreases finding affinity for negatively charged DNA
- This increases Euchromatin/Permissive chromatin Formation

- Histone Demethylation has opposite affect i.e it increases Heterochromatin/Repressive chromatin formation
- Chromatin writer complexes called MARKS and bring about epigenetic changes by addition or removal of methyl or acetyl groups.
- Euchromatin (Active) → Heterochromatin (In active)

  Methylation/Deacetylation
- These MARKS can be erased by chromatin erasers, now available as drugs eg:
- Histone deacetylator inhibitor drugs HDAC inhibitor eg: Vorinostat, Valproic acid

Karyotyping AfraTafreeh.com 00:10:11

- Special strain used – Giemsa stain hence karyotyping also known as Giemsa banding / G banding
- C – banding – highlights constitutive heterochromatin.

TUTORIALS LOGIN FOR SUCCESS

AfraTafreeh.com

CAUSES OF CELL INJURY AND REVERSIBLE CELL INJURY

Causes of cell injury and reversible cell 00:00:30

I. Causes of cell injury

Hypoxia: Most common cause of cell injury

Causes of Hypoxia

a. Ischemia-most common cause of hypoxia

b. Anemia

c. Cardio respiratory arrest

Mechanism of injury due to hypoxia 00:02:48

- Decreased oxygen leads to reduced oxidative phosphorylation
- This reduces ATP – which causes the Na+ K+ ATPase functioning to stop
- Na+ starts moving inside the cell along with water leads to cell swelling – Hydropic change

Hypoxia → decrease O_2 supply → anaerobic Glycolysis

decrease O_2 supply ↓ Decrease Oxidative phosphorylation ↓ Decrease ATP ↓

anaerobic Glycolysis ↓ increase Lactic acid (H^+ ↑) ↓ increase Acidity ↓ Mild chromatic clamping

Loss of microvilli →

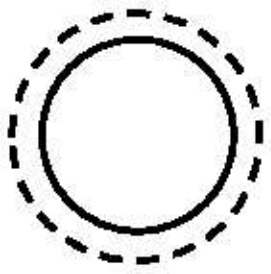

No entry of Na^+ K^+ ATPase

Morphological changes of reversible cell injury

00:05:27

swelling occurs – Hydropic change

I. Hydropic change

- Earliest changes of cellular injury is stoppage of Na^+-K^+ ATPase pump
- Earliest morphological change of cellular injury is hydropic change

i. Hydropic change in liver is called ballooning

ii. Hydropic change in kidney is called cloudy swelling

Mechanism of hydropic change

i. Pinching of endoplasmic reticulum vesicles

ii. This makes the cell appear clearer

AfraTafreeh.com

Electron microscopy view of reversible cell injury

- Loss of microvilli of cells
- Blebs formed across the cell membrane
- Clear vesicles in cytoplasm which are formed due to pinching of endoplasmic reticulum → Due to hydropic change
- Swelling of cell organelles
- Swelling of ribosome's leads to separation of subunits of ribosomes and leads to decreased protein synthesis
- Decreased protein synthesis leads to accumulation of fat- Fatty change

AfraTafreeh.com

- Fatty change is 2nd morphological change of reversible cell injury

II. Fatty change

i. Heart

- Fatty change in heart deposited between myocardial fibers – **Tigered change**

Diphtheritic myocarditis shows diffuse fatty change

ii. Liver

- Fatty change in liver is called steatosis

2 types of steatoses

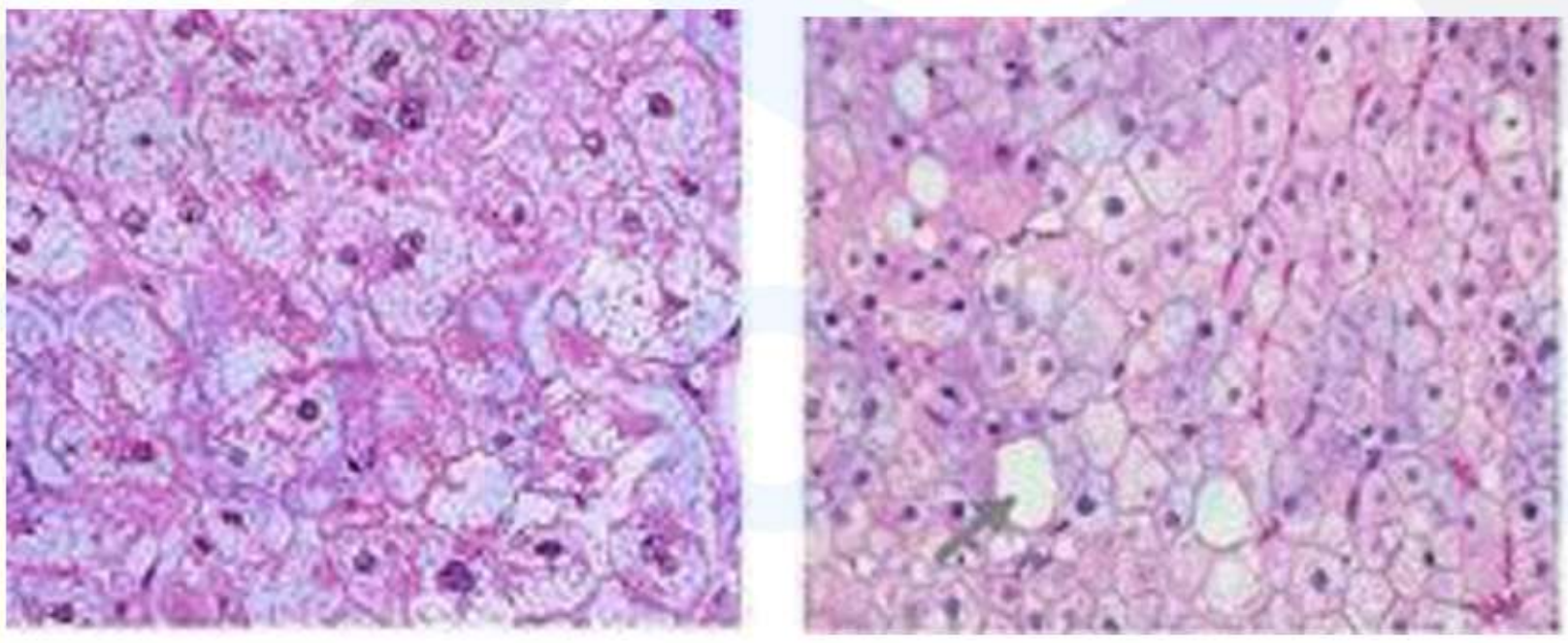

i. Micro vesicular ii. Macro Vesicular Fig 1

- Nucleus is center
- Multiple tiny fat vesicles
- Nucleus pushed to periphery but not indented cytoplasm occupied by large fat vesicles

Signet ring cells–Nucleus pushed to periphery and nucleus is indented by mucin

- Formalin is used as a preservative

10% buffered neutral formalin used as universal fixator

- Formalin dissolves fat hence, to see fatty tissue fresh, frozen sections are used produced in CRYOSTAT machine

  Stain for fat – Osmium tetraoxide
  - Oil red stain
  - sudan black

III. Nuclear changes

Mild chromatin clumping

- Due to decrease O2 supply, leads to anaerobic glycolysis which leads to accumulation of lactic acid and causes decrease PH which leads to mild chromatin clumping

Disaggregation of granular and fibrillar elements of nucleus

Nuclear changes in reversible cell injury is

a. Mild chromatin clamping
b. Disaggregation of granular and fibrillar elements of nucleus

IV. Cell membrane changes

- Most important is in a cell injury is Ca^{2+}
- Mild increase in calcium occurs in reversible injury

AfraTafreeh.com

- This leads to activation of phospholipase which damages cell membrane organelle

Myelin figures-these are concentric lamellated whorls/figures (Made of phospholipase and Ca^{2+}) seen is reversible and irreversible injury

V.Small amorphous densities in mitochondria are seen in reversible cell injury

- Large amorphous densities are seen in irreversible injury

  High yield box:

  - Tissue most resistant to hypoxia-fibroblasts
  - Earliest morphological change of cell injury-hydropic change
  - Earliest morphological change of apoptosis-cell shrinkage.

TUTORIALS
LOGIN FOR SUCCESS

IRREVERSIBLE CELL INJURY

- Initiator of irreversible cell injury is membrane damage
- Calcium moves inside the cells and enters mitochondria

  in mitochondria – calcium through transit pore pushed out into cytoplasm

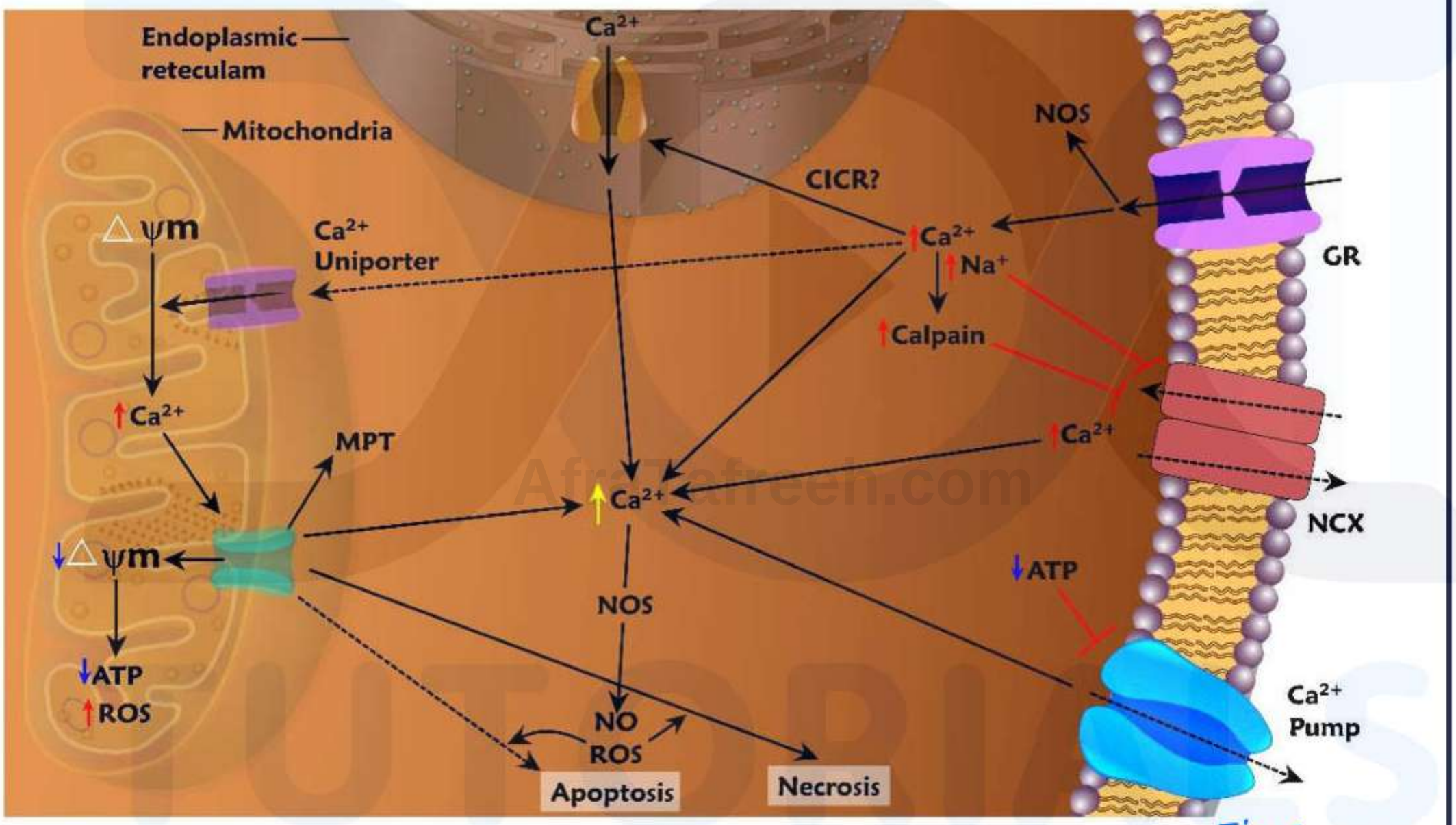

Fig 1

- Inner wall of mitochondria

  ↓

  i. Cytochrome C

  ii. SMAC/DIABLO

  iii. AIF
- Outer wall → BCl2 family
- Movement of $Ca2^{+}$ in mitochondria leads to formation of LARGE AMORPHOUS DENSITIES
- Calcium activates 'PAPE' group of C3 enzymes

AfraTafreeh.com

a. Phospholipase -damages cell membrane leading to formation of myelin figures

b. ATPase – Break down ATP

c. Protease – cytoskeleton is broken down

d. Endonuclease – Breaks down chromatin and DNA in 3 steps

- Step 1: Condenses nucleus – MARKED CONDENSATION – PYKNOSIS
- Step 2: Breakdown of nucleus – KARYORRHEXIS
- Step 3: Complete dissolution of nucleus – KARYOLYSIS

- Cells which contain high number of mitochondria called oncocytes

  Example: - In muscles, kidney and liver.

Basics of H&E 00:13:40

Universal Histopathology stain – H and E → Hematoxylin and eosin

Hematoxylin – Blue colored dye

→ $C_{16}H_{14}O_6$

Taken from bark of tree (Hematoxylon campechianum)

↓

Binds to RNA and DNA (Blue)

Eosin – pink colored dye

↓

Binds to proteins (pink)

Slide appearing bluer – tumors (lot of DNA, RNA)

Slide appearing pinker – Loss of nucleus (In cell injury).

CELL DEATH AND DIFFERENCES BETWEEN APOPTOSIS & NECORSIS

- Cell death two types

I. Programmed cell death 00:01:14

i. Apoptosis

ii. Necroptosis

iii. Pyroptosis

iv. Entosis

v. Netosis

II. Non programmed

i. Necrosis

AfraTafreeh.com

Apoptosis	Necrosis
- Single cell - No inflammation - No membrane damages - Active process - Programmers involved - Shrinkage of cells	- Contigious group of cells - Inflammation is present - Membranes are damaged - Passive process - Cell size becomes large

AfraTafreeh.com

Apoptosis 00:03:40

- Steps of apoptosis

  i. Dead cell activates endonucleases and breaks linker molecules – Inter nucleosomal cleavage
  Leads to formation of 200 base pair cut sizes (Oligomers)

  ii. Apoptotic body is formed which contains all the cut oligomers. Phosphatidly serine flips from inside of the membrane to outside by process of flipping, the apoptotic becomes negatively changed.

Disorders associated with defective apoptosis 00:12:00

I. Auto immune disease

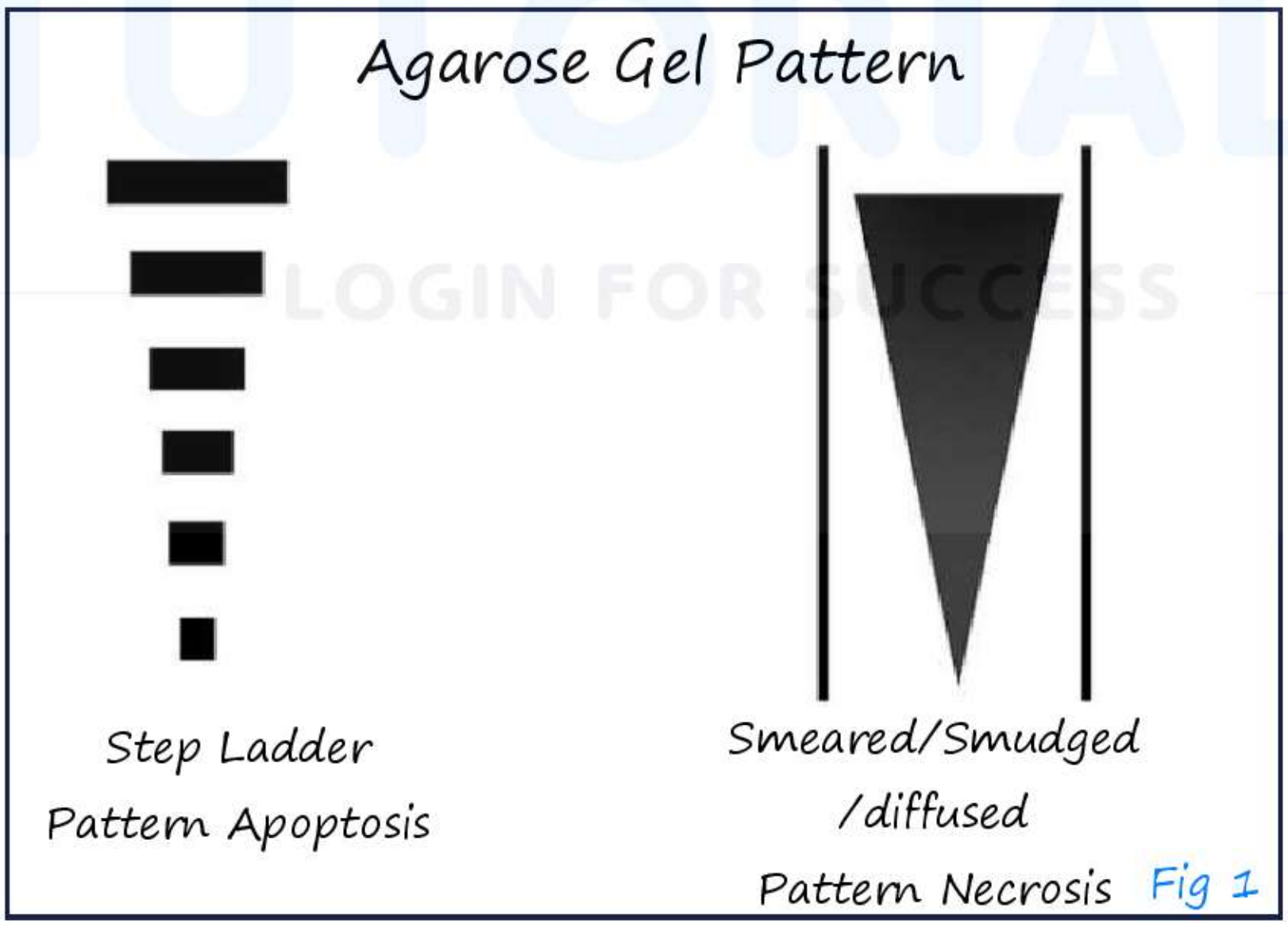

Fig 1

II. Macrophages identifies the phosphatidyl serine on the outside of the apoptotic membrane & attack the apoptotic bodies

Apoptosis

I. DNA Electrophoresis in apoptosis – step ladder pattern

II. TUNEL – Tdt mediated UTP Nick End Labeling – better & new technique

III. Hematoxylin Eosin stain – Apoptotic bodies appear pink due to absence of DNA maternal apoptotic bodies appear as eosinophilic body.

- Apoptosis is most common form of cell death in humans, examples are
  a. Embryogenesis
  b. Virus infected cells undergo

AfraTafreeh.com
TUTORIALS
LOGIN FOR SUCCESS

Apoptotic Bodies

- Viral hepatitis – Councilman bodies/acidophilic/eosinophilic bodies Lichen planus – Civatte bodies.
- Annexin V dye – this dye binds to phosphatidyl serine of apoptotic bodies.
- Most characteristic morphological feature of apoptotic bodies

↓

CHROMATIN Condensation

AfraTafreeh.com

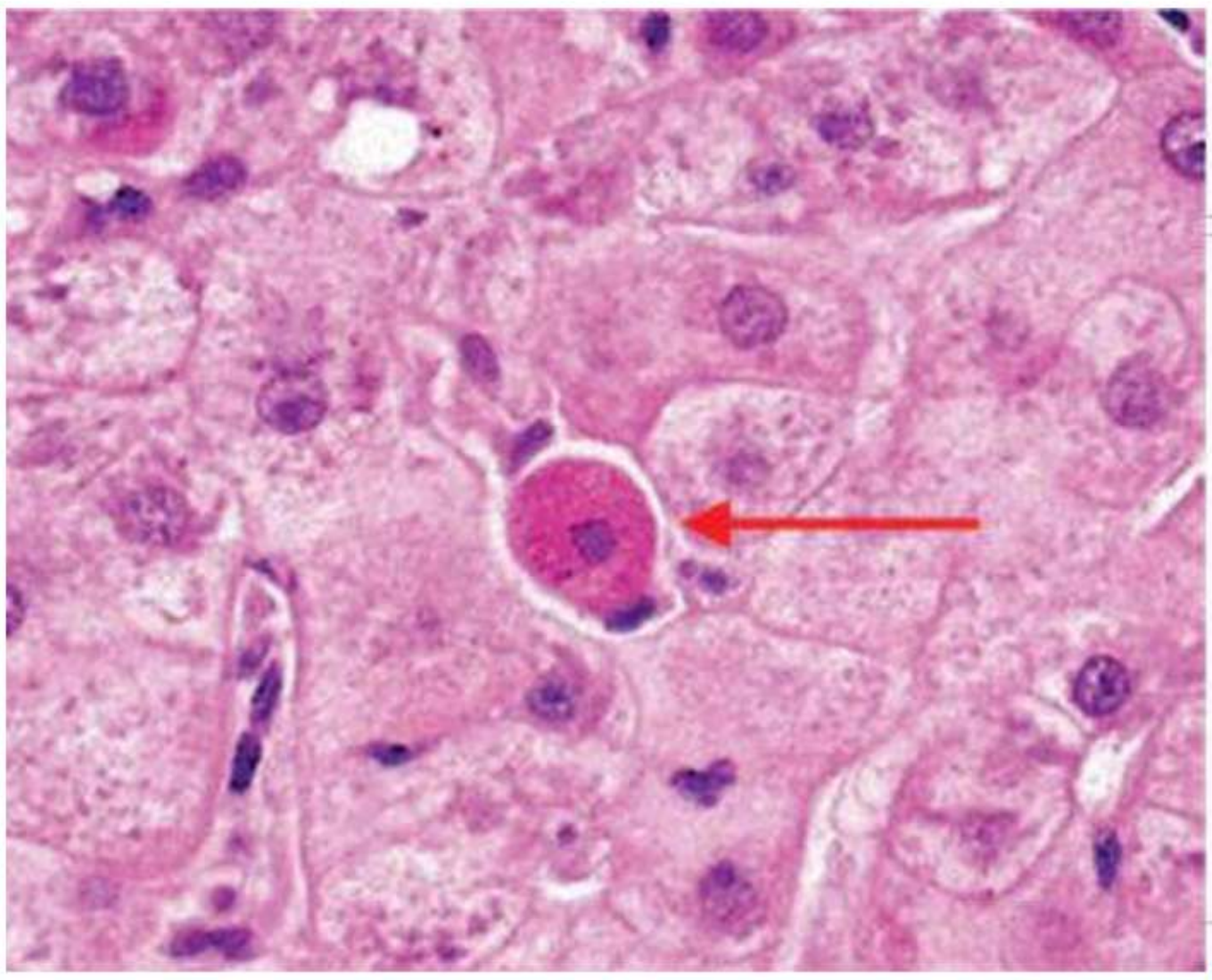

Fig 2

peripheral crescents of compacted chromatin, and others that are uniformly dense or fragmented

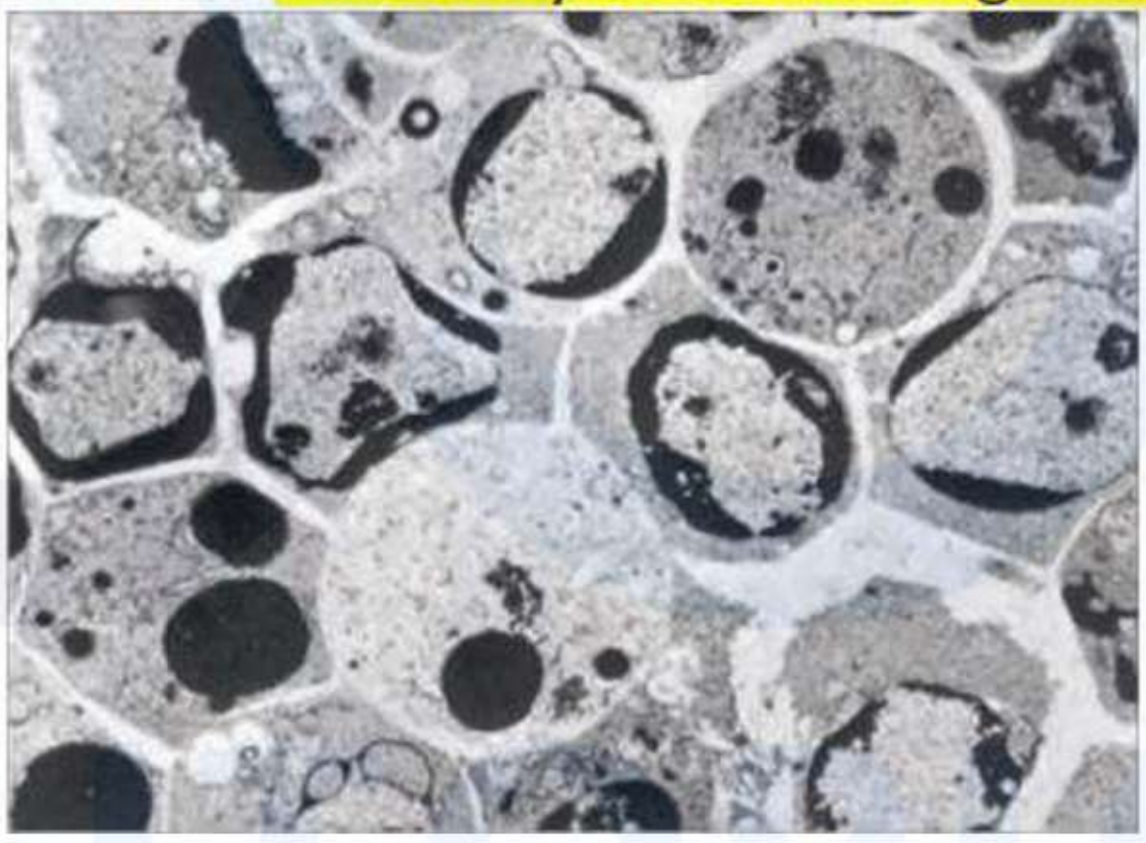

Fig 3

- Diseases associated with increased apoptosis
  - Neuro degenerative disease → Parkinsonism
  - Ischemic disease → Myocardial infection
  - Viral infection → Hepatitis.

MECHANISM OF APOPTOSIS AND VARIOUS TYPES OF PROGRAMMED CELL DEATHS, NECROPTOSIS, PYTOPTOSIS, ENTOSIS AND NET OSIS

Single for apoptosis 00:00:30

- Extrinsic pathway

  Mitochondrial signals
- Intrinsic pathway

a) Extrinsic pathway

Two types of death receptors

1) FAS
   - Death domain associated with FAS is called FADD (FAS associated death domain)
2) TNF Receptors
   - Death domain associated with TNF receptors is called TRADD (TNF related death domain)

AfraTafreeh.com
TUTORIALS
LOGIN FOR SUCCESS

Mechanism

- FAS Ligand binds to FAS-R-Activate FADD
- TNF binds to TNF-R-Activate TRADD

(both) → Activate CASPASE 8, CASPASE 10

i. CASPASE is actually a cysteine protease that attack aspartic acid

ii. CASPARE 8 was discovered in Caenorhabditis elegans bacterial caspase

AfraTafreeh.com

iii. Caspase 10 is human caspase

- CD 95 marker of FAS i.e., marker of extrinsic Pathway

b) Intrinsic pathway

- Mitochondria has two membranes
- BCL2 is an anti-apoptotic protein present in outer mitochondrial membrane
- SMAC/DIABLO, AIF, Cytochrome c present on inner mitochondrial membrane

Mechanism of intrinsic pathway

- Signal of apoptosis → loss of BCL2 → Replaced by BAX-BAK (Apoptotic proteins) → increase the permeability of mitochondrial membrane → proteins like cytochrome c moves outside
- Cytochrome c binds with AFPAF-1 (apoptosis activating factor 1)
- Cytochrome C – Apaf-1 Activates caspase 9
- SMAC/DIABLO → Inhibits the inhibiting anti-apoptotic factors of cytochrome
  - SMAC (Second mitochondrial activator of apoptosis)
  - Cytochrome C + SMAC/DIABLO → Activate CASPASE 3,6,7
  - CASPASE 3,6.7 → executional caspases
  - CASPASE 3 → Most important executional caspases

- CASPASE 8, 10, 9 → Initiatior caspases
- AIF is involved in neuronal apoptosis
- Cytochrome C – 1st mitochondrial activator of apoptosis
- SMAC/DIABLO – 2nd mitochondrial activator of apoptosis

Apoptosis

Sensors of apoptosis 00:18:08

- BAD
- BID
- BIM
- PUMA
- NOXA

AfraTafreeh.com
TUTORIALS
LOGIN FOR SUCCESS

Mediators of apoptosis

- Bc12

  Virus

  ↓ produce

  FLIP -1

  ↓ Blocks

  Caspase 8

  Apoptosis is stopped

  Once the caspase 8 is blacked then own body activates another pathway.

AfraTafreeh.com

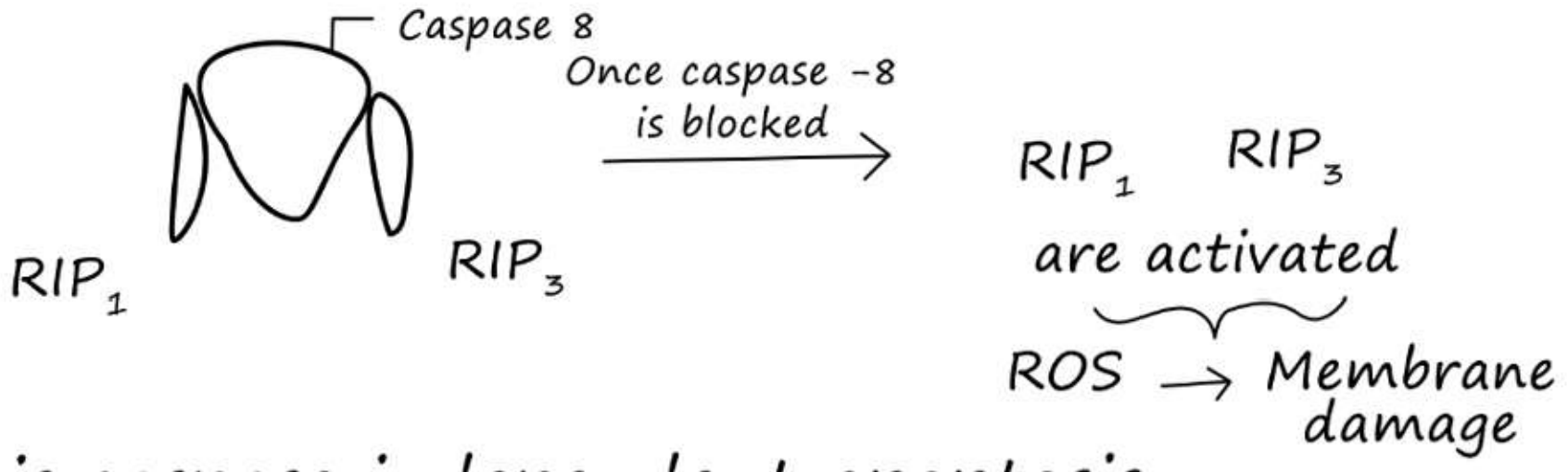

This is caspase independent apoptosis.

Necroptosis – CASPASE Independent apoptosis

00:24:39

- Type of programmed cell death
- Morphologically it is necrosis
- Mechanically it is apoptosis
- It is a programmed necrosis
- It is a caspase independent apoptosis involving RIP 1 and RIP 3 proteins which activate reactive oxygen spieces causing cell membrane damage.

Pyroptosis 00:30:46

- Type of programmed cell death
- NOD like receptors get activated → these activate inflammasome
- Inflammasome contain adapter proteins and caspase 1
- Caspase 1 and IL1 → causes fever
- Caspase 1 and 11 → activate apoptosis

Entosis 00:32:00

- Type of programmed cell death
- A process by non-macrophage cell eating another cell
- It is seen in autoimmune Hepatitis – hepatocytes phagocytose immune cells.

Emperipolesis 00:32:49

- Macrophage cell or megakaryocytic eats another cell but the cells ae viable within the macrophage.
- It is seen in ROSAI DORFMAN Disease → massive lymphadenopathy, sinus histiocytosis, emperipolesis.

Netosis

- Neutrophilic extracellular trap osis
- Neutrophils undergo apoptosis to release histones which combine with arginine to form a trap.

AfraTafreeh.com
TUTORIALS
LOGIN FOR SUCCESS

AfraTafreeh.com

NECROSIS, ITS MECHANISMS AND SUBTYPES

Necrosis: it is a morphological change in a cell after cell death

Types of necrosis

i. Coagulative necrosis 00:01:40

- It is the most common type of necrosis
- There is denaturation of proteins
- Hematoxylin stain has high affinity for proteins and cells appears pink
- Tissue architecture is preserved
- The cells are enlarged and appear as homogenously glassy
- The outline of the cells are intact – tomb stone appearance
- Seen most commonly in heart and solid organs like liver, spleen, kidney
  - Zenker's degenerative necrosis is a type of coagulative necrosis of muscle
  - Localized coagulative necrosis-infarct
  - Moth eaten appearance is seen in coagulative necrosis

Fig 1

ii.Liquefactive necrosis 00:07:32

- It is seen in brain, bacterial infection
- Enzymatic degradation of tissue
- Leads to complete dissolution cells, tissue architecture is lost

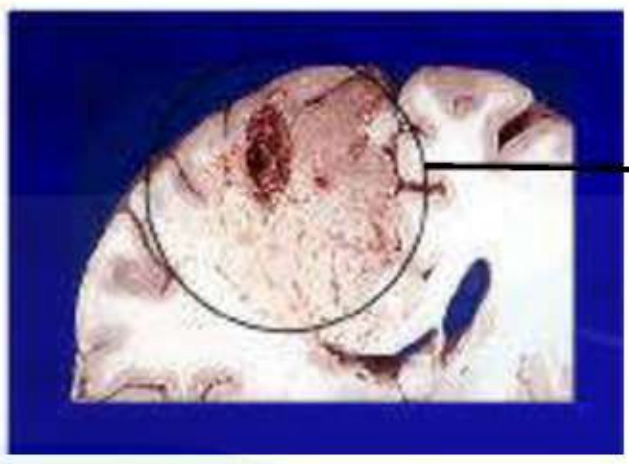

liquefactive necrosis

Fig 2

iii. Gangrene 00:13:45

- Necrosis along with putrefaction is called gangrene
- Types of gangrene

  a. Wet gangrene

  b. Dry gangrene

  c. Gas gangrene

A. Wet gangrene

- Liquefactive necrosis undergoes putrefaction: enzyme rich action seen
- No line of demarcation

Wet Gangrene

Fig 3

B.Dry gangrene:

- Coagulative necrosis undergoes putrefaction

AfraTafreeh.com
TUTORIALS
LOGIN FOR SUCCESS

AfraTafreeh.com

- Line of demarcation is present

Fig 4

C.Gas gangrene;

- It is a type of wet gangrene occurs due to gas forming organisms like klebsiella / clostridium which enter body through open wound

Fig 5

iv. Caseous necrosis 00:17:10

- "Caseous" means cheesy
- It is a variant of coagulative necrosis
- Bacteria containing high lipid content attacks tissues, leading to deposition of lipid in the tissue leading to caseous necrosis
- It is most commonly due to mycobacterium tuberculosis
- M. Tuberculosis contain mycolic acid in the cell wall
- It is also seen in histoplasmosis infection and other fungal infection

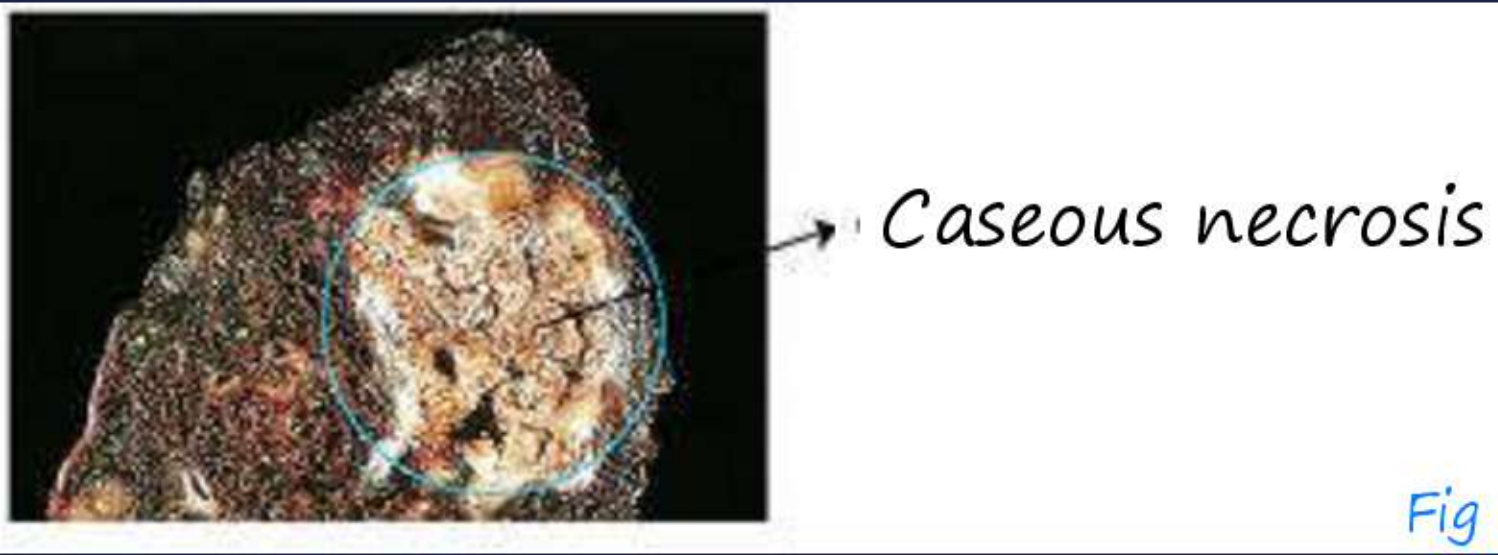

Fig 6

v. Fat necrosis 00:20:37

Fat necrosis causes:

I. Lipase action

II. Trauma

Trauma → Fat ← lipases

Saponification { free fatty acids + calcium
chalky white deposits

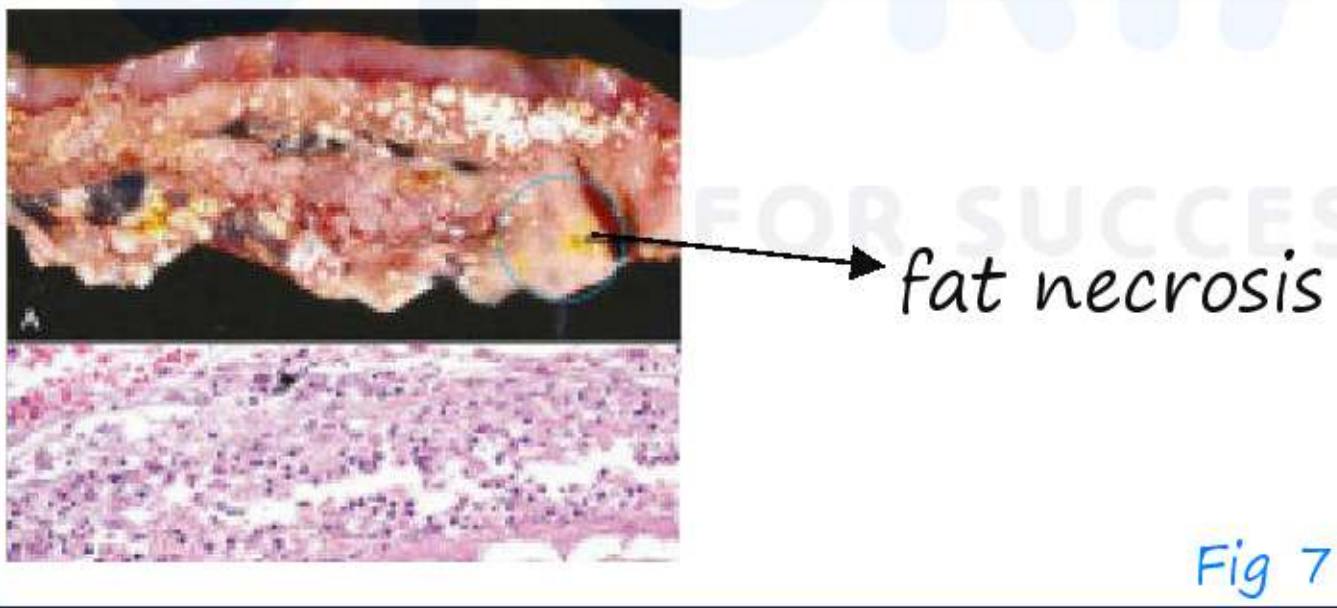

Fig 7

Example of Fat necrosis;

- Acute pancreatitis → due to lipase activation
- Trauma to fatty tissue like breast and buttocks, omentum

AfraTafreeh.com

vi. Fibrinoid necrosis: 00:24:00

Causes:

a) Malignant hypertension

b) Immune complexes

- Mechanism → damage to endothelial cells of blood vessels, leads to deposition of fibrin and inflammation
- Fibrin is made up of coagulation proteins, dead endothelial cells and inflammatory cells

• Immune complex disease commonly showing fibrinoid necrosis

i. Polyarteritis nodosa (PAN)

ii. Aschoff nodules

iii. Libman such's endocarditic in SLE

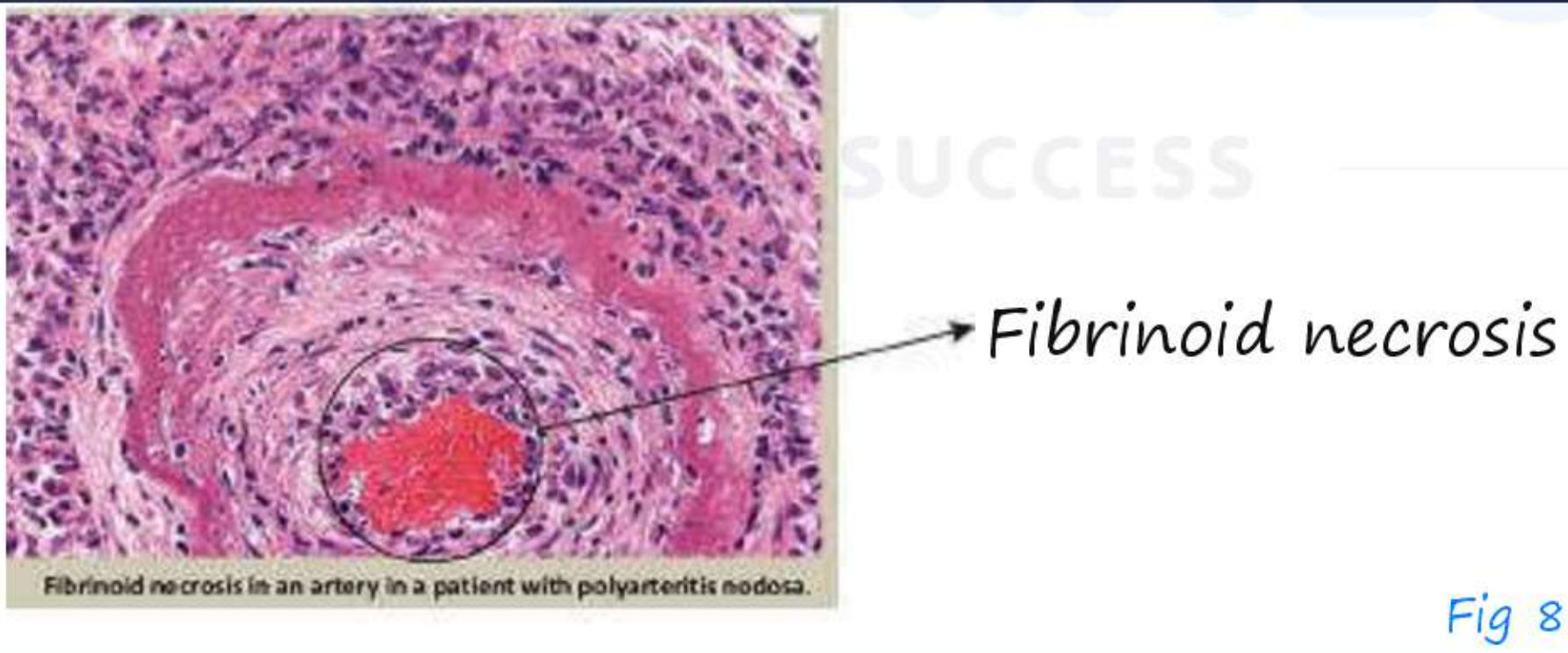

Fig 8

CELLULAR ACCUMULATION-PROTEINS

Cell accumulations 00:00:30

I. Proteins

II. Fat

III. Calcium

IV. Pigments.

I. Protein accumulation

a) Normal protein accumulated

b) Misfolded protein accumulated

a) Normal protein accumulated 00:02:00

AfraTafreeh.com

i. Resorption droplets

ii. Immunoglobulins

iii. Intermediate filaments

i. Resorption droplets - seen in nephrotic syndrome

- It is seen in proximal convoluted tubules
  - Protein accumulations

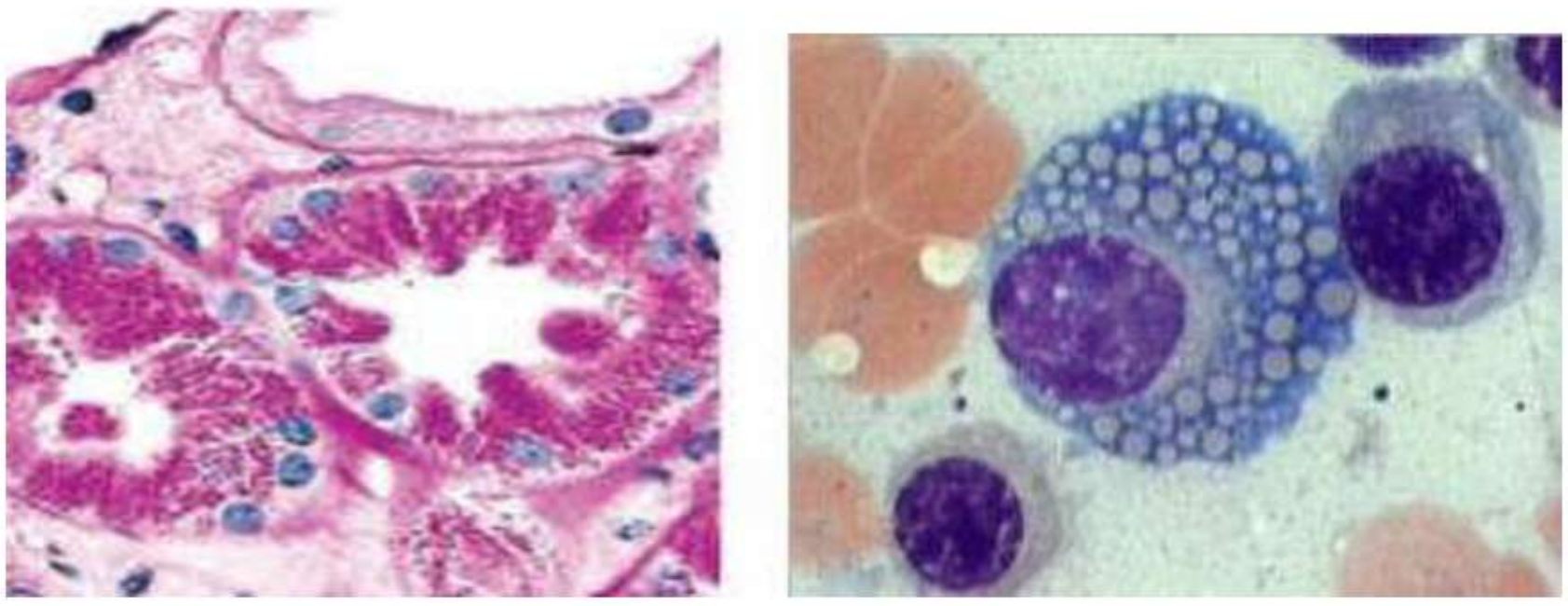

Fig 1

AfraTafreeh.com

ii. Immunoglobulins

- Plasma cell has eccentrically placed nucleus having a perinuclear halo
- The nucleus has a spoke wheel chromatin
- The perinuclear halo is due to abundant golgi apparatus
- Excess production of Ig's leads to accumulation of Ig's
- Russell bodies – these are the Ig accumulation in the cytoplasm

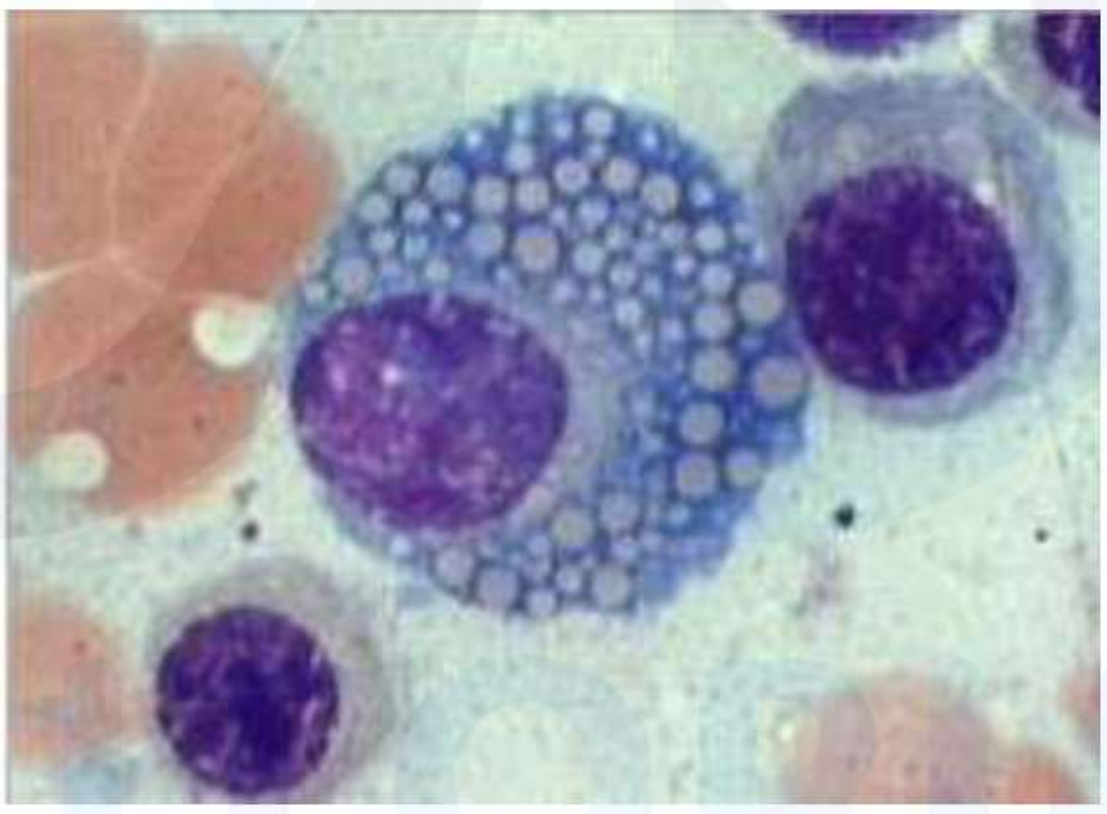

Fig 2

- Dutcher bodies – there are the Ig accumulation in the nucleus
- Mott cells are plasma cells containing multiple Russell bodies

iii. Intermediate filaments

- There are 6 normally present intermediate filament: –

  a. Cytokeratin – epithelium

  b. Vimentin – mesenchymal tissue

c. Neuro filament – Neural cells

d. Glial filament associated protein – Glial tissue

e. Lamin – Nucleus

f. Desmin – Skeletal muscle

- Mallory bodies = excess cytokeratins + ubiquitinaze in hepatocytes to form Mallory bodies

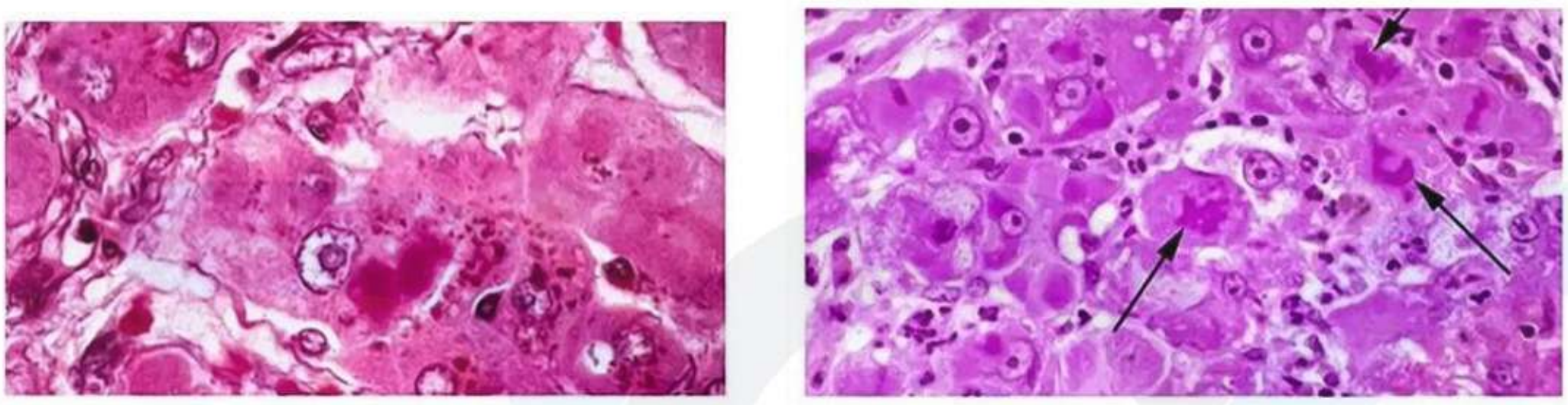

Fig 3

- Crooke hyaline – excess cytokeratin + ubiquitanize in pituitary cells of cushing disease patient to form crooke hyaline

AfraTafreen.com

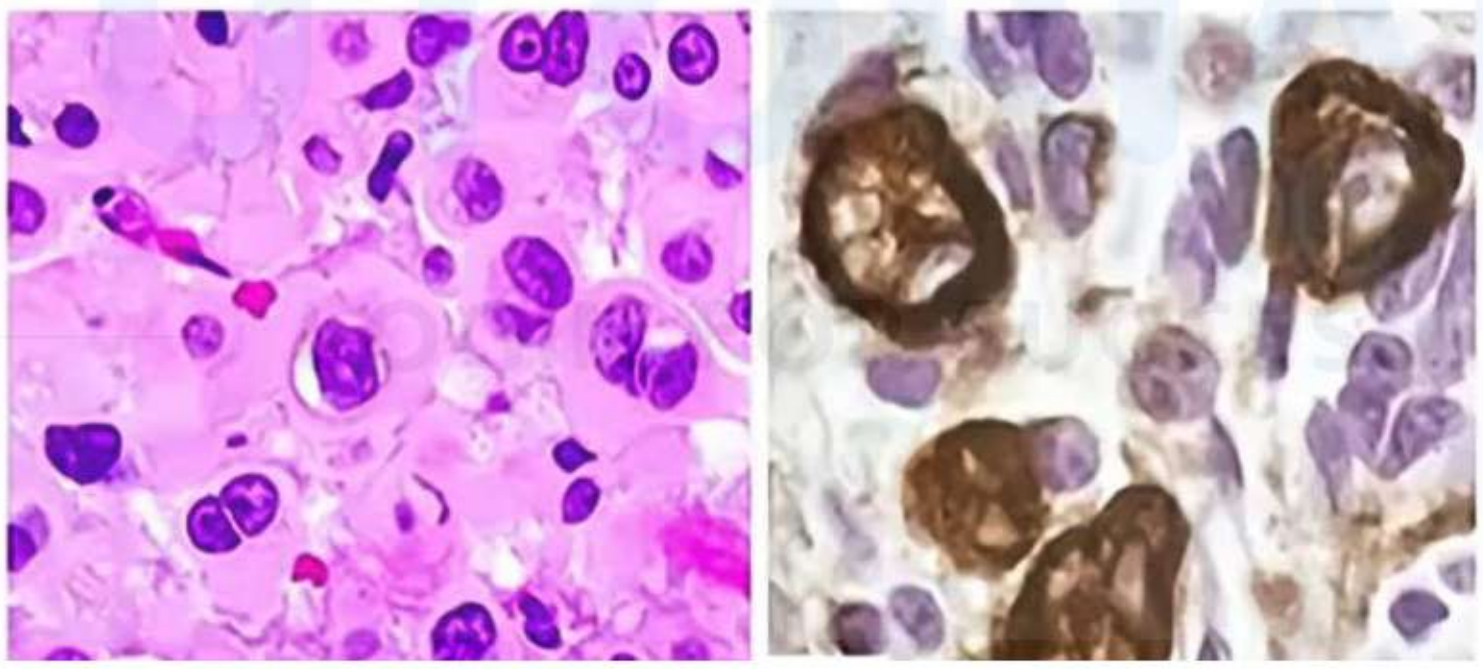

Fig 4

- Neuro fibrillary tangles – neuro filaments undergo ubiqutinization in neurons of Alzheimer individuals to form neuro fibrillary tangles.

AfraTafreeh.com

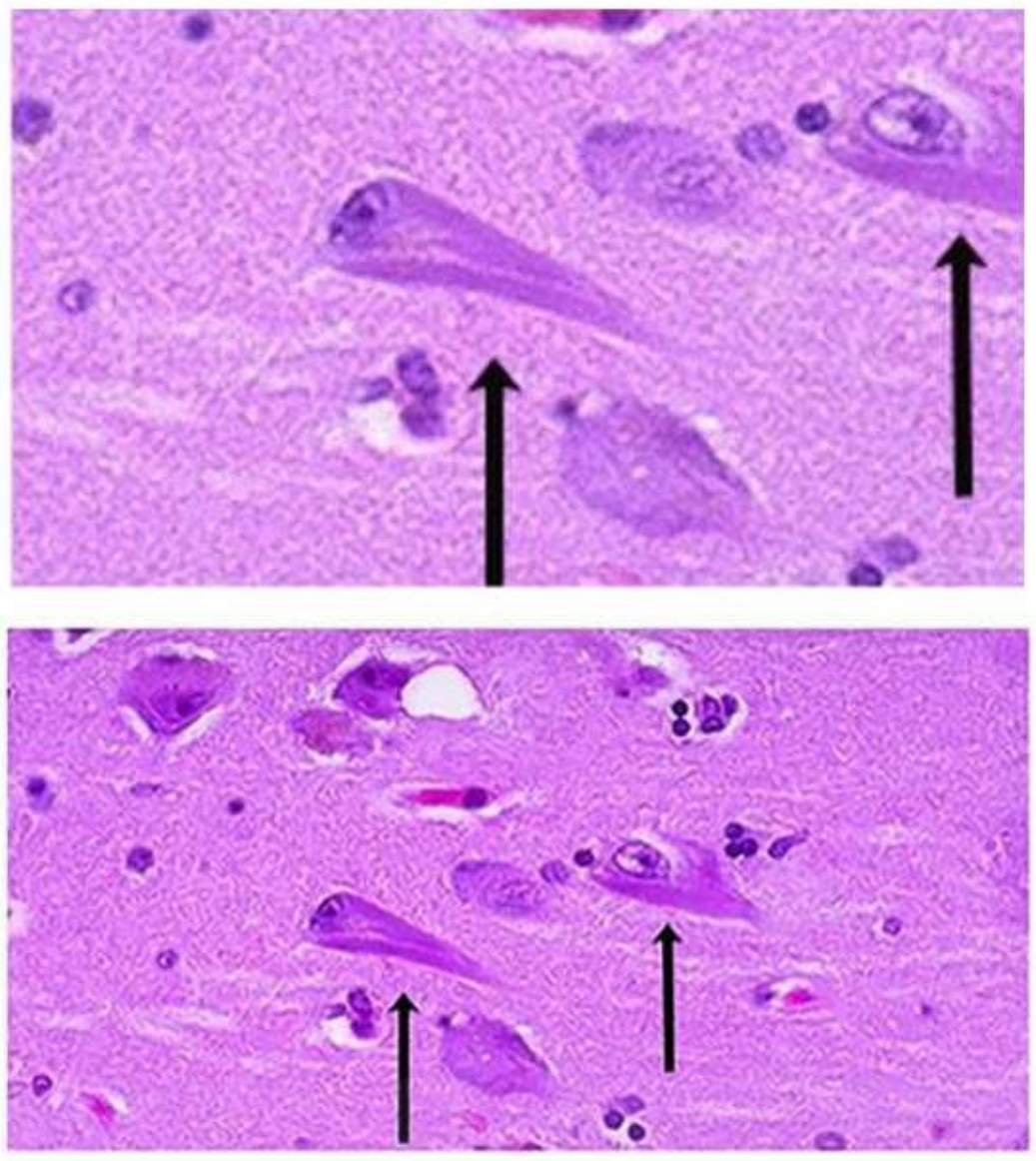

Fig 5

b) Misfolded protein accumulation 00:14:14

Deficiency	ER Stress	Both
LDL – Receptors	Alzheimer's	α1
Cystic fibrosis	Prion	Trypsin
Tay Sachs disease	Retinitis pigmentosa	deficiency

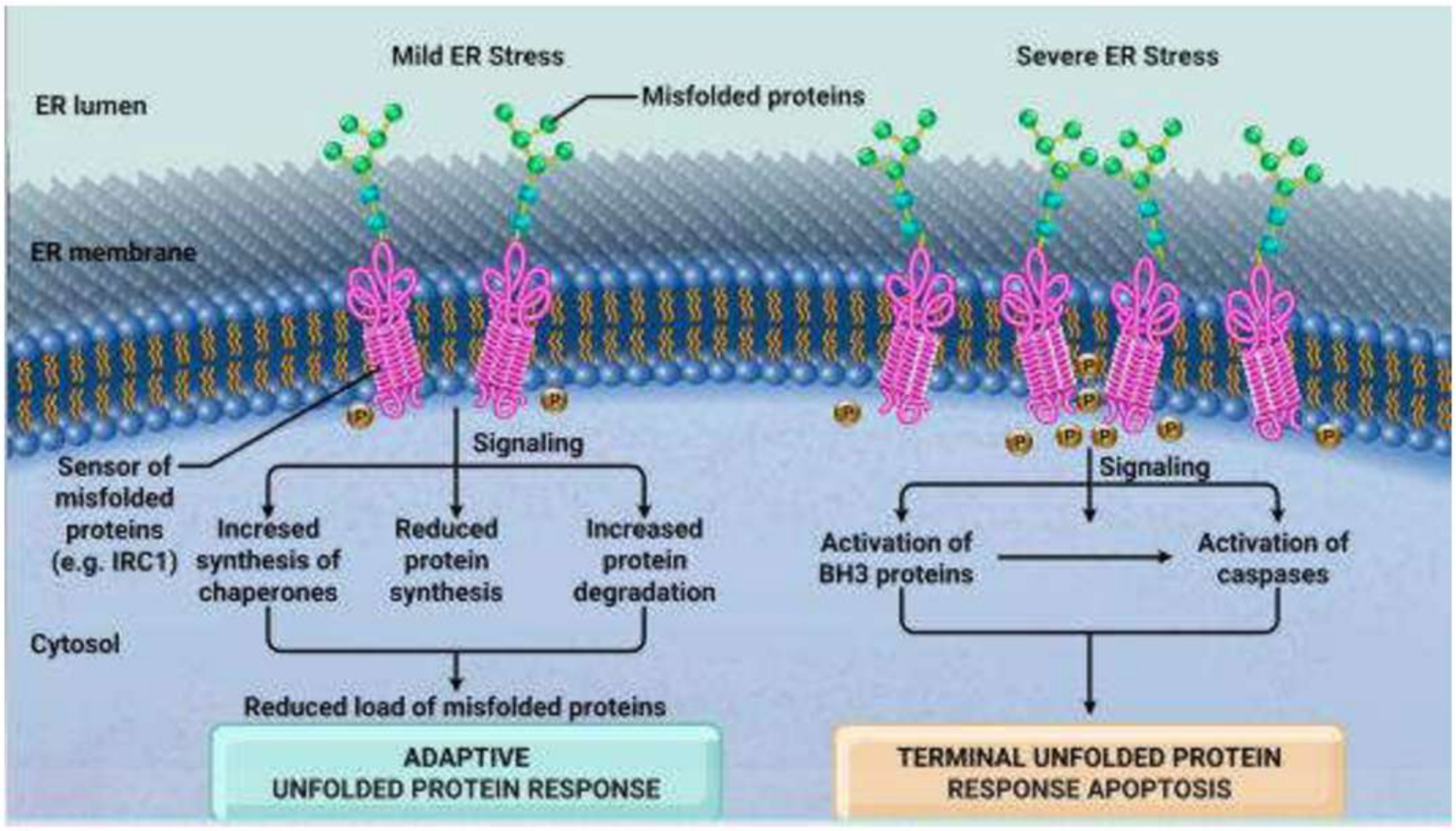

Fig 6

It is classified in three types: -

I. Endoplasmic reticulum stress (Mild)

a. Adaptive unfolded protein response

- Mild misfolded protein activates this response
- This response consists of

i. Increase number of chaperons

ii. Decrease protein synthesis

iii. Increase protein degradation

b. Apoptosis

- Severe endoplasmic reticulum stress due to excess misfolded proteins
- Activates BH3 which is a proapoptotic protein which activates caspases which cause apoptosis of cells

II. Functional deficiency

- Excess misfolded proteins lead to functional deficiency of proteins
- Example LDL receptors

AfraTafreeh.com

III. Endoplasmic stress and functional deficiency

- Example α_1 antitrypsin misfolding leads to α_1 antitrypsin functional deficiency in lungs causing pan acinar emphysema
- α_1 antitrypsin misfolding leads to endoplasmic reticulum stress in hepatocytes leads to accumulation of protein in hepatocytes – Neonatal Hepatitis.

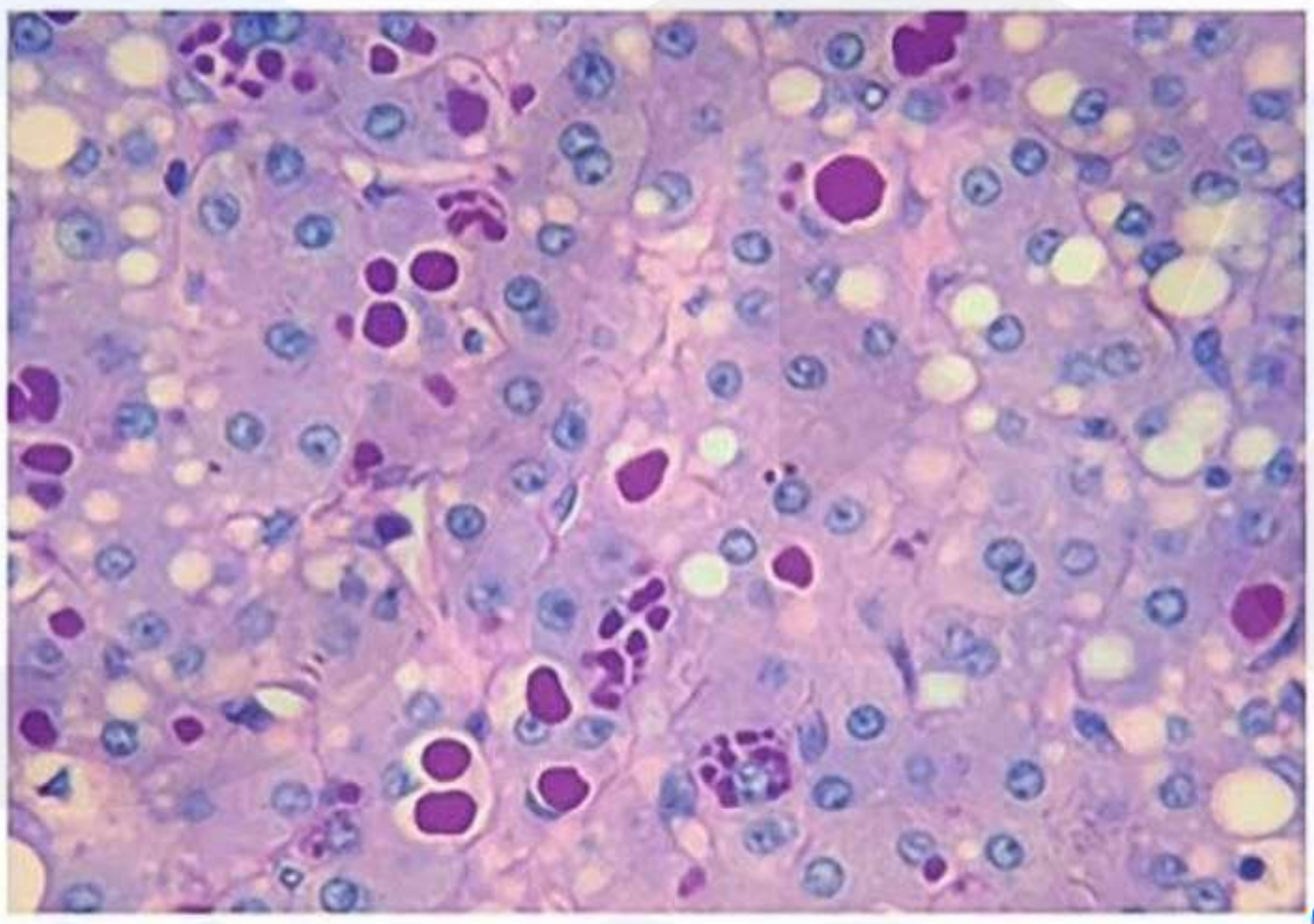

Fig 7

TUTORIALS
LOGIN FOR SUCCESS

Disease caused by misfolded proteins

Disease	Affected protein	Pathogenesis
Diseases caused by mutant proteins that are degraded, leading to their deficiency		
Cystic fibrosis	CFTR	Loss CFTR leads to defects in chloride transport and death of affected cells

Familial hypercholesterolemia	LDL receptor	Loss of LDL receptor leads to hypercholesterolemia
Try sachs disease	Hexosaminidase beta subunit	Lack of the lysosomal enzyme leads to storage of GM2 gangliosides in neurons
Diseases caused by misfolded proteins that result in ER stress induced cell loss		
Retinitis pigmentosa	Rhodopsin	Abnormal folding of rhodopsin causes photoreceptor loss and cell death, resulting in blindness
Creutzfeldt Jacob disease	Priories	Abnormal folding of PrPsc causes neuronal cell death
Alzheimer disease	A_β peptide	Abnormal folding of A_β peptide causes aggregation within neurons and apoptosis

AfraTafreeh.com
TUTORIALS
LOGIN FOR SUCCESS

AfraTafreeh.com

Diseases caused by misfolded proteins that result from both ER stress-Induced cell loss and functional deficiency of the protein		
Alpha I – Anti trypsin deficiency	Alpha – 1 Anti-trypsin	Storage of nonfunctional protein in hepatocytes causes apoptosis absence of enzymatic activity in lungs causes destruction of elastic tissue giving rise to emphysema

TUTORIALS
LOGIN FOR SUCCESS

CELLULAR ACCUMULATIONS-FATS

FAT ACCUMULATION

I. Forms of Fat accumulation 00:00:30

a) Phospholipids

b) Cholesterol

c) Triglycerides

a) Phospholipid's accumulation

- Phospholipid accumulation in the cell is in the form of myelin figures

b) Cholesterol accumulation

i. Cholesterolosis

ii. Xanthoma

iii. Atherosclerosis

iv. Nieman pick – C

AfraTafreeh.com
TUTORIALS
LOGIN FOR SUCCESS

> Foam cells – Macrophages containing cholesterol

i. Cholesterolosis – Accumulation of foam cells in lamina propria

Example: Strawberry gall bladder

ii. Xanthoma – Accumulation of foam cells in subcutaneous tissue and tendon sheaths.

iii. Atherosclerosis – Hallmark of Atherosclerosis is endothelial dysfunction – Intima is lined by foam cells forming fatty streaks

AfraTafreeh.com

Fatty streak

- Endothelial dysfunction leads to accumulation of cholesterol on endothelial cells. Macrophages eat cholesterol this leads to formation of fatty streak
- Fatty streak is a flat lesion
- Atheromatous plaque – Fatty streak over time gets covered by smooth muscle cells of tunica media of blood vessels forming a bulging lesion into the lumen of blood vessels called atheromatous plaque.
- Cholesterol clefts are found in atheromatous plaques which formed due to extra cellular cholesterol -washed away by formalin.

c) Triglyceride accumulation

- Steatosis – the process of triglyceride accumulation – reversible change
- In Liver two types of steatosis seen
  I. Micro vesicular
  II. Macro vesicular
- Steatosis in heart leads to TIGEROID pattern
- Muscles and Kidney may also shows Steatosis.

TUTORIALS
LOGIN FOR SUCCESS

Stains of FAT 00:15:44

- Oil red O stain – Frozen section / fresh
- Sudden black stain – Fixed section.

CALCIUM ACCUMULATION AND MALAKOPLAKIA AND STAINS

There are two types of calcium accumulation.

00:00:30

Metastatic calcification	Dystrophic calcification
• Excess calcium production leading to ca^{2+} deposited in normal tissue Causes i. Hyperparathyroidism -increase ca^{2+} levels ii. Renal failure • Secondary hyperparathyroidism iii. Vitamin D increase • Sarcoidosis • William's syndrome iv. Malignant metastasis to bone • Metastatic calcification occurs in alkaline media	• Normal calcium production leading to ca^{2+} deposition in dead/damaged tissue Causes i. Rheumatic heart disease – calcification of heart valves ii. Atherosclerosis – dysfunction of endothelial cells iii. Tuberculosis – shows caseous necrosis which can undergo calcification iv. Tumors

AfraTafreeh.com
TUTORIALS LOGIN FOR SUCCESS

AfraTafreeh.com

• Lungs > kidney > intestinal tissue of stomach > systemic arteries > pulmonary vein	a. Papillary carcinoma – psammoma bodies b. Meningioma – meningothelial – which show psammoma bodies

- Milk alkali syndrome also shows metastatic calcification
- Long term dialysis leads to aluminum toxicity –leads to metastatic calcification
- Immunohistochemical stain for meningioma is EMA – Epithelial membranous antigen
- Psammoma bodies are seen in

  a. Papillary carcinoma

  b. Meningioma

  c. Prolactinoma

  d. Glucagonoma

  MONCKERBERG SCLEROSIS, a type of dystrophic calcification of –tunica media

Calcium identification:

- H & E stain – calcium appears as basophilic amorphous deposits

Special stains for calcium

i. Ven kossa

- Does not bind to calcium directly
- It binds to calcium compounds
- It gives black color
- It is used for massive calcium accumulation
- It is most commonly used

ii. Alizarin Red

- It is used for less or minute quantities of calcium accumulation

Malakoplakia: 00:21:53

- Macrophages engulf E. coil lead to minute calcium deposition in the macrophages and form **Michaelis gutman bodies**
- These macrophages are called **von hanseman** macrophages
- This disorder is seen predominantly in urinary bladder
- Stain used is alizarin red.

AfraTafreeh.com

AfraTafreeh.com

CELLULAR ACCUMULATIONS (PIGMENTS)

Types of pigments 00:00:20

I. Exogenous
  i. Carbon
  ii. Tattoo

II. Endogenous
  i. Melanin
  ii. Hemosiderin
  iii. Lipofuscin

Exogenous Pigments 00:01:11

i. Carbon

- It is deposited in alveolar macrophages – DUST CELLS
- Broncho-alveolar lavage (BAL) – alveolar macrophages help in identification of bronchial tissue

ii. Tattoo

- It is deposited on dermal macrophages
- Macrophages surround these pigments and do not cause inflammation

TUTORIALS
LOGIN FOR SUCCESS

Endogenous Pigments 00:04:00

i. melanin

- it is the only endogenous black pigment
- excess of melanin pigment:

  a. Nevus

  b. Melanoma

- Absence of melanin pigment test for melanin – Albinism

i. Special stains

  a. Masson fontana stain

Masson
- Fontana → Melanin
- Trichrome → Blue – collagen, Muscle – red

AfraTafreeh.com

ii. Immuno histochemical stains – specific stains

  a. S 100

  - It is positive in cartilage, neural tissue, histiocytes, melanin

  b. HMB-45 – most specific stain for melanin

Hemosiderin 00:11:00

- It is oxidized and broken form of ferritin (which is the storage form of union)
- Excessive accumulation of hemosiderin – Hemosiderosis

AfraTafreeh.com

Types of Hemosiderosis

a. Haemochromatosis

- It is a genetic defect in HFE gene leading to excess accumulation of hemosiderin in body especially liver

b. Acquired hemosiderosis: It occurs in

i. Blood transfusion

ii. Hemolytic disease

Hemosiderosis of affects 3 organs

Pancreas	Liver	Pituitary
Hemosiderin accumulation In pancreas cause bronze diabetes	Accumulation of hemosiderin in liver leads to cirrhosis	Hemosiderin accumulation in pituitary decrease gonadotropin hormone leading to infertility

Clinical Manifestation of Hemosiderosis

i. Skin pigmentation – It occurs due to excess melanin

ii. Patients develop cardiomyopathies most common cause of death in hemosiderosis

Hemosiderosis on Histopathology

- Perls prussian blue stain
- Principle – it detects Fe^{3+} form of hemosiderosis

Lillis stain used to detect Fe^{2+}

Lipofuscin 00:30:54

- Shows perinuclear accumulation of hemosiderin
- Seen better on electron microscopy

Prussian blue reaction

- Ferric hydroxide + potassium ferrocyanide
- Ferric ferrocyanide-leads to formation of insoluble blue compound

AfraTafreeh.com

Hemosiderin laden macrophage in lungs due to heart failure called failure cells

HFE gene mutation most common mutation in hemochromatosis C282Y other – S65C,

TUTORIALS LOGIN FOR SUCCESS

Types of hemochromatosis

- Type – i: HFE related mutations

  C282Y > S65C > H63D
- Type – ii: Hemojuvelin
- Type – iii: Transferrin receptor mutation
- Type – iv: Ferroportin mutation

  This condition is autosomal dominant.

AfraTafreeh.com

AGING

Theories proposed for aging 00:00:30

i. Telomerase or senescence

ii. DNA repair theory

iii. Free radical theory

iv. Misfolded proteins

v. Metabolic theory

vi. Telomeres

Hayflick limit

- The limit up to which a chromosome can divide before telomers shortening occurs
- It is usually 60-70

i. Telomerase 00:01:00

– RNA dependent DNA polymerization

- It prevents shortening of telomeres
- It is only present in germ cell
- It is absent in stem cells but less in number
- Somatic cells acquire telomerase – cancer replication

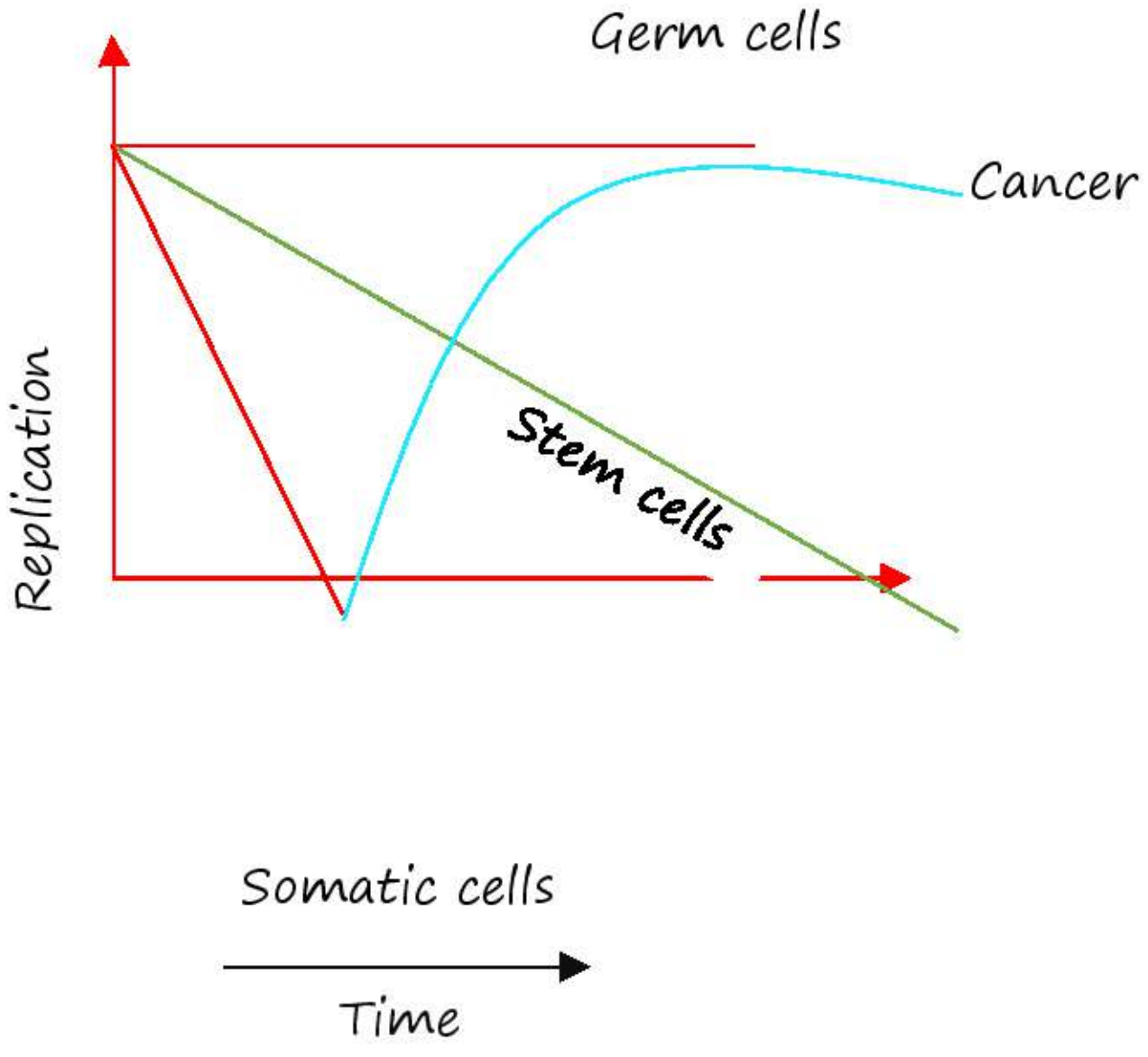

- TERT gene – gene which can elongate telomere
  - Tumors acquiring TERT gene lead to poor prognosis
  - Example is primary glioblastoma – long telomere
  - Shortened telomer – it is seen is telomere dyskeratosis congenital

AfraTafreeh.com

ii.DNA repair theory 00:10:30

TUTORIALS
LOGIN FOR SUCCESS

Premature ageing (progeria)-occurs due to DNA repair

Defect in DNA helicase (defect in WRN gene) ↓ Werner syndrome (adult progeria syndrome)	ERCC (excision repair defect) ↓ Cockayne syndrome	Lamin intermediate filament defect (LMNA gene) ↓ Hutch Gilford syndrome (acquire defect)

AfraTafreeh.com

- LMNA gene defect is involved in lamin intermediary filament defect
- Syndrome associated with DNA defect
  - i. Fanconi
  - ii. Ataxia telangiectasia
  - iii. Xeroderma pigmentosa
  - iv. Bloom syndrome

iii. Free radial theory 00:18:23

- They cause DNA damage
- It also leads to lipid peroxidation leading to formation of lipofuscin

iv. Misfolding protein 00:19:56

- Protein homeostasis defect
- Misfolded proteins accumulate in the cell and triggers endoplasmic reticulum stress and it causes ageing

TUTORIALS LOGIN FOR SUCCESS

v.Metabolic Theory 00:21:15

- Calorie restrictions leads to activate ion of sirtuins (Histone deacetylase)

Sirtuins – Histone Deacetylase

- It decreases apoptosis
- It decreases metabolic activity
- Decreases free radical injury
- It increases repairs
- It improves insulin metabolism
- Low doses of red wine induce sirtuins

All these together increase LONGEVITY

- Blocked by RAPA MYCIN
- IGF-1 causes ageing.

AfraTafreeh.com
TUTORIALS
LOGIN FOR SUCCESS

AfraTafreeh.com

INTRODUCED TO NEOPLASIA BASIS

Neoplasia 00:00:30

i. Anoikis

- A form of programmed cell death that occurs in Anchorage- dependent cells when they detach from surrounding extracellular matrix (ECM)
- Protective mechanism against metastasis

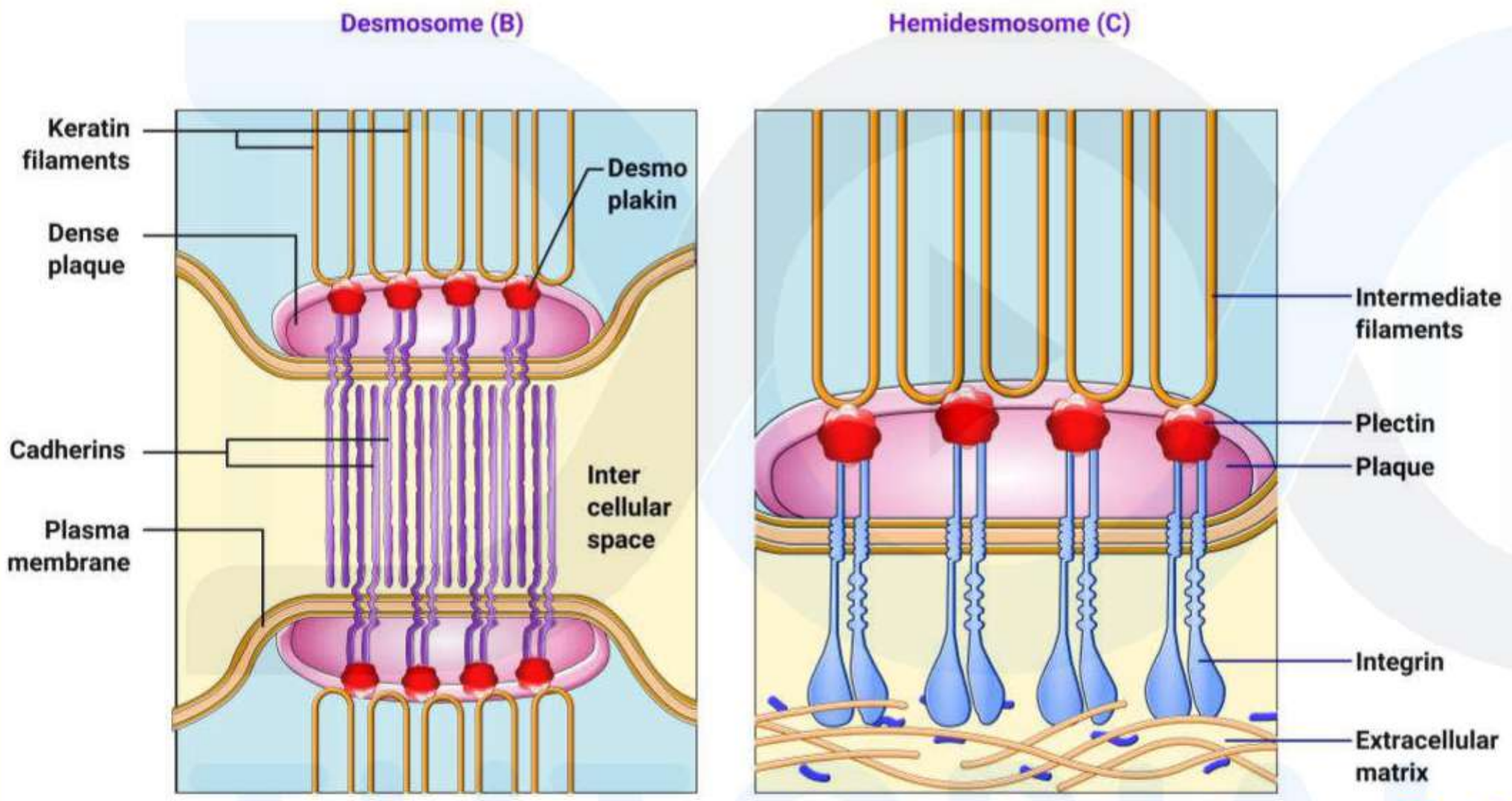

Fig 1

ii. Contact inhibition

- A regulatory mechanism that functions to keep cells growing into a layer one cell thick (a monolayer). If a cell has plenty of available substrate space, it replicates rapidly and moves freely
- Contact inhibition is lost when cells undergo malignant transformation, leading to Uncontrolled proliferation and solid tumor formation

Features of maturity	Features of Immaturity
• Have polarity • Nucleus towards Basement membrane • Tight junctions - Very important in maintenance of Polarity of cells • Differentiation - Daughter cells Always resemble parent cell • Normally-in Mitosis Bipolar mitotic	i. Loss of polarity of Nucleus ii. Loss of differentiation ↓ • Also known as anaplasia. - Anaplasia is very important • Hall mark of Malignancy. iii. Atypical Mitosis - Tripod mitosis (Second most important feature) iv. Increased N/C ratio • Prominent Nucleoli • Cells enlarged

AfraTafreeh.com
TUTORIALS
LOGIN FOR SUCCESS

Dysplasia 00:09:00

- Recognizable morphologic changes in cells that indicate the development of a Neoplasm

Intact Basement membrane in Dysplasia

- When only lower 1/3rd of Epithelium → Low grade dysplasia
- >1/3rd but <2/3 of Epithelium Involved → High grade dysplasia
- >2/3 of Epithelium Involved — Carcinoma-in-situ

AfraTafreeh.com

Neoplasia

- Basement membrane not intact
  Stain for Basement membrane
  i. PAS
  ii. Sliver methenamine (preferred stain)

Neoplasm 00:11:44

Two types

i. Benign
ii. Malignant

Characteristics	Benign	Malignant
Metastasis- Best criteria to differentiate benign from malignant	i. Absent	i. present (except BCC, glioma do not Metastasize)
Local Invasion	ii.no local invasion	ii. BCC & Glioma show extensive local invasion

Nomenclature of tumors 00:13:25

	Epithelial	Mesenchyme
Benign	denoted by suffix 'oma'	Suffix 'oma
	Eg: Benign tumor of Glandular epithelium - Adenoma	Eg: Benign tumor of smooth muscle -leiomyoma

	Carcinoma	Sarcoma
Malignant	Example: - Malignant tumor From Glandular epithelium adenocarcinoma	Example: - Malignant tumor of Blood vessels Angiosarcoma From Bone- osteosarcoma Smooth muscle -leiomyosarcoma
	Usually metastasize by Lymph nodes except RCC&HCC Spread via veins	Spread via Blood Vessels
	Any epithelial tumor is positive for intermediate filament CK (cytokeratin)	Any mesenchymal tumor will be positive for Vimentin

AraTafreeh.com

AfraTafreeh.com

OMA Entities 00:20:04

Choristoma	Hamartama	chloroma
Ectopic presence Of Normal functioning Tissue Eg: Endometriosis	i. Haphazard arrangement of tissues Indigenous to that organ	i. Extramedullary Proliferation of Blasts
	Considered as a Benign tumor of lung – Hamartoma	ii. MPO in myeloblasts emits Green color fluorescence under light hence named chloroma
		iii. Usually present in head and Neck area
		iv. Previously Chloroma was called as granulocytic sarcoma

- Most common benign tumor of lung → Hamartoma
- NOTE: Blood All the tumors are Malignant
- No Benign tumors
- Example: – Leukemias, Lymphoma

Teratoma	Biphasic
Tumor arising from totipotent cells give rise to Ecto, endo, mesoderm Example: - Dermoid cyst 1) Benign cystic teratoma 2) Predominantly has ectodermal derivatives	Show both epithelial and mesenchymal Proliferations Benign Biphasic tumor ↓ / malignant biphasic tumor ↓ Carcino sarcoma Example: 1. Pleomorphicadenoma 2. Fibroadenoma 3. Chondroid syringoma

- Stain used here is alizarin red

AfraTafreeh.com

TUTORIALS
LOGIN FOR SUCCESS

Pleomorphic adenoma

- Adenoma implies epithelial component pleomorphic implies various type of mesenchymal tissues
- Most common tumor of salivary glands

Fibro adenoma

- Fibro implies mesenchymal proliferation
- Adenoma-Ductal epithelial proliferation
- Most common benign tumor of breast

Chondroid syringoma

- Skin tumor

AfraTafreeh.com

Carcinosarcoma

- also known as metaplastic carcinomas
- malignant epithelial and mesenchymal component
- positive for both cytokeratin and vimentin
- show EMT (Epithelial-Mesenchymal Transition)
- malignant mixed Mullerian tumor (MMMT) is a type of carcinosarcoma

  Triphasic Tumors Example: Wilm's Tumor

  i. Epithelial

  ii. Mesenchymal

  iii. Blastemal.

DOC TUTORIALS
LOGIN FOR SUCCESS

MICROBIAL CARCINOGENESIS

Microbial carcinogenesis 00:00:05

Causes of carcinogenesis

- Viruses
  - DNA Virus
    - HBV
    - EBV
    - HHVB
    - HPV
  - RNA
    - HTLV-1
    - HCV
- Bacteria
  - H. Microbial carcinogenesis
- Parasites
  - ↓
  - Schistosomia
  - clonorchis sinenesis

AfraTafreen.com
DOC TUTORIALS
LOGIN FOR SUCCESS

- Merkel cell carcinoma virus.
- While bacteria and viruses produce carcinogenesis by virtue of gene alteration
- Parasites cause cancer by virtue of metaplasia

  Example: - Urinary bladder normally as transitional epithelium
- Parasite (Schistosoma) irritates lining of bladder

  ↓

  Squamous Metaplasia

  ↓

  Squamous cell carcinoma
- So, schistosomiasis causes SCC
- Similarly, Clonorchis irritates lining of bile duct causing cholangiocarcinoma

AfraTafreeh.com

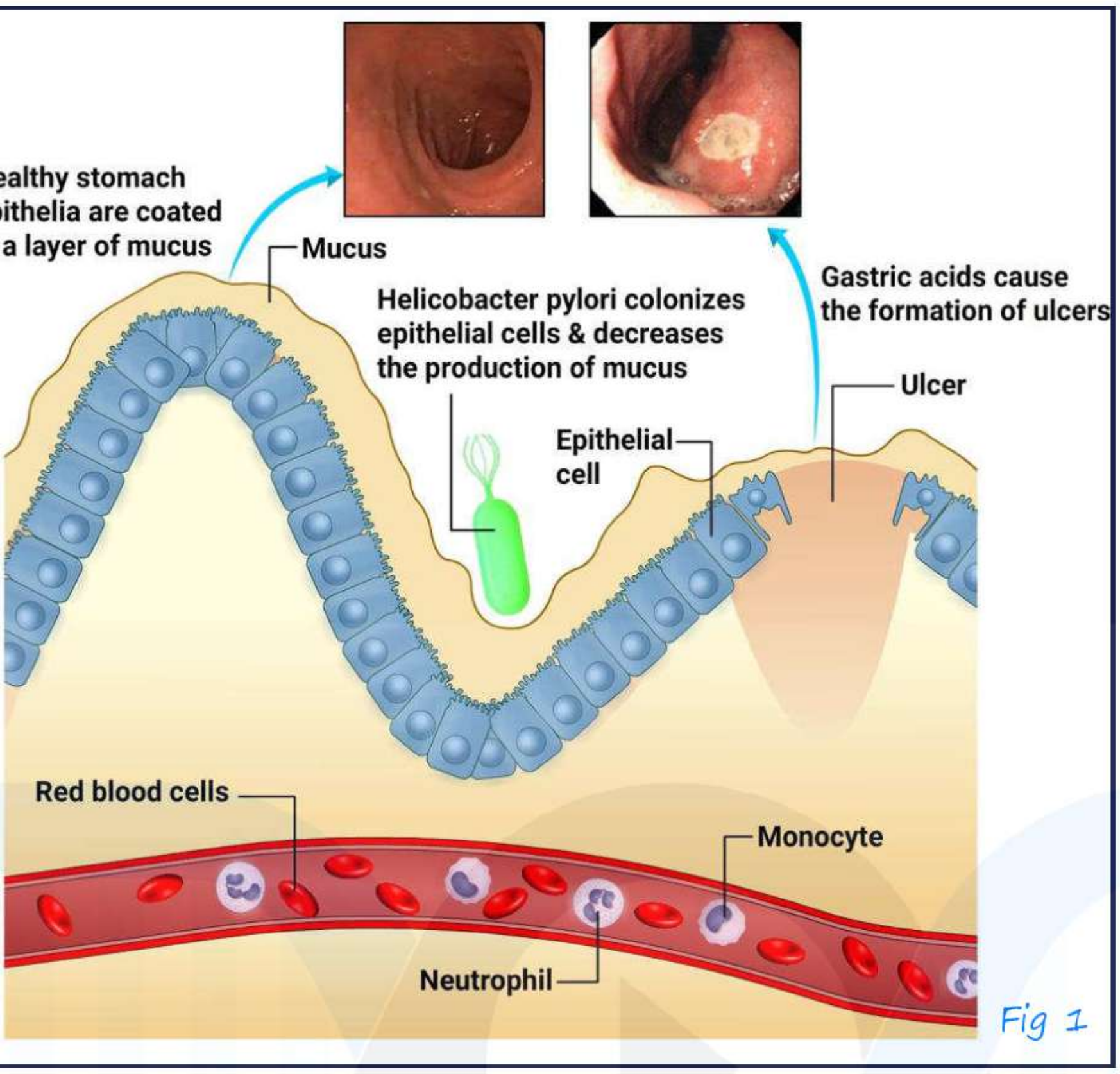

Fig 1

Pathogenesis of H.Pylori induced cancer 00:04:00

Neutrophilic infiltrate and inflammatory cells

↓

Gastric inflammation

↓

Gastritis (Type B Gastritis)

[note: Type A gastritis is autoimmume]

↓

H.pylori produces

↓

Cag A and vac A

↓

Enter into epithelial cells of stomach causing proliferation

↓

Can give rise to gastric adenocarcinoma

↓

Chronic inflammation of gastric epithelium (gastritis)

↓

T cell infiltration and activation

- Overtime T cells become independent and start proliferating and activating B cells → Development of MALToma
- MALTOMA usually arises in areas of chronic inflammation
- They can regress if injurious foci are removed.
- T (11,18) in MALToma causes increase in cell cycle and decrease in apoptosis
- This translocation is responsible for independent proliferations of T cells

AfraTafreeh.com
TUTORIALS
LOGIN FOR SUCCESS

Easiest stain to visualize H.pylori

- Modified giemsa stain or
- Sliver stain like warthin starry
- Steiner stain

AfraTafreeh.com

Viruses induced cancer

RNA viruses

HTLV-1
↓
Produces TAX
↓
Causes proliferation of T cells
↓
Adult T cell lekumia/lymphoma

HCV
Predeliction for CD4 T cells
↓
'scant' indention of nucleus of CD4 T cells
↓
'Flower cells / 'clover leaf cells'

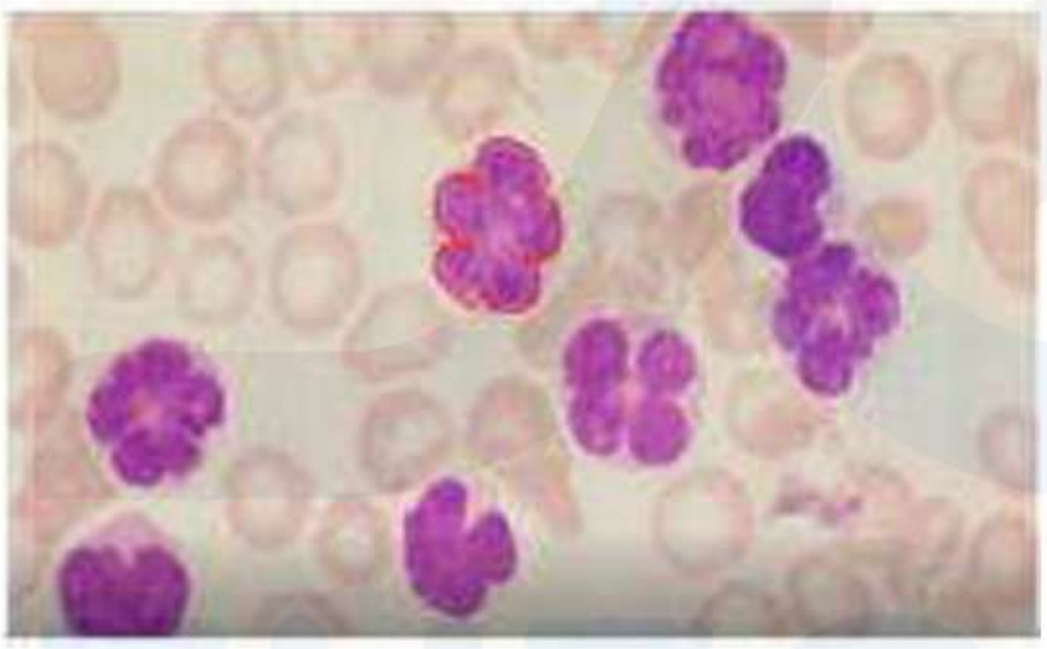

Fig: 2

- HTLV-1 - Flower cells
- HTLV2 causes tropical spastic paraparesis

LOGIN FOR SUCCESS

HCV – Hepatitis – C virus 00:15:00

- Rapid damage of cells followed by extensive proliferation major pathway of HCV causing cancer
- Causes Hepatocellular carcinoma (HCC)
- Highest risk of transfusion transmitted infection is of Hepatitis – C virus.

- (Remember – Hep B is the most common transfusion transmitted Hepatitis.)
- Antigen to be tested for presence of HCV is NS5a

DNA VIRUSES

HPV HBV EBV HHV8 MERKEL

Cell carcinoma virus

↓ causes

Merkel cell carcinoma

- Merkel cell carcinoma
  - Neuro endocrine tumor of skin
  - Occurs in elderly > 70 year
  - Small round cell tumor
  - High grade
  - NET = Salt and pepper chromatin
  - Poor prognosis

AfraTafreeh.com
TUTORIALS
LOGIN FOR SUCCESS

HHV-8 00:19:25

- Typically co-infects with HIV
- Produces 2 cancers
  - Kaposi sarcoma
  - Primary effusion lymphoma

Primary effusion lymphoma

- Presents as malignant effusions of the body cavities

AfraTafreeh.com

- Patients diagnosed often have a compromised immune system from secondary conditions such a HIV
- PEL is negative for B cell markers
  Negative for T cell markers
  But uniquely positive for plasma cell markers – CD38 and CD138 also positive for CD30
- Kaposi sarcoma – can be caused by HIV alone or HHV-8

Four types

i. Sporadic
ii. Endemic } caused by HHV-8
iii. Transplant associated
iv. HIV associated Kaposi sarcoma → only caused by HIV

Type 1

- Is sporadic Kaposi sarcoma
- Can occur in any race
- Typically occurs in skin

Type 2

- Endemic
- Typically, in africans and involves lymph nodes

Type 3

- Transplant associated

- Can involve multiple sites.

Hep-B virus 00:20:24

- Main pathogenesis – common to both HBV is damage followed by proliferation
- HBV produces a gene HBX
- Causes transactivation of viral and host genes → HCC

HPV 00:23:50

HPV produces

E6 E7

AfraTafreeh.com

- Normally E2 keeps E6 and E7 under control
- When E2 is repressed, E6 and E7 get activated

TUTORIALS
LOGIN FOR SUCCESS

E6

Blocks p53

Activates TERT gene

↓

TERT gene elongates telomers

↓

Extends life of cancerous cells

AfraTafreeh.com

E7

- Binds to RB gene
  ↓
  E_2F is free
  ↓
  Cell cycle proliferates
- CDKN1 Family
  - P21
  - P27

  Blocked
  ↓
  Cyclin D active
  ↓
  Cell cycle proliferation

Cyclin D is regulated by
- P_{21}
- $CDKN_2A$ (P 16)

- When p_{21} is blocked by E_7 → cyclin D is kept in control by $CDKN_2A$ [P 16]
- So, levels of p16 rise in HPV infection. This acts as a surrogate marker to identify HPV infection.

  This is assessed on IHC

  ↓

  Antibody against p_{16} is elevated in cells

  ↓

  All cells become brown in color

  Indicating raised p_{16} is levels in HPV infection

  HPV infected cells show a very typical morphological change
- Koilocytes (infected squamous cells)
- Nucleus becomes raisinoid with peri nuclear halo
- HPV can cause SCC cervix/vagina/penis

Laryngeal carcinoma and warts

Ebstein Bar Virus (EBV) 00:34:35

Ebstein bar virus (EBV)

↓

Infects B cells via CD_{21} receptor/CR_2

↓

Induces 3 genes

LMP1

1) Behaves like constitutive CD40L + CD40R (B cell)

↓

B cell proliferation

2) Activate NF-KB pathway

↓

B cell proliferation

EBNA2

↓

Activates cyclin D

↓

Cell cycle proliferation

↓

B cell proliferation

<u>Update:</u>

SRC protooncogenes Are activated by $EBNA_2$

SRC protooncogenes

↓

Oncogenes

Viral IL 10

↓

Viral IL 10

↓

Usually Suppresses Inflammation

↓

Tumor cells proliferate extensively

LMP1 + EBNA2 → Extensive proliferation of B cells

AfraTafreeh.com

- CD8T cells are activated to check the ex
- cessive proliferation of B
- These CD8 have a typical appearance resembling ballerina skirt thus named 'ballerina skirt cells as downey cells kill infected B cells

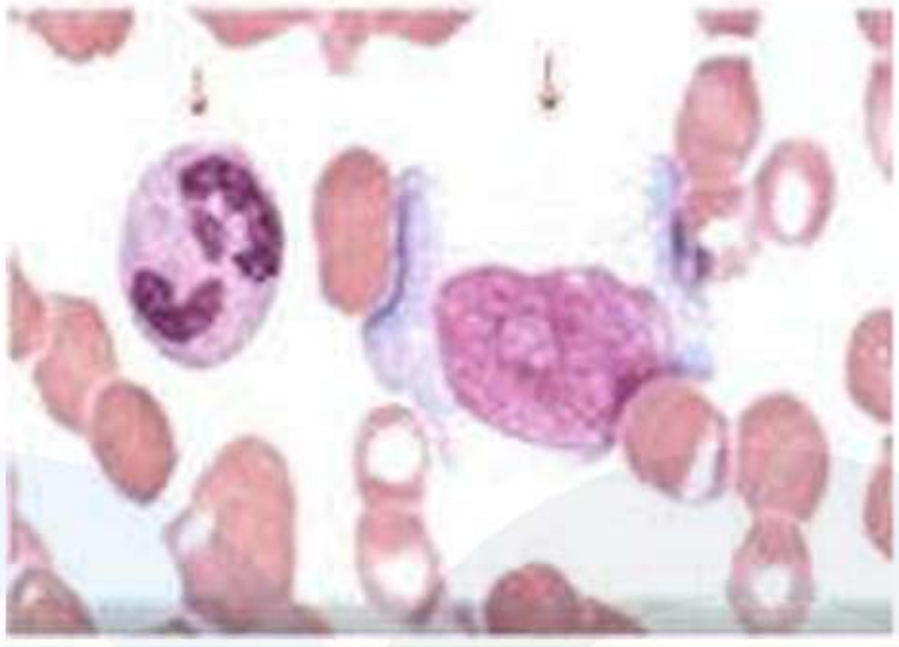

Fig 2

(Downey cells – Activated CD8T cells which kill infected B cells)

- In some unfortunate conditions when B cells are proliferating additional mutations occur.

Proliferating B cells

t(8,14)	REL	BCL-6
↓↓	Protooncogene	activated
Activates c-myc (Transcription activator)	activates	DLBCL
↓↓	↓↓	Immunoblastic lymphoma
Increases proliferation Burkitt's lymphoma	Hodgkin's lymphoma	

TUTORIALS LOGIN FOR SUCCESS

EBV can also cause

i. (NK/T cell lymphoma)

- Usually occurs in nasal cavity
- Very aggressive lymphoma
- Also called as lethal midline granuloma

ii. Epithelial cancer-

a. Nasopharyngeal carcinoma

b. Gastric ca

(Gastric ca Most common cancer caused by EBV)

iii. Sarcomas-leiomyosarcoma.

AfraTafreeh.com
TUTORIALS
LOGIN FOR SUCCESS

AfraTafreeh.com

RADIATION CARCINOGENESIS

Radiation Carcinogenesis 00:00:05

Radiation

Non-Ionising
UV
↓
Cause cancer by forming Pyrimidine dimers

Ionising
Alpha, gamma, CT scans
↓
Cause direct DNA

UV Rays

UVA – 320-400 → used in PUVA therapy for psoriasis

UVB – 280-320 → causes cancers in humans

UVC – 200-280 → filtered by the ozone layer

UV-B → pyrimidine dimers
↓
Corrected by NER-Nucleotide excision repair mechanism
↓
Prevents cancer

- NER defects seen in patients with xeroderma pigmentosa
- These patients present with multiple UV radiation caused cancers
- SCC, BCC, Melanomas

Gorlin syndrome

- 'PATCHED' gene defect

- Presents with multiple BCC
- Brain tumors
- Medulloblastoma
- Also known as nevoid basal cell carcinoma syndrome

Ionizing radiation 00:05:23

↓

- Cause double stranded DNA breaks

  Cancer produced

  i. Most common leukemia after a latent period of approximately 7 years

  ↓

  Especially AML

  Remember – CLL never occurs after radiation

High risk

AfraTafreeh.com

Solid malignancies

- Most common thyroid papillary carcinoma especially in children
- Latent period of solid malignancies is more

  High risk malignancies –

  i. Leukemia (AML)

  ii. Papillary carcinoma thyroid

High risk

Low risk malignancies

- Some organs are relatively resistant to radiational cancers
- Skin, GIT, Bone

AfraTafreeh.com

Intermediate risk

Breast – Gene $CHEK_2$ in breast – This gene keeps on checking for radiational injuries

- So CHEK2 mutations are very common in radiation induced breast cancers.

TUTORIALS
LOGIN FOR SUCCESS

CHEMICAL CARCINOGENESIS AND AMES TEST

Etiology of Cancers 00:00:05

Etiology of cancers

- Genetic
- chemical
- radiation
- microbial

Chemicals 00:01:35

Chemicals

Directly acting carcinogens
↓
Cause DNA Damage
↓
Example: Anti-cancer drugs
i. Alkylating agents
ii. Chlorambucil
iii. Topoisomerase inhibitors
Usually cause AML

Indirectly acting carcinogens
↓
Produce metabolite A which is the ultimate carcinogen
↓
Causes cancer

AfraTafreeh.com

- Ultimate carcinogen is A carcinogen which is produced by metabolization

AfraTafreeh.com

- Chemical metabolize to produce a product A which causes cancers, such chemicals are called Indirectly acting carcinogens

  Example:

  i. Benzopyrenes present in 'soot' cause squamous cell carcinoma of scrotal skin, also released due to smoking
  ii. Benzanthracene
  iii. Griseofulvin
  iv. Aflatoxin
  v. Thorotrast causes angiosarcoma.

Aflatoxin 00:05:59

i. Found in the nuts stored for prolonged duration
ii. Causes mutation in P53 by typically affecting codon 249 (Signature mutation of Aflatoxin)

- At codon 249 Arginine → serine (Arginine is replaced by serine)

CLASSIFICATION OF INFLAMMATION AND MECHANISM OF INFLAMMATION

Signs of inflammation 00:09:20

- Red, hot, pain, swelling – given by Celsius
- Loss of function – given by Virchow

Two types of inflammation	
I Acute	II Chronic
• Most common cell involved neutrophils • Exception **typhoid** • Hallmark of acute inflammation is increase **Vascular permeability** • Short lived	• Most common cells involved mononuclear cells i.e Macrophages • Exception **pseudomonas infection** • **Hallmark of chronic inflammation is tissue destruction** • Long lived

AfraTafreen.com

I. Acute inflammation

It has 3 phases

1.Intravascular

2.Trans vascular

3.Extravascular

AfraTafreeh.com

Intravascular phase 00:06:11

- It has 2 major events

  I. Vascular

  II. Cellular

Vascular events – changes in blood vessel.

00:06:57

a. Vasoconstriction – it is a reflex mechanism of body

b. Vasodilation – Predominantly seen in arterioles and also causes more blood to reach the tissues.

  - Histamine molecule is a mediator which increases the vasodilation.
  - Increase vascular permeability – This occurs predominantly in post capillary venules and it makes more fluid go out of the vessel so that only cells are left which is called stasis.
  - Permeability can be increased depending upon cause of injury, and this cause decides the mechanism of permeability.

Vascular permeability 00:13:50

- Causes/mechanism

  1. Endothelial contraction

     - Most common cause of vascular permeability
     - Immediate transient response (ITR).
     - It is mediated by histamine

- Example: Thorn prick

2.Endothelial damage/Necrosis/Endothelial death

- Immediate sustained response (ISR)
  Example: Burns, Bacterial infections

3.Mild endothelial injury

- Delayed prolonged response (DPR).
  Example: Sunburns – late appearing sunburns are due to ultraviolet light causing mild endothelial injury

4.Leukocyte mediated injury

- Late appearing and long lived response
  Example: seen in lungs-Acute respiratory distress syndrome and happens in pulmonary capillaries of lungs which causes hyaline membrane disease.

5.Transcytosis

- Vesicovacuolar/vesicovenular channels- These channels are present in interendothelial space.
- Increase in number of these channels leads to increase the fluid leakage and ion through them. This process is termed as transcytosis
- It is mediated by VEGF (Vascular endothelial growth factor)
  Retraction:This is due to cytoskeletal reorganization and done by interlukin & TNF.

Cellular events of acute inflammation – changes in cell. 00:29:20

1.Margination

- Inflammation cells move to periphery of vessel mediated by tumor necrosis factor (TNF) and interleukin 1 (IL1)
- These mediaters will cause expression of certain adhesion molecules and make the cells sticky so these are called selectins.

2.Selectins – CD-62 markers required to identify the selectins.

Types of selectins 00:31:39

1.Selectin p

- Present in **platelets and endothelial cells**.
- In alpha granules of platelets p-selectin is present
- In weibel palade bodies of endothelial cells p-selectin is present

2.Selectin E

- Predominantly found on **endothelial cells**
- Most important selectin on endothelium in acute inflammation

3.Selectin L

- This selectin is present on leukocytes
- It has strong affinity for glycam-1 and madcam-1 on endothelium

TUTORIALS LOGIN FOR SUCCESS

- It also has affinity for sialyl lewis x
- It is also involved in the process of homing

I. Rolling: predominant phenomena done by selectins. 00:38:25

- Sialyl lewis x-carbohydrate moiety's present on all cells have an antigen called sialyl lewis x.
- Selectins stick on SLX of endothelial cells forming a transient bond in the process of rolling.

II.Adhesion 00:40:58

- It is the firm binding of inflammatory cells to the endothelial cells
- Integrins involved in the process of adhesion

AfraTafreeh.com
TUTORIALS
LOGIN FOR SUCCESS

Types of integrins 00:41:52

- β1 integrin is also called as VLA4 molecules
- β2 integrin is also called as LFA & Mac molecules
- VCAM-1 and I CAM-1 present on endothelial cells
- VCAM-1 forms a complementary strong bond with VLA4 molecule
- Similarly, I CAM-1 forms a complementary strong bond with LFA1Mac molecule
- This bond is called as adhesion
- **LFA1 & Mac molecule identify by CD11 and CD18 respectively**

AfraTafreeh.com

Molecules	Function	
Glycam-1 Mad cam-1	Involved in the process of rolling	They belong to immunoglobulin family
V cam-1 I cam-1	Involved in the process of adhesion	
PECAM-1	Involved in the process of Transmigration	

III. Transmigration/Diapedesis 00:46:28

- PECAM-1 is a molecule present on endothelium of the vessel wall which allows the movement of inflammatory cells from intravascular to extravascular by the process of diapedesis
- PECAM-1 can be identified by **CD31**
- Selectins attach to both WBC and endothelium
- Integrins are present **only on inflammatory cells.**

TUTORIALS
LOGIN FOR SUCCESS

MECHANISM OF INFLAMMATION

Extravascular phase 00:00:15

- Chemotaxis – It is defined as unidirectional movement of WBC towards site of injury under effect of chemokines.

  a. Chemokine

C: denotes cysteine X: denotes other amino acids	Peptide chain Disulfide bond

Types of chemokines 00:02:49

AfraTafreeh.com

1. A chemokine (alpha chemokine)

   - CXC

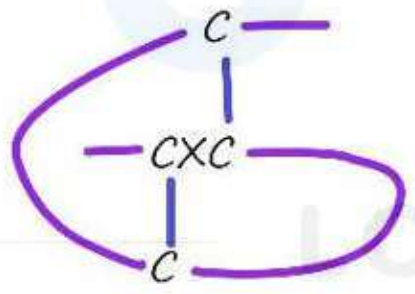

   - These act only on Neutrophils

     Example: IL-8

2. β – chemokine (beta chemokine)

   - CC

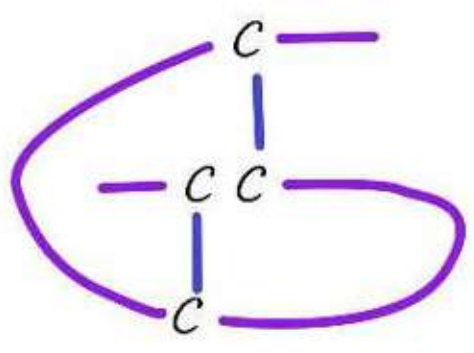

AfraTafreeh.com

- Act on all WBCs **except neutrophils**

  Example: - eotaxin – acts on eosinophil's

  Monocyte chemo attractant protein [MCP]

  Rantes – Acts on T-lymphocytes

3.γ-chemokine (gamma chemokine)

- c

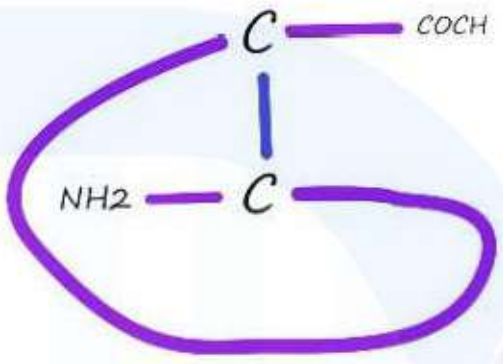

- example: Lymphotaxin

4.fractalkine CX3 C

- Specific cells for specific infections
  - Bacterial – Neutrophils
  - Viral-Lymphocytes
  - Parasite-Eosinophil's
  - Tuberculosis-Mono phages

Types of chemotactic molecules 00:06:06

I. Exogenous

a. Bacterial products

II. Endogenous

a. Chemokine

b. Complement proteins

c. LTB4

III. Complement proteins

- C5 a
- C3 a
- C5 a is more potent than C3 a
- C5 a the most potent anaphylotoxin

IV. LTB4

- It is a leukotriene obtained from lipoxygenase pathway

Neutrophils enhanced traps (NET) 00:10:05

- Neutrophils reach the foci of infection and form net
- This net is a result of histone and arginine released by the programmed cell death of neutrophils
- This trap help to keep the mediations localized at site of injury
- In these traps, the infections agent undergoes phagocytosis
- This process is call NET osis
- Over expressive/NET osis leads to uncontrolled autoimmune disease.

AfraTafreeh.com
TUTORIALS
LOGIN FOR SUCCESS

Phagocytosis 00:12:46

Steps

I. Recognize

II. Engulf

III. Kill

AfraTafreeh.com

Recognize 00:13:45

- Occurs by two mechanisms

  1.Opsonization

  2.Mechanism other than opsonization

1.Opsonization

- It is the process by which certain molecules known as opsins coat the harmful cell which is recognized by WBC and killed by phagocytosis.
- Opsonization facilitates phagocytosis

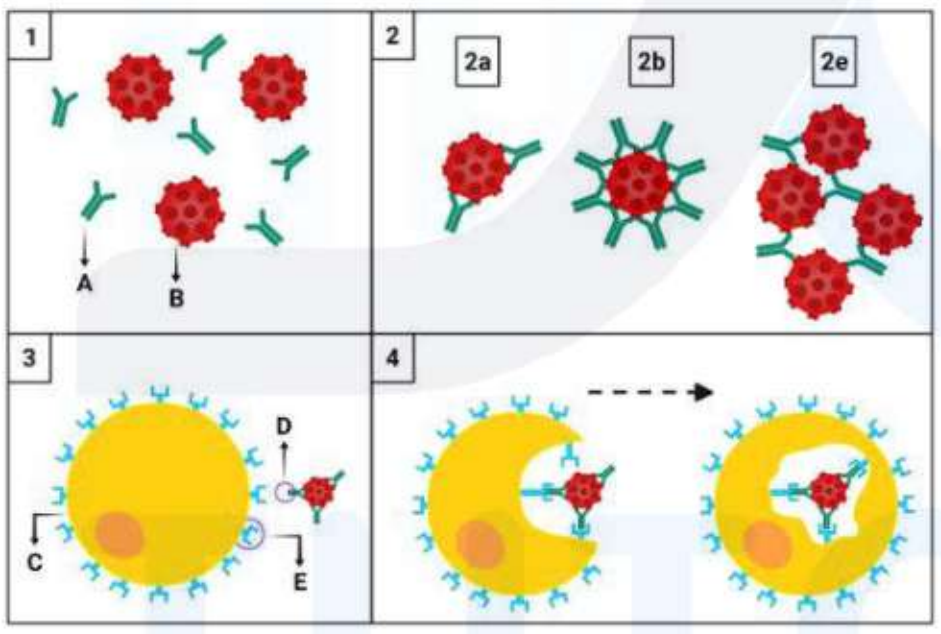

1) A – Antibodies
   B - Pathogens
2) The antibodies bind to pathogens
   2a-Opsonization
   2b-Neutralisation
   2c-Agglutination
3) C – A Phagocyte
   D- Approaches the pathogen and Fc region
   E -Antibody binds to one of the Fc receptors
4) Phagocytosis occurs as the pathogen is ingested

Types of opsins 00:15:37

1.FC portion of Ig G

- Ig G is an incomplete antibody

- It coats the molecule hit cannot kill it due to zeta potential
- Zeta potential is present in all cells which acts as fome separating two cells.

2.C3b, C5b – These complement proteins act as opsins

3.Mannose binding lectin

4.Fibrinogen

5.CRP [c-reactive protein]

2. Mechanisms other than opsonization:

00:20:10

- These are more time-consuming methods
- Receptors involved in their processes are
  a. Mannose receptors [carbohydrate receptors]
  b. Scavenger receptors
  c. Opsin R

AfraTafreeh.com
TUTORIALS
LOGIN FOR SUCCESS

I. Engulf 00:21:43

- This step occurs by the mechanism of actin polymerization which forms pseudopods
- These pseudopods surround the molecule and form a phagosome
- Phagosome fuses with lysosome to form a phagolysosome

AfraTafreeh.com

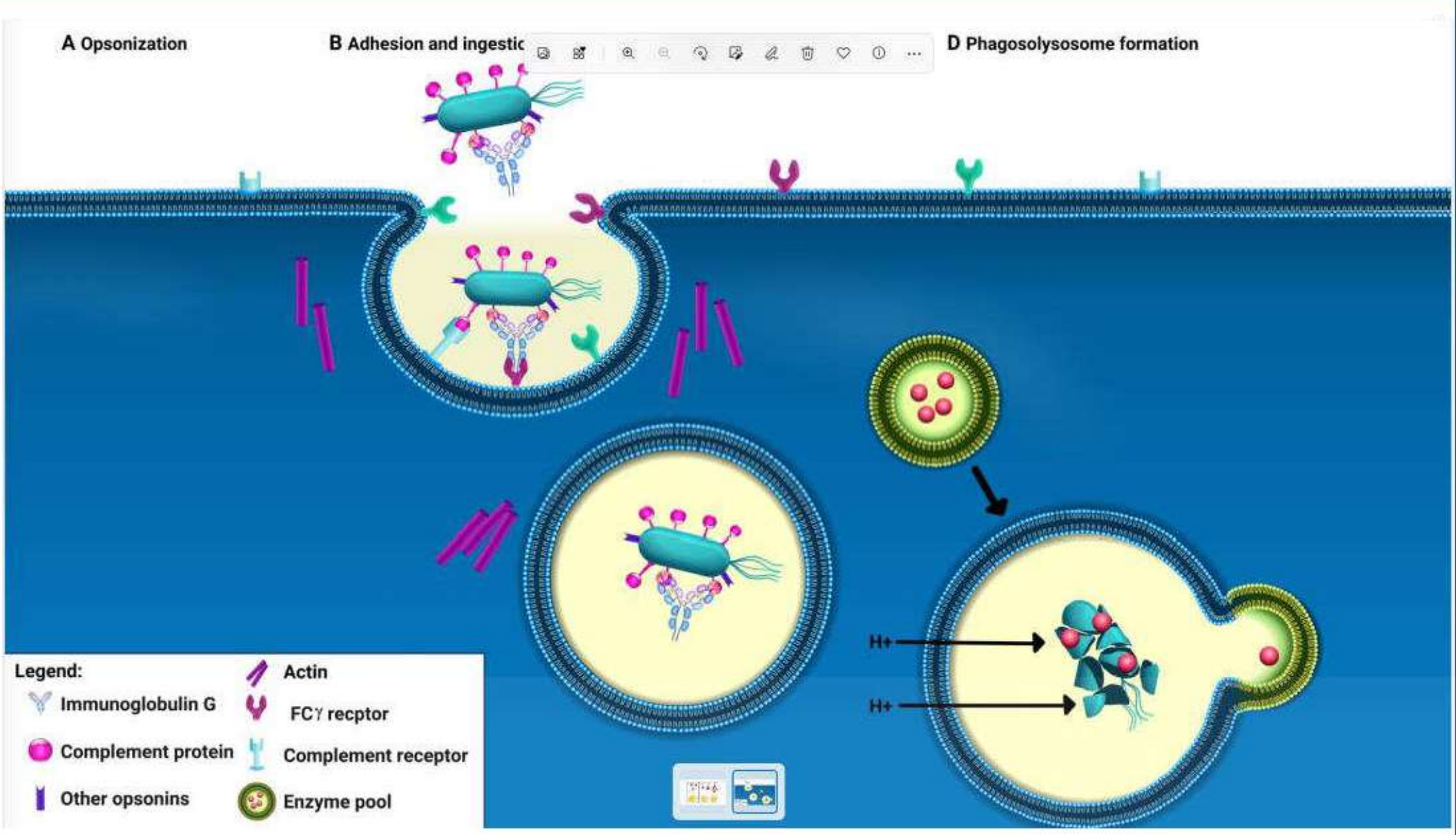

Fig: 2

II. Kill 00:24:02

- Killing occurs in phagolysosome
- It occurs by two mechanism
  a) O2 dependent killing
  b) O2 independent killing

a. O2 dependent killing

- Most common
- More effective
- It occurs by the production of free radicals

I. NADPH Oxidase/PHOX (phagocytic oxidase)

- This enzyme is present on the wall of the phagolysome
- It has 4 sub units
  - P91 and p22 present on cell membrane
  - P47 and p67 present is cytoplasm

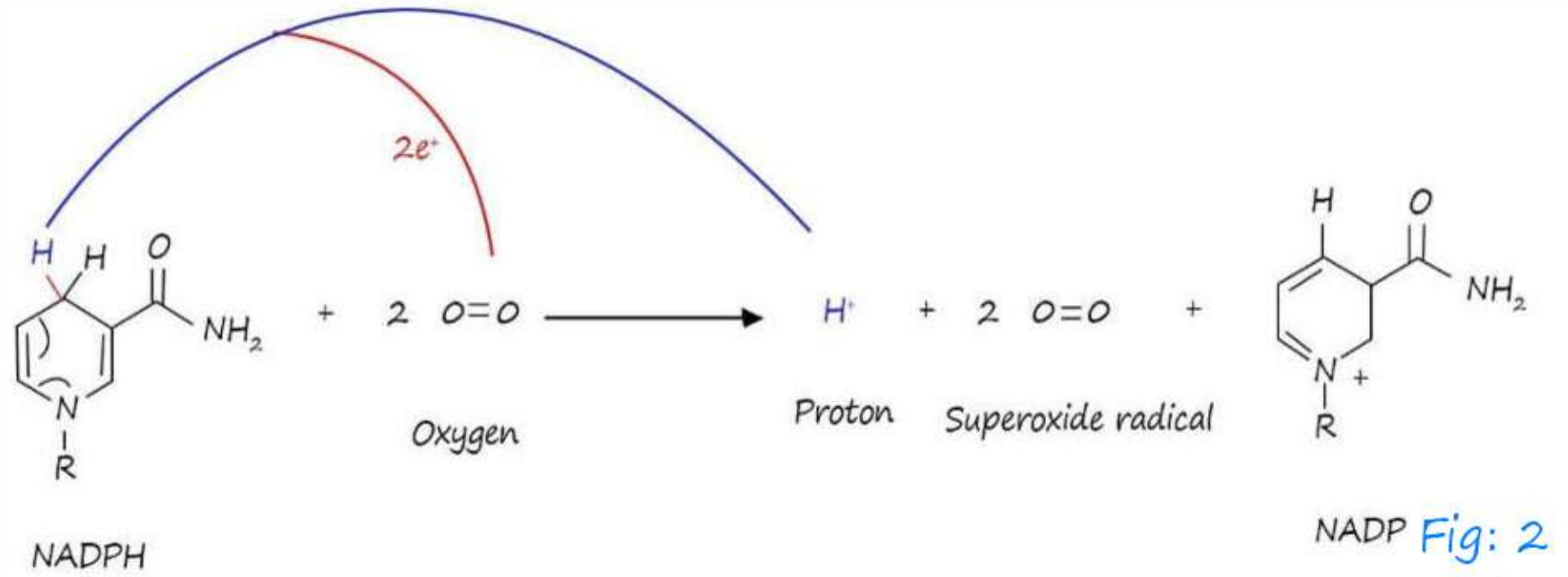

Fig: 2

- Deficiency of NADPH oxidase leads to chronic granulomatous disease
  It occurs in two forms
- X-linked recessive- due to membrane p91 deficiency
- Autosomal Recessive – due to cytoplasm subunit deficiency

AfraTafreeh.com

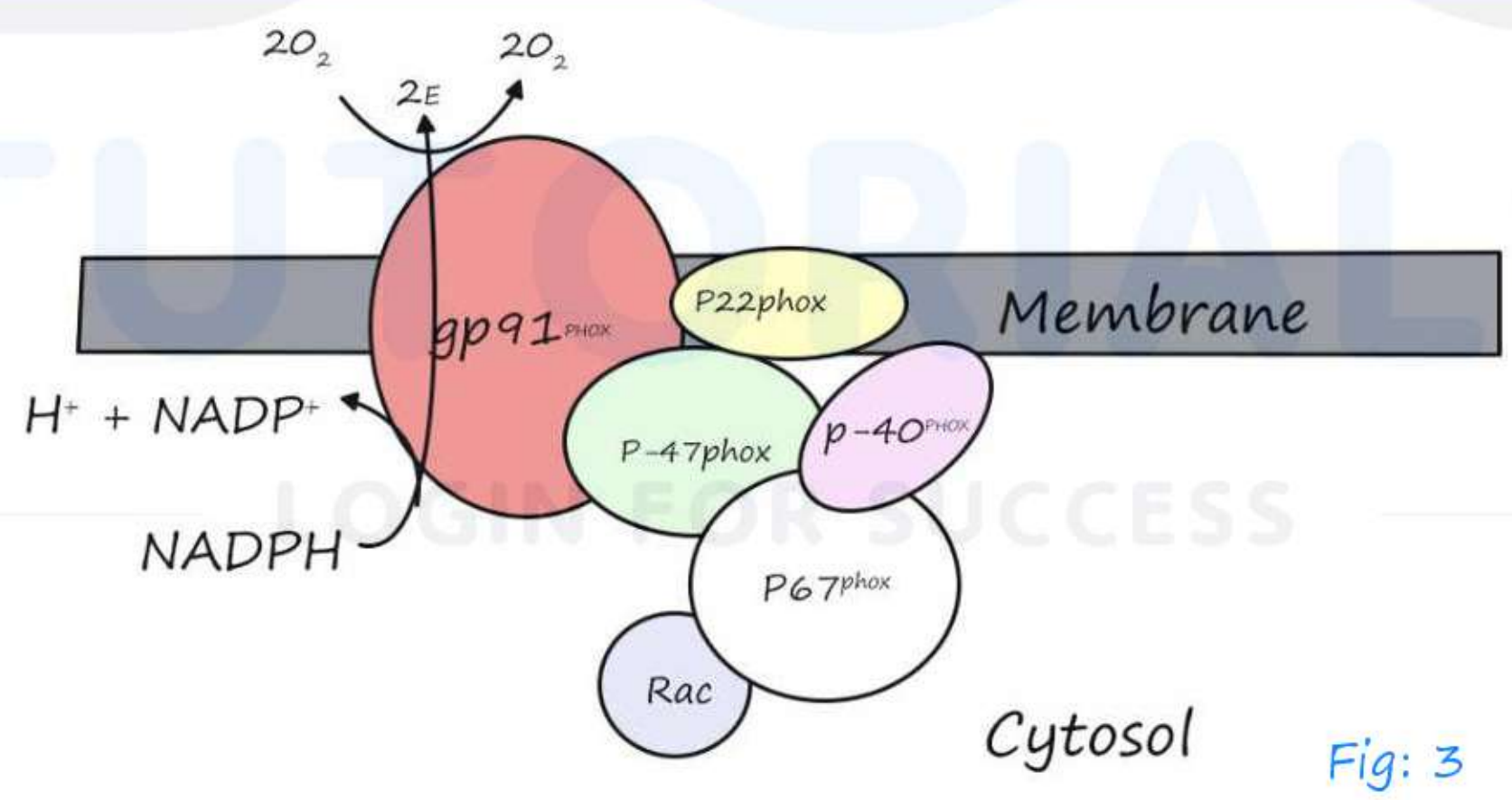

Fig: 3

- O_2^o – free radical formed by NADPH oxidase
- O_2o converted into neutral molecule via antioxidant-Superoxide dismutase (SOD)
- Superoxide dismutase present is very high concentration in the brain
- Here, no free radical injury occurs in brain

AfraTafreeh.com

O_2^o $\xrightarrow{SOD}$ H_2O_2

H_2O_2 $\xrightarrow{peroxidase}$ H_2O

- H2O2 are treated in peroxisomes which (peroxides) are rich in catalase
- Peroxidase enzyme found in cytoplasm in glutathione peroxidase
- Most powerful antioxidant is glutathione peroxidase

> - Glutathione peroxidase deficiency leads to G6pD deficiency
> - Glutathione peroxidase is the only mechanism of cleaning free radical in red blood cells

II. Fenton reaction 00:34:02

H_2O_2 $\xrightarrow{Fe2+}$ $OH^{\cdot}$ (Hydroxyl free radical)

Most potent free radical – OH·

III. H_2O_2 – MPO Halide system

H_2O_2 $\xrightarrow[MPO]{Cl^-}$ HOCL

MPO – Myeloperoxidase

HOCL is the most efficient free radical

IV. Peroxy nitrite

H_2O_2 $\xrightarrow[\text{Nitric oxide}]{NO}$ $ONOO^{\cdot}$ (Peroxy Nitrite)

V.Eosinophilic peroxide

$H_2O_2 \xrightarrow{I^{\cdot}} HOI^{\cdot}$ (Hypoiodide)

HOI–Most effective parasitical agent

ENZYMES	FREE RADICALS
i. NADPH Oxidase ii. MPO Halide system iii. Fenton reaction iv. Peroxy nitrite	i. O_2^{0} ii. HO $CL^{\cdot}$ iii. $OH^{\cdot}$ → Most potent free radicals iv. $ONOO^{\cdot}$

b.O2 independent killing 00:41:05

iqraTafreeh.com

WBC Granules

Primary (1°) Azurophilic granules	Secondary (2°) specific granules	tertiary
i. Myeloperoxidase (MPO) **ii. Acid hydrolase** iii. Neutral protease **P – Prolinase 3** E – Elastase	**i.Lactoferrin** **ii. Alkaline phosphatases** iii. Lysozymes iv. Gelatinase (NGAL)	Gelatinase

DOCTUTORIALS LOGIN FOR SUCCESS

AfraTafreeh.com

C – Cathepsin G iv. Lysozymes v. Defensins **vi. Nonspecific collagenase**	v. Plasminogen activator **vi. type Iv collagenase** vii. Cathelcidin	

- Gelatinase also called as Neutrophil gelatin associated lipocalcin
- NGAL – Most important new biomarker of acute kidney injury
- Cathelcidin – It is a vitamin D dependent molecular which kill TB bacilli

After killing is completed 00:48:40

Negative feedback	**Apoptosis**
i. This is undertaken by Anti-inflammatory molecules are: - Lipoxin - TGF β - IL-10 - Resolvins	i. Residual WBC's undergo the process of apoptosis ii. Monocytes have PDL1 (programmed death ligand) which bind to PD receptors on T-lymphocytes and release Anti-inflammatory I.L-10 which aids in apoptosis

DISEASE OF INFLAMMATION

Defects of inflammation 00:00:16

I. Leukocyte adhesion defect (LAD)

1.LAD -1

- It occurs due to **integrin B2 defect** integrin B2 defect is made up of LFA/MSC-1
  Clinical presentation of LAD-1
- Delayed separation of umbilical cord stump
- Repeated and recurrent infections
- Diagnosis by flow cytometry which detects CD11 and CD18 present on LFA/MAC 1

2.LAD- 2

- It occurs due to defect of **sialyl lewis x**
- It is present on cells and cell membrane
- The defect is in the glycosylation process which hinders the attachment of fucose to cell membrane
  - Defect in glycosylation is LAD-2 leads to absence of 'H' antigen-which causes Bombay blood group
  - It is a specific type II c glycosylation defect

3.LAD – 3

- It is a genetic defect. The gene is **FERMT-3 gene**
- This gene is responsible for proper functioning of integrins in hematopoietic system

AfraTafreeh.com
TUTORIALS
LOGIN FOR SUCCESS

AfraTafreeh.com

- It most commonly involves WBC and Platelets
- In WBC, it is seen as LAD-1
- In platelets it is seen as glanzman thromboasthenia
- **LAD1 + Glanzman thrombasthenia = LAD3**

II. Defect is phagolysosome 00:07:09

Chediak Higashi syndrome

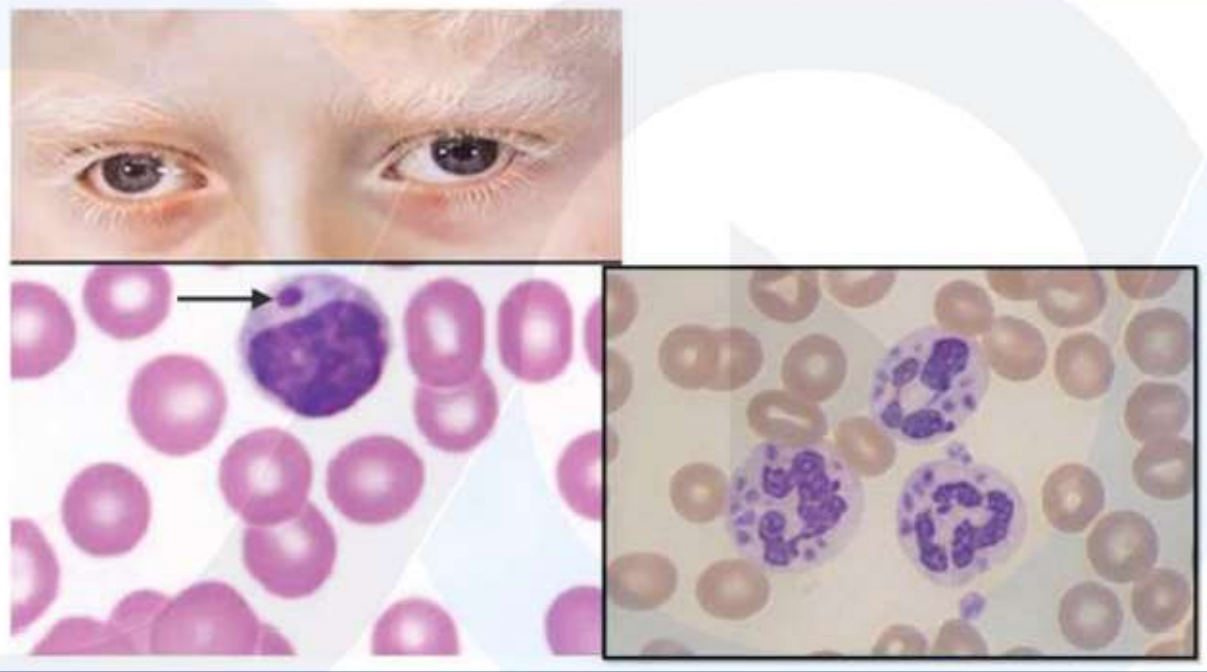

Fig: 1

- It is due to defect in **LYST1 gene (Lysosomal transporter gene)**
- This defect leads to absence of fusion of phagosome and lysosome hence phagolysosome is not formed
- In WBC, they cytoplasm shows peculiar **giant cytoplasmic granules**

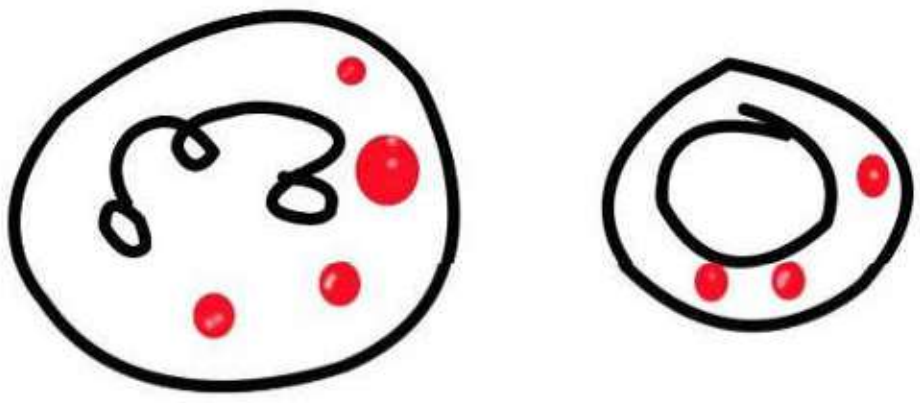

Clinical presentation

- Albinism
- Neutropenia
- Defective chemotaxis

III. Chronic granulomatous disease 00:11:06

- Defect in enzyme NADPH oxidase (PHOX)
- It occurs in two forms
- X linked recessive – due to p91 subunit defect in cell membrane
- Autosomal recessive – due to subunits p47, p67 in cytoplasm
- Diagnosis-previously, NBT – Nitroblue tetrazolium test
- Diagnosis of choice is **Dihydro rhodamine test (DHR) by flowmetry** is used for diagnosis this test works by the mechanism of detecting oxidative burst in cell

AfraTafreeh.com
TUTORIALS
LOGIN FOR SUCCESS

IV. MPO defect 00:13:54

- Myeloperoxidase deficiency
- Absence of myeloperoxidase, leads to increase in peroxides.
- Patient is susceptible to catalase positive and catalase negative organisms

AfraTafreeh.com

- Chronic granulomatous disease, the MPO pathway is active, **hence patient is protected from catalase negative organisms.**

Other defects: 00:18:20

- **Early complement deficiency – SLE**
- **Late complement deficiency – Neisseria infections (5-9)**

TUTORIALS
LOGIN FOR SUCCESS

BASIC FUNCTION OF IMMUNITY

Immunity

Innate immunity
(Natural immunity)
(Native immunity)

- Defense mechanism that are present even before infection i.e since birth
- It is the first line of defense.

Humoral component

i. Acute phase reactors

- Interferons
- Complements
- Lysozyme

Cell mediators

- Natural killer cells
- MALT-in GIT, Tonsils (Mucosa associated lymphoid Tissue)
- Macrophages, Neutrophils
- Dendritic cells

Adaptive immunity
(Acquired immunity)

- Mechanism that are stimulated by microbes and are capable of recognizing microbial and non – microbial substances

Humoral component

i. Antibody

Cell mediator

i. T lymphocytes [CD4/HELPER & CD8/KILLER T/CYTOTOXIC T]
ii. NK/T cell-a 1
iii. Subset of T-cell

- Barriers like skin, mucosa are also part of innate immunity

Note: Complements are part of both innate and adaptive immunity

AfraTafreeh.com
TUTORIALS
LOGIN FOR SUCCESS

AfraTafreeh.com

Characteristics of innate immunity

- Present since birth
- No change with repeat exposure
- No lag phase
- No immunological memory
- Mechanical barrier
- Natural flora
- Not specific
- Not diverse
- Acquired after infections
- Specific to microbe
- Generates memory
- Repeat exposure shows rapid and enhanced response

DOC TUTORIALS
LOGIN FOR SUCCESS

Acquired or adaptive immunity 00:03:30

- Resistance that an individual acquires during life by recognizing and selectively eliminating specific foreign molecules

Active immunity

- Induced infections or by immunogens (antigens, toxoid)
- Provide effective protection for long period

Passive immunity

- received passively[example injection of readymade antibodies]
- effect is transient :only immediate immunity
- no memory

- immunity effective only after lag period
- immunological memory present
- booster effect is there on subsequent exposure
- negative phase may occur

- subsequent dose is less effective
- no negative phase
- applicable in the immune deficient anti rabies immunoglobulins are the example of passive immunity

AfraTafreeh.com
TUTORIALS
LOGIN FOR SUCCESS

AfraTafreeh.com

INNATE IMMUNITY

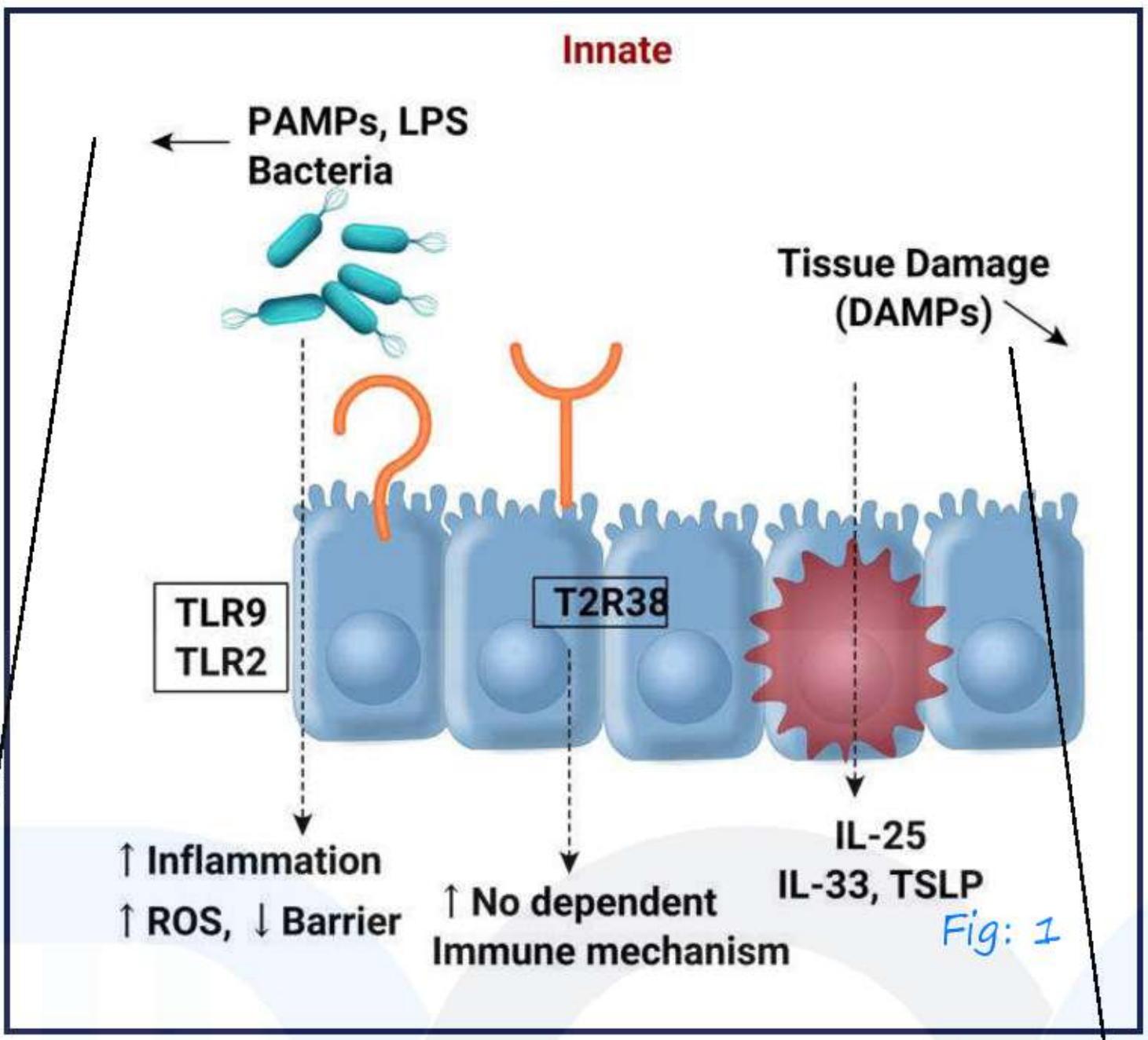

Fig: 1

Pathogen associated molecular patterns (PAMP)

Recognized by cells involved in immunity which release danger associated molecular pattern like uric acid(DAMPs)

Pattern recognition receptors (PRR)

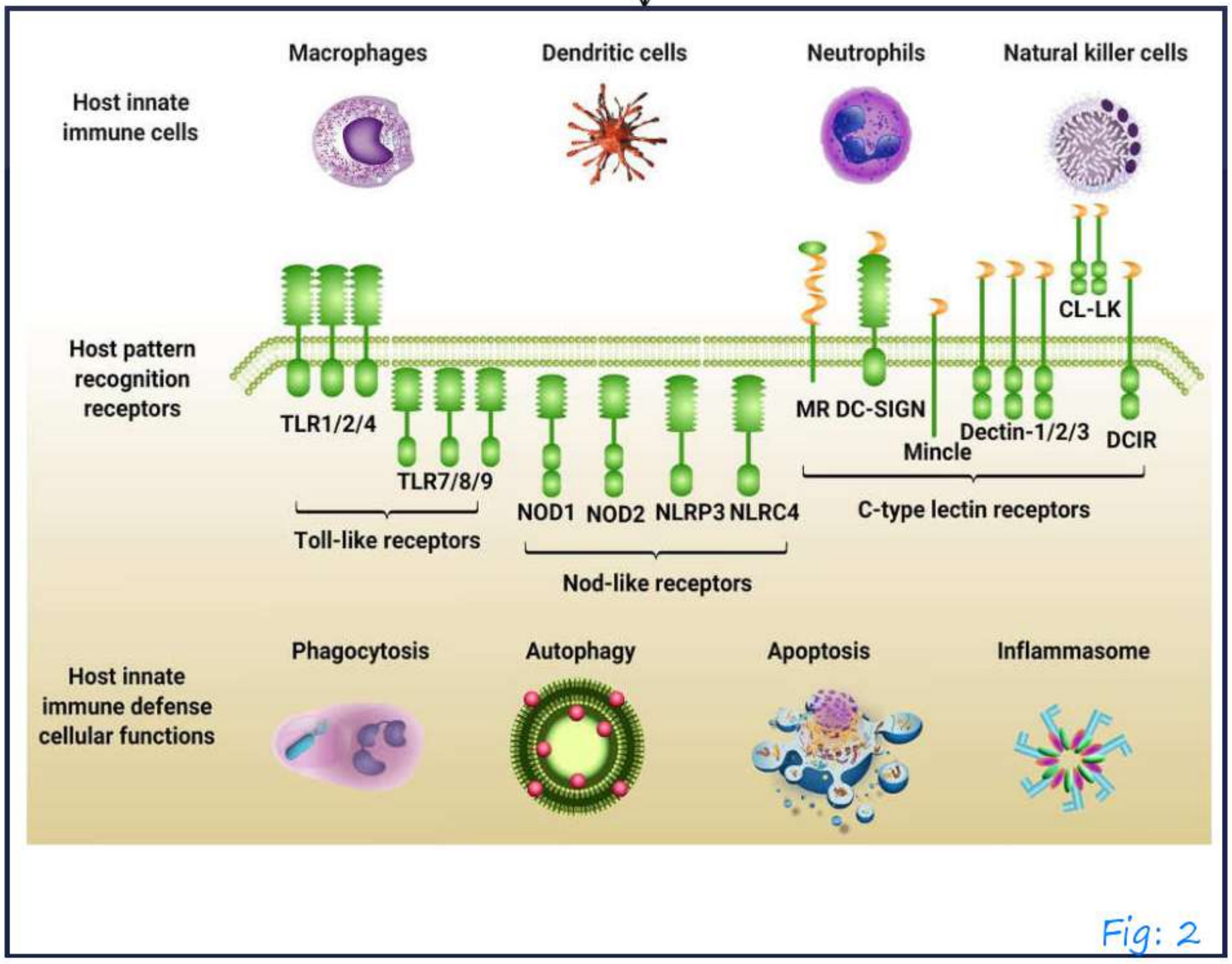

Fig: 2

They are 4 types

- TLR – Toll like receptor (Best defined pattern recognition receptor)
- CLR – Recognize fungal infections – C – type lectin receptors
- RLR – Recognize viral infections – RIG like receptors
- WLR – Flagellated organism containing flagellin antigen are recognized by this receptor
- Also recognize excessive metabolic byproducts (Uric acid) and electrolyte imbalance

Toll like receptors 00:00:05

AfraTafreeh.com
TUTORIALS
LOGIN FOR SUCCESS

- Total 10 types of toll like receptors
- TLR 2 – active against gram positive bacteria, Tuberculous bacteria.
- TLR 3 - ds RNA Viruses
- TLR 4 - Gram negative, Leptospira, chlamydia
- TLR 5 – toxoplasma
- TLR 6 - mycoplasma
- TLR 7 - SS RNA Virus
- TLR 9 – DNA Virus

Mechanism of action of toll like receptors:

- Present on epithelial/Endothelial/Dendritic cells

AfraTafreeh.com

- So, Toll like receptors identify PAMP and via signal Transduction proteins they stimulate nuclear transcription factor which activates

NF-Kβ → Activate other cells involved in immune mechanism

Cytokines, IFN-1

NOD like receptors: NLRs 00:05:37

- Can identify both PAMP and DAMP
- Present in cytoplasm

On stimulation by DAMP or PAMP

↓

NLR activates inflammasome

- IL-1 → Fever → Pyro ptosis
- Caspase 1 and 11 → Apoptosis → Pyro ptosis

Applied pathology

- Gain of function mutation of NOD 2 receptors causes periodic fever syndrome

- **Inflammatory Bowel Disease**-Crohn's disease NOD 2 mutation
- The identification of NOD 2 mutation is relatively specific for **Crohn's disease.**

Two new type innate immunity: 00:09:23

- **C type lecithin receptors[FOR FUNGI] and RIG like receptors [for identifying VIRUSE ENTERING CYTOPLASM]**

AfraTafreeh.com
TUTORIALS
LOGIN FOR SUCCESS

AfraTafreeh.com

ADAPTIVE IMMUNITY

Immune cells

- Lumphoid cells
  - B Cells
  - T Cells
  - ILC (Innate lymphoid cells
    - ↓ N k Cells – also known as large granular lymphocytes (LGL)
- Antigen presenting cells

- T cells – 70%-80% in peripheral blood
- B cells – 20%
- N K cells – 5-10%

Immunophenotyping i.e study of CD markers

- B cell Marker – CD 10
  - CD 19
  - CD 20
  - CD 21
  - CD 22
  - CD 23
  - CD 24
  - CD 79

  (CD 20, CD 21, CD 22, CD 23 — CD 19 To 24)

- Pan B cell markers – CD 19.

T cell marker

- CD 1 to B (CD_4 – Helper T cell)

- CD 28
- Pan T cell – CD 3 because CD 3 is part of T cell receptor.
- CD – 1 – seen in Thymocytes and Langerhans cells

T cells

- T cell cannot identify any soluble antigen. So there are antigen presenting cells (APC) which take up the antigen process it and excpress them on surface via special molecular called MHC>

Antigen presenting cells

Professional APCS	Non-Professional APC
i. Macrophages ii. Dendritic cells iii. B cells	i. Do not express MHC II molecule Constitutively, but only upon stimulation by certain cytokines ii. Fibroblast iii. Thymic epithelial cells. iv. Pancreatic Beta cells. v. Vascular endothelial cell vi. Glial cells

TUTORIALS LOGIN FOR SUCCESS

AfraTafreeh.com

Dendritic cells

Follicular Dendritic Cell	Interdigitating Dendritic Cell
1. Bear Fc receptor for IgG & receptor for C3b. 2. Hence can trap Antigen bound to Antibodies	1. Present below epithelial surfaces of body 2. Most powerful APC for Naive T Cell (ideally CD-4).

- Follicular Dendritic cells are present in Germinal centers of lymphoid fallicles in Spleen & lymph nodes.
- They present antigen to B-Cells.

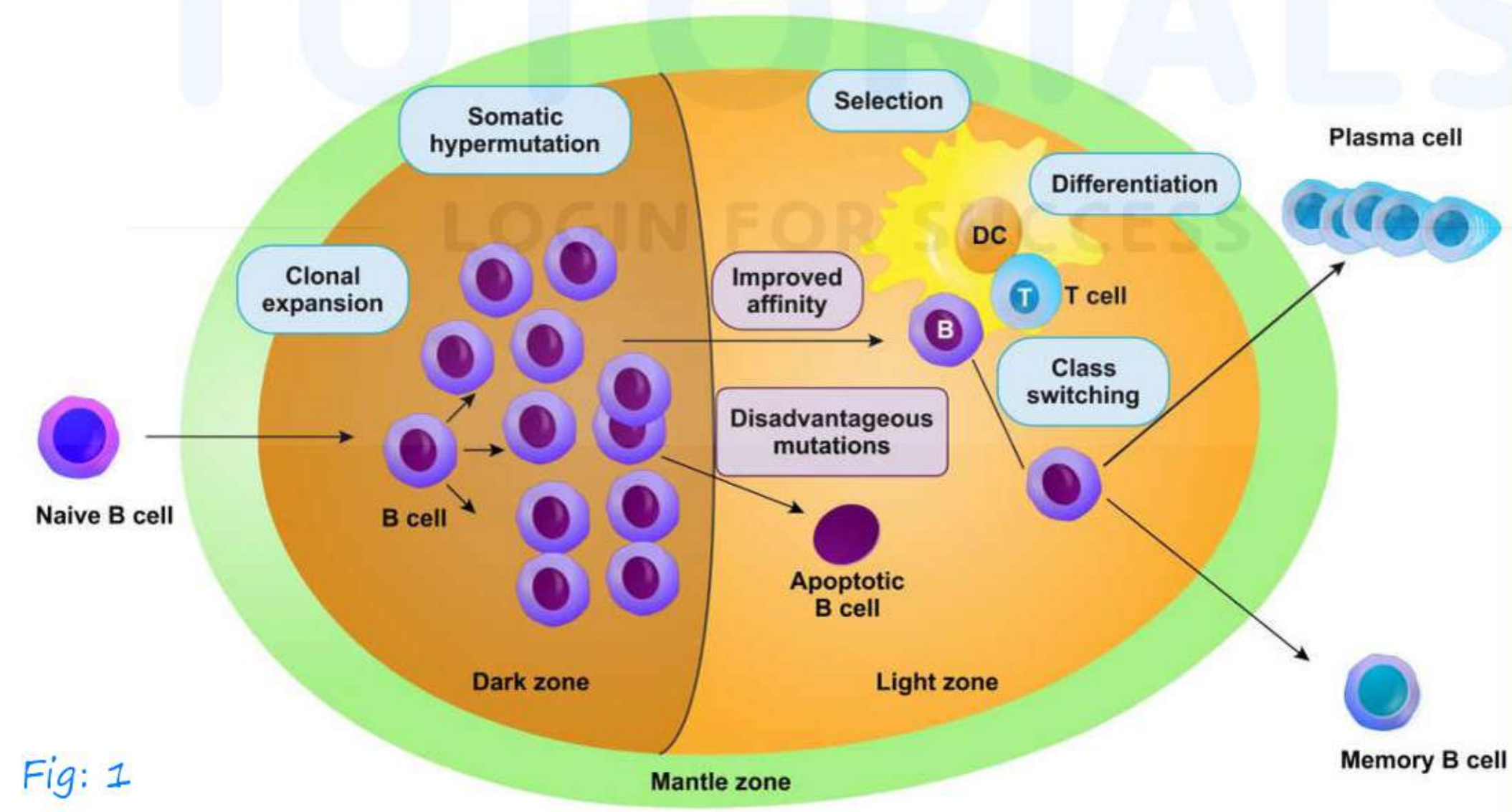

Fig: 1

- Germinal centres lack BCl-2 (Anti-Apoptotic factor)

Antigen

↓

Recocognised by follicular dendritic cells (FDC)

↓ presented to

Naïve B-cells

Results in

Somatic hypermutation | Affinity maturation of B cells

- Activation induced cytosine Deaminase enzyme helps Somatic hypermutation

Applied pathology

- HIV makes FDC as its Reserve
- So there is no somatic Hypermutation and Affinity mutation of B cells
- This leads to formation of defective Immunoglobulins, unable to act against HIV

AfraTafreeh.com
TUTORIALS
LOGIN FOR SUCCESS

Classification of T cells

- Helper T Cells (CD_4 T)
  - Effector T cell
    - TH_1
    - TH_2 TH_{17}
  - Regulatory T cells
- Cytotoxic T cells (CD_8 T)

AfraTafreeh.com

CD8 cytotoxic T cells

Mechanism of action

- Perforin – Granzyme pathway
- FAS -FAS Ligand pathway

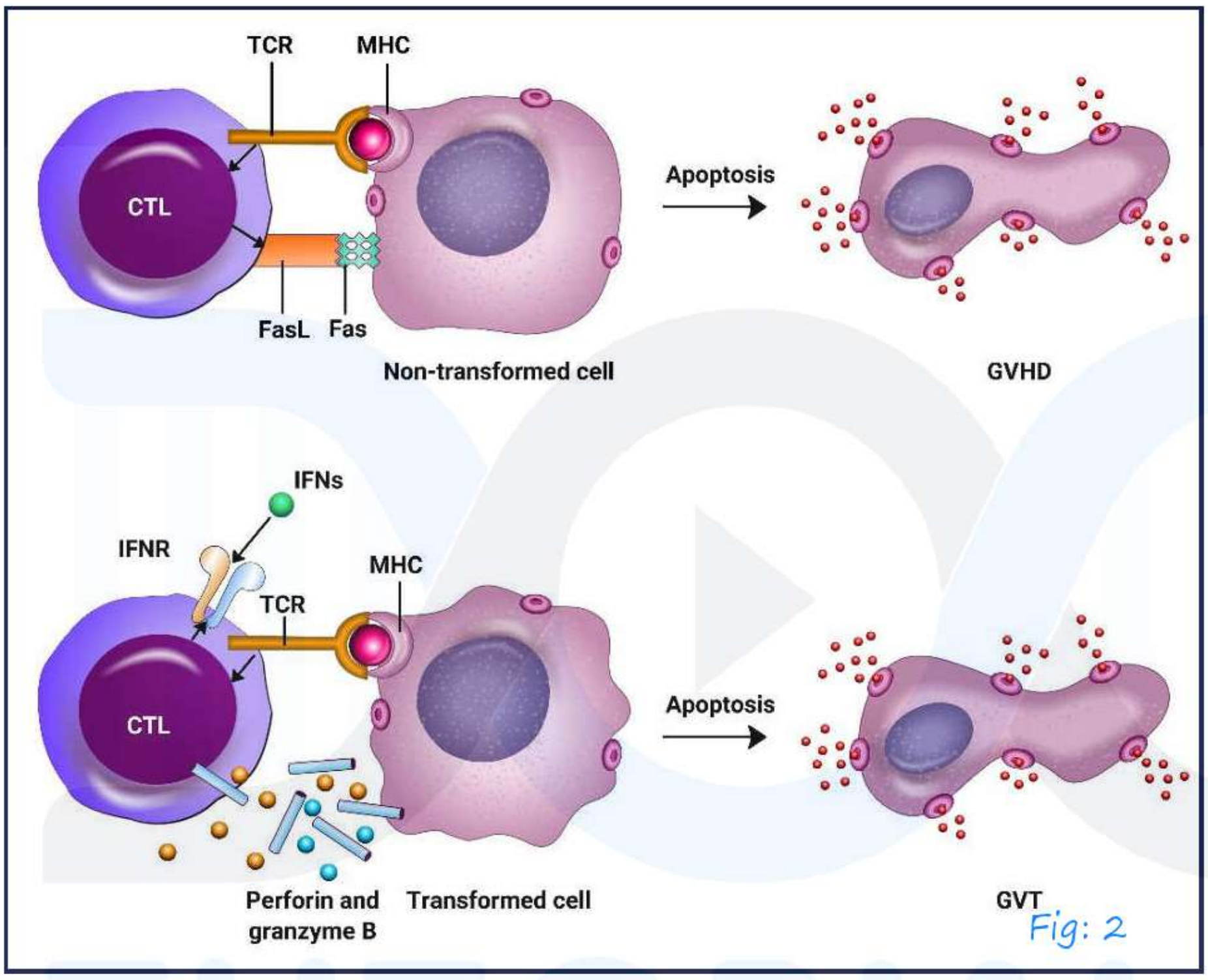

Fig: 2

On antigen stimulation

- Perforin forms channels in cell wall by causing perforation of cell wall
- Granzyme then passes through

Natural killer cells also act in a similar fashion

Function of CD8 T cell

- Killing of virus affected cell
- Tumor cells
- Graft rejection

- Type IV Hypersensitive reactions

Effector T cells

TH_1 | TH_2 | TH_{17}

(Against intracellular Ag)

TH_1 → IL-2

↓

IFN gamma

↓

Macrophage → Epithelioid cells

↓

Granuloma formation

i.e type IV hypersensitivity reaction

⊕

IL-2 → TH_1

↓ ⊕

- Regulatory T cells, also known as suppressor T cell
- They bear IL-2 receptor on them

AfraTafreeh.com
TUTORIALS
LOGIN FOR SUCCESS

AfraTafreeh.com

MHC AND ITS MATCHING

Major histocompatibility complex (MHC)

00:00:30

- Located on short arm of **Chr 6p**
- Codes for histocompatibility (Transplantation) antigen
- Main junction – To bind peptide fragments of foreign protein (Antigens) for presentation to appropriate antigen specific T cells
- Human MHC antigen are synonymous with Human leukocyte antigen (HLA)

MHCClasses 00:00:05

MHC classes

Class-I	Class-II	Class-III
i. Glycoprotein expressed on all nucleated cells and platelets **(Expect RBC and sperms)** ii. Present antigen to CD-8 (Cytotoxic T cell)	i. Glycoprotein, restricted to antigen presenting cells (professional & non-professional types) • Macrophage • Dendritic cell • B cell • Nonprofessional	i. Soluble protein of complement system ii. C2 and c4 of classical pathway iii. Properdin factor B of alternative pathway

iii. Principle antigen involved in graft rejection and cell mediated cytolysis iv. Locus of class I gene **A, B, C, E, G** v. HLA.E = Self recognition target of NK cells. vi. HLA-G. = (Gestationalis) – fetal cells are coated by HLA-G. Our body thus treats them as self-cells, called **Feto maternal tolerance.**	[endothelial cells, fibroblasts] ii. Present antigen to CD-4 (Helper T cells) **iii. Locus-D region** •DP •DQ •DR iv. Responsible for graft versus host response and mixed leucocyte reaction (MLR) v. Present antigen to CD-4 (helper T cells)	iv. Heat shock protein v. TNF α and β

AfraTafreeh.com

Applied pathology

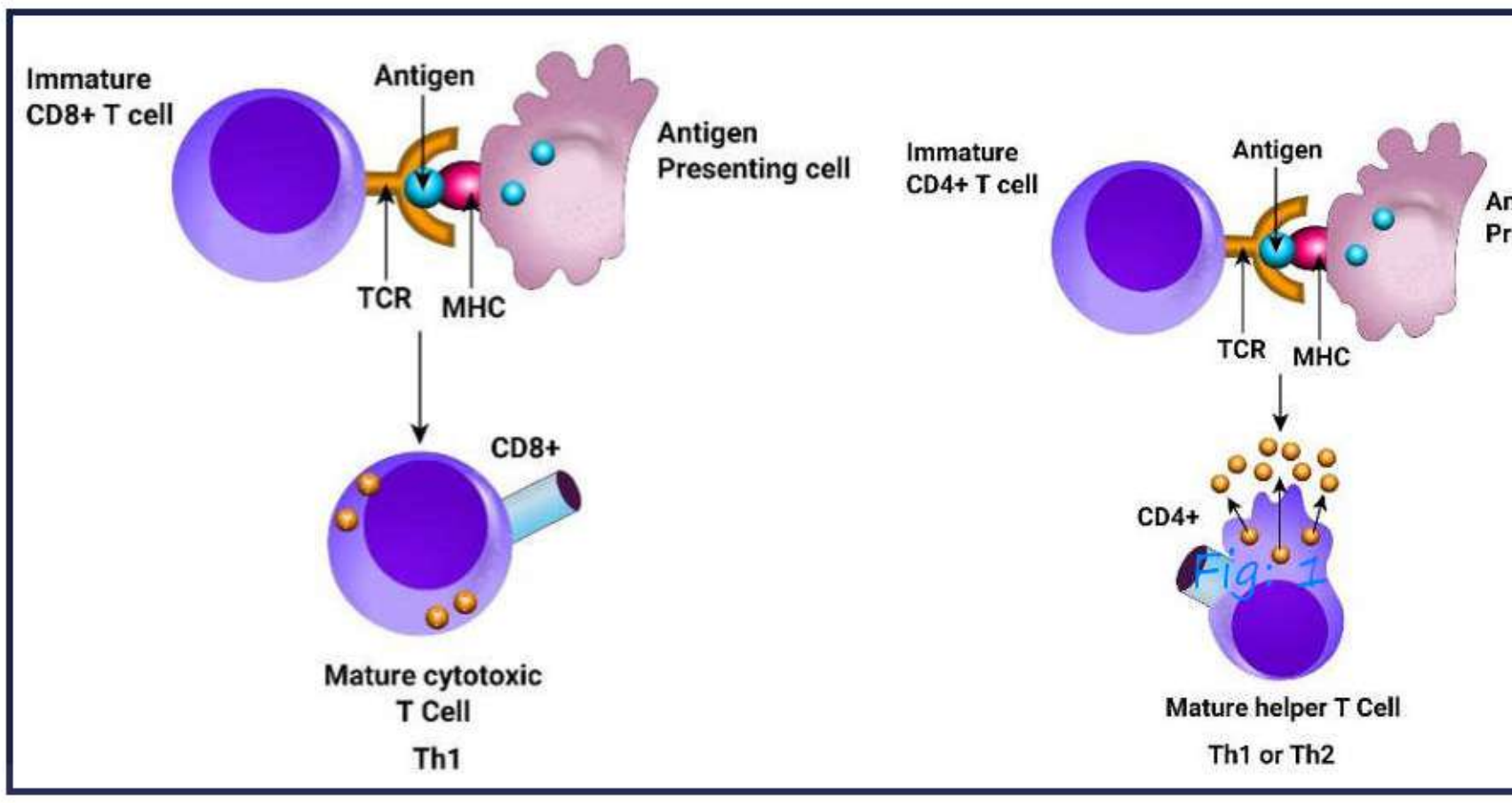

Fig: 1

- Deficiency of MHC-II results in Bare lymphocyte syndrome, a form of severe combined immunodeficiency

Structure of MHC 00:05:43

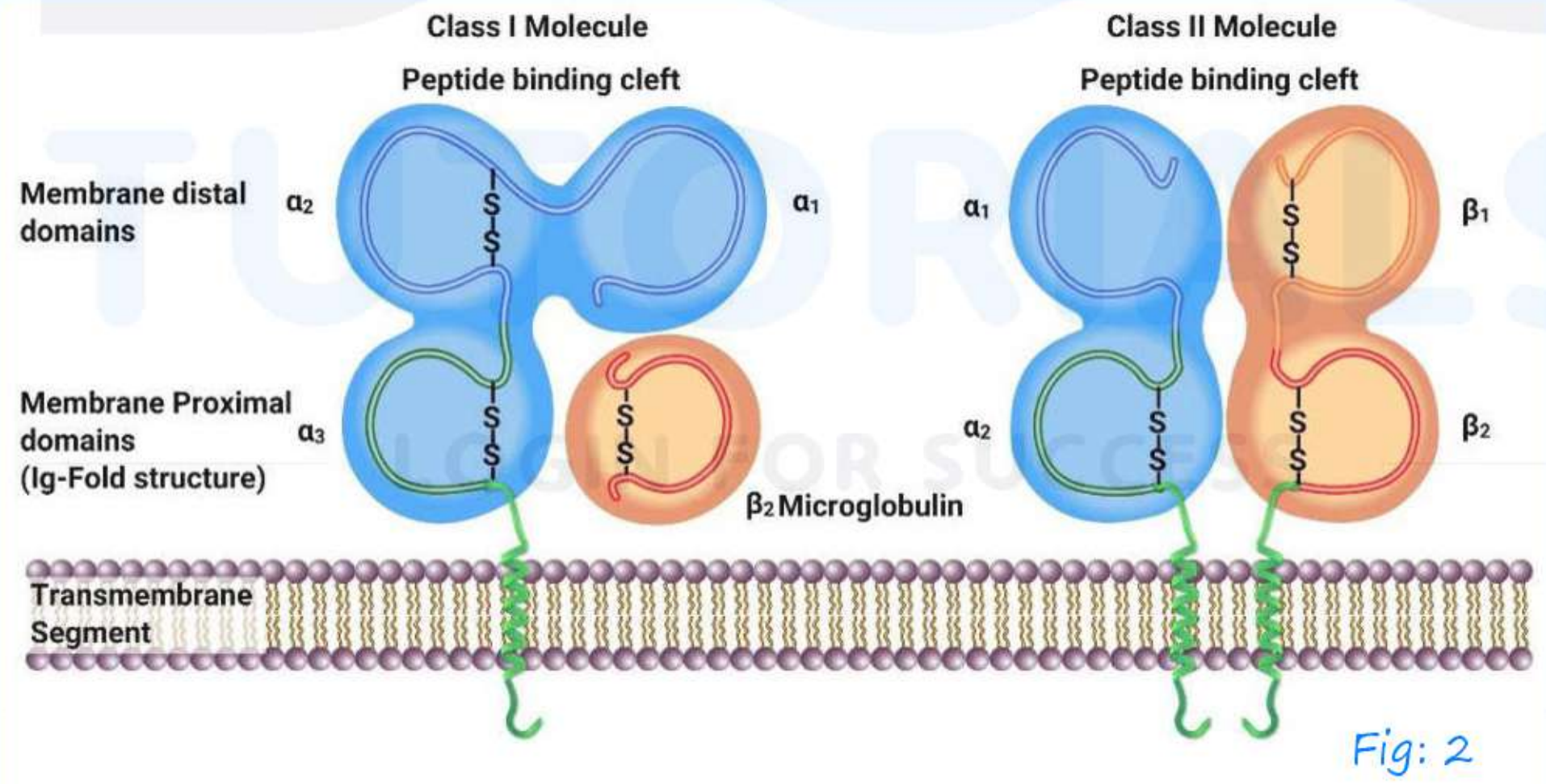

Fig: 2

- β2 CODED from chr 15
- Antigen binding site:
  - α1, α2 in MHC I
  - α1 β1 in MHC II

Applied pathology

- mutation of HLA DQ2 is seen in **celiac disease**
- an autoimmune condition with hypersensitivity to gluten

MHC matching 00:11:00

- both the alleles of HLA antigens have to be matched
- at least 10 HLA should be matched, of which most important are HLA - **A/B and DR**
- HLA antigens are the most common cause of graft rejection
- Anti-HLA antibodies may cause Hyperacute rejection Matching results are reported as
- 100% match
- 6/6 match or 0 0 0 mismatch is HLA-A/B and Dr are matched
- In case of **bone marrow transplantation, 100% match is desired**
- Kidney transplant-**50%**
- Cornea-0%
- In case of **liver** transplants, HLA matching does not confer an advantage
- In case of **cardiac** or **lung** transplantation, HLA matching is not practicable because of the short permissible cold ischemic time.

AfraTafreeh.com
TUTORIALS
LOGIN FOR SUCCESS

AfraTafreeh.com

INTERACTION OF B CELL AND T CELL HYPER IGM SYNDROME

T Lymphocyte 00:00:05

- Thymus derived lymphocyte, constitute 60-70% of peripheral lymphocytes

T cell receptor

- There are two types of T cell receptors

Two types

• Made of αβ proteins • Expressed 95% times • MHC restricted	• Made of YΔ(gamma delta) proteins • Only 5% expression • Can accept lipid antigen without MHC • Present in mucosa of GIT, GUT(GenitoUrinaryTract)

- Antigen binds to TCR (T cell receptor) which is signal 1
- All T-cells have CD-3, which is involved in transduction of signal 1 (CD-3 is pan T cell marker)
- CD4, CD8 act as co-receptors of T-cell receptor

T cell markers includes

a)CD 1 to 8

b)CD 28

CD 28 binds to B 7.1 and 7.2 of APC and provide signal -2

Dendritic cells (APC)

- Every dendritic cell on surface have B7 molecules
- Without any antigenic B7 stimulation, B7 expression is less
- This B7 of APC, binds to **CTLA 4** of T cell, causing silencing of T cells
- CTLA 4 has very high affinity and it binds B7 even when its expression is less

AlfaTafreeh.com

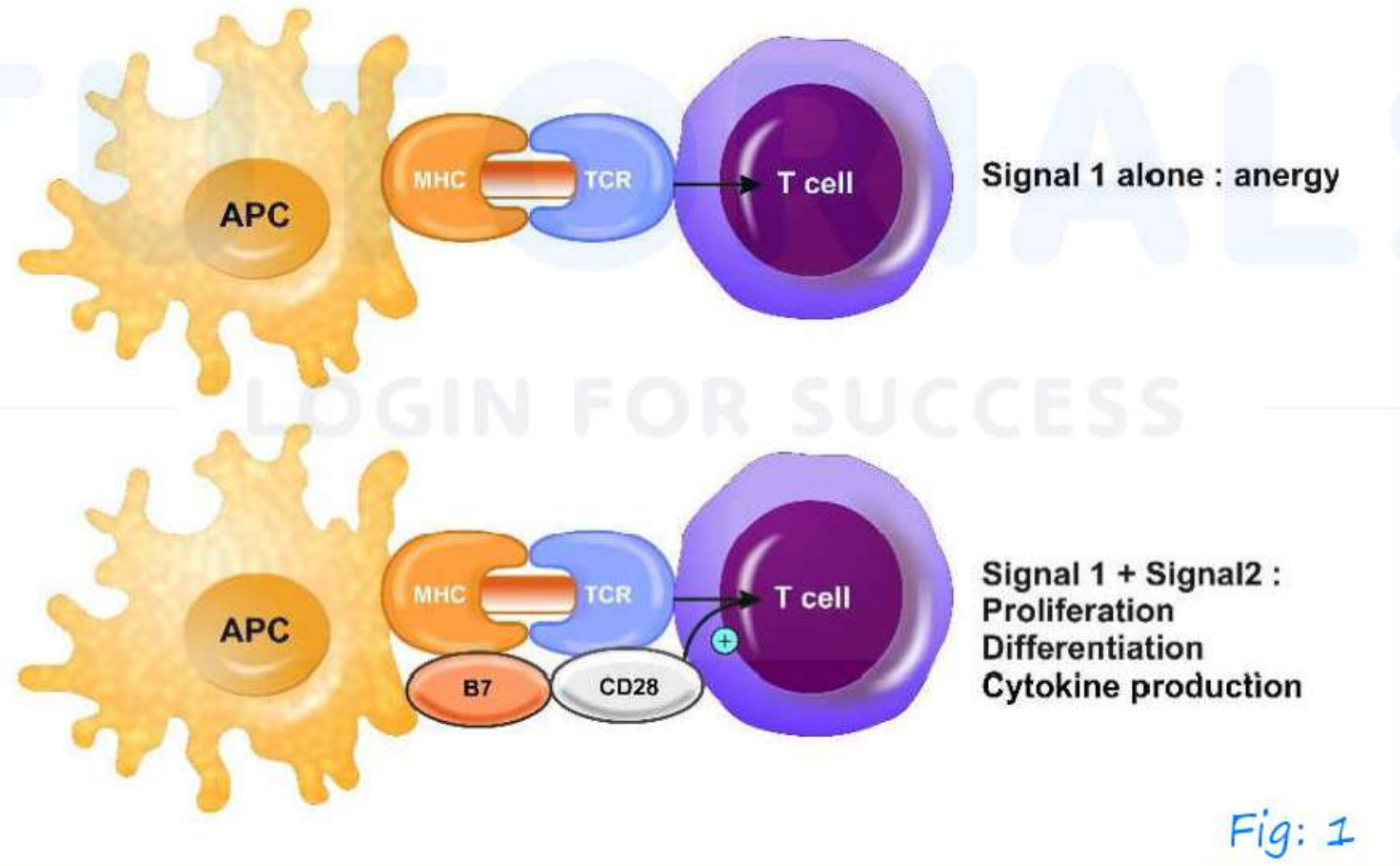

Fig: 1

AfraTafreeh.com

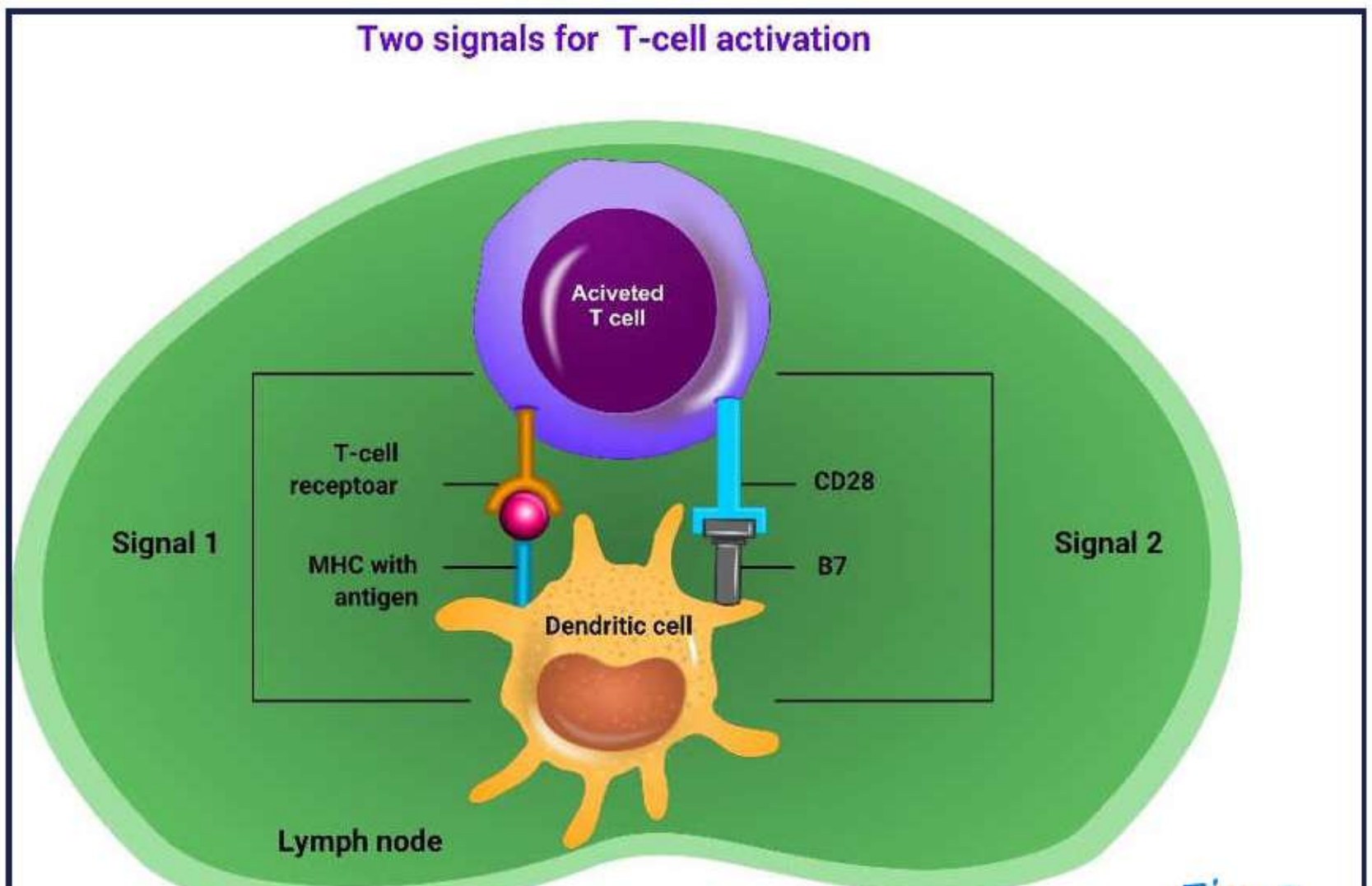

Fig: 2

- MHC binding to T cell receptor via CD4, CD8 = signal 1
- CD 80, CD 86 binding to CD 28 of T cell provides signal 2
- **Anergy** – Permanent inactivation of Both T cell and B cell due to lack of co-stimulatory signal (signal 2)
- T cell → co stimulatory signal → CD 80/86 with CD 28
- B cell → co stimulatory signal → CD 40L with CD 40 R
- Anergy is a mechanism to prevent autoimmunity in peripheral blood only. So, it is called **Peripheral immune Tolerance**

Applied pathology 00:14:40

- T cells also have PD-receptor which binds to PDL1 of monocytes

  Monocytes PDL1 + PD receptor (T cell)

  ↓

  Release of IL 10

  ↓

  Suppresses inflammation
- Cancer cells coat themselves with PDL1, thereby suppressing inflammatory response
- So anti PDL1 drugs are now being used for certain cancers like Breast Ca, Hodgkins lymphoma

AfraTafreeh.com

T cell markers
i. CD-3 → Pan T cell Marker
ii. CD 4 and 8 → co-receptors
iii. CD 28 → Provides signal 2
iv. CTLA4 → Anergy
v. CD 40 ligand → Binds to CD40 protein on antigen presenting cells (APC)

B-Lymphocyte 00:18:20

- 10-20% of peripheral lymphocyte
- Responds to free antigen, unlike T cells
- B cells also act as antigen presenting cells to T cells
- BCR (B cell receptor) – made up of IgM and Ig D

AfraTafreeh.com

- For B cell activation – CR2/CD21 helps in proliferation of B cells
- EBV utilizes these receptors to attack and infect B cells
- CD79 a and b – Helps in signal transduction and has a receptor CD40
- CD40 ligand is present in T cell and CD40 receptor is present in B cell
- Membrane bound antibodies IgM and Ig D present on surface of all Naïve B cells and represent antigen – binding component of B cell receptor complex (BLR)
- First Ig class to appear on B-cell surface is IgM

B cell markers
• CD 10 • CD 19 to 24 • CD 79 • Pan B cell marker-CD19.

TUTORIALS
LOGIN FOR SUCCESS

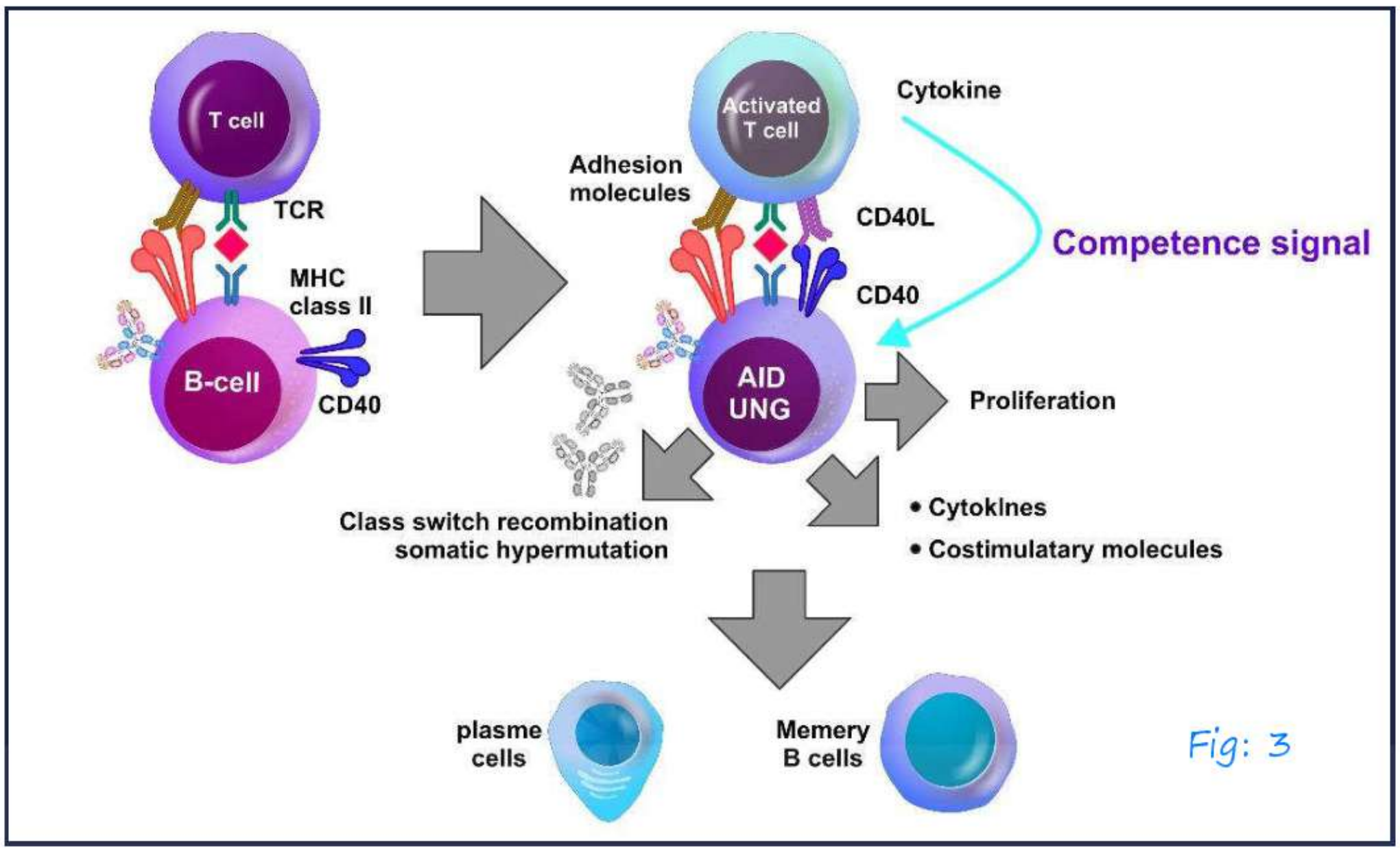

Fig: 3

Competence signal Helps in 00:19:38

- Isotype switching of B cells to other Ig class – Ig G/A/D/E
- Affinity maturation of B cells – They can now process protein antigen also
- B cell mitogen (Proliferation)
- Responds only to polysaccharide antigen

Applied pathology

Hyper IgM syndrome 00:22:37

- Absence of either CD 40 ligand on T cells or CD 40 receptor on B cells, prevents competence signal. There by resulting in NO Isotype switching
- Other cause – Absence of enzyme – Activation induced cytosine deaminase results in **Absence of CD 40 R.**

AfraTafreeh.com

IMMUNODEFICIENCY DISEASES – CLASSIFICATION AND DETAILED OVERVIEW OF SCID

Immunodeficiency diseases 00:00:17

- primary immune-deficiency syndrome
  - Genetically determined
- secondary immune deficiency syndrome
  - example: Infections – AIDS
    - drugs
    - chemotherapy
    - radiotherapy

Primary immune-deficiency syndrome 00:01:16

Stem cells

(Immature cells in bone marrow are CD 34 positive
mature cells are CD 34 negative)

↓

Common lymphoid progenitor cells

- **(PAX -5-gene expression)**
  Pro B cells
  ↓
  Pre-B cells
  ↓
  B-lymphocytes
- **(NOTCH gene expression)**
  Pro T cell
  - Il-7 is the major interleukin that helps in the

↓ development of T

Lymphoid follicles Lymphocyte

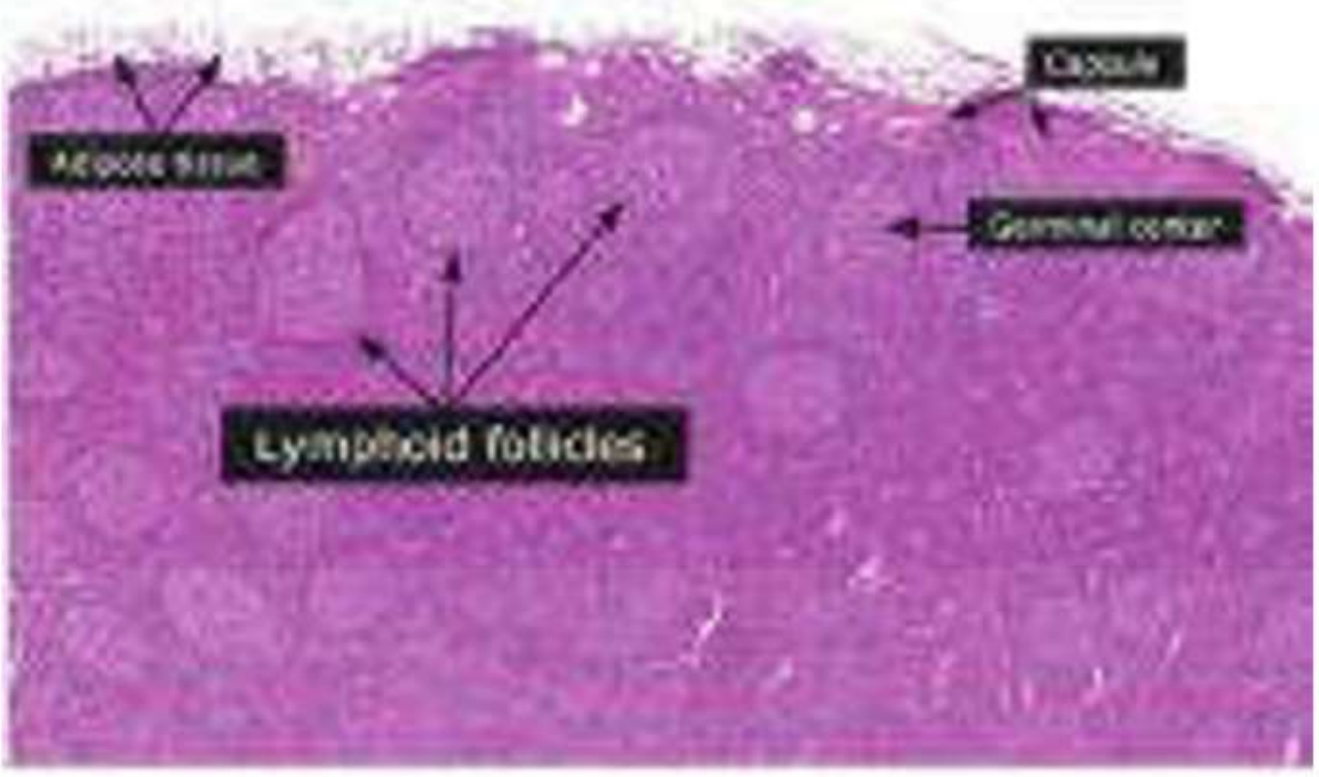

Fig: 1

AfraTafreeh.com
TUTORIALS
LOGIN FOR SUCCESS

Characteristics of germinal center

- Negative for Bc12 (anti-apoptotic factor)
- **Affinity maturation and somatic hypermutation** of B cells with the enzyme Activation Induced Cytosine Deaminase (AID) from germinal centre B cells can either go to

Bone marrow → Develop into plasma cells

Cortex of lymph node → Present as memory B cells

AfraTafreeh.com

Classification of immunodeficiency disorders

00:08:02

- Defect in lymphocyte maturation
  - SCID
  - Bruton agammaglobulinemia
  - Digeorge syndrome
  - Bare lymphocyte syndrome
- Defect in lymphocyte activation and function
- Associated with systemic disorders

Severe combined immunodeficiency 00:12:09

- Due to absence of MHC-II
- Include syndromes with severe combined deficiency of both humoral and cell mediated immunity

SCID
- X linked
- Autosomal recessive

X linked ↓

- 60% case
- Most common type of SCID
- Defect in gamma (γ) subunit

  Of cytokine receptor – Y_C – also known as IL_{2G}

  ↓
- Impaired formation of

  Interleukins 2/4/7/15

DX TUTORIALS
LOGIN FOR SUCCESS

IL-7	IL-15	IL-2	Il-4
↓ Aids in T cell ↓ Combined deficiency of T cells and N K cells ↓ T negative NK negative **B positive**	↓ In NK cell development ↓ B cells are present normally	↓ TH cell proliferation	↓ B cells fail to produce IL-4 for IgE production

AfraTafreeh.com
TUTORIALS
LOGIN FOR SUCCESS

AfraTafreeh.com

Autosomal recessive SCID 00:15:37

3 defects

1. Deficiency of enzyme Adenosine deaminase (Enzyme of purine metabolism)
   ↓
   Accumulation of deoxyadenosine in rapidly proliferating cells
   ↓
   T cell, NK cell, B cell – combined deficiency of all
   ↓
   T negative
   NK negative
   B negative

2. Defect of JAK3 Tyrosine kinase γ subunit of cytokine receptor
   ↓
   JAK 3 → IL2 IL4 IL7 IL15
   So, JAK-3 defect
   ↓
   Interleukins not formed
   IL 7 defect – No T cell
   IL 15 defect – No NK cell
   ↓
   T negative
   NK negative
   B positive

3. RAG 1 and 2 defect (Recombination Activation Genes)
   ↓
   Help in proper activation of T cell and B Cell Receptors (If defective)
   ↓
   T negative
   B negative
   NK positive

DOCTUTORIALS LOGIN FOR SUCCESS

SCID 00:22:28

- T Negative, B negative, NK negative
  - ↓ ADA deficiency 1 and 2 defect
  - ↓ AR
- T negative, B positive, NK negative
  - Yc/IL-2G defect
    - ↓ XLR
    - XLR
  - JAK 3 mutation, RAG 1 and 2 defect
    - ↓ AR
    - AR
- T negative, B positive, NK negative
  - ↓ RAG
  - ↓ AR

AfraTafreeh.com

Fig: 2

Applied pathology 00:25:19

- SCID presents in infancy with profound immunodeficiency these infants are highly susceptible to severe infections especially viral infections causing pneumonia, chronic diarrhea, candidial infections of mouth and diaper area
- Pneumonia by fungus pneumocystis jirovecii

AfraTafreeh.com

- In all forms of SCID, there is deficiency of T cells. **Maternal T cells** affect fetal tissues like skin, GIT, liver etc. presenting **as morbilliform rash over skin**
- This phenomenon is similar to that seen in graft versus host disease (GVHD) to which these patients are highly susceptible

Clinical case 00:29:41

- Mr. David Philip Vetter – was a prominent sufferer of SCID. He was popularly known as the bubble boy since he heads to live in a specially constructed sterile plastic bubble from birth until he died at age 12 from Burkitt's lymphoma
- SCID is the first disorder to be treated by gene therapy
- Vector mediated injection of Y_c in treatment of **XLR** SCID

  ↓ Drawback

  Causes unlimited proliferation of T cells leading to **T cell ALL**
- Enzyme replacement therapy with polyethylene glycol modified bovine adenosine deaminase (PEG-ADA) was later started.

BRUTON AGAMMAGLOBULINEMIA

- X linked agammaglobulinemia
- Agammaglobulinemia → Absence of Gamma globulins i.e. Immunoglobulins
- Due to mutation in **Bruton Tyrosine Kinase (BTK)** on chromosome X9

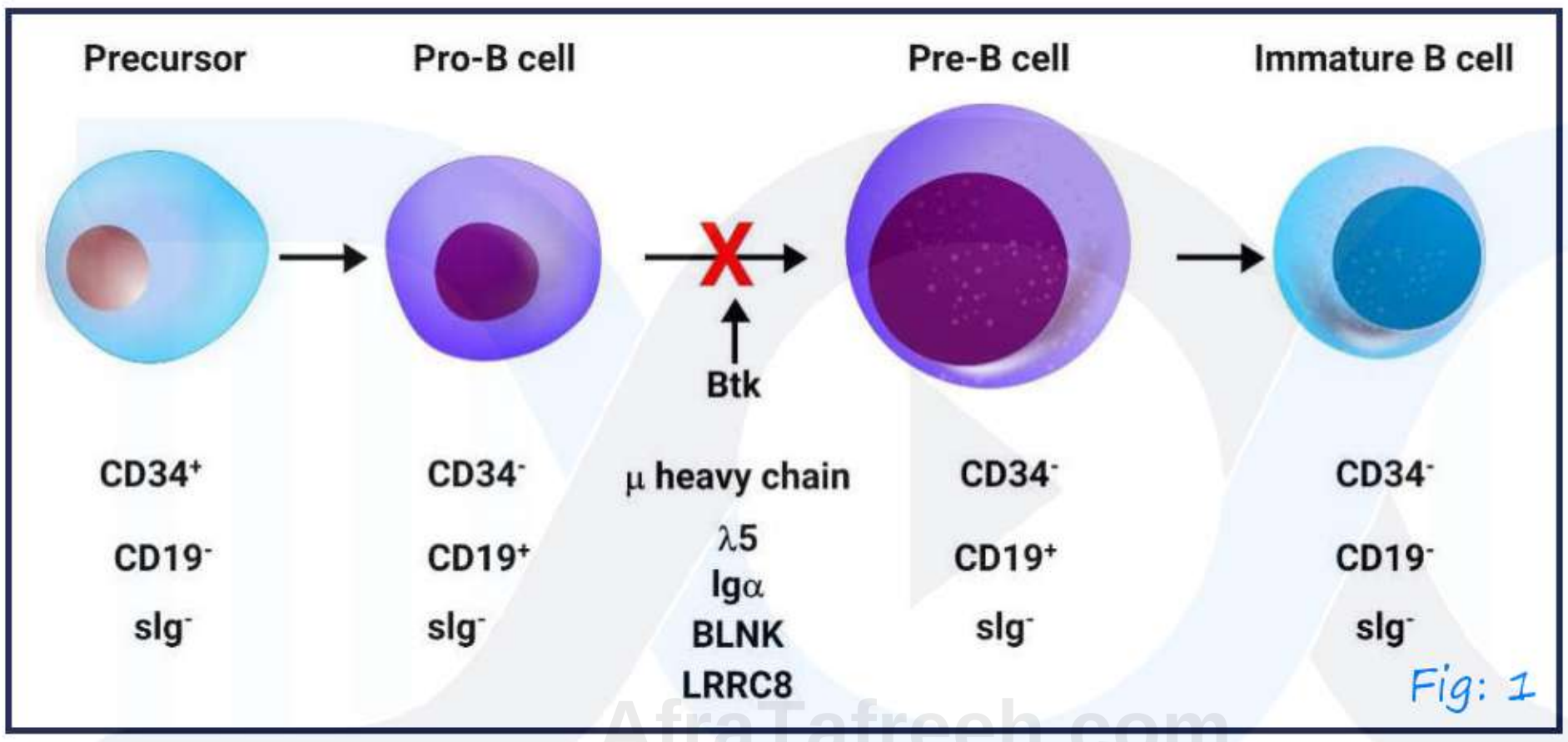

Fig: 1

AfraTafreeh.com

- So, No B cells are formed. Thereby no formation of germinal center in lymphoid follicles
- No formation of Peyer's patches, Tonsils
- No B cells → no plasma cells → No immunoglobulins i.e Agammaglobulinemia

Presentation

- Male child ♂>>♀
- More than 6 months of age
- Recurrent respiratory infections
- No IgG – so opsonization defective → Infections by capsulated organisms like pneumococci

AfraTafreeh.com

Enterovirus infection

- Polio
- Echo
- Coxsackie
  - Polio vaccination in these children can result in **Paralytic Poliomyelitis**
  - So live attenuated polio vaccine (Sabin) is **contraindicated** in children suffering from Bruton agammaglobulinemia
  - Echo virus can cause severe **encephalitis**
  - Absence of Ig A – Giardia infections

Diagnosis

- On biopsy of lymph nodes – No germinal center seen
- BTS gene analysis
- Flow cytometry – Documents absence of B cells – Diagnosis of choice.

DOC TUTORIALS
LOGIN FOR SUCCESS

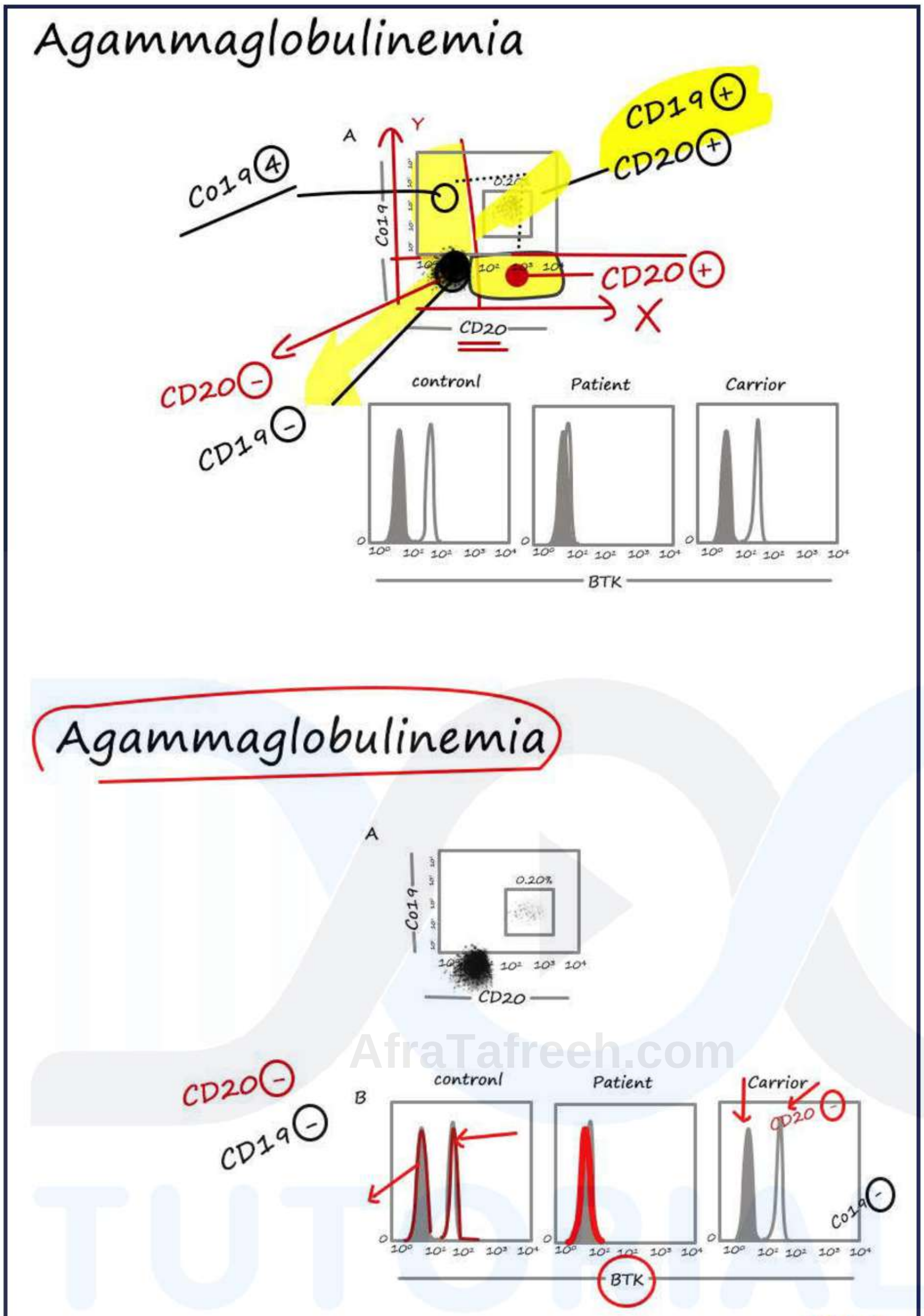

Fig: 2

AfraTafreeh.com
TUTORIALS
LOGIN FOR SUCCESS

AfraTafreeh.com

DI GEORGE SYNDROME AND RECAP OF LYMPHOCYTE MATURATION DEFECTS

- CATCH 22 disorders
- Cellular immune deficiency disorder due to deletion of a small segment of chromosome 22 at chr 22 q 11 locus
  - There is deletion of 30 to 40 genes in the middle of chromosome 22 at location **22 q 11**
  - Autosomal dominant

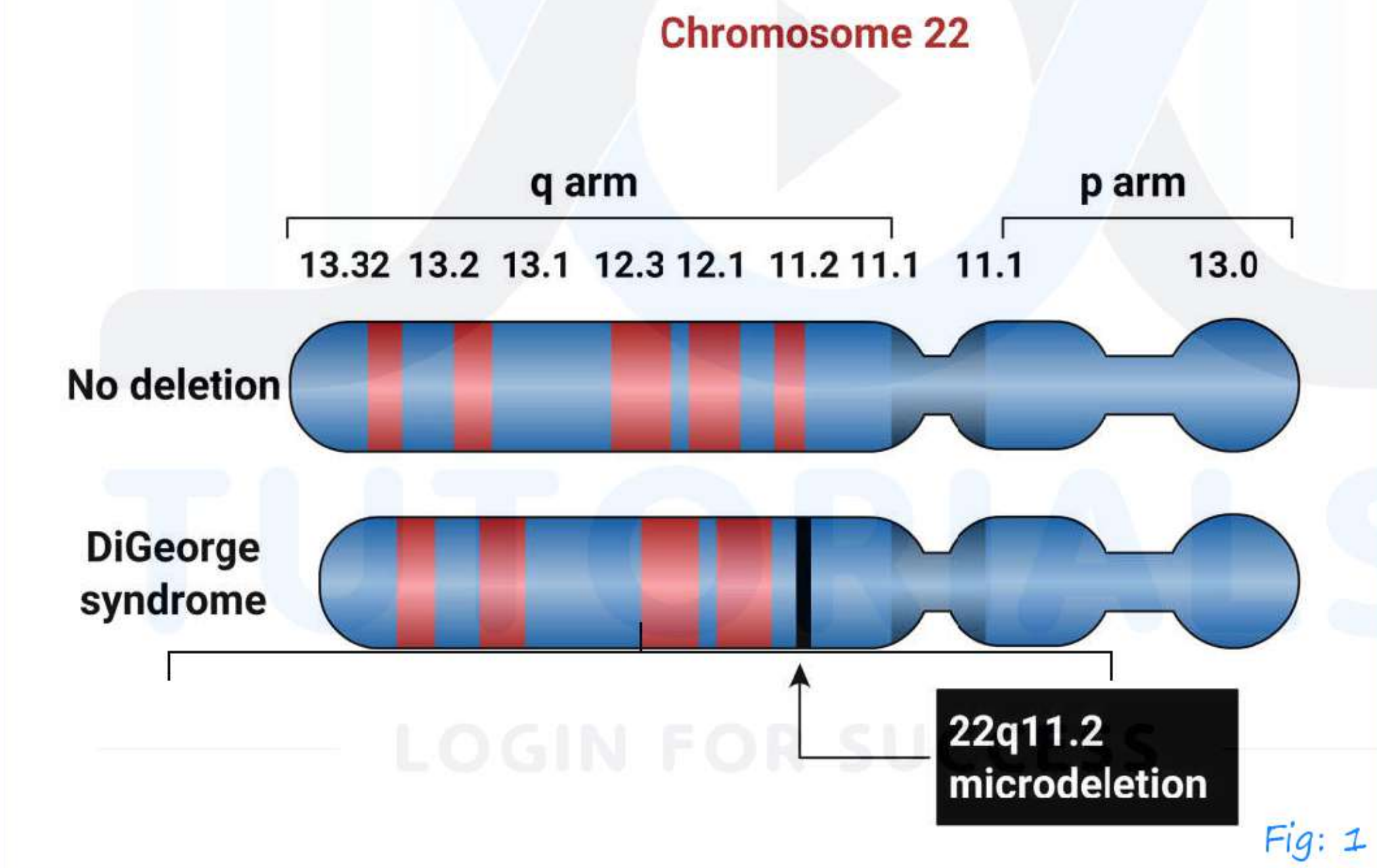

Fig: 1

  - This deletion results in **failure of development of 3rd and 4th pharyngeal pouches**

Hypoplasia of thymus	Hypoplasia of parathyroid	Heart and vessels defect
↓	↓	↓
No T cells	Hypocalcemia TETANY	Cardiac defects

- One of the genes deleted at the locus if **TBX1gene,** which helps in migration of neural crest cells
- If absent → results in <u>abnormal facies</u>
- TBX1gene defects are also linked to <u>schizophrenia</u> and attention deficit syndrome

mnemonic – CATCH 22
C – Cardiac defects A – Abnormal facies T – Thymic Hypoplasia C – Cleft palate H – Hypocalcemia 22 – Chromosome 22 q 11

Fig: 2

AfraTafreeh.com
TUTORIALS
LOGIN FOR SUCCESS

- Other names of Di George syndrome
- Velocardiofacial syndrome (VCFS)
- Conotruncal anomaly face syndrome (CTAF)

Diagnosis:

- Genetic analysis using fluorescence in situ hybridization (FISH), which is able to detect microdeletions that standard karyotyping miss.

AfraTafreeh.com

- In this technique fluorescent probes are designed to tag to the gene of interest
- In deletion of the desired gene, no fluorescence is emitted.

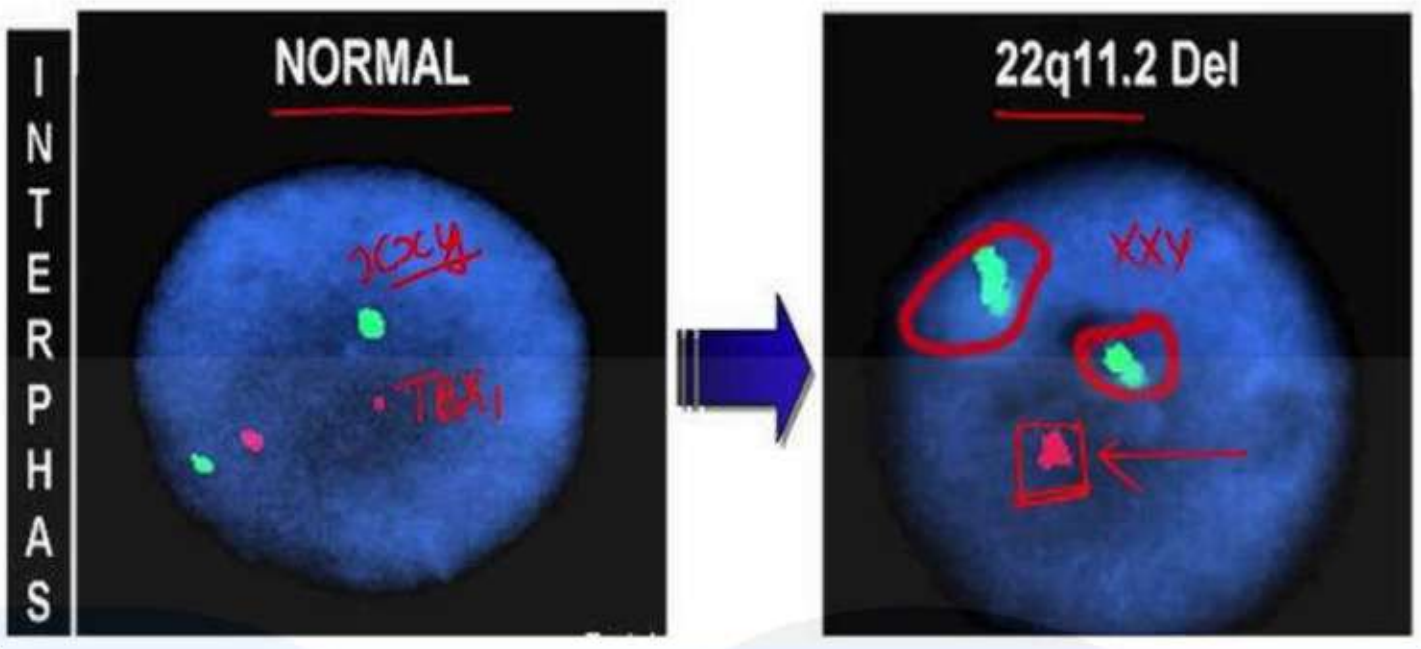

Fig: 3

Recap of primary immunodeficiency disorders

- SCID – Combined immunodeficiency
- A gammaglobulinemia – B cells absent
- Di George syndrome – T cells absent
- Bare lymphocyte syndrome – MHC II defect.

TUTORIALS
LOGIN FOR SUCCESS

LYMPHOCYTE ACTIVATION DEFECTS CLASSIFICATION AND COMMON VARIABLE IMMUNODEFICIENCY (CVID)

Lymphocyte activation and functional defects

00:00:30

a) Common variable immunodeficiency (CVID)

b) Hyper IgM syndrome

c) Isolated IgA deficiency

d) X-linked lympho proliferative disorder

Common variable immunodeficiency

- Patho physiology

  Pre B cells

  ↓

  B cells

  ↓

  Germinal center

  ↓

  Bone marrow

  ↓

  Plasma cells

  ↓

  Antibody

  From B cell → plasma cells

  Cytokine receptor BAFF

AfraTafreeh.com
DOCTUTORIALS LOGIN FOR SUCCESS

AfraTafreeh.com

If there is a defect in BAFF (B cell activating factor)

B —✗→ PC —✗→ Ab

- Conversion of B cells to plasma cells does not occur via a feedback mechanism, production of B cell increases
- More B cells enter germinal center for somatic hyper mutation and affinity maturation

↓

Germinal center hyperplasia, hyperplasia of Peyer's patches and tonsils

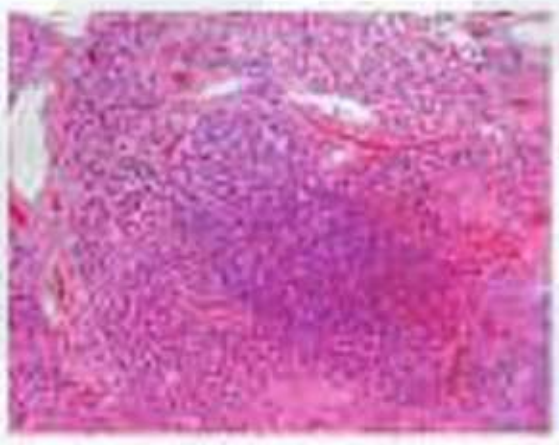

Fig: 1

Sometimes there could be a defect in ICOS gene **ICOS – Inducible Co-stimulator**

T cells receptors

CTLA4	CD28
↓	↓
Silencing	provides signal 2 for T cell activation
↓	
anergy	
↓	

ICOS stimulates CD 28

if there is a defect in

ICOS

↓

CD 28 not activated

↓

T cell activation does not occur

So BAFF defective

↓

- B cells present
- No plasma cells

ICOS defective

↓

Co-Stimulation of T-cell absent

- BAFF defects is more common than ICOS defect. Thus, clinical manifestation could be either due to B cell or T cell defect there by named common variable immune deficiency

AnaTutorial.com TUTORIALS LOGIN FOR SUCCESS

Clinical presentation

- BAFF defect – Autosomal receive inheritance
- Presents at a later age

AfraTafreeh.com

No plasma cells

- Lack of IgG
  ↓
  No opsonization
  ↓
  infection by capsulated organisms example: Pneumococci
- lack of IgA
  ↓
  recurrent giardiasis
- enterovirus
- herpes virus

Gist

Pre-B || → B cell || → Plasma cells → Ab

Baff (Cytokine Receptor)

Bruton Agamma Globulinemia	CVID
i. Age more than 6 months ii. No B cells → No plasma cells iii. No germinal center iv. No peyer's patches v. XLA	i. Late childhood ii. B cell normal, No plasma cells iii. Hyperplasia of germinal centers iv. Has peyer's patches v. Higher chances of recurrent giardiasis

HYPER IGM, ISOLATED IGA DEFICIENCY, X LINKED LYMPHOPROLIFERATIVE DISORDER AND RECAP OF ALL IMMUNODEFICIENCY DISEASE

Lymphocyte activation disorders 00:00:30

- Common variable immunodeficiency
- Hyper IgM syndrome
- Isolated IgA deficiency
- X-linked proliferative disorders

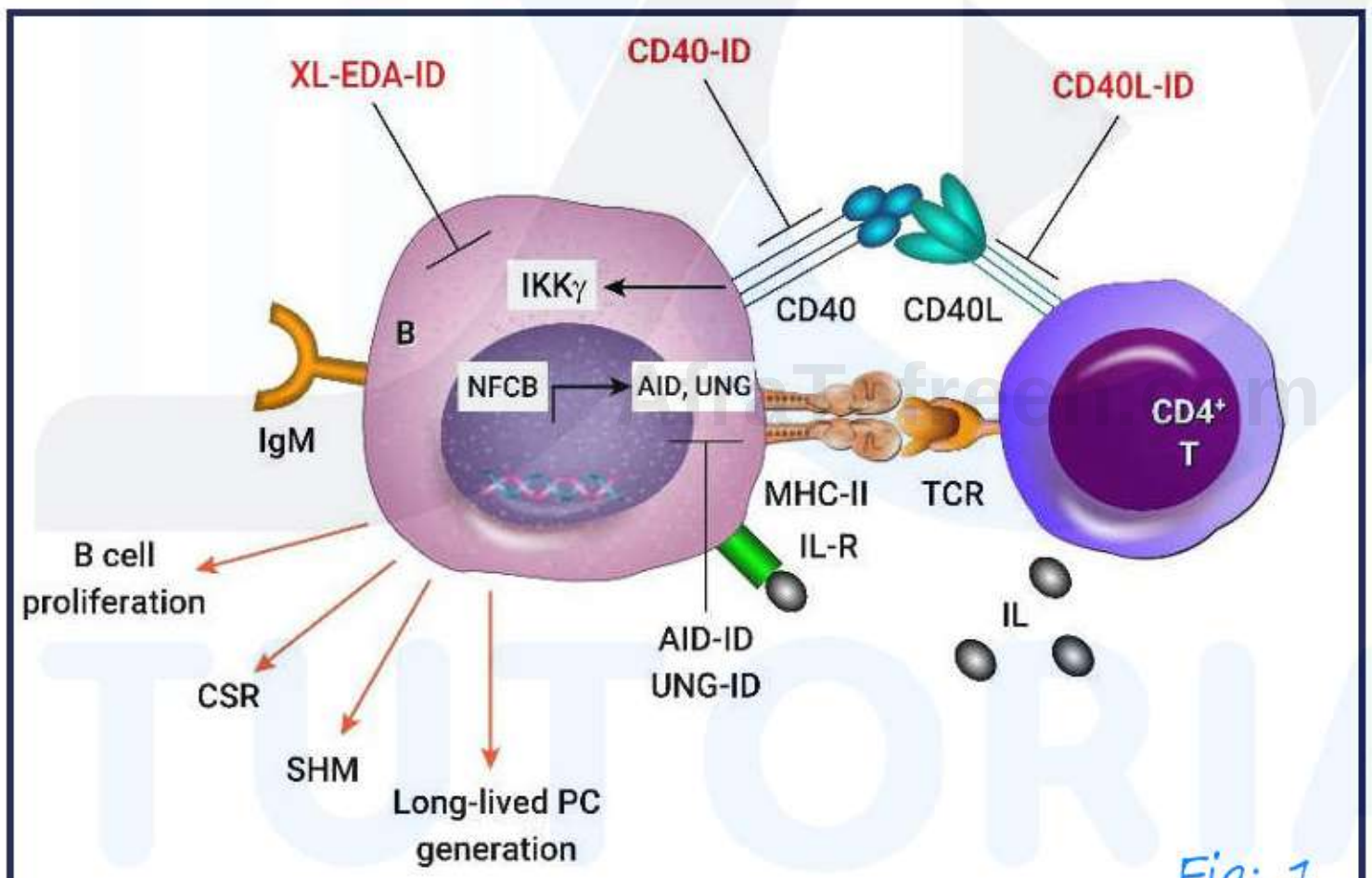

Fig: 1

Hyper IgM syndrome 00:00:06

Competence signal

a) Isotype switching of immunoglobulins – IgM to IgG/A/D/E

b) Affinity maturation – Polysaccharide's antigen to protein antigen processing

c) Macrophage activation

AfraTafreeh.com

- Most common defect is absence of CD 40 ligand on T cells in **<u>Inherited as X-linked recessive</u>**
- <u>Other rare causes</u> – Autosomal recessive

a)<u>Absence of CD 40 receptor</u> on B cells

b)Absence of <u>activation induced cytosine deaminase (AID) enzyme.</u>

There is no interaction of B and T cell

↓

No competence signals

↓

No isotyping switching from IgM to IgM to IgG/A/D/E Causing hyper IgM syndrome

↓

Also there is no activation of macrophages

↓

Macrophages are not able to process pneumocystis antigen causing infections

<u>Diagnosis:</u>

a)demonstrating absence of CD40 L over T cell by flow cytometry

b)CD marker used to identify CD 40 L is CD 154

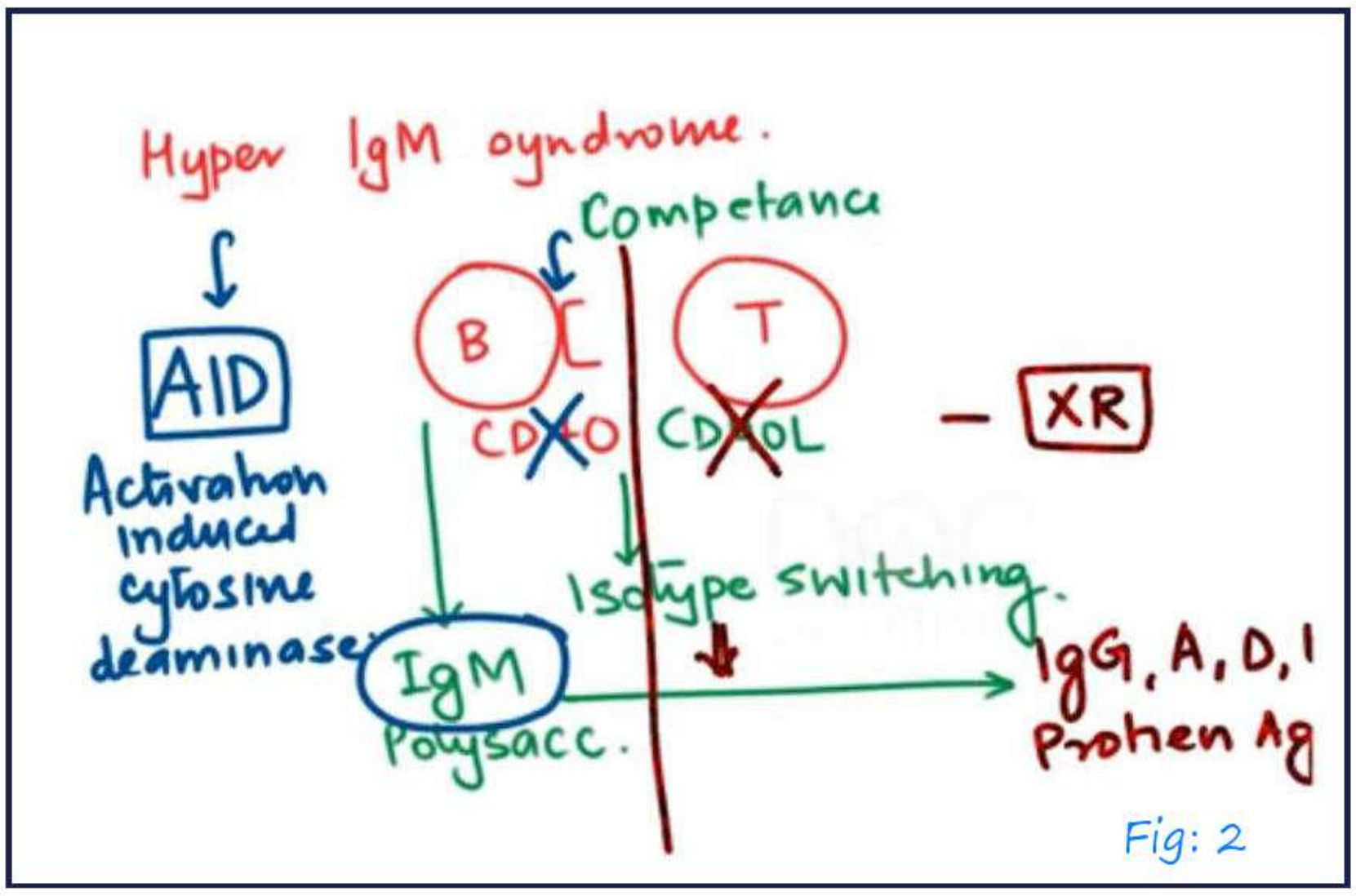

Diagnosis – Flow Cytometry - absence of CD4ol

Isolated IgA deficiency 00:06:33

- This can occur either as an isolated deficiency disorder or as a part of common variable immunodeficiency
- Since IgA antibody provides mucosal defenses, these patients are prone to recurrent respiratory tract infections
- Recurrent diarrheas

Clinical relevance of isolated IgA deficiency

- These patients are prone to anaphylactic relation with blood transfusion
- Always transfuse saline washed RBC to these patients

X linked lymphoproliferative disorders 00:09:52

- Present with severe EBV infections and lymphoproliferation

AfraTafreeh.com

- Cause-Defect in SAP (SLAM activating protein) on chromosome X SLAM stands for Signal Lymphocyte activation molecule crucial for proper functioning of B, T and NK cell

Pathophysiology:

a)Defect in SLAM

↓

Defect in SLAM

↓

Defective functioning of B, T and NK 12

↓

EBV (Ebstein Bar Virus) infects B cells via CD 21 and in the absence of T and NK cell functioning

↓

B lymphocytes proliferate excessively

b)Follicular helper cells

- Normally B cells are present in follicles and T cells in para follicular area
- CD4 T cells from para follicular area migrate to follicles to help in proper formation of germinal center these are labelled as follicular helper cells
- Because of defect of SLAM → **follicular helper cells** Cannot migrate → germinal centers are not formed

Lymphocyte activation and function defects

a) CVID – Defect in BADD or ICOS

b) Hyper IgM syndrome – CD40 L/CD40R/AID enzyme deficiency

c) Isolated IgA deficiency – transfuse only saline washed RBCs

X Linked lymphoproliferative disorder – Defect in SAP EBV infections

Lymphocyte maturation defects

a) SCID – Inherited as either XLR or AR

b) Bruton agammaglobulinemia – BTK gene mutation

c) Di George syndrome – chr 22q 11 (TBX1 gene)

d) Bare lymphocyte syndrome – MHC II defect

AllaTafeeh.com
DOC TUTORIALS
LOGIN FOR SUCCESS

AfraTafreeh.com

WISKOTT ALDRICH SYNDROME

Classification of immunodeficiency diseases

00:00:18

- Defect in lymphocyte maturation
- defect in lymphocyte activation and function
- associated with systemic disorders
  - Wiskott Aldrich syndrome
  - Ataxia telangiectasia

Wiskott Aldrich syndrome

00:01:08

- X linked recessive disease
- Defect in WASP gene on **chromosome x p (short arm)**
- WASP gene helps in joining of receptors to cytoskeleton of cells, thereby also helps in movement of cells

Systemic manifestations

1) **Thrombocytopenia and small sized platelets**
   - Pinching of platelets from megakaryocytes requires intact cytoskeleton. In Wiskott Aldrich syndrome platelets formed are less in number and smaller sized.
2) **Immunodeficiency**

Ig M ↓

Ig A↑ Ig E ↑

Ig G Normal

- Therefore, IgM is less. Polysaccharide antigens are not processed causing increased risk of infection

3) Recurrent eczema

'TIE' triad – mnemonic

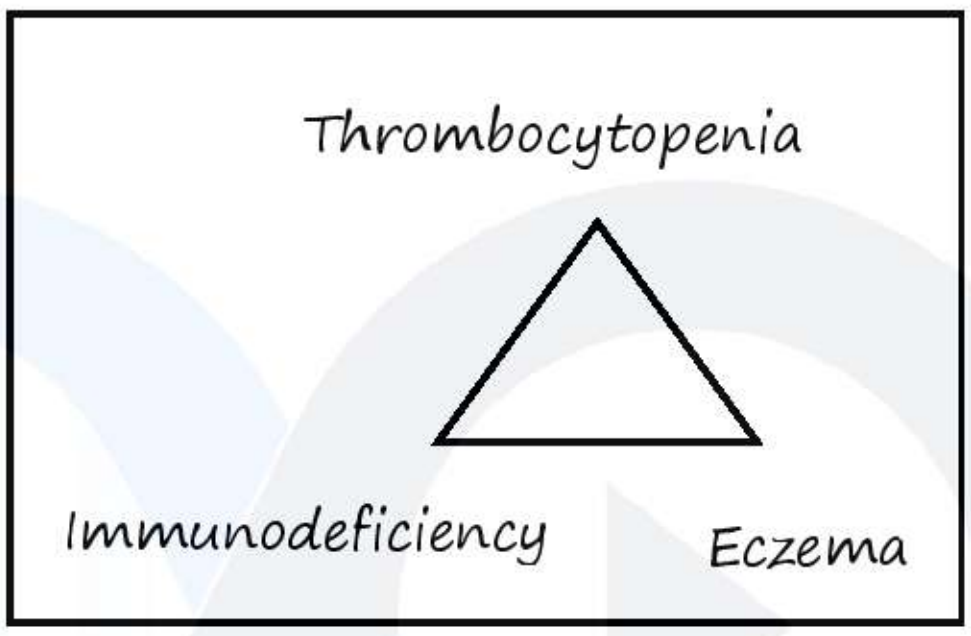

AfraTafreeh.com
TUTORIALS
LOGIN FOR SUCCESS

AfraTafreeh.com

CYTOPLASMIC PROTEINS AND IMMUNOHISTOCHEMISTRY

Normal Cell

- Eosinophilic cytoplasm
- Basophilic nucleus
- Nuclear chromatin

Cytoskeleton 00:00:05

- Cellular elements that lend shape & form to the cell
- Primarily three filaments
  i. Microtubules
  ii. Microfilaments
  iii. Intermediate filaments

I. Microtubules

- Hollow fine tubules made up of protein called tubulin.
- They are polar with assembly (polymerization) at one end (plus end) & disassembly (depolymerization) at other end (the minus end)
- They are dynamic portion of cell cytoskeleton
- Function to determine cell shape and cell movements.
- Microtubules are necessary for formation & function of mitotic spindles.

II.Microfilaments – (5-9.5 nm diameter)00:02:22

- Filamentous structures, made up of two of F-actin (filamentous actin) stands that are coiled helically
- Actin is the most abundant protein in mammalian cells, and is most often associated with muscle contraction
- 2 types of actins
  a. G actin (Globular)
  b. F actin (Filamentous)
- Similar to microtubules, Microfilaments move about by polymerization at one end & depolymerization at other end.
- Microfilaments are abundant in lamellipodia. The processes that cell put out when they crawl along surface.

III. Intermediate filaments (diameter 10-12 nm) 00:03:00

- Unlike microtubules & microfilaments, intermediate filaments are very stable & remain mostly polymerized, not undergoing rapid assembly & disassembly & not disappearing during mitosis, as do actin & many microtubules.

AfraTafreeh.com

- Important exception to this is lamins, which subsequent to phosphorylation, disassembly at mitosis & reappear when it terminates.

6 types of intermediate filaments

i. Cytokeratin (epithelial tissue) – carcinoma
   Eg. Squamous cell carcinoma

ii. Vimentin – present in fat cells endothelial cells, smooth muscle, mesenchymal tissue.
   Eg. Lipoma, liposarcomas, endothelial cancers, smooth muscle myomas, melanoma

iii. Desmin – (skeletal muscle) – positive for Rhabdomyosarcoma.

iv. Neurofilament – present in 2 types of tumors

   A. Neuro-endocrine tumor (NET)
      a. Carcinoid
      b. Pheochromocytoma
      c. Neuroblastoma
      d. Small cell carcinoma lung

   B. Neuronal tumor of Brain
      a. Ganglioglioma
      b. Gangliocytoma
      c. Neurocytoma

v. Glial fibrillary acidic protein (GFAP)
   - Positive for Glial tumors of brain
      a. Astrocytoma
      b. Ependymoma

c. Oligodendroglioma

vi. Lamin (A, B, & C) – In nuclear lamina.

Applied pathology

- Intermediate filament, Lamin present in Nucleus is derived from genes LMN (A, B & C)
- Acquired mutation of Gene LMN (A) → No synthesis of lamin which result in premature aging (progeria)
- This syndrome is called as Hutchinson Gilford Syndrome.

Immunohistochemistry 00:12:46

- Artificial antibody covered with fluorochrome.

Ab
↓
Target – Tumor tissue (antigen)

AfraTafreeh.com

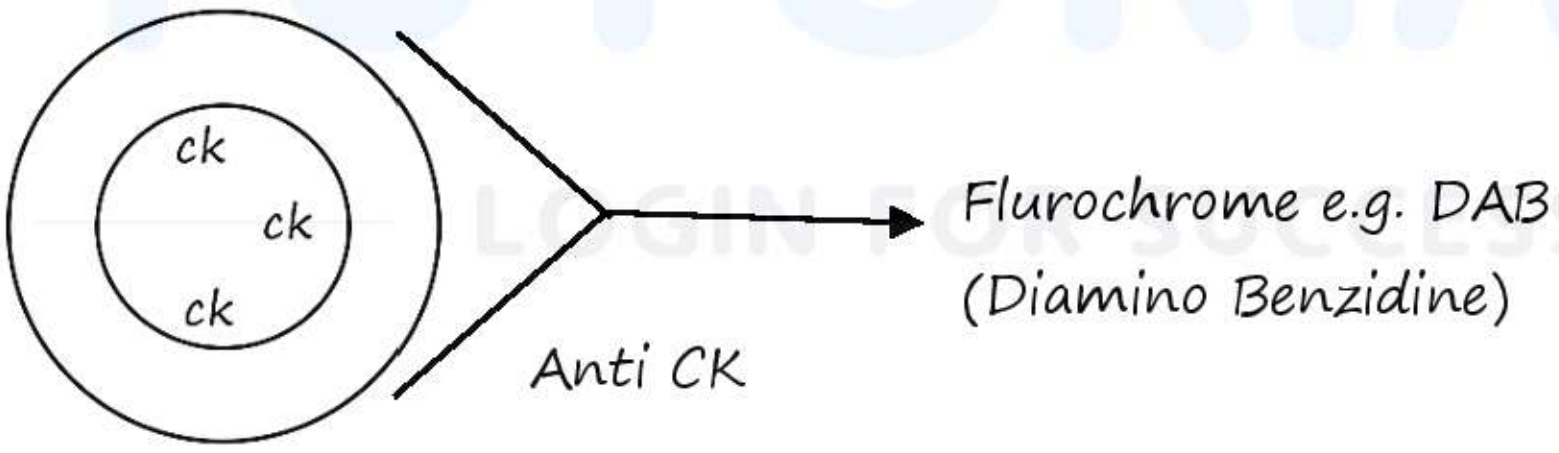

AfraTafreeh.com

- Basis – Intermediate filaments



Present

DHC staining patterns

- If high in a cell EM increase Hallmark of cell injury
- Cytoplasmic
- Membranous

Nuclear pattern 00:22:40

		
E.g – i. Steroid hormone receptors - ER, PR ii. Ki – 67 (mitotic activity marker)	i. Cytokeratin ck ii. Vimentin iii. Desmin iv. S100	i. Her 2 Neu.

iii. HMB45 – (Melanin specific marker)
Pecoma

iv. TTF-1

Thyroid Transcription Factor – 1

(Positive in adenocarcinoma lung)

- S100 positive tumors
  i. Neural tumors – Schwannoma, Neurofibroma
  ii. Melanoma
  iii. Cartilagenous tumors
  iv. Histocytic tumors Eg; Langerhans cell histiocytosis LCH.

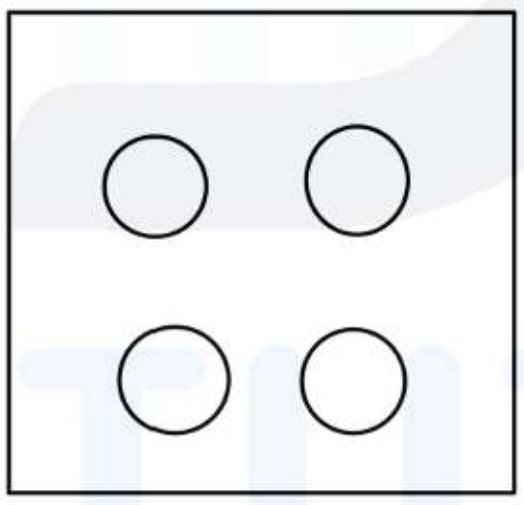

Membranous pattern of staining in her 2 Neu positivity

AfraTafreeh.com

Scoring of HER-2 Immunochemistry Arrays

- Based on intensity and percentage of membrane positive cells, giving a score of 0 to 3+

  3+ = positive her 2 neu (circumferential complete staining in >10% of tumor)

  2+ = Equivocal – Require confirmation with FISH

  1+/0 – Negative.

AfraTafreeh.com

MICROTUBULES, CILIOPATHIES & CILOCYTHOPTHORIA

Molecular motors 00:00:06

Axoplasmic transport

- Physical transport of substances through axoplasm
- Requires Ca^{+2} ATP (energy), microtubules, microfilaments (sometimes) and molecular motors.

MICRO TUBULES

a) Hollow tubes formed of protein "Tubulin" having 2 subunits α and β

b) It has 2 ends

(+) Assembly end (-) Disassembly end

- In a state of dynamic instability

c) They serve as 'tracks'

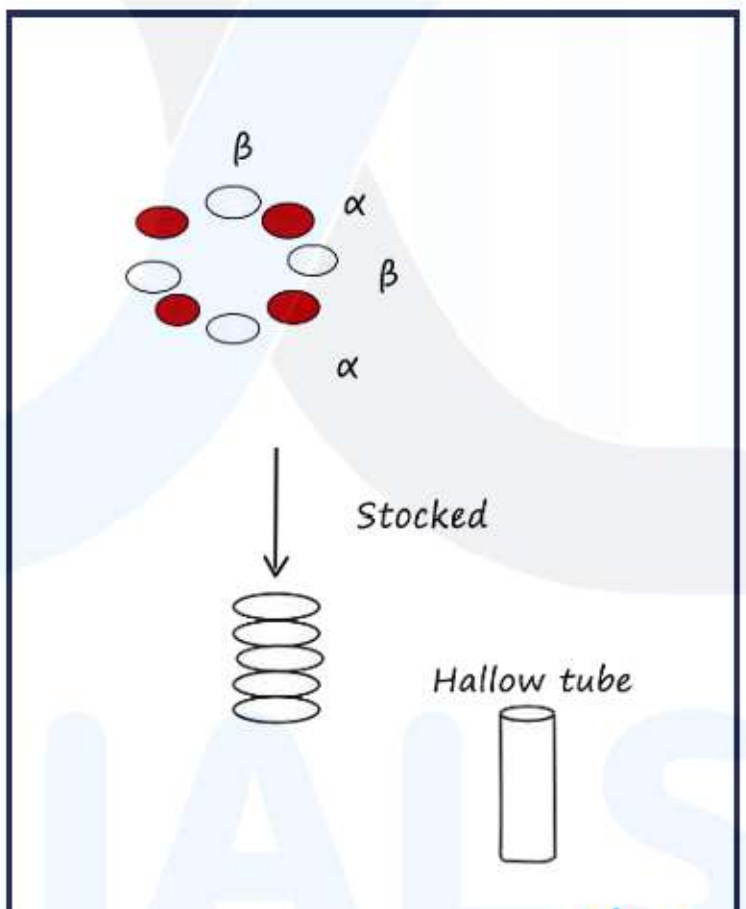

Fig 1

d) They are major structural components of cilia and flagella, also are a major component of axons and dendrites

Microfilaments

- Solid tubes
- Sometime function – as tracks

Molecular motors

- 100-500 KDa ATPase

Example: Kinesin

Myosin 4

Dynein

Types of axoplasmic transport

Fast transport

Anterograde

400mm/day

- Towards plus end of microtubule

Uses molecular motors

- Kinesin
- Myosin V

Molecules transported

- Vesicles
- Neuropeptides
- Mitochondria
- Reticulum
- Lysosomes

Retrograde

200mm/day

- Towards minus end of microtubules
- Uses molecular motor
- Dynein

Molecules transported

- AV neurotropic viruses
- Rabies
- Tetanus toxin
- Nerve growth factor

Slow transport

- Always anterograde
- At 0.5-10 mm/day

AfraTafreeh.com
TUTORIALS
LOGIN FOR SUCCESS

AfraTafreeh.com

Molecules transported

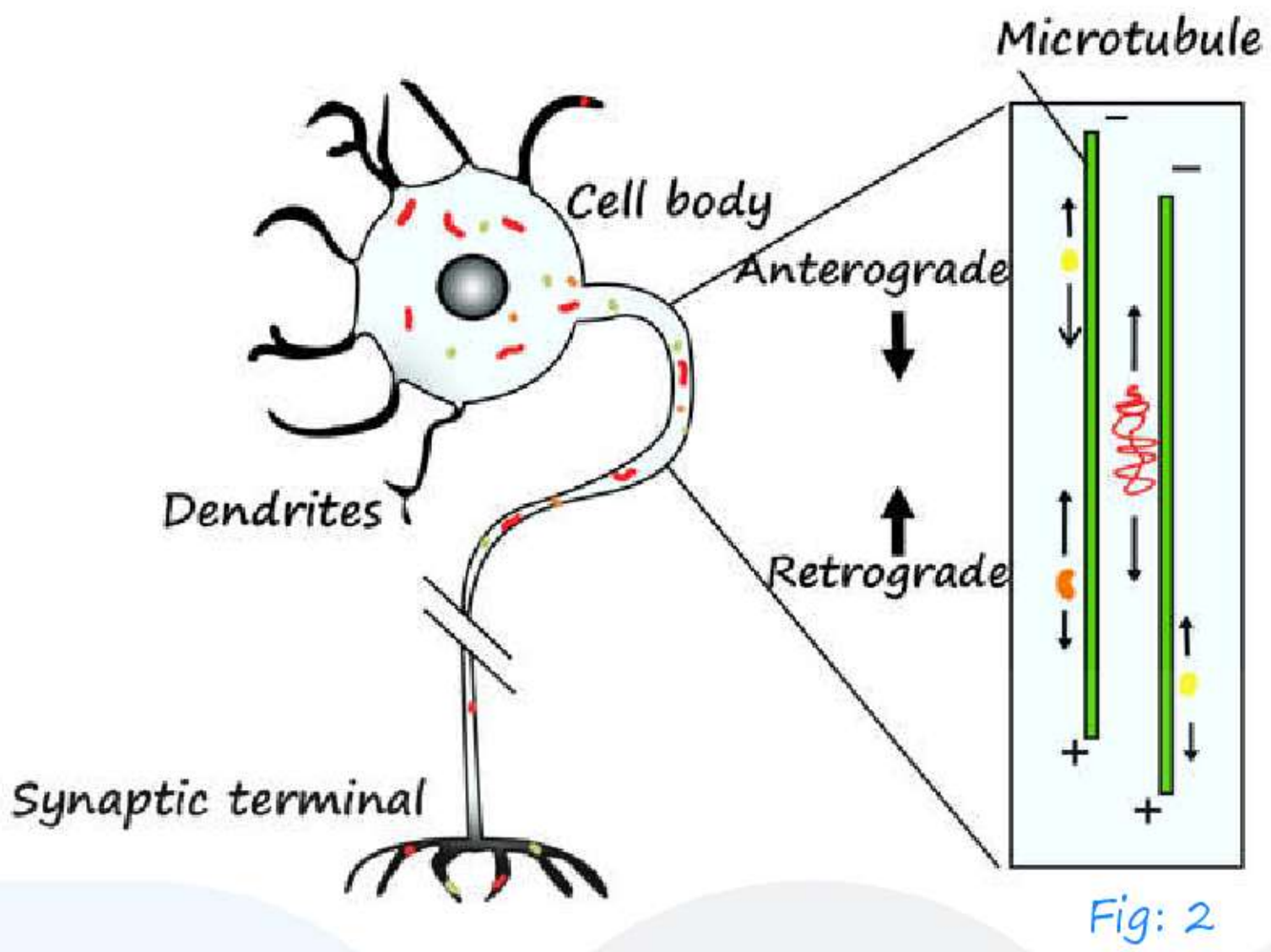

Fig: 2

Ciliopathies 00:03:13

- Group of disorders associated with genetic mutations encoding defective proteins, which result in either abnormal formation or function
- As cilia are a component of almost all vertebrate cells, cilia dysfunction can manifest as a constellation of features, including retinal degeneration, renal disease and cerebral anomalies.

Example:

1.Bardet biedl syndrome

2.PCKD

3.Joubert syndrome (MRI – Molar tooth sign)

4.Meckel Gruber syndrome

5.Senior loken syndrome

Cilio Cyto Pthoria 00:06:52

- Papanicolau coined the term ciliocytophtoria (CCP) to identify the degenerative process in the bronchial ciliated cells consequent to viral infection by influenza virus, Corona virus, at least three distinct phases of CCP are distinguishable during viral infection



Normal ciliated cell with a homogenous cytoplasm and hyperchromatic

Initial same word of ciliary apparatus with disappearances of stria-Early cytoplasmic vacuolization

Further rarefaction of ciliary apparatus with disappearance and confluence of inter cytoplasmic vacuoles in the nucleus chromatin coalesce with a peripheral halo

Decapitation of Apical portion of ciliated cell

Fig 3

AfraTafreeh.com
LOGIN FOR SUCCESS

AfraTafreeh.com

CELL TO CELL INTERACTIONS PART – I

- The extracellular matrix (Ecm) surrounding cells includes.
- Basement membrane (BM) and interstitial matrix (Icm) or intercellular matrix.

Linkage between cells (Intercellular junction):

00:02:44

Intercellular junctions fasten cells to each other and to basement membrane.

Types

Tight junction junction	Gap junction	Anchoring
i. Bind adjacent cells and prevent movement of ions and other molecules across intercellular space ii. Maintain polarity of cells	i. They are intercellular connections called hemichannels or connexons ii. Made up of protein subunits "connexins" iii. Gap narrows down to 2nm at gap junctions	• Cell to cell • Cell to CM

iii. Tight junction is seen in epithelial cells of intestine, Renal tubules, Gall bladder and choroidal plexus. iv. They are made up of ridges of adjacent cells. Example: • Zona occludens • Catenins • Claudins • Zonulin • Occludins	iv.Connexons permits substances (ions and others) to pass from one cell to other: i.e they conduct Ionic currents. v. Gap junctions are seen in cardiac and smooth muscles 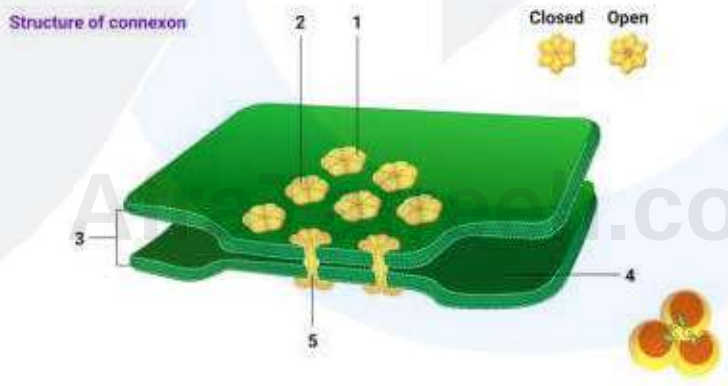	

Figure 1: structure of connexon

1.Connexon

2.Connexin monomer

3.Plasma membranes

4.Intercellular space (2-4nm)

5.Hydrophilic channel

AfraTafreeh.com

Adhesive/Anchoring junction: 00:08:30

I. Cell to cell

1.Zona adherens

- Immediately below Zona occludens
- Formed by microfilaments
- Like Zona occludens they strongly bind adjacent cells and maintain polarity of cells

2.Desmosomes

- Characterized by local thickening of adjacent membrane
- Intermediate filaments converge at desmosomes of two epithelial cells

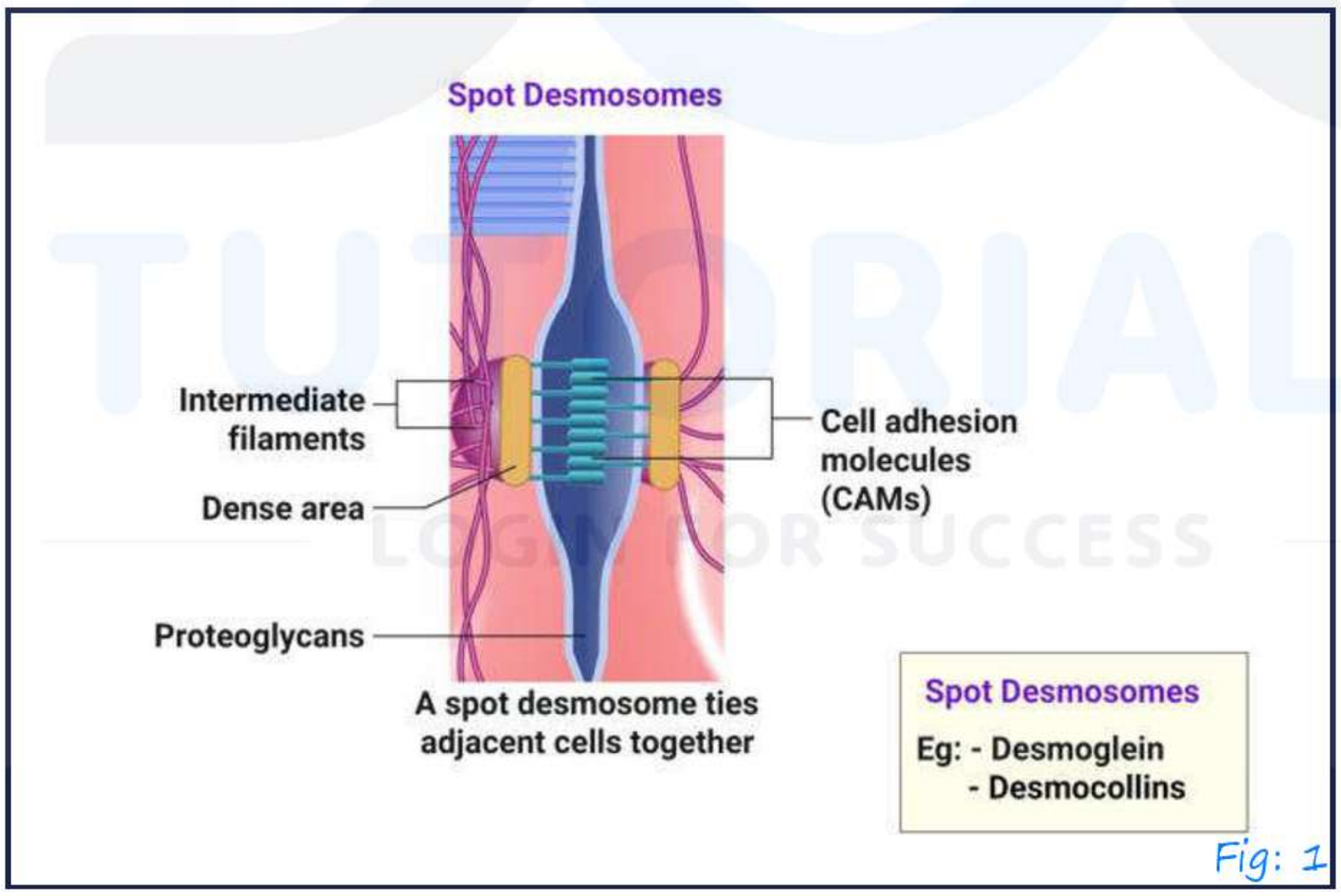

Fig: 1

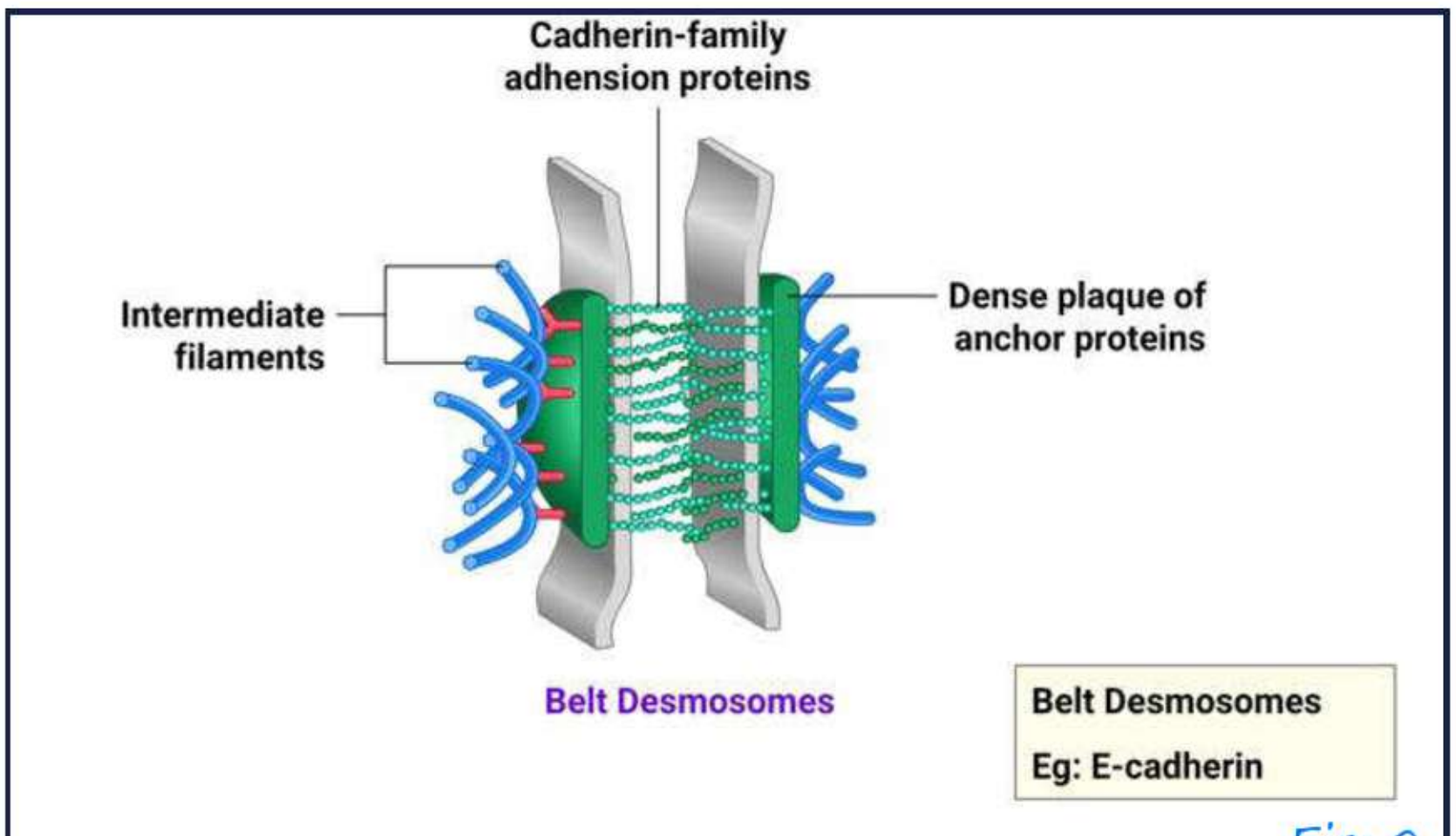

Fig: 2

- Loss of contact inhibition is a mechanism by which tumor cells metastasize
- E – cadherin is responsible for 'contact Inhibition" [Belt desmosomes]

II. Cell to ECM

- Hemidesmosomes (Half of the desmosome) attach the epithelial cells firmly to underlying connective tissue (like Basement membrane)

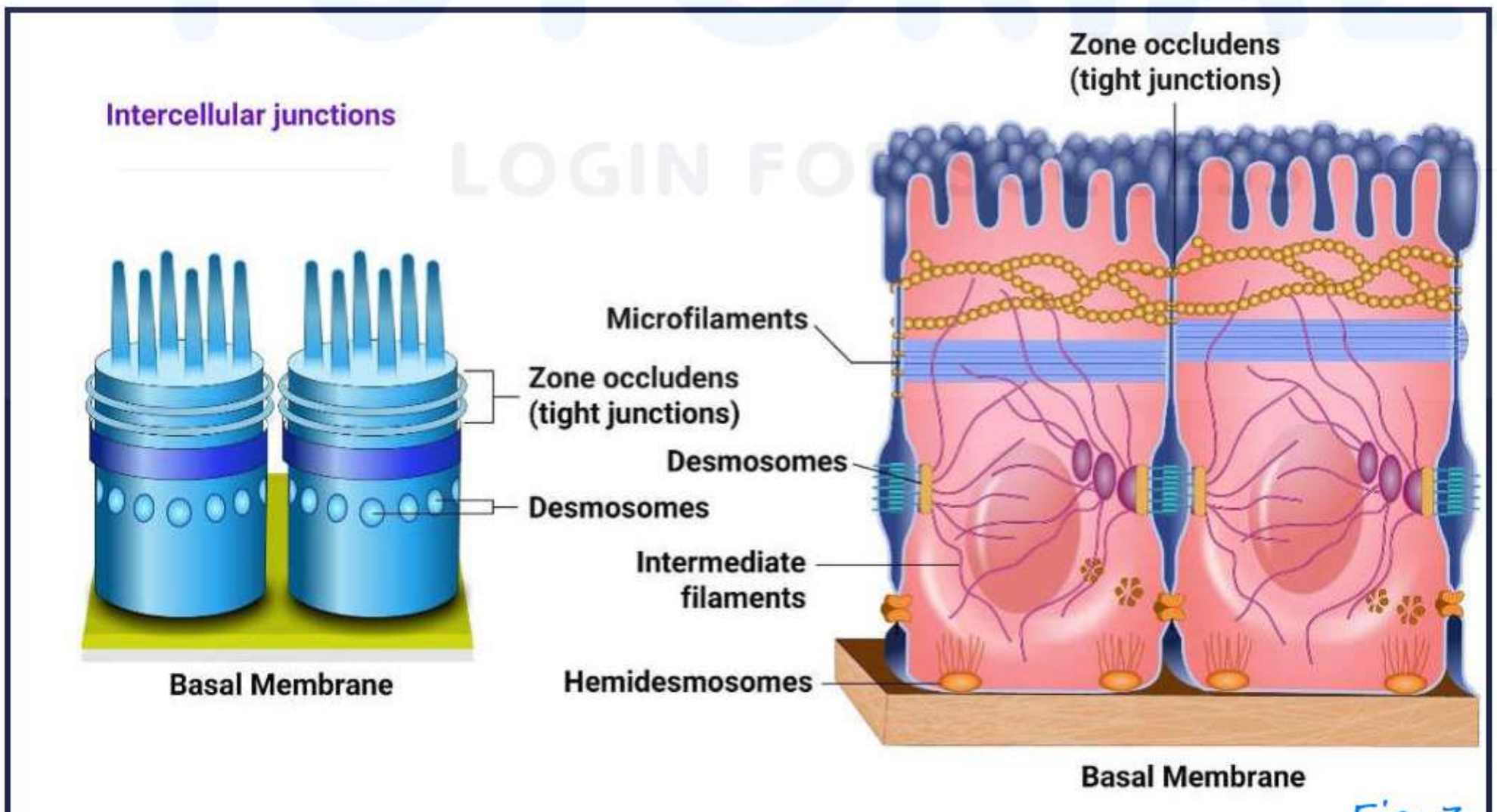

Fig: 3

AfraTafreeh.com

- Intercellular junction, (left) The Zona occludens and zona adherens forms a continuous ring around the cell
- The desmosomes form an interrupted ring around the cell, (Right) Longitudinal section of two cells showing intercellular junctions
- The zona occludens forms the tightest junction and usually does not permit movement of electrolytes across them.

Types of desmoglein and associated disorders:

00:15:20

- Desmoglein
  - Type 1 → upper part of skin's epithelium
  - Type 2 → present in cardiac cells
  - Type 3 → lower part of skin epithelium
  - Type 4 → present in hair. If defective it leads to hypotrichosis.

Types 1 and 3 = In skin.

Arrhythmogenic RV-CM (Right ventricular Cardio Myopathy)

- AD
- Defect in gene encoding desmosome 2
- Gross specimen

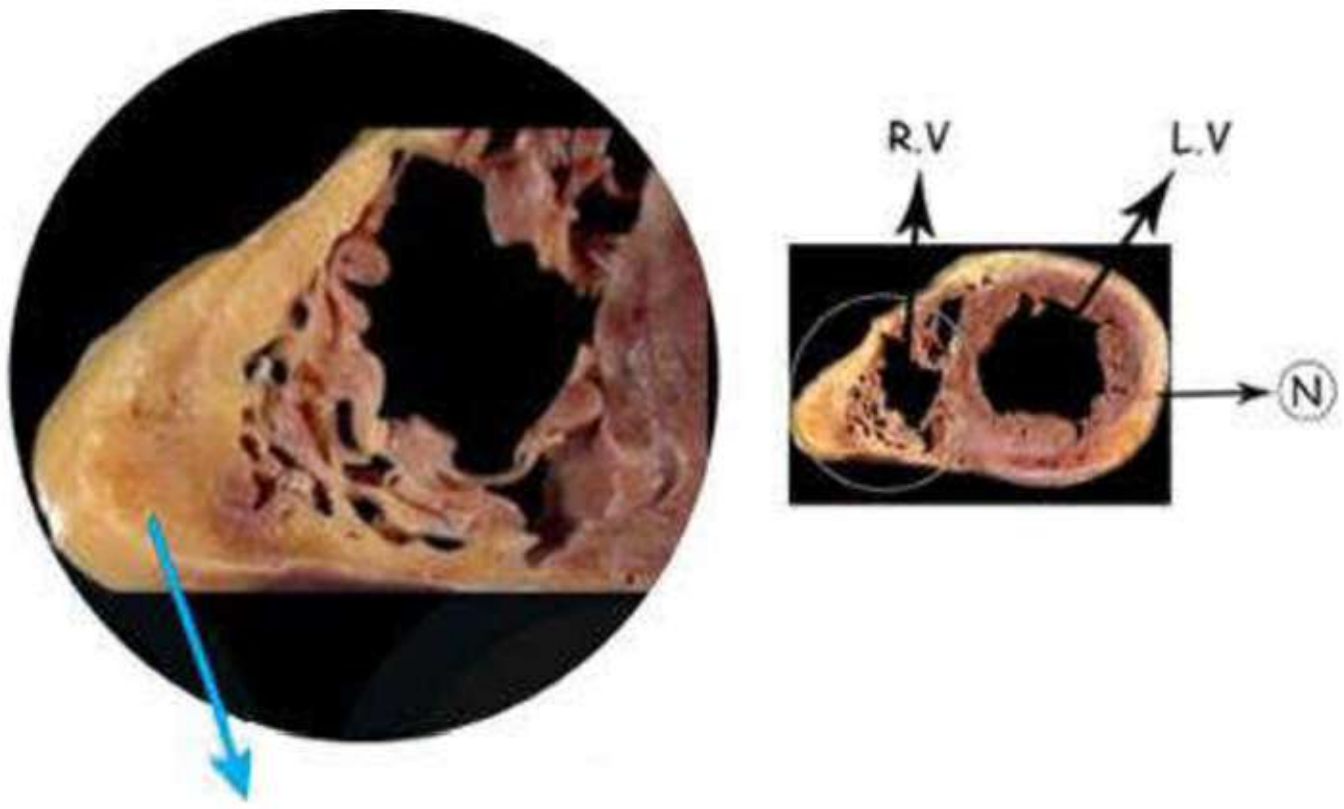

Fig 4

Yellow tissue

↓

Fibro-fatty tissue replace Rt ventricular wall

↓

Responsible for arrhythmia

↓

Arrhythmogenic R.V CM.

Fibro-fatty pale

↓

Blue on Masson's trichome:

Naxos syndrome

↓

Mutation in plakoglobin gene

- Wooly hair
- Hyperkeratosis of palms and soles
- With fibro fatty replacement of R.V WALL
- Arrhythmogenic

AfraTafreeh.com

ANCHORING JUNCTION WITH BULLOUS LESIONS OF SKIN AND IMMUNOFLUORESCENCE

Hemidesmosome and its related disorder00:01:30

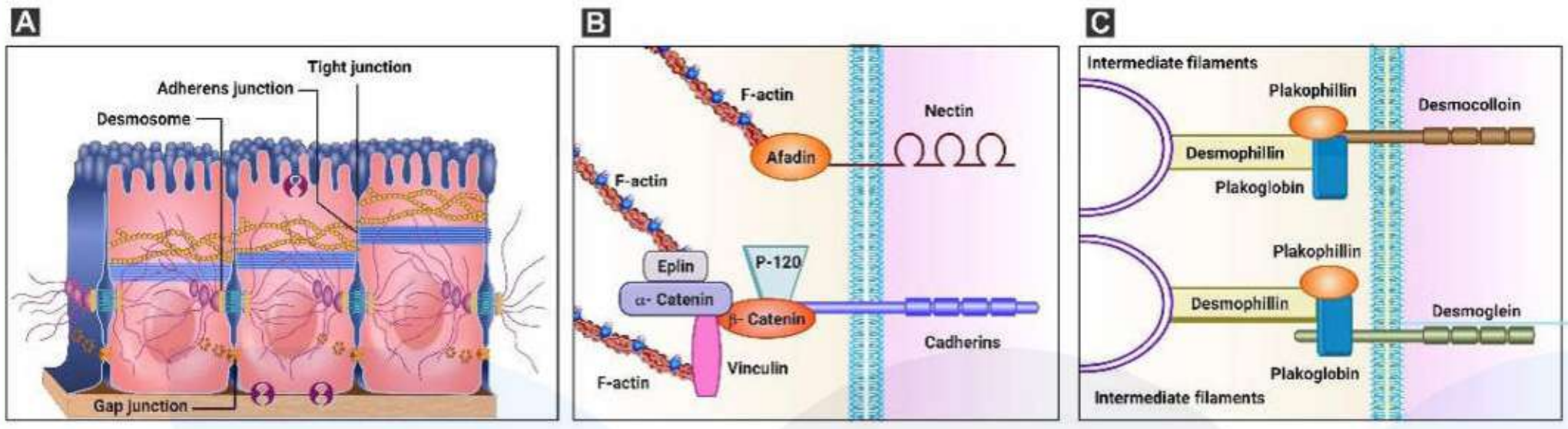

Fig 1

- Adhesive glycoprotein in BM = laminin
- Adhesive glycoprotein in ICM = Fibronectin
- Hemidesmosome attach Basal cells to basement membrane via integrins, consisting of RGD motifs (Tripeptide)
  - R-Arginine
  - G-Glycine
  - D-Aspartic acid

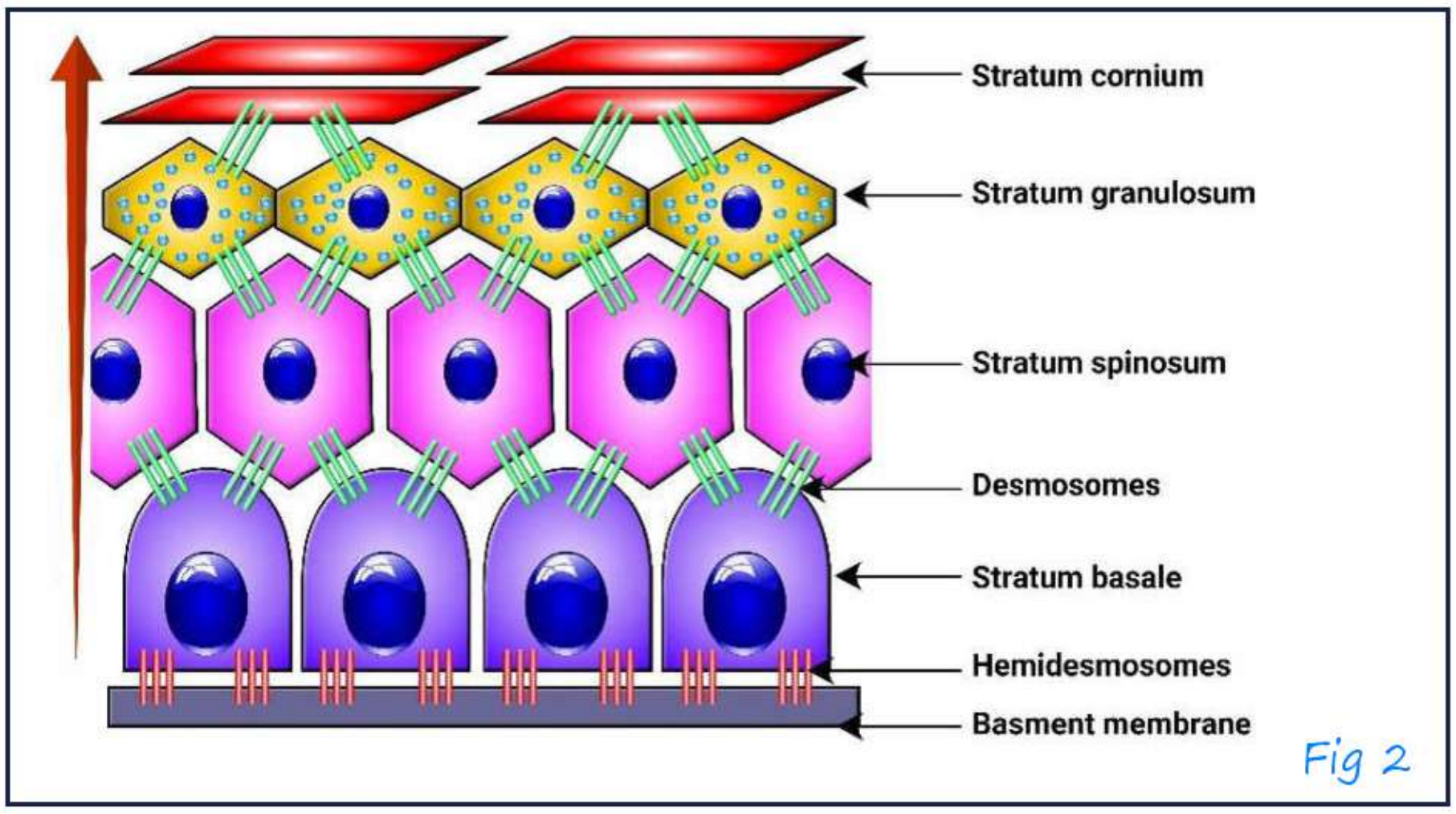

Fig 2

Stratum corneum → DSF1: Antibody against Dsg1

↓

Stratum Granulosum Pemphigus foliaceous (sub corneal Bulla)

Stratum spinosum → Desmoglein 3: Antibody against Dsg3

AfraTafreeh.com

↓

Stratum Basale pemphigus 3: Antibody against Dsg3

- Basement membrane ← Hemidesmosome Dermis

↓

- Anti-body against Hemidesmosomes

↓

- Bullous pemphigoid (sub epidermal bulla)
- Pemphigus syndrome and bullous pemphigoid are type 2 hypersensitivity

AfraTafreeh.com

Bullous pemphigoid 00:12:56

- Ab against B.M – hemidesmosomes causes separation of Epidermis from Basement Membrane resulting sub epithelial bulla
- I/F → linear ribbon like immune fluorescence (BM affected)

MIC:	Subepidermal bulla 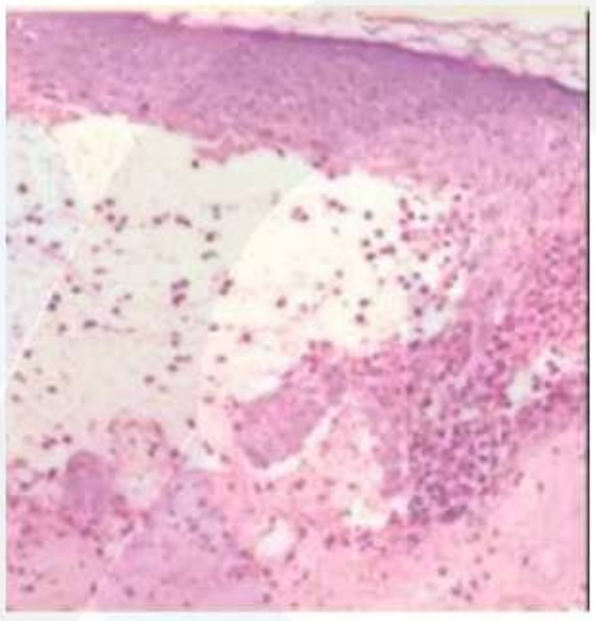
DIF:	Linear IgG, C_3 in basement membrane zone

Pemphigous vulgaris 00:15:33

- IgG against desmoglein 1, desmoglein 3 (more commonly)

- Desmoglein – protein holding 2 cells together

↓ damage

Acantholysis (cell separation)

- I/F = Fish net immunofluorescence Dye used – Fluro Iso thiocyanate (FITC) is used to tag antibody.
It gives green color immunofluorescence → Gives a fish net pattern

MIC:	Suprabasal bulla (Tombstone pattern)
DIF:	IgG deposits is intercellular spaces – fishnet pattern 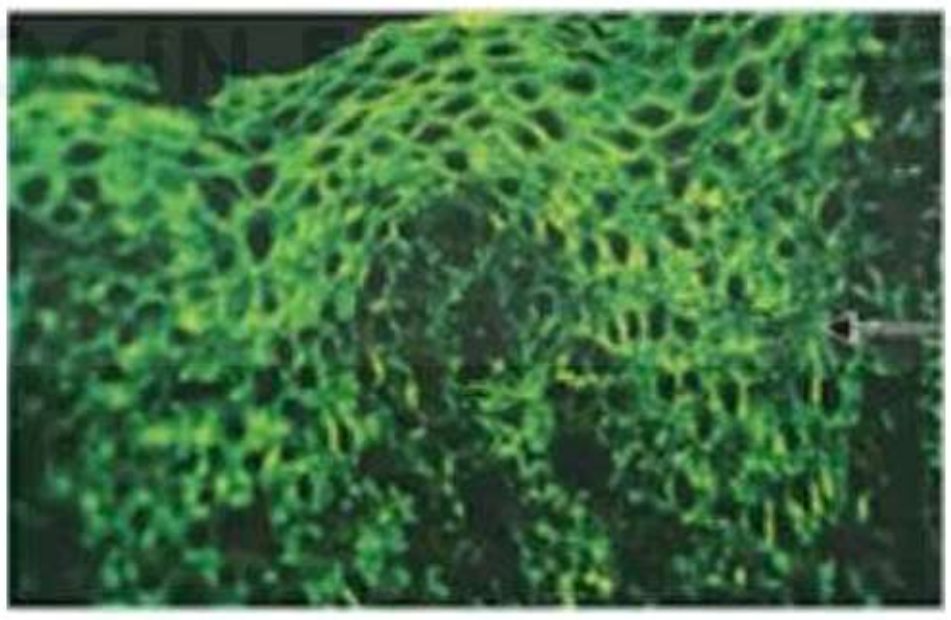 Fish Net Pattern

- Usually done to the adjacent cells of bulla and not to the bulla itself

AfraTafreeh.com

Characteristic	Pemphigus vulgaris	Pemphigus Foliaceous
i. Anti-body ii. Bulla iii. Split iv. Mucosa involvement	i. Ab against Dsg 3>1 ii. Suprabasal Bulla iii. Split between Basal layer (deep) and rest of the layers of epidermis iv. Oral mucosa is frequently involved	i. Ab against Dsg 1 ii. Sub corneal Bulla iii. Split occurs superficially in sub corneal layer of epidermis between stratum granulosum and stratum corneum iv. Rare

TUTORIALS
LOGIN FOR SUCCESS

EXTRACELLULAR MATRIX, FIBRILLINOPATHIES, MARFAN SYNDROME AND STAIN FOR ELASTIC FIBRES

Extracellular matrix proteins 00:00:05

- Giving tensile strength
  - collagens
  - Elastins
- adhesive proteins
  - In B.M → Laminin
  - In Interstitial matrix → Fibronectin (Produced by fibroblasts)
- lubricant proteins
  - Proteoglycans
  - Hyaluron

AfraTafreeh.com
TUTORIALS
LOGIN FOR SUCCESS

Fibronectin

Applied pathology:

i. Metastasis - integrins over Hemidesmosomes of tumor cells bind to fibronectin in interstitial matrix facilitating metastasis to distant areas

ii. Fibrin Glue A – Topical biological adhesive effect of which imitates final stages of coagulation. It is a form of concentrated fibrinogen prepared from whole flood by crypoprecipitation and combined with thrombin to make fibrin glue.

AfraTafreeh.com

Elastin: - 00:07:35

- Connective tissue protein that is responsible for properties of extensibility and elastic recall in tissues
- Present in lung, large arterial blood vessels, cardiac valves, uterus, tendons and some elastic ligaments

Applied pathology: -

- Mutations in elastin gene (Eln) leads to supravalvular aortic stenosis (Wiliam-Beuren syndrome)

Fibrillin

- Glycoprotein secreted by fibroblasts
- Acts as a scaffold for deposition of elastin
- Structural component of microfibrils

Applied pathology: -

- Genes coding for fibrillin – FBN 1 gene
  FBN 2 gene

TUTORIALS
LOGIN FOR SUCCESS

Fibrilinopathies 00:11:35

1. Mutation in FBN 1 gene on chromosome 15 (15q) results in marfan syndrome
   - Triad of skeletal changes – Ectopia lentils (up and out dislocation), Aortic aneurysms
2. Defect in FBN 2 gene on chromosome 5q results in

- Congenital contractual arachnodactyly (no heart + eye defects)
- FBN 2 gene is present only in embryonic life normal

  Chromosome 15 defects

  1. Marfan syndrome
  2. Angelman syndrome imprinting disorders
  3. Prader willi syndrome

  Pneumonic-map genome (2, 3)

Recent updates on marfans 00:14:06

- Resulting in,

  Defect of Fibrillin gene

  ↓

  Over activation of TGF β gene (Growth factor)

  ↓

  Causes excessive proliferation of cardiac valves

  ↓

  Resulting in cardiac anomalies like mitral valve prolapse in marfans syndrome
- So Anti – TGF B drugs are example: Losartan are given to patients of marfan syndrome
- Since fibrillin acts as a scaffold for deposition of elastin, mutations in fibrillin gene causes fragmentation of elastin fibers.

AfraTafreeh.com
TUTORIALS
LOGIN FOR SUCCESS

AfraTafreeh.com

- Special stains like Verhoff Von Gieson (VVG) and/or Von Gieson Elastic (VGE) help in visualizing Elastin fibers, as black colour fibers.
- Cystic medial necrosis a characteristic finding in biopsy of large vessels in patients of marfan

  Example: Aorta.



Fig: 1

TUTORIALS
LOGIN FOR SUCCESS

COLLAGEN AND SOME OF ITS DEFECTS AND DIFFERENTIATION OF EPIDERMOLYSIS BULLOUS FROM BULLOUS PEMPHIGOID

Collagens: 00:00:05

- Major structural protein in extracellular matrix
- Most abundant protein in the body
- Triple helix protein with hydrogen bonds in between to a wounding to a right-handed superhelix.
- Covalent cross links provide tensile strength to collagen enzyme lysyl oxidase requiring vitamin C and copper as cofactor is responsible for cross linking.

AfraTafreeh.com
TUTORIALS
LOGIN FOR SUCCESS

Applied pathology:

- Scurvy: Deficiency of vitamin C results in defective collagen synthesis. Since collagen cross linking by the enzyme lysyl oxidase is dependent on vitamin C and copper.
- Weakend collagen results in loss of tensile strength of extracellular matrix supporting blood vessels.
- There by the blood vessels rupture easily, resulting in petechiae ecchymosis, bleeding gums.

AfraTafreeh.com

Menke's (kinky or steely) Hair syndrome:

00:03:36

- X linked recessive condition (x_q)
- Mutation in ATP7A gene resulting in defective copper mobilization from intestine
- Deficiency of copper then hampers collagen cross-linkage by enzyme lysyl oxidase clinical manifestation = kinky/steely hair also known as pili torti.

Wilson's disease:

- Autosomal recessive
- ATP 7B Mutation resulting in defective biliary copper excretion from liver cells'

Types of collagens

00:05:59

Fibrillar collagens

i. Collagen type 1 – Major collagen present in Bone-also the most abundant collagen.

ii. Collagen type 3-seen in wound repair vascular system

Non-Fibrillar collagens

i. Collagen type 4 – present in basement membrane

ii. FACIT Collagen-helps in linking two fibrillar collagens together also called collagen type 9

iii. Collagen type 7 – present in dermal epidermal junction links basement membrane to underlying dermis

Applied pathology:

Epidermolysis bullosa acquista

- Group of inherited bullous disorder characterized by blister formation in response to mechanical trauma
- Pathology – Normally basement membrane is attached to basal cells of epidermis via Hemidesmosomes and is attached to dermis with the help of collagen type7.
- Mutation in collagen VII gene causes epidermo-dermal separation resulting in sub epithelial or epidermo-dermal bulla.

Bullous pemphigoid: 00:10:52

- Chronic, autoimmune subepidermal blistering disorder IgG antibodies against hemidesmosome deposit at basement membrane around dermo epidermal junction
- Linear immunofluorescence

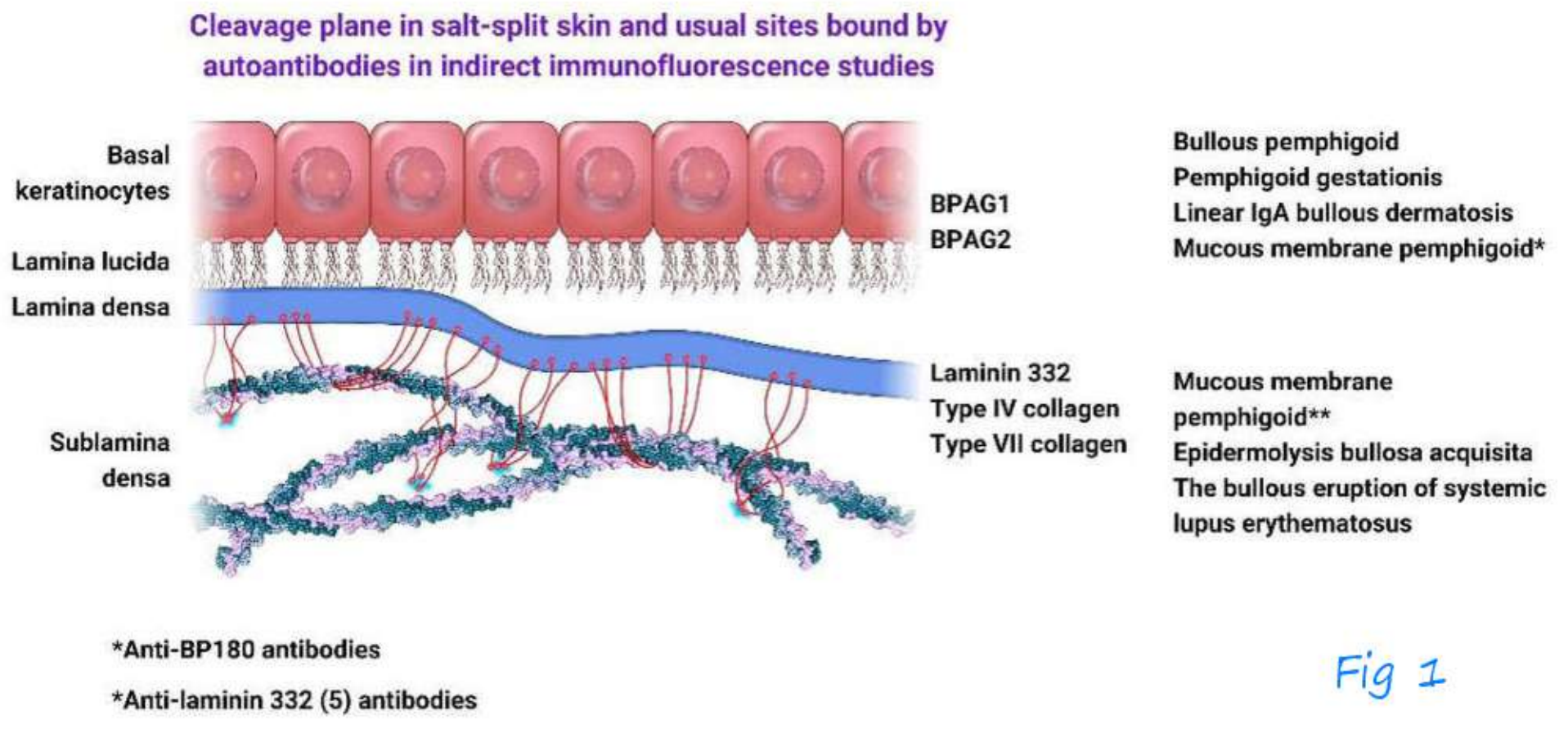

Fig 1

AfraTafreeh.com

NATURAL KILLER CELLS (NK CELLS)

- It is part of innate immunity
- It does not require antigen presentation by MHC complexes
- They are large granular lymphocytes
- Constitute only, 5-10^ all lymphoid cells
- NK-cell adhesion molecules (NK-CAM) has a marker called CD56

Fig 1

- Functional activity is regulated by balance between signals from activating and inhibitory receptors
- **NKG2D** is the main activating receptor
- CD-94 and killer cell Ig, like receptor are inhibitory receptor
- Normally inhibitor receptor of NK cell binds to MHC-I present over all nucleated cells of body

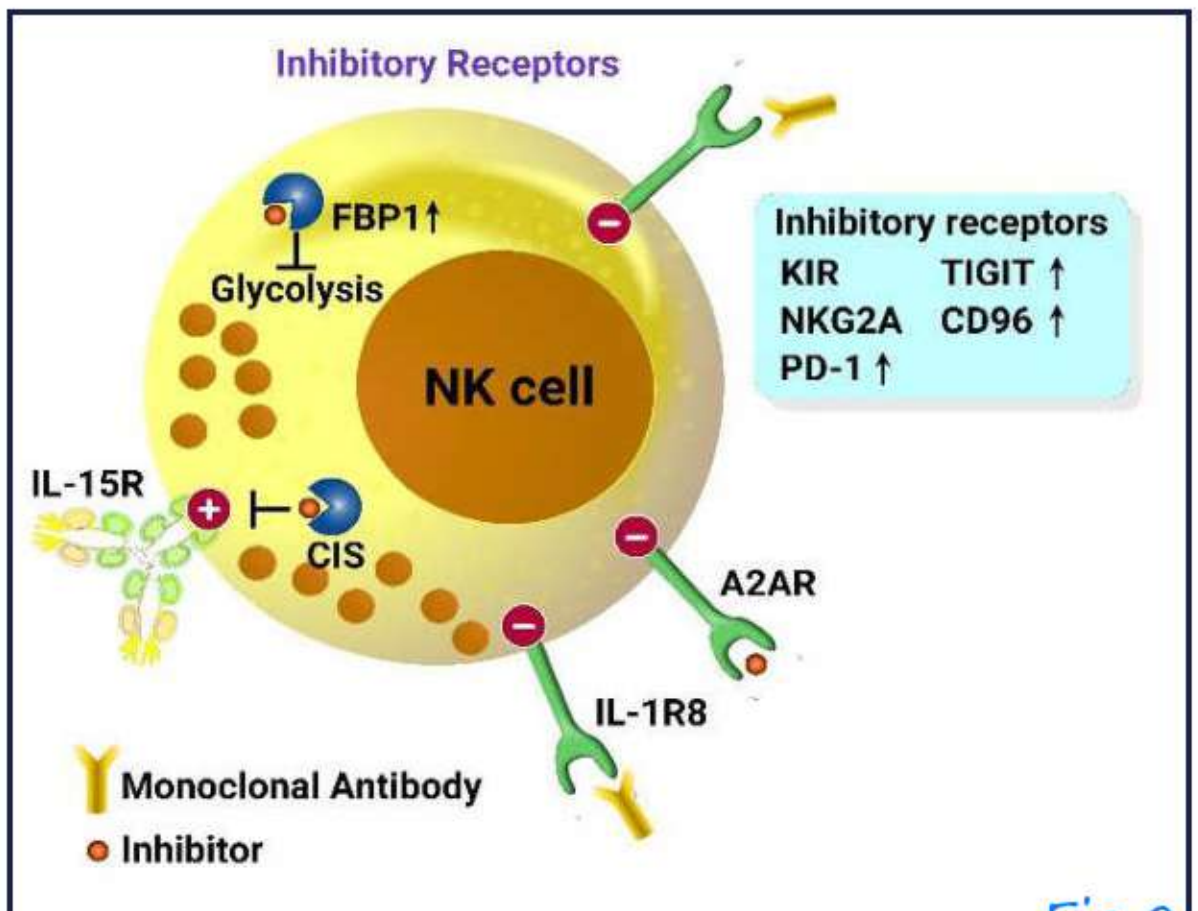

Fig 2

- So, NK cell do not kill cells which express class I MHC (All normal nucleated cells express it)
- **HLA-E is** the self-recognition target of NK cells.

Target cell killing by NK cell

- Inversely related to target cell expression of MHC class I molecule
- So, it kills cell that express little or no HLA class I molecule (provides immunosurveillance)

  Such as:

  a)Virus infected cells

  b)Certain tumor cells

  c)Allogenic cells

AfraTafreeh.com

- It kills host cells infected with intracellular bacteria

  Example: -

  - Mycobacteria
  - TB
  - Listeria.

TUTORIALS
LOGIN FOR SUCCESS

Activation arm

Kills by

- FAS-FASL Pathway
- Perforin-Granzyme Pathway

- Thus, NK cells help in **immune surveillance or 'Stress surveillance'.**

AfraTafreeh.com

LGL Express

- Receptor for NCAM-I (Cell Adhesion molecule)

↓

CD 56

- Receptor for Fc portion of IgG → CD 16 which is used for ADCC (ADCC – Antibody dependent cell mediated cytotoxicity)

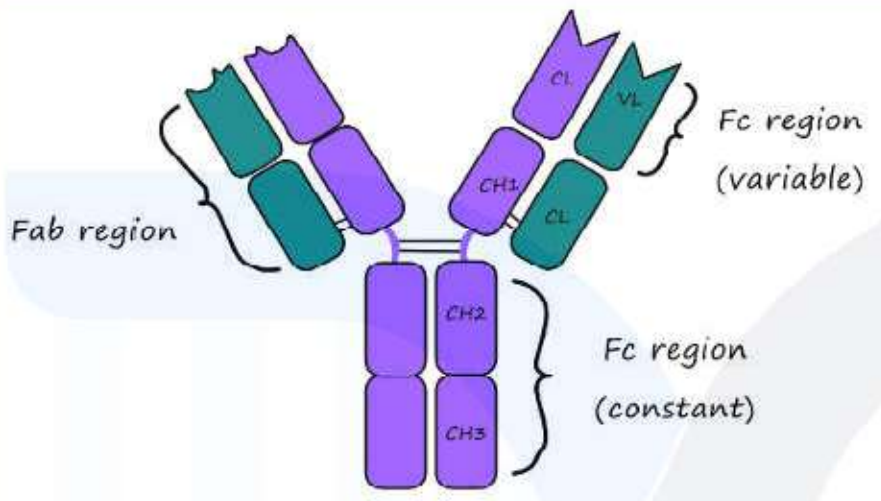

IgG antibody

= Sensitized/opsonized cell

Fig: 3

- Ig G antibody does not lyse the cells because it cannot overcome the zeta potential because of its short arms.

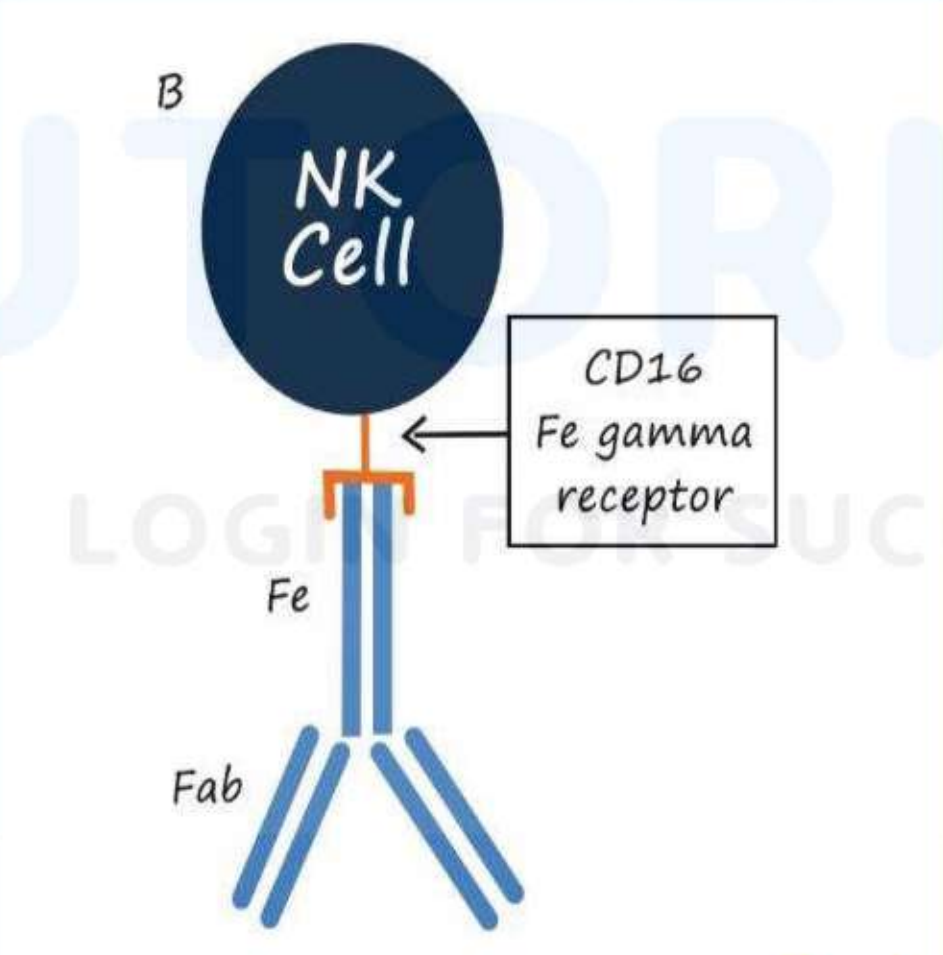

Fig 4

↓

Lysis of cell

↓

Antibody dependent cellular cytotoxicity

Antibody dependent cellular cytotoxicity 00:10:37

- This is Type II Hypersensitivity reactions

  So, markers of NK cell

  a) CD56 – Cell Adhesion molecule marker

  b) CD16 – identifies FC receptor of IgG coating cells

- NK cells can release cytokines and are also stimulated by cytokines

  NK cells can release IFN gamma

  ↓⊕

  Macrophages

  ↓

  Kills intracellular pathogens

- Thus, it's part of innate immunity

AfraTafreeh.com
TUTORIALS
LOGIN FOR SUCCESS

Cytokines stimulating NK cells 00:14:27

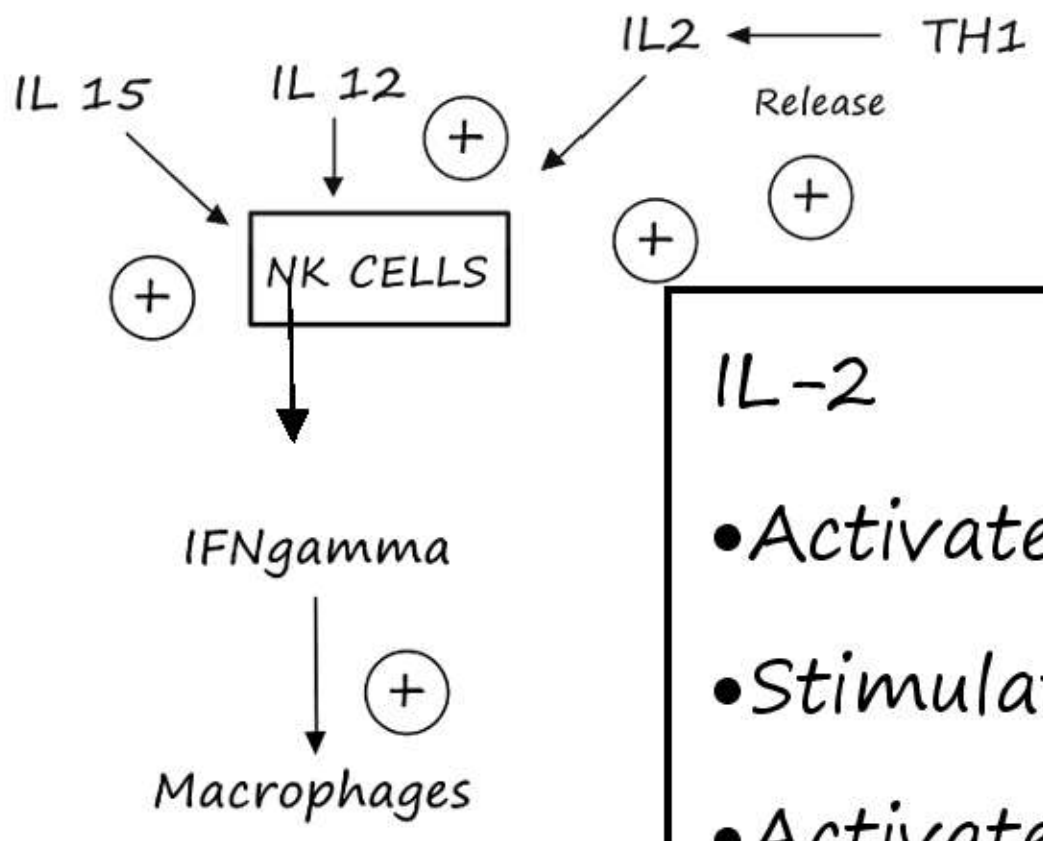

IL-2

- Activates NK cells
- Stimulates TH1 production
- Activates T-regulatory cells

- (CD 25 marker helps to identify IL-2receptors)

  → and in turn regulatory T cells

AfraTafreeh.com

Applied pathology 00:16:54

- IL-2 and IL-15 are absent in **severe combined immune deficiency (SCID)** especially x – linked recessive type.

↓

So NK cells are not produced

Updates 00:19:13

1.Innate lymphoid cells

- Some lymphocytes behave like TH1 cells but do not have T cell receptors

They can produce cytokines similar to TH1, TH2 and TH17

TH1 → IFNγ TH2 → IL 4/5 TH17 → IL 22

- So, it was postulated that NK cell could be a type of innate lymphoid cells, since they do not have T cell receptor but can release IFN gamma.

2.NK-T cell

- T cell which has markers of NK cells

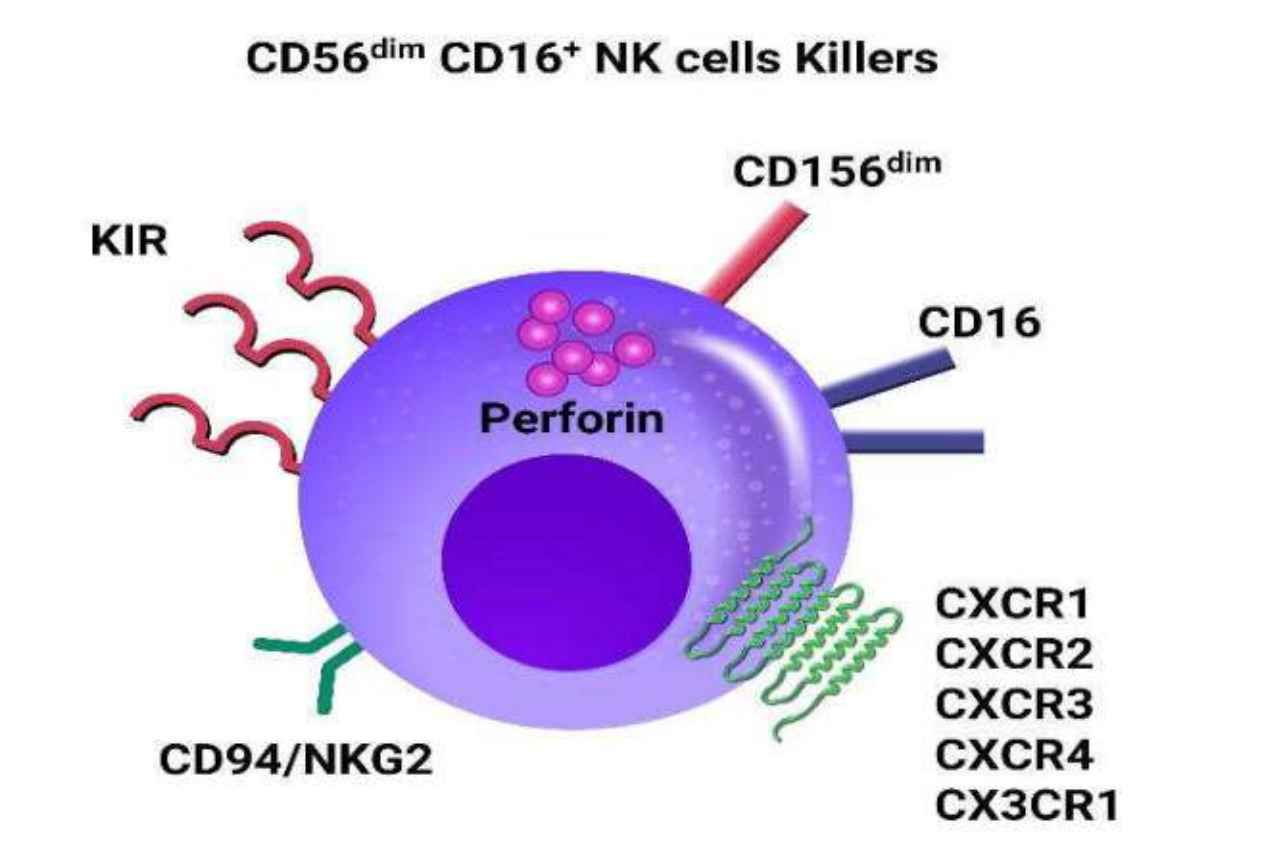

Fig 5

- They can respond to glycolipids presented by MHC like molecules especially **CD 1**
- They are CD1 restricted immune cells

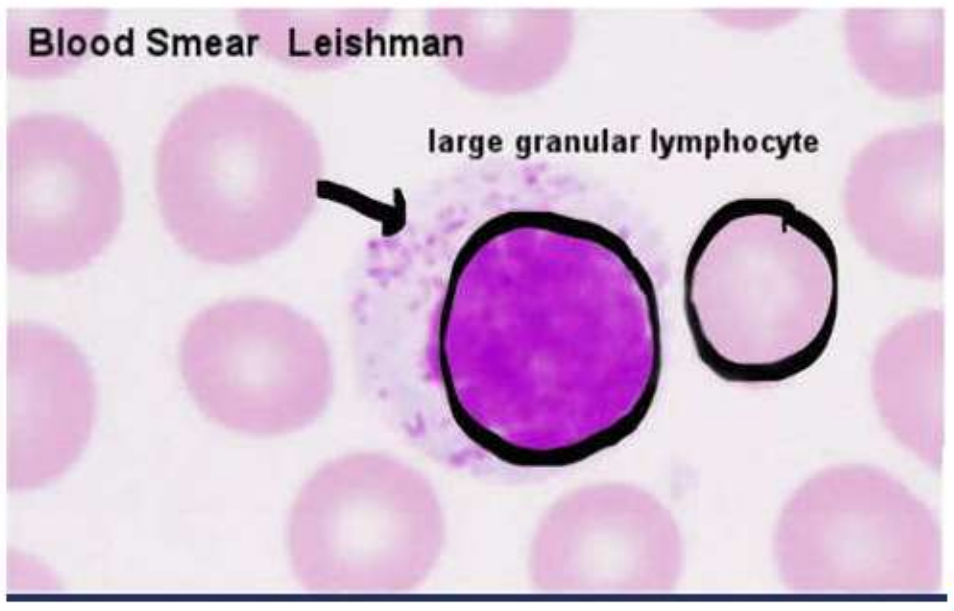

Fig 6

NK/T cell lymphoma 00:24:56

- Misnamed as lethal midline granuloma
- Clinical features: - Septal perforation
- Usually associated with Ebstein Bar Virus Infection.

AfraTafreeh.com
TUTORIALS
LOGIN FOR SUCCESS

AfraTafreeh.com

HYPERSENSITIVITY REACTIONS

Hypersensitivity Reactions 00:00:08

- Exaggerated response to normal stimulus
- Four types

Hypersensitivity type I 00:01:10

Type I hypersensitivity reaction

Early phase
- Ocular immediately

Late phase
- Occurs after 2-24 hrs. of the stimulus

Response to first exposure immediate response

Late phase
- Occurs after 2-24 hrs. of the stimulus

Antigen
↓
APC
↓ MHC II
CD4 T cells
↓
TH2 cells (pivotal role)
↓ Release

i. IL4 = also released by mast cells. Causes IgE formation

B cells $\xrightarrow{IL4}$ IgE

ii. IL5 $\xrightarrow{\oplus}$ Eosinophils

iii. IL13 $\xrightarrow{\oplus}$ Mucus production

IgE so formed tags mast cells

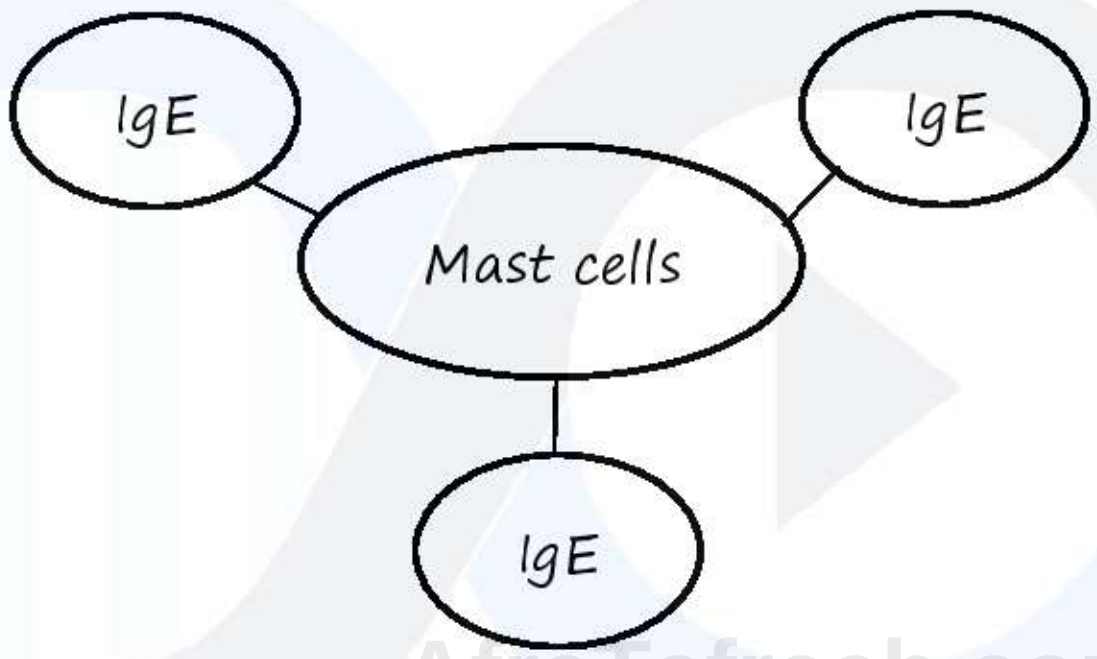

AfraTafreeh.com

Subsequent exposure – delayed response

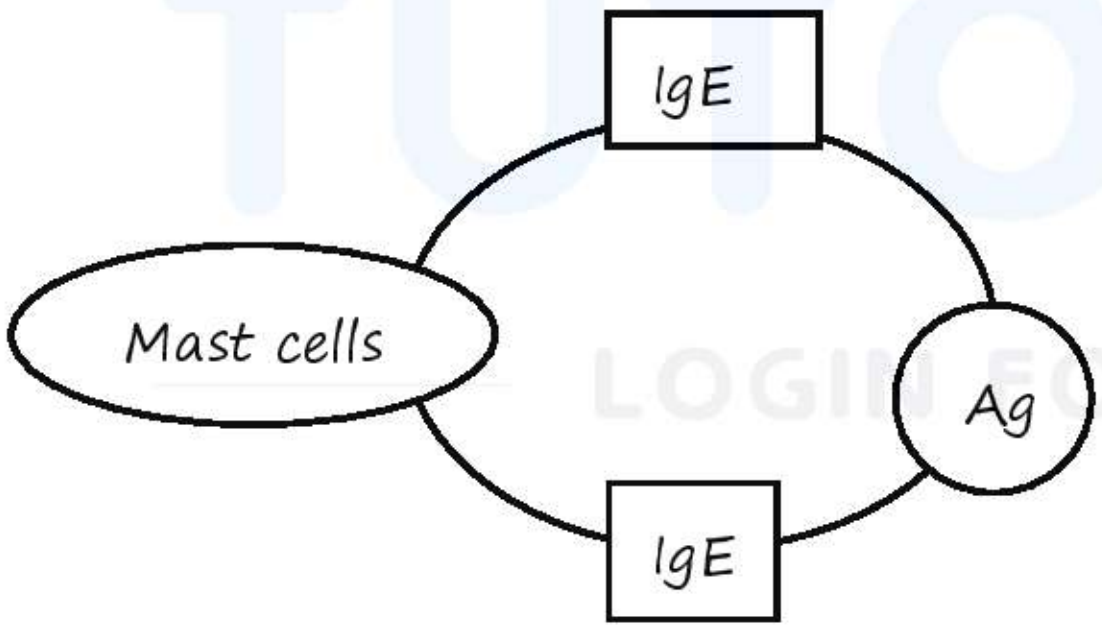

- Antigen causes cross linking of IgE antibody
- Tagged over mast cells

AfraTafreeh.com

Mast cells activated

↓

Degranulation

Pre-formed mediators

i. Histamine (Most imp)

ii. Serotonin

iii. Heparin

iv. Serum tryptase can be used as a biochemical marker for mast cell activation

Indication of Adenoidectomy

- Lipid mediators

i. PGD2 – mast abductors

ii. PAF (Platelet activation increased vascular factor)

iii. LTB4, LTC4, LTD4 – Slow reaching substance of anaphylaxis (SRS-A)

↓

Vasodilatation increase vascular permeability bronchospasm

TUTORIALS
LOGIN FOR SUCCESS

Late Phase – 2-24 hour later

Release of mediators like eotaxin

↓

Eosinophils

↓

Infiltrate into tissues

↓

Damage of tissues

- Late phase is always due to eosinophils

Type I HSR

- Ab – IgE (cytotropic)
- Cells – IgE B-cell, mast cells, Basophils, Eosinophils
- Pivotal role – TH2 cell
- Most important vasoactive amine – Histamine

Examples:

- Urticaria, angioedema, hay fever, eczema
- Anaphylactic shock
- Theobald smith phenomenon
- Penicillin/drug induced anaphylaxis

AfraTafreeh.com

Type IV HSR/Delayed Hypersensitivity Reaction

00:16:22

Type IV HYPER Sensitivity RXN:

Intracellular pathogen -> APC ->TH1 and forms Granulomas

or CD8

Cell mediated HSR

- Delayed type by CD4 TH1
- Induration is its characteristic

- Cell mediated cytotoxicity by CD – 8 T cells
- Perforin, Granzyme

AfraTafreeh.com

- Antigen + Antigen presenting cell along TH1 → IFN_y → Macrophages → Epithelioid cells → Granuloma formation

- So, in type IV HSR
- No antibody
- Initiated by specifically sensitized I lymphocytes
- Eg: Tuberculin test, lepromin test
- Contact dermatitis
- Type I lepra rxn
- Rheumatoid arthritis (type IV> Type III HSR)

DOC TUTORIALS

Type II HSR (Cytotoxic or Catalytic) 00:18:40

LOGIN FOR SUCCESS

Mechanism

- Opsonization
- Induction of Inflammation
- cellular Dysmutation

i. Opsonization:

- Antibody response – IgG or IgM

IgG:

Antigen Cell → IgG Ab → Opsonization

Phagocytosis by Macrophages of spleen

Eg: ITP
AIHA

IgM Ab
↓ ⊕
Complements
C3 b
C5 b → Opsonize → Cytolysis

Eg: IgM AIHA – (Cold AIHA)

ADCC

Ag
↓
IgG
↓
CD16
↓
NK Cell
↓
CD 56

Activation of NK – cell

↓
Release of performed in Granzyme
↓
Killing without phagocytosis
↓
Antibody dependent cellular cytotoxicity (ADCC)

ii. Induction of Inflammation:

- Ab – Ag complex
  ↓
  Macrophages come to lyse
  ↓
  In lysis release of cytokines causing local tissue damage by inflammation

  (Called Frustrated Phagocytosis)

  Eg:

  a. Anti GBM disease

  b. Good pasture syndrome

  c. Pemphigus Vulgaris

AfraTafreeh.com

- Ab – IgE (cytotropic)

Cellular Dysfunction:

- No cell damage
- No Inflammation

↓Anti Ach R Ab — Myasthenia Gravis

Ach R

↓Ab TSH R — Grave's Disease Anti receptor antibody causing stimulation

Thyroid

- Late acting thyroid stimulator
- Antibody stimulate TSH receptor
- Both are examples of cellular dysfunction

So Type II HSR:

- Ab – IgG or IgM
- Lysis or phagocytosis by opsonization – most commonly involves blood cells
- Eg:
  a. Transfusion reactions
  b. Erythroblastosis fetalis

TUTORIALS LOGIN FOR SUCCESS

Type III HYPER Sensitivity Reaction: 00:28:14

Immune Complex HSR

- Local immune complex disease
  ↓
  Arthus reaction
- Systemic immune complex disease
  ↓
  Serum sickness

- Ag+Ab+Complement = Immune complex (IC)

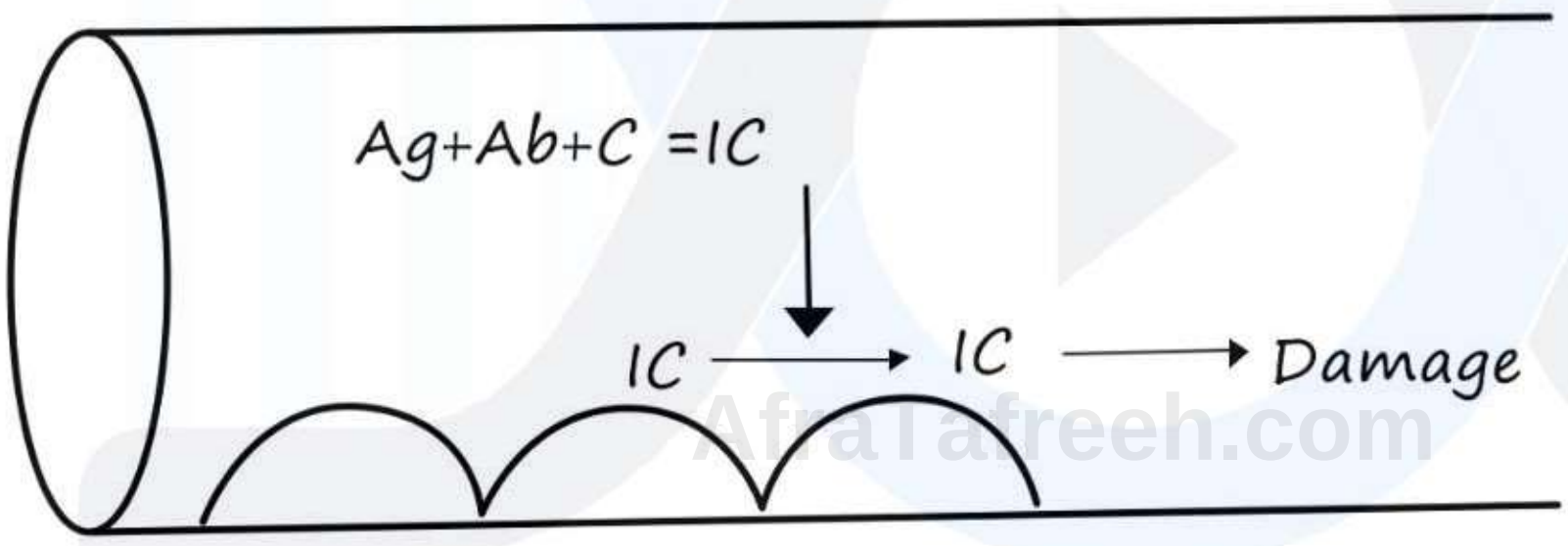

AfraTafreeh.com
TUTORIALS
LOGIN FOR SUCCESS

- Sequence – immune complex formation
  ↓
  Deposit
  ↓
  Damage
- E.g.:
  i. Vasculitis
  ii. SLE
  iii. Glomerulonephritis
  iv. Type 2 lepra reaction

AfraTafreeh.com

AMYLOIDOSIS

Amyloidosis: 00:00:05

- Clinical disorder caused by accumulation of pathogenic amyloids – most of which are aggregates of misfolded proteins is a variety of tissues
- Associated with chromosome 21
- Amyloid is so named because the extracellular protein which accumulates has characteristics like amylase

Characteristic property

Physical

1) On electron microscopy
   - Length is indefinite
   - Non-branching fibril
   - Diameter – 7.5 to 10nm
2) **β pleated sheets** – Best seen by X ray diffraction

Chemical

Amyloid made of 2 basic proteins

- 95% fibrillary proteins
- Other Glycoproteins 5%
  - Serum amyloid P component (SAP) [major glycoprotein it stabilizer amyloid]

β pleated sheets

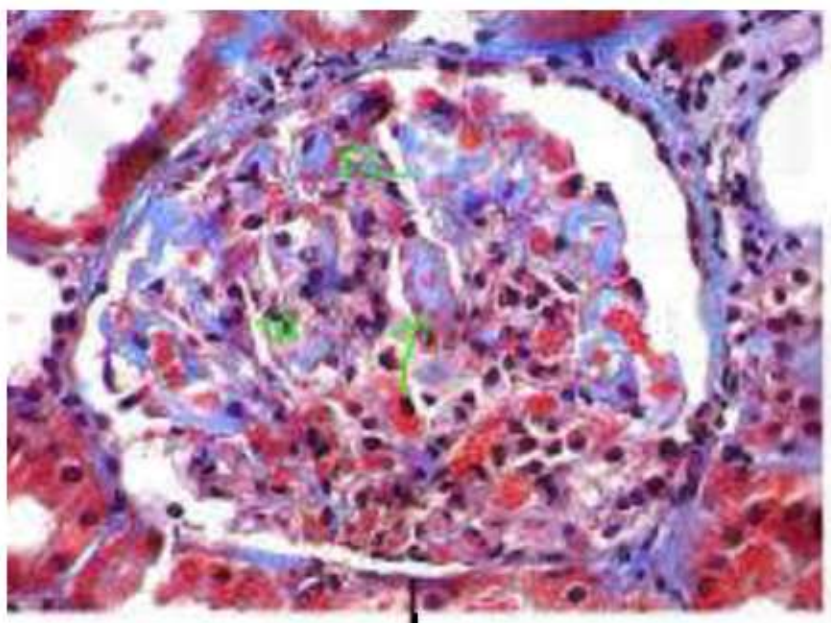

Pink amorphous extra cellular accumulation

↓

Causes pressure atrophy of cells

Fig: 1

- Fibrillary proteins have very high affinity for the 5% non-fibrillary proteins
- The 'P component' help in diagnosis of amyloidosis

AfraTafreeh.com

Types of Amyloidosis 00:03:05

Types of amyloidosis

primary AL Amyloidosis

- Seen in patients of monoclonal gammopathy example: Multiple myeloma, NHL
- Most common type of amyloidosis
- Excessive formation of immunoglobulin's
- Deposition of light chains in tissues as amyloid [(lambda) >>> K (Kappa)]
- Knowns as Al (Light chain) Amyloidosis
- Usually at age > 40 year
- Kidneys – most commonly involved
- Macroglossia – Pathognomic
- Functional hyposplenism (in absence of significant splenomegaly)

secondary AA Amyloidosis (IL1, IL6)

most commonly associated with chronic inflammatory conditions – Deposited as AA amyloid

a) Bronchiectasis
b) Osteomyelitis
c) Ankylosing spondylitis
d) Tuberculosis
e) Rheumatoid arthritis
f) Inflammatory bowel disease

(Mnemonic – BOATRI)

-RA – most common cause

Remember –
Bronchiectasis – not a premalignant condition. It is associated with 2°

TUTORIALS
LOGIN FOR SUCCESS

-only type of amyloidosis which occurs in children

chronic inflammation

IL_1

IL_6

↓ IL_6 Receptor

Liver

↓

•Release of acute phase reactants, most important being serum amyloid associated protein (SAAP)

↓

•Deposits in tissues as AA Amyloid

AfraTafreeh.com

Other types of Amyloidosis 00:07:38

Other Types Of Amyloidosis	
Aβ Amyloidosis	Aβ 2 Amyloidosis
•Aβ deposition seen in brain Aβ / Aβ Aβ / Aβ — diffuse plaque ↓ seen in Down's syndrome Alzheimer	• Deposition of β_2 Macroglobulin in joints/synovium/Tendons • Seen in patients on **long term hemodialysis** β2 micro globulin cannot pass through hemodialysis filter

TUTORIALS LOGIN FOR SUCCESS

AfraTafreeh.com

Neuritis plaque ↓ seen in Alzheimer — Neuritis	↓ • Starts accumulating extracellularly ↓ • Deposits as amyloid typical presentation – carpal tunnel syndrome

- ATTR – Transthyretin accumulation
- Transthyretin – Negative acute phase reactant
- Transport molecule of chlorine and retinol

Types of amyloidosis

Excessive formation of Normal TTR	increased levels of mutated TTR
↓	↓
Accumulation in heart	deposition around neurons
↓	↓
Senile amyloidosis	familial Amyloid neuropathy

Hereditary amyloid syndromes

familial amyloid neuropathy
↓
mutated ATTR deposition
↓
Senile amyloidosis

familial Mediterranean fever
↓
activates gene 'Pyrin' → IL1 → Pyrexia
↓
activates inflammasome
excess acute phase reactants
↓
SAAP
↓
AA amyloid

AfraTafreeh.com

Endocrine –

1) ACal (calcitonin) seen in **medullary carcinoma of thyroid** amyloid stroma by altered calcitonin
2) AIAPP – Islet amyloid polypeptide

- Seen in type II DM
- Amyloidosis is a discriminatory feature between Type 1 and Type 2
  Type 1 – Not seen
  Type 2 – Amyloidosis seen

AfraTafreeh.com

Organs involved in amyloidosis

1) Most common and most serious – kidney
   - Most common presentation is massive proteinuria > HIN
2) Heart – second most common organ involved
   - ECG – Pseudo infarct pattern
   - MRI with gadolinium – Sub endocardial enhancement
   - Restrictive cardiomyopathy is seen in senile
   - amyloidosis

Misfolding of protein disorder

- amyloidosis
- Alzheimer's
- Parkinson
- Huntington chorea
- Cystic fibrosis

TUTORIALS LOGIN FOR SUCCESS

Diagnosis of amyloidosis 00:19:28

I. FNAC

II. Biopsy

III. Extent of amyloidosis -Scintigraphy

IV. Gross

I. FNAC

i. Best site – Abdominal fat pad aspirate (80% sensitivity) >> Rectum (60% sensitivity)

ii. Because fat pad capillaries are first affected by deposition of amyloid around them

iii. Also the ease of aspiration

On Congo Red Staining

Under Light Microscopy	Under Polarized Microscopy
↓	↓
Salmon Red Appearance	Apple Green Birefringence

AfraTafreeh.com

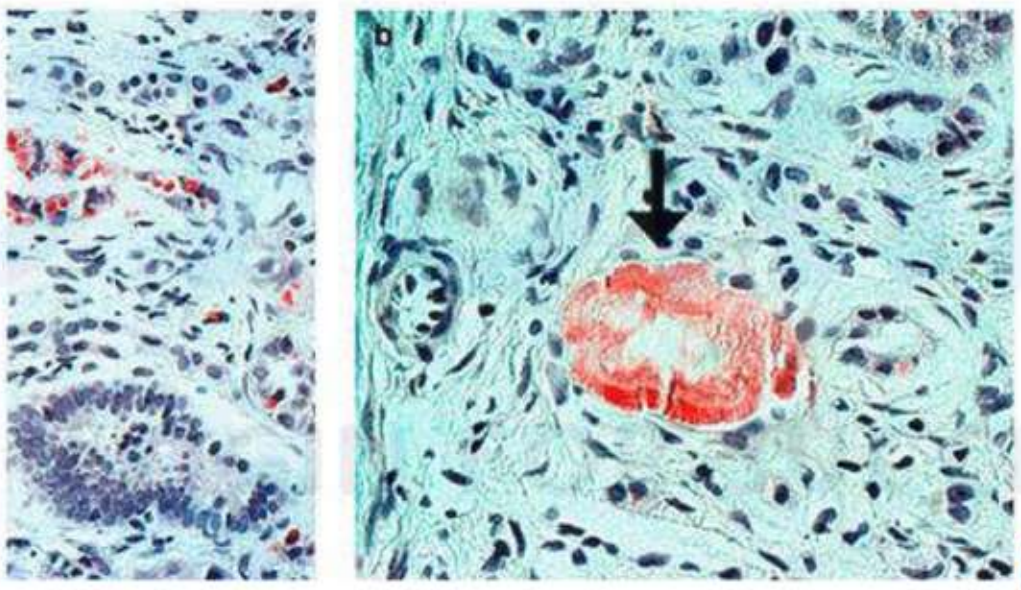

Fig: 2

- Amyloid fibrin
- Fibrin
- Collagen, Hyaline
- This LM is not diagnostic
  - Congo red – most widely used stain for amyloidosis other stains

AfraTafreeh.com

1) Methyl violet (Metachromatic stain) – used for rapid staining
2) Thioflavin under UV light → yellows color birefringence
3) 5% proteins in amyloid can be glycosaminoglycan (GAG)

- Identified by Alcian Blue

4) Toluidine blue
5) Crystal violet

Remember: If silver methamine is used – Silver gets oxidized and forms black precipitate – masking amyloid

II. Biopsy

- Definitive diagnostic test
- Shows 3D orientation of amyloid

TUTORIALS
LOGIN FOR SUCCESS

Biopsy

- H and E stain (L/M) → Extracellular pink
- Congo red Polarizing microscopy → Apple Green Birefringence
- Electron microscopy → Infinite long non-Branching fiber with fixed diameter of 7.5 – 10nm

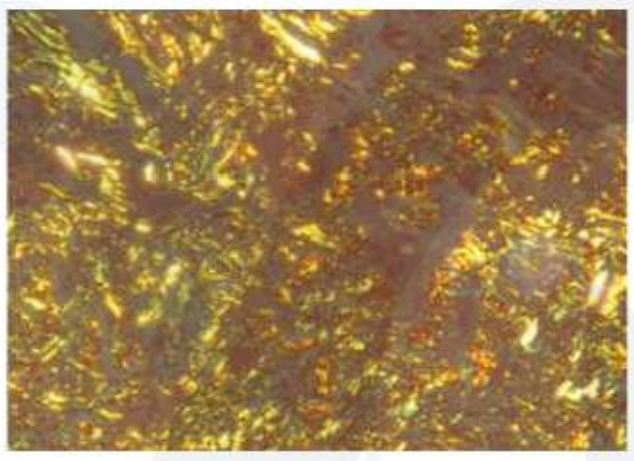



Basis of congo red staining is β pleated sheets

II. Extent of amyloidosis

- Detected by scintigraphy
- Uses radiolabeled 'SAP' – Serum Amyloid P component
- Highlight the area of amyloid definition

III. Gross

- All organs with amyloid are increased in size **except kidney which decreases** became amyloid deposition

AfraTafreeh.com
TUTORIALS
LOGIN FOR SUCCESS

AfraTafreeh.com

in kidney first starts in mesangium as the deposition increases. It compress vessels causing ischemia and later atrophy of kidney

- Cut section of organ shows waxy appearance

↓

On addition of iodine

↓

Shows mahogany brown discoloration

↓

On further addition of sulphuric acid H_2SO_4

↓

Changes to blue color

This reaction is similar to amylase, hence named amyloid

Amyloid deposition in other organs 00:33:58

i. Liver-starts in space of Disse

ii. Kidney – First start in mesangium → enlarged to form modules

TUTORIALS LOGIN FOR SUCCESS

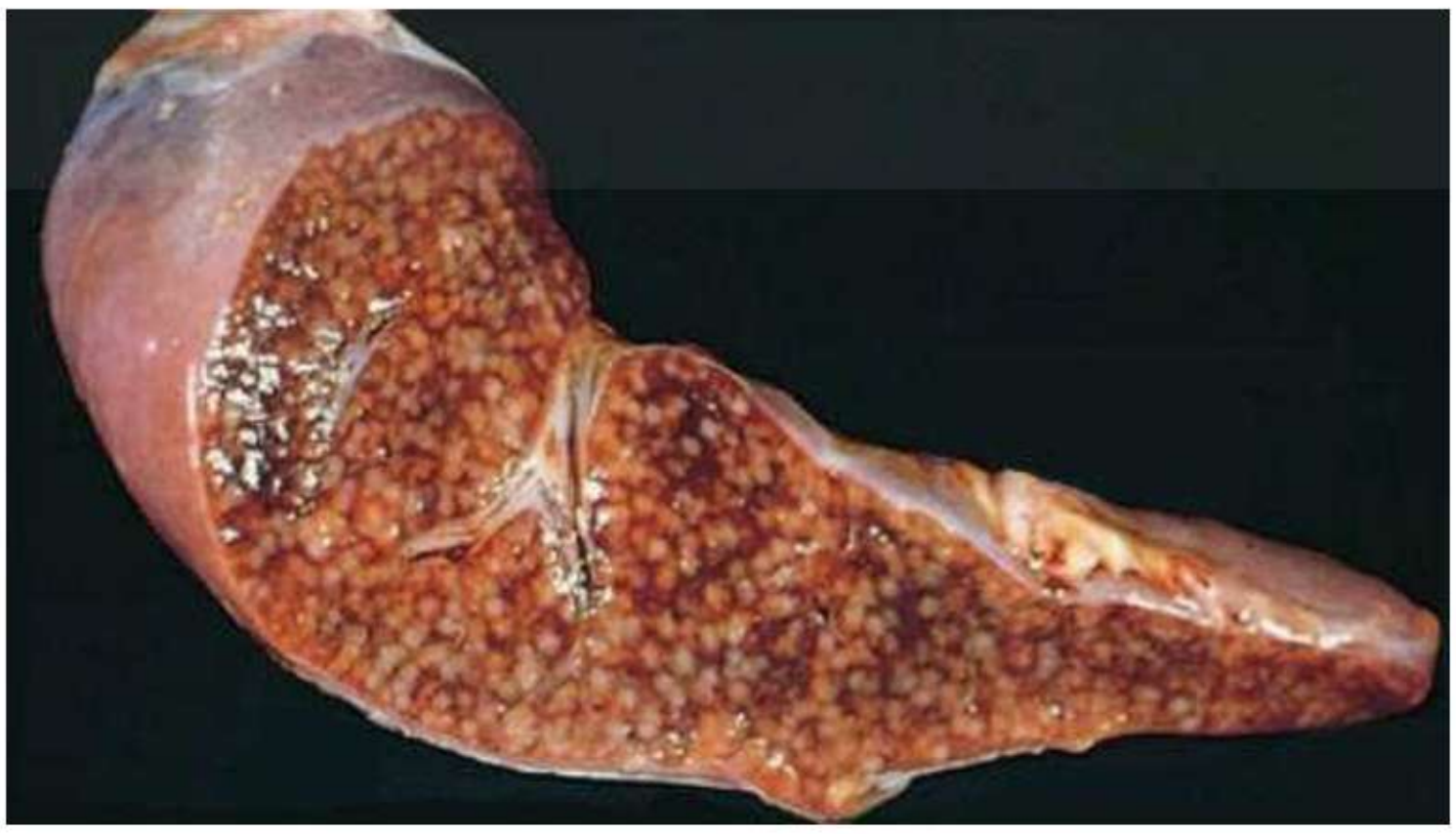

Fig: 3

iii. Spleen

Spleen

Deposition in follicles (White pulp)

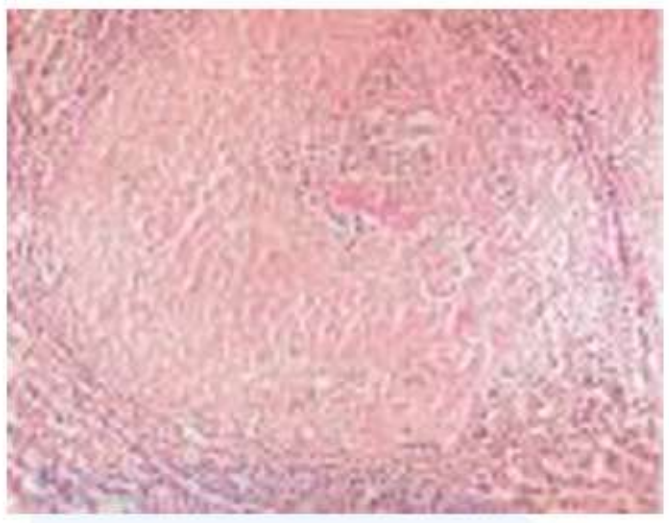

↓

Sago like appearance

↓

Sago spleen

a) Moderate to marked enlargement

b) Cut section – Translucent waxy nodules resembling sago grain

c) Micro: involves peri-arteriolar lymphoid sheath (White pulp) and hence they form discrete deposits

deposition in sinuses (Red pulp)

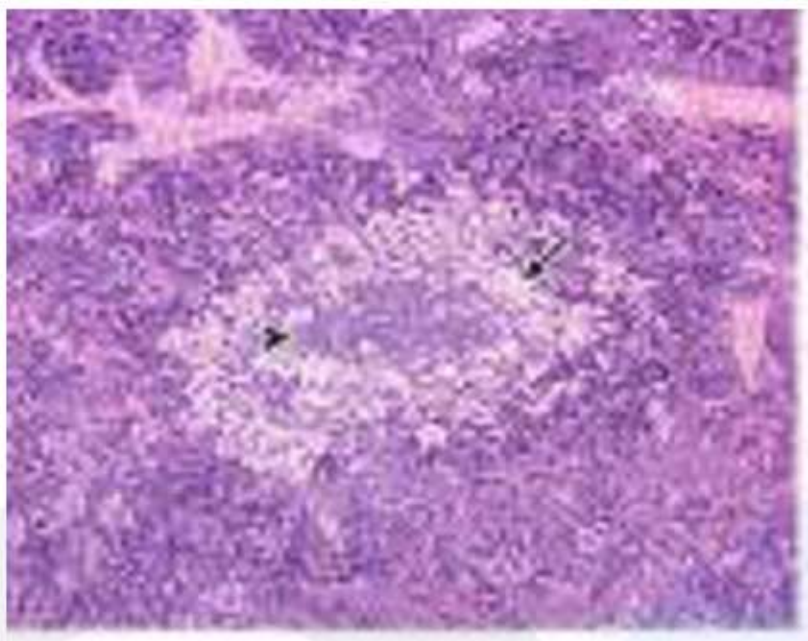

lardaceous spleen

a) Moderate to marked enlargement

b) Cut section – map like areas resembling lard

c) micro: Deposit start in the walls of splenic sinuses, which progresses till they form large diffuse masses

IfraTanveen.com TUTORIALS LOGIN FOR SUCCESS

iv. Heart – Sub endocardium is involved first

Remember

AfraTafreeh.com

- Senile amyloidosis – (N) ATTR deposition
- Atrial amyloidosis – Executive atrial natriuretic factor (ANE) deposition

v. Skin – Pinch purpura – Amyloid deposition around vessels in skin

vi. Hematological manifestation

- Involves coagulation factor X manifestation → bleeding.

TUTORIALS
LOGIN FOR SUCCESS

GRAFT REJECTION

Types of Graft 00:01:21

i. **Auto graft**: Transplanted from one site to another on the same patient

ii. **Isograft:** Transplant from genetically identical donor, such as an **identical twin**

iii. **Allograft**: Transplant from individual of same species

iv. **xenograft**: from another species

Example: - Heart valves from porcine tissue

In the subsequent discussions, kidney is taken as a prototype of graft rejection

AfraTafreeh.com

Hyper acute rejection 00:05:19

- Immediate (within minutes to hours) graft destruction due to ABO or pre-formed anti-HLA antibodies
- Usually when donors are people who get repeated blood transfusions or multiparous females
- Kidney transplants are particularly valuable to hyper acute graft rejection
- Donor kidney when transplanted should
  i. Turn pink
  ii. Gain its turgor
  iii. Pass few drops of urine
- In hyper acute rejection
  i. Kidney turns cyanotic/Blue
  ii. Becomes flaccid
  iii. Passes few drops of bloody urine

AfraTafreeh.com

Histopathology

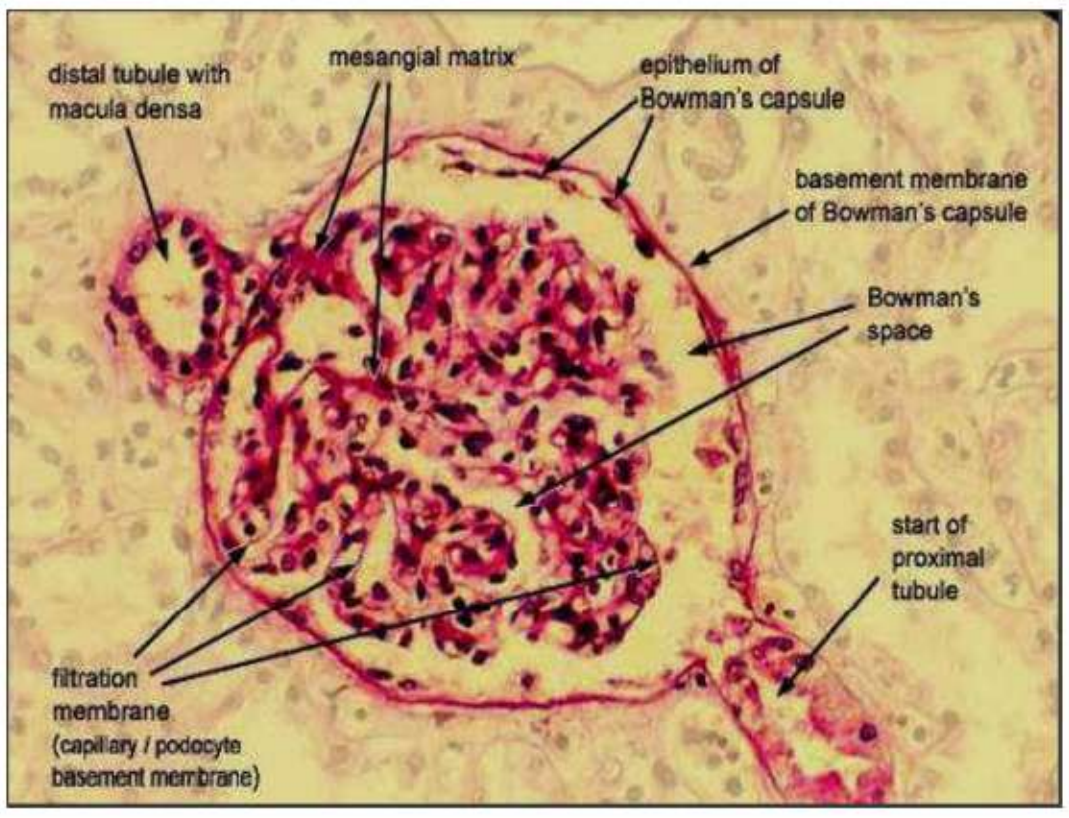

Fig: 1

Immune complex damages endothelium of blood vessels

↓

Activation of coagulation pathway

↓

Hemostatic plugs lines blood vessels

↓

Fibrinoid necrosis

Histopathological change 00:15:03

i. Neutrophilic infiltration

ii. Intravascular thrombosis

iii. Fibrinoid necrosis of blood vessels

iv. Coagulative necrosis in glomerulus

Heart and liver transplants are relatively resistant to hyper-acute rejection

Natural IgM antibody

- Patients with 'A' blood group have anti-B anti bodies so, if 'A' blood group individual receives transplant from blood group B individual

↓

- The anti-B antibodies cause graft destruction this is hyper acute rejection, a **type II hyper sensitivity reaction**
- Rule of transplantation – Always do **ABO matching blood group of** donor and recipient should always be the same

Acute graft rejection 00:21:00

AfraTafreeh.com

- Occurs during the first 6 months
- Most commonly presents between 5-30 days after transplantation
- Usually, reversible

They are two types of acute rejection

Acute Humored Rejection	Acute Cellular Rejection
• More common type • Than cellular • Type II HSR	•Type IV HSR
Mechanism	**Mechanism**
antibody damage endothelium ↓ type II HSR ↓	CD4+CD8 T cells damage endothelium ↓ type IV HSR ↓ donor's APC present antigens to both and CCD4

AfraTafreeh.com

MHC I and MHC II of donor tissue act as antigen against which antibodies are formed in the recipient

Acute Humoral Rejection

↓

Ag-Ab complex

↓

activates complement pathway (Classical complement pathway)

- C1, C2, C3, C4
- C4d is especially important

↓

deposits around blood vessels in peritubular capillaries and glomerular vessels

↓

inflammation of vessels

↓

rejection vasculitis to demonstrate vasculitis

↓

anti C4d antibody tagged with DAB (Brown color)

C4D
- DAB
- Brown color of vessels due to C4d depository

CD8 is more involved in cellular graft rejection endothelitis

Acute Cellular Rejection

- Infiltration (CD8>>CD4)
- **Tubulitis** is labelled as and type I rejection
- **Endothelitis** as type II
- Endothelitis responds to therapy
- **Interstitial mononuclear** cells seen

Chronic Graft rejection 00:38:58

- occurs after the first 6 months
- Most common cause of graft failure
- Non-immune factors may contribute to pathogenies
- Characterized by myo-intimal proliferation if graft arteries loading to ischemia and fibrosis

- Type IV HSR
- Eventually occurs in all kidney transplants presenting with raised creatinine levels
- Recipient APC present the transplanted tissue as antigen to

CD 4 cells

↓

TH1 ←

↓

IFNY, IL2

IFNY

↓

Macrophages → Epithelioid cells → Granuloma fibrosis

AfraTafreeh.com

Morphological changes in kidney

- Duplication of glomerular BM
- Atrophy of tubules
- Interstitial fibrosis
- Sclerosis of blood vessels

} Chronic transplant Glomerulopathy

> Conditions showing duplication of glomeruli
>
> i. MPGN
>
> ii. SLE
>
> iii. Chronic transplant glomerulopathy

AfraTafreeh.com

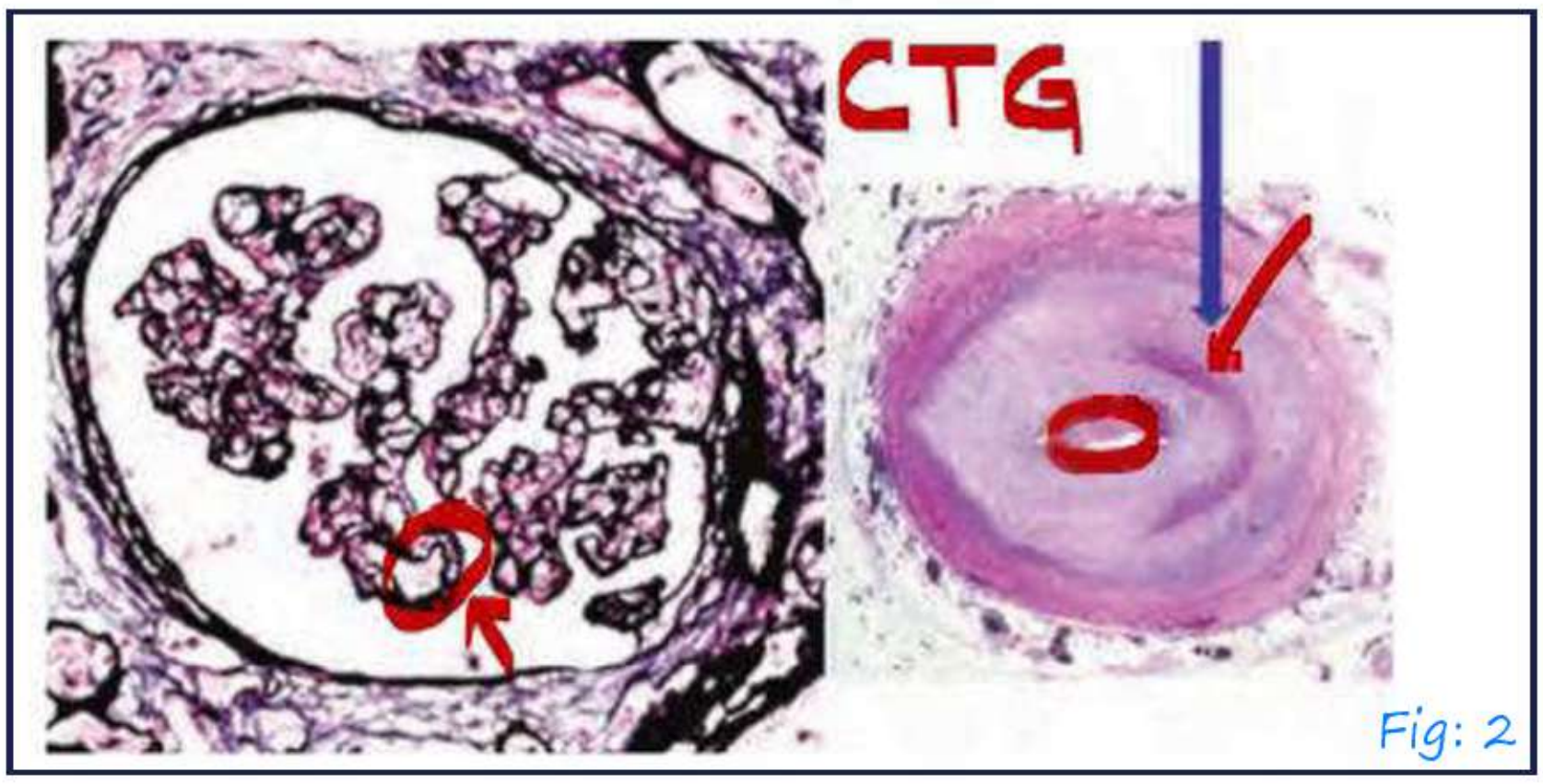

Fig: 2

Pathways in transplant rejection

Direct Pathway	Indirect Pathway
Donor APCs - acute cellular rejection	Recipient APCs - Chronic rejection

Manifestations of classic graft rejection

i. Kidney → Glomerulus sclerosis and tubular atrophy

ii. Pancreas → Acinar loss and islet cell destruction

iii. Heart → Accelerated coronary artery disease

iv. Liver → vanishing bile duct syndrome

v. Lungs → Obliterative bronchioles.

PREVENTING GRAFT REJECTION AND GVHD, GVL

Methods to prevent graft rejection 00:00:30

I. **ABO typing and MHC typing** ABO typing is more important than MHC typing

- **MHC typing** – At least 10 MHC should be matched reporting of MHC typing
- Binary system example: 000 mismatch reporting if A, Band DR are matched
- **10/10 match**
- 100

II. Immunosuppressants

↓

Suppress self – T cells

↓

Drawback: Donor T cell in the graft can cause disease in host referred to as **Graft Versus Host Disease (GVHD)**

AfraTafreeh.com
TUTORIALS
LOGIN FOR SUCCESS

GVHD

If occurs < 100 days of transplantation	If occurs > 100 days of transplantation
↓	↓
Acute GVHD	Chronic GVHD
↓	↓
Clinical manifestation	Clinical manifestation

AfraTafreeh.com

<u>Donor T cells attack</u>

1) Skin causing rash
2) GIT causing diarrhoea
3) Liver causing jaundice

Skin → sclerosis

All organs are involved and presentation is similar to **systemic sclerosis**

- GVHD primarily occurs in **Bone marrow transplantation** Donor T cells cannot be suppressed because:
  1) Engraftment will not occur if bone T cell are suppressed
  2) **<u>Graft Versus Leukemia (GVL)</u>** – Beneficial manifestation employed as immunotherapy for management of intractable cancers.
- Example – BM transplantation in-patient of leukemia <u>Donor T cells</u> attack the leukemic blasts in recipient's bone marrow

TUTORIALS
LOGIN FOR SUCCESS

New bone marro → T CELLS (−) → Leukemia BM

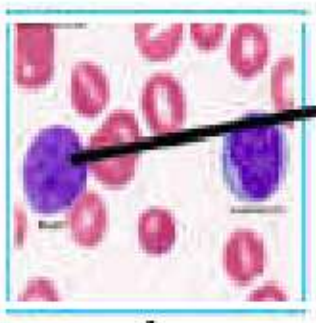

Donor T cell kill the Blast cells

↓

Curing the leukemia

↓

Referred to as graft versus leukemia

Other methods to prevent graft rejection

1. **Plasmapheresis** – Removal of immunoglobulins

   Newer methods

AfraTafreeh.com

2. Mixed chimerism – Refers to continued mixing of donor and recipient hematopoietic cells into recipient tissues. Induces a chimeric state of mixed donor and recipient's immune cells. At least 1% circulating cells are of donor origin repeated exposure to donor immune cells reduces risk of rejection
3. Injecting T regulatory cells into the recipient

   ↓

   Suppress immunity
4. Blocking co-stimulatory molecule

Signal 2 → T cell activation | No signal 2 → No T cell activation

AfraTafreeh.com

TOLERANCE AND ITS DISEASES

Levels of Tolerance 00:00:30

Tolerance

- Central Tolerance
- Peripheral Tolerance

Central Tolerance: 2 Mechanisms

Central deletion (Negative selection)	Central editing (Receptor editing)
↓	↓
For t cells	For b cells
↓	↓
Example: thymus has **AIRE gene** (autoimmune regulator gene)	Bone marrow: B cell-R (Receptor for self-antigen)
↓	↓
Traps self-antigen I.e. identifies autoreactive cells	B cell-R + self Ag
	↓
	Auto – antibody
↓	↓
Kills them by apoptosis	This is prevented by receptor editing
↓	
Normal t cells are released into circulation	B-R converted to B-NR (non-responsive receptor)

Peripheral tolerance 00:03:33

There are 3 types of mechanisms

3 mechanisms

Regulatory T cells anergy Apoptosis

I. Regulatory T cells

- Subset of CD4T cells → FOX P3 and CD 25
  ↓
  Suppress immunity

II. Anergy – No second SIGNAL

- If there is No second signal, there would be no activation of T cell → suppressing immunity due to inactivation of B8

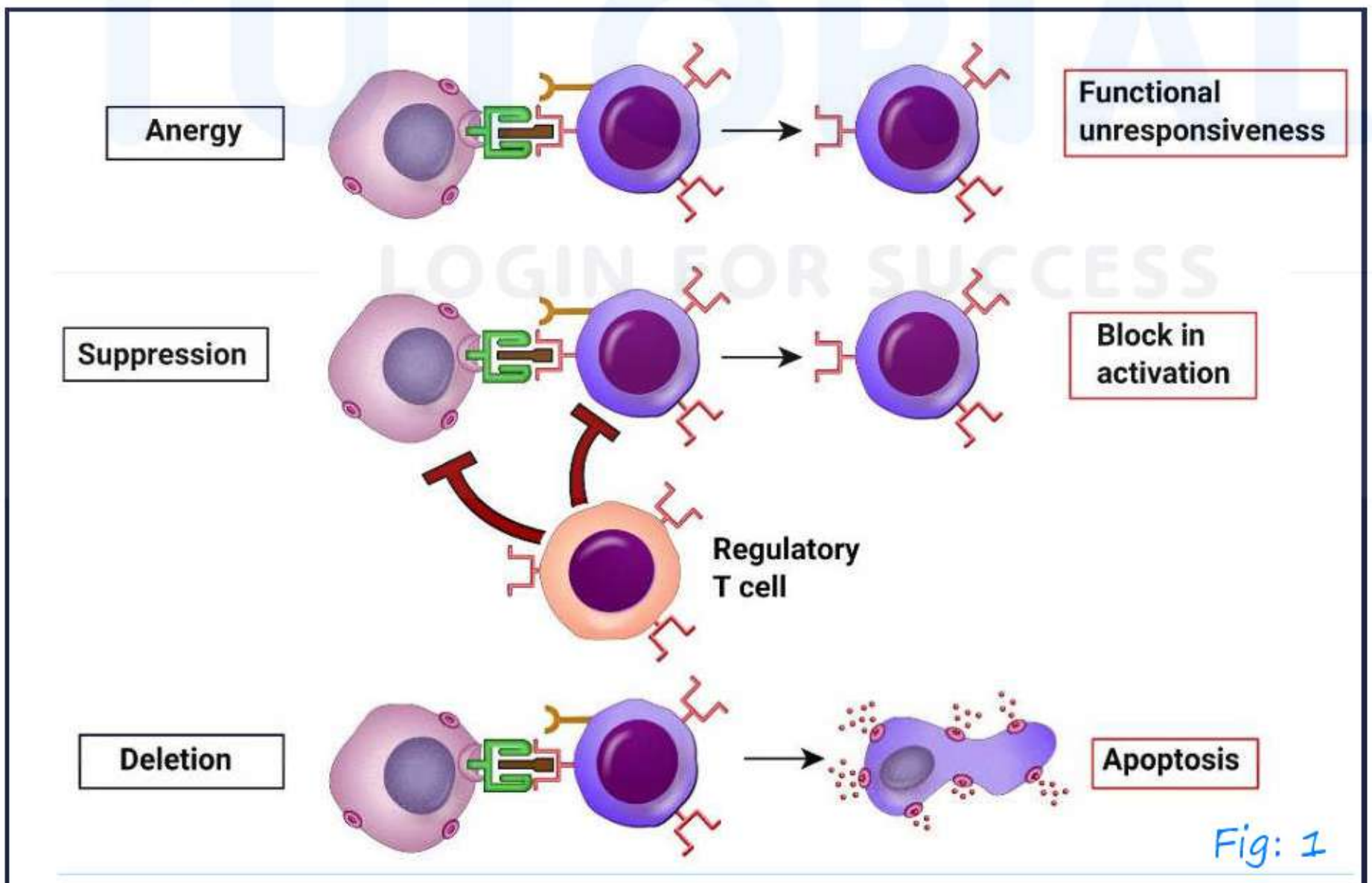

Fig: 1

III. Apoptosis

- CD 8 cells have FAS-L

AfraTafreeh.com

- Cells expressing FAS are killed by CD 8 cells by FAS-FASL pathway

Immune Privileged sites

1. EYES
2. Testes
3. CNS

Diseases of Tolerance 00:08:49

Diseases of tolerance

Diseases of central tolerance

↓

Absence of AIRE gene

↓

Self-reacting t cells release into circulation

↓

Multiple organs defected

↓

Causing autoimmune poly-endocrinopathy

Diseases of peripheral tolerance

Few examples: -

- Diabetes mellitus type 1
- Addison's diseases

Autoimmune polyendocrinopathy

Type-I	Type-II
Due to mutation of AIRE	Polygenic inheritance

Diseases of peripheral tolerance

- Regulatory T cells
- Anergy
- Apoptosis

I. Regulatory T cells

1) FOX P3 deficiency

Result in

IPEX syndrome
I – Immune Dysregulation
P – Polyendocrinopathy
E – Enteropathy
X – X Linked Disease

TUTORIALS
LOGIN FOR SUCCESS

2) CD -25 also known as IL2 Receptor

↓ Mutation

- Inflammatory bowel disease
- Mutations in IBD
  1) NOD 2 mutation
  2) ATG 16 (Autophagy related genes)
  3) CD 25 mutation

AfraTafreeh.com

II. Anergy

Genes silencing T cells

- CTLA4
- PD Receptor (Programmed death receptor) on T cells

III. Apoptosis

- No expression of FAS causes ALPS – Autoimmune Lymphoproliferative syndrome

TUTORIALS
LOGIN FOR SUCCESS

MORPHOLOGICAL FEATURES OF INFLAMMATION

Morphological Features Of Acute Inflammation

00:00:21

- Acute
  - Catarshal
  - Serous
  - Purulent
- Chronic
- Granulomatous

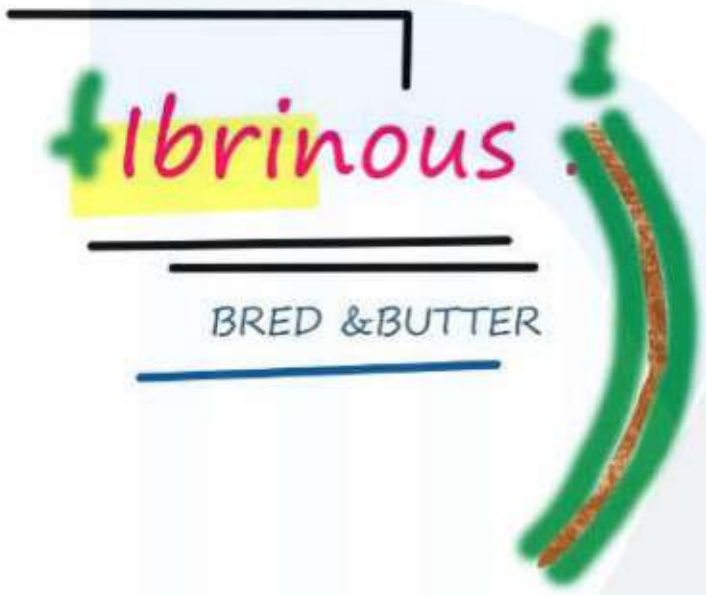

Morphologic patterns of acute inflammation

Catarrhal inflammation

- Commonest type of inflammation
- Increased mucus secretion
- Seen in common cold

Serous inflammation

- Exudation of cell poor fluid
- E.g. effusion in cavitites

Fibrinous inflammation

- Deposition of fibrin in extracellular space.
- Due to large vascular leaks/local procoagulant stimuli (Cancer).

Purulent (suppurative) inflammation, abscess.

- Purulent exudates are characterized by pus made of neutrophilis, liquefield debris of necrotic cells, and edema fluid.
- Most common cause – bacteria that cause liquefactive necrosis.

AfraTafreeh.com

I. Acute inflammation

It is of 4 types:

1. Catarrhal inflammation 00:02:24

- It is seen in inflammation of mucous membrane
- Most common type of acute inflammation

Example Common cold

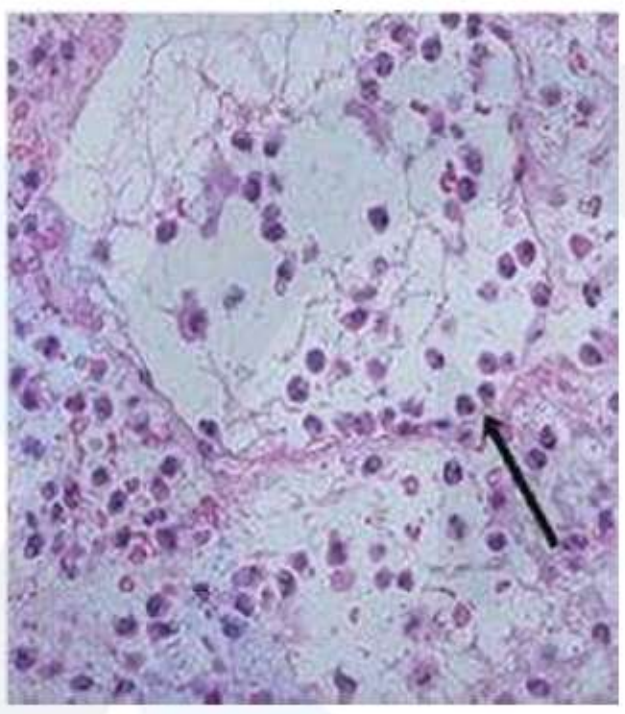

Fig: 1

2. Serous inflammation 00:02:32

- Cell poor fluid
- It is seen in effusions

Example: Ascites, pleural effusion, Bullae

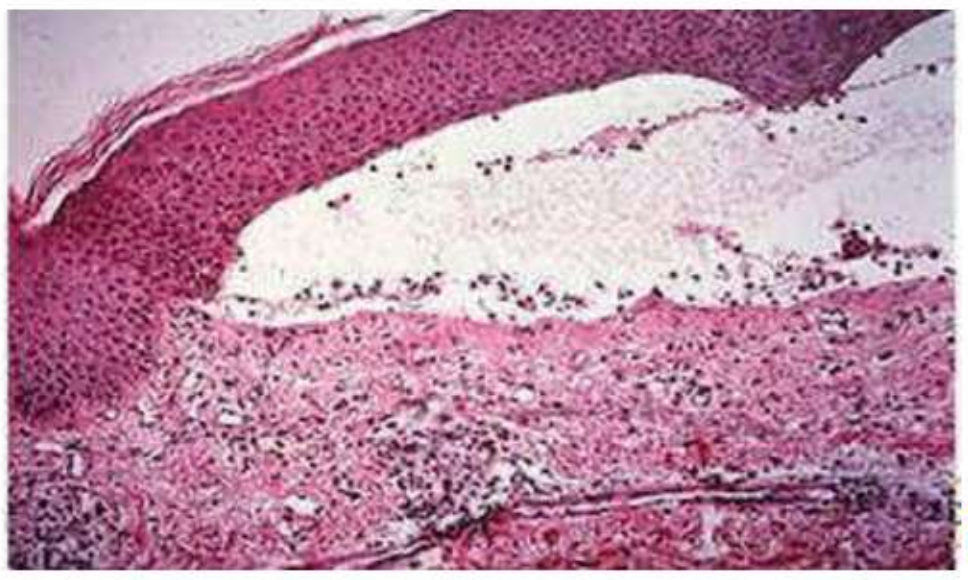

Fig: 2

3. Purulent inflammation 00:03:10

- Pus is defined as collection of neutrophils
- Localized collection of purulent inflammation is called abscess
- Most common cause of purulent inflammation is bacteria

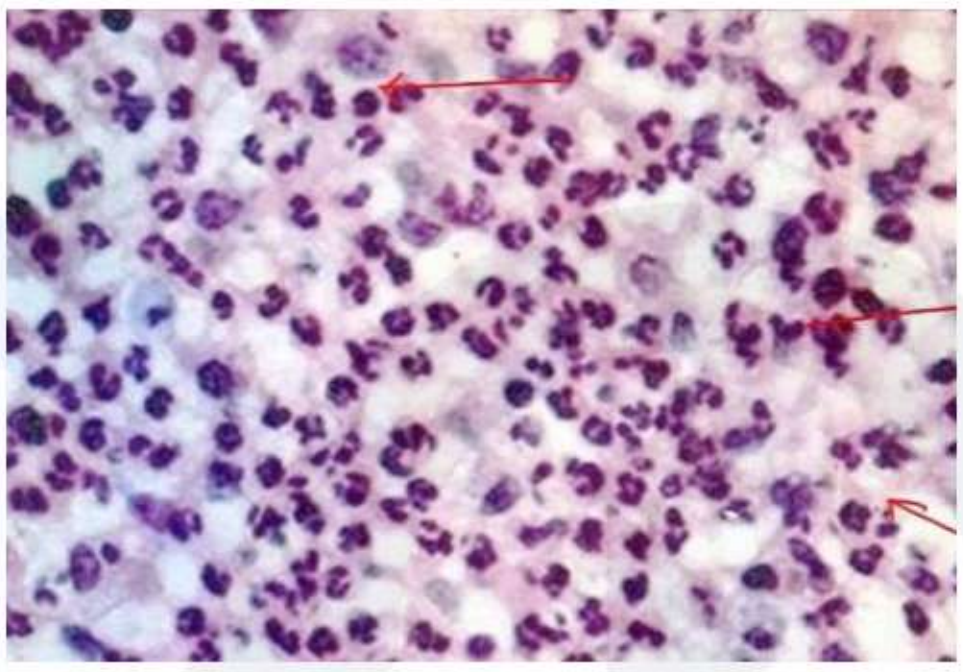

Fig: 3

4. Fibrinous inflammation 00:03:50

AnaTafreeh.com

- Deposition of fibrin in extra cellular space is due to large vascular leaks which cause procoagulant stimuli
- Fibrin is white in colour
- In acute rheumatic fever, fibrin deposited in pericardial cavity gives a typical bread and butter appearance

TUTORIALS LOGIN FOR SUCCESS

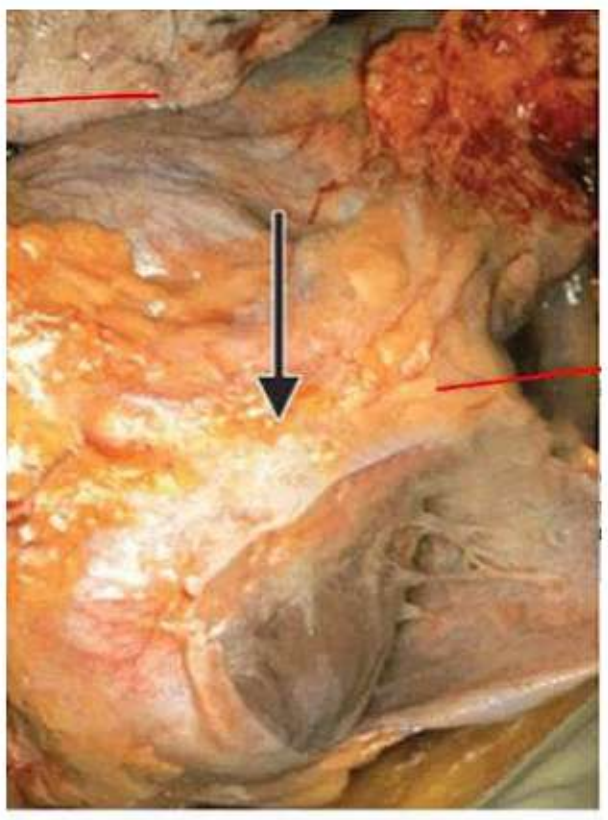

Fig: 4

AfraTafreeh.com

CELLULAR MEDIATORS (IBQ MAST CELL)

Two types of mediators 00:00:30

I. Cellular

II. Plasma

I. Cellular mediators further classified

a) Preformed cellular mediators

b) Newly formed cellular mediators

a) Preformed cellular mediators

1 histamine	2 serotonin
i. Derived from histidine source ii. Mast cells (present around blood vessels) are richest source of histamine iii. Other sources – Basophils, platelets mast cells iv. Stimuli activating mast cell are: **a) Allergic stimuli** i. Allergic stimuli cause the cross linking of IgE molecules which	i. Derived from tryptophan source → platelets ii. Serotonin is synthesized in enterochromaffin cells in blood and taken up and by platelets iii. Serotonin is released from enterochromaffin cells in blood and taken up and by platelets

activates mast cell and releases histamine. **b) Anaphylatoxins – C5a, C3a** Common infection like cold, trauma stimulate them i. Stain for mast cells- toluidine blue (Metachromatic stain). 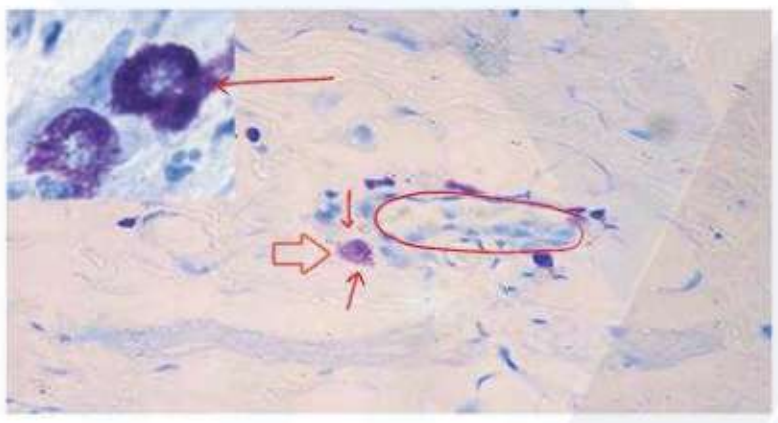 **Action of histamine** i. Bronchoconstriction ii. Increased vascular permeability iii. Vasodilation.	iv. Serotonin is stored in dense granules in platelets Action of serotonin v. Increased vascular permeability vi. Vasodilation at site of inflammation and small vessels vii. Vasoconstriction at site of large vessels

AfraTafreeh.com
TUTORIALS
LOGIN FOR SUCCESS

b) Newly formed cellular mediators

- Nitric oxide
- Lipids
- Proteins

1. Nitric oxide

- It is derived from L-arginine under the action of nitric oxide synthase (NOS)
- L – Arginine $\xrightarrow{NOS}$ No.

AfraTafreeh.com

Types of NOS

- Inducible
- Endothelium
- Neuronal
- Action of NO is vasodilation and decreases platelet aggregation, forms ONOO – (peroxynitrite) that kills bacteria

2.Lipids

- They are derived from cell membrane. **lipoprotein lipase** acts on lipids and releases arachidonic acid and linolenic acid enzymes acting on arachidonic acid

  1.COX pathway

  2.LOX pathway

COX pathway

Two enzymes:

- COX – 1 present in all cells
- COX – 2 only in inflammation

COX pathway

Arachidonic acid

↓ COX -2

PG G_2

↓

PGH_2

PGH2

$PG\ I_2$ | $TX\ A_2$ | $PG\ D_2/PG\ E_2/PGF_2\alpha$

- **PG I2** – Released from endothelium
- Action – It causes vasodilation and decrease in platelet aggregation
- **TXA2 (Thromboxane A2)** – Released from platelets
- It causes vasoconstriction and increase in platelet aggregation
- **PGE2** – It causes pain and fever
- **PGF2 (Alpha)** – It causes smooth muscle contraction Example: - Uterine

LOX pathway

AfraTafreeh.com

5 HPE TE

(5 – Hydro peroxy eicosa tetra enoic acid)

↓ **5 LOX**

5 HE TE

TUTORIALS LOGIN FOR SUCCESS

- 5 HETE – acts in chemotaxis
- 5 LOX pathway occurs in neutrophils

5HPETE

↓ 12-LOX

Lipoxins

Lipoxin acts as an:

- Anti – inflammatory molecules
- Inhibit natural killer cell

AfraTafreeh.com

- Inhibit neutrophilic chemotaxis
- Neutrophils and platelets binding activates the 12 LOX pathway

5 HPE TE

↓

LTA4

LTC4.D4. E4 LTB4.

- **LTC4, D4, E4** – They are called as slow reactive substances of anaphylatoxins (SRS-a)
- Action is vasoconstriction, increase in vascular permeability **bronchoconstriction**
- **LTB4** – It causes chemotaxis

High yield box

1. Vasoconstriction – Thromboxane A2, SRS-a
2. Pain – PGE2, Bradykinin
3. Chemotaxis – LTB4, 5HETE, C5a, C3a
4. Anaphylatoxins – C3a, C5a

Cytokines 00:30:01

Two types of cytokines

I. Inflammatory

II. Homeostasis

I. Inflammatory

a) Acute inflammatory cytokine → TNF, IL-1, IL-6, IL17, Chemokines – CXC, CC, CX3C

TUTORIALS LOGIN FOR SUCCESS

- All are released by macrophages except IL17 which is produced by TH1
- TNF and IL1 increase expression of adhesion molecules
- TNF causes cachexia
- IL1 causes fever
- IL6 is released from macrophages, its receptor is present on liver, during inflammation it binds to the receptor and release acute phase reactants

b) Chronic inflammatory cytokines → IL-12, IFN γ, IL-17

II. Chronic cytokines

- IL-12 – Released by macrophages which activates TH1
- IFN γ – Converts macrophages to epithelioid cells and lead to granuloma formation
  It is released by TH1 cells
- It activates neutrophils
- IL 17 – It is released by TH17 cells
  It is commonly seen in inflammatory bowel disease.

Homeostasis – New

- These cytokines direct movement of T cells towards paracortical areas and movement of B cells towards follicles

AfraTafreeh.com

PLASMA MEDIATORS WITH COMPLEMENT, OPATHIES

Plasma mediators 00:00:05

There are three types of plasma mediators

I. Kinin system

II. Coagulation system

III. Complement system

I. Kinin system

- Kinin acts as coagulation factor XII

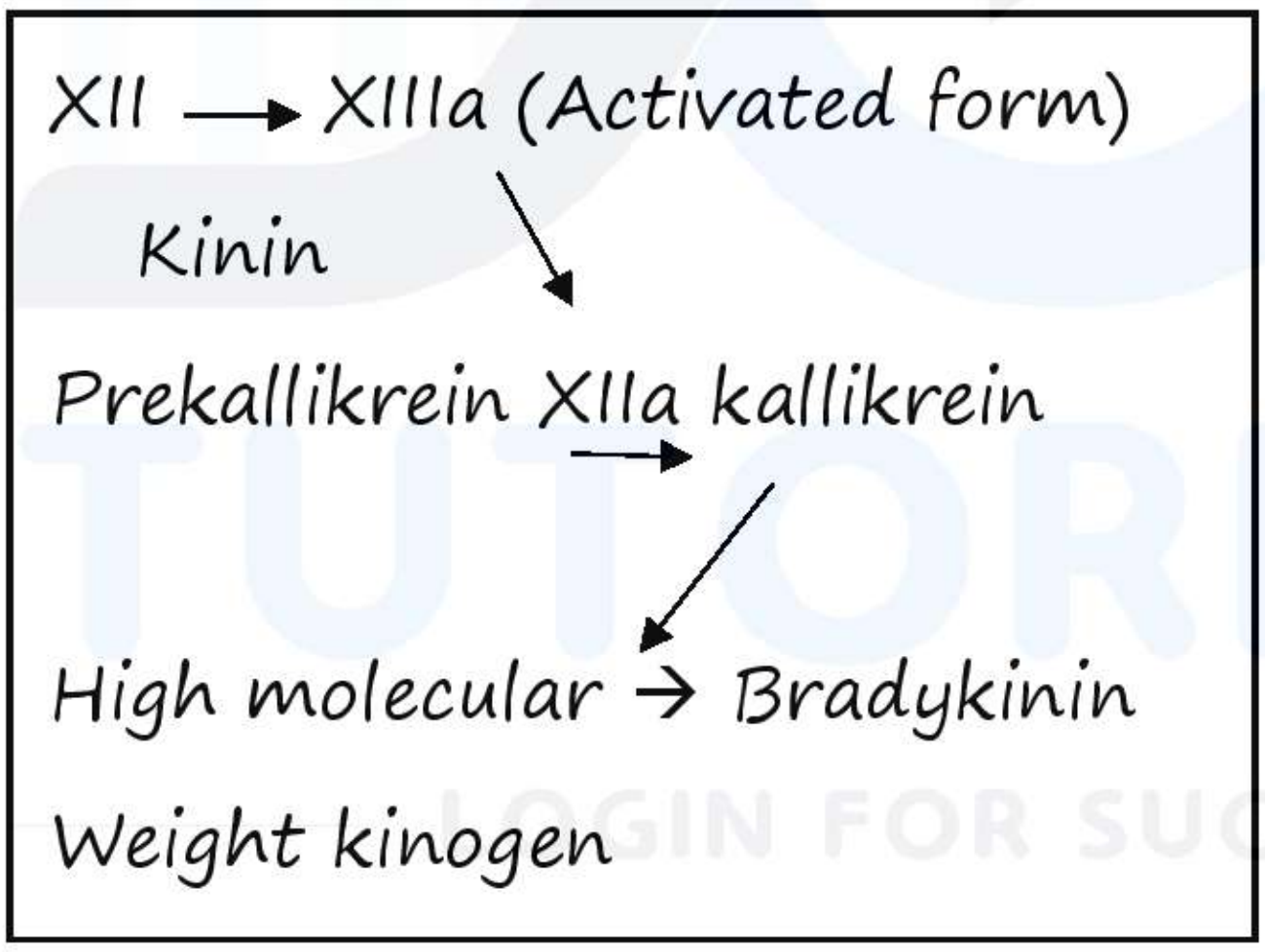

Bradykinin formed at the end of kinin pathway

actions:

- Pain
- Increased vascular permeability
- Vasodilation
- Bronchospasm

II. Coagulation system

- Thrombin is known as the master regulator – as it activates PAR (Protease activation receptors)
- These receptors are involved in the process of inflammation

III. Complement system

1. Classical complement pathway
   - It is activated by antigen – Antibody pathway

     Ag → C1 → C2 → C3
2. Alternate pathway
   - It is activated by Ig A
   - In this pathway microbes directly activate C3
   - C1, C2, C4 are not involved
3. Lectin pathway
   - Mannose binding lectin receptors
   - Binds on surface of microbes
   - These receptors activate

       C1 → C2 → C4
                  ↓
                 C3

AiraTuition.com
TUTORIALS
LOGIN FOR SUCCESS

AfraTafreeh.com

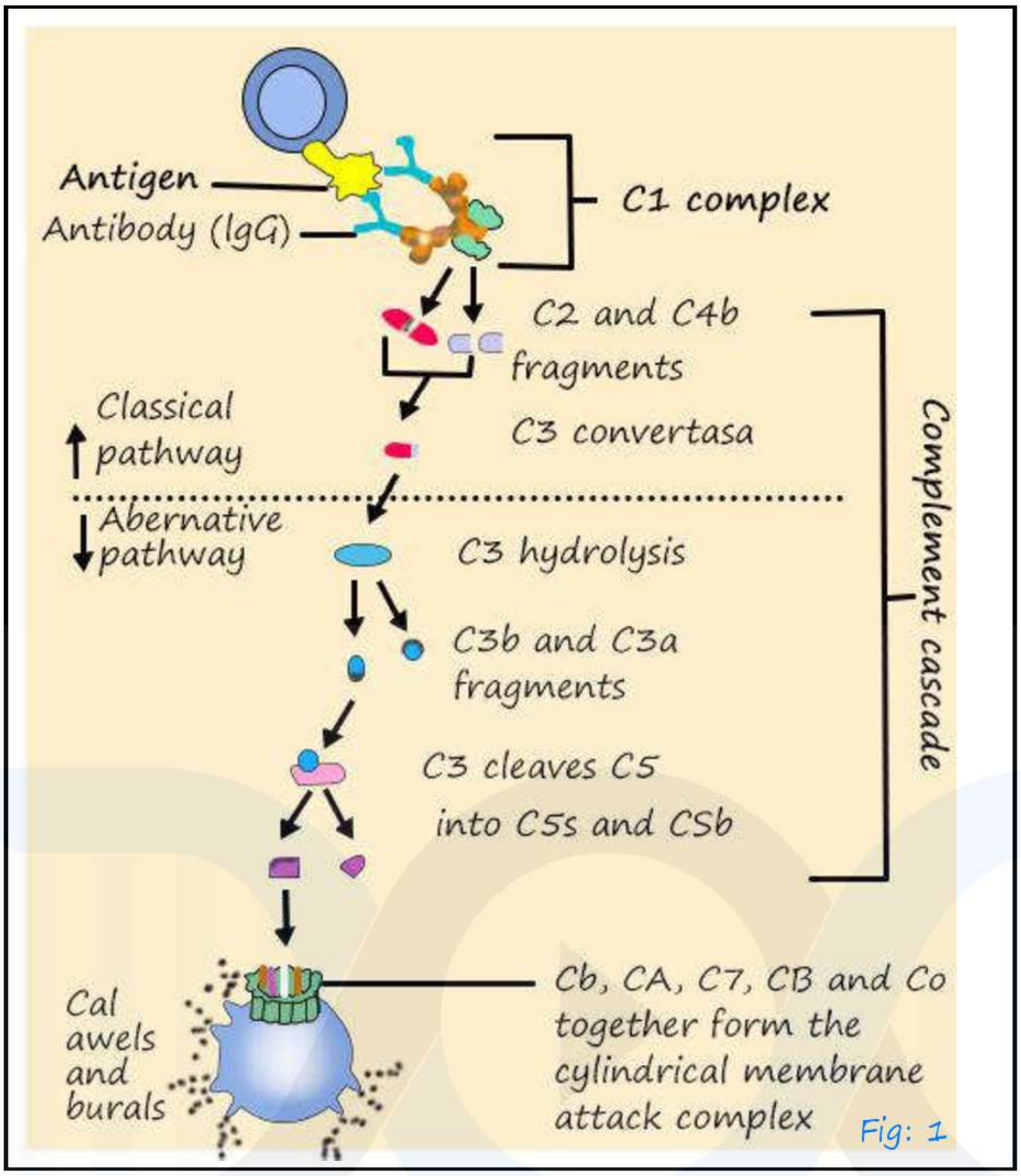

Fig: 1

- C3 convertase acts on C3 and breaks it down into C3a and C3b

C3 —C3 Convertase→ C3a – chemotaxis / C3b – opsonisation

- C3 activates C5 convertase which acts on C5

C3b → C5 Convertase

C5 —C5 Convertase→ C5a – chemotaxis / C5b –

- C5b combines with C5 – C9 known as **MAC**

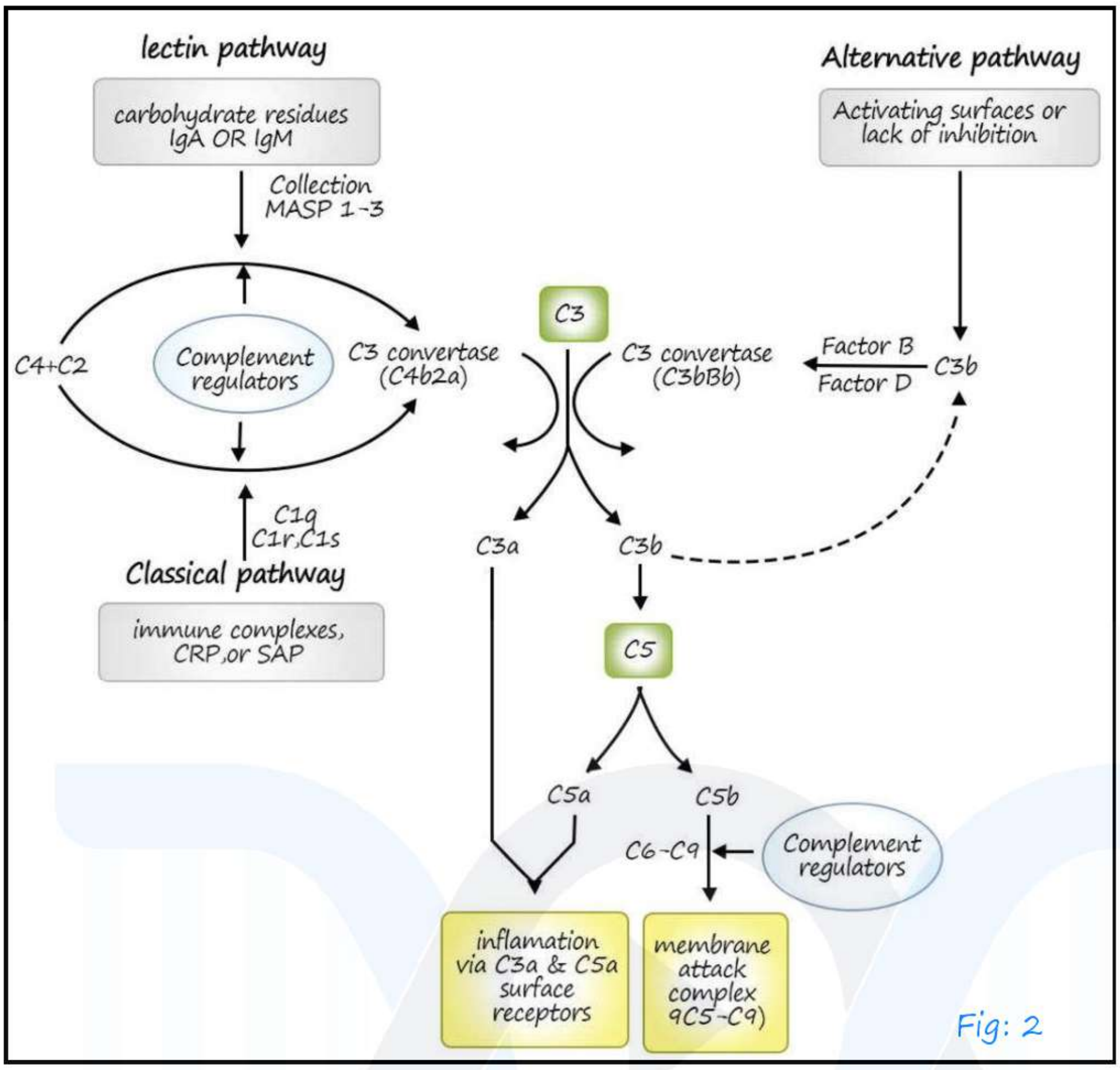

Fig: 2

AfraTafreeh.com

- Membrane activated complex
- MAC [C5-C9] → Attacks thin wall bacteria and kills them

  example: Neisseria
- C3a; C5a → Chemotaxis, anaphylatoxin
- C3b; C5b → Opsonization
- If Early part of components (C1, C2) are deficient – cause autoimmune diseases like SLE
- If later part of the components is deficient –C5-C9 – cause Neisseria

High yield box

- C1 – inhibitor – Inhibits complement C1

AfraTafreeh.com

- C1 – Inhibitor deficiency leads to **Hereditary Angioedema**
- This is a non-pitting edema

Complementopathies 00:11:10

1.Atypical hemolytic uremic syndrome

- C3 convertase is controlled by **factor H.I**
- Absence of factor H, I lead to over activation of C3 convertase which damages cells
- This is seen in Atypical HUS

2.C3 Glomerulonephritis

- C3 NeF stabilizes C3 convertase
- Absence of C3NeF → over ease expression of C3 convertase
- This is seen in C3 glomerulo nephritis it was earlier called MPGN2
  (Membrane proliferative Glomerulo nephritis)

3.Paroxysmal Nocturnal Hemoglobinuria

- **DAF** (Decay Accelerating Factor) it controls C3 convertase in RBC
- **MIRL** (Membrane inhibitor reactive lysis) it controls C5 convertase in RBC
- DAF and MIRL are GPI linked proteins
- Absence of DAF and MIRL occurs in paroxysmal Nocturnal Hemoglobinuria.

CHRONIC INFLAMMATION, TYPES OF MACROPHAGES AND GIANT CELLS

- Hall mark of chronic inflammation is Tissue destruction
- The main morphological cell in chronic inflammation is macrophages
- Exception is pseudomonas infection it has neutrophilia

Macrophages 00:02:30

Two types:

I. Activated macrophages

II. Resident macrophages

AfraTafreeh.com

I. Activated macrophages

- They are derived from blood monocytes
- Blood monocytes have a life span for **1 day in blood**
- When blood monocytes enter tissue, they turn into macrophages
- Activated macrophages are classified as:

  a) Classically activated

  b) Alternatively activated

a) Classically activated

- Act on TH1 helper cells which release interferon gamma act on macrophages
- Which are converted into epithelioid cells
- These cells have a **slipper shaped nucleus**

AfraTafreeh.com

- The epithelioid cell cluster together to form granuloma

Classically Activated macrophages → Activate TH1 → Release IFNgamma ↘ Macrophages epitheloid cell
IFN gamma ↓

- Classically activated macrophages are involved in inflammation and cause tissue destruction

b) Alternatively activated

- TH2 cells release IL4, IL13 which act on macrophages and release **TGF β and IL-10.**
- Transforming growth factor (TGF β) causes fibrosis, angiogenesis and, anti-inflammation
- TGF β and IL-10 lead to formation of granulation tissue by proliferation of blood vessels
- Alternatively activated macrophages are anti-inflammatory and cause tissue repair
- **Hall mark of repair is granulation tissue**
- Granulation tissue is forme by the proliferation of blood vessels, macrophages and extracellular matrix

II. Resident macrophages

- These macrophages are derived from yolk sac and fetal liver

Organ/Tissue	Resident macrophages
i.Brain ii. Liver iii.Spleen iv.Kidney v. Bone vi.Placenta vii. Synovium viii. Bone marrow/ ix. Skin/lymph nodes	i. Microglia ii. Kupffer cells- (localized in a sinusoidal wall) iii. Littoral cells iv. Mesangial cells v. Osteoclasts vi. Hofbauer cells vii. Type a cells viii. Histiocytes

Giant cells 00:16:25

AfraTafreeh.com

- Macrophage have tendency to fuse together and form giant cells
- Types of giant cells:
  I. Physiological
  II. Pathological

I. Physiological

- Synctiotrophoblast
- Osteoclasts

> Megakaryocyte is not a giant cell, it undergoes endodublication

AfraTafreeh.com

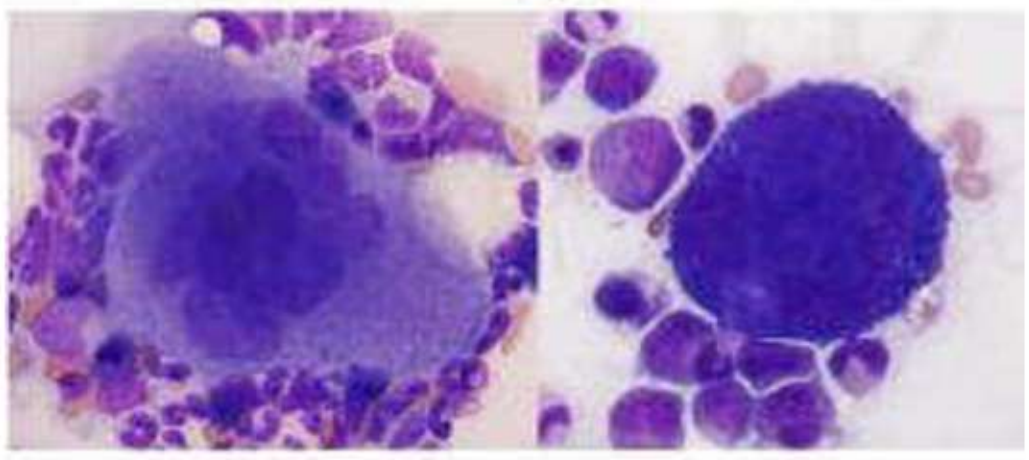

Fig: 1

- If megakaryocyte becomes a giant cell, it is called pawn – Ball megakaryocyte, Seen in myelodysplastic syndrome

II. Pathological giant cell

a. Horse shoe pattern giant cell

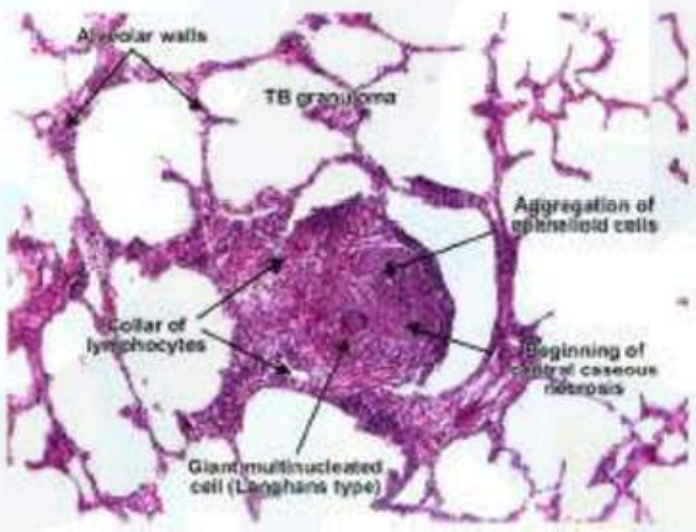

Fig: 2

- Nuclei are arranged in **horse shoe pattern**
- There type of giant cells is called Langhan's Giant cell see in TB
- **Langerhans cells are immature dendritic cells**

b. Foreign body giant cell

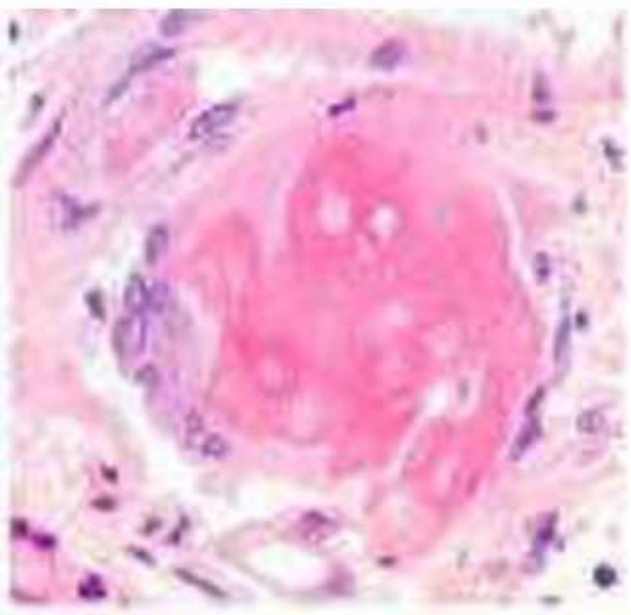

Fig: 3

- Nuclei are arranged in a haphazard manner

- Foreign body is visible under polarized light as refractile matter

c. Touton giant cells

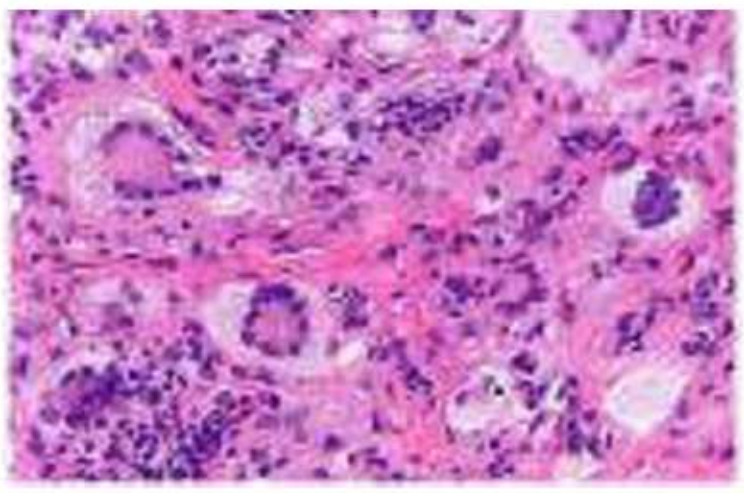
Fig: 4

- Nucleus in centre and surrounding cytoplasm is foamy
- Seen in xanthoma

d. Tumor giant cells

i. Specific

ii. Non specific

AfraTafreeh.com

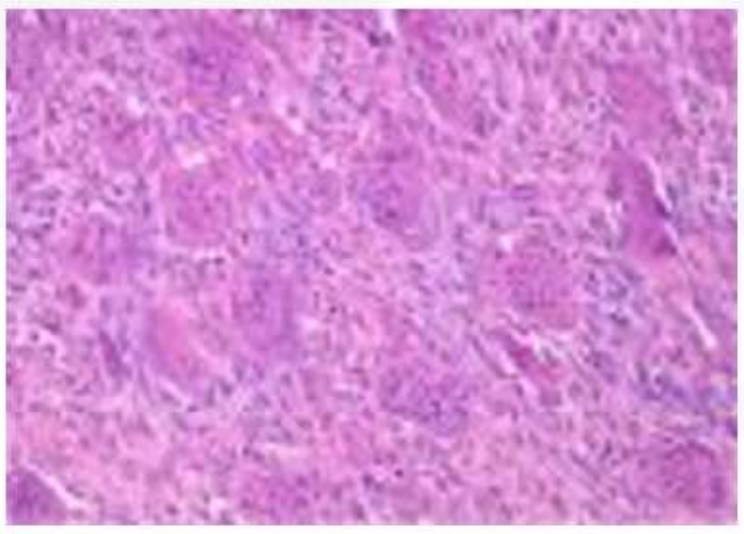
Fig: 5

i. Specific tumor giant cells

- Reed Sternberg cells a very important
  Example: Hodgkin lymphoma
- Owl eyed nucleus having eosinophilic nucleoli
- Differential diagnosis of reed Sternberg cells in cytomegalo viruses
- Owl eye inclusions seen in CMV
- A perinuclear halo around nucleoli

AfraTafreeh.com

- It also has granules cytoplasmic inclusion

ii. Nonspecific tumor giant cells

- Osteosarcoma
- Hepatocellular carcinoma

e. Warthin finkeldey giant cells

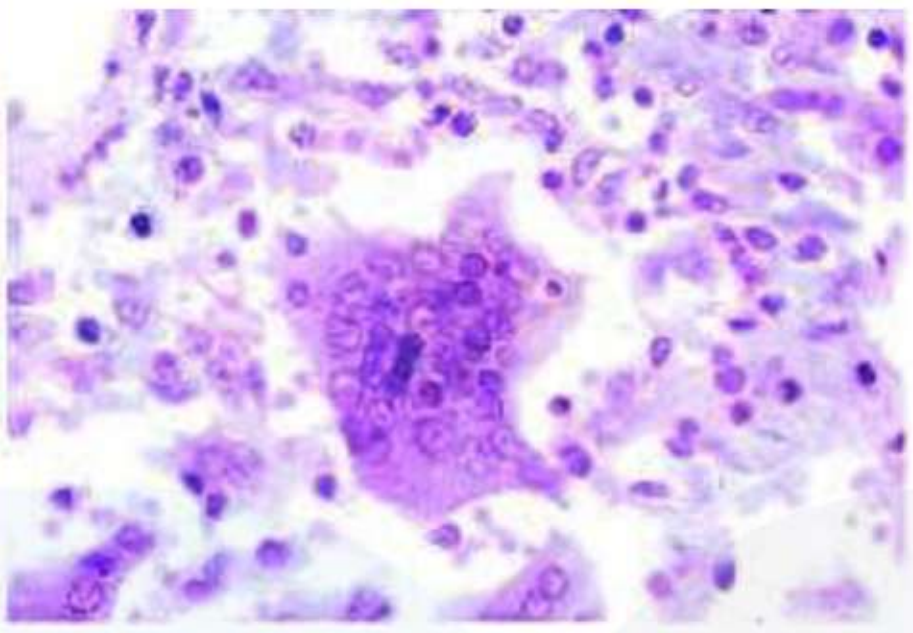

Fig: 6

- Amoeboid shaped cells
- Every nucleus contains inclusions
- Seen in measles (height pneumonia) reed

f. Herpes simplex virus

- 3M's – Multinuclearity nucleus
- Molding of the nucleus
- Marginate → chromatin moves to margin and nucleus clear in center
- Giant cell tumor/Osteoclastoma
- Seen in large bones and tendon sheaths
- In tendon sheath, mostly hands it is called Tenosynovial Giant cell tumor
- The malignant component in the GCT is the mononuclear cells
- Giant cells are benign and undergo reactive proliferation seen surrounding the malignant mononuclear cells.

TYPES OF GRANULOMAS

Granulomas 00:00:49

- It is formed by classically activated macrophages and giant cells classification of granuloma
- Non immune
- Immune
- Non immune granuloma is seen in foreign body, Immune system is not involved in the formation of granulomas, there is no T cell response
- Most common foreign bodies are silica, talc

AfraTafreeh.com
TUTORIALS
LOGIC FOR SUCCESS

Immune granuloma 00:02:18

Two types:

I. Infections associated granuloma

II. Non infections associated granuloma

I. Infections associated granuloma 00:02:52

1.Tuberculosis

- Mycolic acid present in the cell wall of TB bacilli leads to caseous necrosis
- The granuloma – consists of a center of caseous necrosis, surrounded by epithelioid cells having slipper nuclei, surrounded by lymphocytes
- Long standing granuloma may be surrounded by fibroblast

AfraTafreeh.com

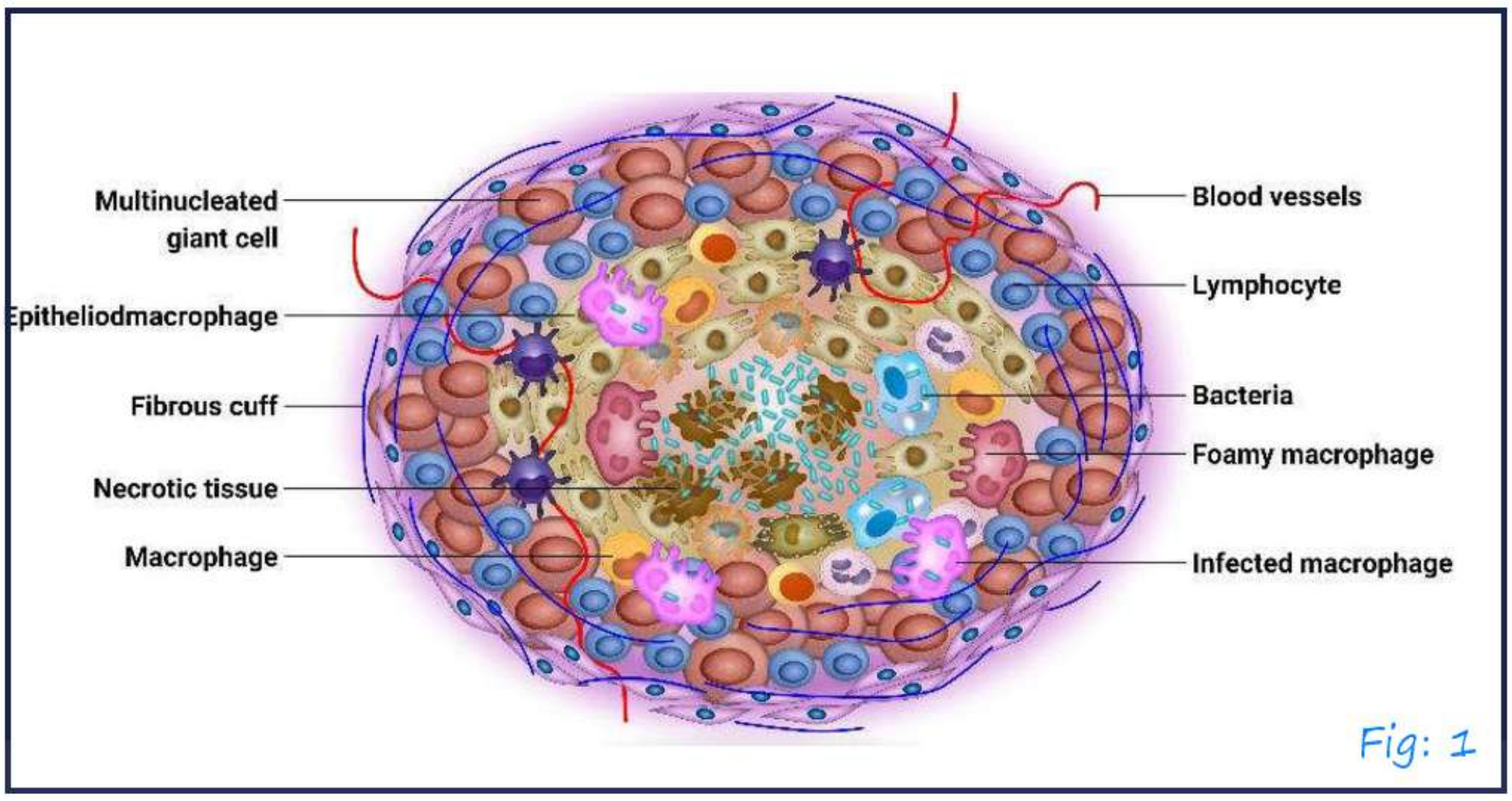

Fig: 1

- Naked granuloma- doesn't have lymphocytic coating on the outside. It is usually seen in sarcoidosis. It is a non-caseating granuloma.

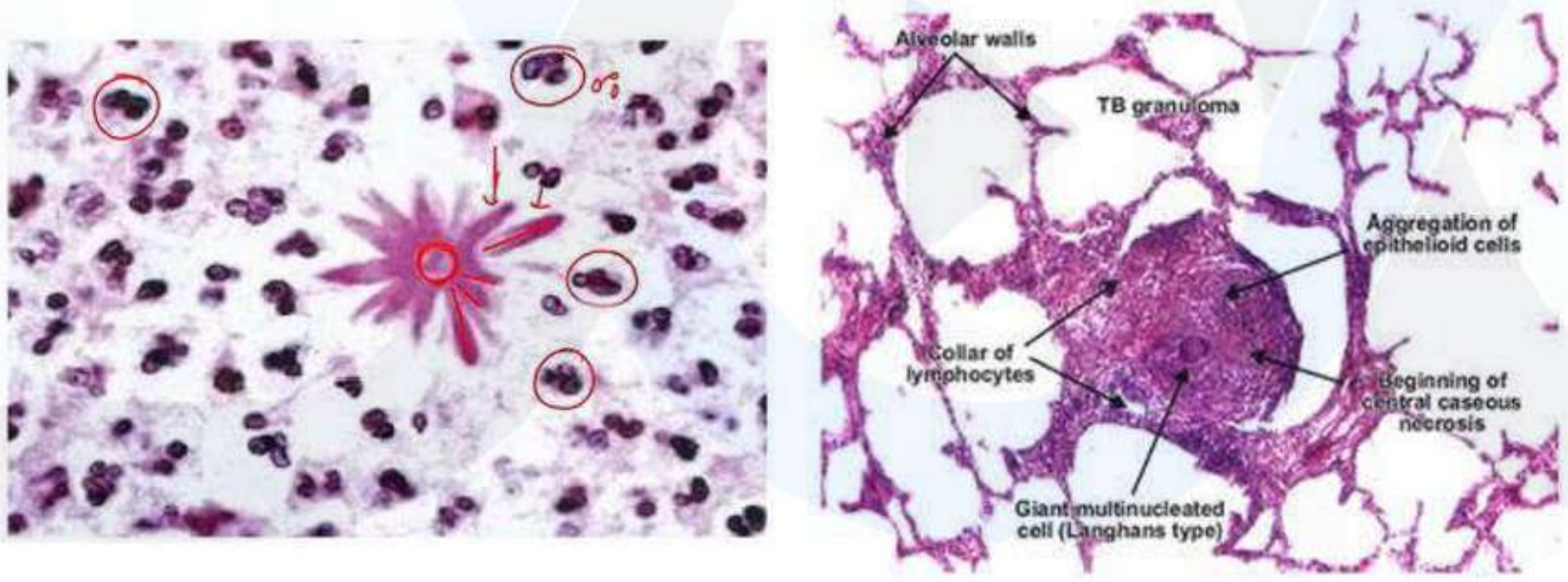

Fig: 2

Asteroid bodies 00:09:28

Sarcoidosis	sporothrix
- Intracellular	-extracellular
- Inside giant cell/ macrophage	-inside neutrophil
- central spore	

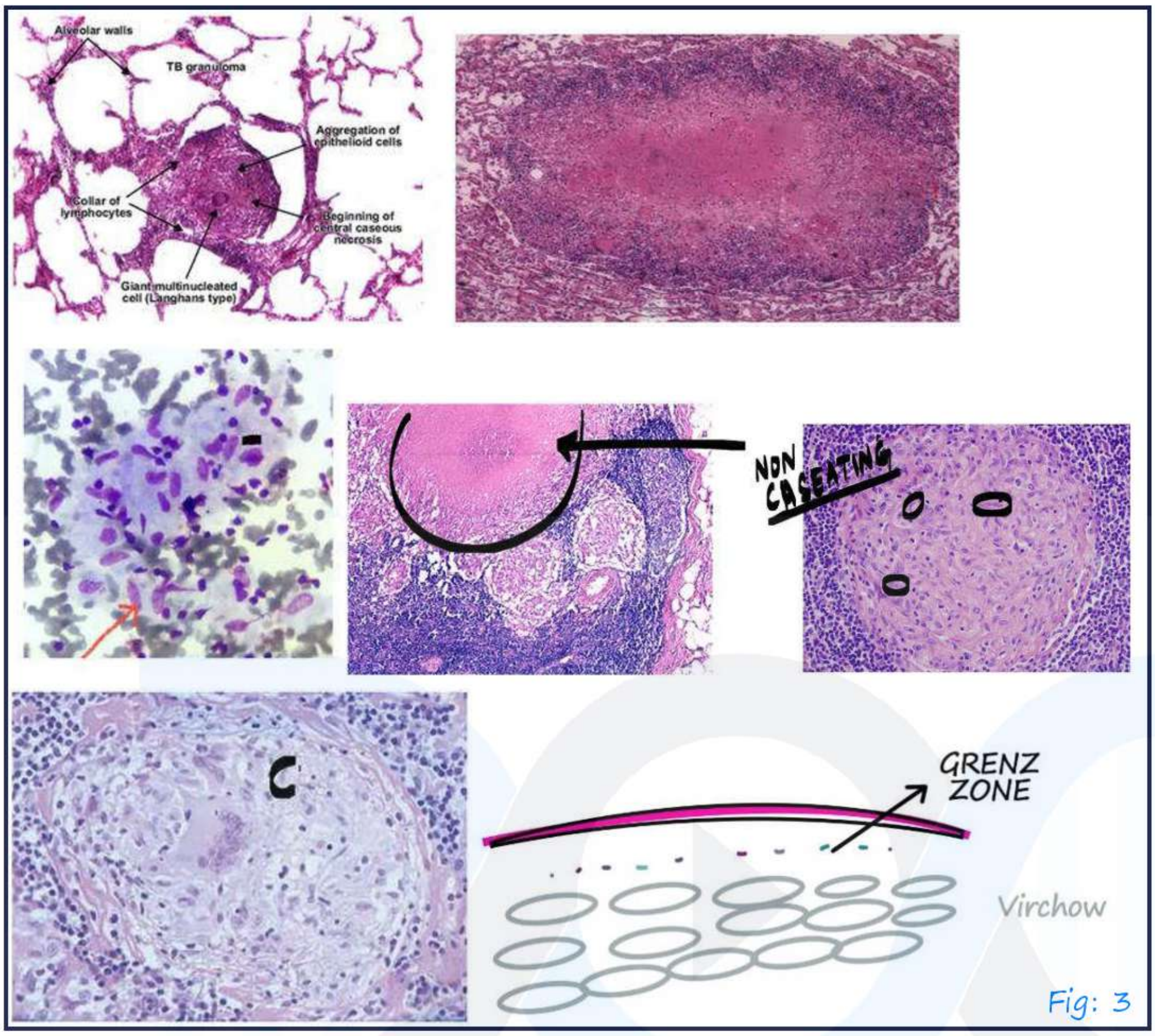

Fig: 3

AfraTafreeh.com
TUTORIALS
LOGIN FOR SUCCESS

2.Leprosy

Two types:

i. Lepromatous

ii. Tuberculoid

i. Lepromatous

- Immune system is weak/absent
- The macrophages eat lepra bacilli and form foam cells containing bundles of acid-fast bacilli called **Globi**
- There foam cells are called Virchow cells
- The Globi is stained by
- ZN stain

AfraTafreeh.com

- Wadefite stain / Fite - Faraco stain (low acid stain)

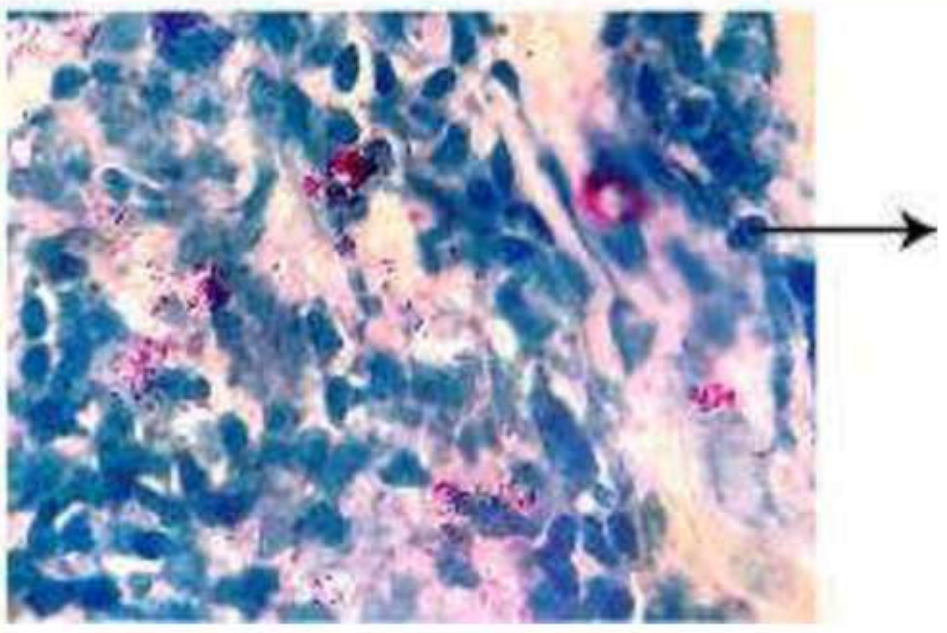

Globi of lepra bacilli (Cigar bundles)

Fig: 4

- Skin biopsy of lepromatous leprosy patient

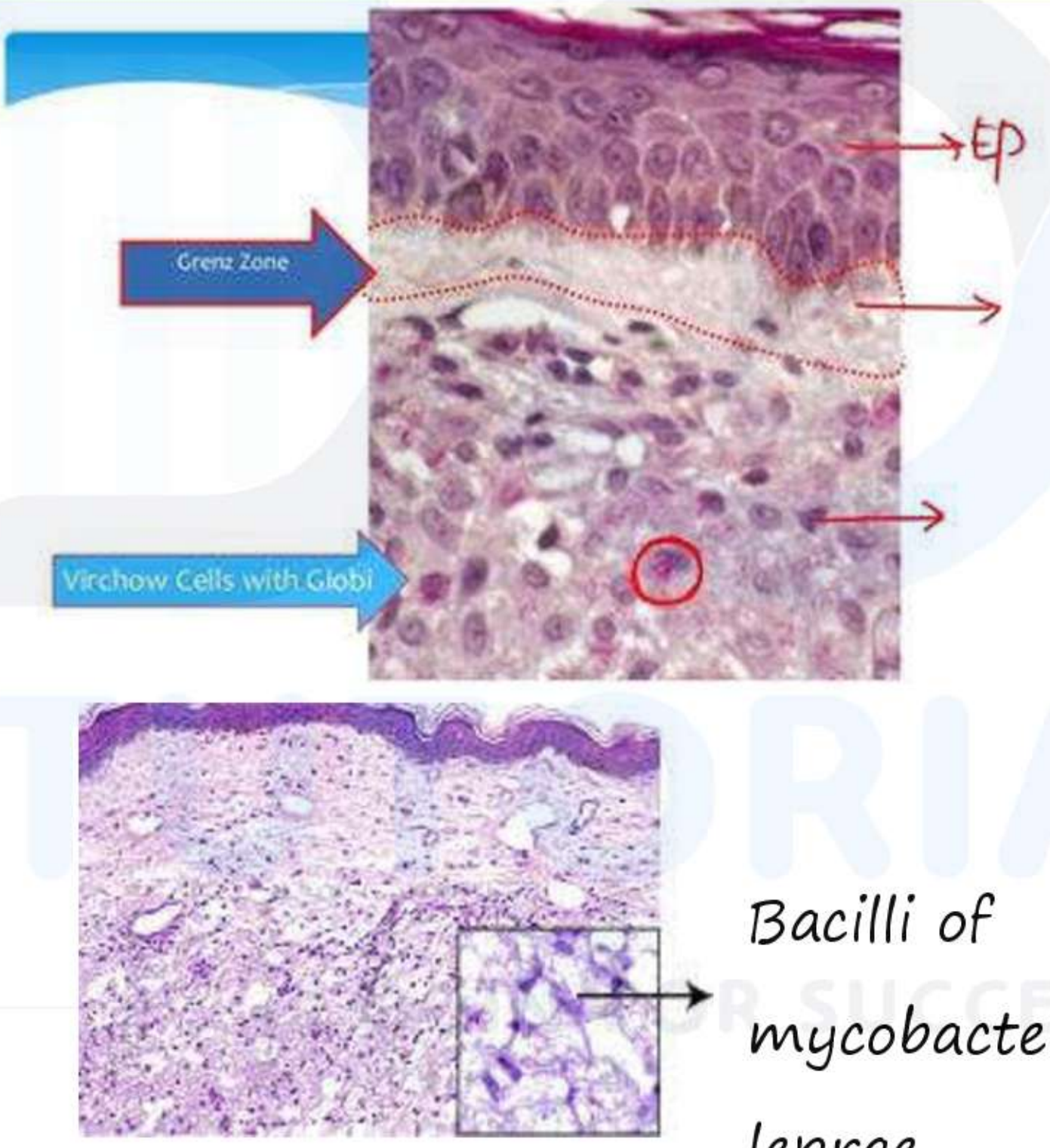

Bacilli of mycobacterium leprae

Fig: 5

ii. Tuberculoid

- Non caseating
- Localize around appendages
- Immune system is strong

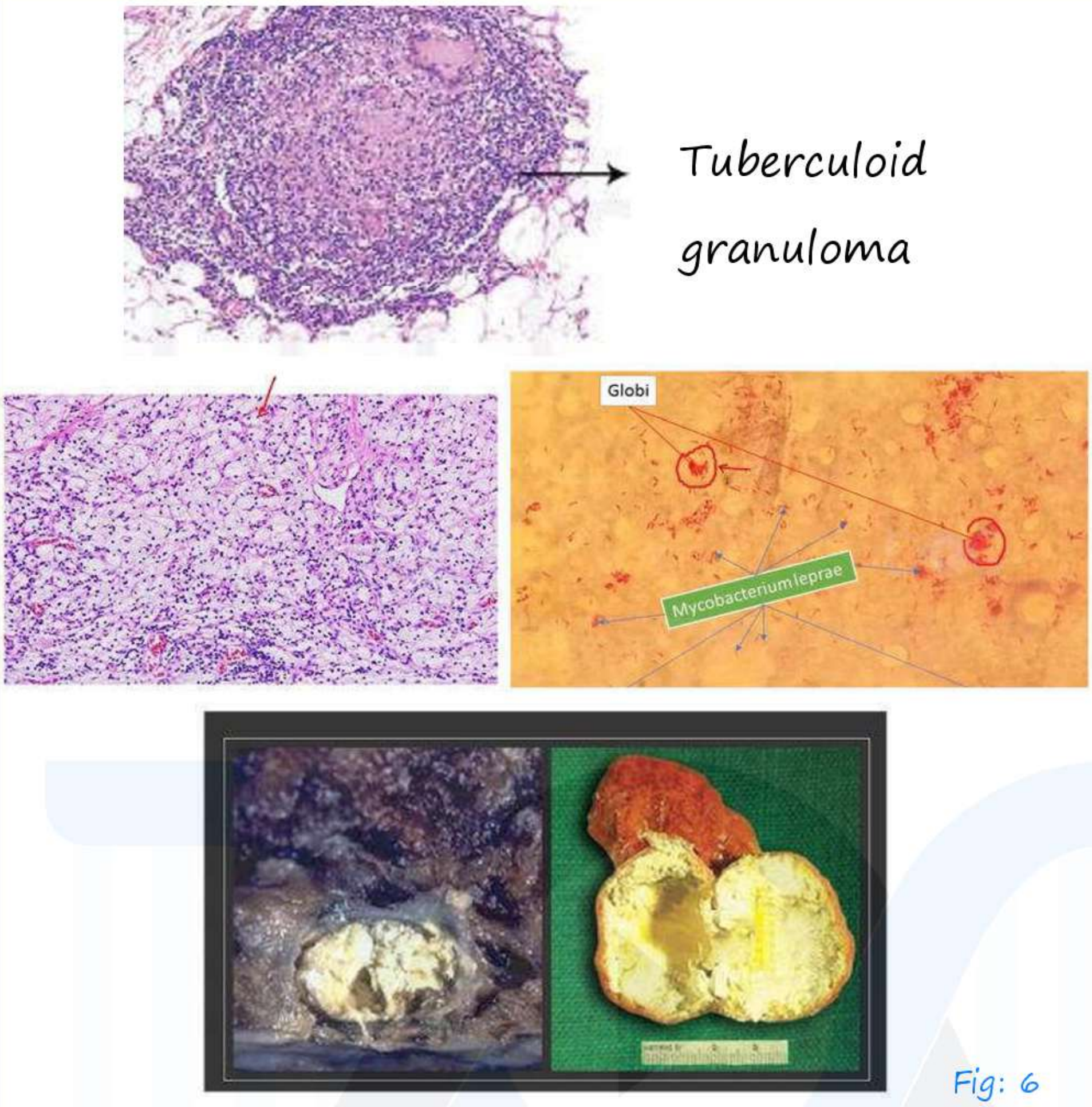

Fig: 6

AfraTafreeh.com

→ label ***caseous necrosis***

3.Syphilis

- A syphilitic granuloma is called **gumma**
- It predominantly has plasma cell

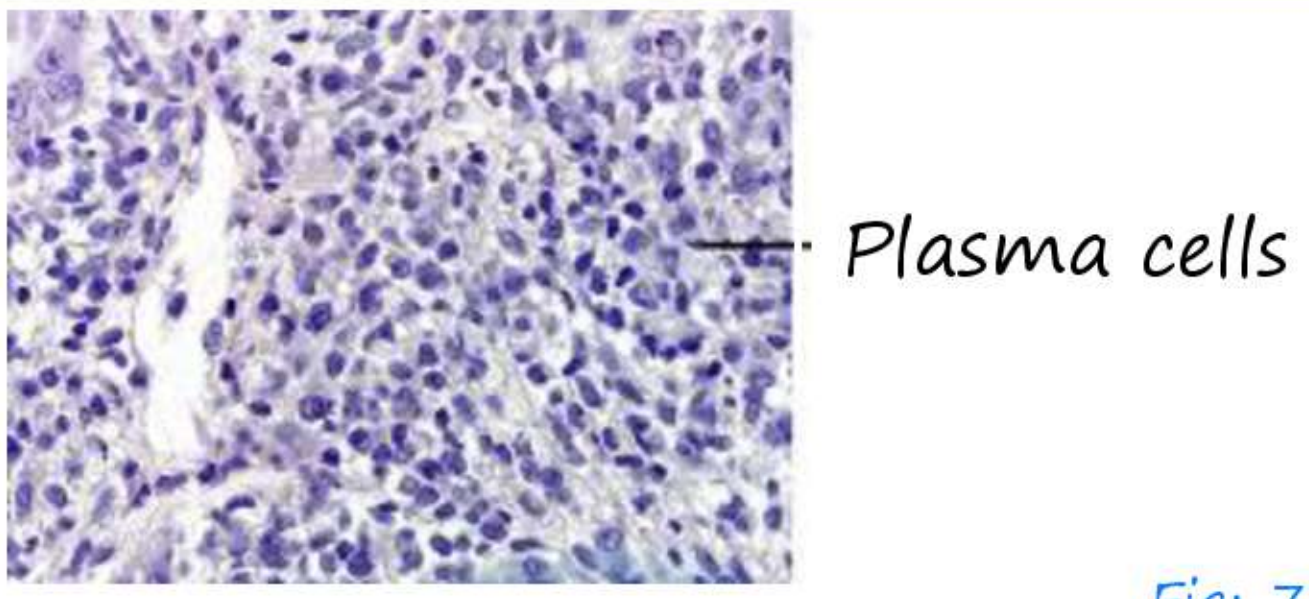

Fig: 7

4.Cat scratch disease

- A unique necrotizing granuloma called as **stellate granuloma**

AfraTafreeh.com

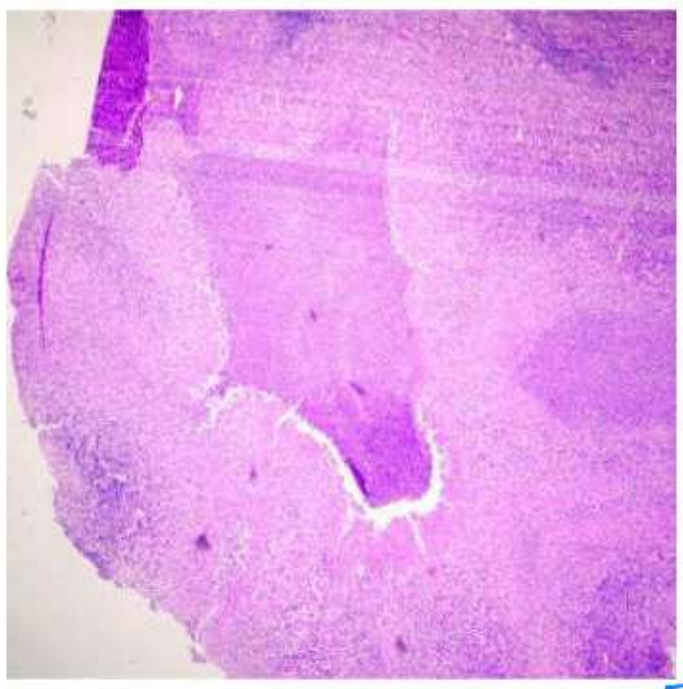

Fig: 8

- The center of the granuloma is filled with necrosis
- Neutrophils surround this necrosis
- This leads to pus formation
- This pus moves in different directions hence to stellate formation

Fig: 9

5.Malaria

- It is seen in plasmodium Falciparum infection
- It is seen in brain
- It is called as **Durck's granuloma**
- The centre of the granuloma has blood, black pigment called as **Haemazoin**
- It is then surrounded by Astrocytes which is type of glial cells proliferation.

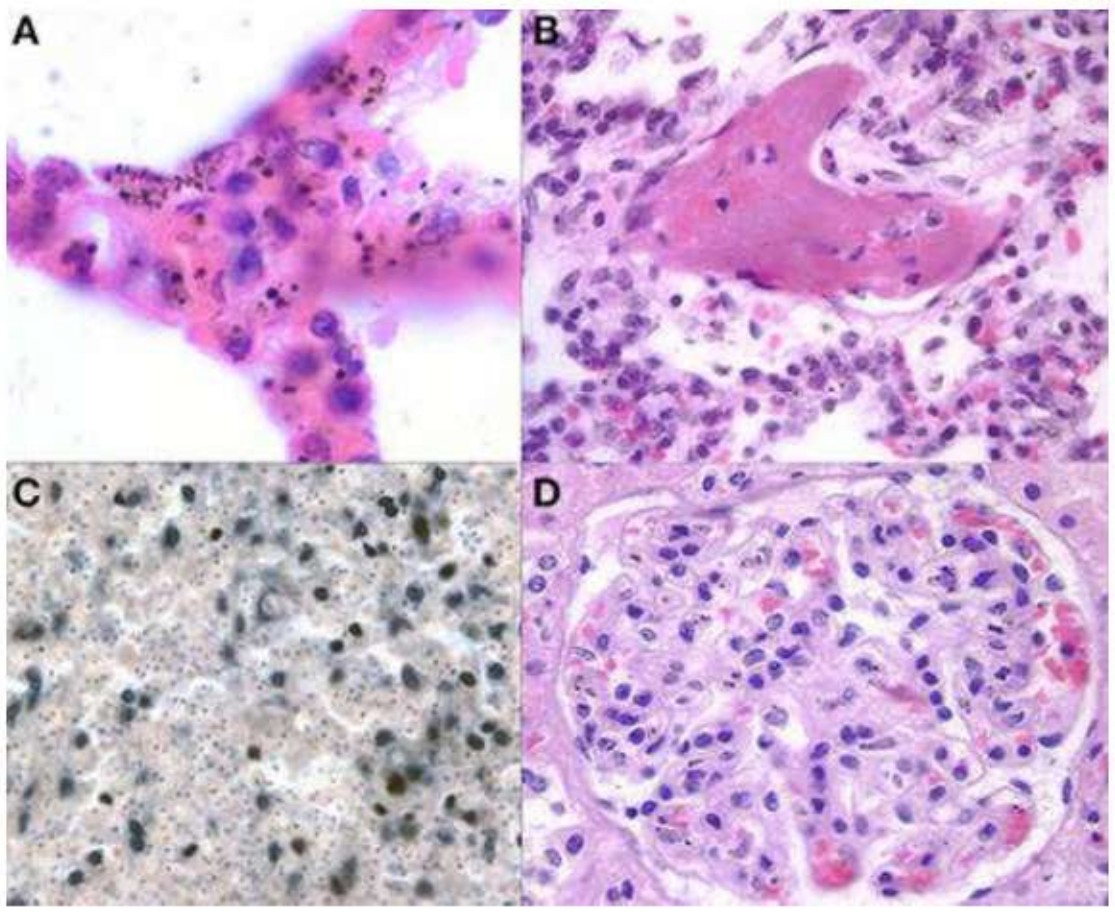

Fig: 10

6.Q fever

- It has a **doughnut granuloma** also called as Fibrin Ring Granuloma

Allopurinol administration in patients also show doughnut granuloma in liver

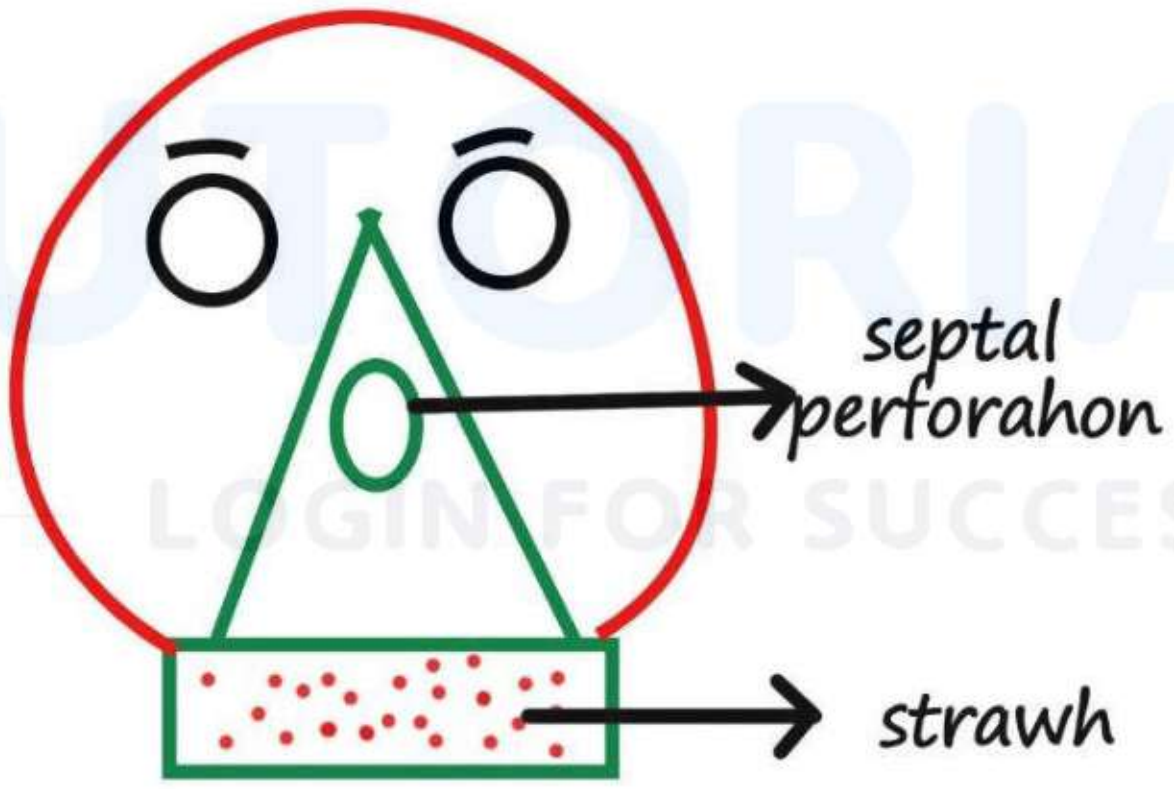

Fig: 11

Non infections associated granuloma 00:36:40

1.Sarcoidosis

2.Wegner's granulomatosis /Granulomatosis and polyangiitis

AfraTafreeh.com

- It involves three systems

URT, LRT

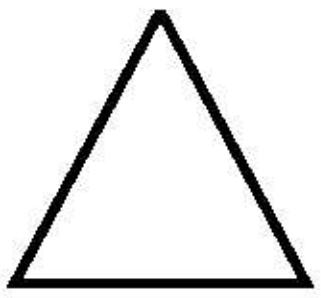

Renal system   blood vessel (Vasculitis)

- Granuloma formation is seen in Respiratory and blood vessels
- The granuloma shows geographic necrosis which leads to cavity formation in lungs, and this granuloma is surrounded by palisading histiocytes.
- URT – nasal septa perforation
- Gums- strawberry gums

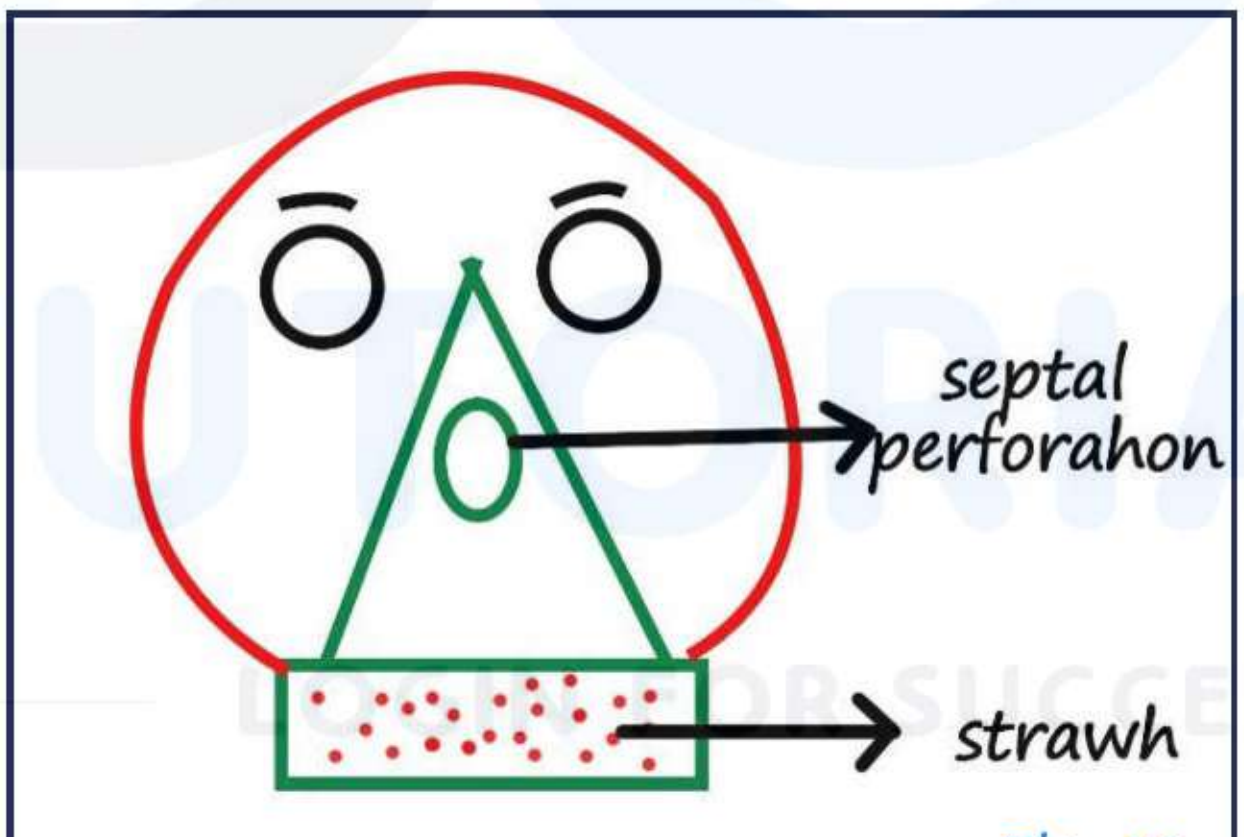

Fig: 12

- Granulomatous vasculitis
- Kidney- necrotizing glomerulonephritis (RPGN)
- c ANCA → against PR3
- LIMITED WEGENERS: Respiratory tract is involved more, kidneys are spared.

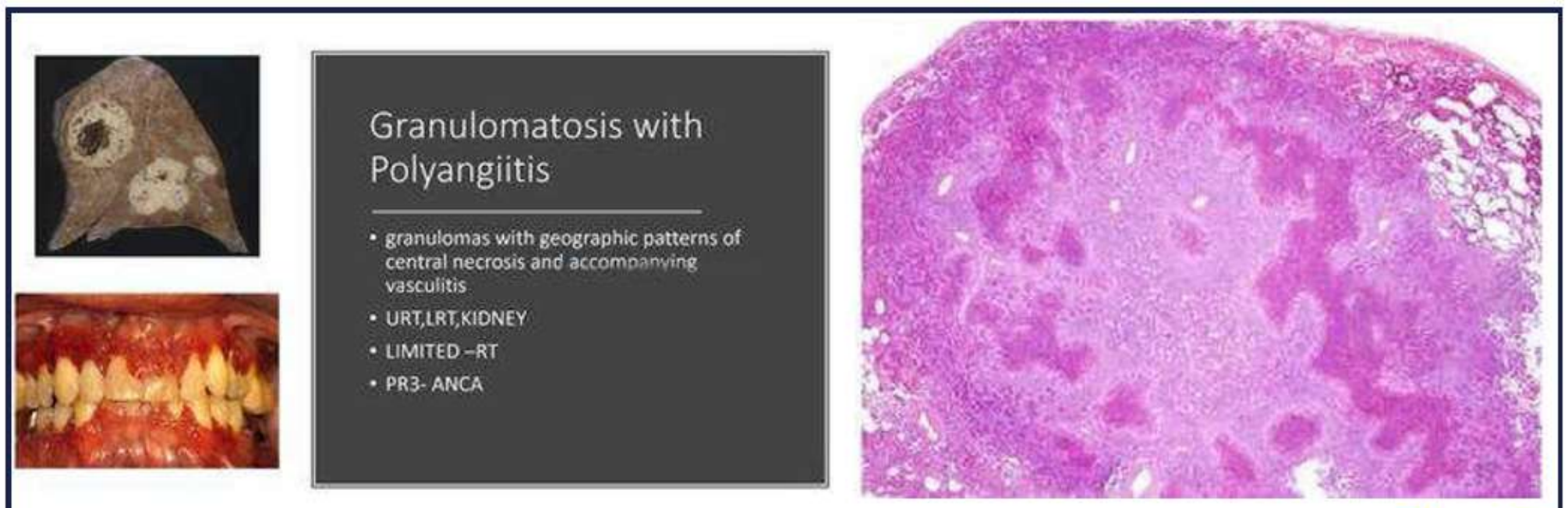

Fig: 13

3.Rheumatoid arthritis

- Palisading histiocytes

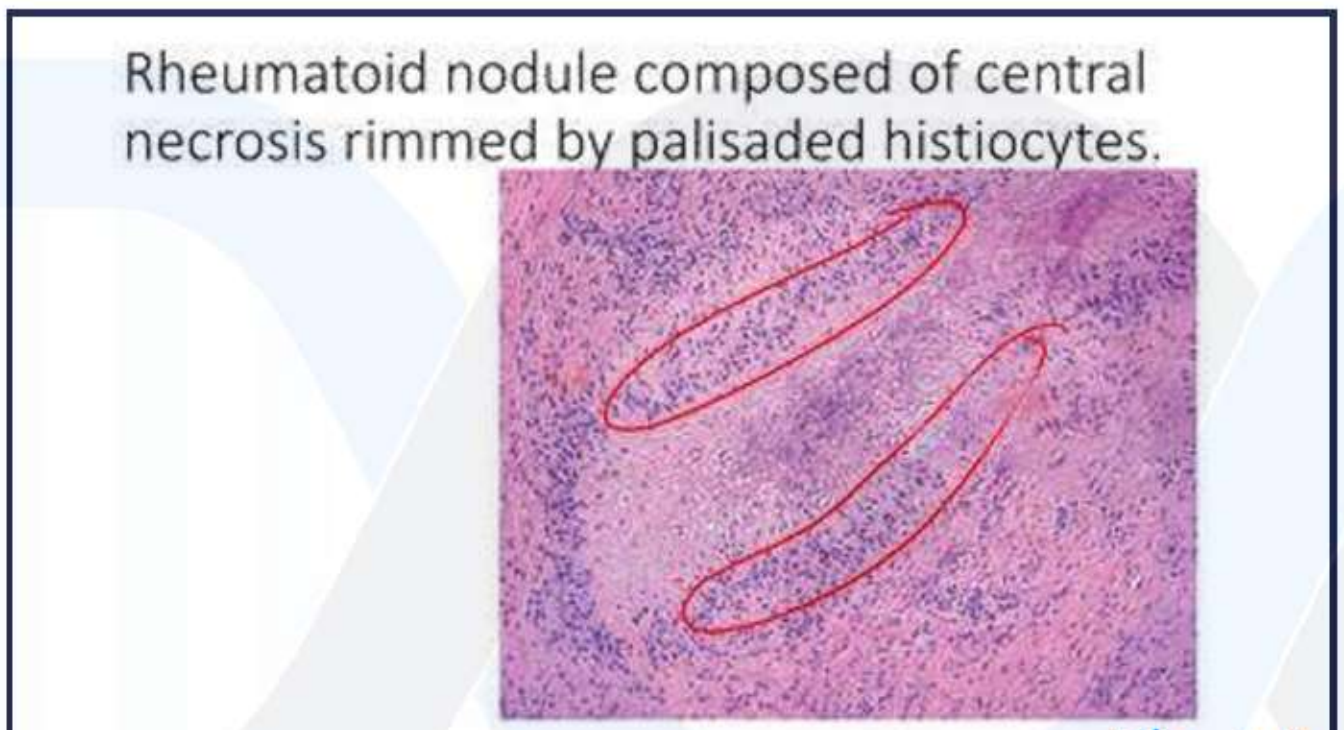

Fig: 14

4.Crohns disease

- Ibd
- Non caseating

5.Malignancy

- Hodgkins lymphoma

Necrotising Granulomas: 00:49:54

High yield Box
TB
Cat scratch disease
Wegner's granulomatosis (GPA)

AfraTafreeh.com

DIAGNOSIS OF INFLAMMATION

Two methods of diagnosis inflammation 00:00:21

I. Protein electrophoresis

II. ESR

Acute Phase Reactants: 00:01:34

Positive APR	Negative APR
i. Fibrinogen ii. CRP iii. Serum amyloid Associated protein iv. Hepcidin v. Haptoglobin vi. Ceruloplasmin vii. Alpha2 macroglobulin viii. Complement C3, C4	i. Retinol binding protein ii. **Albumin** iii. Transthyretin iv. Transferrin

Protein electrophoresis 00:02:43

- It detects acute phase reactants
  - Acute inflammation – Albumin drop protein electrophoresis

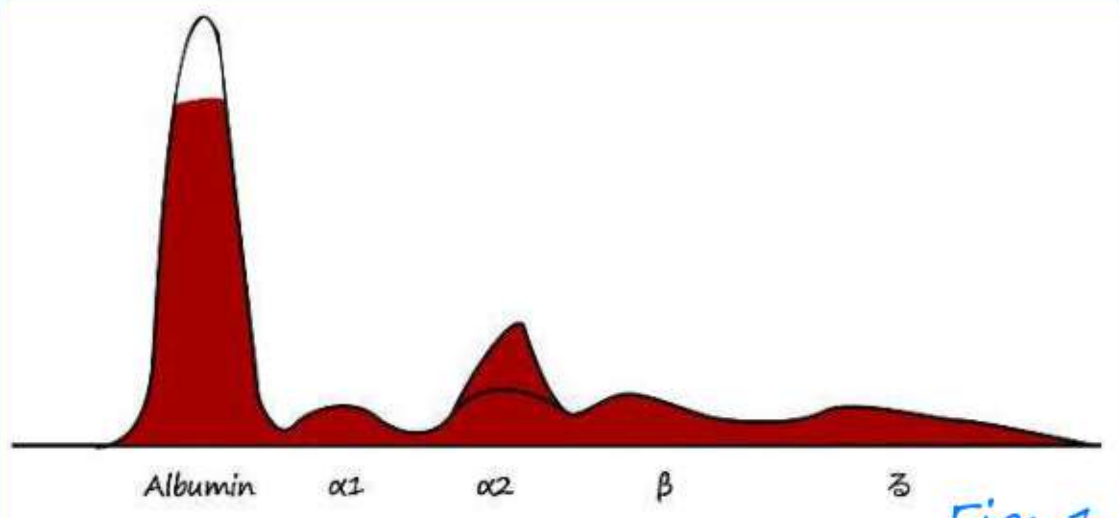

Fig: 1

- Chronic inflammation – polyclonal gammopathy and drop in albumin

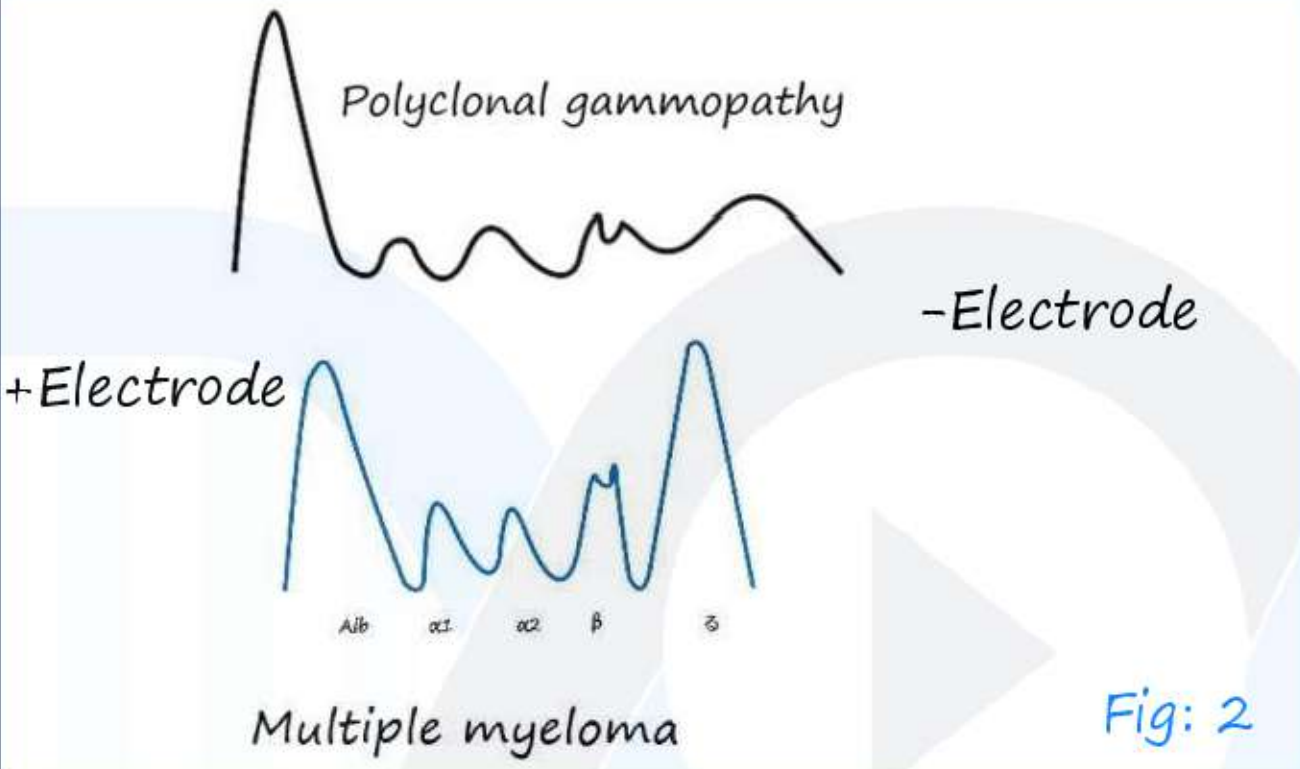

Fig: 2

- Multiple myeloma – M-band-monoclonal (single spike)

AfraTafreeh.com
TUTORIALS
LOGIN FOR SUCCESS

AfraTafreeh.com

ROSAI DORFMAN DISEASE

Rosai Dorfman Disease 00:00:30

- **Emperipolesis** – One cell eats another cell without killing the cell the nucleus is intact
- Rosai Dorfman Disease

Clinical presentation

1. Males, young age
2. Self-limiting disease
3. Massive lymphadenopathy

Microscopic appearance – Macrophages showing emperipolesis and sinus histiocytosis

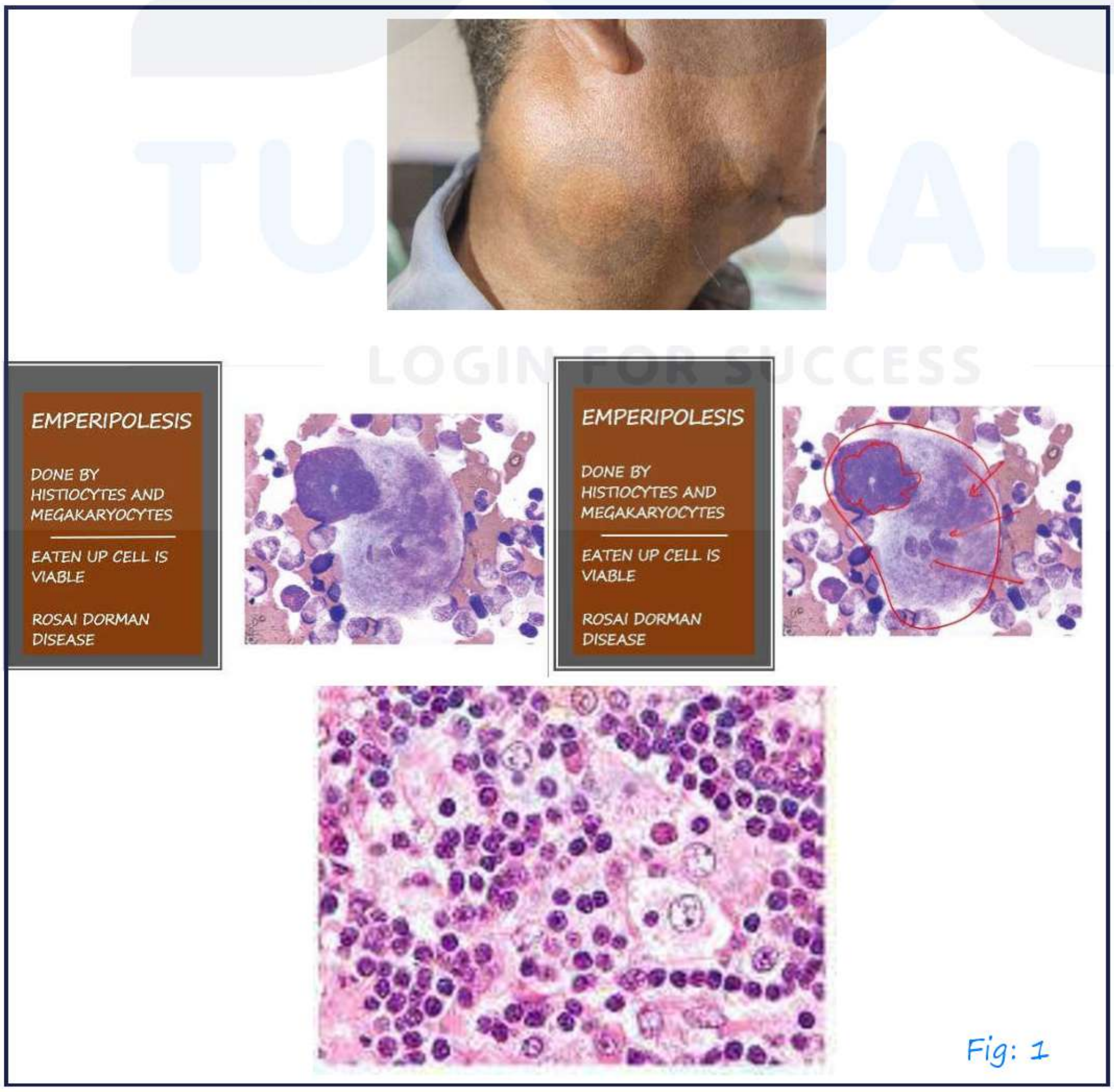

Fig: 1

CELL CYCLE

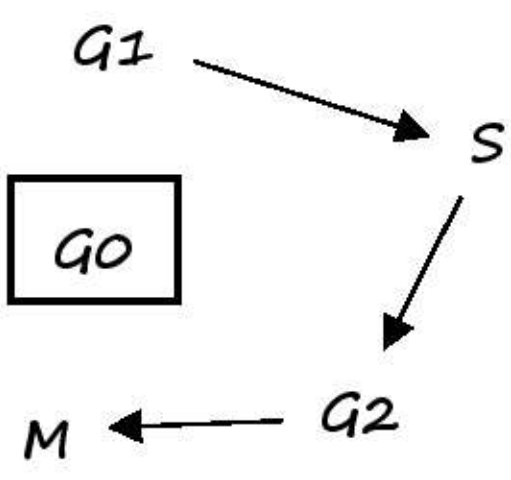

P53 (Guardian of genome)

GO – Resting phase

S – Synthetic phase DNA duplication

p53 00:01:45

i. p53 controls G1 → s phase of cell cycle

⊕

ii. DNA injury → p53

Stop

p53 ↓ p21 ↓ stops cell cycle G1S > G2M

Repair

p53 ↓ GADD45 ↓ Growth Arrest and DNA Damage 45 ↓ DNA repair → **If facts** → Apoptosis

Kill

↓ p53 ↓ BAX (proapoptotic) ↓ Apoptosis

iii. p53 → 53K Dalton – molecular weight

↓

Chromosome 17p

iv. Known as the Guardian of Genome (or) molecular policeman

AfraTafreeh.com

AfraTafreeh.com

v. Associated with multiple hereditary carcinoma syndrome

↓

Li Fraumeni syndrome

Radiation typically targets mitotically active cells i.e., M phase

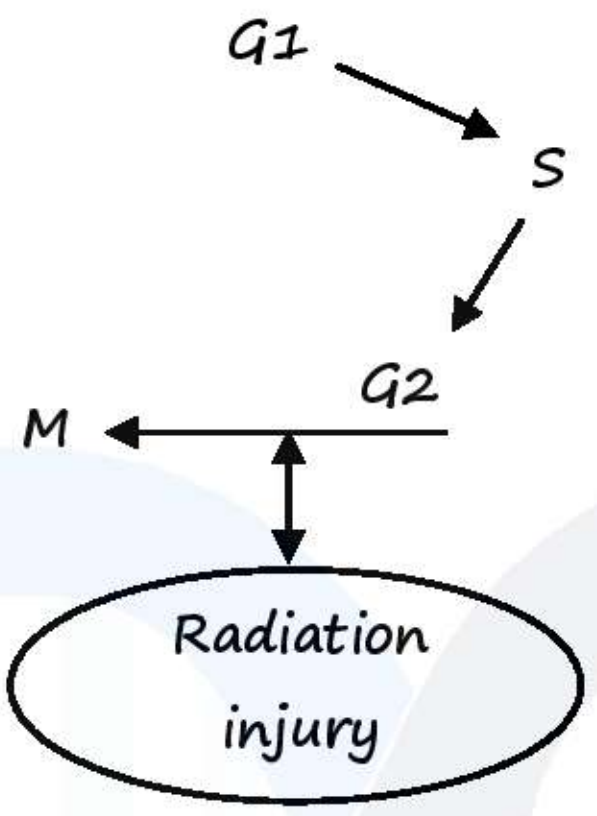

Radiation injury

p53 dependent mechanism → p53

p53 independent mechanism → **BRCA**, **ATM**

So, G2-M phase is under the control of

p53

BRCA

and ATM

whereas G1-S is only under control by p53

p53 acts

More important role	Indirectly at G1-S phase

- Directly at G2 M phase
  - Of p53 is in G2M phase
  - MDM2 keeps p53 level under control

MDM2

↓ ⊖

p53

- Most common gene to be mutated in sporadic cancer

AfraTafreeh.com

↓

p53

- These cancers are resistant to therapy poor prognosis

LOGIN FOR SUCCESS

RB gene 00:12:48

- Grandmother of the cell cycle/ Governor of cell cycle
- First tumor suppressor gene
- Located on chromosome 13q14
- Normal cell inactive because retinoblastoma (Rb) gene is holding elongation factor 2 EF-2 transcription factor required for cell cycle

Rb + EF-2 → Cell inactive

AfraTafreeh.com

Rb active – Hyperphosphorylated

Cyclins (synthesized)	Cyclin Dependent Kinase (CDK) – Already present – provide phosphate group (p)
D →	4
E →	2
A →	2
B →	1

Cyclin/ CDK –(P)
↓
Cyclin D/CDK –4

Give (p) group to Rb →
Oxidative phosphorylation

Rb inactive – Hyperphosphorylated

EF–2 free → Cell cycle proceedes

E2F

- G1 → S
  Cell cycle moves from G1 to S
- Initiates Next Cyclin
  ↓
  Cyclin E

i. Phosphorylated Rb gene makes the cell cycle on

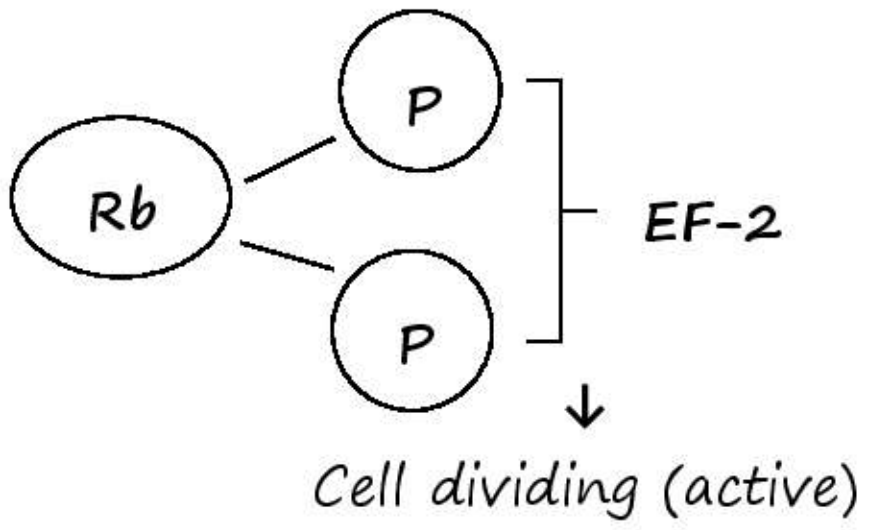

ii. Dephosphorylated Rb gene → cell cycle stops

Rb + EF 2

↓

Cell inactive

- Rb gene is the on/off switch of cell cycle

iii. Initiator of cell cycle is cyclin D/CDK4

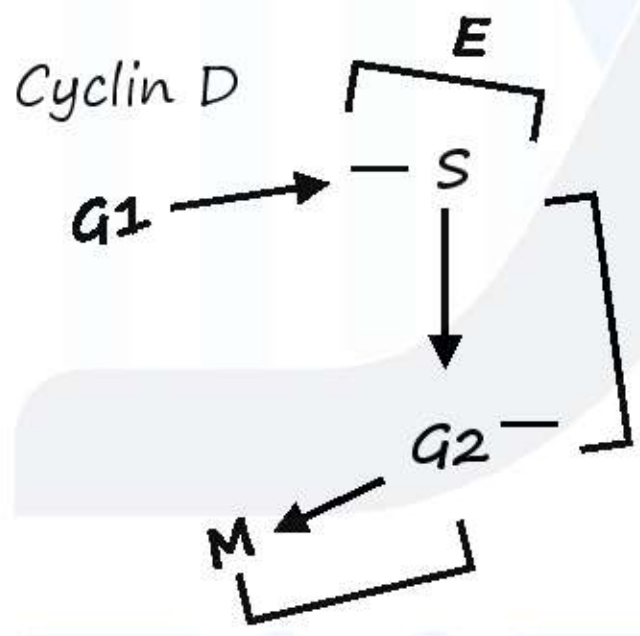

So G1S
- D (most important)
- E

G2M
- A
- B (most important)

AfraTafreeh.com
TUTORIALS
LOGIN FOR SUCCESS

- For initiation of G1-S → Cyclin D most important
- For progression of G2M → Cyclin B most important

- Cyclin B should be knocked off for cell to come out of mitotic phase

Cip/kip family

Cell cycle regulators

INK/ARF family

CDKN – Cyclin Dependent Kinase

AfraTafreeh.com

Cip/kip family

- p 21
- p 27
- p 57

p53 → p 21 ⊖ → Cyclin D

p 16 ⊖ → Cyclin D

TGF β ⊕ → P 27 ⊖ → Cyclin

P 14 ⊖ → MDM2

↓

P 53 not inhibited

So, p 14 → ↑↑ p53

INK/ARF family

- p 14
- p 16 → CDKN2A (New name for p16)
- p 15
- 17 p 18

Remember

HPV blocks CDKN1 family levels of P16 increase to keep cyclin D under control p16 is a surrogate marker of HPV infection

Applied aspects of cell cycle regulators 00:29:50

i. Deletion of p16/CDKN2A →

No p16
↓
Cyclin D active
↓
Rb → Ⓟ, Ⓟ —EF-2→ Cells divide extensively → Cancer

- Remember:
  - Most common tumor suppressor gene mutated in pancreatic cancer = p16
  - Most common oncogene mutated in pancreatic cancer – RAS

ii. Deletion of Rb gene

a) Retinoblastoma
↓ People
Very high risk of developing Osteosarcoma later in life

Tri radial retinoblastoma = retinoblastoma + Pineoblastoma

b) Small cell carcinoma of lung (loss of Rb gene)

- Remember
  - Most common tumor suppressor gene affected in small cell Ca lung → Rb
  - Most common Oncogene mutated in small cell Ca lung → LMIK

AfraTafreeh.com

AfraTafreeh.com

c) HPV → E7

⊖ ↓

Rb

Simian virus 40 (virus of mesothelioma)

↓ ⊖

Polyoma virus —⊖→ Rb ←⊖— E7 of HPV

↑ ⊖

Adenovirus (EIA antigen)

Updates 00:43:07

- Rb gene has power of inducing histone methyltransferase
- Histone deacetylation (or)methylation blocks the gene
- If phosporus is removed form Rb gene, it immediately activates histone methyl transferases and deacetylases histone

↓

Transcription stops

TUTORIALS
LOGIN FOR SUCCESS

GENETIC BASICS OF CANCER – INTRODUCTION

Molecular basis of cancer-group of genes involved

00:00:05

- Protooncogenes
- tumor suppressor Genes
- apoptotic genes
- DNA Repair genes

Tumor suppressor genes

00:02:20

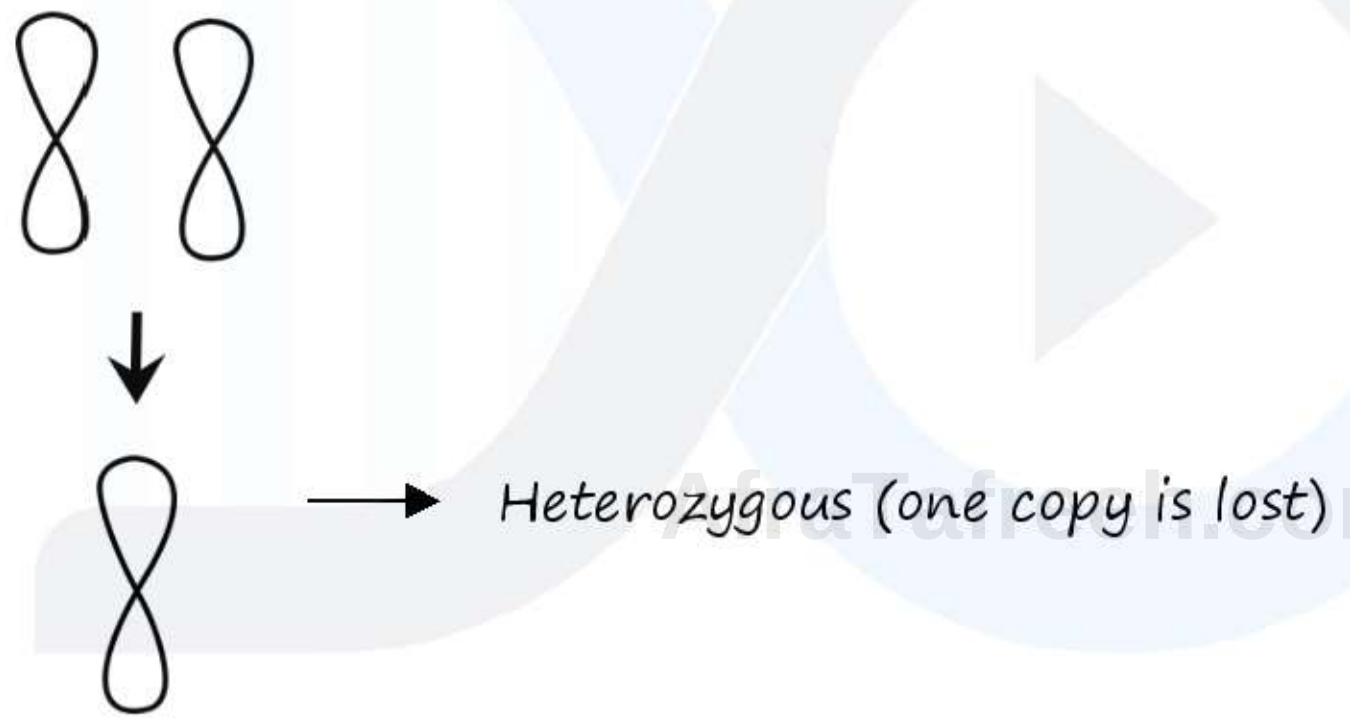

2nd HIT

Loss of heterozygosity → cancer (Both are lost either because of deletion or methylation)

- For tumor suppressor gene to cause cancer the main mechanism is loss of heterozygosity

Knudson two-hit hypothesis – two hit theory

00:03:00

- Hypothesis that most tumor suppressor genes require both alleles to be inactivated, either through

AfraTafreeh.com

mutations or through epigenetic silencing to cause a phenotypic change

- Majority of sporadic cancers require two hits to occur

Familiar cancers – people are born with first HIT, i.e one gene is already deleted or epigenetically modified

↓

They require just one more HIT to develop carcinomas

Example: Person born with only one copy of P53 are said to have Li Fraumeni syndrome

Proto-oncogenes 00:11:21

- Growth and development of cell
- Always under control by regulatory molecules

Proto-oncogenes —A/T/P→ Oncogenes → uncontrolled growth

(Controlled) (Uncontrolled)

A – Amplification

T – Translocation

P – Point mutation.

GENETIC BASIS OF CANCER PROTO ONCOGENES

PART – II

Signal Transduction Family 00:00:05

Signal Transduction Family

- GTP
- Tyrosine Kinase Family
- NOTCH
- JAK/STAT family

GTP-Family 00:01:41

FARNESYL Anchors attached to cell membrane

↓

GTP ← GDP

⊕

RAS

↓

BRAF	PI3 K
↓	↓
Nucleus	AKT
↓	↓
C–myc	mTOR
↓	↓
Proliferation	Protein synthesis increases cell size

AfraTafreeh.com
TUTORIALS
LOGIN FOR SUCCESS

- Proto-oncogene of GTP pathway → RAS

AfraTafreeh.com

- Proto-oncogene of RAS family is BRAF
- RAS → point mutation → oncogene → cancer
  - i. K-RAS – most important
  - ii. H-RAS → Bladder Ca
  - iii. N-RAS → Melanoma
  - iv. G NAS → Pituitary Adenomas
  - v. GNAQ → uveal melanoma
    - 1st proto-oncogene discovered was RAS
    - Most common Oncogene mutation

Cancer associated with K-RAS

- Lung Adeno Ca
- Colon Cancers
- Pancreatic Biliary Ca

TUTORIALS
LOGIN FOR SUCCESS

- BRAF – Proto oncogene of RAS family causes multiple tumors

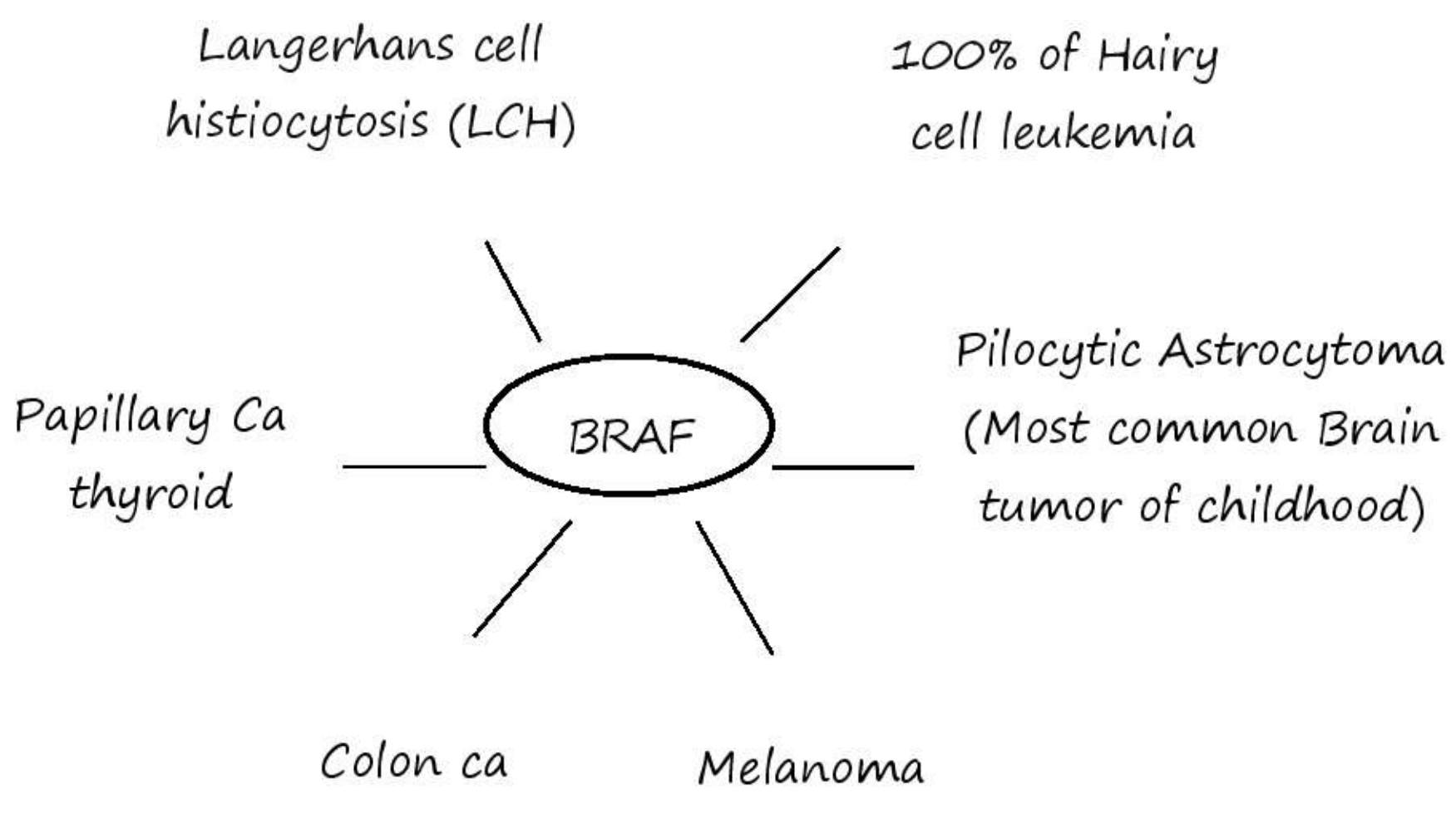

- Medullary Ca Thyroid – RET mutation (point mutation)
- Papillary Ca Thyroid – BRAF mutation (RET/PTC rearrangements)

Mutations in melanoma

i. BRAF

ii. CDKN2A/P16

iii. N-RAS

Regulations of GTP family 00:21:47

- GAP – GTPase activating protein

  ↓

  Activate GTPase

  ↓

  Breaks down GTP

  ↓

  RAS inactivated

  NF1 molecule acts a GAP molecule and blocks GTP.

- PTEN (second guardian of genome) → controls PI3K

  ↓

  Control proliferation

I. Tyrosine kinase family 00:25:19

– Translocation is the main phenomenon

- Non-receptor tyrosine kinase → protooncogene (abL)

  ↓

  (abL-bcr Translocation)

AfraTafreeh.com

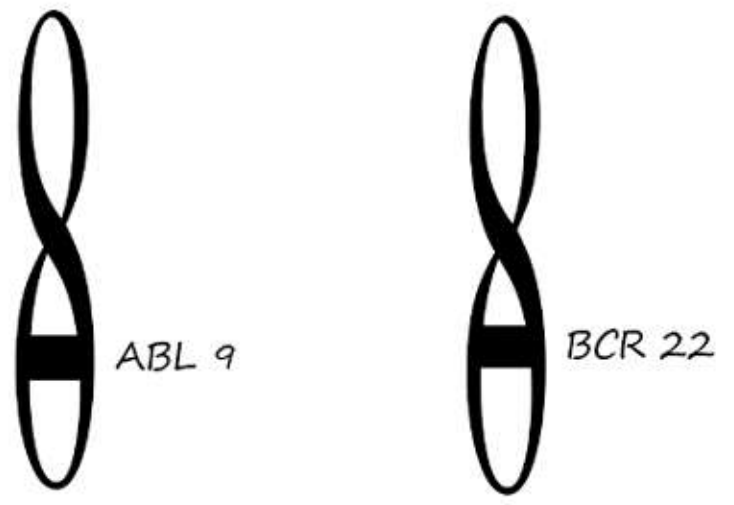

➔ Philadelphia chromosome

- Reciprocal translocation
- abL – bcr fusion gene produce transcripts of various sizes
- Rule of Thumb: smaller the size of the transcript → more the tyrosine kinase activity → more proliferation
- Size smallest 190 kDa → maximum Tyrosine kinase activity seen in ALL
- Bigger the size – 230 kDa – Lesser tyrosine kinase activity.

↓

CNL(chronic neutrophilic leukemia) has least proliferation-best

Prognosis

210 kDa – in CML

- Update – Gene identified with CNL – CSF3 R
- Drug of choice in CML – Tyrosine kinase inhibitor- imatinib

Oncogene addiction 00:31:55

- CML is addicted to oncogene abL – bcr induced Tyrosine Kinase for its proliferation.
- If you block tyrosine kinase by inhibitors – CML will disappear the phenomena is oncogene addiction.

II. JAK-STAT family 00:33:38

- Proto oncogene – JAK2 V617F – point mutation at position 617 valine changes to phenylalanine (point mutation)
- JAK-2 Belongs to family of janus kinase.
- This mutation results in multiple cancers

AfraTafreeh.com

Chronic myeloproliferative neoplasms (CMPN)

- CML
  - ↓ Abl-Bcr translocation
- Polycythemia vera (PV)
- Essential thrombocytosis
- Primary myelofibrosis

Due to JAK2 mutation

- 95% of PV have JAK2 mutation.

AfraTafreeh.com

III. NOTCH Pathway 00:38:30

- Either point mutation or Translocation
- Usually associated with T cell leukemia
- In majority of hematological neoplasms, protoncogene to oncogene conversion occurs by translocation

TUTORIALS
LOGIN FOR SUCCESS

PROTO PART – III

Transcrition Activators 00:00:05

- Most important mediator is Myc

Myc

C N L

- These transcription activators can immediately start transcription by themselves i.e., they can immediately cause proliferation by themselves
- Tumors with Myc mutation have maximum proliferation

AfraTafreeh.com

I. C – MYC

- Precast on chr8

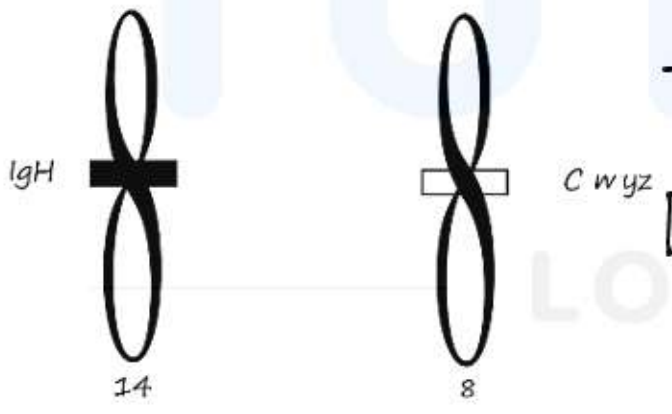

Translocation [Cmyc-IgH] → C-myc activated

↓

Proliferation

↓

Burkitt's Lymphoma

- Chromosome 14 has immunoglobulin heavy chain
- Most common mutation in Burkitt's Lymphoma is t(8,14)

AfraTafreeh.com

- Other mutation in Burkitt's are

T(2,8) chromosome t(2, 22) rare

immunoglobulin light chain

T(8,22)

- Hallmark gene of Burkitt's Lymphoma is c-myc

↓

Transcription activator

↓

Mitotic activity in Burkitt's is 100%

- Because this tumor arises in the germinal center there is no BcL2, This implies that apoptotic activity is high
- Characteristic

i. High proliferative index

ii. High apoptotic activity

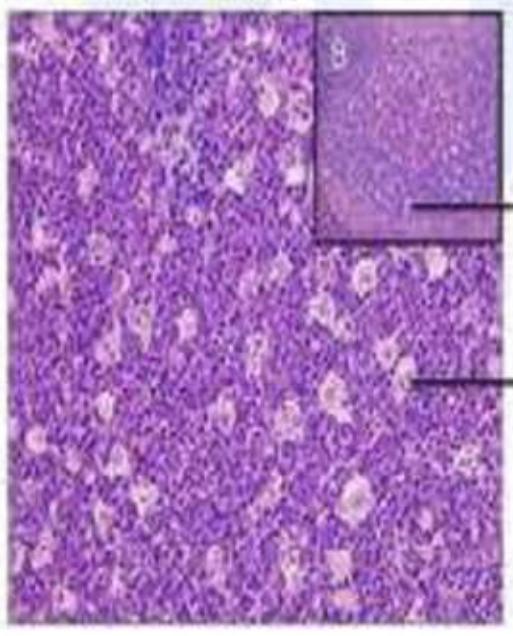

Error! Not a valid embedded object. Fig: 1

- Due to lack of Bcl-2 Apoptosis → Microphages come to clear

↓

Tumor cell debris + foamy cytoplasm

↓

Starry sky appearance

- Starry – Macrophages
- Sky-Small round blue tumor cells
- Chemosensitive tumor – 1st leukemia/lymphoma treated by chemotherapy
- Bad prognosis
- Burkitt lymphoma is usually associated with EBV

t(8,14) → Activation of c-myc
t(2,8) → Activation of c-myc
t(8,22) → Activation of c-myc

II. N-MYC

- Seen in neuroblastoma

N myc
↓ amplified
Poor prognosis in Neuroblastoma

III. L-Myc —amplification→ small cell ca lung

AfraTafreeh.com
TUTORIALS
LOGIN FOR SUCCESS

C-myc —translocation→ oncogene

N-myc, L-myc —amplification→ oncogene

AfraTafreeh.com

IV. Recent updates

Newer transcription activators

REL → Hodgkin's lymphoma

FOS, C jun → leukemia/lymphoma

Cell Cycle Family 00:13:33

cell cycle family

- Cyclin D
- CDK4 → Glioma

Cyclin D present on chr 11 → t(11,14) → 1) Mantle cell lymphoma 2) Myeloma

Chr 14 IgH + → chr 8 (C-myc) → Burkitt

Chr 14 → chr 11 (Cyclin D_1) → Mantle cell lymphoma, myeloma.

Protoncogenes	Amplification	Translocation	Point mutation
GF	All G factors		
GFR	EGFR β2	ALK(ALCL)	KIT, RET, ALK, ErbB
Signal TP		abL	RAS, BRAF, B catenin, JAK2, NOTCH
TA	N myc, L myc	C myc	
Cell cycle		Cyclin D	

Revision

AfraTafreen.com
TUTORIALS
LOGIN FOR SUCCESS

AfraTafreeh.com

APOPTOTIC GENES AND DNA REPAIR GENES

I. BCL_2 00:00:05

- Anti-apoptotic
- Coded by chromosome 18

Germinal center(GC) – No BCL2

If- t(14,18)

(IgH activates BCL2)

↓

Germinal center start expressing BCL2

↓

Proliferation of B cells GC enlarged

↓

Follicular lymphoma

t(14,18)→ Follicular lymphoma

↓

Confirm by IHC

BCL2 tagged with DAB

Update: Epigenetic change in follicular lymphoma

↓

MLL2 (Histone Methyl transferase)

II.MCL-1 00:07:02

- Behave like BCL2
- Mutation seen in mantle cell lymphoma

Chromosome 14
- → 8 → Burkitt's lymphoma (C-Myc)
- → 11 → Mantle cell lymphoma (Cyclin D1)
- → 18 → Follicular lymphoma (BCL2)

AfraTafreeh.com
TUTORIALS
LOGIN FOR SUCCESS

AfraTafreeh.com

REPAIR AND REGENERATION AND THEIR DISORDERS

Regeneration: 00:00:30

- It is the process of proliferation of cells
- Replacing dead cells with no scar formation
- It is commonly seen in skin cells

Repair:

- Tissue regeneration at site of injury leading to scar
- Hallmark of repair is granulation tissue
- Alternatively activated macrophages are activated and cause formation of granulation tissue
- Granulation tissue is made up of proliferating blood vessels, extracellular matrix, alternatively activated macrophages
- Neonatal wounds have no scars

TUTORIALS
LOGIN FOR SUCCESS

Regeneration: Three type of cells 00:02:52

Labile	Stable	Permanent
i. All types Epithelium has labile cells ii. In constant pool of proliferation whenever needed	i. Liver ii. Pancreas iii. Kidney iv. Liver shows maximum number of stable cells v. Stable cells are in resting G_0 phase of cell cycle, on stimuli they move in the multiplying phase of cell	i. Permanent cells show only repair, No regeneration ii. It is associated with scarring Example: • neuron • Cardiac cells

Repair 00:06:47

Wound healing

I. Primary intention
- Surgical incision
- Clean cut wound with opposed edges
- No wound contraction

II. Secondary intention
- Large gaping wound
- Loss of tissue
- Activation of myofibroblasts (has power of muscle) cause wound contraction

DOC TUTORIALS LOGIN FOR SUCCESS

AfraTafreeh.com

- Then wound undergoes abnormal contraction leading to ugly scar formation

Chronology of injury 00:10:00

- Day 0 – Platelets appear at site of injury and forms clot
- 24 hours – Neutrophils appear
  - 1-3 day: a thin layer of epithelium is formed
- By Day 3: -
  - **Macrophages** replace neutrophils [Alternatively activated]
  - Macrophages stimulate **angiogenesis** by releasing IL-10 and TGF β
  - TGF β also activates **collagen (Type III)**
  - This collagen type III is vertically oriented, does not bridge the gap
  - Granulation tissue form which is made of Alternatively activated macrophages
  - Granulation tissue starts appearing on day 3

> Exception: granulation tissue in heart appears on day 7

- Day 5: - Full epithelial thickness is regained
  - Maximum angiogenesis appears
  - Maximum granulation tissue is formed

- Collagen becomes horizontally arranged and bridges the gap edge of the wound

- Day 14:
  - Blanching appears due to disappearance in inflammation
  - Fibroblast proliferation occurs
- Day 30:
  - Collagen I replace collagen III
  - Dermal appendages are lost forever

Strength of wound

- Suture gives **80%** strength of wound
- After 1-week suture removed 10% strength of wound remains
- 70-80% of original strength achieved **after 3 months**
- 100% of original strength never achieved
- Enzymes involved in remodeling are **matrix metalloproteinases (MMP)**
- MMP are zinc dependent enzymes – these enzymes break down ECM
- Types of MMP

  1.Collagenases

  2.Stromelysins

AfraTafreeh.com
TUTORIALS
LOGIN FOR SUCCESS

AfraTafreeh.com

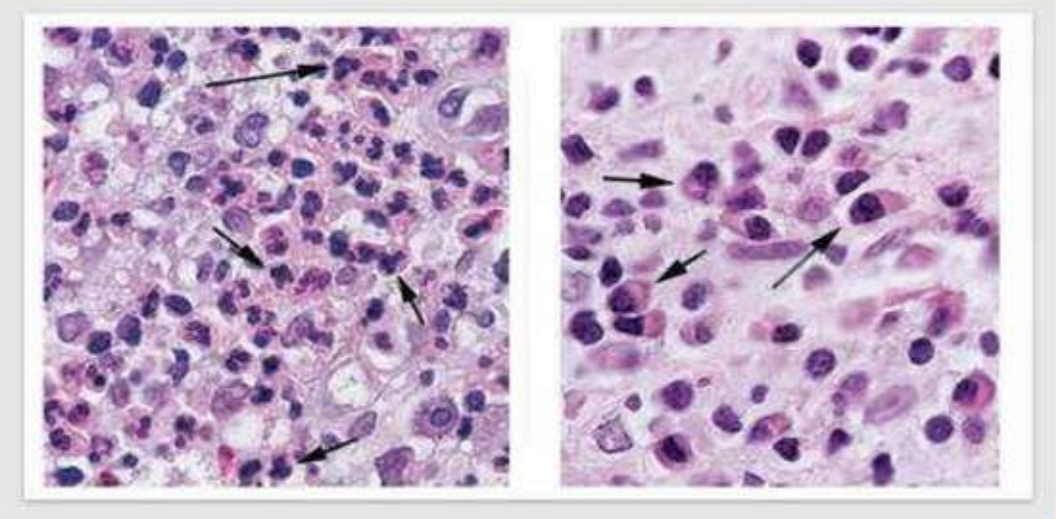

Fig: 1

Factors helping in proliferation of blood vessels	Factors stabilizing blood vessels
F – Fibroblast growth factor [FGF] A – Angiopoietin V – VEGF (Vascular endothelial growth factor)	P -PDGF (Platelet derived growth factor) T-TGF β

Errors of wound healing 00:30:50

I. Granulation tissue error

a)Granulation tissue not formed wound does not close

b)Excess granulation tissue is called **proud flesh**

Proud flesh – Granulation tissue grows excessively and comes to the level of epithelium wound is unable to epithelialize

- Treatment is by cautery

II. Collagen

- Type III collagen is involved in wound healing
- Excess collagen limited to cut wound – **Hypertrophic scar** seen in LSCS scar
- Excess collagen invading surrounding tissue – **keloid**

- It is genetically associated
- It is more common blanks
- Most common site sternum, ear lobes
- Special stain of collagen is masson trichome
  - Blue color – Indicates collagen
  - Red color – Indicates Muscle
  - Black color – Indicates Nucleus

Fig: 2

Fibroblasts

AfraTafreeh.com

- Excessive proliferation of fibroblasts forms desmoid.

Kelo id

Proud flesh

Fig: 3

Factors delay wound healing

- Foreign body

AfraTafreeh.com

- Site of injury – like joints – movement of joint hiders wound healing
- Size of wound – large wound healing size delays healing
- Infection
- Steroids reduces immunity
- Zinc deficiency leads to MMP deficiency which is involved in wound healing
- Vitamin C deficiency delays healing as it causes hydroxylation of lysine and proline in collagen
- Diabetes mellitus.

TUTORIALS
LOGIN FOR SUCCESS

GENETIC BASIS OF CANCER – TUMOR SUPPRESSOR GENES PART-II

Nuclear Tumor suppressor genes 00:00:05

I. Rb

II. P53

III. P16

IV. BRCA 1 and 2

V. WT_1

VI. MEN-1

I. Rb gene – first tumor suppressor gene to be found
governor of the cell – on and off gene of the cell

AfraTafreeh.com

II. P53 – most common gene mutated in sporadic cancers

Because of deletion of p53 – Breast cancer
Brain tumors – 2° Glioblastoma
Soft tissue tumors

III. P16 – CDKN2A → mutation results in melanoma, Pancreatic cancer, Squamous cell carcinoma lung

IV. BRCA 1 and 2

- BRCA very important regulator of G2M phase
- G2M controlled by
  - i. P53
  - ii. BRCA
  - iii. ATM

AfraTafreeh.com

- BRCA is a DNA repair tumor suppressor gene

BRCA 1	BRCA 2
i. Chromosome 17q ii. Most commonly associated with Hereditary breast cancer iii. Causes triple negative i.e., ER,PR and Her-2 Negative breast cancers or medullary type of breast cancers iv. Ovarian tumor BRCA1 > BRCA2 serous ovarian cancers	i. Chromosome 13q ii. Male breast cancer BRCA2 iii. Prostate ca } BRCA2 iv. Pancreatic ca } BRCA2 v. CLL } BRCA2 vi. Acute leukemia } BRCA2 vii. Luminal B type breast ca [ER,PR Positive]

Remember-Lobular carcinoma of breast – due to loss of CDH1

V. WT_1 gene

i. Present on chromosome 11p13

ii. Helps in mesenchyme to epithelial transition especially, in kidney

iii. Renal and gonadal development

iv. WAGR Syndrome Denys Drash tumors due to mutation in WT-1 gene have renal and gonadal abnormalities

v. WT-1 mutation → wilm's tumor

DOT TUTORIALS LOGIN FOR SUCCESS

vi. In hematopoietic stem cells, WT1 is never present but if WT1 expression occurs. It can causes acute leukemia's

vii. In case of hematopoietic stem cells, WT1 can act as oncogene. While it is a tumor suppressor gene in kidney and gonads

VI. MEN-1

↓

Protein – menin

- MEN 1 Syndrome – Mutation of tumor suppressor gene

  MEN-1 which codes for menin

- MEN 2 Syndrome – Mutation of a RET gene, RET gene is a proto oncogene
  - MEN-1 → Due to mutation of tumor suppressor gene MEN-1
  - MEN-2 → Due to mutation of proto-oncogene RET

AllAtafreeh.com
TUTORIALS
LOGIN FOR SUCCESS

Location of genes – Revision 00:19:15

BRCA 1 – 17q	NF1 – 17q Caspase 1 and 11 → activate apoptosis	P53 – 17p
BRCA 2 – 13q	NF2 – 22q	Rb – 13q
		VHL – 3P

AfraTafreeh.com

GENETIC BASIS OF CANCER – TUMOR SUPPRESSOR GENES – PART – I

Cytoplasm

i. APC

ii. SMAD 2&4

iii. STK-11

iv. PATCHED

v. PTEN

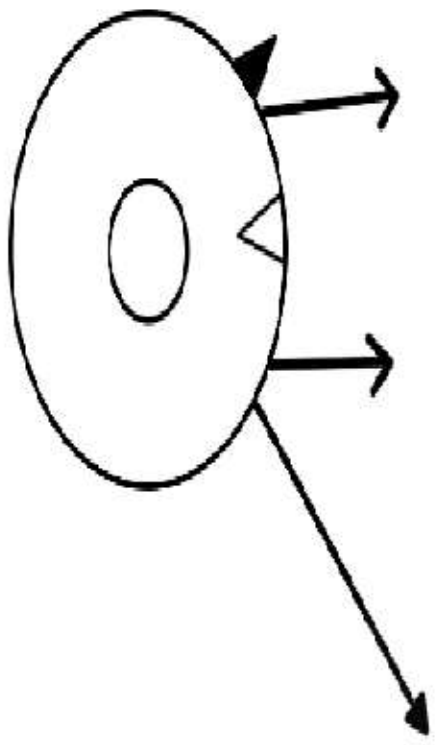

On outer surface of cell membrane

CDHI, TGF β codes for E – cadherin contact inhibition

NF1 (present on inner side of membrane)

NF2 (present in cytoskeleton)

I. CDH1 00:00:30

CDH 1 codes for → E cadherin → contact inhibition

- Mutation of CDH1 → Loss of contact inhibition
- Loss of E-cadherin is a very common passenger mutation for metastasis

Loss of CDH1 is driver mutation for

Diffuse Gastric Carcinoma

i. Loss of contact inhibition

ii. Mucin within cells, Nucleus Pushed to periphery

a. Signet Ring Cells

iii. Infiltrate walls of stomach

↓

Extensive fibrosis 'Desmoplasia'

↓

Linitis Plastica (or) Leather Bottle stomach

Lobular Carcinoma Breast

i. Usually Bilateral

ii. Linear arrangement of cells

iii. Loss of contact inhibition – Indian File pattern

iv. Targetoid mucin or Bulls eye appearance

v. Prognosis – Good ER PR.+ ve

II. TGF – β 00:11:56

- Now called as pleiotropic' gene

↓

One gene has multiple effects

- TGF – β is a growth factor but not a proto – oncogenes

Functions –

AfraTafreeh.com

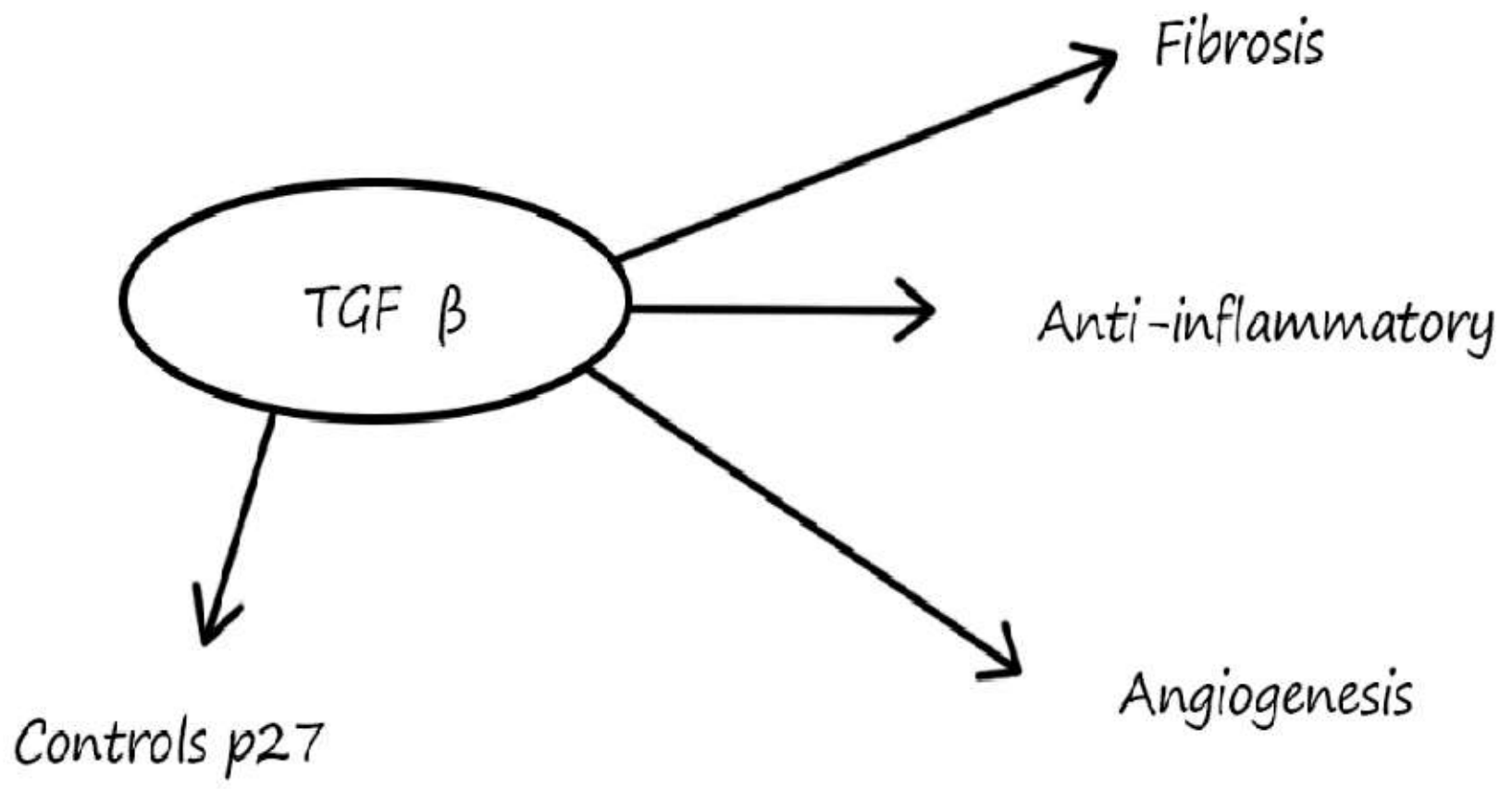

- TGF – β is a 'double edged sword' depending on the situation it can either stop or promote the growth of the tumor by facilitating Angiogenesis
- TGF – β mutations are common in colon cancers.

NF1 & NF2 00:15:30

NF 1	Acts like a GAP – RAS
NF2	Provides Cytoskeletal stability

III.

- NF1 code Neuro fibrin → mutation causes neurofibroma & MPNST (Malignant Peripheral Nerve Sheath Tumors)
- NF2 codes for Merlin → Mutation causes
↓
Schwannoma, Ependymoma, Meningioma

NF1	NF2
Chr17q	Chr 22q

IV.APC 00:21:35

- Present on Chr5
- Called as gatekeeper of colonic proliferation

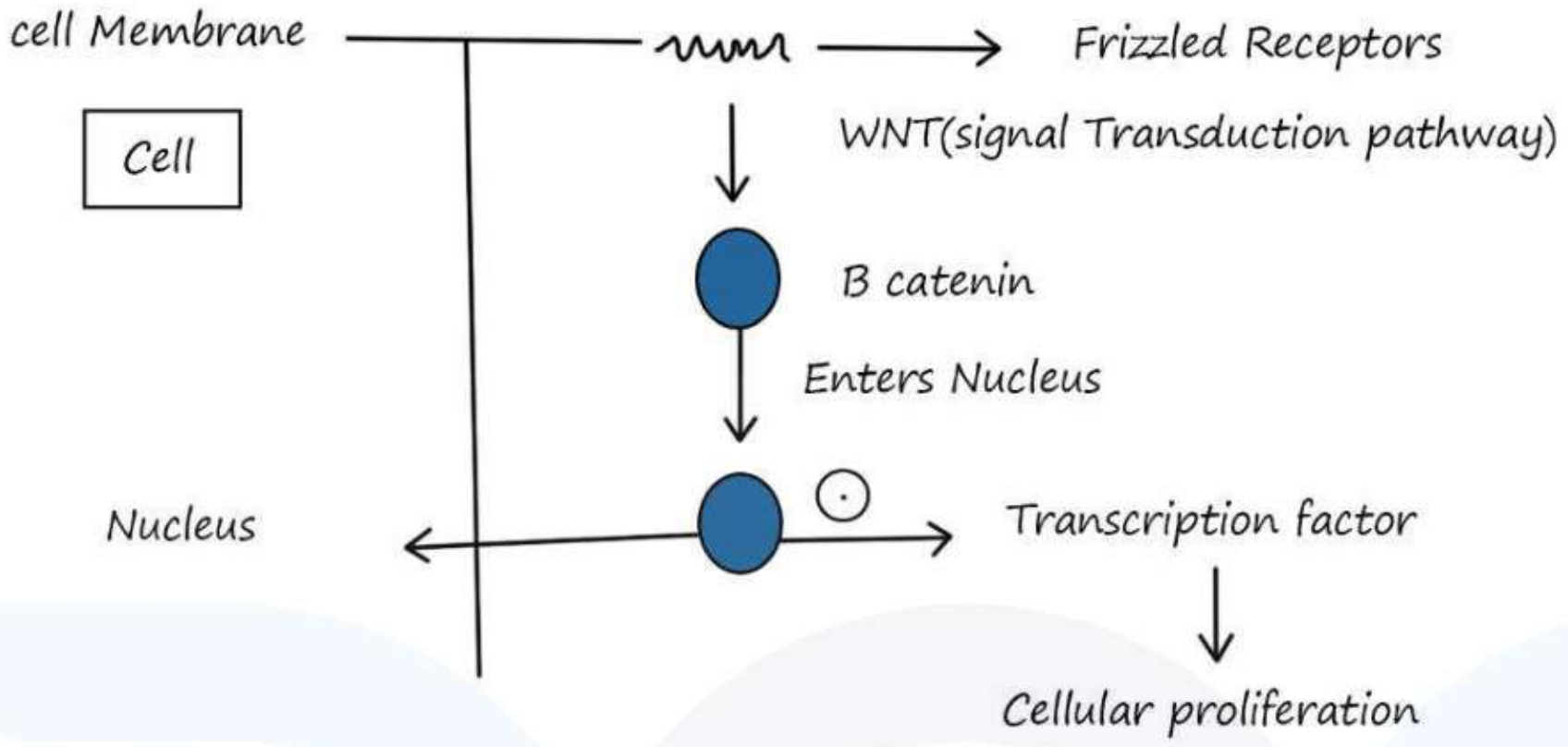

- When the gatekeeper of colonic proliferation (If APC is deleted Beta catenin not broken) → hyperplasia → polyp → Adenoma → Carcinoma

Adenoma Carcinoma sequence

β – catenin → point mutation

↓

Enters nucleus

↓

Keeps including TCF

↓

Proliferation

- APC can't break mutated β – catenin
- So, point mutation β catenin can also cause cancers
  – approximately 50% of hepatoblastoma & 20% of HCC have point

AfraTafreeh.com

AfraTafreeh.com

Loss of APC → Colon

point mutation of β – catenin →
- Hepatblastoma
- HCC

- Mutation of β catenin can be deleted by IHC
- Normally β catenin present in cytoplasm

V. SMAD 2 & 4 00:30:11

- Major TGF β pathway controllers
- Loss of SMAD causes excessive proliferation

↓

Can causes juvenile polyps

VI. STK – 11 00:30:59

- Also known as LKB1 very important metabolic controller
- Mutation of STK 11 → peutz jegher syndrome

VII. PTEN 00:31:51

- Major controller of → PT3K

↓

AKT

↓

MTOR

↓

Protein synthesis cell proliferation

- PTEN controls PI3 kinase pathway

  ↓

  Second guardian of Genome

- Mutation of PTEN – Cowden Syndrome

  (mneumonic – BET)

Breast Ca^{+2}	Endometrial cancer	Thyroid Cancer

Polyps of Intestine 00:33:55

Neo plastic

- FAP
- Sessile Serrated Adenoma (SSA)

AfraTafreeh.com

- Non – Neoplastic

  i. Inflammatory → Usually occurs in rectum

  ii. Hyperplastic polyp

  iii. Hamartomatous polyps

AfraTafreeh.com

Hamartomatous polyps

Peutz Jegher's syndrome	Juvenile adenomatous polyposis
i. Smooth muscle extends into the superficial epithelial layer in a tree like manner known as arbotization	i. Not hereditary. It is acquired
ii. Mutation of STK11	ii. >50 year
iii. Most common site jejunum	iii. Alopecia, skin pigmentary changes, nail atrophy (onycho dystrophy)
iv. Polyposis develops by age 20	iv. M/C symptom is Diarrhea
v. Associated with hypermelanotic macule l peri-oral region, buccal mucosa	v. M/C site of polyp – stomach
	vi. Polyps are found throughout GIT w/Characteristics oesophageal sparing

- Neoplastic polyp
- Familial adenomatous polyposis
- APC mutations on long arm of chromosome 5q 21

2FAP syndromes

Gardner's	Turcot's
i. Supernumary teeth	i. Brain tumors Typically, medulla blastoma (mneumonic tumor in turban)
ii. Osteomas	ii. Turcot syndrome falls into two groups based on their types of brain tumor and genetic alternation
iii. CHRPE	

- Medulloblastoma in FAP
- Gioblastoma multiforme in HNPCC

- Remember turban tumors is cylindroma

PATCHED gene 00:45:27

- Controls hedgehog pathway → very important pathway
- Helps in morphogenesis of brain and skin

If loss of patched gene

↓

Hedgehog pathway uncontrolled

↓

Excessive proliferation of brain cells and skin cells

↓

Brain tumors esp – medulloblastoma & multiple basal cell carcinomas

AfraTafreeh.com
TUTORIALS
LOGIN FOR SUCCESS

AfraTafreeh.com

GENETICS BASIS OF CANCER-ANGIOGENESIS GENES-VHL, ENERGY AND ONCOMETABOLISM

I- Angiogenesis 00:06:10

- No tumor can grow more than 1-2 mm in size without its own vascular supply or angiogenesis

Hypoxia

↓

HIF 1alpha (Hypoxia inducible factor 1 alpha)

↓

HIF 1 alpha Induces VEGF in nucleus

↓

Angiogenesis

- HIF 1alpha → Erythropoietin → increase RBC count

Angiogenesis + increase RBC count

↓

Normal O_2

↓

Tumor suppressor gene VHL (Von Hippel Lindau) produced

↓

Breaks HIF 1 alpha

↓

Angiogenesis stops

VHL is a tumor suppressor gene which controls angiogenesis

VHL – Chromosome 3p

If VHL deleted → no break on HIF 1 alpha

↓

Increase Angiogenesis -multiple cancers

Most common cancer due to deletion of VHL

Hemangioblastoma

↓

Cerebellar tumor with increased vascularity

1) Renal cell carcinoma – clear cell type
2) Pheochromocytoma
3) Endolymphatic sac tumors
4) Liver cysts and pancreatic cysts

Pro-angiogenic molecules	**Anti-angiogenic molecules**
- VEGF	-Thrombospondin
- TGFβ	-Endostatin
- FGF	-Angiostatin

AfraTafreeh.com
TUTORIALS
LOGIN FOR SUCCESS

- Thrombospondin coats tumor cells → macrophages come and kill the tumor cells thrombospondin server as 'EAT ME' signal
- NOTCH pathway – helps in proper sprouting of blood vessels

II- Energy

Energy
- Warburg hypothesis
- autophagy

AfraTafreeh.com

i. Warburg hypothesis 00:08:55

- Tumor cells are glucose hungry they always prefer **aerobic glycolysis** the metabolites produced are used for growth and development of tumor cells
- This phenomenon was studied by otto Warburg and called Warburg effect
- He invented PET scan on this basis
- Inject 18FDG – Fluro deoxy Glucose preferentially taken up more at tumor sites

  i. Helps in finding extent of metastasis

  ii. To check for residual tumor

ii. Autophagy 00:12:22

- Tumor cells can eat up other cells to derive energy

Tumor cells can either

Increase Autophagy And go into a state Dormancy	decrease Autophagy when it is induced by tumor suppressor genes

Genes controlling energy

i. STK11 – Mutation → Peutz jegher's syndrome

ii. PI3K pathway – kept under control by PTEN gene deletion of PTEN – Cowden syndrome

Update:

Oncometabolism 00:16:17

i.

Isocitrate dehydrogenase(IDH)	Mutated IDH
↓ Product A ↓ Produced normally	↓ Product B ↓ Used by tumor cells

IDH mutations

- Most common oligodendroglioma-approximately 90% have the mutation
- Secondary glioblastoma
- Acute myeloid leukemia(AML)
- Cholangiocarcinoma

ii. Succinyl dehydrogenase mutation (SDH)

↓

Seen in childhood GIST, paraganglioma, pheochromocytoma

(Remember – Adult GIST most common mutation – KIT)

iii. Fumarate hydratase (FH) mutation

↓

Hereditary leiomyomatosis, renal cell carcinoma syndrome (papillary RCC with multiple leiomyomas).

AfraTafreeh.com

GENETIC BASIS OF CANCER – METASTASIS AND ESCAPING IMMUNITY AND DEATH AND RECAP

Steps of Metastasis 00:00:05

- Detachment of tumor cells

i. Loss of E-cadherin (cell adhesion molecule)-loss of contact inhibition

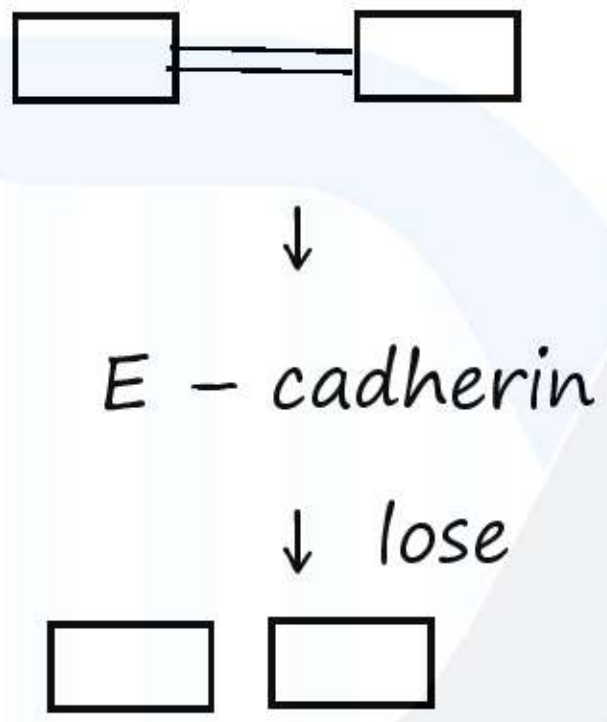

- Loss of contact inhibition → metastasis
- Seen in
  - Diffuse gastric cancer
  - Lobular carcinoma breast

ii. Loss of anoikis

- Hemidesmosomes (attaches basal layer cells to B.M)

  Anoikis – Detached cells are killed by programmed cell death

  Loss of anoikis = detached cell not killed → metastasize

iii. Epithelial mesenchymal transition (EMT)

Epithelial cell → Mesenchymal cell (Pro migratory phenotype)

- Metastatic oncogenes promote EMT
- Metastatic oncogenes

i. EZRIN gene (involved in Rhabdomyosarcoma and osteosarcoma)

ii. SNAIL and TWIST (Breast cancer)

iv. Extra cellular matrix degradation

Tumor cells manipulate macrophage

↓

Activated macrophage secrete

- Matrix metalloproteinases (MMP) [MMP2 and 9]
- Cathepsin
- Urokinase plasminogen activator
- MMP 2 and MMP 9 (9>2) are very important for degrading extracellular matrix

  Integrins over tumor cells stick to extracellular matrix

  Proteins (fibronectin) and move by active polymerization

v. Intravasation – Mesenchymal cells infiltrate blood vessel

TUTORIALS
LOGIN FOR SUCCESS

AfraTafreeh.com

vi. Circulation

Circulation

As tumor embolus circulates

hide behind platelets and

-preferred route of spread

-evades immune system

- Tumor cells expressing chemokines lodge in tissues expressing complementary chemokines receptor
- CD44 has very high affinity for hyaluronic acid present in high end venules of lymph nodes
- So CD44 helps in lymphatic metastatic

  Chemokines CXCR4, CCR7 – Breast cancer metastasis

  Tissues where metastasis does not occur skeletal muscles > spleen

vii. Final step → extravasation and lodgement

- Metastasis are mostly lodged to periphery of the organ since hemodynamics [blood velocity] is slower and extravasation cause at metastatic tumor cells survive on feeder vessels of the organ
- So tumor grows concentrically around a blood vessel
- There by metastatic are well defined around a feeder vessel
- Treatment – embolization of feeder vessel.

Escape 00:14:49

Tumor cells have escape

- Immunity
- death

Escaping immunity

- Tumor cells activate T regulatory cells which suppresses immunity
- They express PDL1 and mimic self, cell, since monocytes also express PDL1

Tumor cells ← PDL1 → ✕ T cells

↓ PDL1

Suppress immunity

AfraTafreeh.com

- 2018 NOBEL PRIZE – anti PDL1 therapy → kills tumor cells
- Cancer cells express galectin and suppress immunity
- From antigen negative clones

Escaping death 00:18:50

I. Limitless replicative potential – Telomerase expression telomerase in RNA dependent DNA polymerase (Reverse transcriptase) which is normally expressed in

i. Germ cells (Maximum activity of telomerase is seen)

ii. Stem cells

AfraTafreeh.com

- Telomerase are not active in normal somatic cells they die after fixed number replication

Somatic cells replication

↓

Telomere shattering

↓

Check point p53 or RB

Activated

↓

Cell cycle arrest

Cellular senescence)

Non-activated/mutated

↓

Non homologous end joining pathway (NHEJ)

↓

Forms dicentric chromosome

↓

During mitosis more random freaks are formed

↓

More dicentric chromosome formation

↓

Many cycles of **Break-Bridge-Break Cycle**

↓

Induces chromosomal instability and mutation

No telomerase

↓

Mitotic crises/mitotic catastrophe and death

Telomerase expressed

↓

Escape break – Bridge-break cycle

↓

Tumorigenesis

II. TERT Gene can add telomeres

↓

Elongation of telomeres

Seen in primary glioblastoma

Longevity

- Cancer stem cells uniquely express MDR gene (Multi drug resistant)

↓

Show resistance to therapies

Cellular and molecular hallmarks of cancer

00:31:18

AfraTafreeh.com

TUTORIALS

LOGIN FOR SUCCESS

- Self-sufficiency in growth signals (proliferation without external stimuli)
- Insensitivity to growth – inhibitory singals (Resistant to tumor suppress genes)
- Evasion of apoptosis
- Limitless replicative potential
- Angiogenesis
- Invasion and metastasis
- Ability to escape immune recognition and regulation
- Altered cellular metabolism (by aerobic glycolysis – Warburg effect).

AfraTafreeh.com

DIAGNOSIS OF CANCER PART – I

Diagnosis of cancer 00:00:05

- Symptoms
- serum markers
- FNAC
- biopsy
- molecular tests

I. Symptoms

- Cancer cachexia Manifestations
- ParaNeoplastic

Cancer cachexia Manifestations

↓

- Because of TNF
- Causes loss of both fat and proteins
- Body is in constant inflammatory state

↓ constant

- Free radical – injury

↓

- Lipofuscin pigment deposition (Peri nuclear)

Lipofuscin – Aging – protein energy malnutrition

Paraneoplastic syndromes (PNS) 00:03:10

- Manifestations which cannot be explained by tumor per se but they are associated with the tumor

Example:

1) Acanthosis nigricans – paraneoplastic manifestation of stomach cancer
2) Idiopathic migratory thrombophlebitis – trousseaus phenomena usually seen with pancreatic cancer
3) Most common paraneoplastic manifestation – Hypercalcemia most commonly seen with breast cancer
4) Lung cancer:

a) Showing hypercalcemia – squamous cell ca of lung

b) Amongst lung cancers maximum para neoplastic manifestations are seen with small cell carcinoma lung

- Most common is SIADH (Syndrome of Inappropriate ADH secretion)
- Cushing syndrome

c) Lung adenocarcinoma – Neurological PNS variant – Broncho alveolar carcinoma – precursor of adenocarcinoma – produces systemic sclerosis as paraneoplastic manifestation

> Note: Most common paraneoplastic endocrinopathy – cushing's syndrome
> Most common paraneoplastic syndrome – Hypercalcemia

AfraTafreeh.com

Hyperglycemia	Hypoglycemia
Osteosarcoma and chondrosarcomas	Fibrosarcoma

II. Serum markers 00:10:41

a) Oncofetal antigens

Fetal antigen present in fetal life expression in adult life indicates pathogenesis

- Alpha-Fetoprotein (AFP)
  ↓
  Increase AFP typically associated with
  1) HCC, Hepatoblastoma
  2) Yolk sac tumour
  Typical morphological features of tumours expressing increase AFP
  ↓
  Hyaline Globules
- CEA (Carcino-embryonic Antigen)
  ↓
  Increase CEA – Colon Cancers

Remember- Fibrolamellar variant of HCC has normal level of aFP Tumor marker present is Neurontin

Recent updates 00:13:58

a) Cancer Testis antigens

- Group of proteins united by their importance in development of cancer and in cancer immunotherapy
- Not present in adults

- They do not come out of the surface because MHC1 is not present on sperm cells
- In general expression of these proteins is restricted to male germ cells in the testis
- These antigens include MAGE antigen– **Melanoma antigen genes**

↓

Tumor specific (Present only in tumor) present in melanoma.

b)Carbohydrate antigens (CA)

- CA 125 → Surface ovarian tumors
- CA 19-9 → Pancreatic cancer
- CA 15-3 → Breast cancer
- CA 72-4 → Stomach cancer
- Ca 27-29 → recurrent breast cancer

c) Proteins

- Prostate specific antigens (PAS) – Prostate Cancers
- Immune globulins
- B_2 Microglobulins

(Immune globulins and B_2 Microglobulins } Multiple myeloma)

d) Enzymes

- Prostatic acid phosphatase → prostate cancer
- LDH (Marker of increased turnover) → seminoma
- Alkaline phosphatase – Osteosarcoma
- Tyrosinase – melanoma

AfraTafreeh.com

Hormones

1) Calcitonin – Medullary Ca thyroid
2) Vanillylmandelic acid – Pheochromocytoma
3) 5-H1AA – 5 Hydroxy indole acetic acid – Carcinoid
4) β HCG – Choriocarcinoma/seminoma

[Remember a-HCG is not a tumor marker]

Miscellaneous

1) PAX-8 gene expressed on thyroid and ovarian cells

So PAX -8 positive in thyroid cancer ovarian tumor

2) Oncotype DX – Molecular tumor marker of breast cancer
3) Melanoma – Most sensitive marker – S100, most specific – HMB 45
4) Mitf – 1 (Microphthalmia Transcription factor 1)
   → Tumor marker of choroid melanoma

TUTORIALS LOGIN FOR SUCCESS

Research markers

1) NMP 22-Bladder cancers
2) PCA 3 – (micro-RNA) – prostate cancer.

DIAGNOSIS OF CANCER PART – II FNAC

Cytological techniques for cancer 00:00:15

1) Exfoliative cytology – collection of shed cells

   Example: Pap smear, Broncho alveolar lavage, Gastric lavage

2) FNAC – Fine Needle Aspiration Cytology -for lumps

FNAC

Two types

- Aspiration (FNAC)
- Non aspiration type (FNNAC)

AfraTafreeh.com

Neddle-226-25G

- (Bigger the number → thinner the needle)25G for thyroid lesions because they are very vascular

Aspirate

↓

Immune directly spread on side

Air dried	Fix with 95% ethanol
↓	↓
GIEMSA stain	PAPANICOLAU stain (Nuclear morphology is better preserved)

AfraTafreeh.com

1) Aspiration cytology → only cells are aspirated, does not appreciate their relation with surrounding tissues like blood vessels
   - Vascular invasion or capsular invasion are not appreciated, so FNAC is non-diagnostic for follicular carcinoma of thyroid
2) Sites where FNAC should not be done
   i. Ovarian tumors → Risk of spillage and metastasis into peritoneum
   ii. Testicular tumors → Risk of metastasis to scrotal skin
   iii. Suspected hydatid cyst → Rupture can cause Anaphylaxis

Contraindications to FNAC 00:06:32

1. Unwilling patient
2. Bleeding diathesis
3. Skin infection at the site of FNAC
4. Liver hydatid disease
5. Testicular/ovarian malignancy.

TUTORIALS LOGIN FOR SUCCESS

DIAGNOSIS OF CANCER (PART –III) BIOPSY, SPECIAL STAINS AND IMMUNOHISTOCHEMISTRY

Biopsy 00:00:10

- Trucut biopsy – 14G/18G needle
- Shows relationship of cells with stroma

Biopsy

↓

Fixative 10% Buffered Neutral Formalin

Special stain

1. PAS-Positive tumor
   - Ewings sarcoma
   - HCC (rich in Glycogen)
2. Oil Red O / Sudan Black → Fatty tumors ↓ Lipoma liposarcoma
3. Masson fontana for melanin:
   - Melanin producing tumors
     Example: Melanoma
4. Masson Trichrome
   - Smooth muscle tumor
   - Leiomyoma, Leiomyosarcoma

Immune histochemical markers

i. CK (cytokeratins) → Carcinomas
ii. Vimentin → sarcoma
iii. Desmin → Skeletal muscle tumor
   - Rhabdomyoma
   - rhabdomyosarcoma
iv. NF → Neuronal tumors
v. GFAP → Gliomas

AfraTafreeh.com
TUTORIALS LOGIN FOR SUCCESS

Masson Trichrome

Collagen	muscle
↓	↓
Blue color	Red color

AfraTafreeh.com

Carcinoma CK

CK-7t

CK7+
CK20-
(anything above the colon)
Breast, Lung, stomach

CK7-
CK20+
Colon cancer

CK-20

CK 7-
Ck 20-
(do not follow the law of)
RCC, HCC

CK 7+
CK 20+
Bladder cancer

New IHC markers 00:06:51

- SOX 11 positive for mantle cell lymphoma
- HMB 45
  - Melanoma
  - PECOMAS
- S 100
  - LCH
  - Cartilaginous tumors
  - Neuronal tumors
  - Melanomas
- If β-Catenin present in cytoplasm then it is normal
- During mutation – β-Catenin is present in the nucleus example: HCC, Hepatic adenomas

DOC TUTORIALS LOGIN FOR SUCCESS

Electron microscopy in tumors

a. Cells rich in mitochondria – oncocytic cells – appear pink in color because of excess mitochondria tumors with cells rich in mitochondria

↓

ONCOCYTOMAS

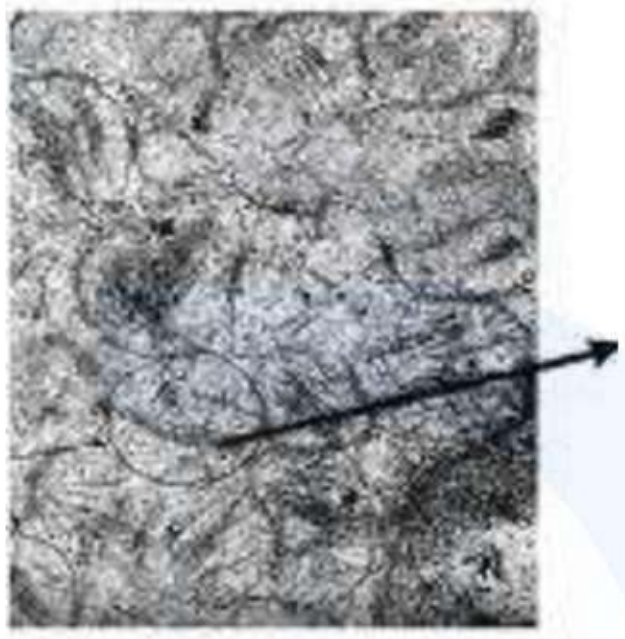

Mitochondrial

Long and thin microvilli
Seen in mesothelioma

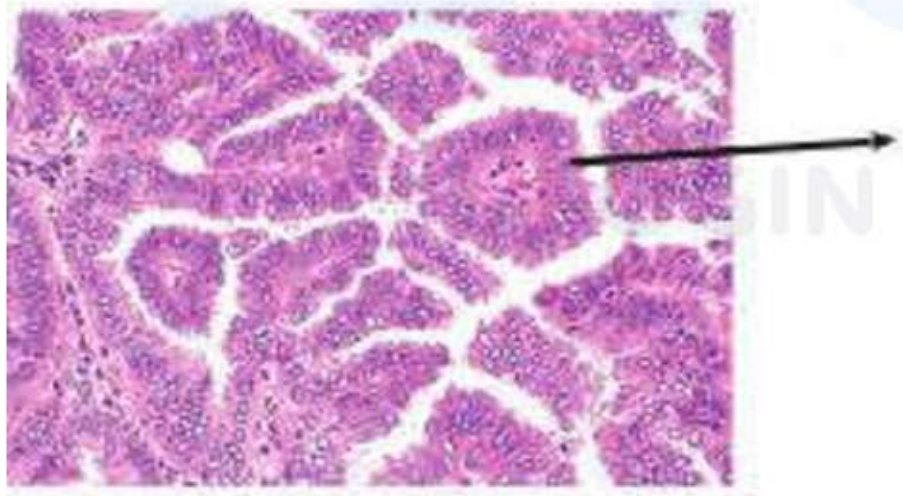

Short and stout microvilli
-Adenocarcinoma of lung

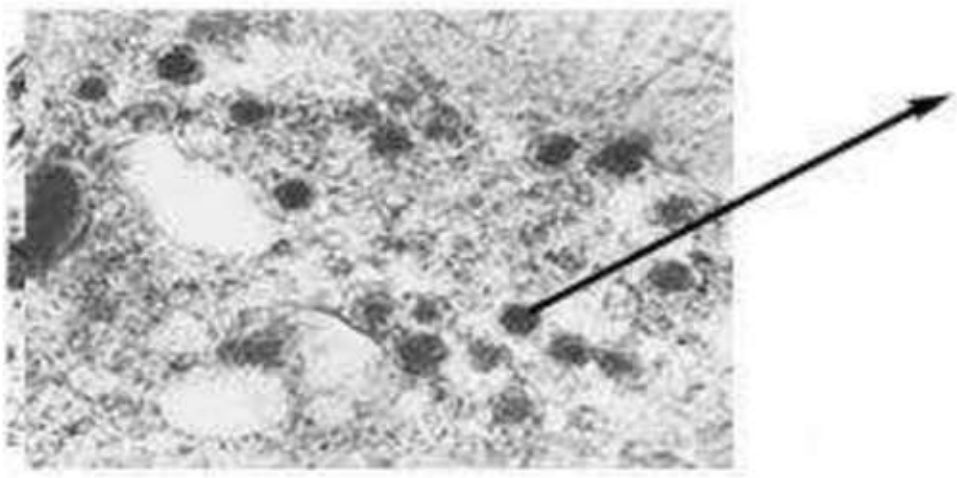

Dense core granules

↓

Typical of neuro endocrine tumors (NET)

AfraTafreeh.com

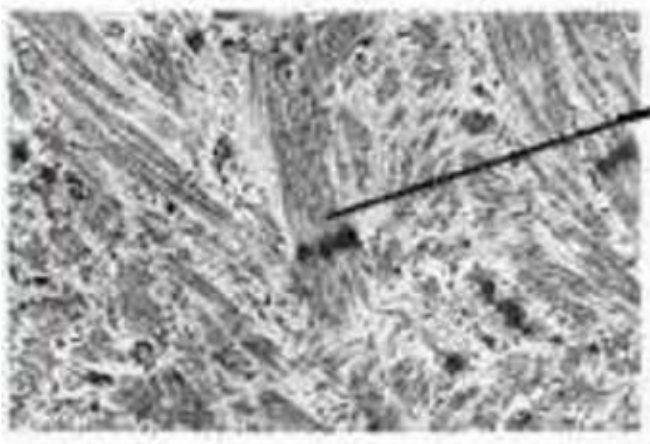

Striations in muscle → suggestive of skeletal muscle differentiation

↓

Rhabomyoma, rhabdomyosarcoma

Desmosome – seen in epithelial cells

↓

Squamous cell carcinoma

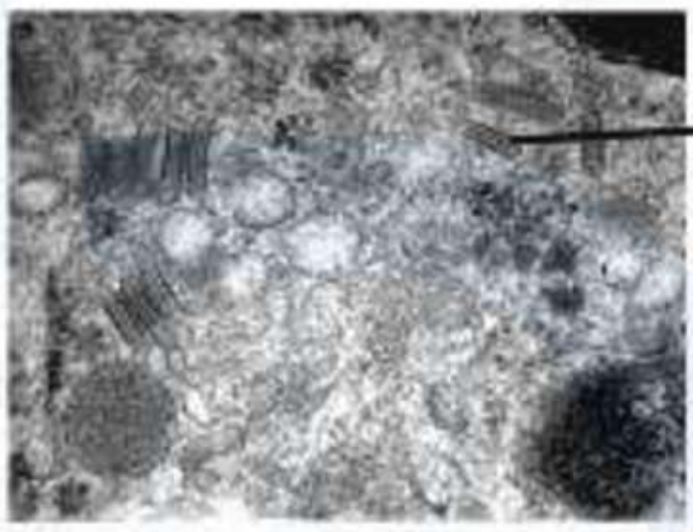

In Langerhans cells

Birbeck Granules

-seen on E.M

-Made of langerin protein

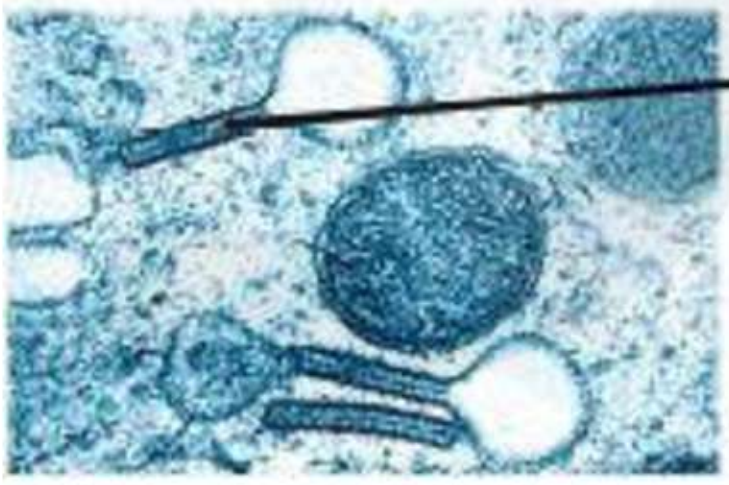

Penta laminar racket like structure with dilated terminal end [Tennis racket appearance of Birbeck Granules on E.M]

-seen in LCH (Langerhans cell Histiocytosis)

Remember

- Tennis Racket cells are seen in embryonal rhabdomyosarcoma involving vagina in <5year old
- Sarcoma botyroides has Tennis racket like cells known as Rhabdomyoblasts

Epigenetic changes 00:15:40

- MLL1 → Acute leukemia

  (Histone methyl transferase)
- MLL2 → Seen in follicular lymphoma
- P300 → Diffuse large B cell lymphoma (DLBCL).

AfraTafreeh.com
TUTORIALS
LOGIN FOR SUCCESS

AfraTafreeh.com

RECENT ADVANCES IN NEOPLASIA

Chromothyrpsis 00:00:30

- Means shattering of chromosomes
- Multiple breaks in chromosome

  ↓ DNA Repair enzymes activated

  Haphazard stitching leads to
- Activation of oncogenes
- Inactivation of tumor suppressor genes → cancer
- Can occur normally in 1% individuals
- 25% of osteosarcomas have chromothyrpsis, followed by Gliomas

iAMP21

- Type of ALL (Acute Lymphoblastic Leukemia) which typically occurs after chromothyrpsis

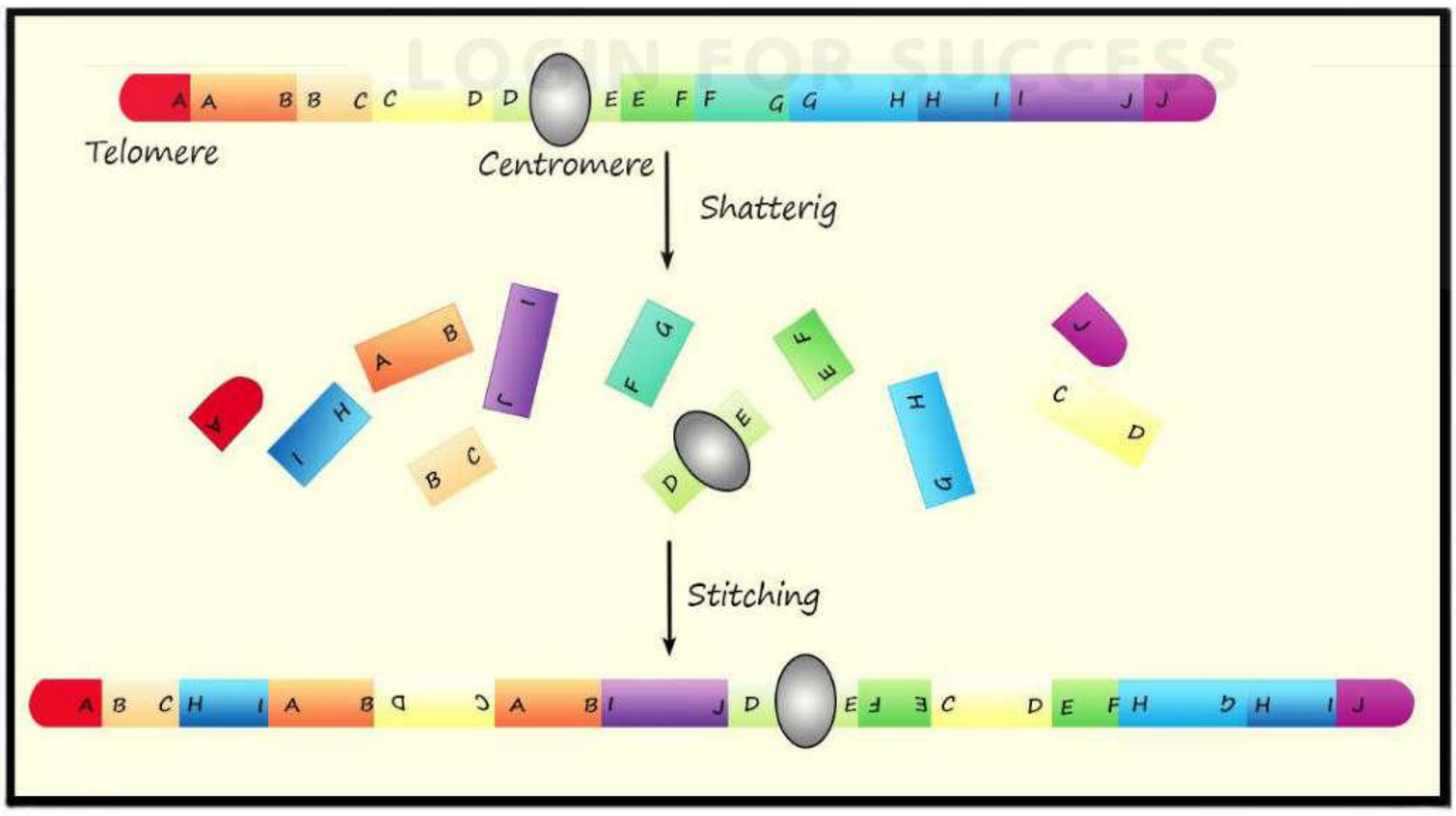

Fig: 1

Darwin's Hypothesis 00:06:00

- Survival of the fittest
- Tumor evolution also follows Darwin's Hypothesis

Driver mutation

Normal cell ⟶ cancer

↓ Multiple passenger mutations

Evolution of tumor

Gompertzian growth curve

- Tumor growth follows Gompertzian growth curve
- Normally tumor becomes detectable when lump appears usually at 10^9 cells(1g) → current threshold for clinical detection
- When cells become 10^{12} (1kg)→ death ensures

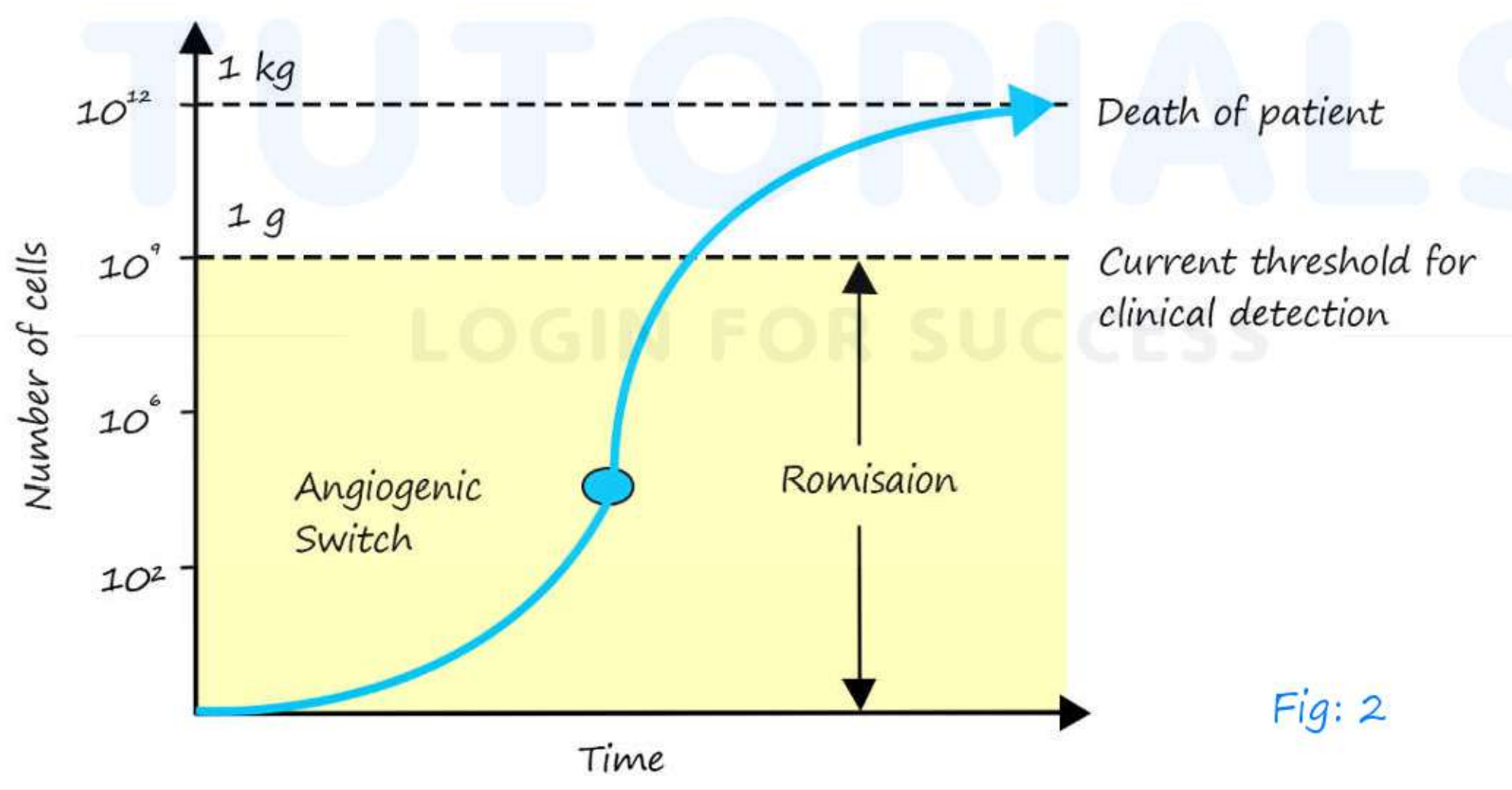

Fig: 2

AfraTafreeh.com

AfraTafreeh.com

Liquid biopsy

- Tumor cells shed their proteins and DNA
- These are analyzed from the bloodstream for mutations

↓

- Facilitates early cancer detection even before a lump appears

PAX genes – Paired Box genes 00:13:52

- PAX 6 defects – wilm's Tumor

  WAGR Syndrome

  If PAX6 is deleted, it results in aniridia
- PAX5 – development of B cells
- PAX3 – Alveolar Rhabdomyosarcoma, Waardenurg syndrome
- PAX2 mutation → Renal coloboma syndrome
- PAX9 → molar agenesis

DX TUTORIALS LOGIN FOR SUCCESS

SOX Genes 00:16:24

- SOX 2 → for conversion of somatic cell into stem cell

  – Expressed in pure embryonal carcinomas

  It can lead to formation of inducible pluripotent stem cells IPSC.
- Seen in embryonal carcinomas
- SOX 17 → seen in seminomas, yolk sac tumors
- SOX 9 → Cartilage

INTRODUCTION TO GENETICS

Genetic disorders

- **Single gene disorders**
  - Mendelian
    - AD
    - AR
    - XR
    - XD
    - Y. Holandric
  - Non classical/ Non mendelian
    - Trinucleotide- XR
    - Genomic imprinting
    - Gonadal mosaicism
    - Mitochondrial
- **Chromosomal**
  - Chromosome No
    - 2n, 3n — Euploidy — Exact multiple of n — Eg: Triploidy
    - 2n+1, 2n-1 — Aneuploidy — Eg: Trisomy 21, Monosomy
  - Chromosome structure Abnormalities
    - Mosaicism
    - Mixture of 2 sets of Chromosomes
- **Multi factorial**
  - Multiple factors Involved
  - Environment also may be involved

AfraTafreeh.com
TUTORIALS
LOGIC FOR SUCCESS

Alleles

- Various form of genes
- 2 sets present in a person-one paternally derived other material

AfraTafreeh.com

Example gene for hair color paternal gene (Blonde)



Maternal gene (Brown)

- Alleles exist due to slight variations in base sequences
- In such case child expresses the gene which is dominant
- Another is the theory of Methylation – causes silencing of gene
- Genotype The entire set of genes present in your body irrespective of their expression
- Loci – Location of the allele eg 15 q 13
- Phenotype Whatever features you express on the outside
- Haplotype– All alleles present on one chromosome.

MENDELEIN DISORDERS, AUTOSOMAL DOMINANT DISORDERS

Autosomal Dominant Disorders 00:00:30

- In heterozygous state also, the disease will be manifested



- Vertical inheritance-disease will be expressed in 50% of the next generation and at least 1 person of every generation will have the disease.
- Usually in AD disorders, the mutations are gain of function mutation

  Except

  Haploinsufficiency

  Dominant negative inheritance

  Loss of function mutations-AR

AfraTafreeh.com

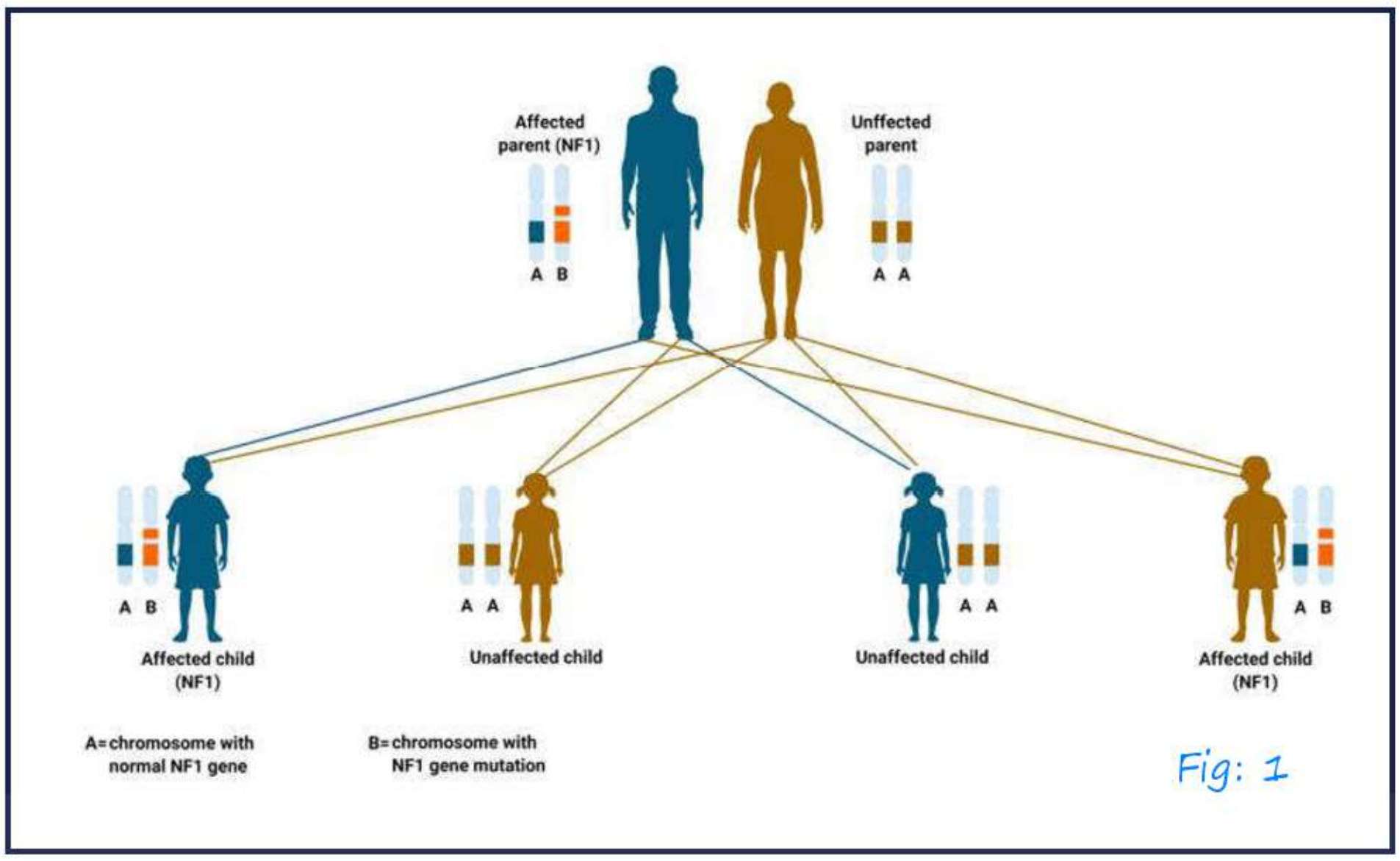

Fig: 1

- Genetically at offspring's have NF gene but phenotype is different-C/a VARIABLE EXPRESSIVITY
- **Incomplete penetrance** - the child has the gene but phenotypically the child is normal
- Only in AD disorders

  Function

Haploinsufficiency. 00:11:00

Gene
↓
DNA
↓
RNA
↓
Protein

Haplosufficiency is normal

Alleles
↓
Mutation
→ Protein
  ↓
  Haplosufficiency
→ No Protein Formation

- 2 alleles are required to make a particular protein. If one undergoes mutation, only 1 allele is left for making protein
- Therefore, Dominant allele has been deleted, one allele is insufficient to cause Full phenotype expression

Mutation on LDL Receptor

↓

Familial hypercholesterolemia (AD)

↓

Occurs due to Haploinsufficiency

- LDL. Receptor → Formed in ER → Comes to Golgi Apparatuses

↓ Attaches to plasma membrane → Clusters and is ready to take cholesterol → Takes cholesterol internalized

Mutation Class	Defect
I	Synthesis
II	Transport
III	Binding
IV	Clustering
V	Recycling

AfraTafreeh.com
TUTORIALS
LOGIN FOR SUCCESS

AfraTafreeh.com

Dominant negative inheritance 00:19:00

AD Mutation
↓
Abnormal protein
↓
Birds improperly
↓
Structure of protein altered

Normal gene
↓
Normal protein
↓
Normal collagen

✳ Triple helix

- Dominant mutation → caused negative effect
  c/a Dominant Negative Effect
  example: – Osteogenesis imperfecta

- Marfan's syndrome FBN1 gene mutation
  ↓
  Abnormal fibrillin
  ↓
  Does not let elastin stabilize

Osteogenesis Imperfecta (OI)

Disorder type I collagen

TYPE I OI	TYPE II/III/IV
i. Clinically mild ii. Haploinsufficiency	i. Clinically severe ii. Dominant negative mutation

iii.Normal Structure of collagen but ↓↓ quantity	iii.Structurally abnormal mutation

Hereditary pancreatitis

- Mutation of PRS51 gene
- Normally pancreas protected as enzyme trypsin destroys itself by cutting itself at R117 position

This splits trypsin & inactivates it

↓

In HP R117 is mutated to H117

↓

Trypsin changes to SUPER TRYPSIN

↓

Super trypsin cannot be inactivated & causes acute pancreatitis

Clues to remember genetic disorders. 00:28:00

- All CNS disorders are AD except
  - i. Freidrich's ataxia
  - ii. Ataxia telangiectasia
- All polyp disorders of GIT ore AD except MUTYH associated polyposis
- OI & Marfans are AD

AfraTafreeh.com

Hematology- Rule of 2

- Hereditary Spherocytosis
- Von Willebrand disease

- Thalassemia
- Sickle cell

- G6PD deficiency
- Hemophilia

All metabolic disorders are AR except

i. Hereditary hypercholesterolemia

ii. Acute intermittent porphyria

Recap

- Manifestation in heterozygous state
- Vertical inheritance
- Incomplete penetrance
- Variable expressivity
- Haploinsufficiency
- Dominant negative mutation
- Mendel said-any new mutation occurring is AD
- Recent concept-new mutation is kept under mosaicism
- AD is overall most common pattern of inheritance

Variable expressivity

- If trait to seen in all individuals carrying mutant gene but is expressed differently amongst individuals

Incomplete penetrance

- Some individuals inherit mutant gene but phenotypically Normal
  Example: Neurofibromatosis

Mnemonic for autosomal dominant disorders

• MEN	MEN syndrome
of	OI Osler render weber syndrome
Mary	Marfans
	Myotonic dystrophy
• Huntington's	Huntington's chores (CA9)
Family	FAP Familial hypercholesterolemia
has VON (WON)	Von willebrand's disease VHL syndrome
	VHL syndrome
• A	Achondroplasia
	Adult PKD
• New	Neurofibromatosis
	Norman's syndrome
• Spherical	Spherocytosis
	Spinocerebellar ataxia-3
• Tuber	Tuberous sclerosis
and liddle	Liddle syndrome

AfraTafreeh.com

S

OCM

S

NPCC

HT

Hypercholesterolemia

TUTORIALS
LOGIN FOR SUCCESS

MENDELIAN DISORDERS AUTOSOMAL RECESSIVE

- Usually express in Homozygous state only
- Only 25% chance of appearing in progeny

↓

Skip generations

↓

Horizontal inheritance

- Skipping of generations
- Loss of function mutations usually

Except Haploinsufficiency] In AR inheritance
Dominant negative

AfraTafreeh.com

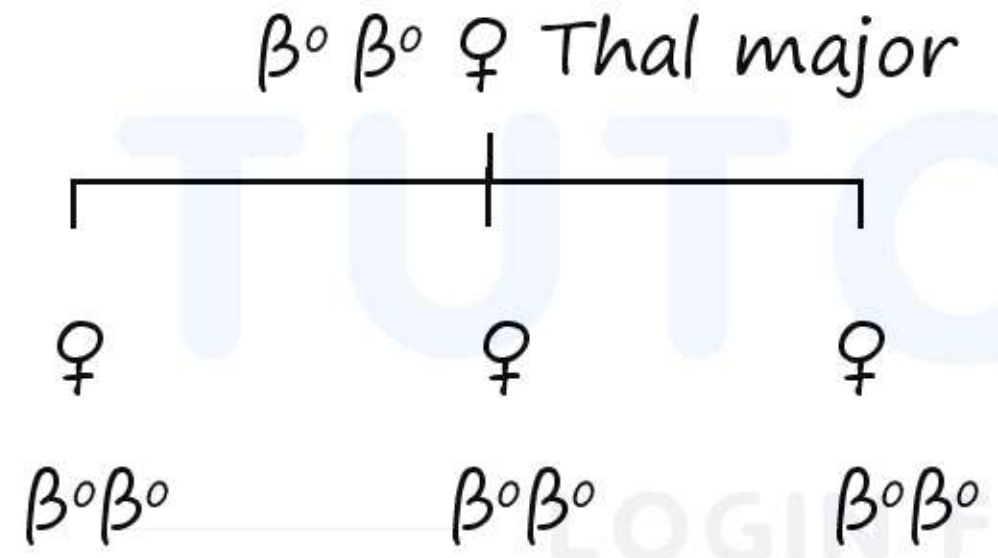

All are β Thal major

TUTORIALS
LOGIN FOR SUCCESS

- Uniform expressivity
- Complete penetrance
  - All metabolic disorders are AR

except

i. Hereditary hypercholesterolemia

ii. AIP

AfraTafreeh.com

Gaucher's dese	Neimans pick disease
β glucosidase / Glucocerebrosidase Deficiency ↓ Accumulate in macrophages ↓	Sphingomyelinase Deficiency ↓ Accumulate in Macrophage-Become-foamy

- Crumpled tissue paper appearance
  - 2year child with hepatosplenomegaly Pancytopenia
  - BM hypercellular
  - Crumpled tissue paper appearance
  - Gaucher's Foamy Macrophages-Neiman pick Gaucher's disease
  - E:M: Rod shaped membrane or tubular structure (Goucher's)
  - EM Zebra bodies

    ↓

    also seen in Metabolic leukodystrophy

    Doc : Enzyme analysis
- Mucopolysaccharidosis
- Not typical of Gaucher's disease
  - Test of choice for both disorders = enzyme analysis Confirm diagnosis
  - Mnemonic for autosomal recessive disorders
- Freidrich's is - Freidrich's ataxia
- Homing - Homocystinuria
- Congenital - Congenital adrenal hyperplasia
- Sickness - Sickle cell anemia
- That - Thalassemia

- Wil - Wilson's disease
- Alter - Alkaptonuria

  α1 antitrypsin deficiency (Emphysema)
- His - Hemochromatosis
- Metabolism - All Metabolic disorders EXCEPT

  Fabry's disease

  Hunter syndrome (MPS-II)
- C- Cystic fibrosis
- Albinism (oculocutaneous)
- N- Neimann picks
- T Tay sach's disease
- H- Hurter and all MPS except HUNTER
- S-NHL
- Bartter & gittleman syndrome.

AnkTaTech.com
TUTORIALS
LOGIN FOR SUCCESS

AfraTafreeh.com

MENDELIAN DISORDERS, X LINKED DISORDERS

- Majority are recessive

	X^d	Y
X	XX^d	XY
X	XX^d	XY

XY – Male Normal

XX^d – Female carrier but phenotypically Normal

- Diseased ♂ never gives disease to son
- Diseased ♂ will give disease to daughter

Daughters are phenotypically normal → XR

Daughters are diseased → XD

TUTORIALS
LOGIN FOR SUCCESS

- XR ♂ >>> ♀

	Y	X^d	
X	XX	XX^d	→ Diseased
X	XY	X^dY	→ Carrier

		X^d	Y	
	X	XX^d (Carrier)	XY	
Carrier ←	X^d	X^dX^d ↓ Diseased	X^dY	→ Diseased

Female can get affected in case if

i. Carrier ♀ marrying diseased male

ii. Lyosonization

- XIST gene- type of LiNc Long inactivating Noncoding RNA

↓

- In ♀ on day 5.5 of embryo life

↓

- One X is inactivated

↓

- Drumsticks-formed

(or)

- Barr bodies in mucosal cells I of Normal X gets lionized

↓

- The diseased X chromosome is expressed

↓

AR disease will be expressed even in females

XR Inheritance

♂ >> ♀

- Sons of affected ♂ is spared
- Daughters-not affected phenotypically but remain as carriers

AfreTofresh.com
TUTORIALS
LOGIN FOR SUCCESS

AfraTafreeh.com

XD Inheritance

- All daughters of affected ♂ are affected sons of affected ♂ are normal

XR	XD
i. G6PD	i. Alport syndrome
ii. Hemophilia	ii. Vit D resistant rickets
iii.Duchenne	iii.Ritt's syndrome
iv.Becker's	
v. Chronic granulomatous Disease (CGD)	
vi.Wiskott aldrich	
vii. Fragile X syndrome	

- Barre body analysis
- Sample - Taken from buccal mucosa and stained
  Number of Barr bodies = number of X -1
- XY = 0
- XX = 1
- XXY = 1
- XO = 0
- XXXY = 2

* Mnemonic for XR disorders <u>Hemophilia</u>
  and
* Agammaglobulinemia (Bruton's), Adrenoleukodystrophy - X linked
* Color blindness & CGD

- Does not - Duchene's, DENTS disease
- Lowe (love) - Louie's disease
- Hunting - Hunters
- Fragile - Fabry's

  Fragile X
- Leach (Less) - Lesch Nyhan syndrome
- Wise - WAS
- Girls - G6PD
- Mnemonic for XD disorders
- All - Alport's
- Rickety - X linked hypophosphatemic rickets

  (Vit D resistant)
- Retts (Rats) rett's syndrome
- Are hypo- Familial hypophosphatemia
- Pigmented-Incontinentia pigmentii
- Ornithine transcarbamoylase (OTC) deficiency.

TUTORIALS
LOGIN FOR SUCCESS

AfraTafreeh.com

MENDELIAN DISORDERS, HOLANDRIC DISORDERS, CO-DOMINANT, PLEIOTROPHY, GENETIC HETEROGENETITY

- Holandric inheritance, codominant inheritance pleiotropy & genetic heterogeneity

  Holandric inheritance/y linked

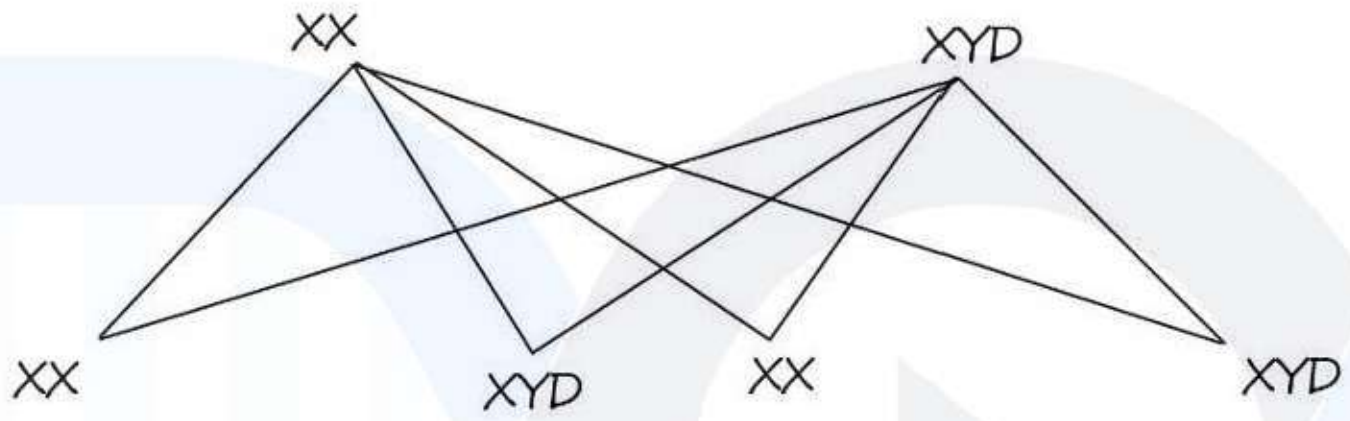

- Affected male transmits disease to son mole-to-male transmission

  Example: Hypertrichosis

Codominant inheritance

- Both alleles will express themselves completely
- Example: Blood group
- Codominant alleles are neither dominant nor recessive
- Both alleles contribute to the phenotype

Pleiotropy

- One gene has multiple effects
- Example: sickle cell disorders

i. Anaemia

ii. Priapism

iii. Vaso occlusive crisis

iv. Crew cut skill

v. Vertebral abnormalities

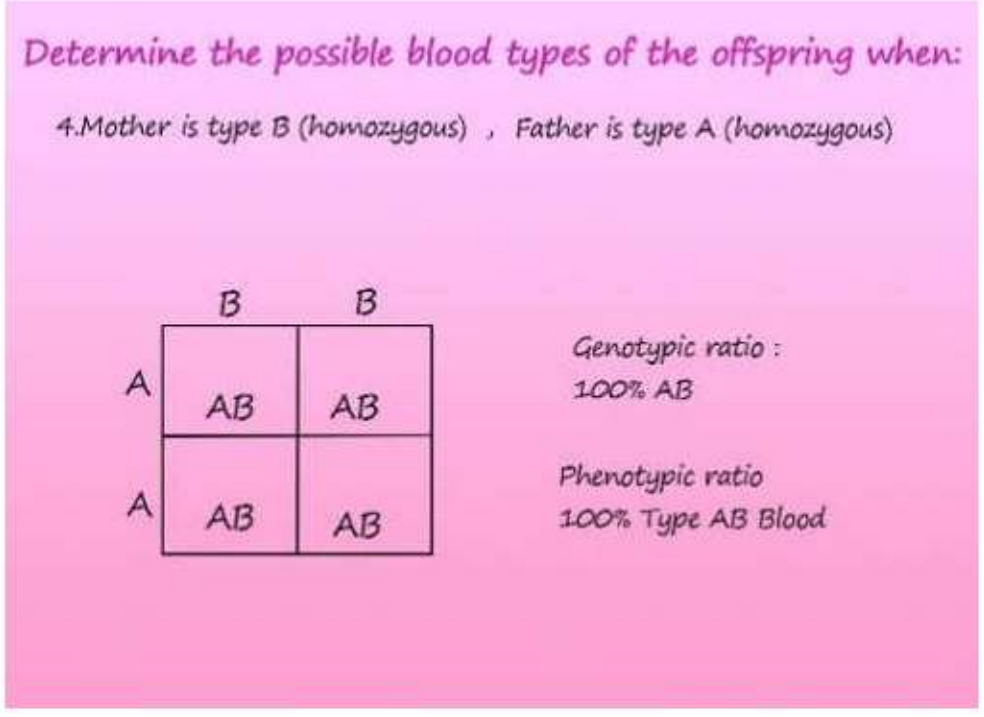

- Genetic heterogeneity
- When multiple mutations cause some effect
- Example: Multiple loci are affected but some phenotype-locus heterogeneity
- Multiple alleles are affected but some effect-allele heterogeneity Eg Deafness (profound childhood deafness), DM.

AfraTafreeh.com
TUTORIALS
LOGIN FOR SUCCESS

AfraTafreeh.com

NON-MENDELIAN DISORDER; TRINUCLEOTIDE REPEAT INHERITANCE & FRAGILE X SYNDROME

- Non classical inheritance

  1.Trinucleotide repeat inheritance

  2.Mitochondrial inheritance

  3.Imprinting

  4.Gonadal mosaicism

Trinucleotide repeat disorders

- Repeats are usually
- CAG
- CGG
- GAA
- The Trinucleotide repeats, double themselves in oogenesis or spermatogenesis When their no exceeds a particular cutoff disease occurs

  Example < 50 (N)

  ↓

  Doubling-cogenesis/spermatogenesis

  ↓

  50-500-c/a permutation

  ↓

  > 500-disease

- 3 stages of trinucleotide repeat disorders

  i. (N) person

  ii. Permutation

  iii. Disease/mutation

- Trinucleotide repeats in coding regions
  i. Huntington's
  ii. Spinocerebellar ataxia
  iii. Spinobulbar ataxia (KENNEDY'S disease)
- CAG repeats H
  - Trinucleotide repeats fried - friedreich's ataxia- GAA
  - Affecting non coding fragile x syndrome-CGG
  - Region's muscle Myotonic dystrophy - CTG
  - CAG repeats in coding region-11 glutamine-> Mis folding of protein
  - Non coding regions when repeats cross cutoff value, the genes get methylated leading to silencing of function of gene
- Grandfather ♀↓ CGG-MR
- Father 1000 ⚥↓ repents more MR
  - Dynamic mutation
- Son 2000 ⚥↓ SMR - Severity in successive generations anticipation
- Grand Son ♂ 4000 Most MR
  - Fragile x syndrome-duplication occurs in oogenesis. In all other it occurs in spermatogenesis

AfraTafreeh.com

Fragile x syndrome 00:14:40

Karyotyping

X chromosome

Hanging fragment of X, chromosome

fragile x

- CGG repeats
- Macroorchidism -90% post pubertal ♂
- 2nd Most common of Mental retardation after Down syndrome
- Affected ♂ are MR with IQ of 20 to 60
- Long face
- Large mandible
- Large everted ears
- Large testicles
- Method of choice for diagnosis PCR based detection of repeats to count the number of repeats
- Very large size of repeats southern Blotting Cutoffs for number of repeats

Called now as Proteinopathies { CODING REGIONS
Huntington
Spin cerebellar ataxia
Spin bulbar muscular ataxia
(Kennedys Disease) }

CAG repeats
↓
Poly glutamine
↓ Repeats
Accumulate in nucleus
↓
Nuclear clusions
↓
Neuro degenerations

Proteinopathies

- Inclusion Bodies
  - Intra cytoplasmic inclusions
  - Intra nuclear inclusions
- Amyloid Fibrils
  - ↓ Extracellular fibrils
  - Extracellular deposition of fibrills

Neurodegeneration

- Huntington's

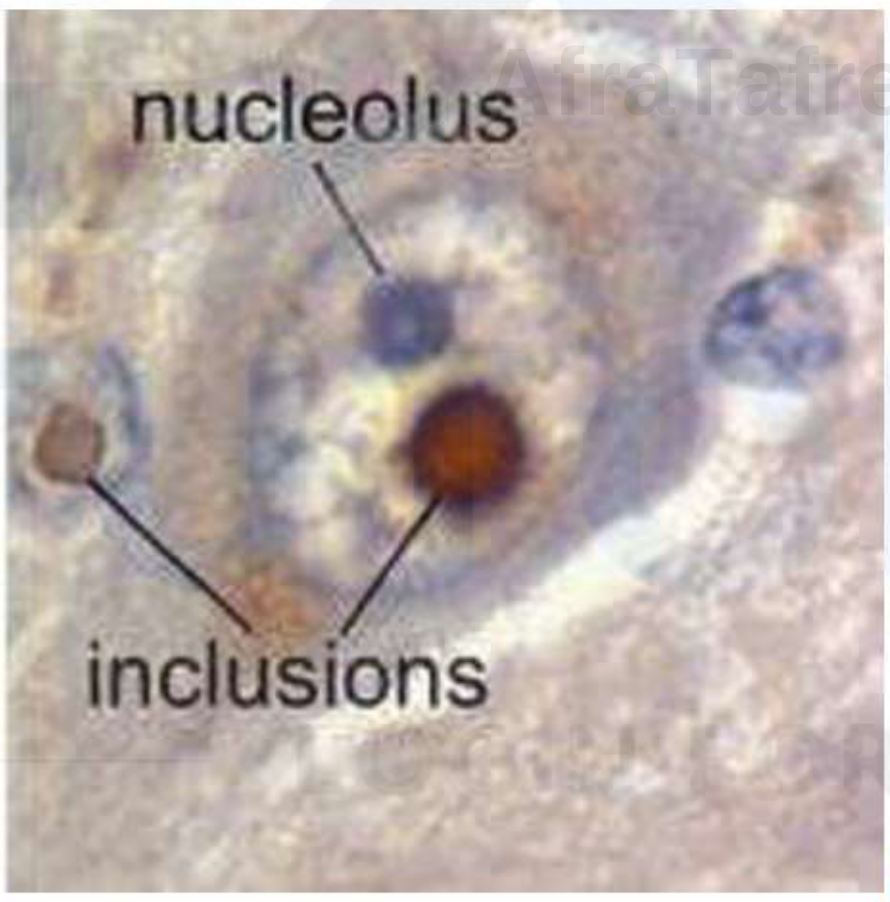

Fig 1

- Parkinson's LEWY bodies (a synuclein)

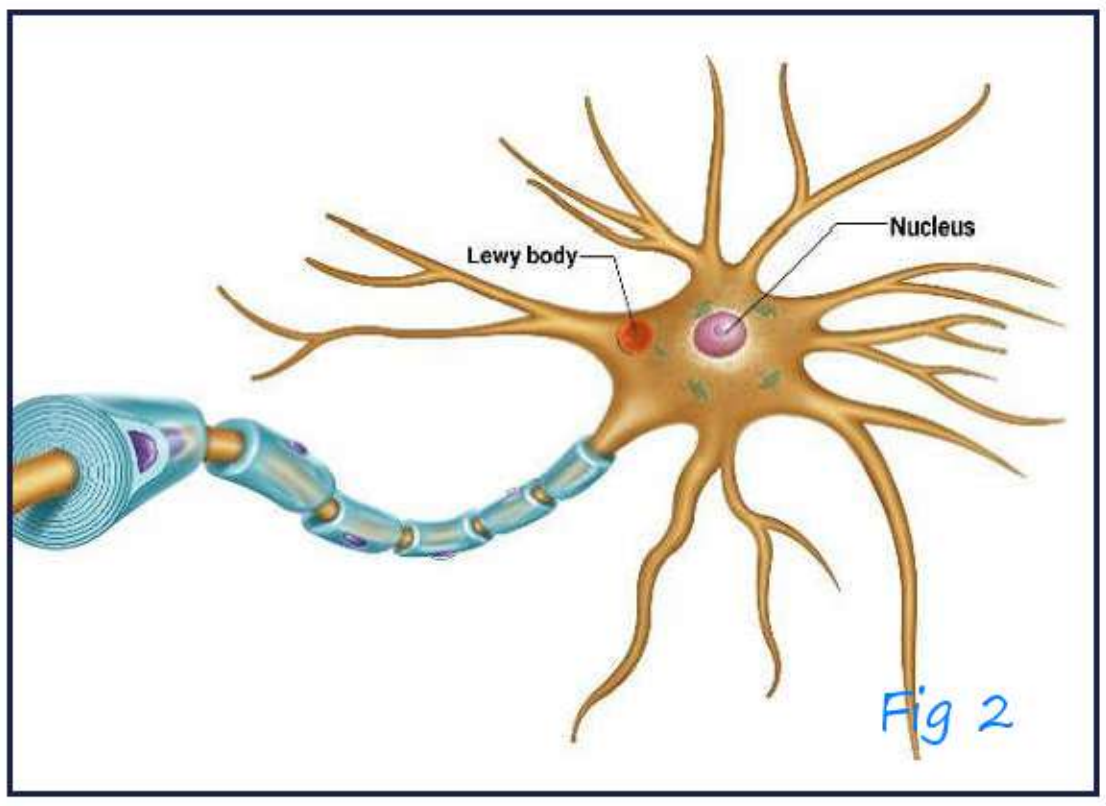

Fig 2

AfraTafreeh.com

- Alzheimer's

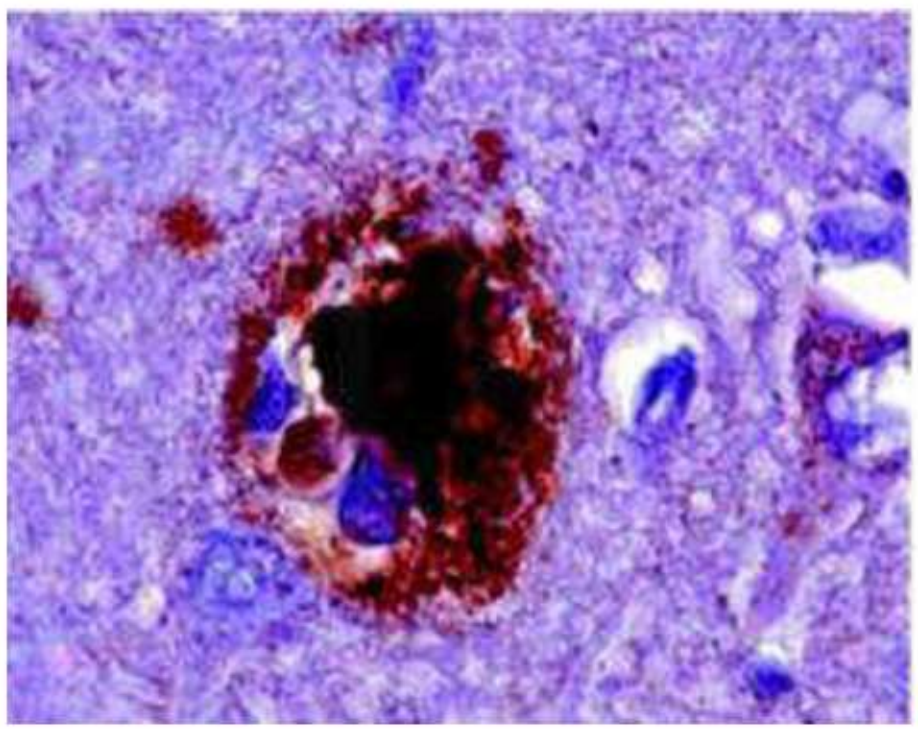

Fig 3

Non coding regions

- Friedrichs ataxia GAA
- Fragile x syndrome CGG
- Muscular dystrophy CTG

Repeats reach cut off
↓
methylation
↓
No mRNA

Transcriptional silencing | No protein loss of function of gene

- Fragile x Ataxia Syndrome
- Disease in Premutation stage

- Repeats reach cut-off value

↓

- But are not methylated

↓

(Form mRNA-Toxic gain) transcriptional regulation

Ovarian Failure In ♀ (< 40 Years)	MR In ♂ (Neuro Degeneration) (60 Years)

- Trinucleotide Repeat disorders

a. Affecting Non-Coding regions

AfraTafreeh.com

Disease	Gene	Locus	Protein	Repeats
fragile x syndrome	FMRI	Xq27.3	FMR-1 Protein ↓ Accumulate in dendrites ↓ Neurodegeneration	CGG
Friedrich's ataxia	FXN	9q21.1	frataxin	GAA
Myotonic Dystrophy	DMPK		DMPK	CTG
CODING REGIONS				

AfraTafreeh.com

Kennedy's disease	AR	X912	Androgen receptor	CAG
Huntington disease	HTT	4P16.3	Huntington's	CAG
Spinocerebellar ataxias	ATXNI	variable	Ataxin	CAG

TUTORIALS
LOGIN FOR SUCCESS

NON-MENDELIAN DISORDERS – MITOCHONDRIAL INHERITANCE

Non-Mendelian disorders – Mitochondrial inheritance 00:00:30

Mitochondria has 37 genes

- 22 – tRNA
- 2 – rRNA
- 13 – oxidative phosphorylation
  ↓
  dependent organs are
  - CNS
  - Muscle
  - Kidney
  - Eye

  – commonly involved

AfraTafreeh.com

- Mitochondria of Zygote is derived from mother
- Sometimes diseased mitochondria and normal mitochondria coexist in a cell – c/a Heteroplasmy
  ↓
- Disease occurs if diseased mitochondria increase and become more than normal mitochondria – phenomenon called as **Threshold Effect**
- If mother is affected → gives disease to all offspring is irrespective of sex

  i. Person syndrome

  - Exocrine pancreatic insufficiency

AfraTafreeh.com

- Sideroblastic anemia
- Perls Prussian blue stain (Iron granules ringed cover > 1/3 siderblast of nucleus)
- Vacuolization of erythroid precursors

ii. Leigh's syndrome:

- Eye involvement ⊕

iii. NARP Syndrome:

- Nystagmus
- Ataxia
- RP – retinitis pigmentosa

iv. MERRF (myoclonic epilepsy and red ragged fibers)

- On masson's trichrome stain

v. MELAS (Myoclonic epilepsy a lactic acidosis syndrome)

Red ragged fibre seen on masson trichromatic stain

vi. LHON (Leber's hereditary optic neuropathy)

vii. KEARNS SAYRE Syndrome

- If child with pearson syndrome progress into adulthood have kearn sayre syndrome
- Have ophthalmoplegia cardiac defects

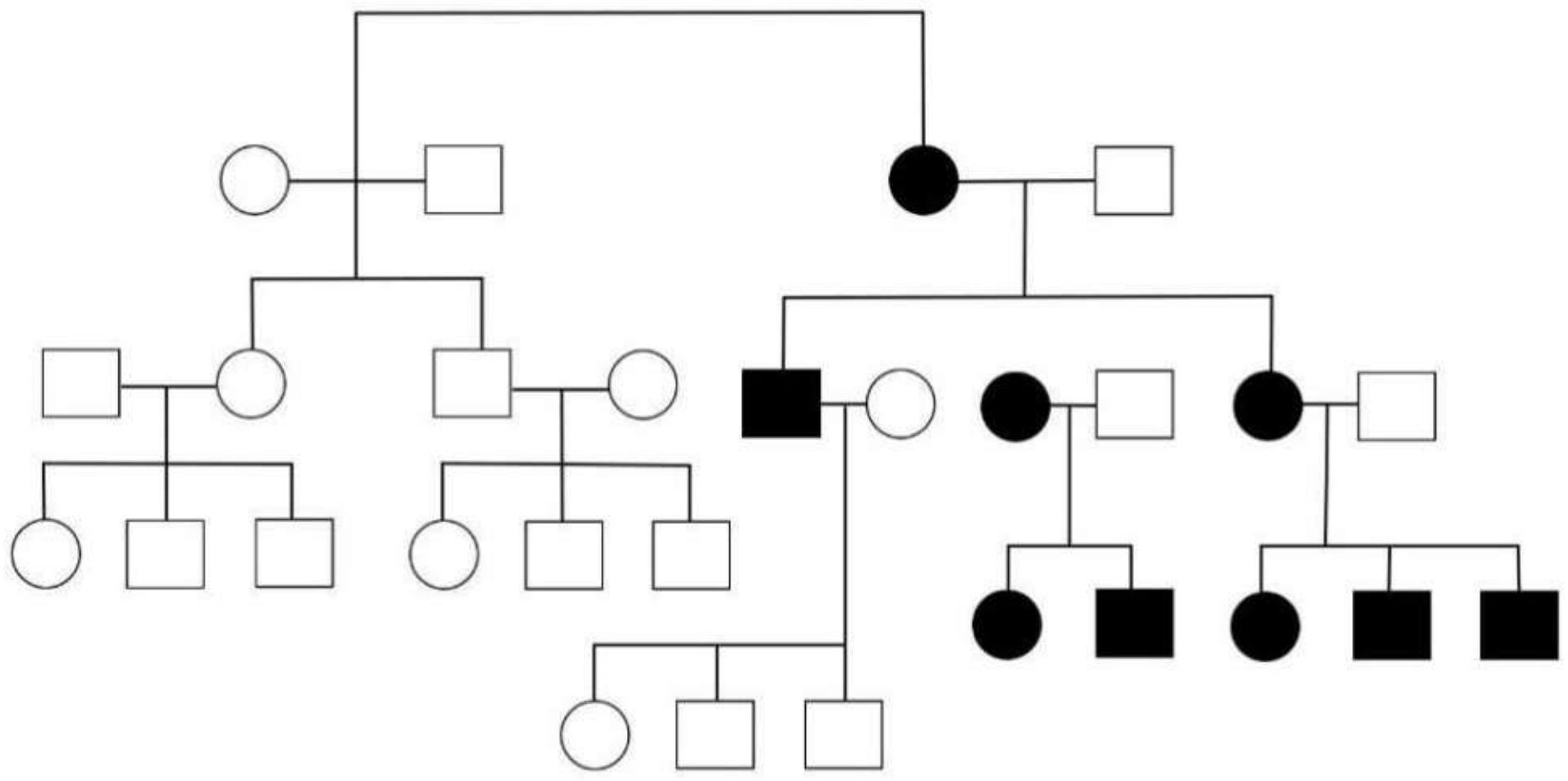

i. Affected mothers – transmit to all offspring's

ii. Affected makes – Do not transmit disease.

AfraTafreeh.com
TUTORIALS
LOGIN FOR SUCCESS

AfraTafreeh.com

NON-MENDELIAN DISORDERS, GENOMIC IMPRINTING

Non-Mendelian inheritance genomic imprinting

00:00:30

Non-Mendelian inheritance genomic imprinting

↓

Silencing

↓

(N) Phenomenon 98.5% of genes-silenced Imprinting

occurs before fertilization

Mother Father

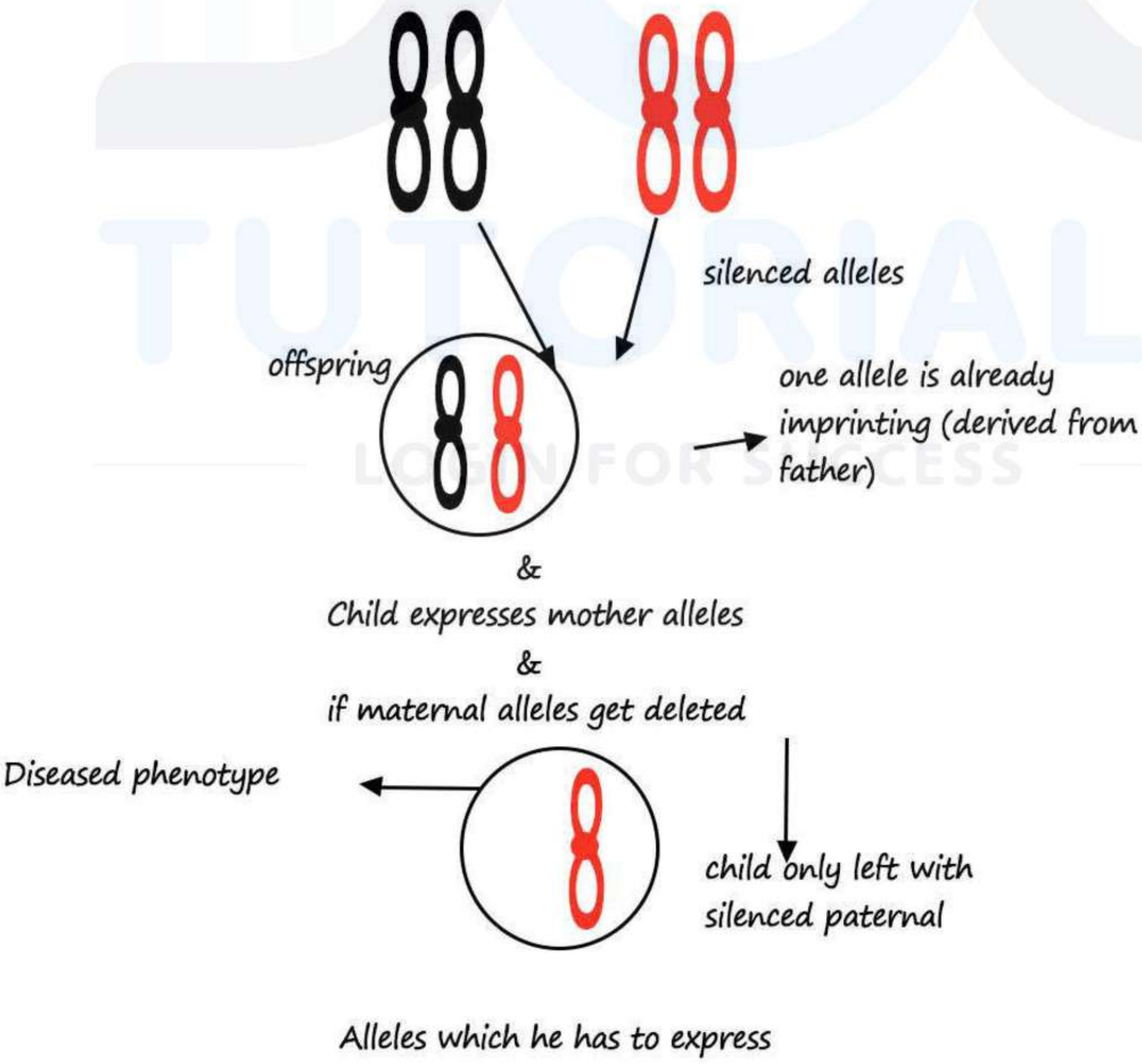

- 70%-Deletion of ma

- Deletion - Most commonly occurring phenomenon responsible for imprinting
- 20 – 25% - uniparental disomy

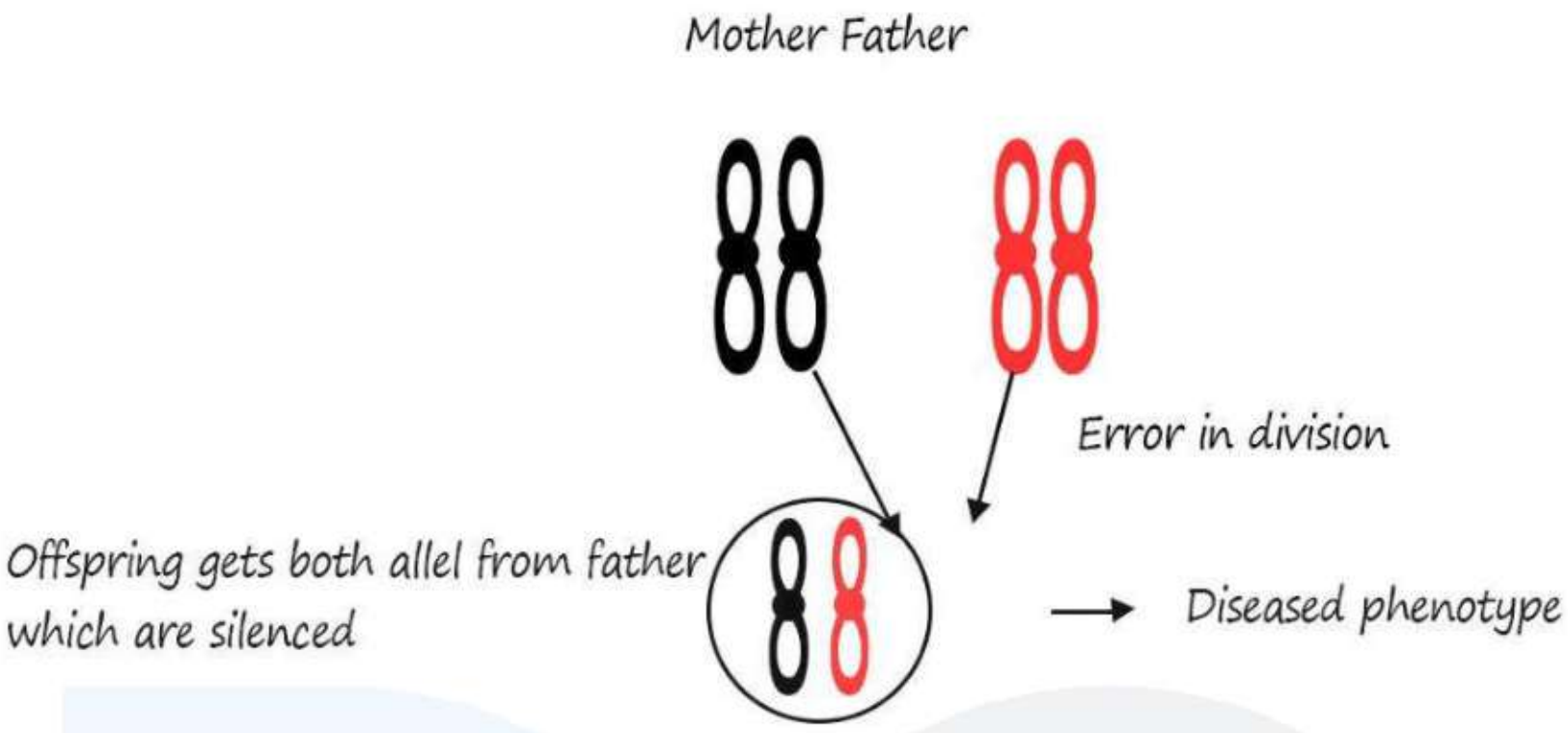

Angleman Prader will syndrome	Deletion maternal Paternal	154 Disomy Paternal Maternal	Imprinting Paternal Maternal

AfraTafreeh.com
TUTORIALS
LOGIN FOR SUCCESS

AfraTafreeh.com

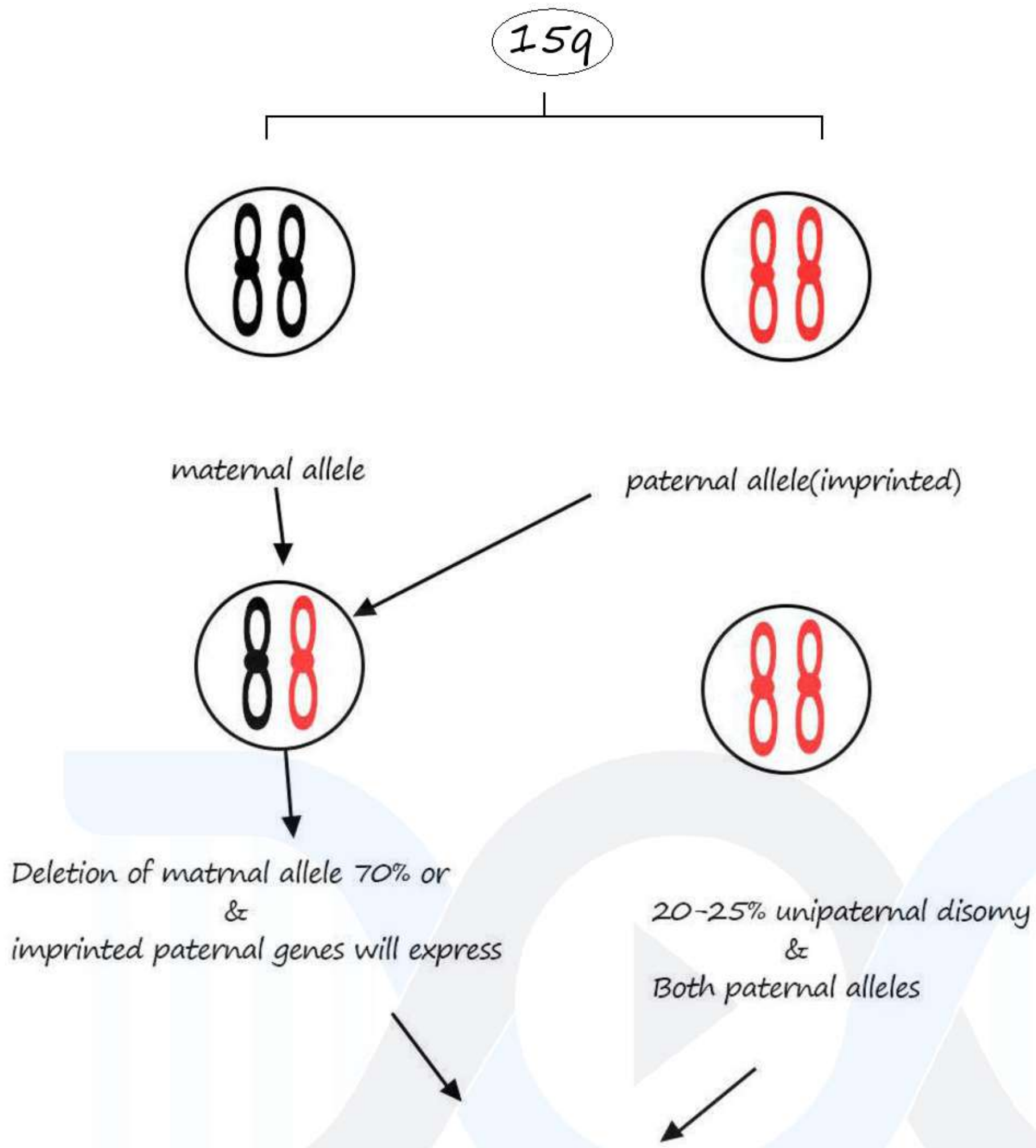

Angelman syndrome

Deletion of maternal allele imprinting of paternal allele

unipaternal disomy

TUTORIALS
LOGIN FOR SUCCESS

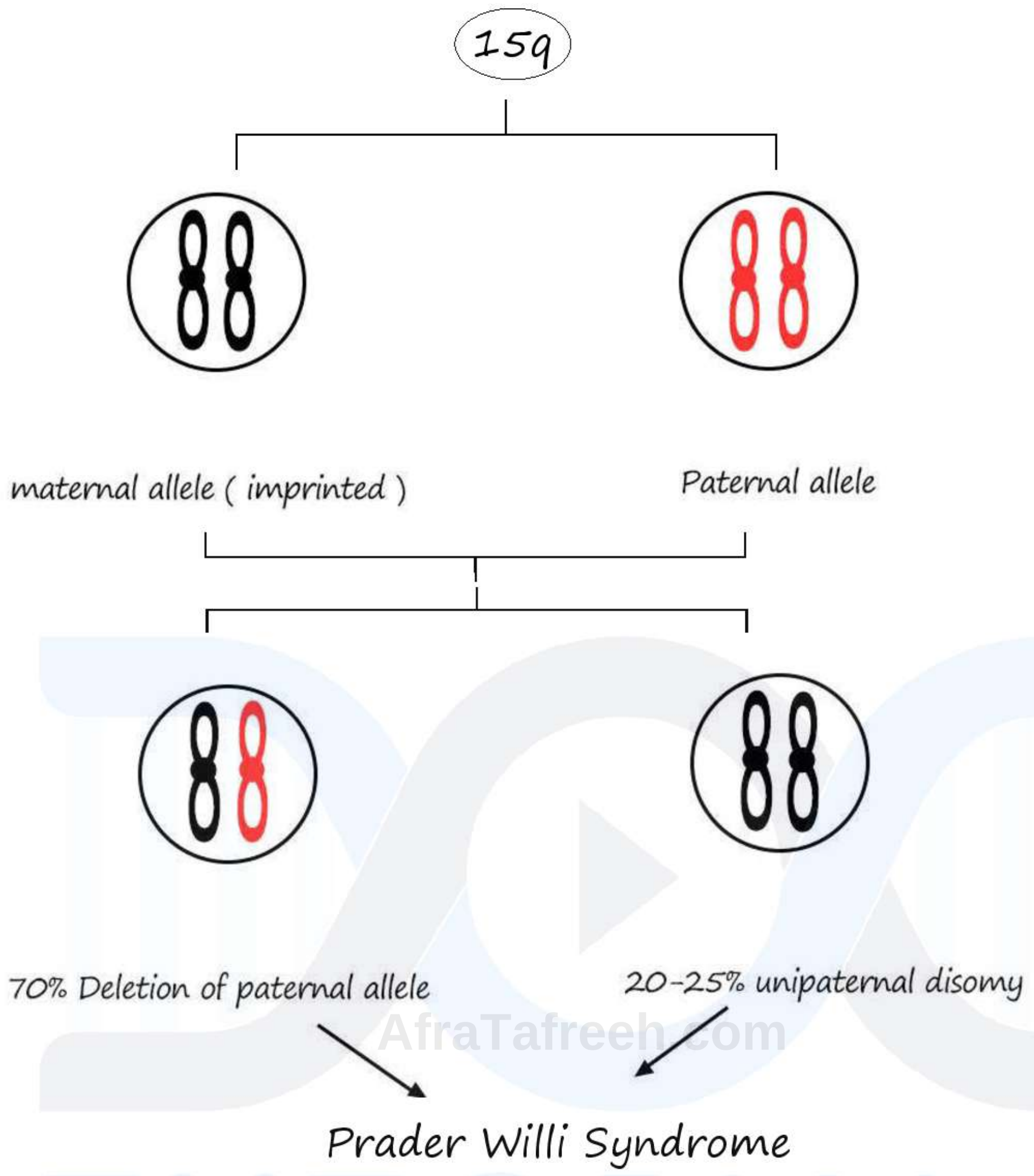

AfraTafreeh.com
TUTORIALS
LOGIN FOR SUCCESS

Deletion of paternal allele imprinting of paternal allele unipaternal disomy

Angelman syndrome: Ataxia, seizures Inappropriate Laughter **happy puppet syndrome**

|

MR

|

Prader willi: Hyperphagia, massive obesity, short hand and feet Hypogonadism

AfraTafreeh.com

Recent update-Genetic Make 4ps of prader willi and angel man

i. Imprinting-silencing

- Methylation
- Histone deacetylation

ii. 70% cases - Deletion

- Maternal deletion Paternal imprinting **Angelman**
- Paternal deletion Maternal imprinting **Prader willi**

iii. 20-25% Disomy

- Paternal disomy - **Angelman**
- Maternal disomy - **Prader willi**

iv. Genetics

- Angelman
- Ulbiquilin ligase UBE 3A gene imprinted on paternal alleles

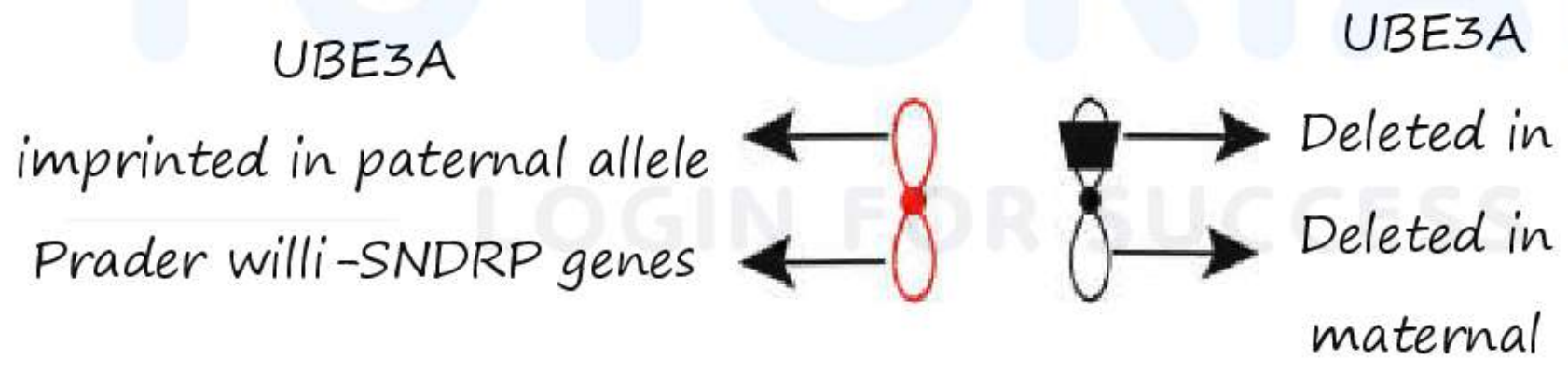

Other Agndromes with Imprinting

- Beckwidth weidmamn syndrome
- WANG syndrome
- Temple syndrome
- Silver-russel syndrome
- Transient Neonatal diabetes mellitis
- Pseudo hypoparathyroidism 1b.

NON-MENDELIAN DISORDERS, GONADAL MOSAICISM

- Occurs after fertilization or early embryonic development
- Each cell differentiates to form different organs

Example

CNS Eye Kidney Gonads

- Only cells forming gonads undergo mutation

- The person grows up to be phenotypically normal person

↓

But he ends up transmitting the disease to offspring through the mutant allele

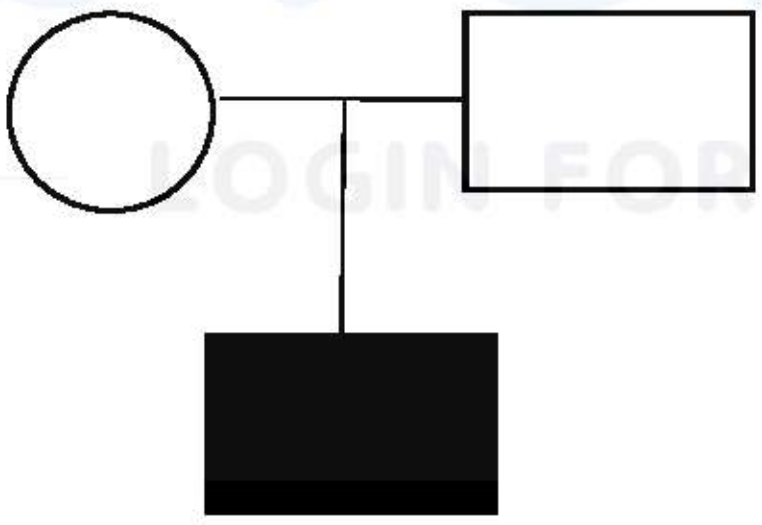

AfiaTafreeh.com
TUTORIALS
LOGIN FOR SUCCESS

Example:

- Osteogenesis imperfecta
- Mutation occurs before fertilization.

AfraTafreeh.com

CHROMOSOMAL DISORDERS

Chromosomal Disorders

Chromosomal number disorders

Euploidy	Aneuploidy	Mosaicism
•2 N	• 2n+1	Mixture
•3 N	• 2n-1	
•4 N	• Trisomy	

chromosomalstructural disorders

Metacentric	Sub Metacentric	Acrocentric
	Example: X Chromosome	Example: Y Chromosome

Chromosomal Structural Disorders

- When 2 acrocentric chromosomes undergo translocation



Example: CML t (9:22)   Balanced reciprocal translocation

- When 2 metacentric chromosomes undergo translocation



Robertsonion translocation

Example:

Downs syndrome (4%)

t (21:22)

t (21:14)

- Downs syndrome occurring due to Robertsonian translocation advanced maternal age has no role in pathogenesis
- Normal plasma division of chromosomes.

AfraTafreeh.com

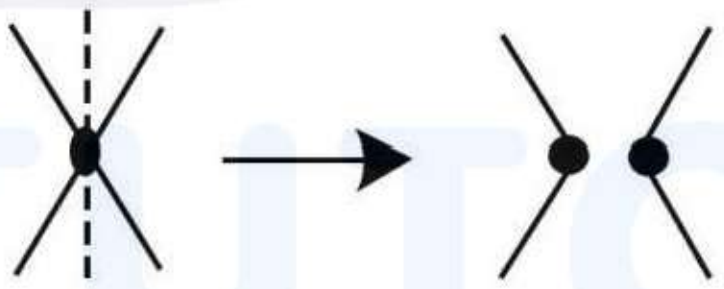

- When cut horizontal to original plane isochromosome formed

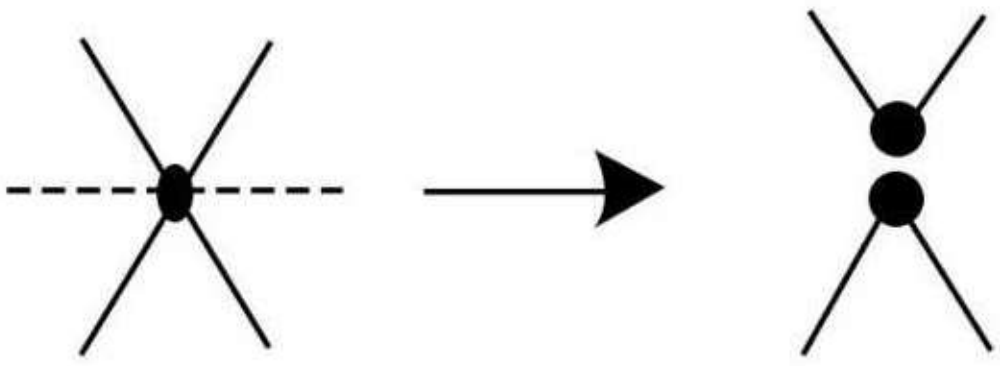

Example:

a)I17q

- Most common isochromosome

AfraTafreeh.com

- Medulloblastoma
- PNET
- CML – gone into accelerated phase → poor px

b) I12p germ cell tumors

Telomers present at endo of chromosome

↓

Cut ends

↓

Become sticky

↓

Join

Ring chromosome

Deletions

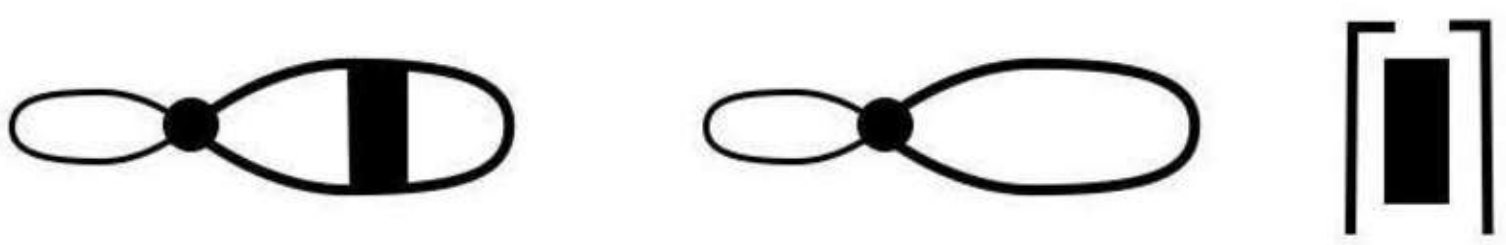

inversions

Paracentric | Pericentric

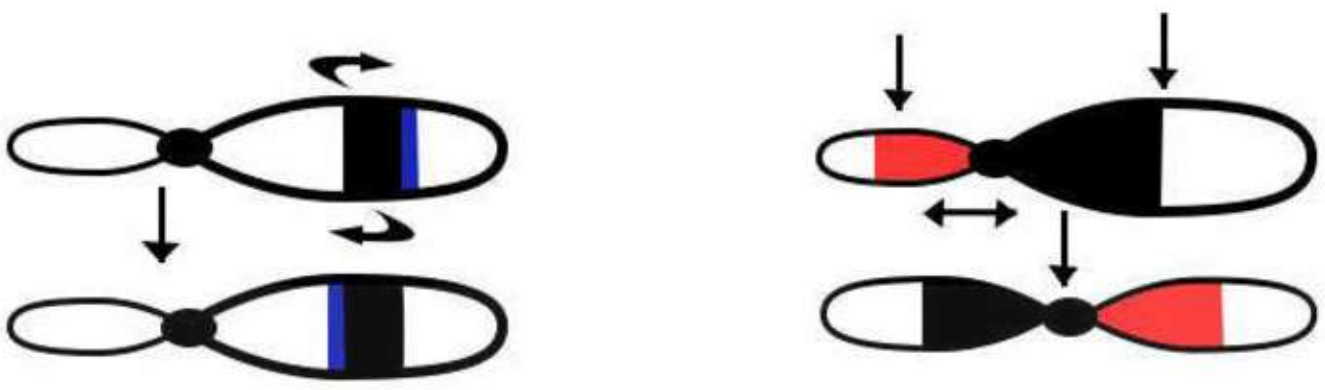

On one side of centromere | On both side of centromere

Numerical abnormalities of chromosomes

00:15:50

AfraTafreeh.com

Euploidy	Aneuploidy	Mosaicism
i. Exact multiples of haploid number of chromosomes example: 3n	i. Not exact multiple of 23 chromosome ii. Due to non-disjunction meiosis and anaphase lap Example: trisomy (2n-1) Manosomy (2n-1)	i. ≥ 2 population of cells in same person ii. Due to MITOTIC errors during cleaves of fertilized ovum

AfraTafreeh.com

- Best way to see numerical abnormality is karyotyping

Mosaics vs Chimeras

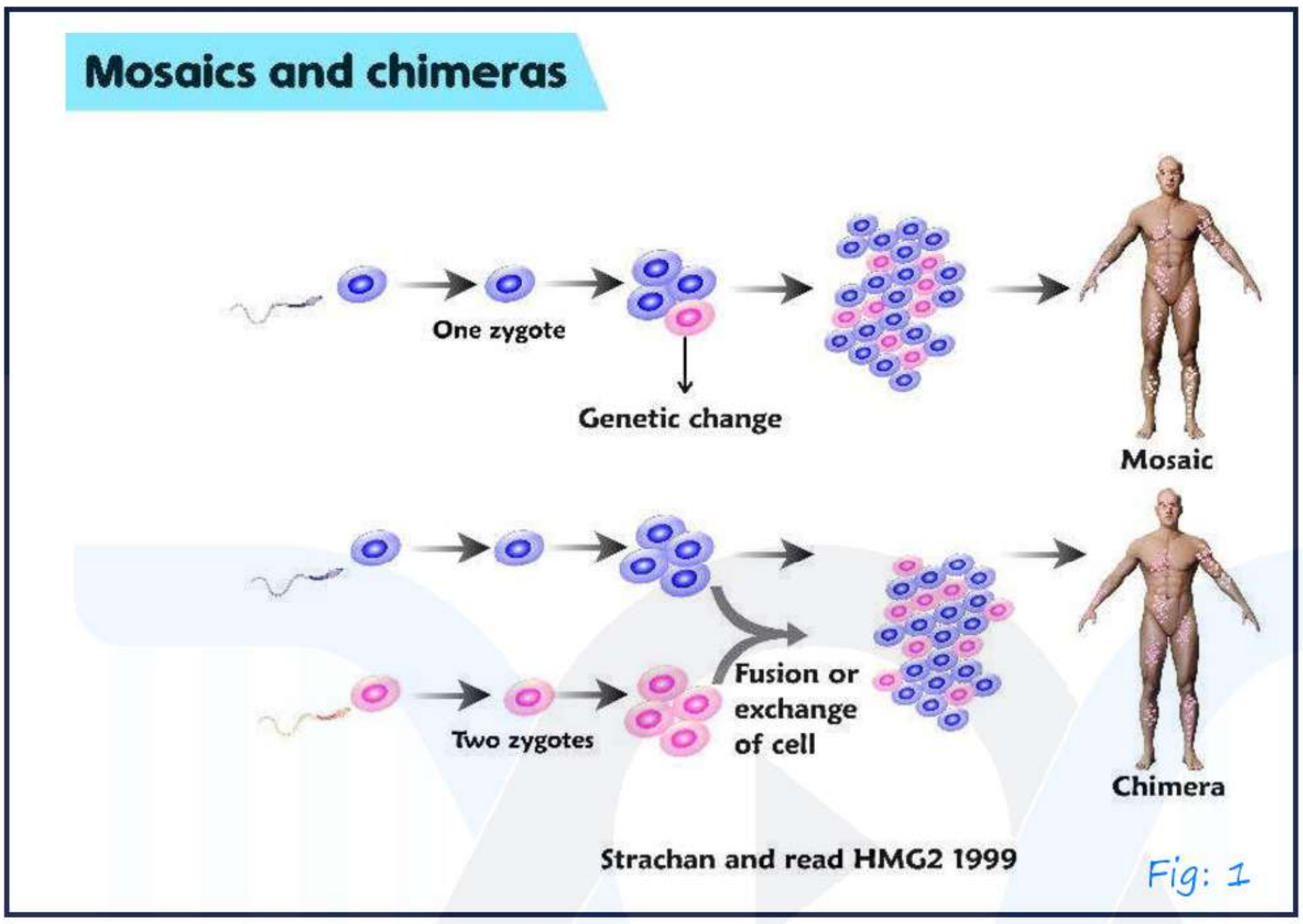

Fig: 1

MOSAICS	CHEMERAS
Example: 1% Downs syndrome seen in humans	Example: Occurs in animals

Down Syndrome 00:25:34

- Most common cause of MR
- Majority - meiotic non dysfunction of chromosome
- Maternal age 35 years
- implicated in pathogenesis
- 4%-Robertsonian translocation
- t(21:22)
- t(21:14)
- maternal age has no implication

- 1%-mosaicism mixture of cells with 46 & 47 chromosomes
- Clinical features- **PROFLEMATIC** situation
- Protruding tongue
- Round face
- Occiput flat/Open wide fontanelle
- Brush field spots/Brachycephaly/Behavioral difficulty
- Low nasal bridge/Language problem/Low tone
- Epicanthic folds/Ears low set hearing problem
- Acute leukemia/Alzheimer's/Atlanto -axial instability/Atresia of duodenum
- Trisomy 21/thyroid problem HYPO THYRODESM)
- Incurved 5th finger (Clinodactyly)/Intellectual disability
- Congenital heart diseases/Cataract
- Mcc Endocardial cushion defect
- Sandle gap /simian crease between 1st & 2nd toes
- MC hematopoietic abnormality TAM Transient abnormal myelopoiesis
- MC leukemia < 4yrs AML M7
- 4years ALL

Diagnosis

In 1st trimester -Nuchal thickness

- Nuchal thickness
- β HCG

AfraTafreeh.com

- PAPP - A

Sample = Chorionic villi biopsy (Invasive)

		Edward	patau
trisomy	21	18	13
β HCG	↑	↓	↓
PAPP - A	↓	↓	↓

2nd Trimester – QUAD test (HIEA)

	21	XO	18	13
APF	↓	↓	normal	↑
Estriol	↓	↓	↓	normal
HCG	↑	↑ ↑	↓ ↓	normal
inhibin A	↑	↑ ↑	normal	normal
Mnemonic	HI is high	HI is V high	HI is low	AF platau is high

- Sample Amniocentesis (Invasive) (Edward)
- 3rd Trimesters-cell free DNA
- Subjected to FISH/Karyotyping

  Sample: maternal blood

  Turners Syndrome (XO)

  Most lethal (coarctation of Aorta)]

CLOWNS

- C-Cardiac abnormalities

  ↓

  MCC Bicuspid aortic value

  Cubitus valgus
- L-lymphedema (CYSTIC HYGROMA)
- O-varies under developed - Streak ovaries
- Infertility Amenorrhea
- W-Webbed nick
- N-Normal Intelligence Nipper Widely spaced
- Short stature
- Short 4th metacarpal

Noonans Syndrome

AfraTafreeh.com

- Resembles turners
- In males + females
- MR
- Hypertrophic pulmonary stenosis
- 5q deletion: CRT-DU-CHAT syndrome
- FRIALS -KLINEFELTER SYNDROOME (KLINFELTS)

  1 barr body seen
- 22q 11 syndrome DI-GEORGE Syndrome Partial

  Trisomy 22 CAT EYE SYNDROOME
- Karyotype - MC 47 XXY
- Long stature with long legs
- Infertility
- Incidence 11 1000 men

AfraTafreeh.com

- Non-Dysfunction of paternal Sex chromosome Advanced paternal age is implicated
- Eunuchoid body proposition
- FSN elevated
- Scanty facial & Axillary hair
- LH elevated
- Testosterone ↓↓
- Small testes & penis
- Leukemia's (AML) & breast Tumors Learning ab Normality
- Secondary sexual characters absent.

TUTORIALS
LOGIN FOR SUCCESS

MULTIFACTORIAL INHERITANCE, POLYMORPHISMS AND LINKAGE

- Example of diseases associated with multifactor

Adults	Children
i. Hypertension ii. atherosclerosis iii. Schizophrenia iv. Diabetes Type 2 v. Allergic Diathesis vi. Psoriasis vii. Ankylosing Spondylitis viii. Gout	i. Pyloric Stenosis ii. Cleft Lip and Palate iii. Congenital Heart Disease iv. Meningomyelocele v. Anencephaly vi. Hypospadias vii. Congenital Lip Dislocation viii. Hirschsprung Disease ↓ RET gene associations have been found

AfraTafreeh.com
TUTORIALS
LOGIN FOR SUCCESS

- Genes Which are for apart on some chromosome undergo recombination

Example: - A&B genes are apert
and well recombination

AfraTafreeh.com

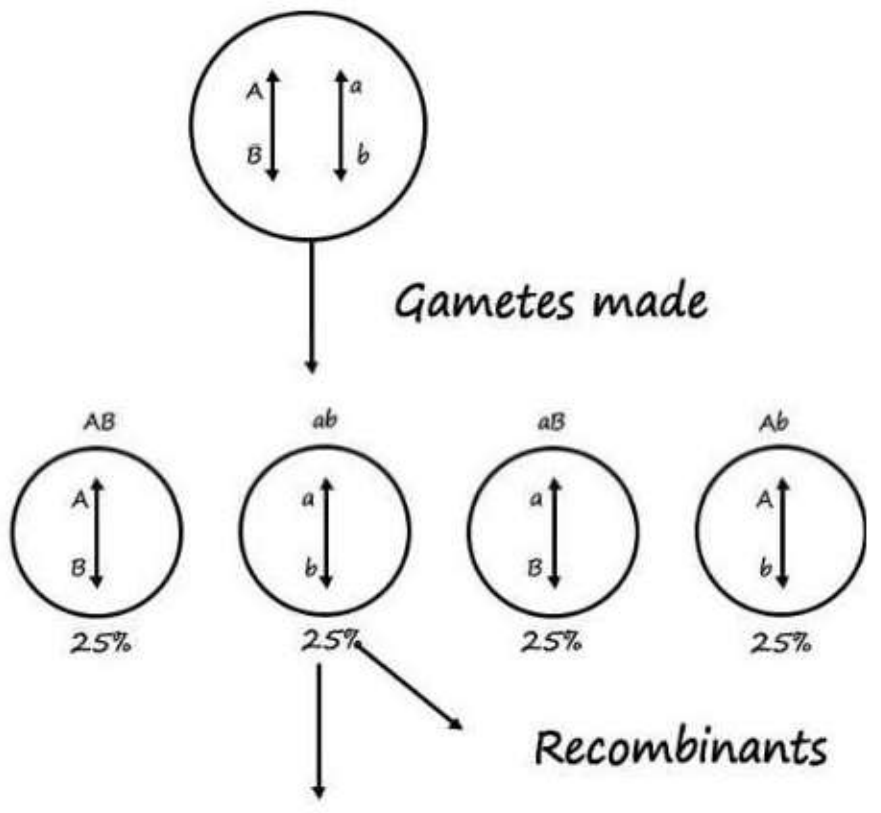

Syntenic genes 00:03:46

- Those genes which are far apart from each other's and thus have high chances of undergoing recombination

Linkage

- When 2 or more genes are located close to each other on a chromosome they do not undergo independent assessment and are instead inherited together as one group this is known as linkage (less chances of recombination).

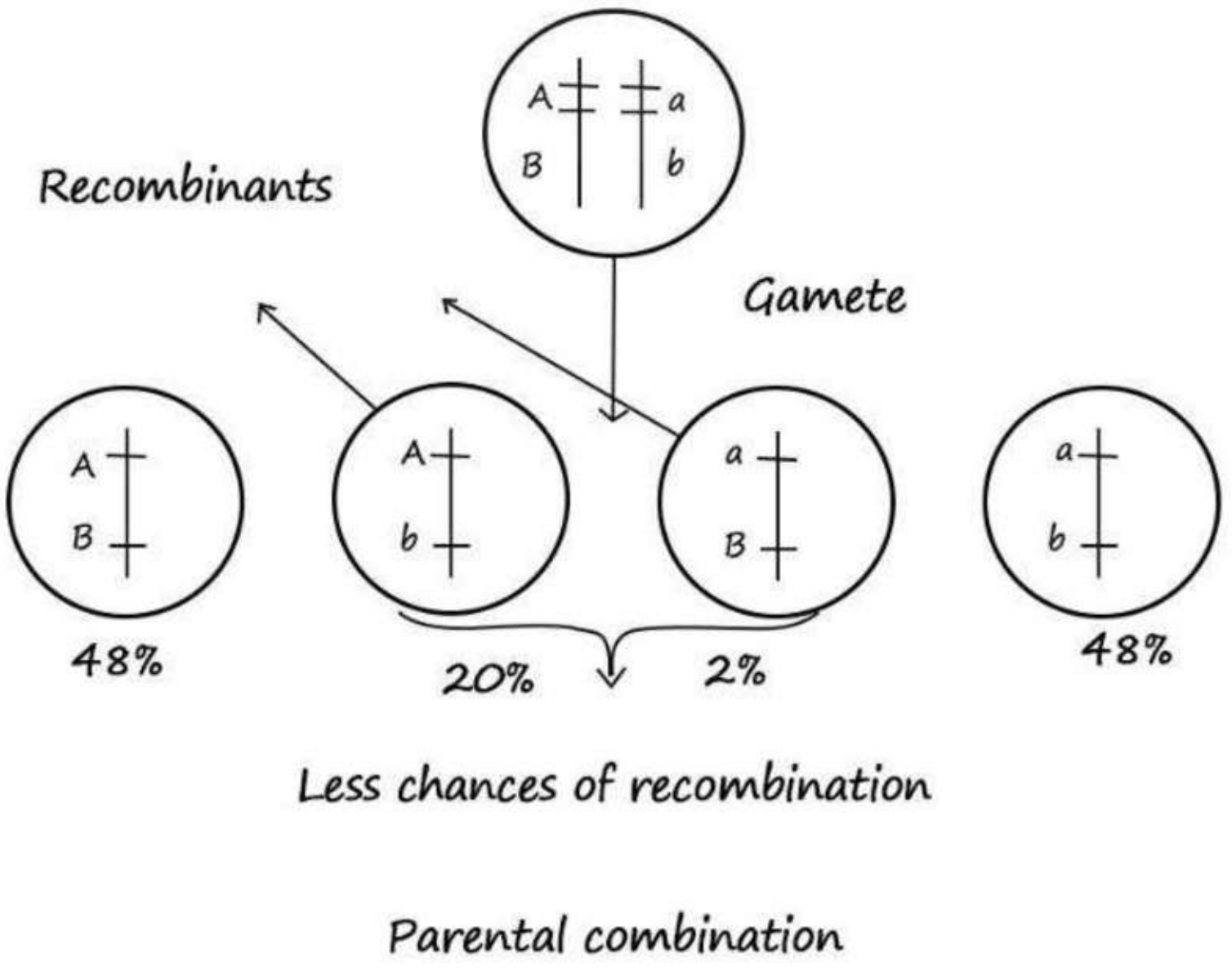

- i.e, closely linked genetic lock are less likely to experience recombination

linkage equilibrium 00:05:20

- Random association of genes (recombination) occurring in syntenic genes.

Linkage Disequilibrium

- Seen in genes which lie very close to each other, these genes are inherited together as a group this reflects correlation between two genetic loci.
- This theory of linkage equilibrium is called as Mendel's law of independent assortment.

AfraTafreeh.com

Polymorphism

- Variation level in human population is 0.5/n this is called as polymorphism Human beings are99 5% alike and only 0.5% different,
- Types of polymorphisms

TUTORIALS LOGIN FOR SUCCESS

i. Single nucleotide polymorphism (SNP)

- When variation in human genome is only due to a single nucleotide

  Example: instead of aC, a G is present
- SNPs can be present in both the coding as well as the non-coding regions of DNA

AfraTafreeh.com

- If SNPs are present in coding regions, they may be associated with symptomatic diseases
  Example: factor V Leiden mutation symptomatic

ii. Repeat length polymorphism

Microsatellites repeat -Variation less than 1 Kilobase and are characterized by a repeat size of 2 to 6 Base pairs	Minisatellites repeat, -larger variations (1-3kilobases) characterized by a repeat size of 15-70 base pairs

- These repeated lengths of polymorphism are kept under control by DNA repair mechanism
- keeps lengthen of repeat in the range of 2-6 bp in microsatellite repeats
- If there is a defect in this mechanism, it results in **"Microsatellite instability"**
- Disease associated genes are found very close to the SNPs on the genome and thus have high probability to exhibit linkage disequilibrium phenomenon.

TUTORIALS
LOGIN FOR SUCCESS

MOLECULAR TECHNIQUES IN GENETICS – BASICS AND KARYOTYPING (168)

Diagnosis of genetic disorders

Disease causing mutation is known (such as in case of down syndrome or hemophilie) disorders

↓

Diagnostic Test of choice is Sequencing

↓

If chromosomal mutation disorder such as Down syndrome

↓

We do:

i. Karyotyping
ii. Fish Fluorescent in situ Hybridization)
iii. Sky (5 color FISH)
iv. chromosomal painting (Modification of FISH)

Disease causing mutation is not known

↓

(Such as multifactorial Diabetes type 2, pyloric stenosis) Etc.

↓

We do:

i. Comparative genome Hybridization (CZH)
ii. Gene wide association Studies (GWAS)
iii. Linkage Analysis

AfraTafreeh.com

AfraTafreeh.com

Karyotyping 00:04:45

- Karyotyping means arranging the chromosomes
- Rules for arranging chromosomes are: -

1. Arranged in decreasing order of length of chromosomes largest chromosomes to smallest chromosomes followed by sex chromosomes

   22 Autosomes-1 por of sex chrome

   (1-22) +(xx/xy)

   (Chromosomes have 2 arms)

   i. Short arm called petit arm represented by Callister p

   ii. Long arm represented by 'q'

   (Small letter q because q is the next letter after p in English alphabet)

2. Karyotyping how to be done in 'Metaphase' using colchicine ("Metaphase arrest")

   (This is an advantage since this procedure can only be done by a metaphase arrest)

3. Fixative of choice-CARNOY'S fixative (3:1 ethanol: glacial acetic acid)

   (saccomanno fixative is used in sputum analysis)

4. Trypsin digestion of unwanted pertain to prevent background staining

↓

After these 4 steps, we de staining with Gieman stain

↓

Called "G Banding"

1.IG-Bonding

- We see dark and light staining bonds
- Dark bands correspond to Heterochromatin
- Light Bands correspond to Euchromatin
- Dark bands – Heterochromatin-Rich in 'AT'
- Light bands – euchromatin – Rich in GC.

2.Reverse Banding

- Dark bands correspond to Euchromatin GC
- Light bands correspond to Heterochromatin AT

  (Reverse of G Banding)

3.C Bending

Stains constitutive type of heterochromatin

(Heterochromatin is of 2 types)

↓ ↓

Constitutive Facultative

↓

Present at centromere

4.T Banding

- Stains Telomeres
- Instead of Giemsa **Quinacrine** disc can also be used it is called as "Q Banding
- Quinacrine is a fluorescent dye which binds to both AT & GC regions, but intense fluorescence is seen in AT regions (hetero chromatin regions)

AfraTafreeh.com

- **<u>Silver Nitrate</u>** Staining can be used in karyotyping to Stain "nuclear organizing regions (NORS) NORS are SANA
- 5 bandings-

  G- Giemsa

  R- Reverse

  C- Constitutive heterochromatin

  T- Telomere

  Q- Quinarian

- Karyotyping image-Giemsa stained
- Chromosomes show light and dark areas.
- Light-Euchromatin
- Dark- heterochromatin
- C Banding Image-Only centromere stained (purple)
- Q bonding image
- Pattern some as 6 Banding but this is fluorescent staining AT regien fluoresce more.
- Silver Nitrate Staining - Also called as AgNO & staining

↓ Ag ↓ Silver organizing

↓ NDR ↓ nuclear

- Chromosomal Anomaly
  - Extra x chromosome
  - XXY seen
  - Klinefelter Syndrome

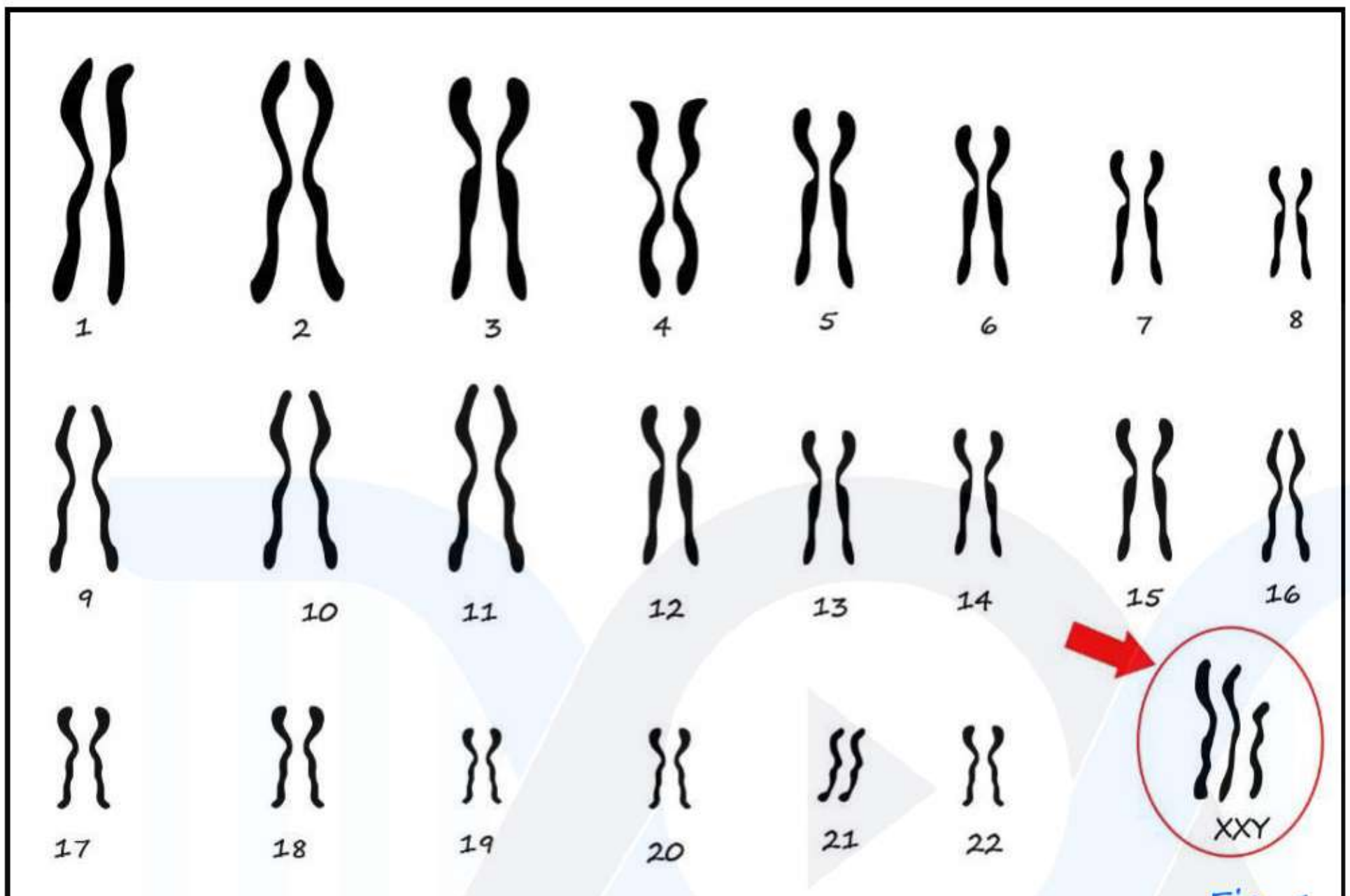

Fig: 1

AfraTafreeh.com
TUTORIALS
LOGIN FOR SUCCESS

- Chromosomal anomaly
  - Extra 21 chromosome -3 in number

    ↓

    Down syndrome -4% cases due to Robertsonian

    Translocation 1 (21: 22) or t (211 14)

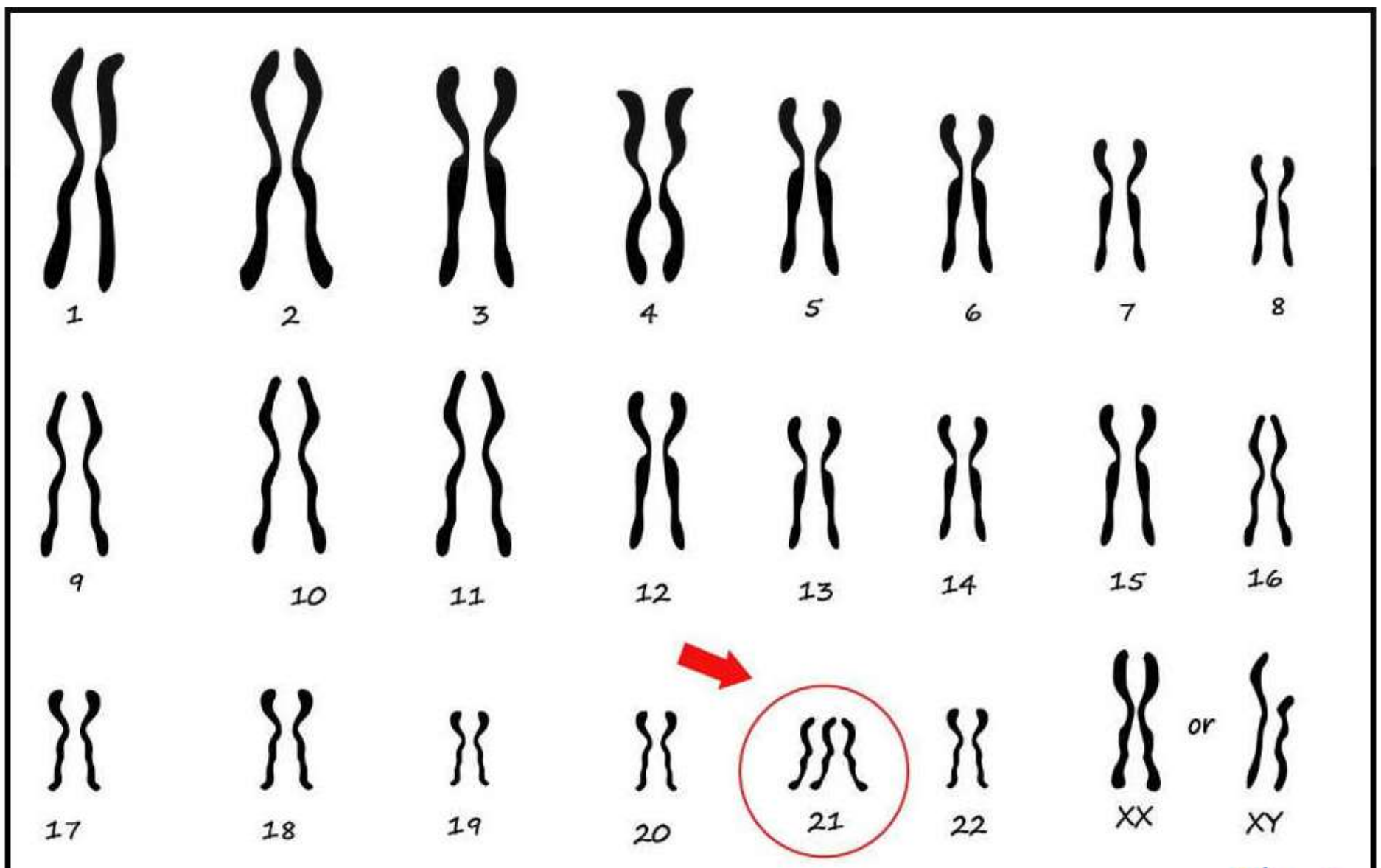

Fig: 2

AfraTafreeh.com

- 1% cases due to Mosaicism,
- Maternal age has no significance in Robertsenian translocation and mosaicism.

• Chromosomal anomaly

3 chromosome 13 seen

↓

- Trisomy 13-Patau syndrome (clinical features cleft up/ palate Malformed case)

Patau syndrome

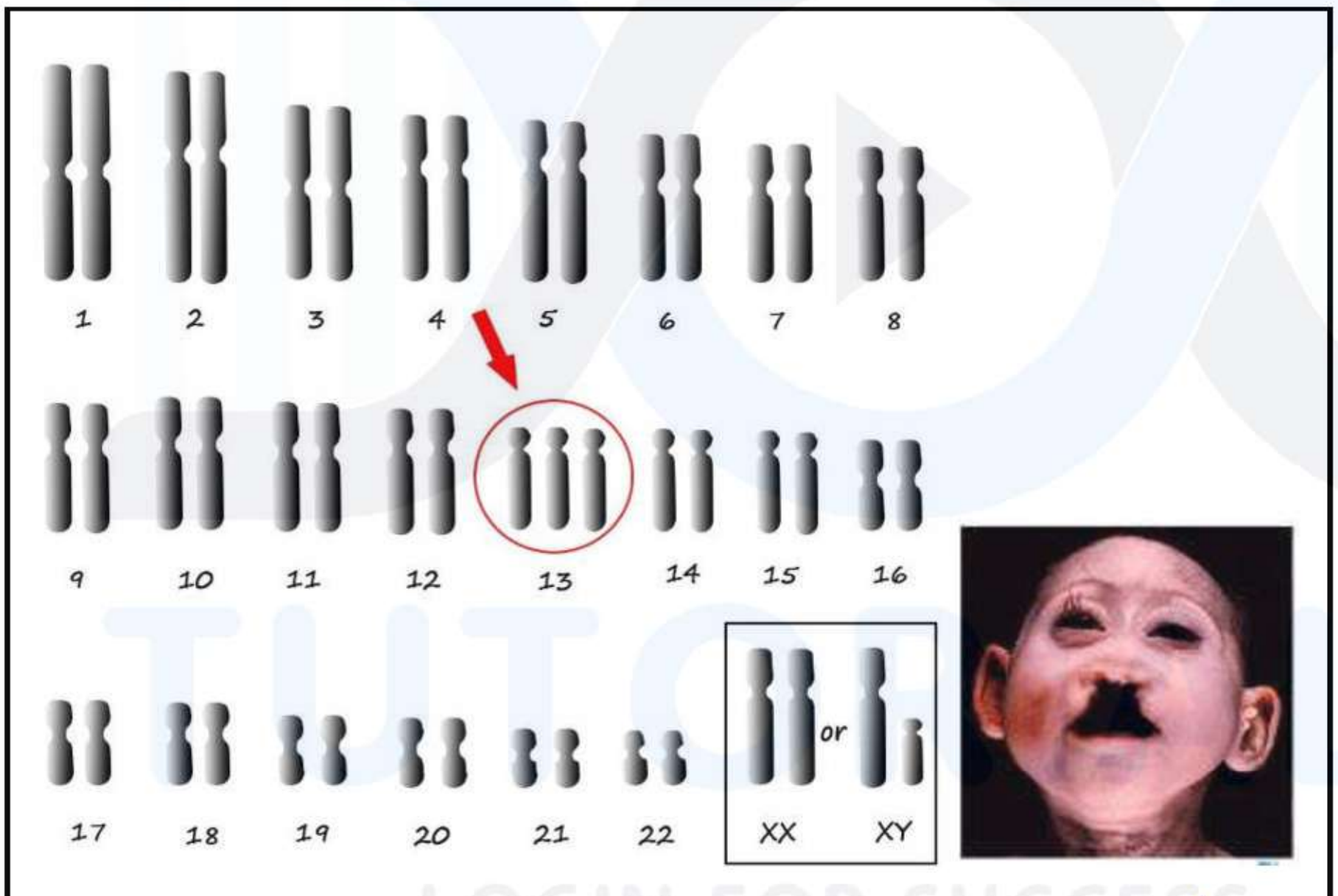

Fig: 3

• Chromosomal anomaly

Only 1 X chromosome present Karyotype XO

↓

Turner syndrome

(IIQ is normal-cystic hygroma)

• Chromosomal anomaly

- Partial deletion of short arm of chromosome 5 is seen
- Cri-du-chat syndrome (5q partial deletion) (Clinical features-small head Cat like cry of child mental Retardation)

Tuner's syndrome

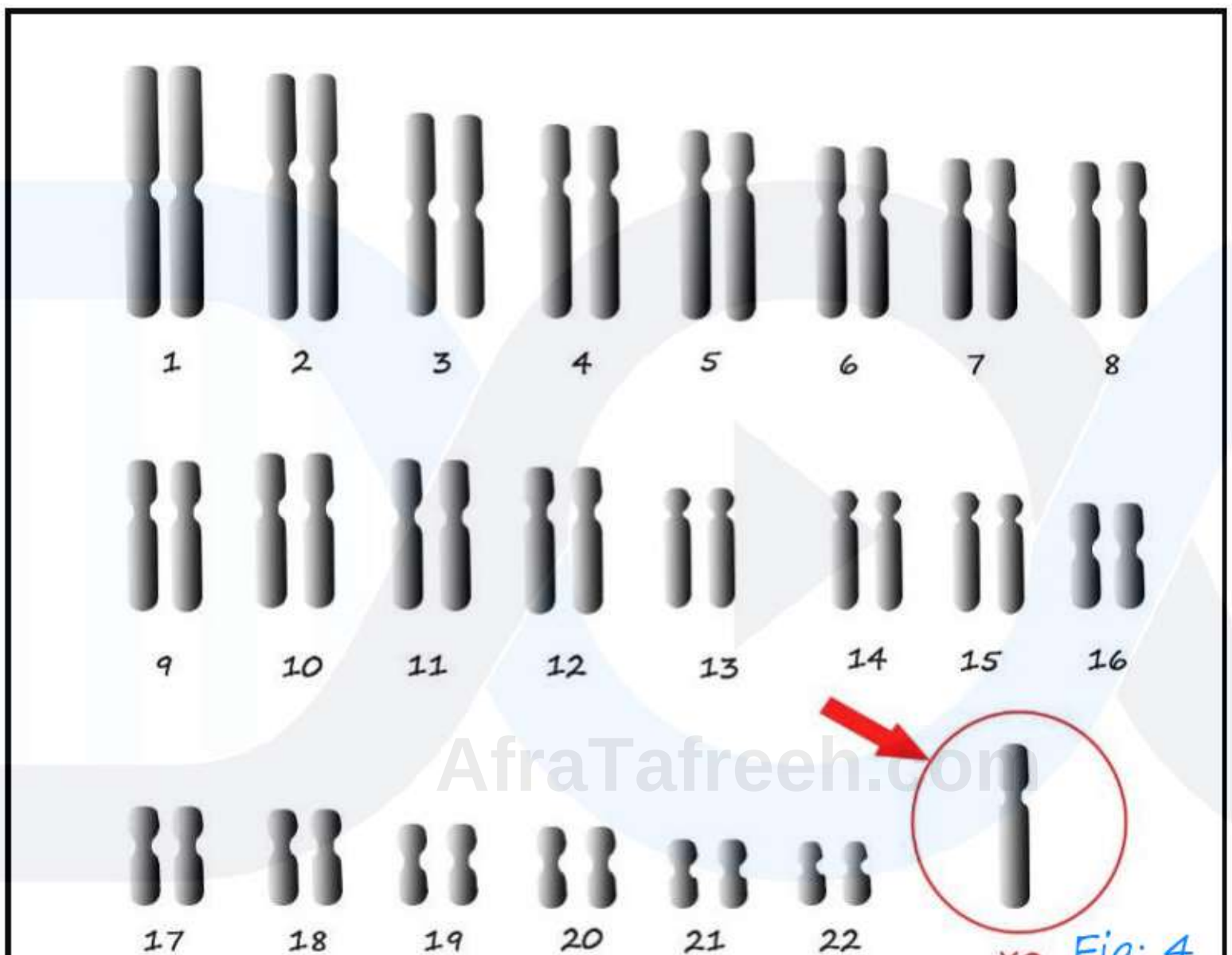

Fig: 4

AfraTafreeh.com
TUTORIALS
LOOK FOR SUCCESS

- In karyotyping lock for -
  i. Number of chromosomes
  ii. Shape of c Shape of chromosome
- Karyotyping can only be done on dividing cells since it has to be done in metaphase (drawback). So, resting cells cannot be Therefore sample for karyotyping nead's to be taken from dividing cells such as -
- Fibroblasts

AfraTafreeh.com

- Blood cells (lymphocyte) (We cannot use monocytes as they can't be made to multiply) Amnion.
- Resolution of Karyotyping – 2–55 million base pairs (Samples used for Karyotyping)

Antenatal	Postnatal
i. Chorionic villus sampling (CVS) (11–13 weeks) ii. Amniocenteses (14–16 weeks) iii. Fetal umbilical blood iv. Circulating fetal DNA (free fetal DNA/ffDNA) in maternal blood.	i. Peripheral Bleed Lymphocytes (not Monocytes) ii. Bone Marrow iii. Slain Fibroblasts iv. Lymph Node tissue v. Solid tumor sample

Idiogram

- It's the diagrammatic representation of pattern of bands within the chromosome
- First you divide the Chromosome
- Region based on the centromere and length of Arms

P arm (short)   q arm (long)

- Now each arm is subdivided into regions

- Starting from close to centromere up to the end of the arm
- Every region is divided into Bands
- (We put a decimal after the region and then write bond no from 1-9) After a single digit band number we can write a angle Sub-band digit Number

  Example:

C	A	R	B	S
1 5	P	1 2	1	2
1 3	q	1 4	2	1

AfraTafreeh.com
TUTORIALS
LOGIN FOR SUCCESS

- Where

  C = Chromosome Ne (1-22/X/Y)

  A = Arm(p/q)

  R = Regions

  B = Bond

  S = Sub bands

Example: 13P 15 5

↙ ↓ ↘ ↘

Chr. Arm (short) Region Band

Example: 13 p 11

↙ ↓ ↘

Chr. Arm (short) Region

AfraTafreeh.com

Example: 11p 13 (WT1) → Location of WT_1 Gene (locus)

↙ ↓ ↘

Chr. Arm (short) Region

Example: 11 p 15.5 → bands → location of WT2 Gene (locus)

↙ ↓ ↘

Chr. Arm (short) Region 13.

TUTORIALS
LOGIN FOR SUCCESS

FLUORCESCENT IN SITU HYBRIDISATION (FISH)

- FISH can be done in interphase (i.e., in resting cells) (advantage of FISH over karyotyping)
- FISH can be done only and only if we know the disease-causing mutation. It can't be done when disease causing mutation(s) is not known.
- FISH requires a "Probe" which is a Complementary copy of DNA which is tagged to a fluorescent molecule Therefore we can use a probe when we know the complementary sequence of the disease-causing mutation on the DNA.
- Normally we use a 2- color FISH
- **Procedure -**

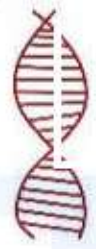 → We open up the DNA →

- If we have If we have to see for example, whether the gene Her 2 Neu – EGFR-B2 (ERG-B2) is amplified or not, we do FISH

↓

Normally only 2 copies of Her 2 Neu are present

(Abnormal)) 1 membrane protein]

↓

2 Copies of Her2 neu

↓

Amplified Her2 Neu le. >2 copies → (Abnormal)

↓

AfraTafreeh.com
TUTORIALS
LOGIN FOR SUCCESS

AfraTafreeh.com

Gene erb β_2 (DNA)

↓ Amplification

Increased RNA synthesis

↓

increased protein synthesis [Her 2 new is a cell

↓ membrane protein

Membrane is completely highlighted on staining (3')

↓

0000=> 3^+ on 1HC (called 3 plus positive) on IHC

↓

- In such 3^+ cases, Trastuzumab (hormonal therapy in breast cancer is effective)
- But if membrane is not completely highlighted (only partial staining), an IHC, it's called 1^+ positivity

↓

In such cases, trastuzumab is ineffective <u>0000</u>

1+ on 1 HC (its regarded as negative)

↓

- Partially positivity which is > 1^+ is called 2^+ and its called 2^+ equivocal positive

TUTORIALS LOGIN FOR SUCCESS

In such cases, we do Fish to look for amplification

0000 ↓

2+/equivocal

↓

On fish of a 2+ sample of 1 HC

↓

2 possibilities

<table>
<tr><th colspan="2">No amplification</th><th colspan="2">Amplification</th></tr>
<tr><td>DNA</td><td>Probes</td><td>DNA
Her 2 Neu</td><td>probes</td></tr>
<tr><td>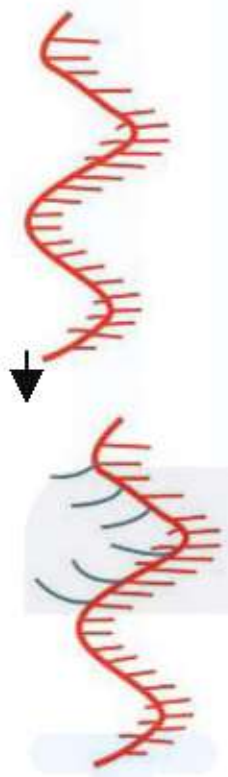
↓
Trastuzumab not useful in this case of + IHC 2+</td><td>
Fluorescent dye</td><td>
↓
shows amplification (more fluorescence)
↓
trastuzumab useful in this case of 2+ IHC</td><td> </td></tr>
</table>

AfraTafreeh.com
DOC TUTORIALS LOGIN FOR SUCCESS

AfraTafreeh.com

- No need to do fish in 1^+ or 3^+ 1HC positive
- Ratio of Her 2 Neu to centromere of chr 17 if > 2.2 indicates Her 2 Neu amplification

$$\frac{\text{Her 2 Neu}}{\text{Centromere of chr17}} > 2.2$$

↓

Her 2 neu amplification

- Down syndrome better diagnosed by fish (by lagging chr 21 to fluorescent dye linked probe) then by kayo

BCR – ABL translocation

↓

BCR – Fluorescent green dye

ABL – Fluorescent red dye

↓

- If translocation between BCR and ABL is present yellow colour is produced on fish by juxtaposition of green dye of BCR and red dye of ABL.
- Diagnostic test of choice for chronic myeloid leukemia (CML) is FISH/PCR (FISH preferred over PCR)
- Five color FISH (called sky)
  i. 5 colors of fluorochromes are used
  ii. Looks like colored karyotype, therefore called spectral karyotyping (Sky)
  iii. Manual interpretation of sky is not possible, it's a computer-based programme.
- Chromosomal painting:

↓

FISH Probes were made for entire chromosomes

PCR AND OTHER MOLECULAR TECHNIQUES

Sequencing

↓

Polymerase chain reaction (PCR)

↓

Amplifies a genome/gene

↓

Done with the rationale that it is easier to pick up a mutated gene when its quantity is more

↓

PCR amplifies the suspected mutant gene, so that it can be detected/ measured.

- Procedure of PCR (Traditional PCR)

  We need –

  i. DNA sample

  ii. Primer Complementary copy of DNA which can activate polymerase also. (a Probe cannot activate polymerase)

  iii. Nucleotides (A.T. C, Gt)

  iv. Tag DNA polymerase: Polymerase elongates the chain

  v. Mix buffer

  vi. PCR tube

  vii. Thermocyctes (the machine for PCR testing)

AfraTafreeh.com TUTORIALS LOGIN FOR SUCCESS

AfraTafreeh.com

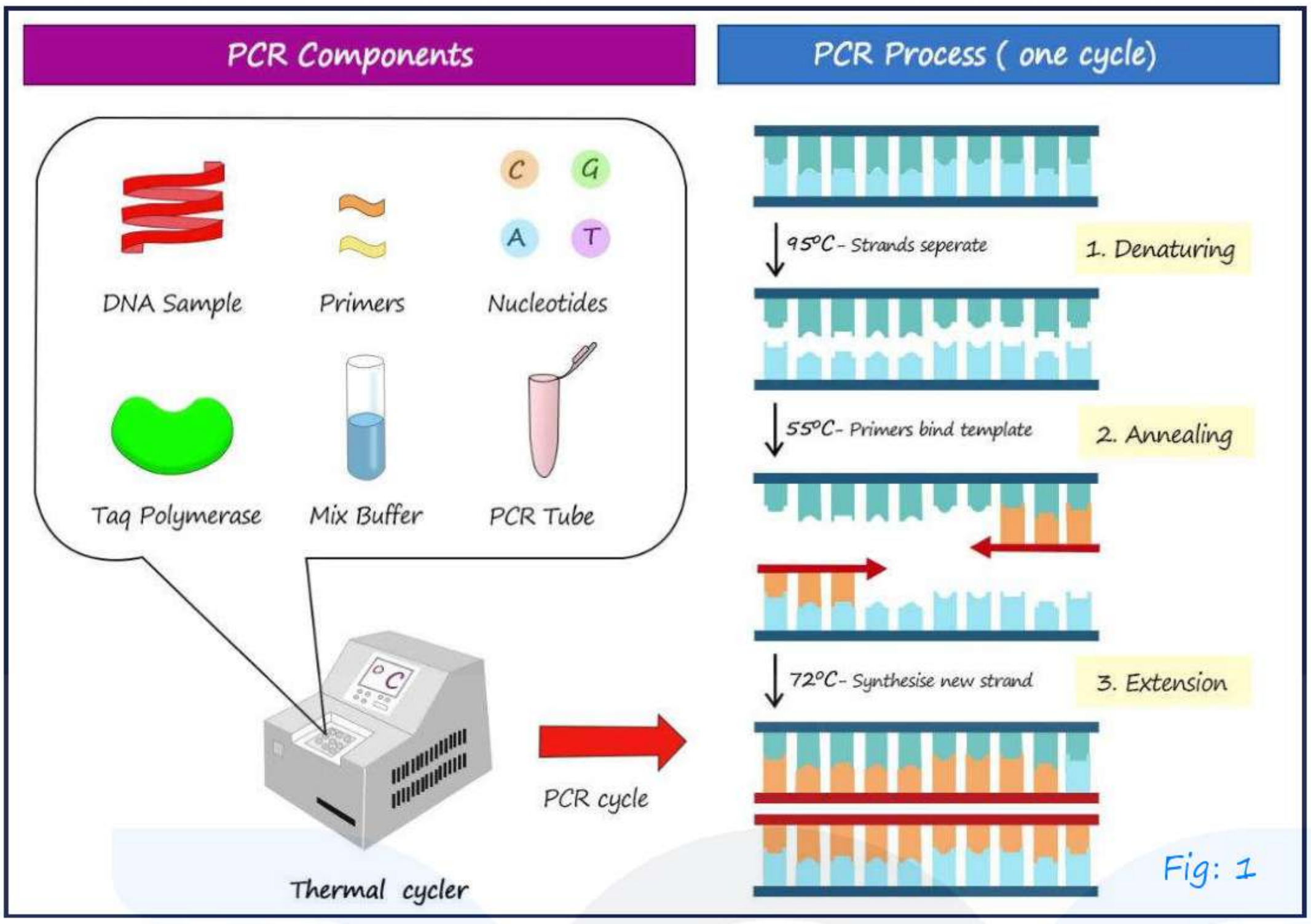

Fig: 1

- Process PCR Cycle

  a) Step 1: <u>Denaturation</u> of parent DNA strands at 95
  Strands separate

  b) Step 2: <u>Annealing</u> Binding of primer to the template DNA segment occurs at 55
  (Does not required fluorochrome tagging)

  c) Step 3: <u>Extension</u> synthesis of new DNA on the template using Tag DNA Polymerase at 72

  - One cycle takes 10 min
  - Cycle goes on until the sample/primer/polymerase etc. exhaust. So, we can make the cycle go on as long as we supply the required materials

  ↓

  - We can stop it by limiting the required materials or by the Procom of chemical stopping

- We can use sanger's technique more commonly stop PCR Chain terminating sequences are used to stop cycle
- (dd NTP) (Gold standard for sequence/determination Sanger's sequencing)
- dd NTP-hove on O-H instead of on (dideoxynucleosides) -OH & these cannot bind to another molecules & thus stops chain synthesis
- Once PCR cycle is stopped after obtaining several copies of genetic material, electrophoresis has to be done to separate out long and short fragments [Electrophoresis is read in 5-3 direction)

- Modification of PCR

AfraTafreeh.com

i. Pyrosequencing: 00:10:05

- We do not do an electrophoresis in this
- We measure the release of pyrophosphate & the emission of light

TUTORIALS LOGIN FOR SUCCESS

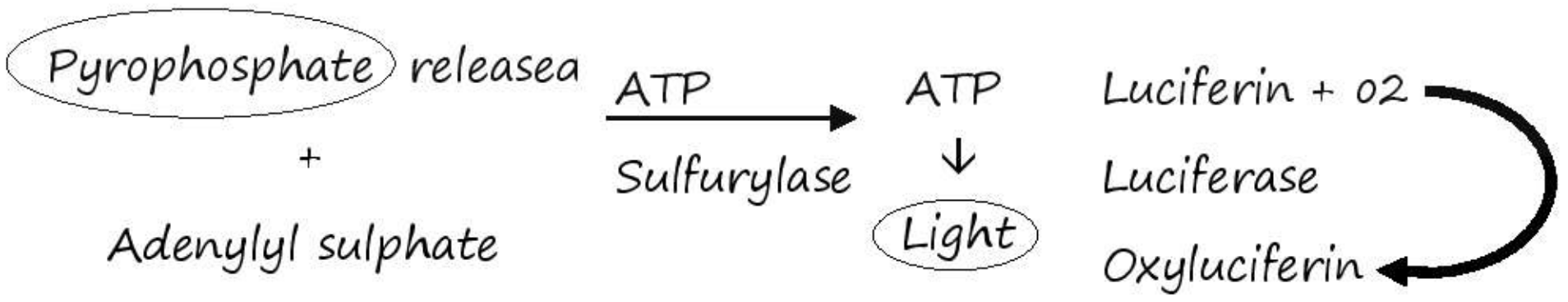

- As little as only 5% of mutant aiieies can be detected by this method

  [Luciferases are present in fireflies]
- Also, very useful for diagnosing cancer cells in biopsies that have a lot of stromal tissue

AfraTafreeh.com

(Biopsies with stromal contamination)

↓

Pyrosequencing is best for this

ii.Single Base Primer Extension – 00:13:31

- Identification of single nucleotide polymorphism which result in disease (such as Factor V mutation)
- Identifying mutation at a specific nucleotide position an oncogenic mutation in codon 600 of BRAF gene.

↓

Tissue sample

↓

DNA extraction

↓

Do multiplex PCR amplification

↓ ↓

Normal Person sequence of BRAF Will have (wild tune) -T- | Mutant -A-

Do single base extension using a CGTA sequence

In wild type the sequence will Attach at A (T present)

In mutant type the sequence will attach at A (Since T is present in the DNA sequence)

- These changes on electrophoresis produce different peaks and thus a mutation at single nucleotide is identified

  Example: Hemochromatosis

  ↓

  Due to mutation in HFE gene,

  1. Most common mutation in HFE gene is C282Y at position 845, G is replaced by A
  2. Another 2nd most common mutation of HFE gene is HE3D mutation, at position 187, C is replaced by G
  3. This means that such mutations can be at variable positions in HFE gene which can all cause hemochromatosis

  ↓

  Thus, in this disorder, RFLP will help in diagnosis

AfraTafreeh.com

iii. Amplicon length analysis: 00:25:55

- This the type of PCR which can be used in trinucleotide repeat mutations like fragile X syndrome
- In fragile X syndrome, genetic disorder due to trinucleotide repeat mutation, there are 3 stages of a trinucleotide repeat mutation, namely –

  i. Normal (20 repeats)

  ii. Permutation (20-55 repeats)

  iii. Mutation (>55 repeats)

AfraTafreeh.com

- In permutation stage, there is doubling of trinucleotide repeats during oncogenesis or spermatogenesis. Thus, the number of DNA molecules is increasing. These extra amplified sequences of DNA are called Amplicons
- These amplicons are measured using amplicon length analysis. (It measured the length of these amplicons), Pieces of DNA, electrophoresis is used for smaller fragments.
  - Diagnostic test of choice for fragile X syndrome: Amplicon length analysis PCR [If the length of trinucleotide repeats is very large, say more than 1000, such large amplicons
  - need southern blotting (Amplicon length analysis is not sufficient)) Therefore, TNR-PCR (Amplicon length analysis)
  - Very large TNR Southern Blot.

TUTORIALS
LOGIN FOR SUCCESS

iv. Real time PCR/qPCR

- Most advanced form of PCR
- Real time PCR is different from RT-PCR (reverse transcription PCR)
- Which is used for conversion of RNA to DNA to identify RNA viruses such as HIV, SARS-CoV2 (covid 19)

- Here we use fluorescent primer. They bind and fluorescence as well as activate polymerase so as the first cycle of PCR occurs,
- Fluorescence occurs, fluorescence keeps increasing (this amplifying fluorescence mean the PCR cycle is occurring errorlessly)
- Used to measure the level of BCR-ABL fusion gene left in a patient of CML during treatment and recovery
- Used to measure somatic point mutations in oncogenes such as KRAS and BRAF.

(For BRAF or RAS oncogenic mutation,

AfraTafreeh.com

- If you know that the condition is running in family (familial) Thus you know the mutation involved.
- If you do not know about the mutation Example: Child presenting with papillary involved

↓

Do a single base primer extension PCR

- An qPCR thus, quantifies presence of particular nucleic acid sequence in real time (i.e during exponential phase of DNA amplification rather than post PCR).

AfraTafreeh.com

MLPA & JIST OF ALL TECHNIQUES

We use 2 primers, they bind together to the target DNA

↓

Step 1: Hybridization

↓

Allow them to covalently join together with the help of ligase enzyme.

Step 2. Ligation (therefore called ligation dependent)

↓

Step 3: Amplification

Mutations which are small-FISH /PCR mutation which are too large for PCR but too small for FISH- MLPA

Example: 27 exons of the CFTR gene in cystic fibrosis detected with MLPA.

DOT TUTORIALS
LOGIN FOR SUCCESS

CGH & GWAS

Disease causing mutation is not known

Comparative genomie Hybridization	Genome wide association studies

I. Comparative Genome Hybridization (CGH)

00:01:05

- A control tissue is mandatory for the test.

  Example:

test tissue (with red Fluorescent marker) 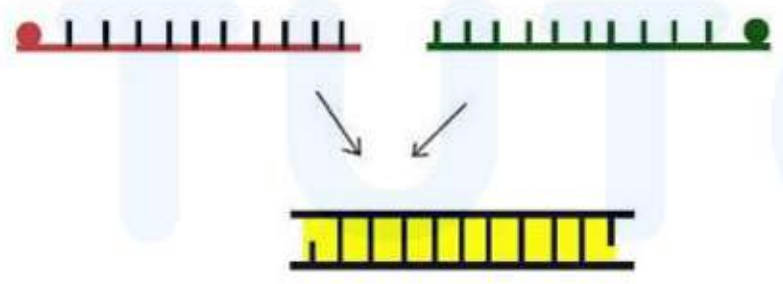	control tissue (with green fluorescent marker) Hybridization will produce yellow color. If test tissue Control normal tissue

- But if there is some extra genetic tissue in the test sample because of duplication of genetic material,

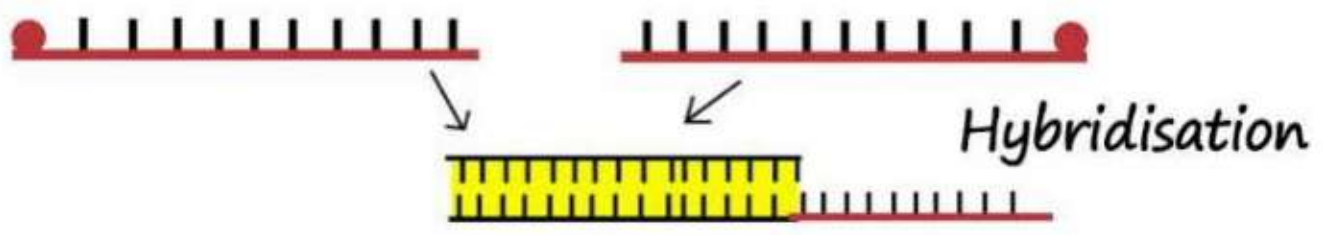

AfraTafreeh.com

AfraTafreeh.com

- Hybridized part imparts yellow color, unhybridized part of control/normal tissue imports green color, which is picked up an applying that the test sample has a deletion
- Thus, CGH can detect just 2 types of genetic changes
  1.Duplication
  2.Deletion
- Use only 2 color labels-Red and Green
  Normal yellow colour
  Duplication: Red colour
  Deletion Green colour
- Array CGH - (Array means micro array technique used in CGH)
- It is done when you want to de CGH to detect duplication or deletion on a large sample size/population /group of people
  Example: Identification of some deletion in a group of students

TUTORIALS LOGIN FOR SUCCESS

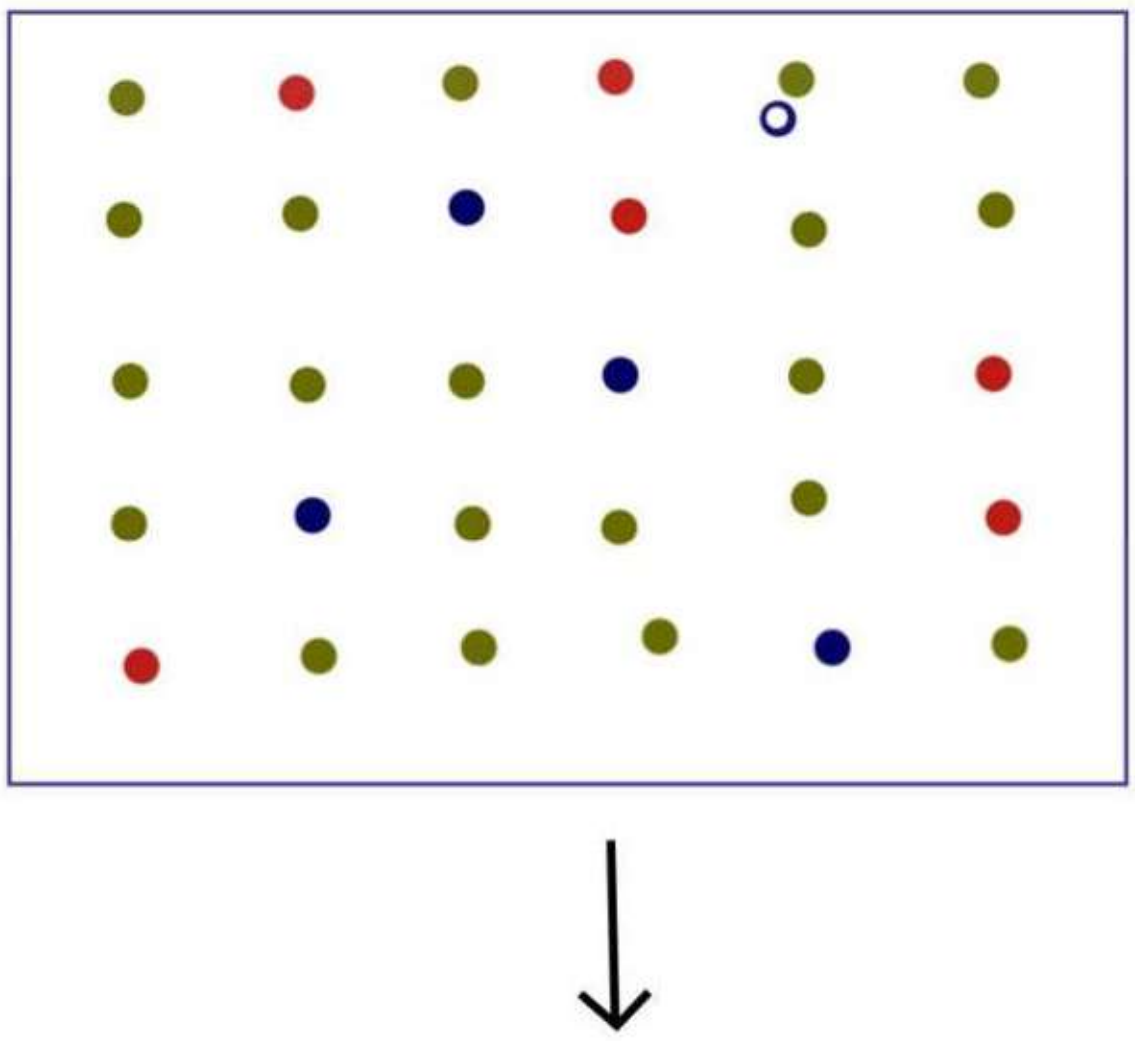

- A microarray test with multiple wells for multiple samples and test.
- Yellow: Normal test for individual
- Red: Duplication of gene
- Green: Deletion of gene

II. GWAS 00:15:44

- GWAS is done in a cohort of patients and polymorphism are studied in this cohort to look for one particular polymorphism that is common in this cohort and may be associated with a certain i disease in this cohort.

AfraTafreeh.com
TUTORIALS
LOGIN FOR SUCCESS

AfraTafreeh.com

MICROARRAY

Microarray

Tissue Microarray	Gene Microarray
↓ Take a wax black with Punched out holes ↓ Put samples in these wells ↓ Example: Tissue samples from several Breast cancer patients are taken and put into the well and the Wells labelled (core of tissue Sample is put), then they are studied on a single slide -Even hormonal slides (ER/PR/Her 2 neu) can be done	↓ Tumor tissue → CDNA / Normal tissue → CDNA -Takes a microarray chip will wells in it Add oligonucleotides which are -complementary to these CDNAS Color is produced ↓ Interpretation is similar to CGH (CDNA of tumor-Red color CDNA of control-Green) Example: Mammaprint

- **Mammaprint:** It's a 70 gene microarray for breast cancer

DOI TUTORIALS LOGIN FOR SUCCESS

- All Her 2 new positive breast cancers cases did not respond equally to trastuzumab therapy

Some responded well	Some did not show any recovery/improvement
↓	↓
This was because of expression of different genes →	This is why we developed MammaPrint to determine the genetic expression and effectiveness of trastuzumab on case-to-case basis.
↓	↓
Good signature on MammaPrint	poor signature on MammaPrint
↓	↓
Responds well to Transtuzumab therapy	Does not Responds well to Transtuzumab therapy

AfraTafreeh.com

TUTORIALS

LOGIN FOR SUCCESS

AfraTafreeh.com

GENE EDITING

- Effects of genes is mediated by proteins

DNA → mRNA → Proteins → Effect

↑ X	↑ X
Knock out technology (By CRISPR) (Blocks DNA)	knock down technology (By mi RNA) (Blocks RNA)

- Blocking of DNA/mRNA impairs protein synthesis and the effect of given DNA/gene

1.Knockdown Technique

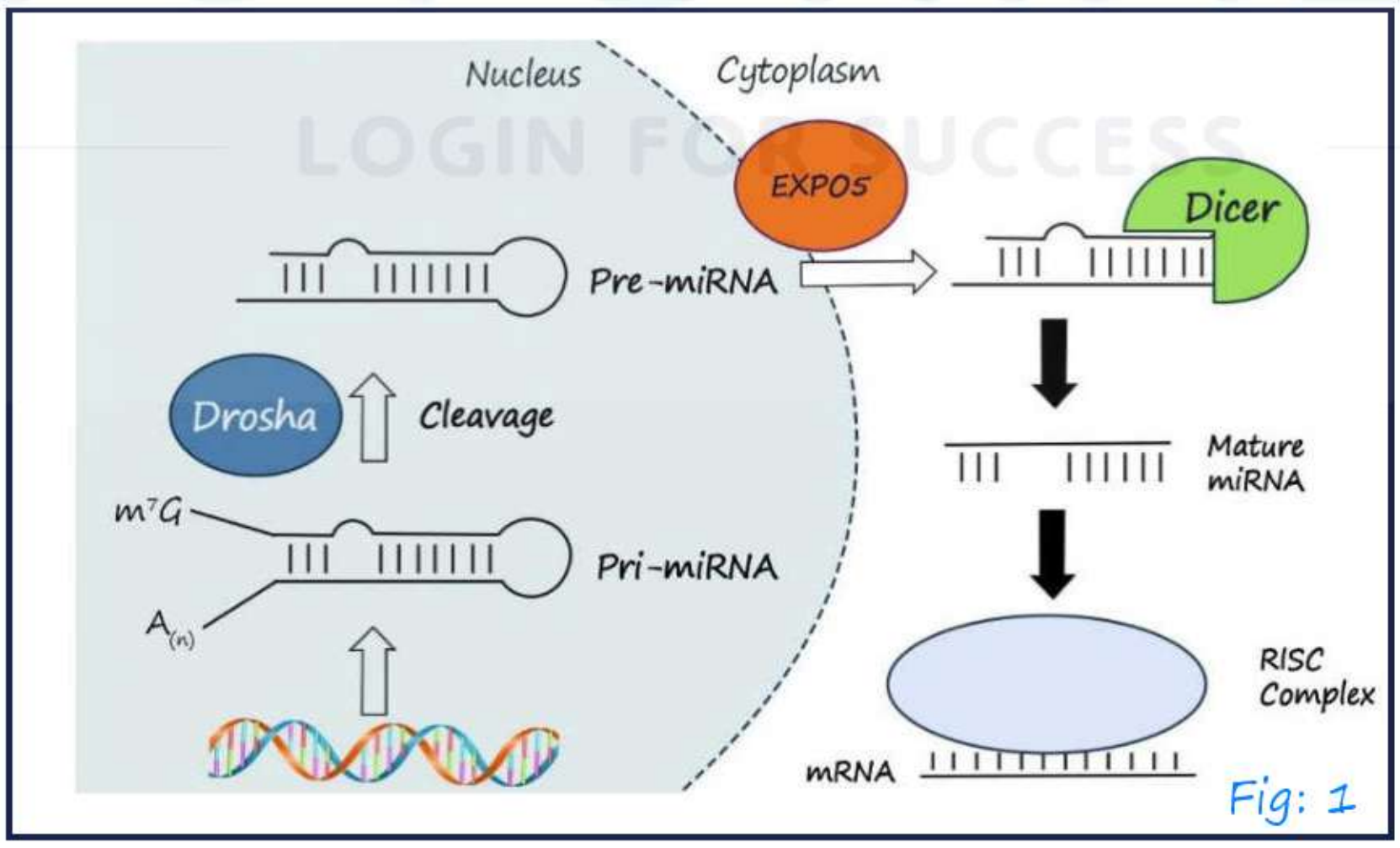

Fig: 1

DNA
↓
Pre-miRNA
↓ cleavage by DRDSHA
Pre-miRNA
↓ EXPOS-transport out of nucleus
Pre-mi RNA in cytoplasm
↓ DICER enzyme (cleaves de RNA to single strand)
Mature mi RNA (55RNA)
↓
RISC Complex (Ribosomal induced silencing
↓
miRNA
↓
Silences target RNA

AfraTafreeh.com
TUTORIALS
SCCM FOR SUCCESS

- Mi RNA is exact complement of target RNA → it will break the target RNA
- Even if mi RNA is not an exact complement but still binds to the target RNA and prevent ribosomal attachment and subsequent protein synthesis

"Gene silencing"
98.5% genes in humans are silenced
↓
By
1. Epigenetics

AfraTafreeh.com

2. miRNAs

Synthetic mi RNA: SI RNA (Small Intervening RNA)

↓

(Drawback) Use Of mi RNA/SI RNA does not permanently silence genes (in treatment of diseases Eg Sickle cell diseases) Since the mutant gene is continuously producing the mutant RNA and protein

miRNA 15, miRNA 16: associated with CLL

↓

Silenced in CLL → Result in cancer

-DICER Mutations sex chord stromal tumours sertoli/leydig cell tumors

↓

(DICER is required for synthesis of natural miRNAs in body).

2. Knockout Technology 00:15:10

- Involves CRISPR (clustered regularly interspaced short palindromic Repeats), also called as genetic scissors, which allows permanent modification of genes. [In sample language, CRISPR cuts the target gene (knocks out gene) to present formation of unwanted /mutant proteins)
- CRISPR is not present in humans, its gene is present in bacteria as defense against bacteriophages

↓

CRISPR molecule produced in bacteria

↓

gets converted to g RNA

↓

- Utilisier CAS 9 (CRISPR associated 9), which is a powerful gene scissor, to cut viral DNA by causing double (CRISPR-CAS9 does not need to be complementary to phage DNA to destroy it)

Genetic engineering in gRNA

gRNA

Constant region	Variant region
↓ Always binds to cas g and produces double stranded breaks	↓ Genetically engineer ↓ New genes can be attached here ↓ Constant region introduces double stranded breaks new DNA which can attach to variant region now combines with these cuts by the process of Homologous DNA Recombination (HDR) ↓ Thus, the new' Donor DNA is now a part of the original DNA ↓ This is called as DNA Transplantation.

AfraTafreeh.com

AfraTafreeh.com

- Now if variant region does not have any gene, then the ds break in original DNA join with each other by non-Homologous end joining (NHES) Since the ends are not complementary.
- CRISR Technology can produce a permanent change in DNA/genome. Thus, no human trials are allowed.

TUTORIALS
LOGIN FOR SUCCESS

UNDERSTANDING PEDIGREE ANALYSIS

● female

□ male

■ Affected

⊘ ⧄ Deceased

□ ○ ○ ○ Twins

[○] / [□] Adopted

▲ Miscarriage

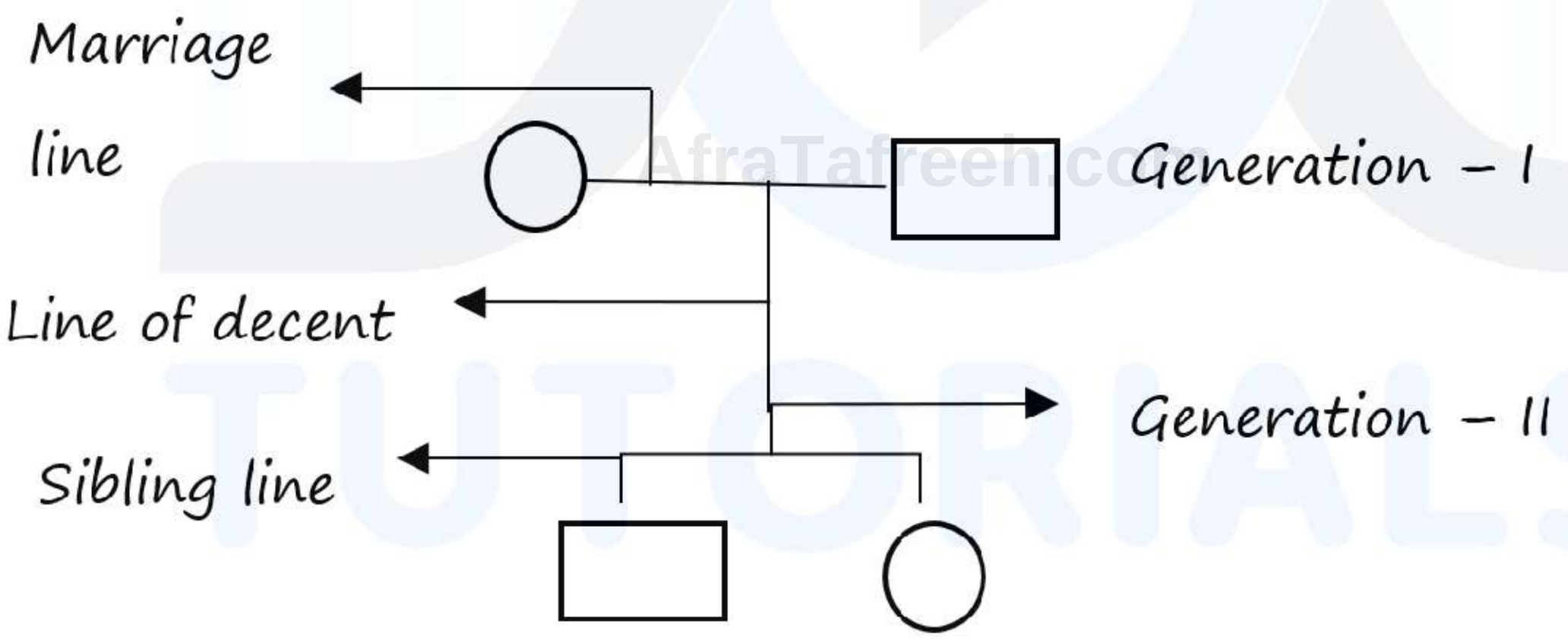

AfraTafreeh.com

How to solve a pedigree in 2 minutes?

Autosomal	Dominant (D)	Unusual
• Dominant (D) • Recessive (R)	Recessive (R)	• Pseudo dominant • Gonadal mosaicism • Holandric • Mitochondrial

- Autosomal recessive always has complete penetrance and uniform expression.
- Autosomal dominant (AD) is vertical inheritance
- Autosomal recessive (AR) is Horizontal inheritance

AD	AR
• Both males and females affected • no skipping of generations • affected parents can have unaffected children but if child is affected parents should always be affected	• Both males and females affected • skipping of generations is seen • unaffected parents may have affected children.

TUTORIALS LOGIN FOR SUCCESS

Example:

1..

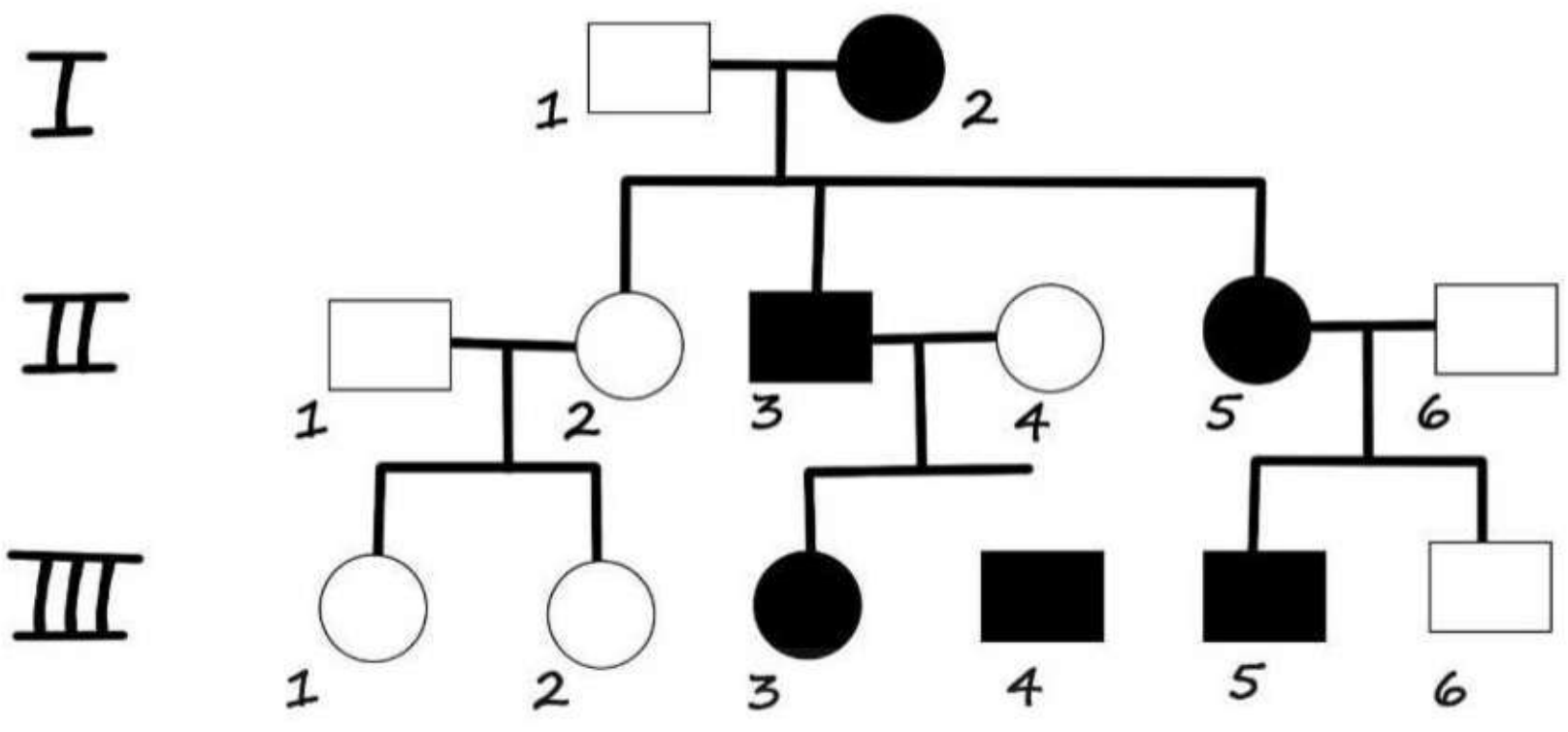

- Both sexes involved
- All generations affected (no skipping)
- Affected parent has an unaffected child, but when a child is affected, parent is also affected in all generation

↓

Therefore, AD pedigree

AfraTafreeh.com
TUTORIALS
LOGIN FOR SUCCESS

2..

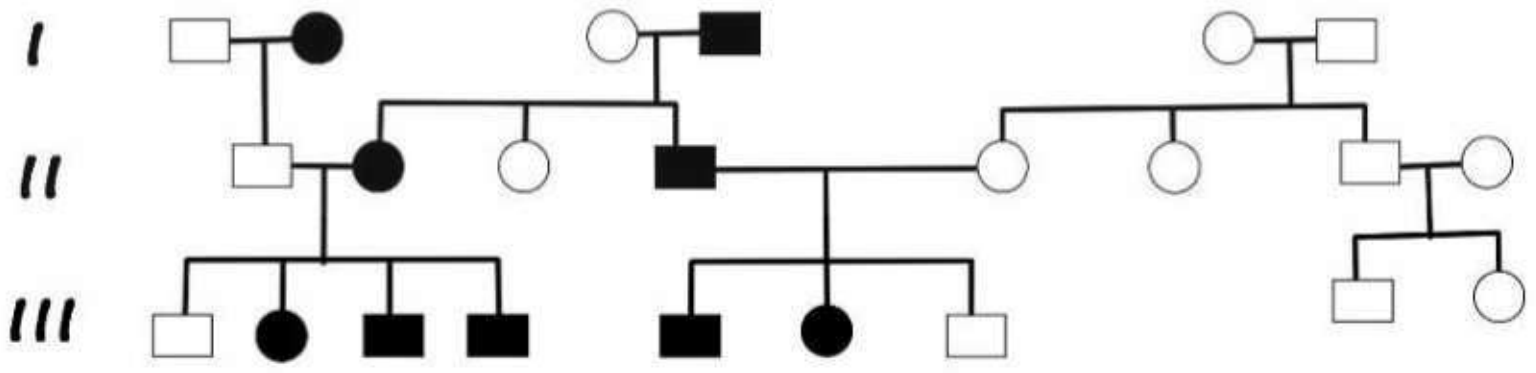

- Both sexes involved
- All generations affected
- Affected parent → unaffected child +

+

affected child always parent affected

↓

AD Pedigrees.

3.

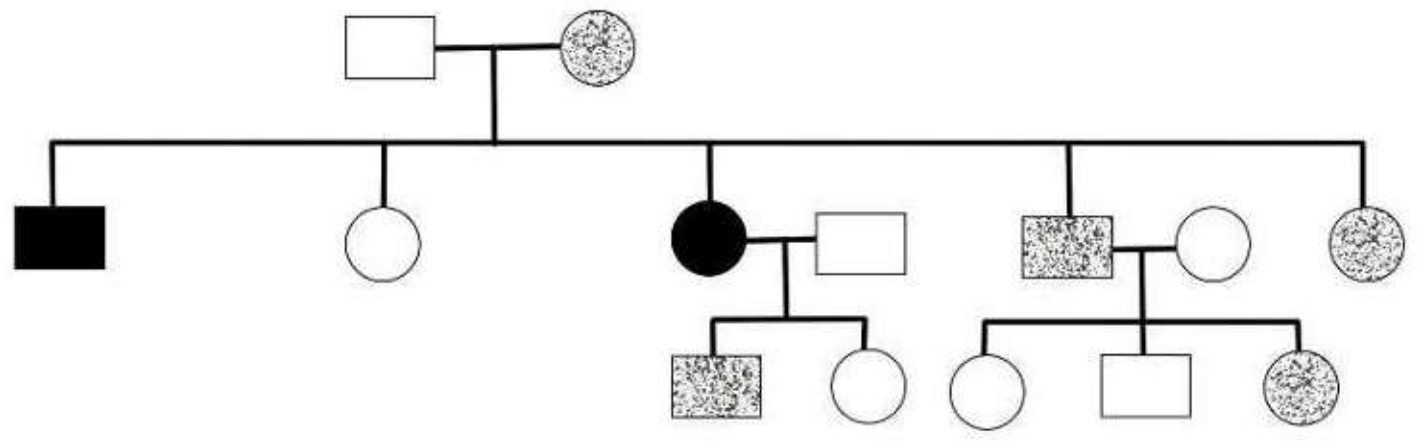

- Both sexes involved (indicates Autosomal disorder)
- Skipping of generation
- unaffected parents affected child

↓

AR Pedigree

4..

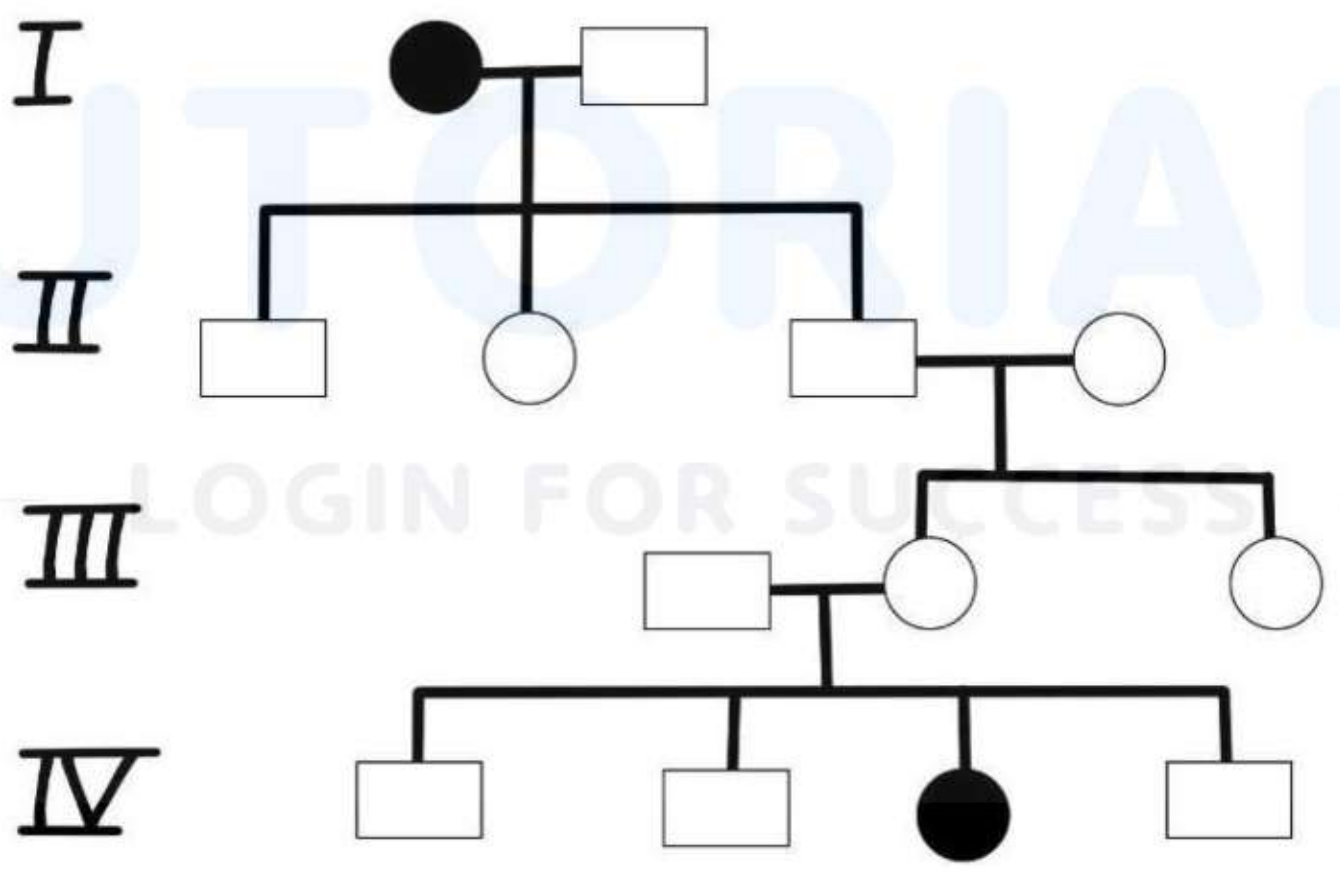

X linked Dominant (XLD) ↓	X linked Recessive (XLR) ↓ -Males are mere affected than females

-Never transfer from father to son -If father is affected all daughters are affected	(How can females be affected? → v. v. rare) ↓ 1 Heterozygous female marrying an affected male 2. Lyonization of normal x chromosomes in a heterozygous female -Father to son transfer never seen -Mather to son transfer is seen (Affected son) -Father to daughter) Transfer → daughter becomes carrier

AfraTafreeh.com
TUTORIALS
LOGIN FOR SUCCESS

Holandric

- Father → sons (y – linked)
- Only males are affected

5.

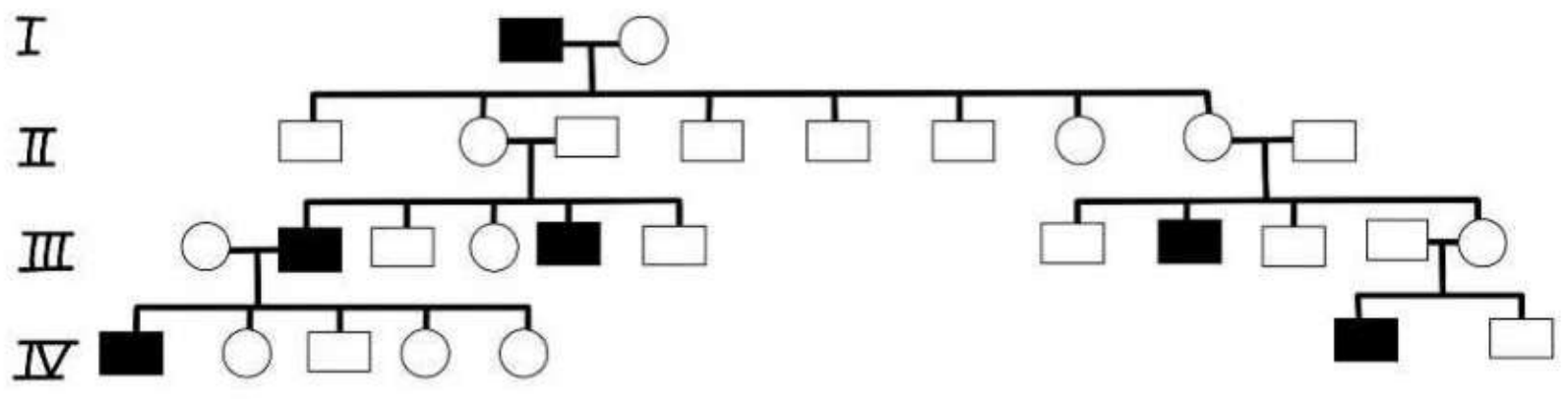

- Males affected only
- Father to son no transmission

AfraTafreeh.com

- No female affected

↓

XLR Pedigree

6.

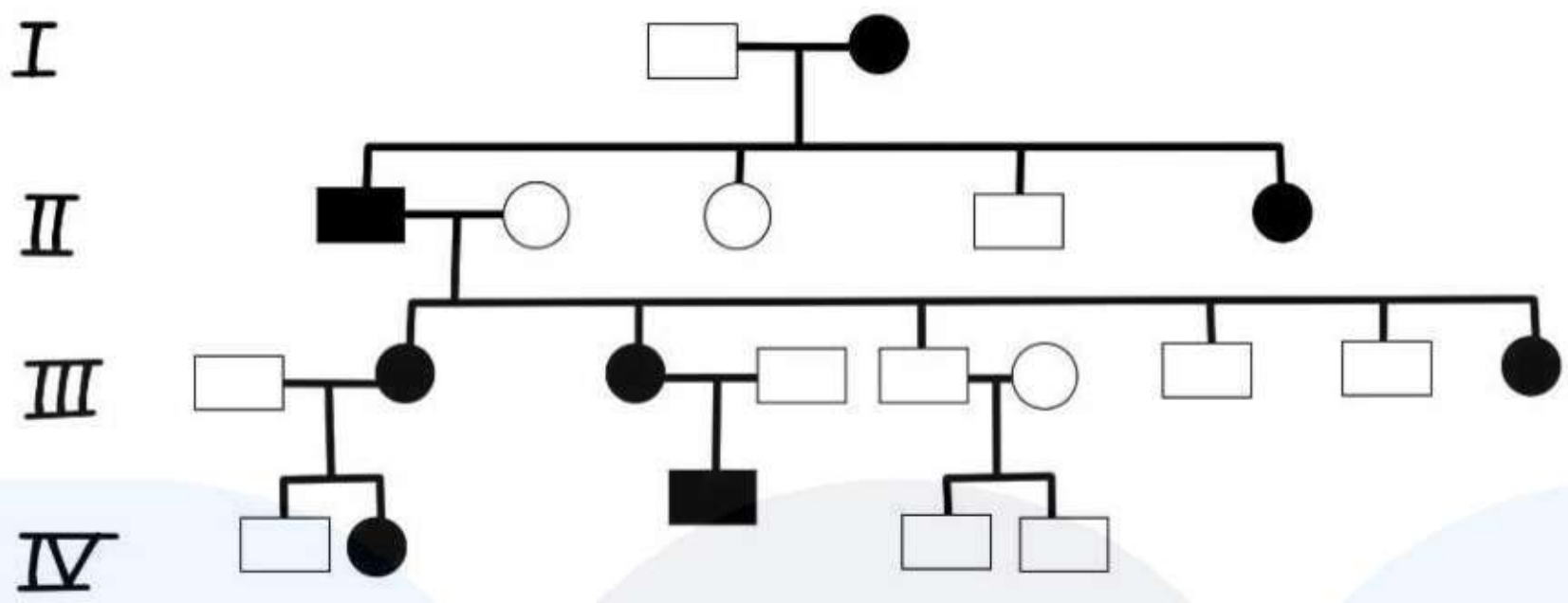

- Both sexes affected
- Mother to son affected
- Father to son not affected
- All daughters of affected father are affected

↓

XLD Pedigree

7.

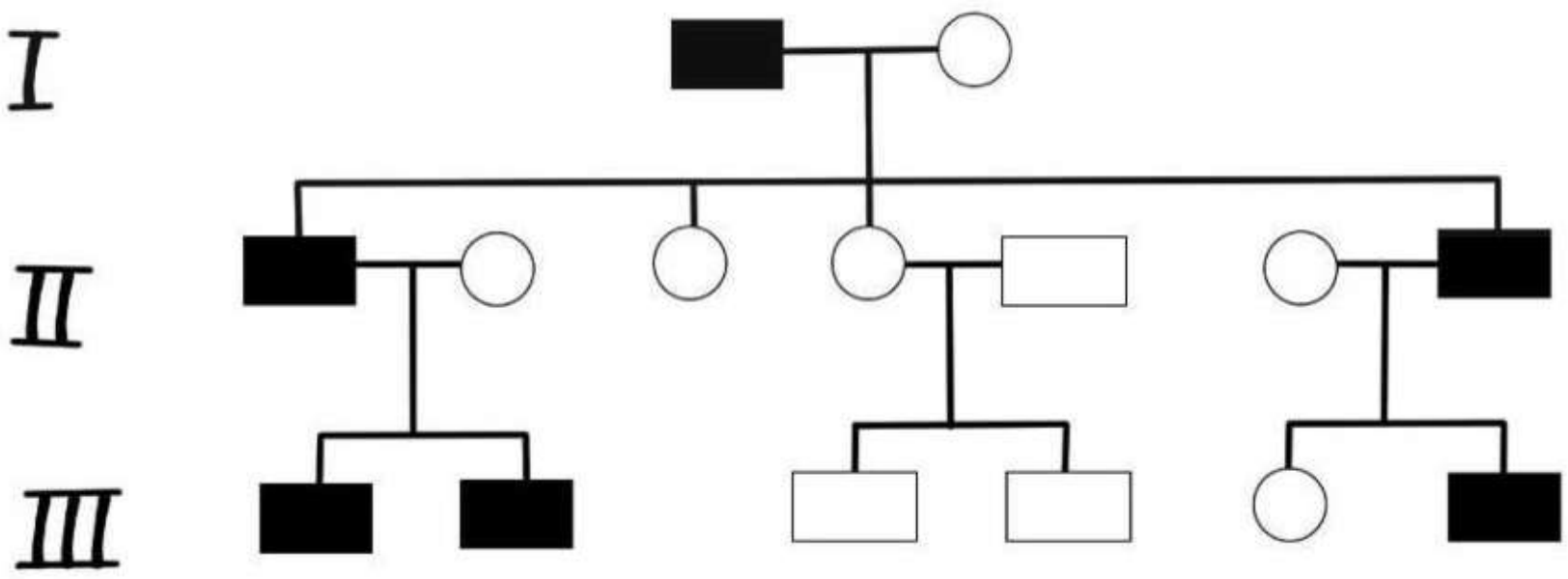

- Sons of affected males affected
- Only males affected

↓

Holandric pedigree

8.

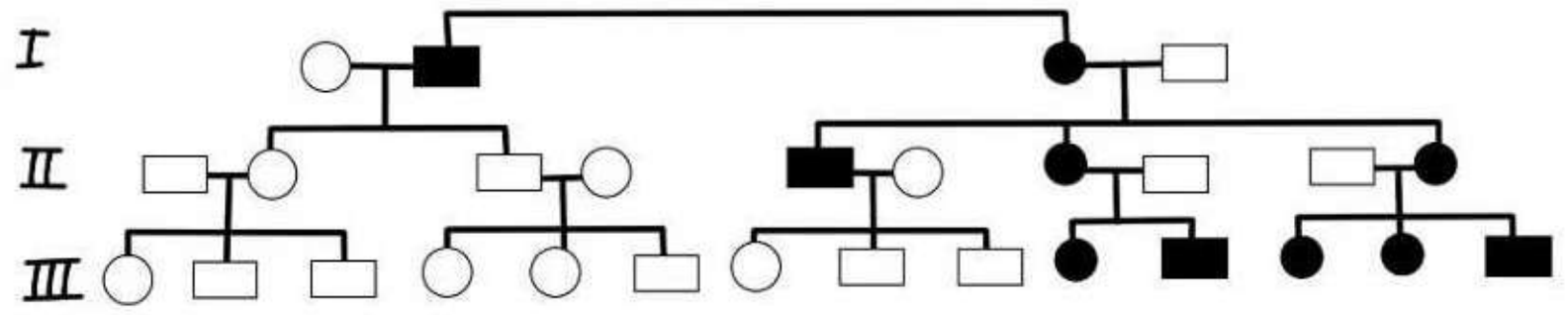

- Both sexes affected
- All progeny affected when mother is affected
- No progeny affected when father is affected

↓

Mitochondrial inheritance

9.

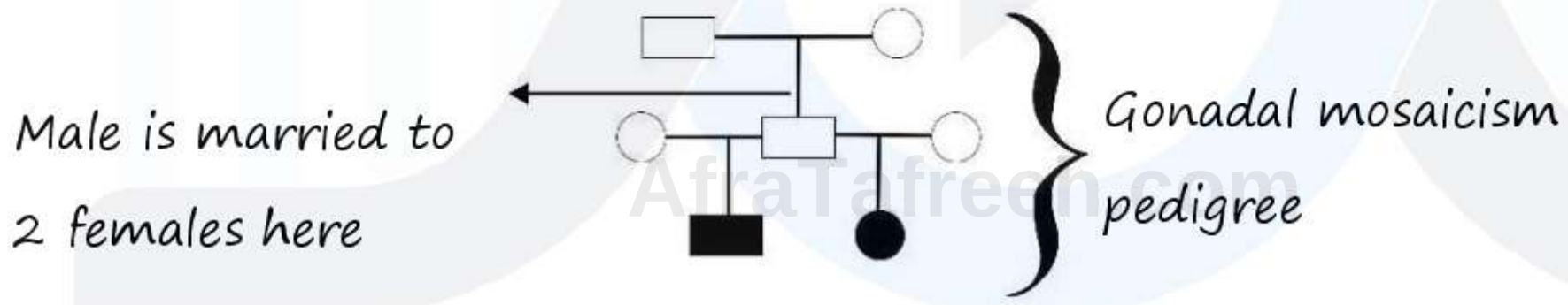

- Phenotypically person is normal
- Only gonadal genes are mutated to transfer disease to all the progeny
- Gonadal mosaicism is a cause of several new mutations now a days
- In the pedigree, the male who married two females has gonadal mosaicism and given the disease to both his children (Generation I and II were normal, generation III showed a new mutation)

AfraTafreeh.com

10.

- Pseudo dominance-
- Occurs when a diseased parent marries a heterozygous parent

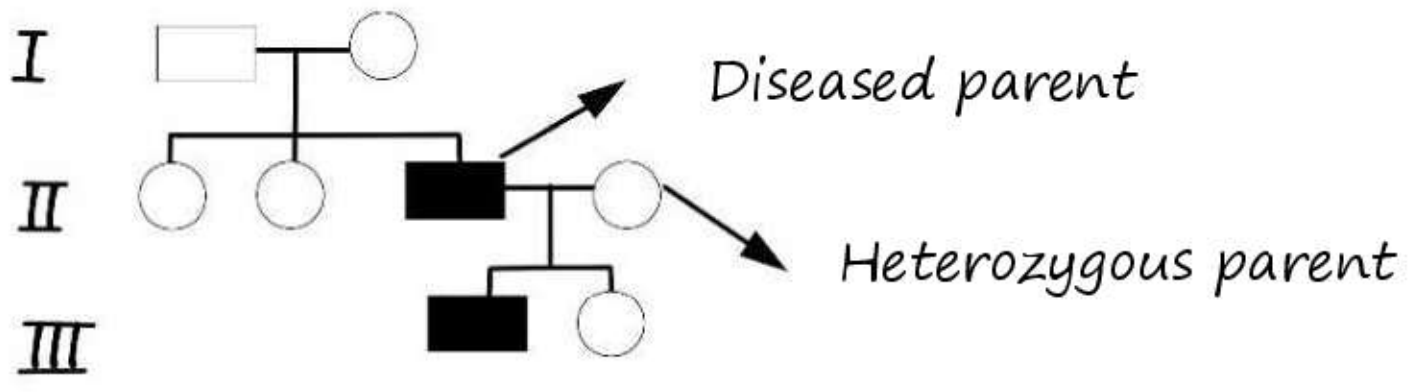

- Here the heterozygous spouse also has the disease gene buy does not express the features of the disease
- The progeny of such couples is 50% affected and 50% carrier.

11. .

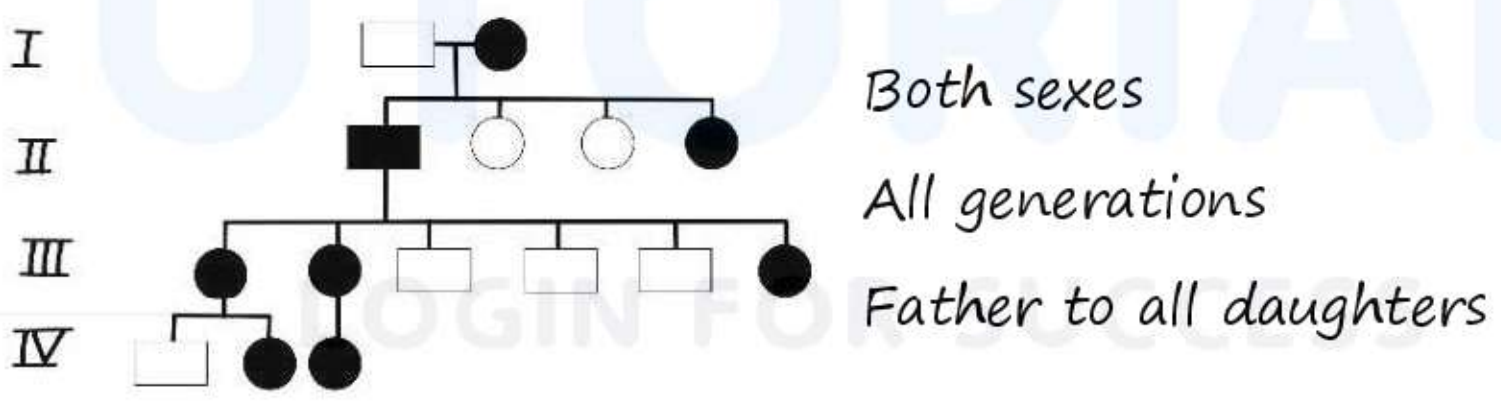

↓

XLD pedigree

12.

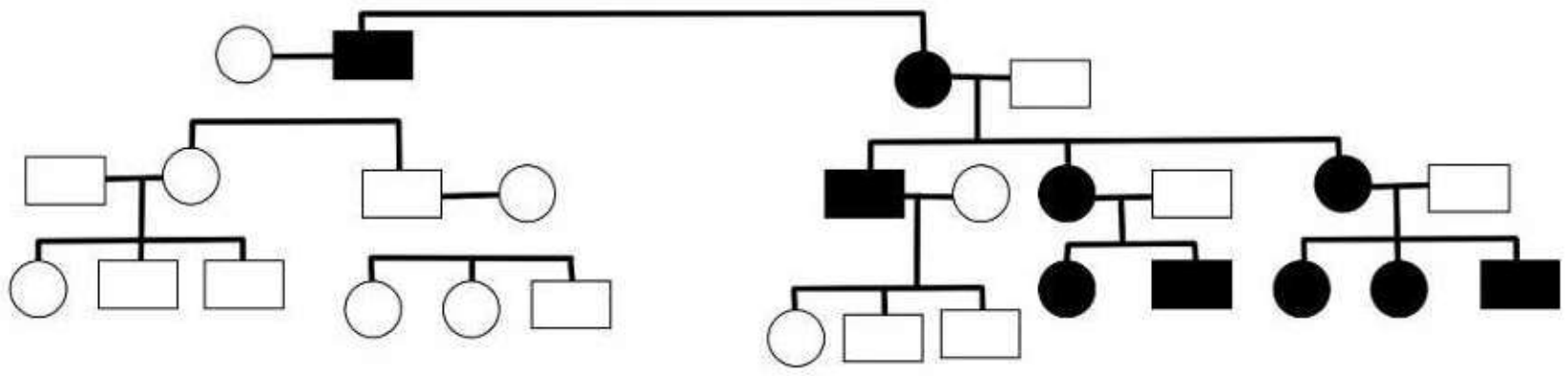

Transmission from mother to all children mitondrial inheritance

13.

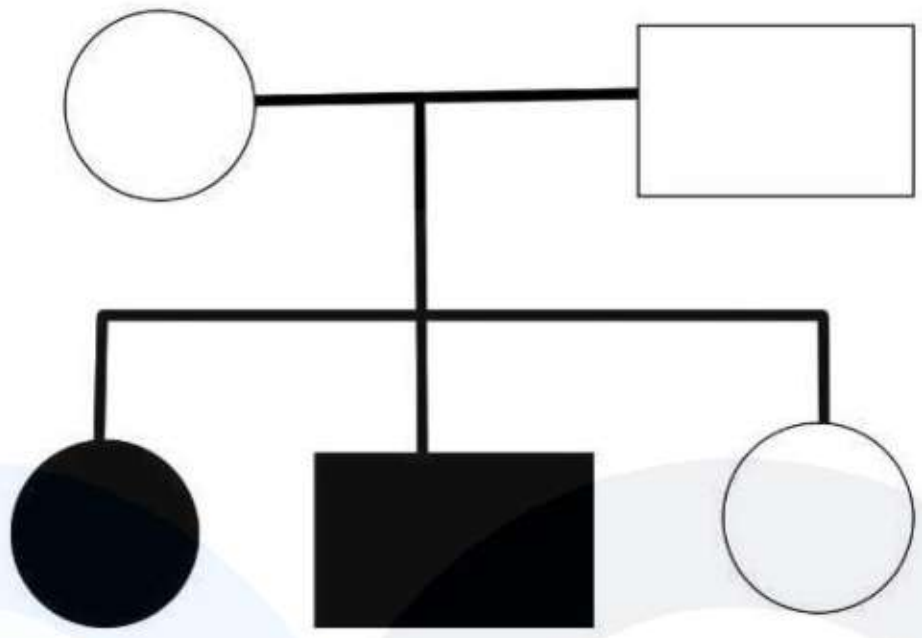

No parents affected only 2 children affected

↓

Could be gonadal mosaicism or Autosomal recessive.

AfraTafreen.com
TUTORIALS
LOGIN FOR SUCCESS

AfraTafreeh.com

AUTOPHAGY AND R-10 UPDATES

i. Autophagy
ii. Endoplasmic stress
iii. Eat me signals

I. Autophagy 00:01:22

- Cells eats itself
- Three types of autophagy
  i. Macro autophagy
  ii. Micro autophagy
  iii. Chaperone associated to do autophagy

  Dedicated organelle to do autophagy

  ↓

  Phagophore
- mTOR – masker of well-being, good nutrition
- initiation of autophagy (macro & autophagy)
  a. absence of mTOR
  b. ULK complexes release beclin -1 stimulated phagophore formation
  c. Phagophore combines with lysosome to form phagolysosome

Initiation of micro autophagy

- Lysosome form invagination and killing occurs

  chaperone mediated autophagy

- Misfolded proteins tagged with chaperone
- Repair or lysosome – LAMP2A (lysosome associated membrane protein 2A)
- LAMP 2A identified chaperone protein and engulf & kill misfolded proteins

Sequential steps in phagophore formation

I. Phagophore Initiation
   - Elongation of phagophore by microtubules light chain 3molecule [LC3]

II. Fuses with lysosome formation of phagolysosome
   - Marker of autophage LC3
     - Genes controlling autophagy
     - ATG 5-most important gene involved in autophagy.
     - Tuberculosis.
       - Mutation in Atg5

         ↓

       - Absence of autophagy
     - ATG 16L1-Autophagy gene Mutated in Crohns disease.
     - Autophagy detected in following diseases

I. Cancer

II. Neurodegenerative disease
   a. Huntington
   b. Alzheimer's

AfraTafreeh.com

III. Infectious diseases – Mycobacteria, shigella, HSV-1

IV. Inflammatory bowel disease

a. Crohns disease (ATG16L1)

b. Ulcerative colitis

New updates in robins 00:24:39

Eat me signals-Markers an apoptotic cell

i. Phosphatidyl serine

ii. Thrombospondin

iii. C1q

- Unfolded protein response is called adaptive unfolded protein response
- It increases chaperone,
- Decrease protein synthesis
- Increase protein degradation severe ER stress
- Terminal unfolded protein response leads to activation of BH3 molecules and leads to apoptosis

TUTORIALS LOGIN FOR SUCCESS

Diseases caused by misfolded proteins leading to their deficiency

I. Cystic fibrosis

II. Tay sach's diseases

III. Familial hypercholesterolemia

- Diseases caused by misfolded proteins that result is both ER stress induced cell loss
- Alpha 1 Antitrypsin Deficiency – Emphysema

Entosis:

- cell-eat-cell form of cell death
- entosis is a type of cellular cannibalism in which cells that are not professional phagocytes engulf nearby Living cells
- For example, hepatocytes may ingest & destroy autoreactive T lymphocytes thus inhibiting Experimental autoimmune liver diseases
- Vacuoles containing cells undergoing entosis may fuse with lysosomes, in which Target cells usually die.

AfraTafreeh.com
TUTORIALS
LOGIN FOR SUCCESS

AfraTafreeh.com

Difference between hyperemia and congestion

Difference between hyperemia and congestion

00:01:41

Hyperemia	Congestion
• Result of Arteriolar dilatation • Active Process • There is increase in volume of blood reaching a particular tissue • Affected Tissue is **REDDENED** because of engorgement with Oxygenated Blood	• Result of Venous obstruction • Passive Hyperemia • There is Stagnation of Blood in a particular tissue • Affected tissue appears bluish-red due to accumulation of deoxygenated Blood • In chronic venous congestion (CVC), there is long standing accumulation of deoxygenated bleed & hence there is a damage to the tissues

DOCTUTORIALS LOGIN FOR SUCCESS

Heart Failure

Left Heart failure

Pressure into Pulmonary Vein

↓

CVC Lung

Right Heart failure

Pressure into Pulmonary Vein

- **CVC Liver**
- **CVC spleen**
- **CVC Kidney**

"Always starts as an Acute Congestion – Becomes Chronic over time"

CVC LUNG 00:05:01

Cause of CVC Lung – Left heart failure

Gross Appearance

A. Lungs are heavy

B. Appear Brownish in colour → Brown Induration of the lungs

Brown induration of lung seen in cut section

Fig: 1

Pathogenesis

A. Macrophages of Alveoli (Dust Cells – consume carbon pigment).

AfraTafreeh.com

AfraTafreeh.com

B. The alveolar septa appear widened & fibrotic (Widened Interstitium). Alveoli are dilated and contain oedema fluid, RBCs and macrophages

C. Due to the massive stagnation, rupture of the congested vessel occurs resulting in oedema hemorrhage. Macrophages consume the excess RBCs from the congestion. Hemoglobin is broken down into Hemosiderin **(HEMOSIDERIN LADEN MACROPHAGES)**

D. Also called as **HEART FAILURE CELL**

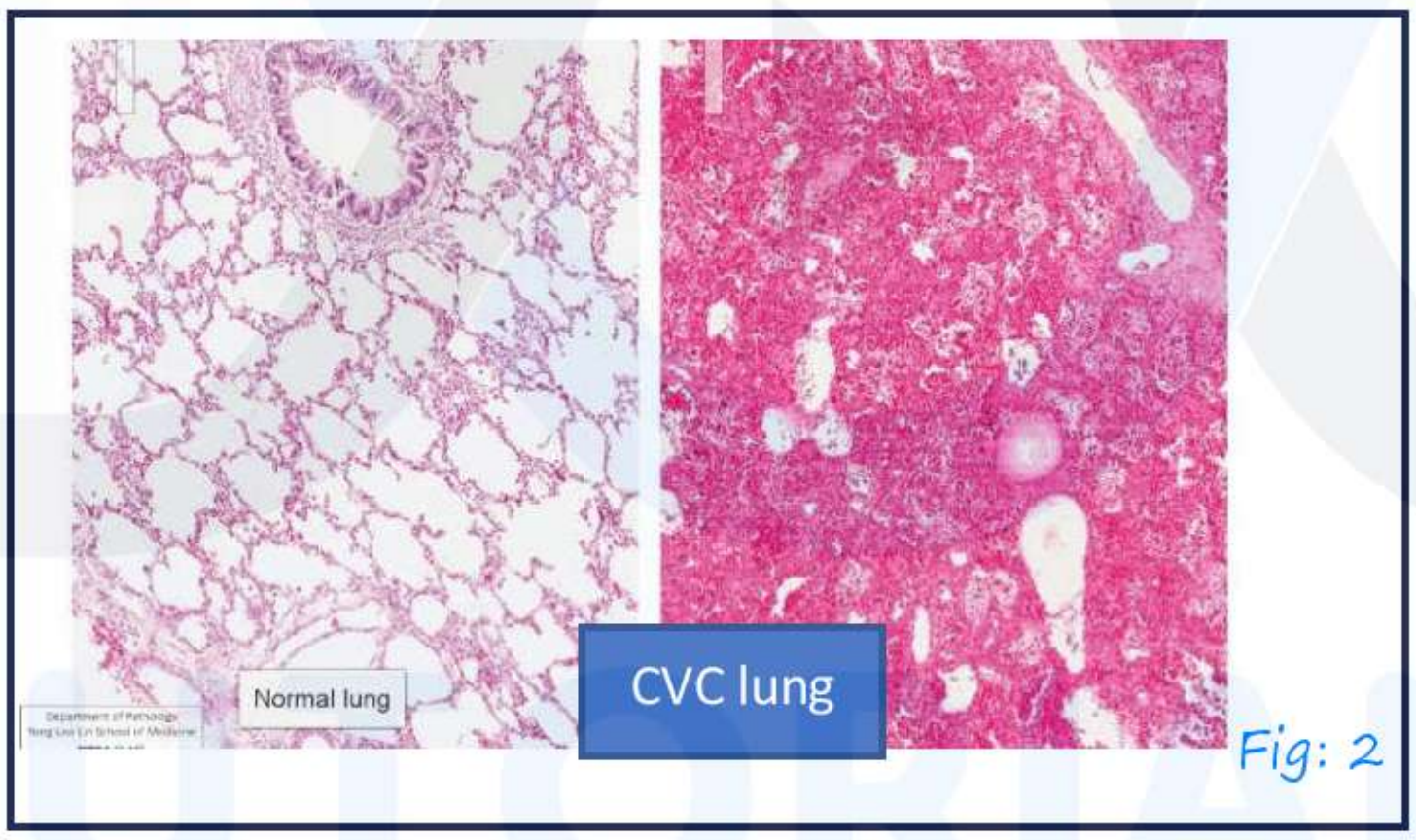

Fig: 2

Macrophages of lung	Macrophages of marrow
• Do not recycle the Iron from RBCs • Non-Recycling Macrophages	• Also called as **NURSE CELLS** • Recycle the Iron from RBCs by lysing the RBC and utilizing it in Haem Synthesis • Therefore, erythrocytes surround macrophages

	in the Bone marrow forming an erthrocytic colony or an erythroid island

Hemosiderin – Golden Brownish to Golden Yellow Colour Pigment

CVC LIVER 00:10:45

Causes of CVC Liver (Backflow of blood from hepatic vein into the liver)

- Right heart failure
- Occlusion of Inferior Cava or hepatic vein (Budd-Chiari syndrome)

AfraTafreeh.com

Gross Appearance of CVC Liver

- Liver is enlarged
- The cut surface shows alternating dark areas of congestion (areas around the central vein) with pale areas of fatty change, giving liver a **Nutmeg appearance**
- If the congestion doesn't stop, Centri-lobular necrosis and liver undergoes regeneration (fibrotic change) – Cardiac Cirrhosis

AfraTafreeh.com

Fig: 3

Histology of CVC Liver

- Blood fills up Central vein & sinusoids around in followed by Centri-lobular hepatocyte atrophy & necrosis
- The Mid-Zonal Hepatocytes may show fatty change due to the relative hypoxia
- In long standing cases, the necrotic area is replaced by Fibrous tissue resulting eventually into Cirrhosis called Cardiac Cirrhosis

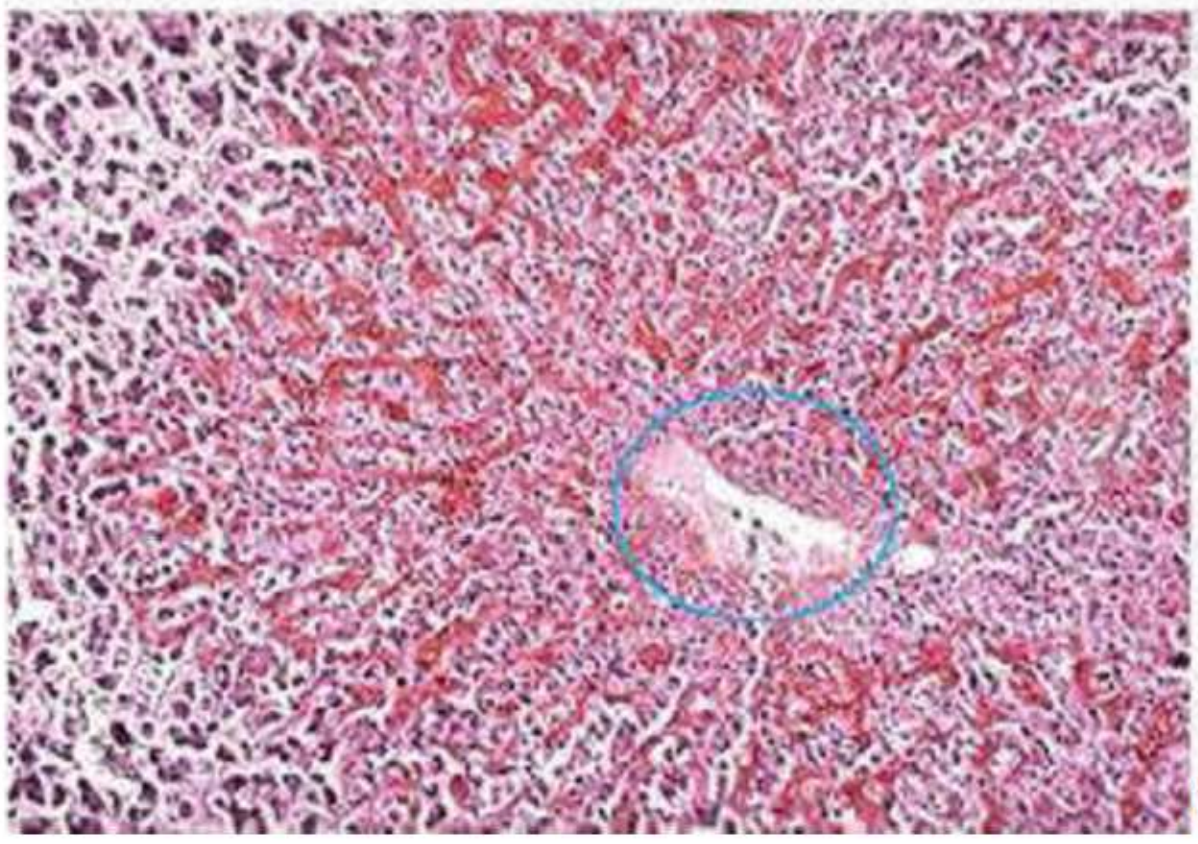

Fig: 4

Causes of CVC Spleen

- Right heart failure
- Portal Hypertension
- Sickle cells blocking the Splenic Vein

Gross Appearance of CVC Spleen

- Spleen is Enlarged & Congested
- Thickened and Tense capsule
- Deep Red to Grey Red cut Surface

Fig: 5

Histology of CVC Spleen

- Sinusoids of the Red Pulp are dilated & engorged with blood and their walls are thickened by fibrous tissue (EXPANSION OF RED PULP)
- Hemorrhage may occur with liberation of Hemosiderin forming Hemosiderin-laden Macrophages

AfraTafreeh.com

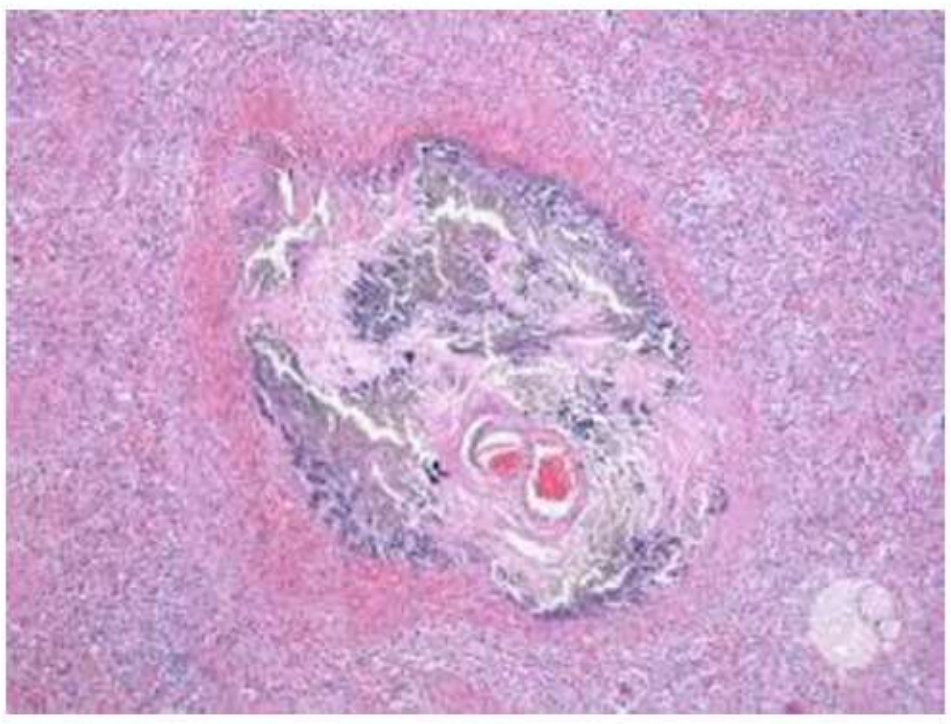

Fig: 6

- Formation of Fibrosclerotic Nodules called Gamna-Gandy Bodies
  - Dystrophic calcification (bluish to purplish colour)
  - Hemosiderin Laden Macrophages
  - Iron deposition.

TUTORIALS
LOGIN FOR SUCCESS

VIRCHOW'S TRIAD

Thrombosis 00:00:07

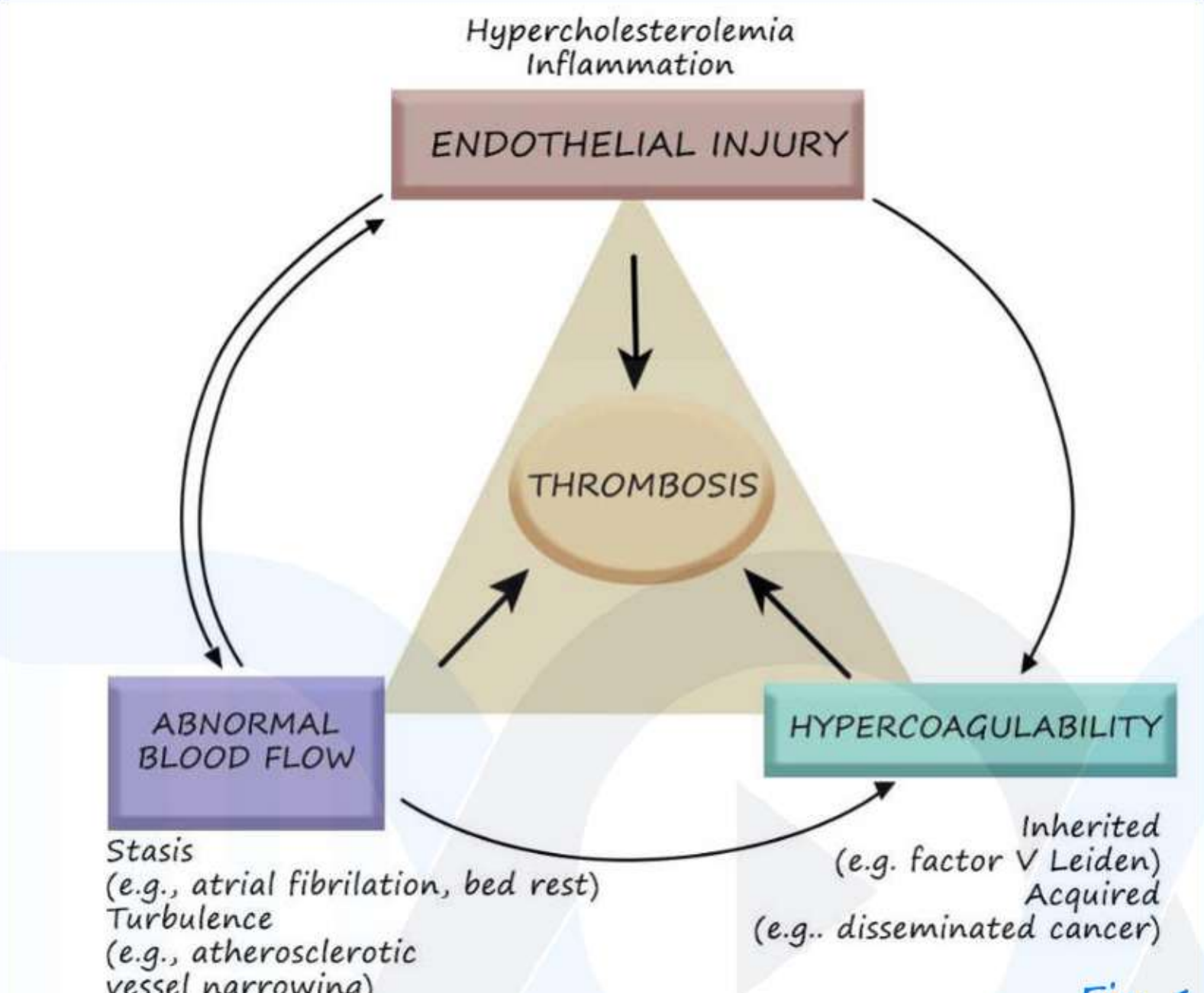

Fig: 1

AfraTafreeh.com

- VGE/Verhoff's Von Geisen Stain (**For Elastic fibres of Internal and External Elastic Lamina**)

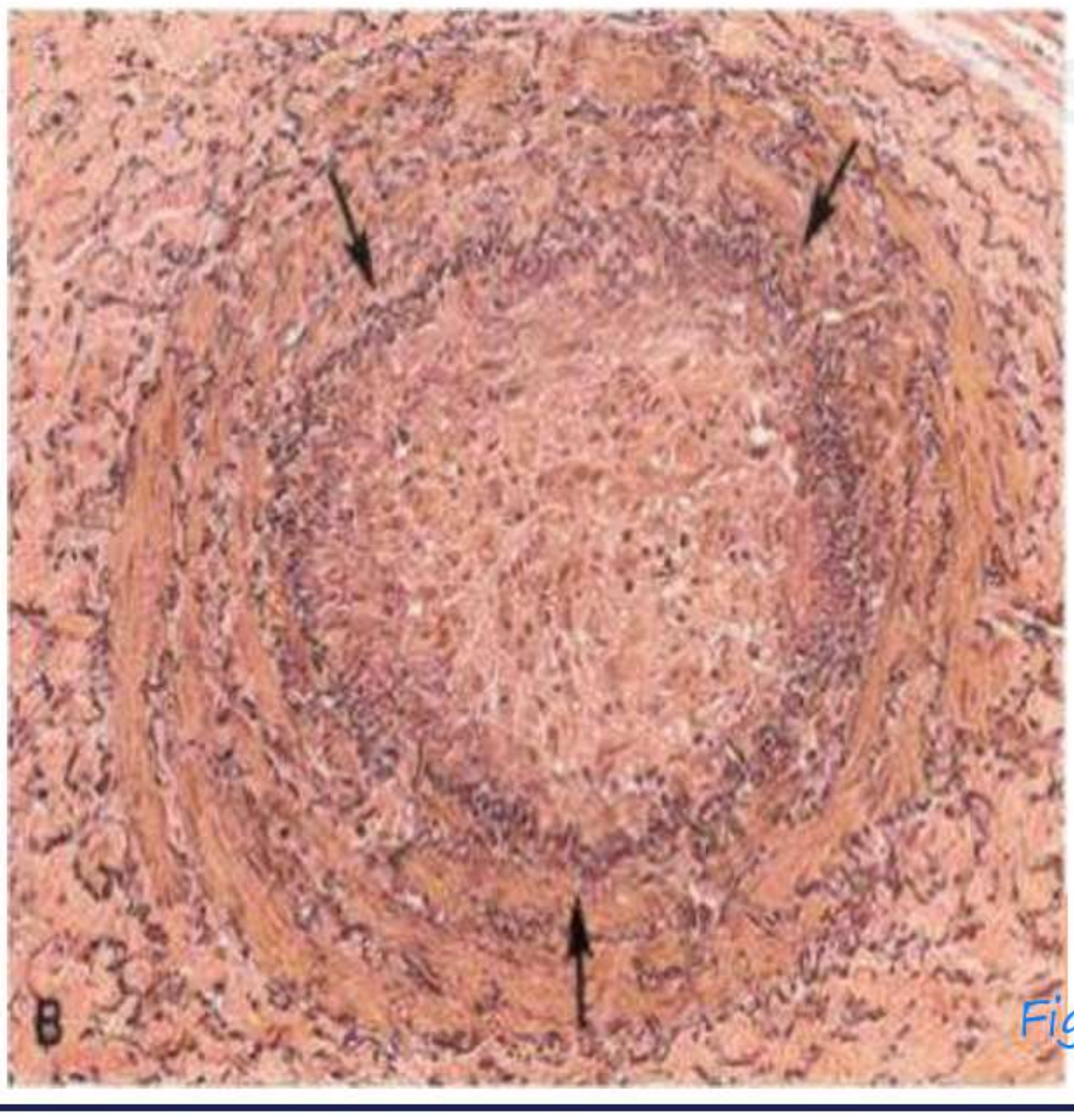
Fig: 2

AfraTafreeh.com

Etiology Of Hypercoagulability 00:07:38

Primary – Inherited	**Secondary – Inherited**	
1.Most common **Factor V Leiden,** SNP at position 506 (Arginine replaced by Glutamine) 2.**Prothrombin 20210A** mutation 3.Protein C and Protein S deficiency 4.Increased coagulation factors	**High risk for thrombosis** 1.Immobility 2.Cancers 3.Prosthetic valves 4.Myocardial infarction 5.Atrial fibrillation 6.HITT 7.APLA Syndrome	**Low risk for thrombosis** 1.Nephrotic syndrome 2.Sickle cell anemia 3.OCP Use

TUTORIALS
LOGIN FOR SUCCESS

Arterial Thrombosis Vs Venous Thrombosis 00:14:41

Arterial Thrombosis	**Venous Thrombosis**
i. Turbulence and endothelial injury ii. Platelet-rich iii. Whitish in Colour	i. Due to stasis and congestion ii. RBC-rich

Virchow's Triad

iv. Partial occlusion of the Lumen	iii. Dark red dependent portion and yellow 'chicken fat' upper portion iv. Complete occlusion of the Lumen v. Not attached to the underlying wall

Distinguishing Ante Mortem and Post Mortem Thrombus 00:16:20

- Ante mortem thrombus - Shows lines of Zahn due to alternate fibrin and darker layer with more RBCs
- **Lines of Zahn** (Alternating light and dark bands)
  - Light Bands – Platelet and Coagulation System
  - Dark Bands – RBCs
- Post Mortem Thrombus – Distinctive chicken fat layer above the thrombus, RBCs in the lowest layers – due to stasis

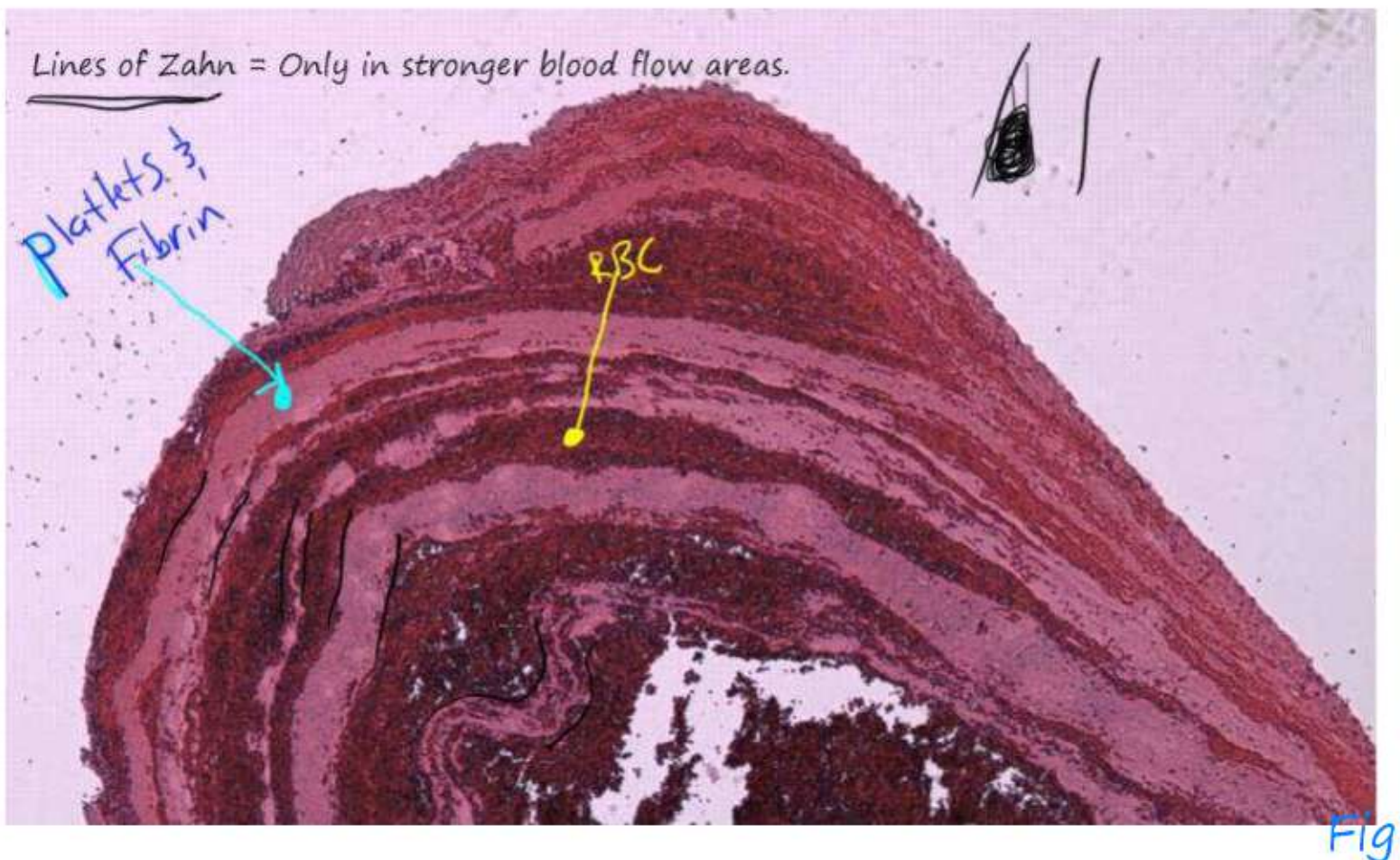

Fig: 3

AfraTafreeh.com

Mural Thrombi 00:20:12

- Seen from the muscle of the heart

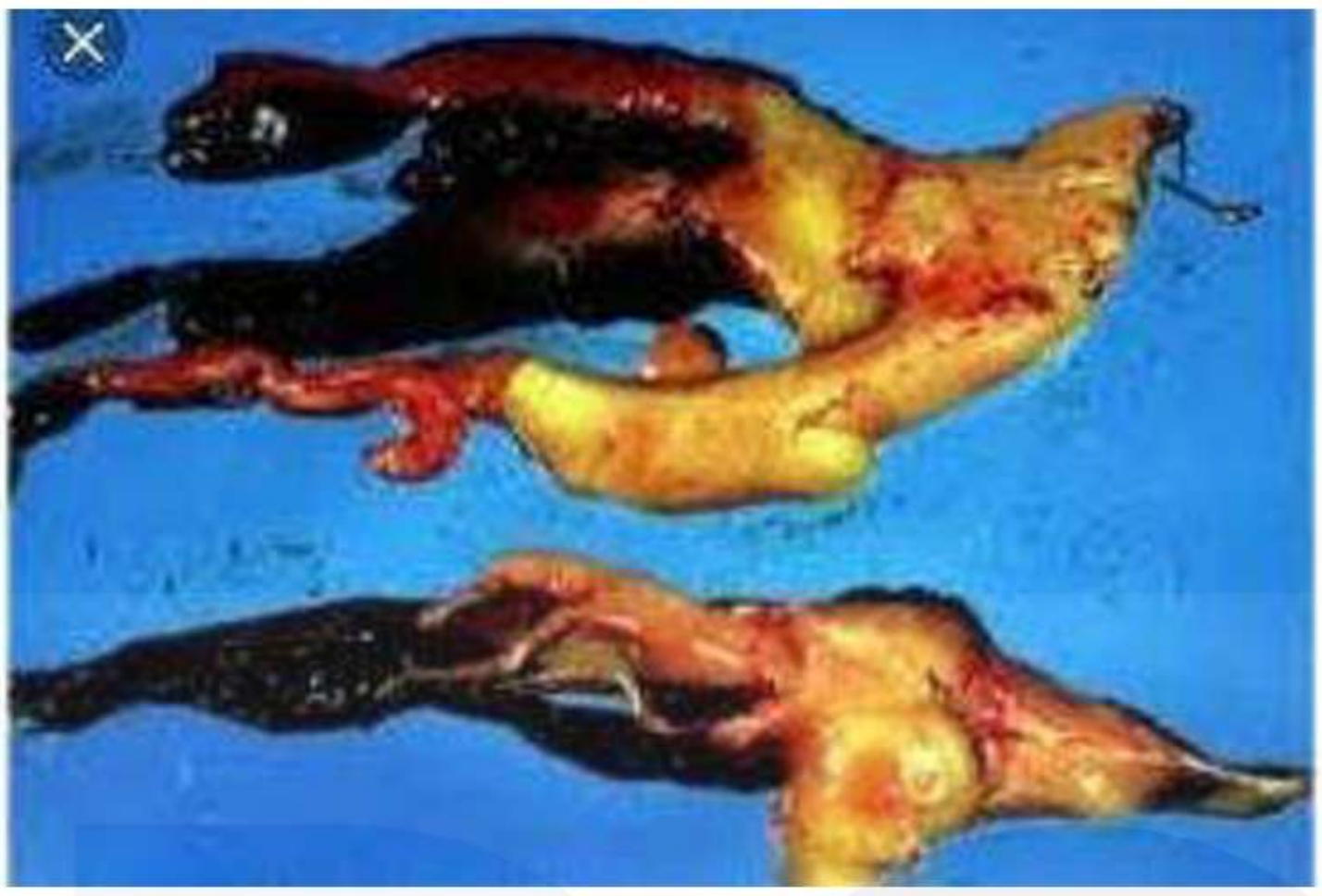

Fig: 4

Remember

- Aneurysms show stasis and are known to develop thrombi
- Complications of Thrombi – EMBOLISM
- Higher Risk of Embolism – VENOUS THROMBI

TUTORIALS
LOGIN FOR SUCCESS

INFARCTS

- Localized area of cell death – Due to ischemic necrosis of the tissue
- Mostly caused by Interrupted Blood supply
- Almost all infarcts are arterial in origin, as venous obstruction causes congestion and edema

Types of Infarcts 00:00:25

Red Infarct	White Infarct
• In organs with **dual Blood supply** e.g., Lung, Liver • In Organs with **loose alveolar tissue** e.g., Intestine, Lung • **Torsion** causes venous obstruction and hence, congestion in the tissue e.g., Ovarian Torsion. Testicular Torsion • **Reperfusion (when the flow is re-established)** of organs or tissues – e.g., Myocardial Infarction	• In organs with **a Single Blood supply** e.g., Spleen (Sickle cells in the splenic vessels), Kidney (renal artery obstruction) • In **Solid Organs** e.g., Spleen • **Arterial Obstructions**

AfraTafreeh.com
DOCTUTORIALS LOGIN FOR SUCCESS

• Ill defined, hemorrhagic margins (because of edema, the tissue is loose)	• Well defined, usually wedge shaped (with the occluded artery at the apex)
• Reddish Infarct	• Pale and progressively paler

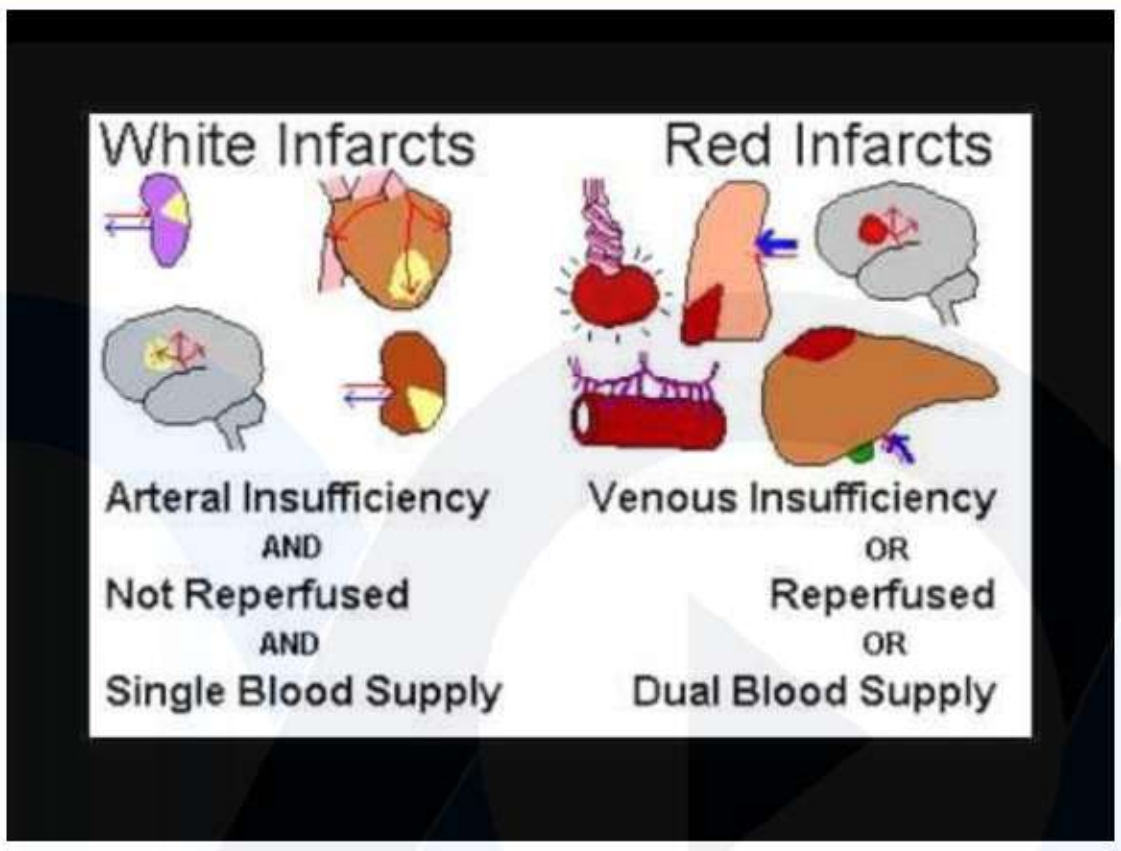

Fig: 1

Dichotomous Infarcts 00:04:56

- Red or White Infarct seen
- Seen in Liver (Solid Organ but with a dual blood supply); Brain
  - The infarct is based upon the etiology of the disease

Organs And Associated Infarcts 00:07:45

Fig: 2

- **Infarct of the lung**

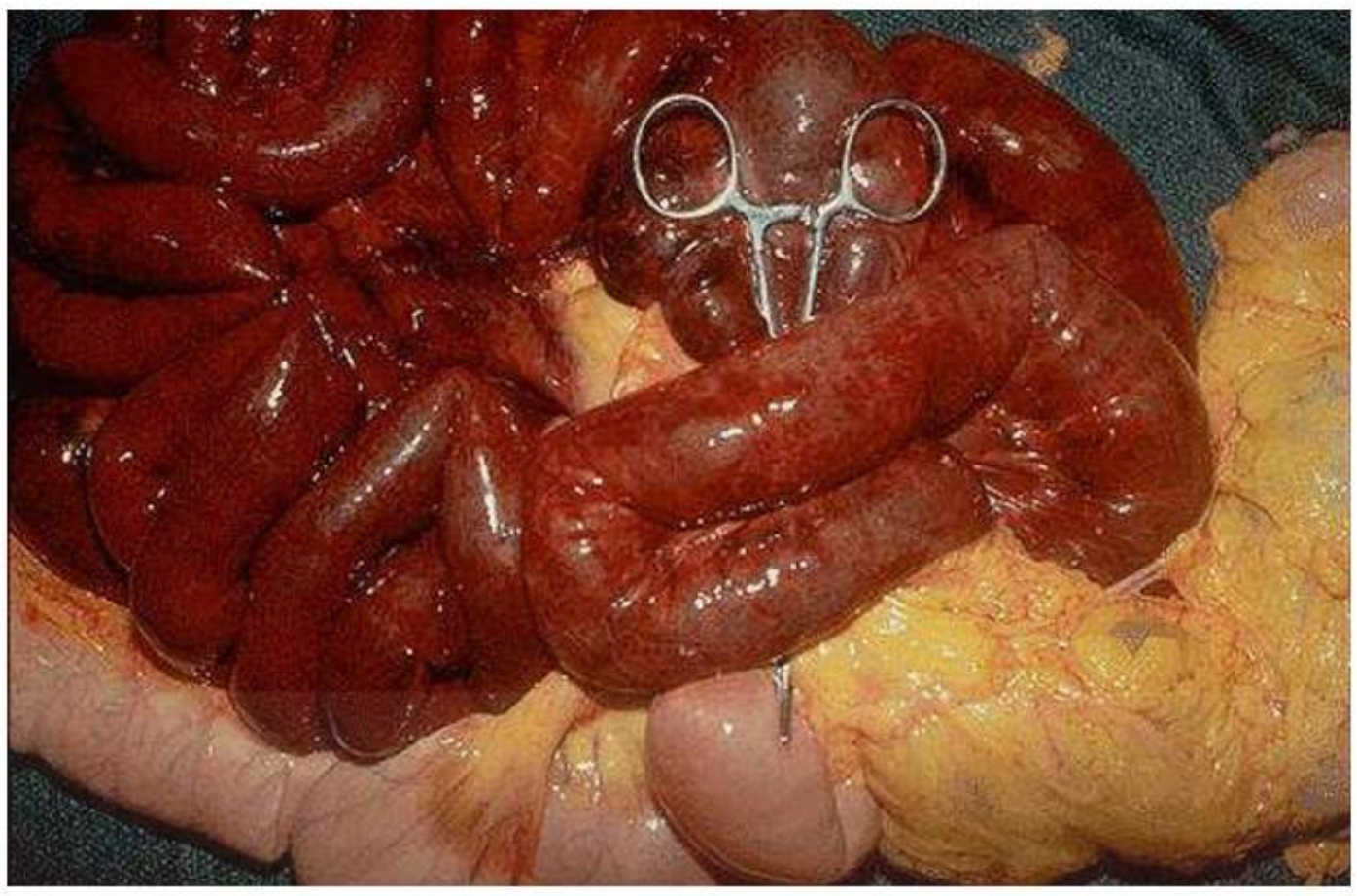

Fig: 3

- **Infarcts in the Intestine**



Fig: 4

- **Infarct of the Spleen (Solid Grayish Organ, notch in the organ visualized)**

Fig: 5

TUTORIALS LOGIN FOR SUCCESS

AfraTafreeh.com

- **Infarct of the Kidney (Medullary rays seen in the organ, visualized cortex and medulla)**

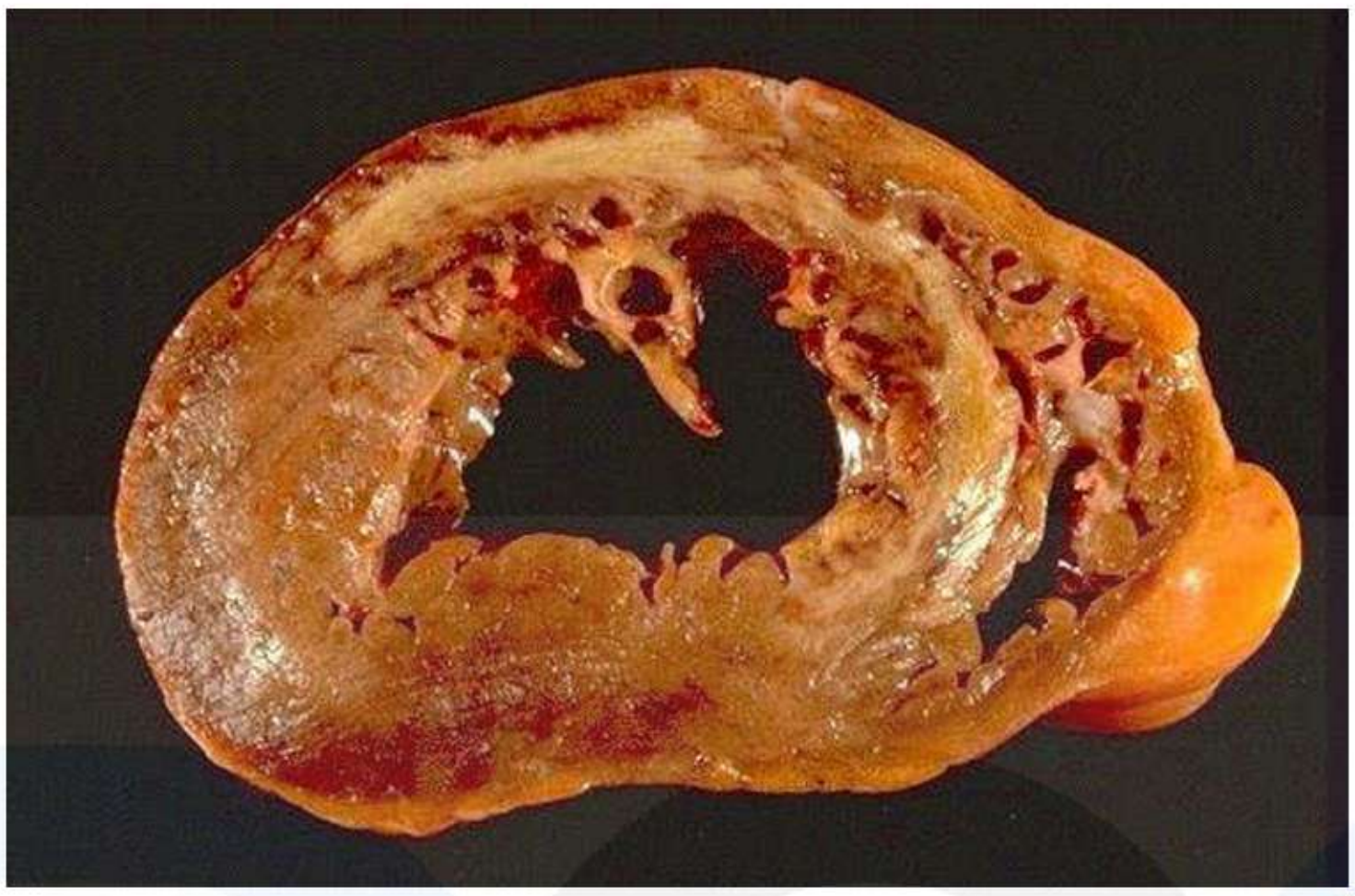

Fig: 6

- **Cut section of the heart (well-defined white infarct)**

TUTORIALS
LOGIN FOR SUCCESS

EMBOLISM

Types Of Emboli 00:00:23

Pulmonary Embolism	Systemic Embolism
• Most pulmonary emboli (60-80%) are clinically silent and arise commonly DVTs of the deep leg veins. • Venous embolism • Asymptomatic till they become a saddle thrombus • The most common type of embolism	• Most systemic emboli arise from the cardiac muscle (cardiac mural thrombi) (due to atrial fibrillations (commonly)) • They get lodged into the systemic arteries. • Arteries of the Lower Limb (75%), Brain (10%) • Arterial embolism

AfraTafreeh.com

• **Note:** Although most common site of DVT is calf veins, they are associated with a low risk of embolism. Risk becomes high when the Thrombosis progresses proximally to involve larger veins. **Saddle Embolus** → Embolus at the bifurcation of pulmonary Artery can lead to sudden death

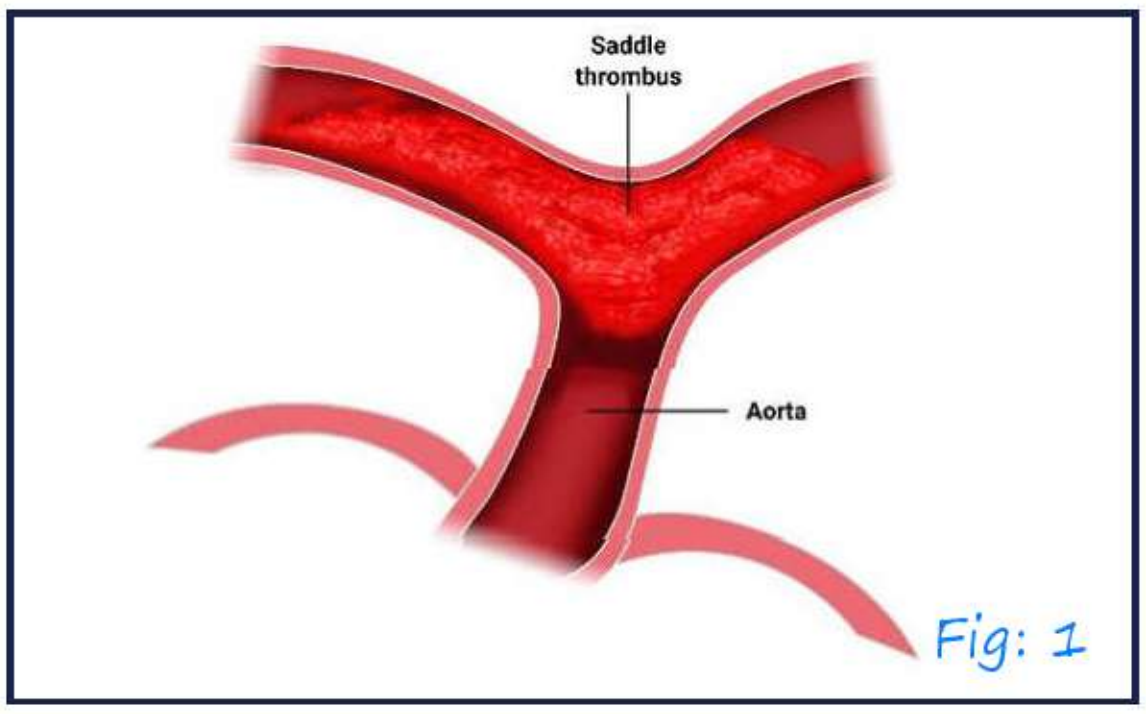

Fig: 1

- Saddle Thrombus

AfraTafreeh.com

Amniotic fluid Embolism 00:03:20

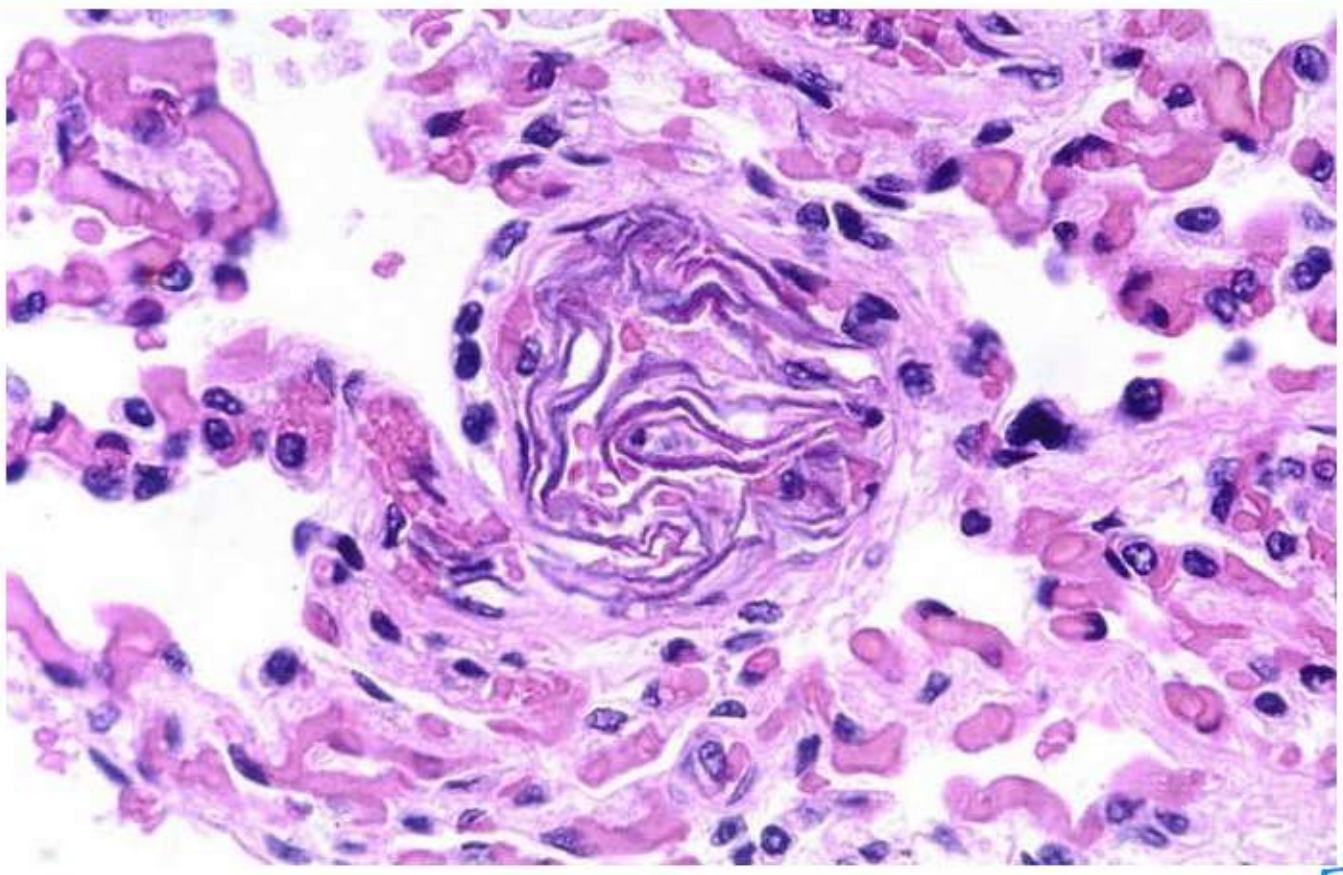

Fig: 2

- Important cause of mortality (post-partum)
- Rupture of placental vessels/uterine vessels – infusion of amniotic fluid or fetal tissue (hair, membrane) into the maternal circulation and approach the lungs
- Squamous membrane in pulmonary vessels

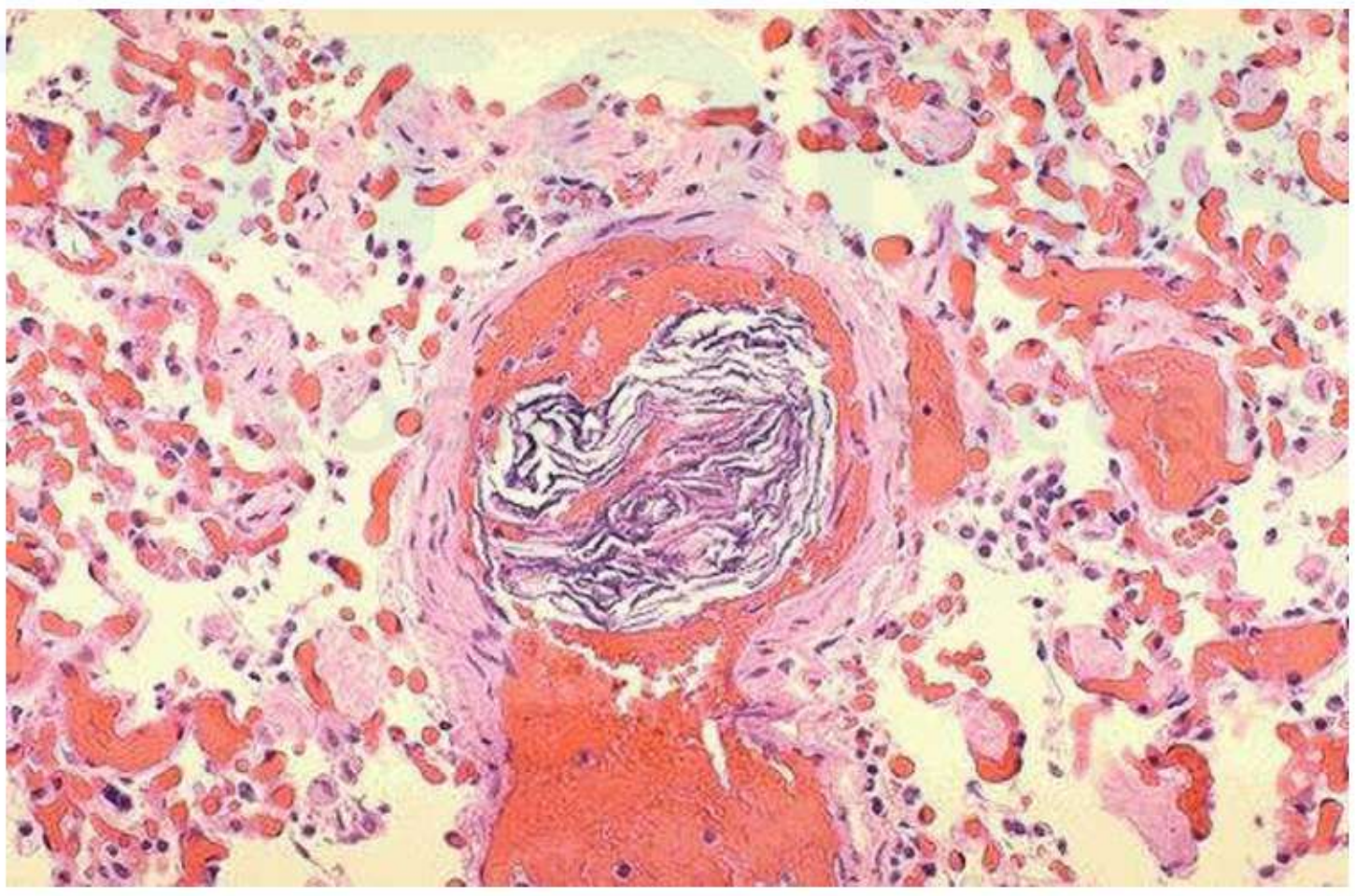

Fig: 3

Air Embolism 00:06:30

- Occurs in
  - Deep sea divers, Construction workers working under water

- **Iatrogenic**: Cardiopulmonary bypass, Neurosurgeries in Sitting Position

- 100 cc of air to become an embolus
- Deep Sea Divers – Dissolved Nitrogen at deeper levels will be released quickly if the diver's surface rapidly. (**SUDDEN ASCENT from high pressure to low pressure**)
- Types of air emboli
  - CHOKES – Respiratory Symptoms – Dyspnea
  - BENDS – Joint Pains
- Usually, Large Joints are involved
  - STAGGERS – Neurological manifestations (not in all types of air emboli)
- Poor prognosis
- Visual Alterations and various types of paraesthesias
- Recent Classification
  i. BENDS + CHOKES – **Type 1 - Simple**
  ii. STAGGERS – **Type 2 – Complex**
- Skin Manifestation in a person with Air emboli (Cutis marmarata) – Upper Trunk, Abdomen and Shoulder

Marbled Skin Appearance Fig: 4

AfraTafreeh.com

- Patients usually present with **Caisson's Disease**
  - Chronic disease
  - Long term workers
  - Osteonecrosis of the femur head

Paradoxical Embolism (Crossed embolism)

Embolism arises from Thrombosis is Vein, but may pass through ASD or VSD to gain access to systemic arteries, i.e embolus from

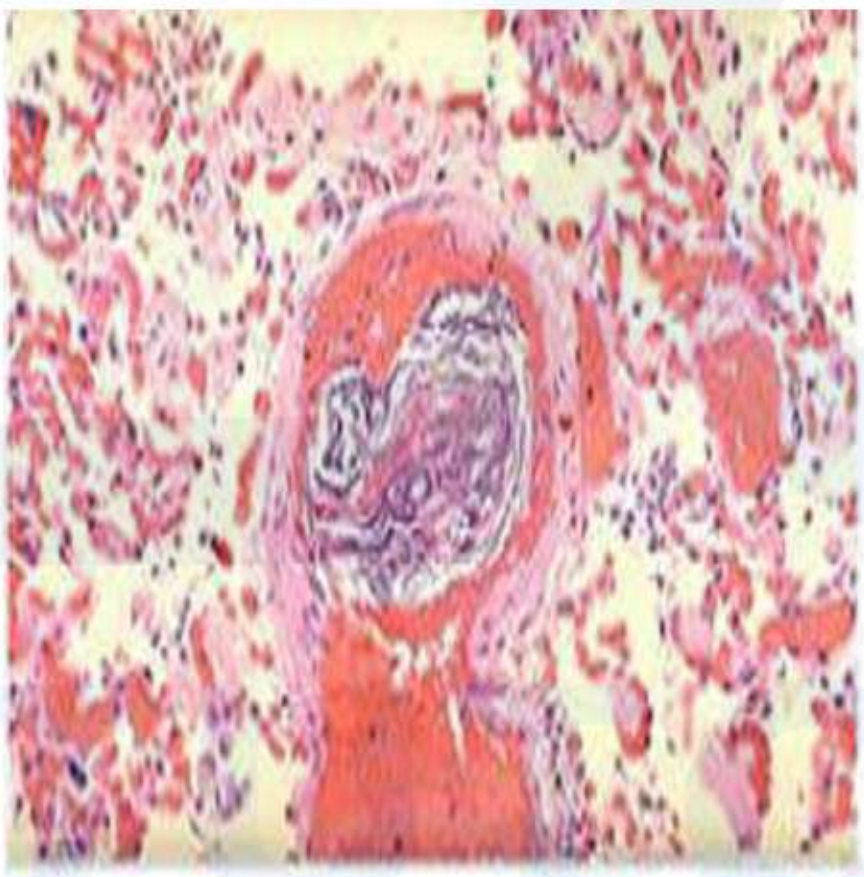

Fig: 5

- Lodge into Pulmonary circulation and couse sudden death
- C/F-Respiratory Distress, Cyanosis Cardiogenic Shock

LOGIN FOR SUCCESS

Fat Embolism / Bone Marrow Embolism

00:15:58

Cause

- Fracture of Long Bones

Pathogenesis

- Release of Bone marrow tissue & fat cells in the form of an embolus (1-3 days after fracture)

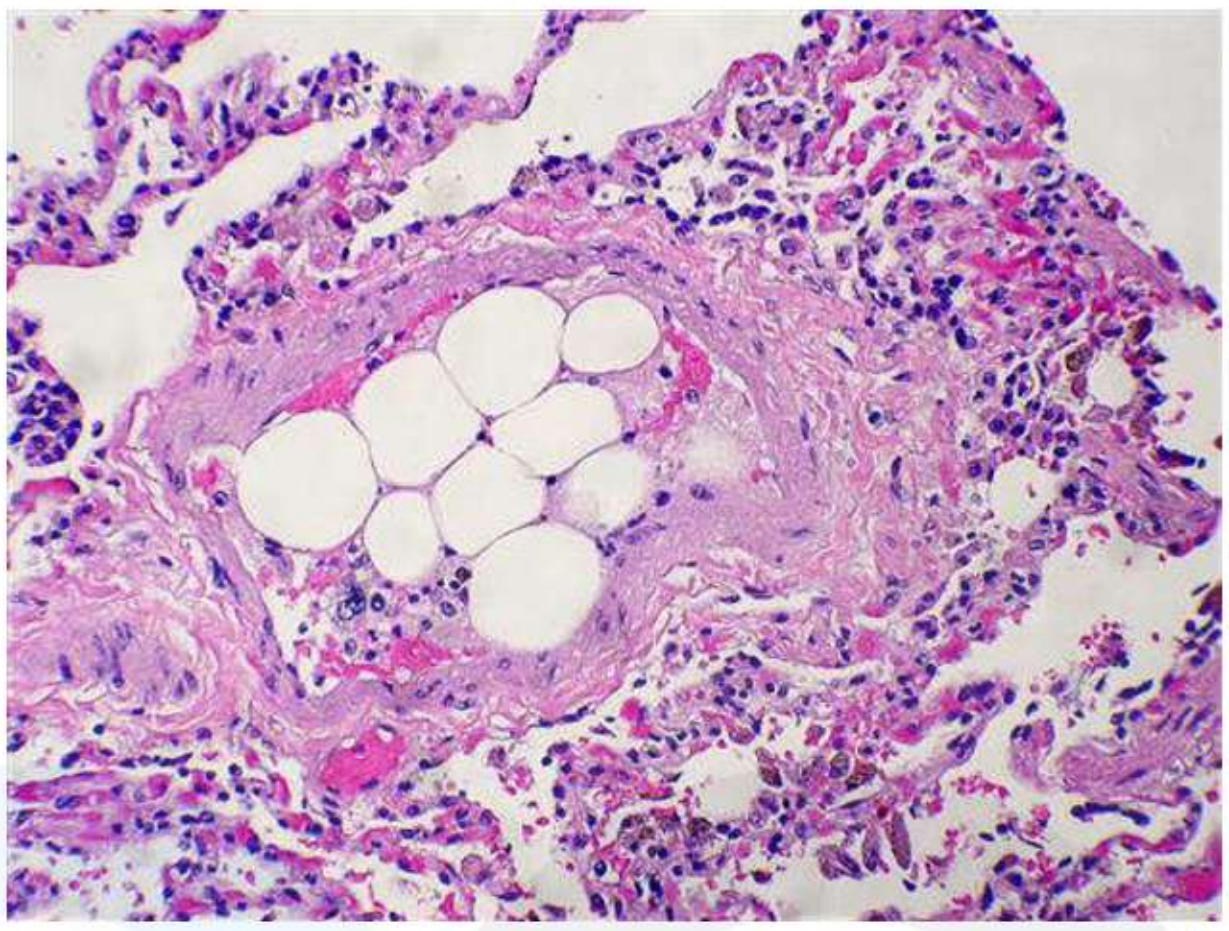

Fig: 6

Clinical Manifestations

1. 1-3 Days after the fracture
2. Pulmonary insufficiency
3. Anemia, Neurological Manifestations and thrombocytopenia (presents with petechiae - Important sign)

AfraTafreeh.com
TUTORIALS
LOGIN FOR SUCCESS

Laboratory Findings

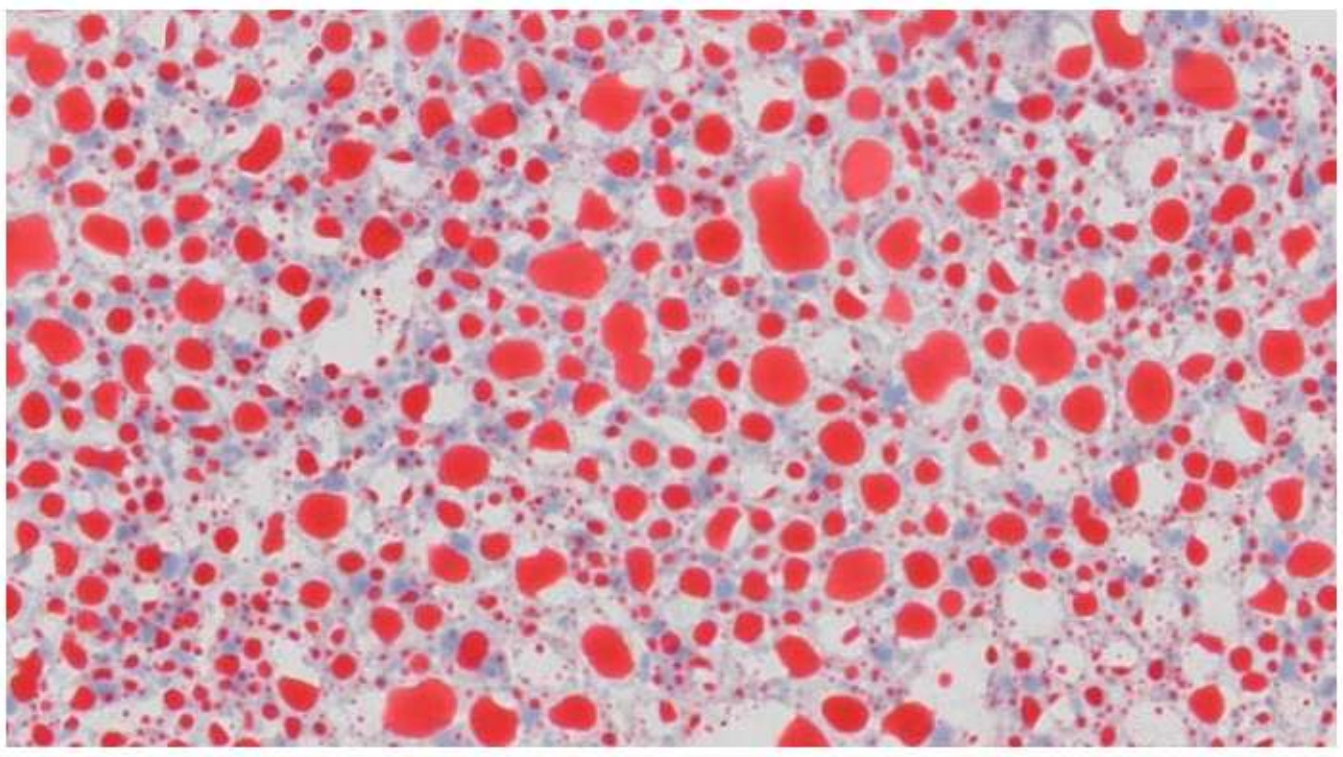

Fig: 7

Oil Red-O Stain

1. Anaemia, Thrombocytopenia

AfraTafreeh.com

2.Microglobinuria in the Urine

3.Bat Wing appearance on Chest X Ray

Diagnosis of Fat Embolism 00:21:10

GURD AND WILSON CRITERIA

Major

1. Pulmonary Insufficiency (hypoxia)
2. Altered Mental Status
3. Thrombocytopenia (petechiae)

Minor

1. Platelet Count
2. Unexplained Anemia
3. Fat Globules in the Urine
4. Fever
5. Tachycardia

1 MAJOR + 3 MINOR or 2 MAJOR + 2 MINOR

TUTORIALS
LOGIN FOR SUCCESS

SHOCK

A Clinical syndrome that develops when there is critical impairment of tissue perfusion due to some form of Acute circulatory failure.

Types of Shock

- Cardiogenic shock
- Hypovolemic shock
- Neurogenic shock
- Anaphylactic shock – IgE Antibody mediated
- Septic shock – Associated with Inflammation leading to cytokine release

AfraTafreeh.com

Pathogenesis of septic shock 00:02:32

Causes

- Gram Positive Bacteria – most common cause
- Gram Negative Bacteria (Endotoxic shock – previous name)

  PAMP – Pathogen associated molecular pattern

AfraTafreeh.com

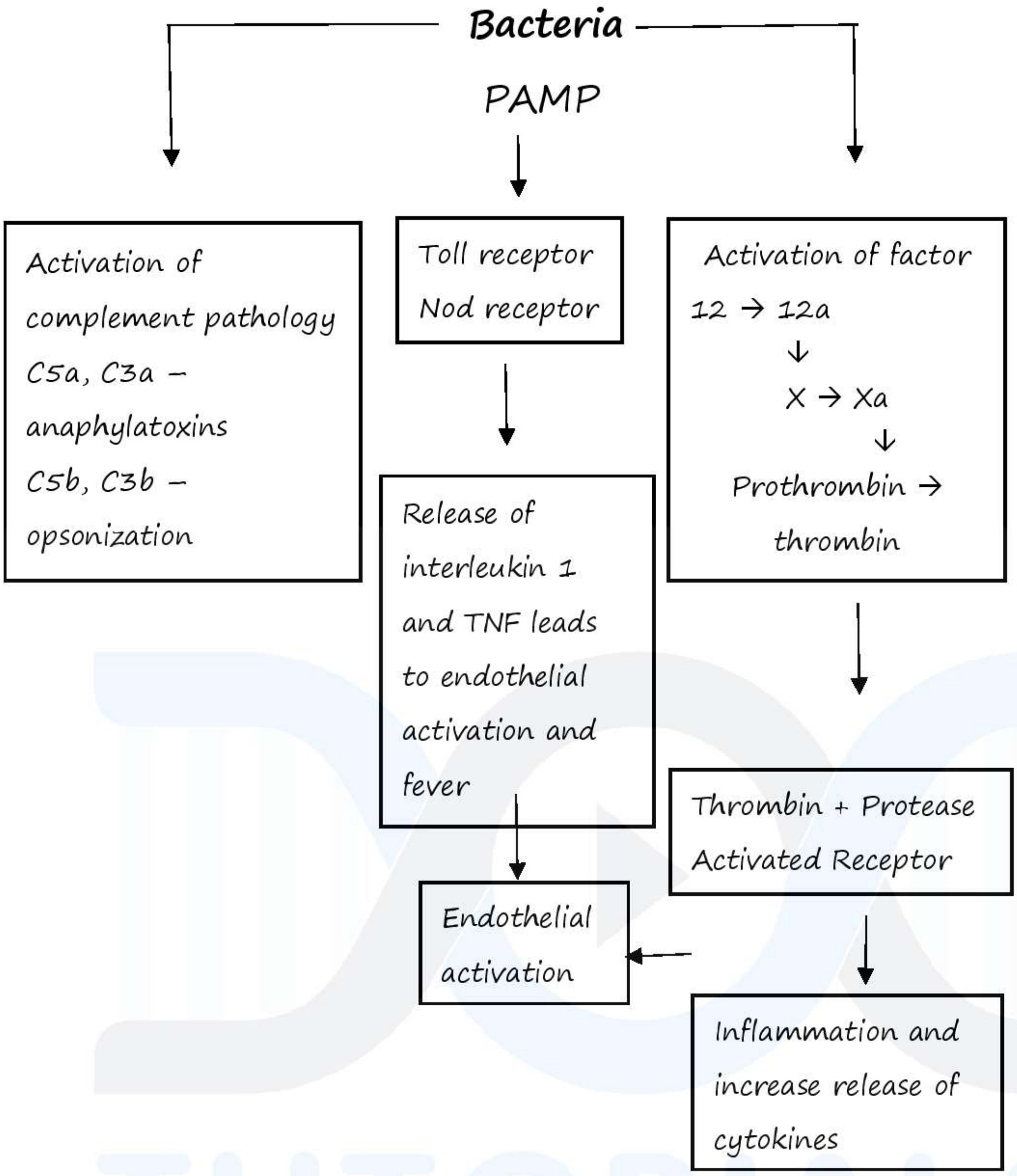

Key event in septic shock – **Endothelial Activation**

Endothelial activation

Procoagulatory state ↓ DIC and Thrombi in vessels ↓ Tissue Ischemia	**IL6, IL8, NO, Reactive Oxygen** ↓ Increased inflammation	**IL 10, STNF-R** ↓ Suppressed inflammation and induced apoptosis ↓

(hypoperfused) ↓ Lactic acidosis	and vascular permeability ↓ Vasodilatation ↓ Causing Warm Peripheries	Induce immunosuppr ession

Characterized by

- Peripheral Vasodilatation (warm Peripheries) (in contrast to other forms of shock)
- Increased Vascular Permeability

Sirs criteria	
Term	**Definition**
SIRS (at least 2 of these are needed to meet criteria for SIRS)	**Body temperature** >38C or <36°C **Heart rate** >90/min **Respirations** 20min or $PaCO_2$<32 mm Hg **White blood cell count** >12.0x 10^9/L or <4.0 x 10^9/L
Sepsis	SIRS plus infection
Severe sepsis	Sepsis-associated with organ dysfunction , systemic hypoperfusion or hypotension

AfraTafreeh.com

AfraTafreeh.com

Septic shock	Sepsis with arterial hypotension despite adequate fluid replacement (lactate increase)

Stages of Progression 00:20:13

I. Non-Progressive Stage

- Neuro-humoral responses active
- Increased sympathetic activity with **increased HR & RR**
- ADH release causing fluid conservation by kidney
- Stimulation of Adrenal medulla causing increased release of corticosteroids
- Compensated by Sympathetic Release
- Vessels of the brain don't respond to sympathetic stimuli – Blood flow to the brain is preserved

II. Progressive Stage

- Tissue ischemia
- No Compensation
- Pulmonary hypoperfusion

III. End/Irreversible/Terminal stage

- Membrane damage
- Lysosomal enzyme activation

Morphological changes in Shock 00:23:35

- Adrenals → Cortical lipid depletion
- Lungs → ARDS/diffuse alveolar damage

- Kidney → Acute tubular necrosis
- Brain → Systemic thrombi
- Intestine → Systemic thrombi

AfraTafreeh.com
TUTORIALS
LOGIN FOR SUCCESS

AfraTafreeh.com

UNDERSTANDING BASICS OF GLOMERULUS

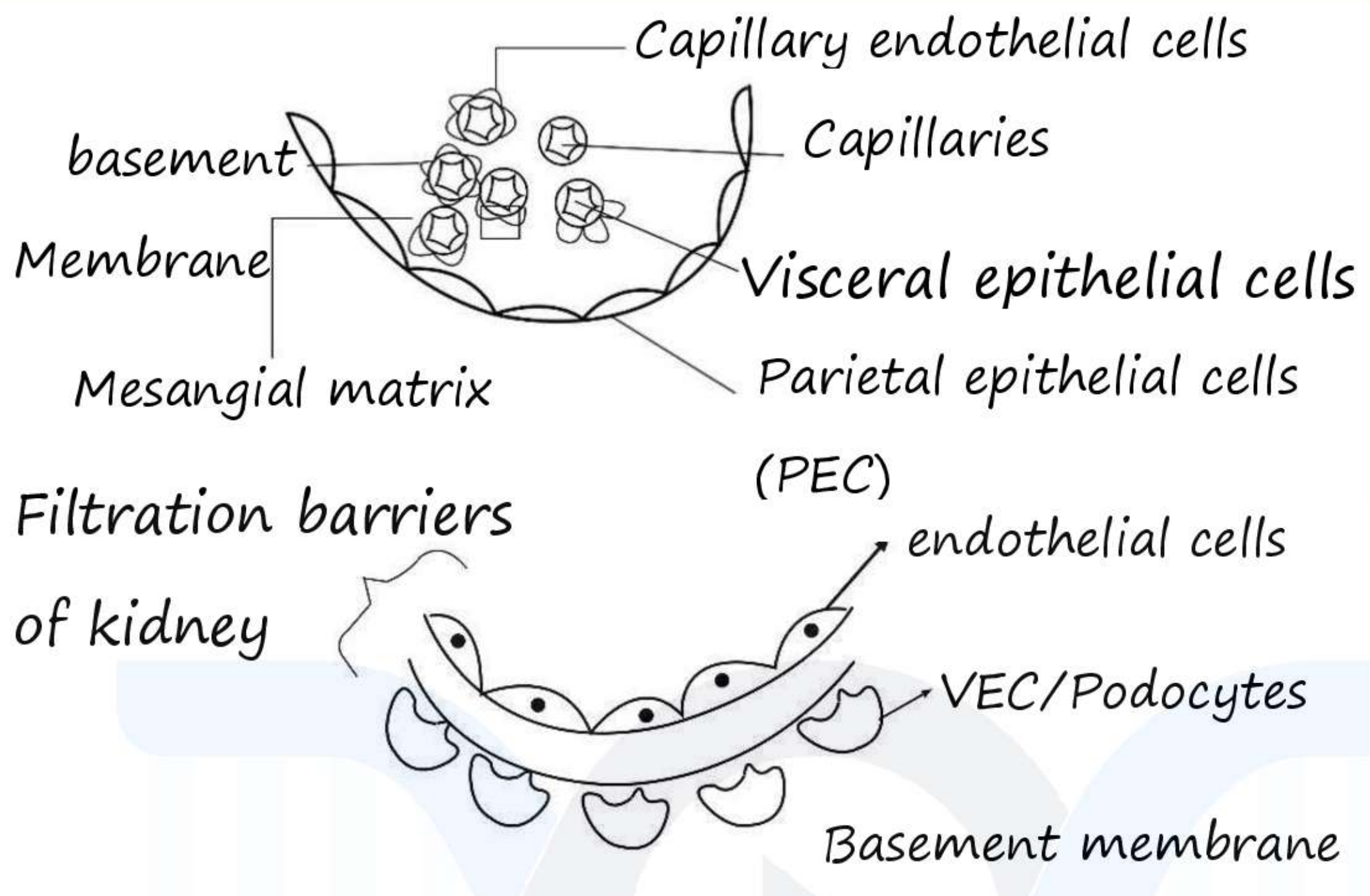

Fig 1

- Visceral epithelial cells are the most important cells which help in filtration– aka podocytes

I. Podocytes and Podocytopathies

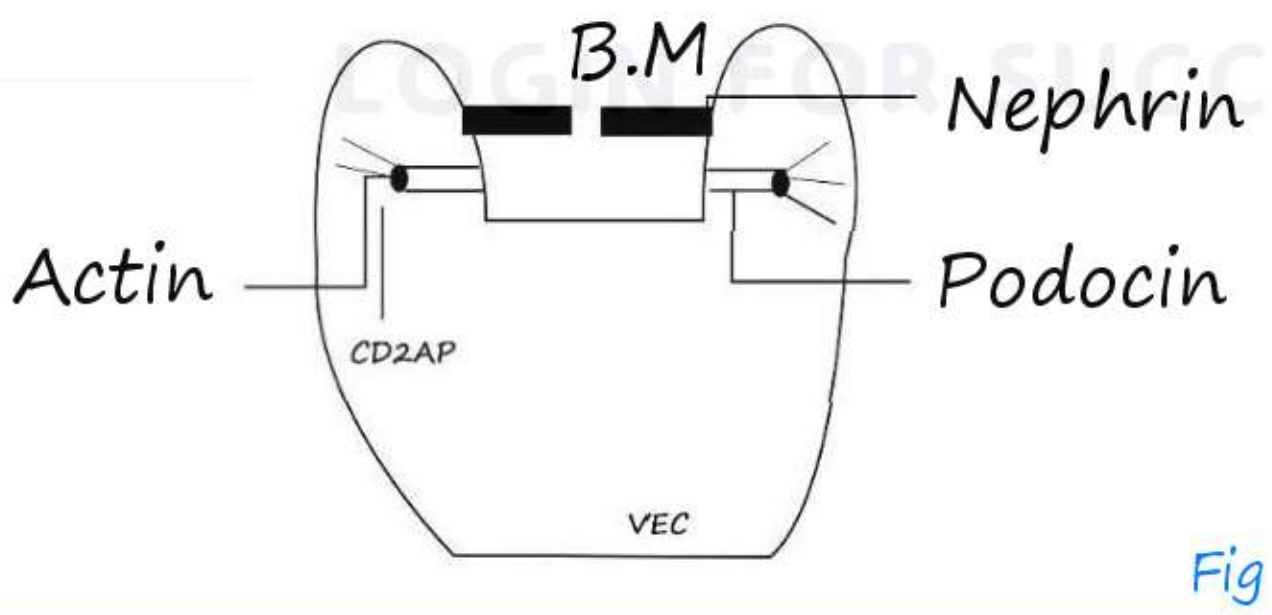

Fig 2

Podocytopathies – Group of disorders which affect Podocytes

4 major proteins in VEC

NPHS1 gene NPHS2 gene			
Nephrin ↓ Mutation seen in finnish type nephrotic syndrome (minimal change disease)	Podocin ↓ Mutation cause AR type of FSGS	CD2AP ↓ CD2AP mutations causes no human disease	Actin ↓ subtype α Actinin 4 ↓ mutation causes AD type FSGS

AfraTafreeh.com

- Gene coding for Nephrin protein → NPHS1
- Gene coding for Podocin protein → NPHS2
- Most common steroid resistant congenital NS is due to Podocin mutation → AR type of FSGS

Basement Membrane

- Made of Collagen Type IV

NC1 → Triple Helix of collagen
↓
Non- collagenous part attached to triple helix by α protein (α3 α4 α5)

- **ANTI GBM DISEASE (α** 3 defective)

If effects BM of Kidney and lung — Hemorrhagic Interstitial Pneumonitis

AfraTafreeh.com

↓

It is called 'GOODPASTURE syndrome'

(Also type 2 HSR)

I. α 3 – NC – COL 4 most common antigenic

II. α 4 – NC – Col IV

Defective α 4 seen in **Thin BM disease**

BM thickness becomes < 200 nm

Normal Thickness of BM [250nm-400nm]

- Develop Benign familial hematuria which Runs in families
- α 5 Chain α5 –NC –Col IV

Defective α 5 → **Alport's Syndrome**

Basement Membrane

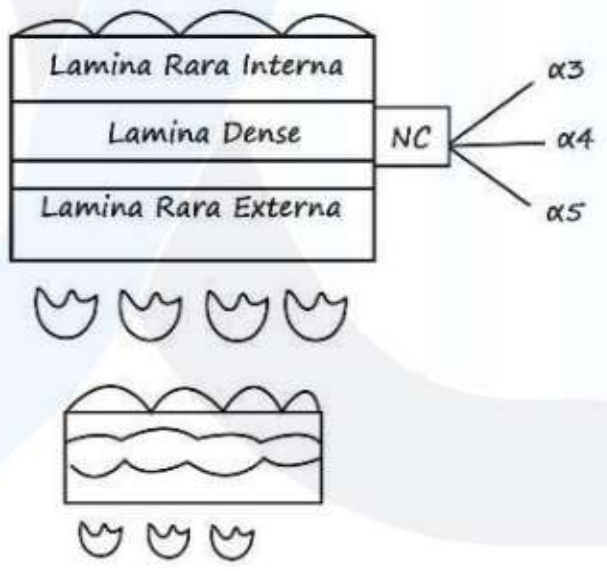

Alport's syndrome

- α5 defective → in Alport syndrome

- Alternate thickening and thinning of lamina densa of BM

↓

- Basket weave Appearance
- Inherited either as XLD or XLR
- There is defective assembly of collagen within basement membrane (Not Ab associated disorder)
- Light microscopy – Interstitum of kidney will show lots of foam cells

- Electron microscopy- Basket weave appearance of lamina dense
- C/F – Triad – In kidney → Shows Hematuria
  Eyes → Anterior lenticonus /Lens Sub luxation
  Ear → SNHL

Other Constituents of BM:

I. Laminin – adhesive Glycoprotein of BM
II. Heparan Sulphate, Proteoglycans
III. Polyanions → Give negative charge to BM

Endothelium

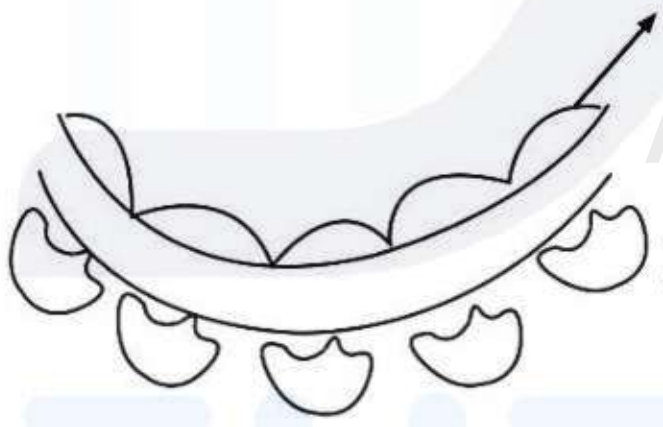

AfraTafreeh.com

Weight of Albumin – 70 kDa
Transferrin – 76 kda
] LMW proteins can pass through fenestrations
↓

- But are not filtered into urine because negative charge of B.M is lost → LMW proteins lost in urine – labelled as highly selective proteinuria
↓
- So, Filtration by Glomerular Filtration barrier is both size and charge dependent

AfraTafreeh.com

Mesangial Matrix

- Formed by mesangial cells(macrophages) which are nothing but mesenchymal cells
- Surrounds the capillaries of Glomerular cells
- These are modified macrophages of kidney.

TUTORIALS
LOGIN FOR SUCCESS

PATHOPHYSIOLOGY OF GLOMERULAR DISEASE

Three Basic Pathogenesis:

1.Antibody mediated – Most common

Antibodies against In situ Antigens

Intrinsic Antigen	Planted Antigen
example: Anti – GBM disease – Ab Against α3 NC col IV	Due to drugs, Immune complies bacterial antigens, DNA

Type 2 HSR

Antibodies against Circulating Antigens

↓

Example: SLE

PSGN – Type III HSR

2.T cell Mediated Diseases

T cells → Cytokines → Damage

3.Complement Mediated Diseases called Complementopathies

Example: C3 Glomerulonephritis – includes MPGN II

AfraTafreeh.com
DOC TUTORIALS
... FOR SUCCESS

AfraTafreeh.com

Sites of deposition of immune complexes

Subendothelial	B.M	Sub epithelial
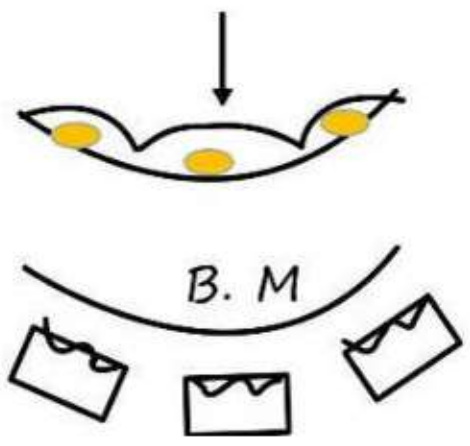	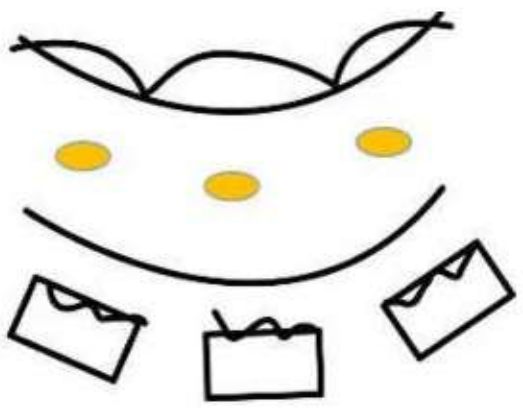	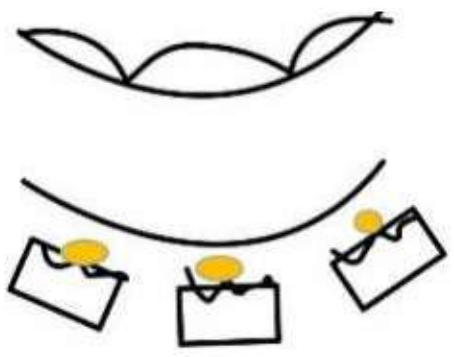
seen in MPGN I	seen in MPGN II Also called Dense deposit disease	seen in •Membranous nephropathy •Subepithelial HUMPS in PSGN

Deposition in Mesangial Matrix – Seen in IgA nephropathy.

HISTOPATHOLOGY OF KIDNEY

Glomerular Diseases

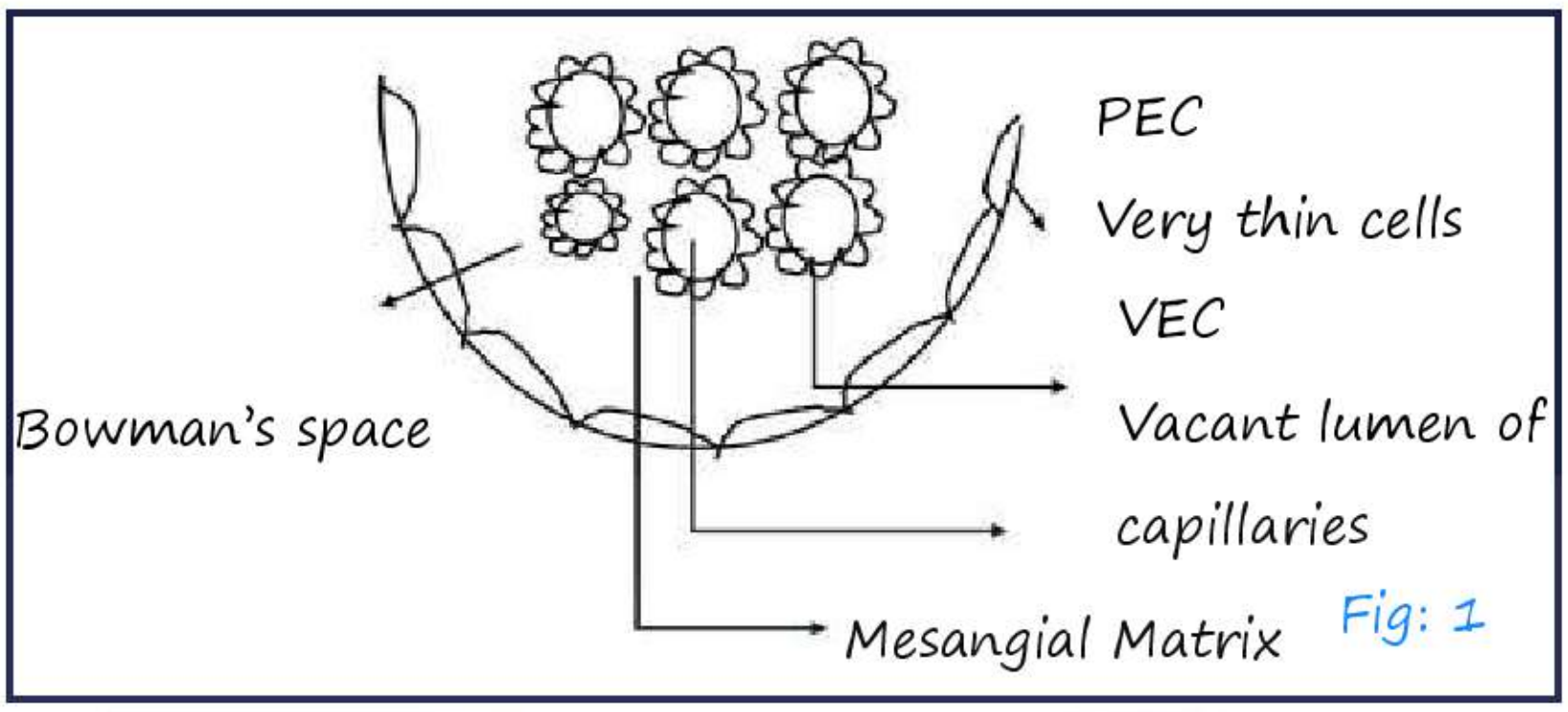

Fig: 1

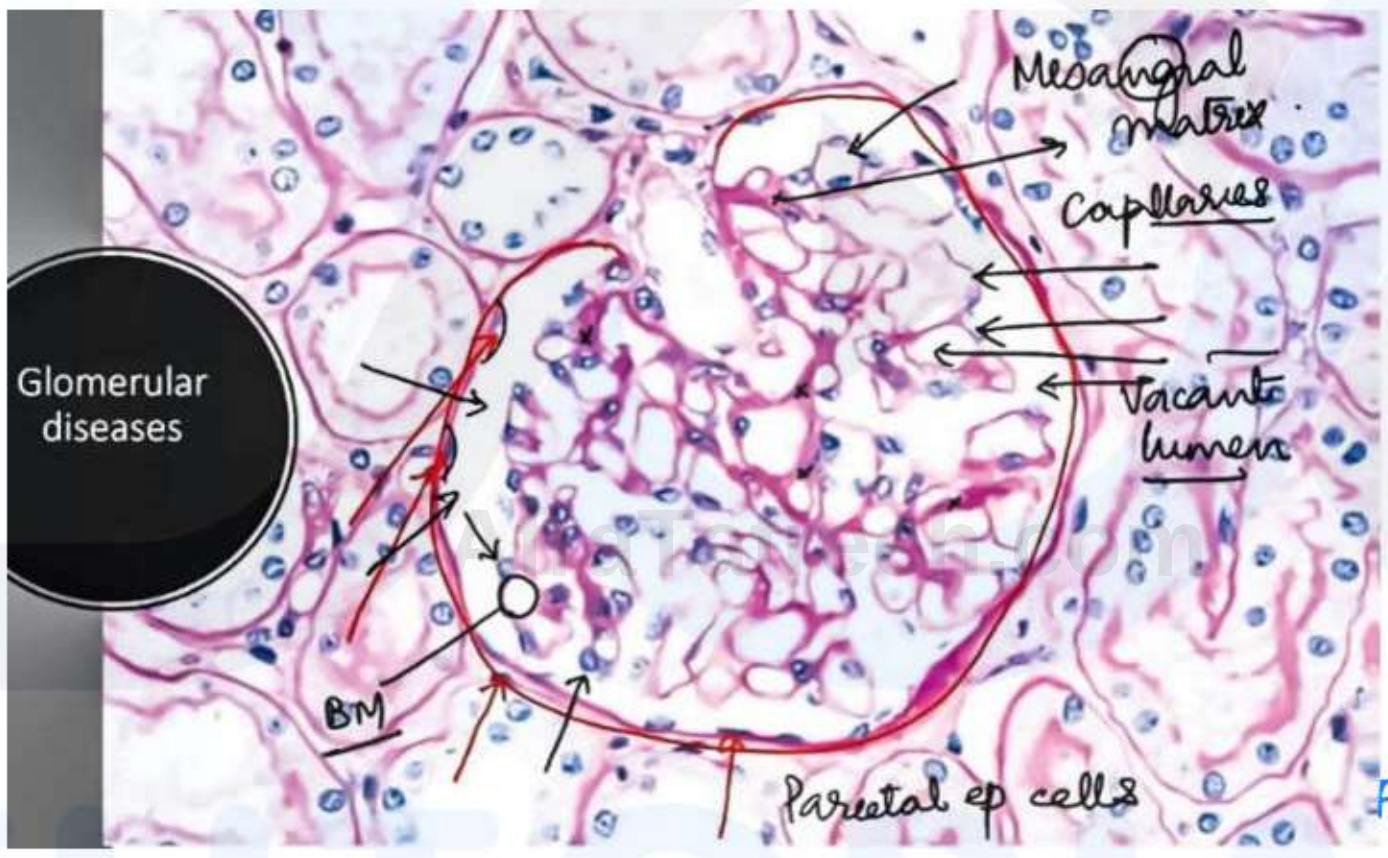

Fig: 2

- Stains to see Basement membrane →

  i. PAS

  ii. Silver Methamine (Better)

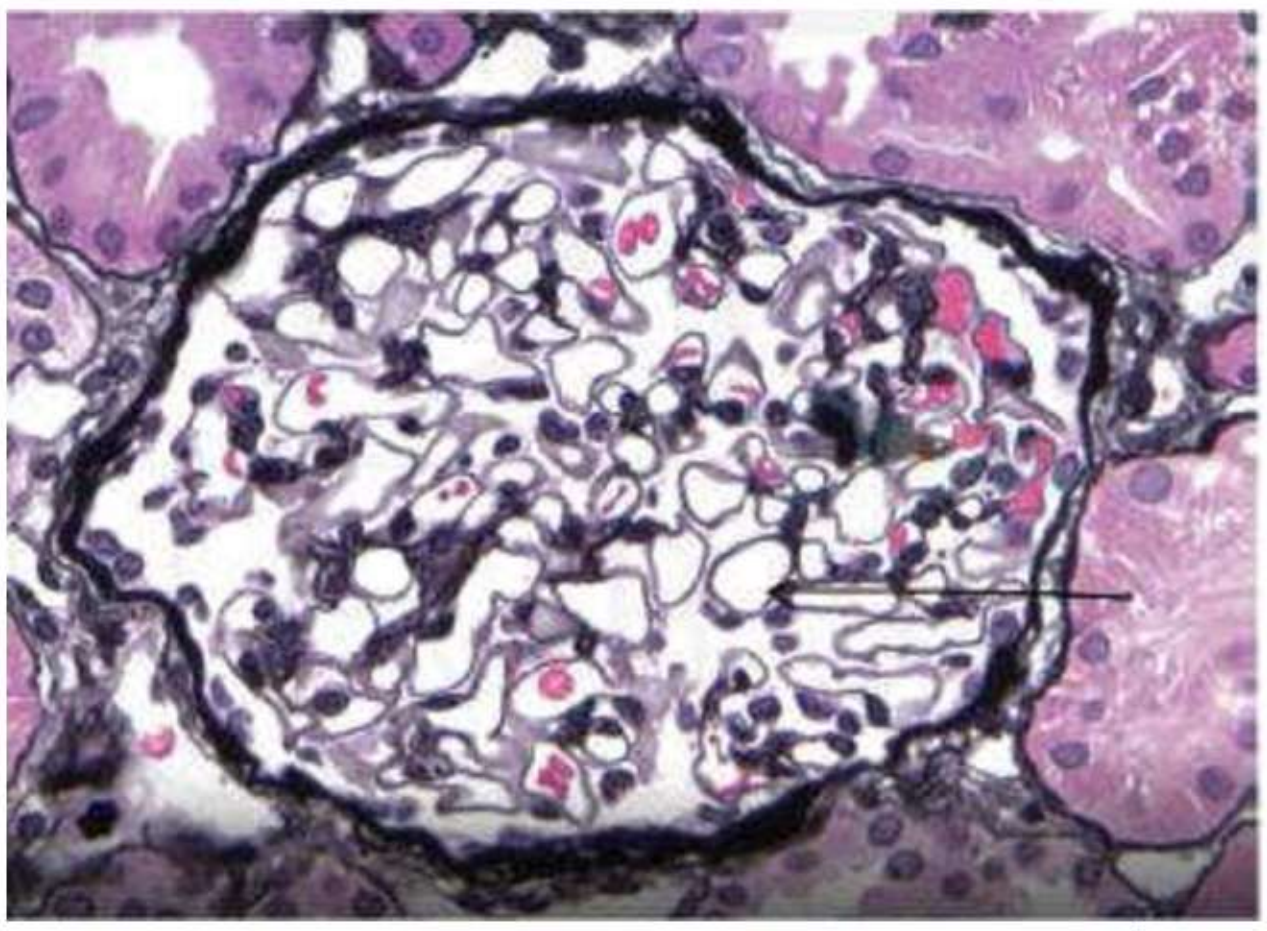

Fig: 3

AfraTafreeh.com

- Silver methamine stain
  - Thickness of B.M → One line thick

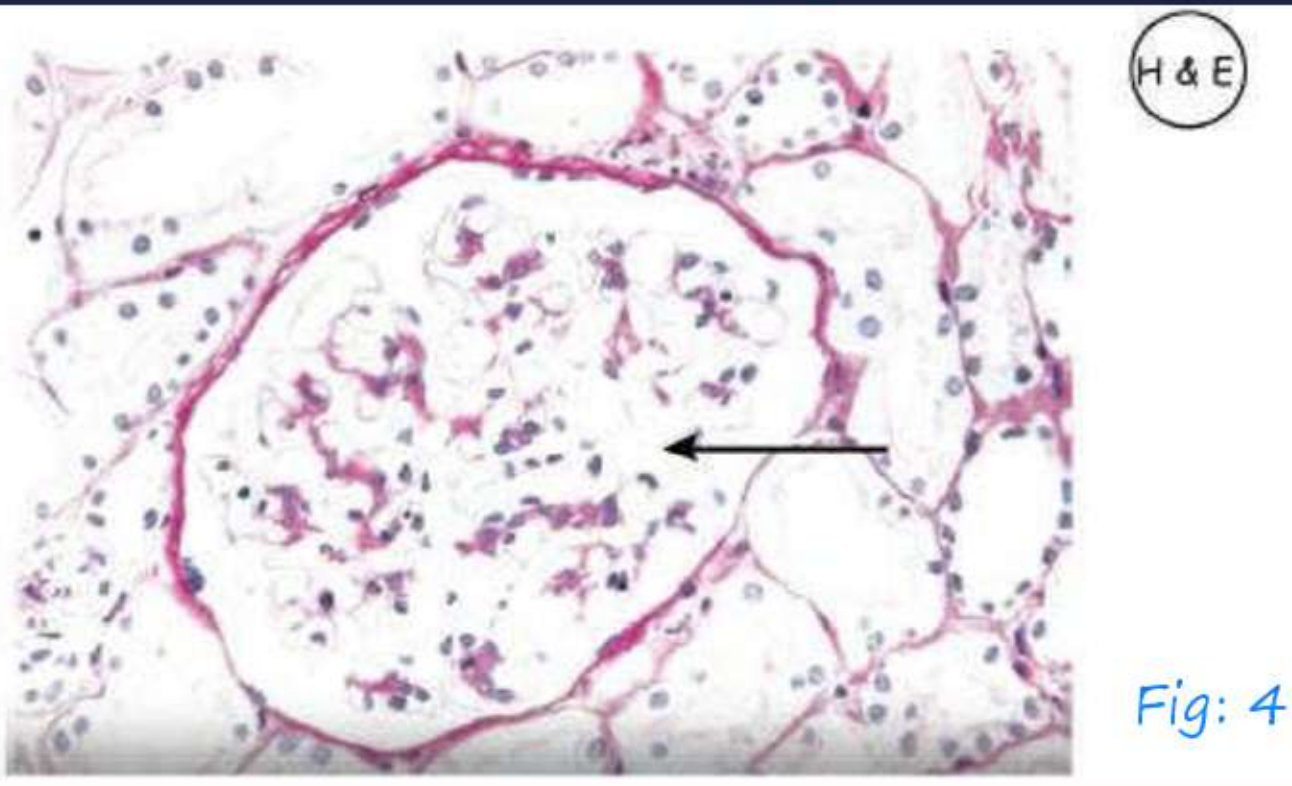

Fig: 4

Abnormalities of normal glomerular structure

I. Diffuse thickening of basement membrane

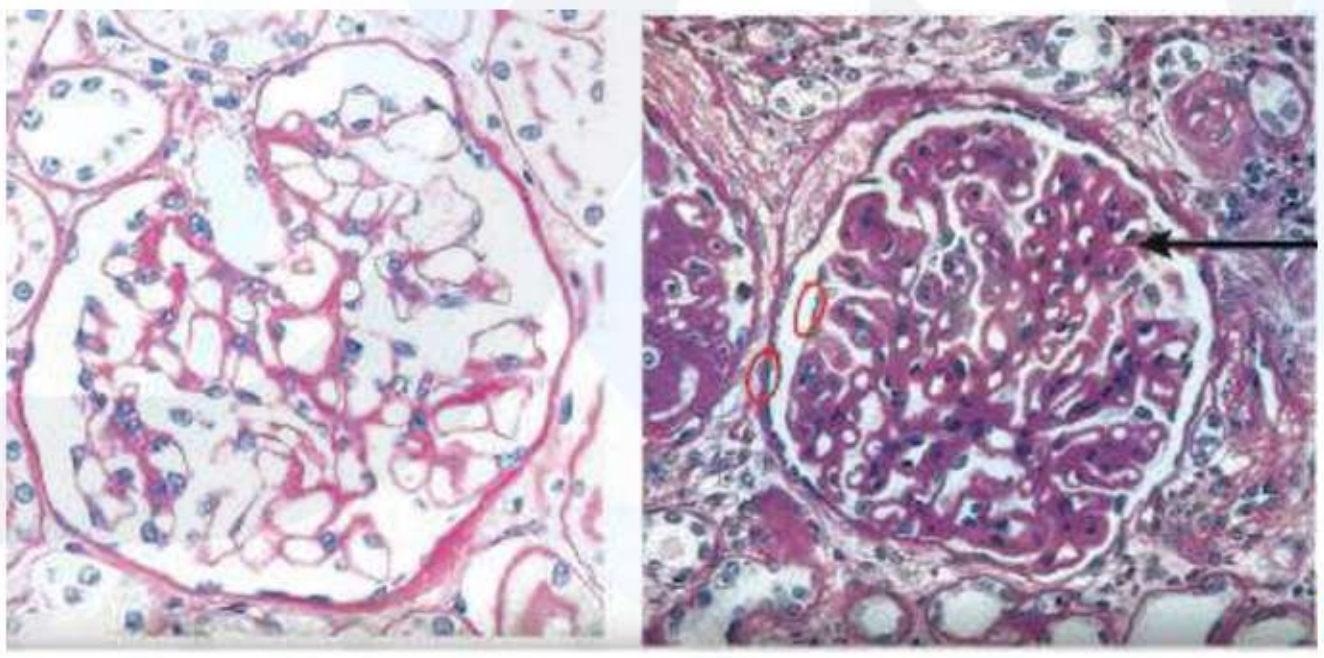

Fig: 5

II. Endocapillary proliferation – typical feature of PSGN

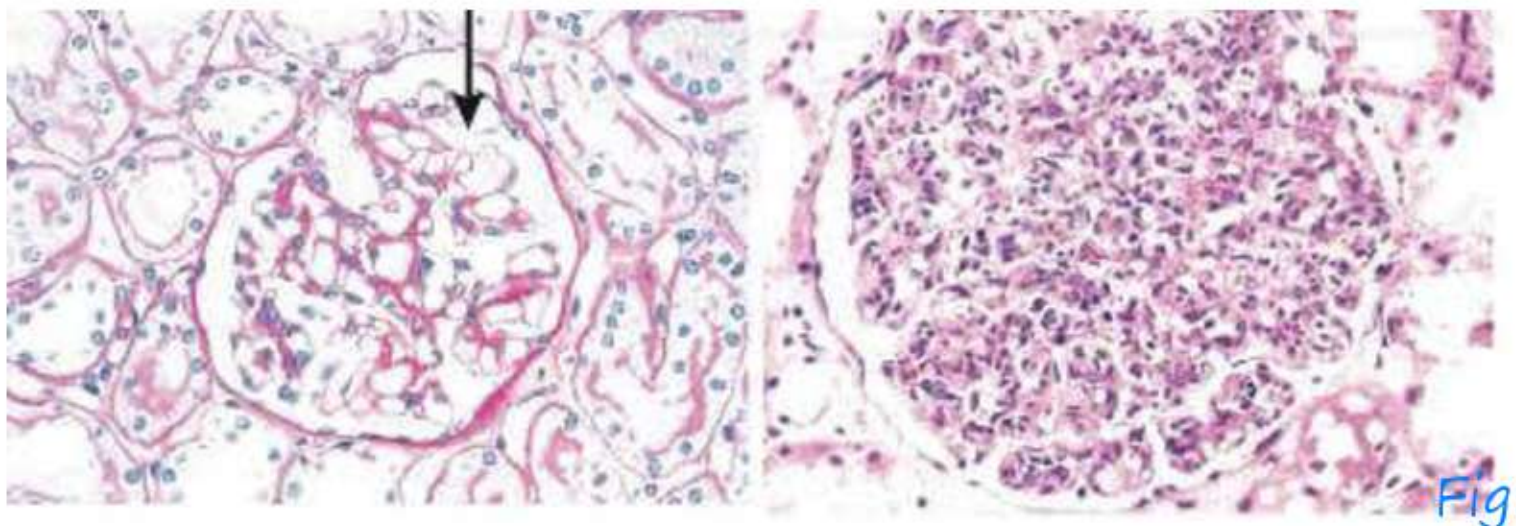

Fig: 6

III. Proliferation of parietal cells forming crescents (Exorability proliferation) visceral epidural cells can get entrapped in crescents

TUTORIALS LOGIN FOR SUCCESS

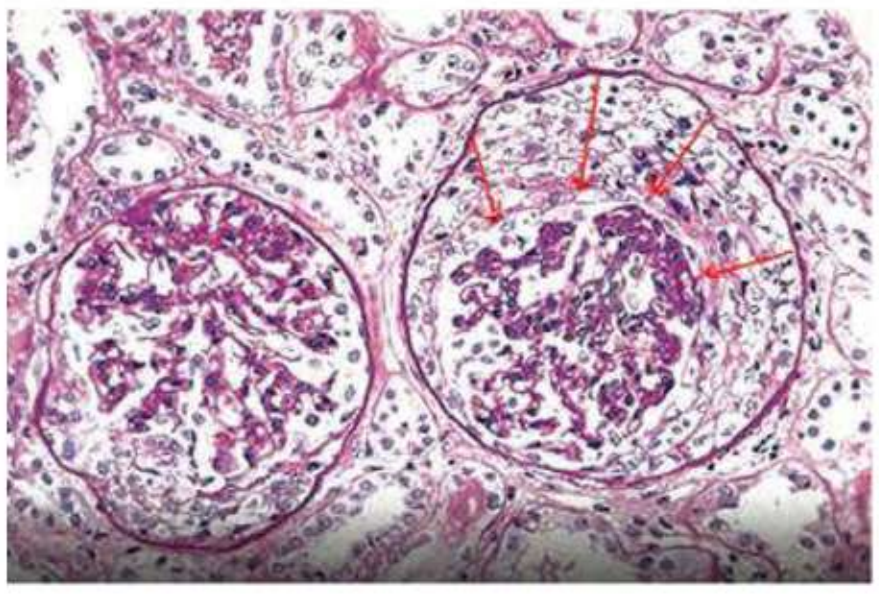

Fig: 7

- Seen in RPGN Crescentic glomerulonephritis

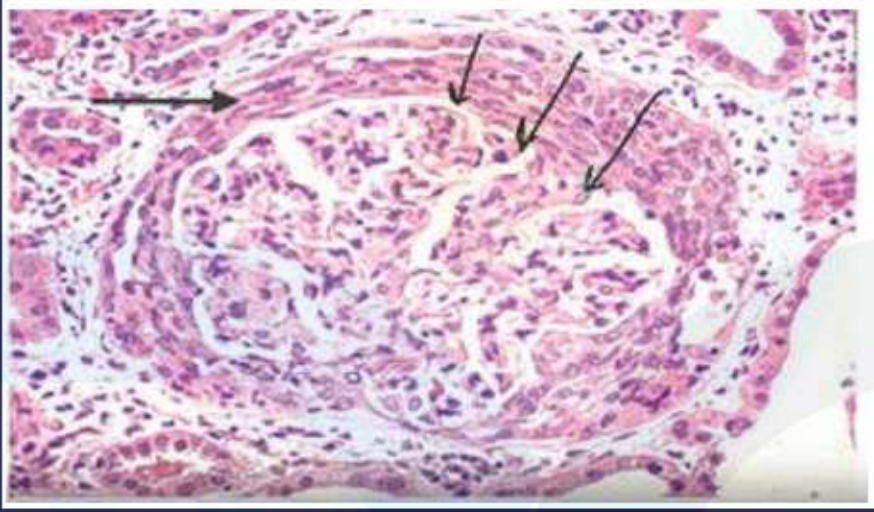

Fig: 8

IV. Only few glomeruli involved → <50% is called focal disease ,>50% is diffuse

AfraTafreeh.com

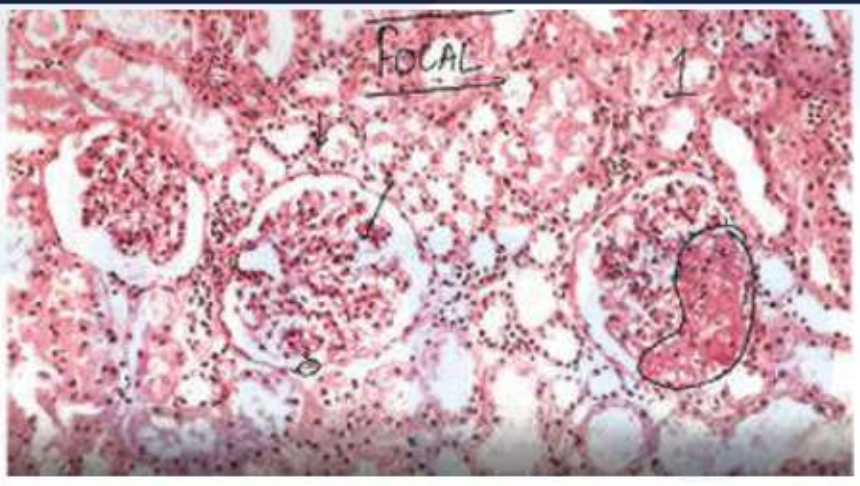

Fig: 9

- Only part of one glomerulus involved → this is called segmental disease, one full glomeruli involved is global disease

  Focal + segmental disease = <u>Focal segmental</u> Glomerular sclerosis

Hyalinosis	Sclerosis
• Excessive deposition of	• Collagen deposition

AfraTafreeh.com

plasma proteins usually around blood vessels	•Special stain to see collagen – blue on mason Trichrome (muscle appears red on MT stain)

- Increased mesangial matrix → seen in mesangioproliferative glomerulonephritis
- Increased deposition in mesangial matrix → seen in IgA Nephropathy

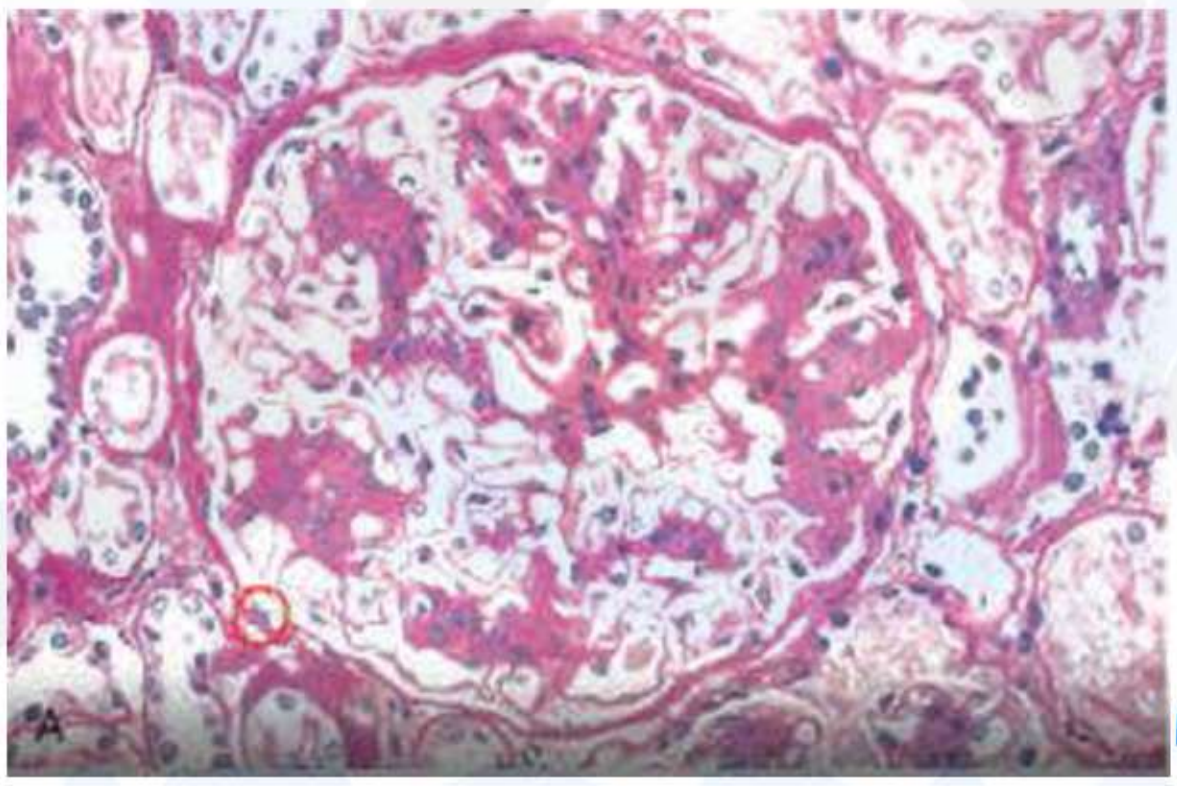

Fig: 10

TUTORIALS
LOGIN FOR SUCCESS

ELECTRON MICROSCOPY OF KIDNEY – UNDERSTANDING WITH IMAGES

Fixative of choice for E/M → 2% Glutaraldehyde

- Normal E/M image of Bowman's Capsule

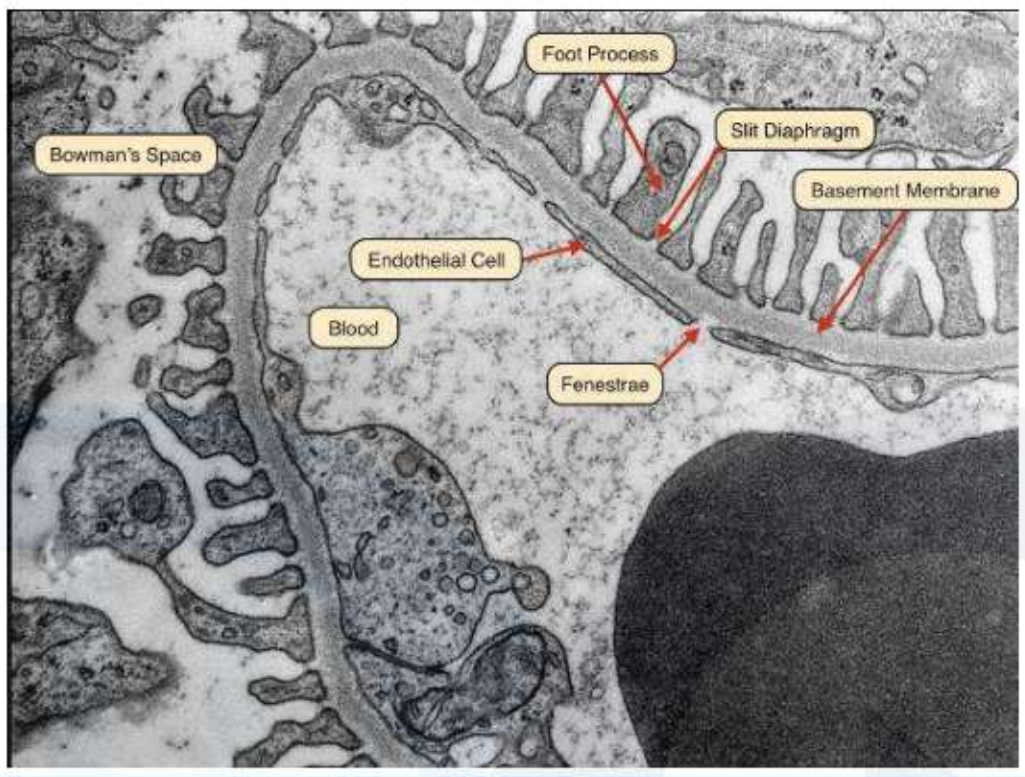

Fig: 1

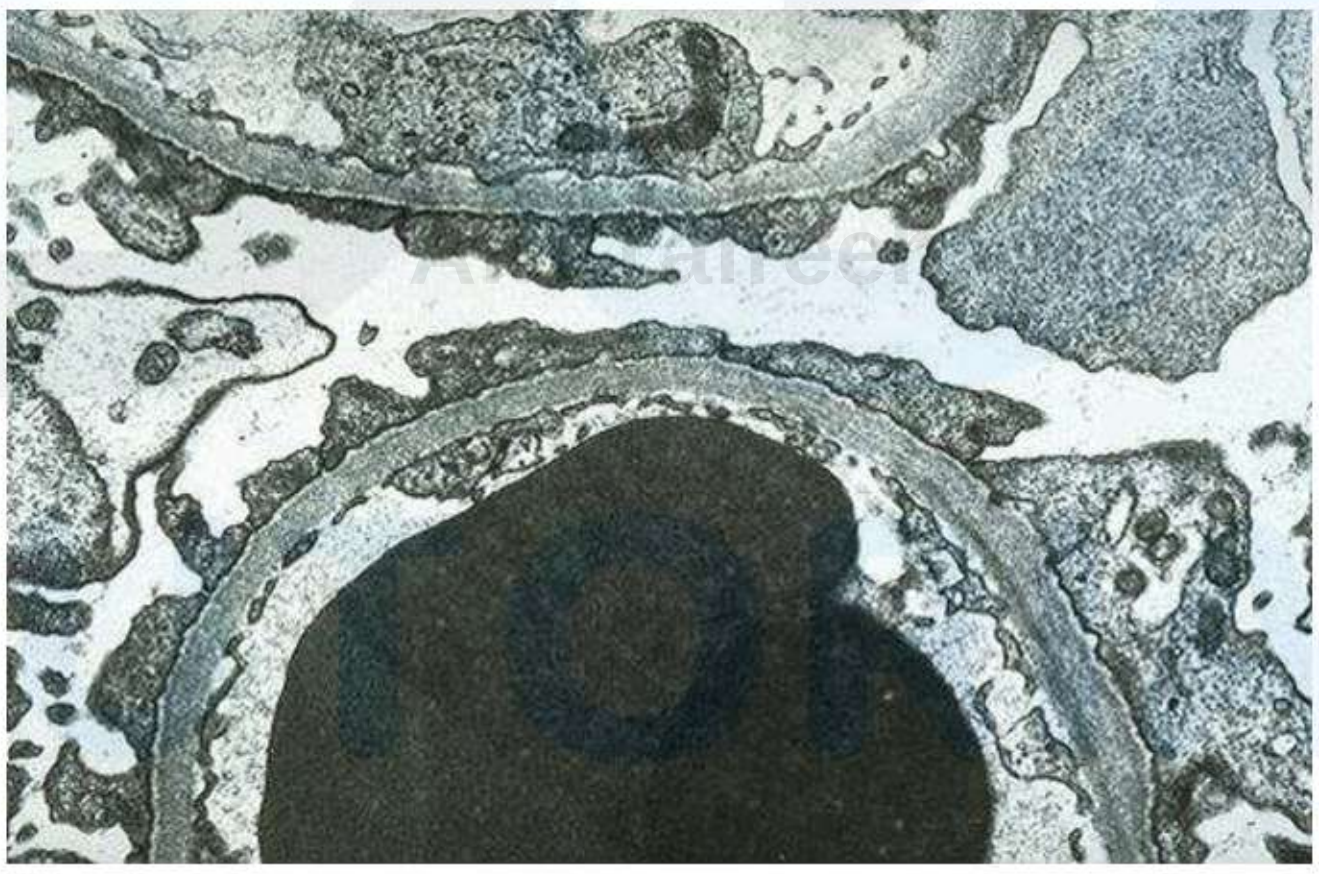

Fig: 2

- Flattening of foot processes or effacement of foot processes. These group of disorders are called podocytopathies

AfraTafreeh.com

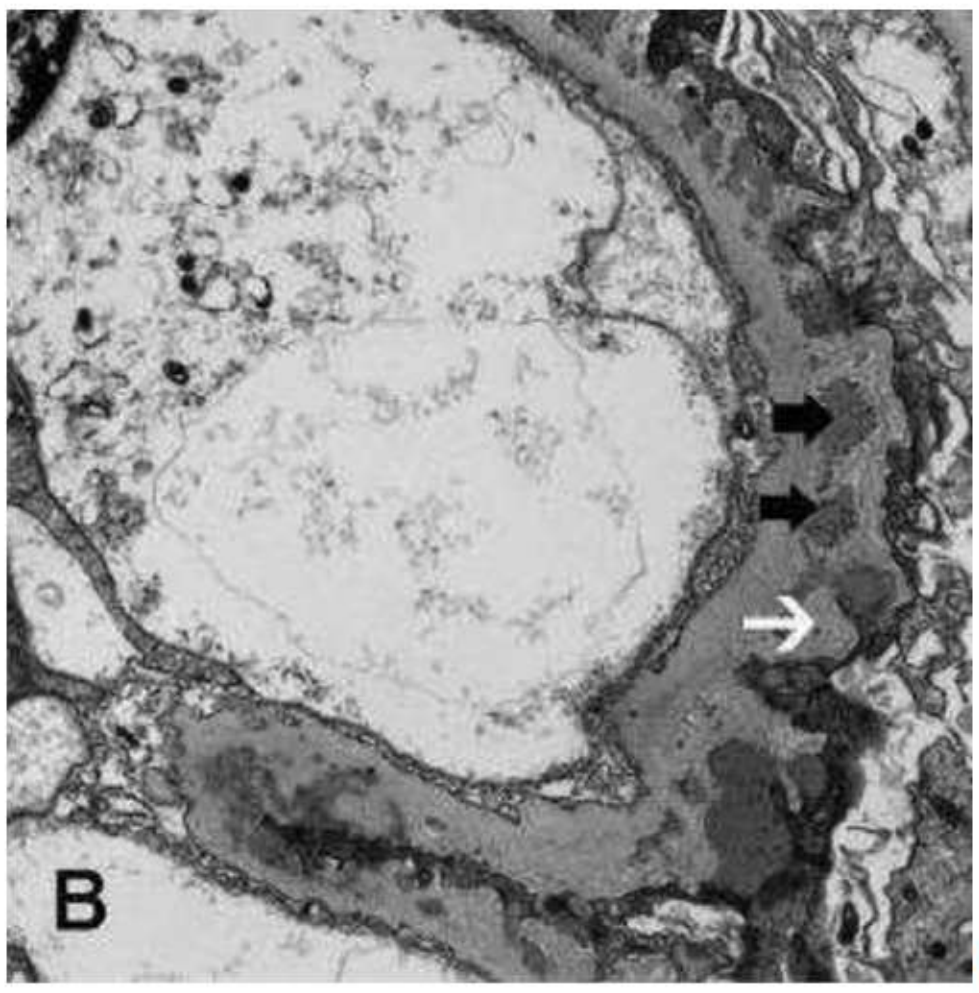

Fig: 3

- Sub epithelial deposits seen in membranous glomerulonephropathy

Dense deposit disease

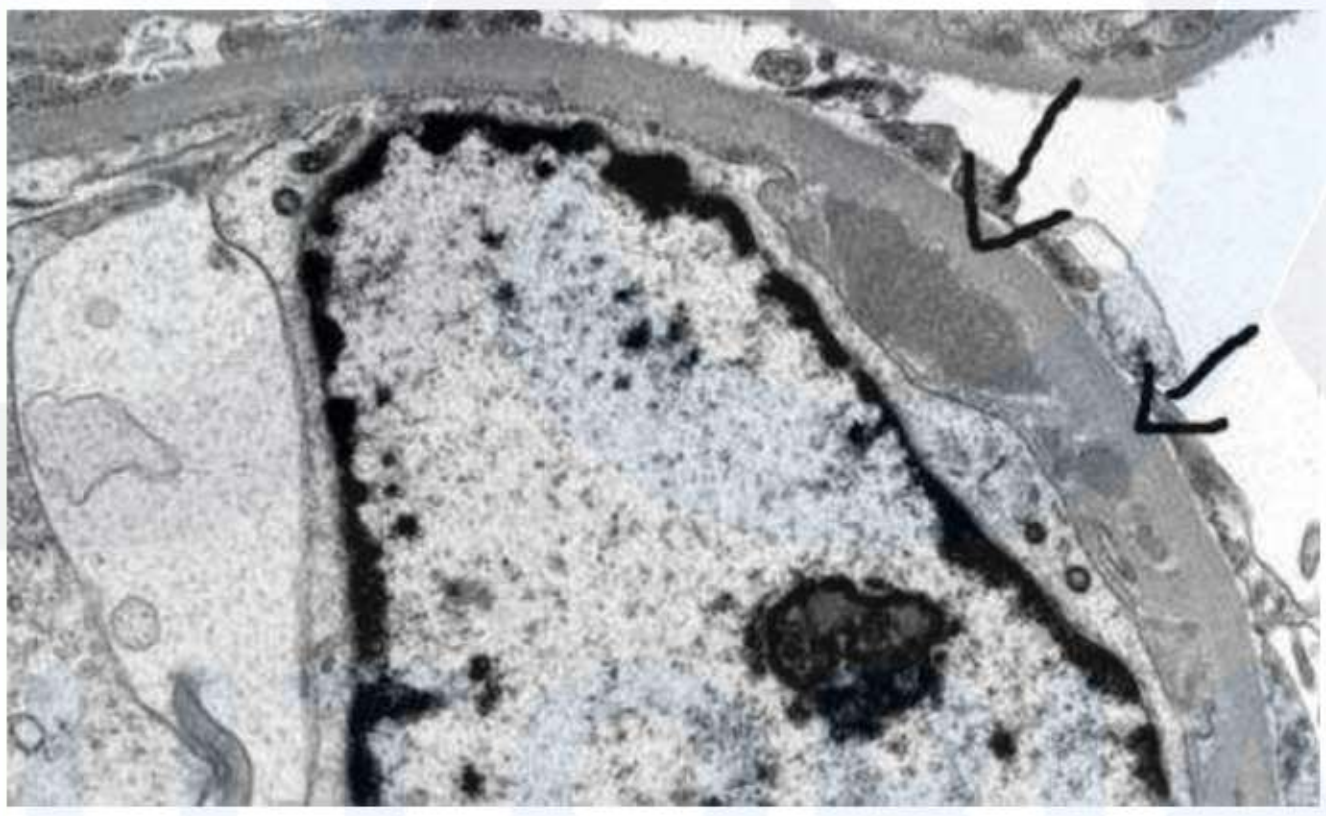

Fig: 4

- Subendothelial deposits seen in MPGN I

LOGIN FOR SUCCESS

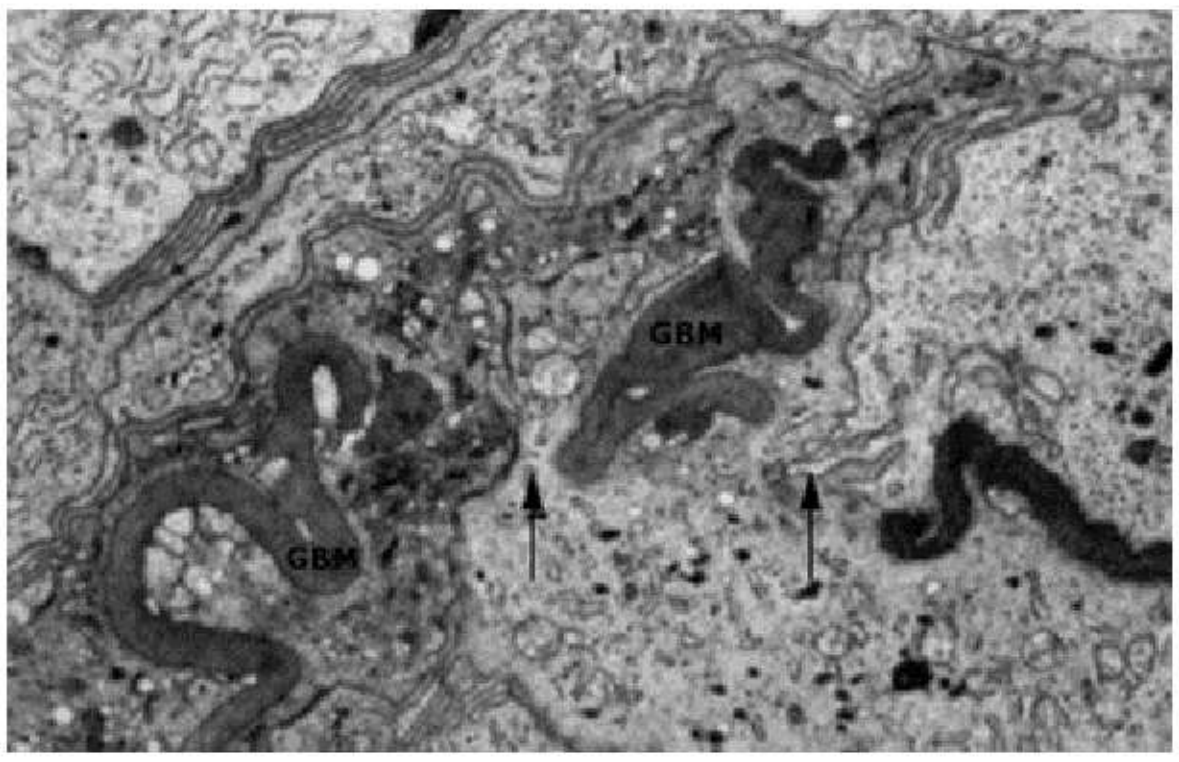

Fig: 5

- Fragmented and wrinkled B.M seen in RPGN

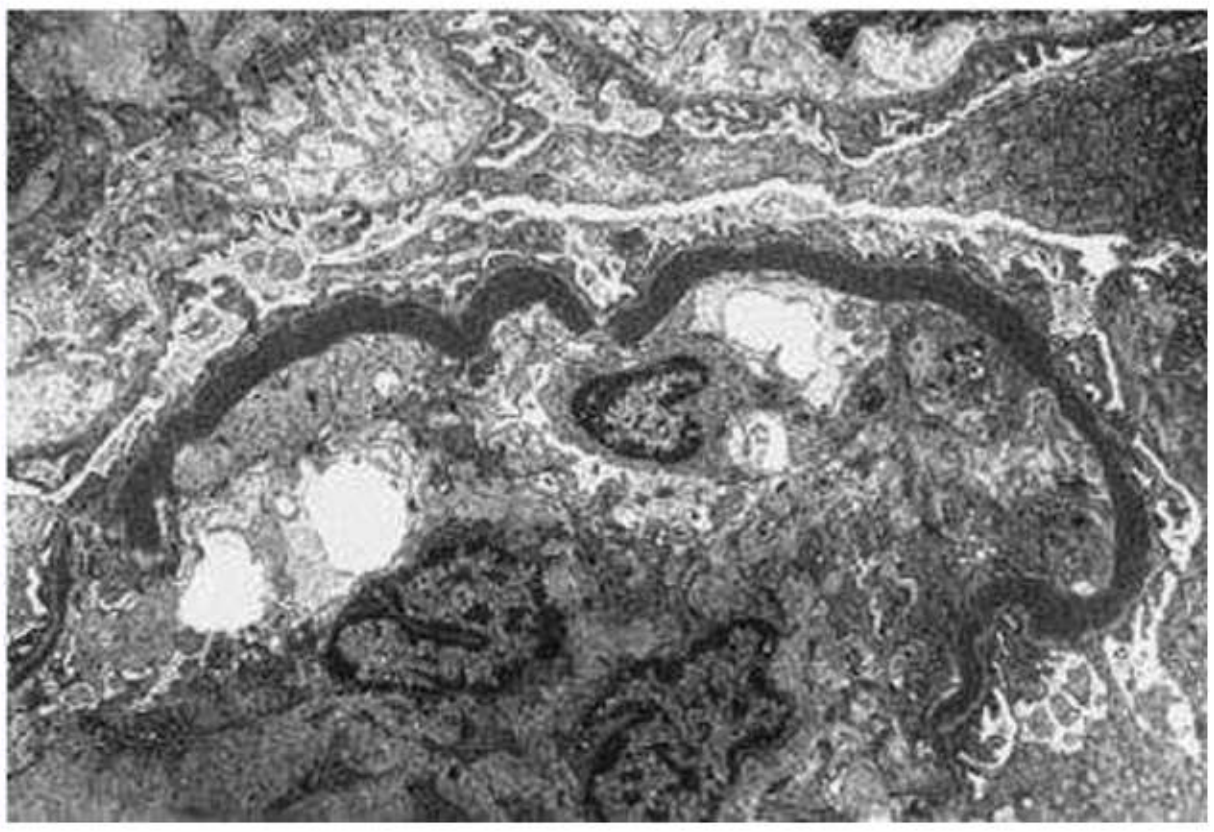

Fig: 6

- Deposits in BM seen in Dense deposit disease or MPGN

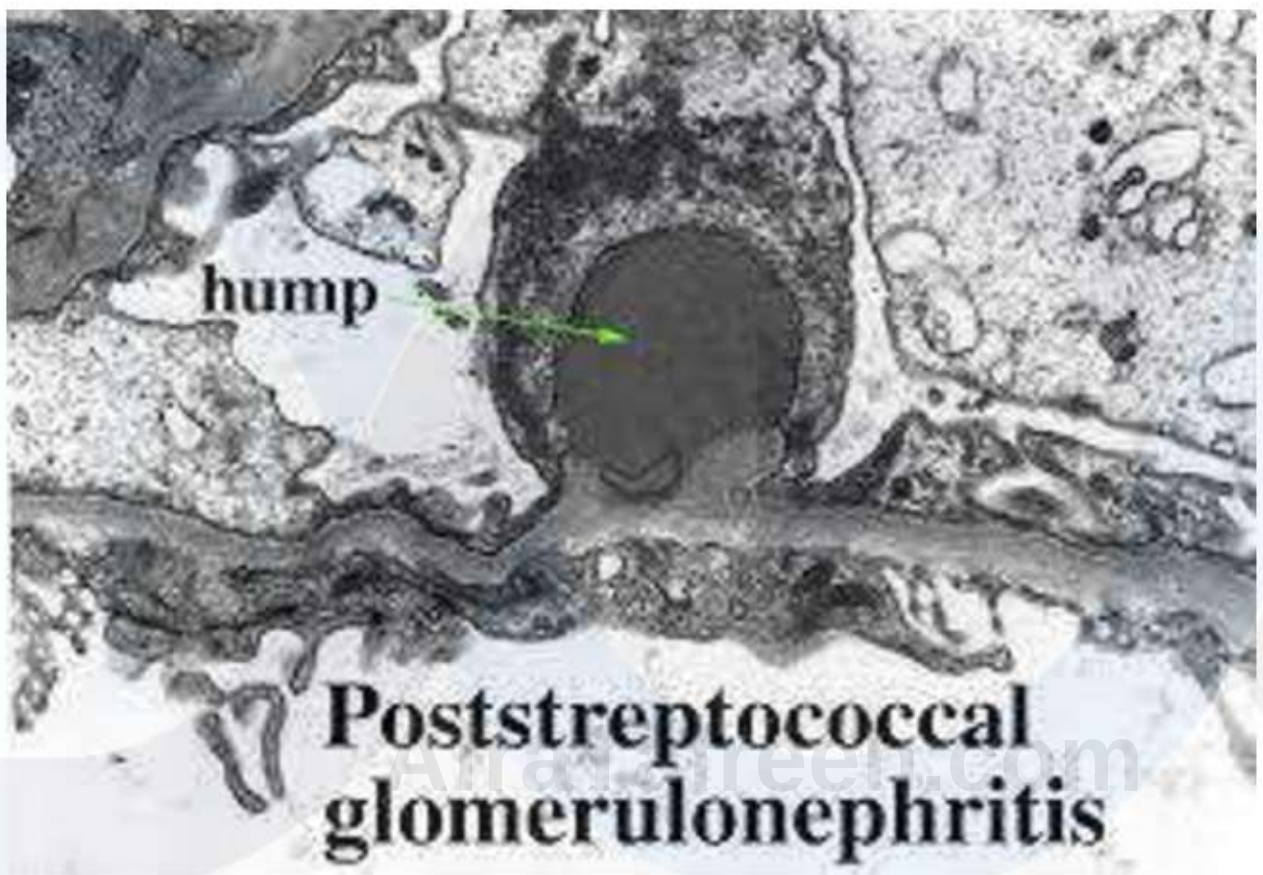

Fig: 7

- Sub epithelial HUMPS Seen in PSGN

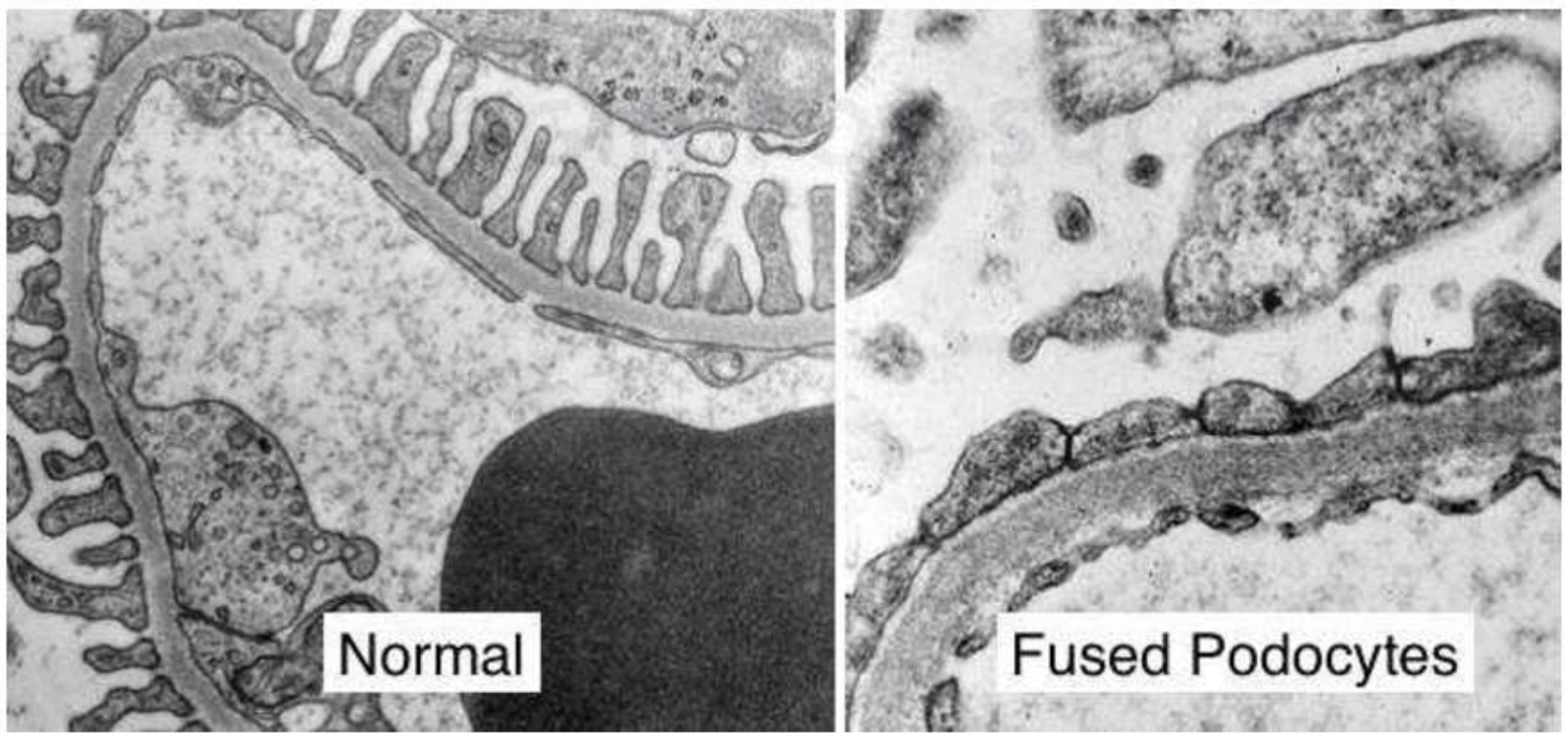

Fig: 8

- Effacement of foot process → Slide of minimal change disease.

AfraTafreeh.com

NEPHROTIC SYNDROME

1. Massive Proteinuria > 3.5g/day
2. Hypoproteinemia (<3 g/dl) -> Oncotic Pressure of blood falls
3. Oedema (Majorly due to fall in oncotic pressure)
4. Lipiduria

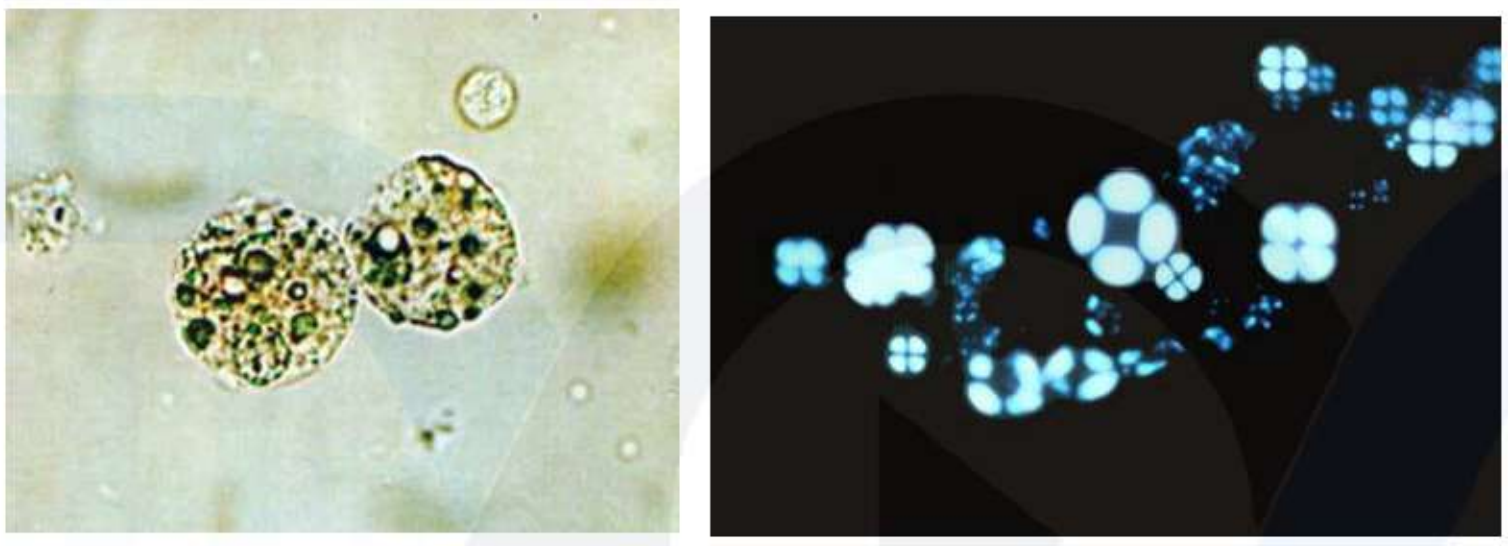

Fig: 1

- Oval fat bodies (renal tubular cells with fat globules).

  Show maltese cross under cross polarization
- Associated with nephrotic syndrome

5. Hyperlipidemia

TUTORIALS LOGIN FOR SUCCESS

Complications of Nephrotic Syndrome

1. Loss of Transferrin in urine -> Anemia
2. Loss of AT III, Protein C & S (anti ~coagulant proteins) in urine

   Thrombosis common, especially Renal Vein Thrombosis
3. Immunoglobulins lost in urine > Recurrent infections

Diseases Presenting as Nephrotic Syndrome

Primary Nephrotic Syndrome Right Indent)

1. Most common cause Nephrotic Syndrome in child» Minimal change disease
2. Most common cause NS in Adults > FSGS
3. Most common cause NS in Elderly > Membranous nephropathy

Fatty Cast

- Pathognomic for High urinary protein Nephrotic Syndrome
- In the Ascending Loop of Henle, Tamm Horsfall Proteins (net like Proteins) entrap Oval fat Bodies forming Fatty Cost

AfraTafreeh.com

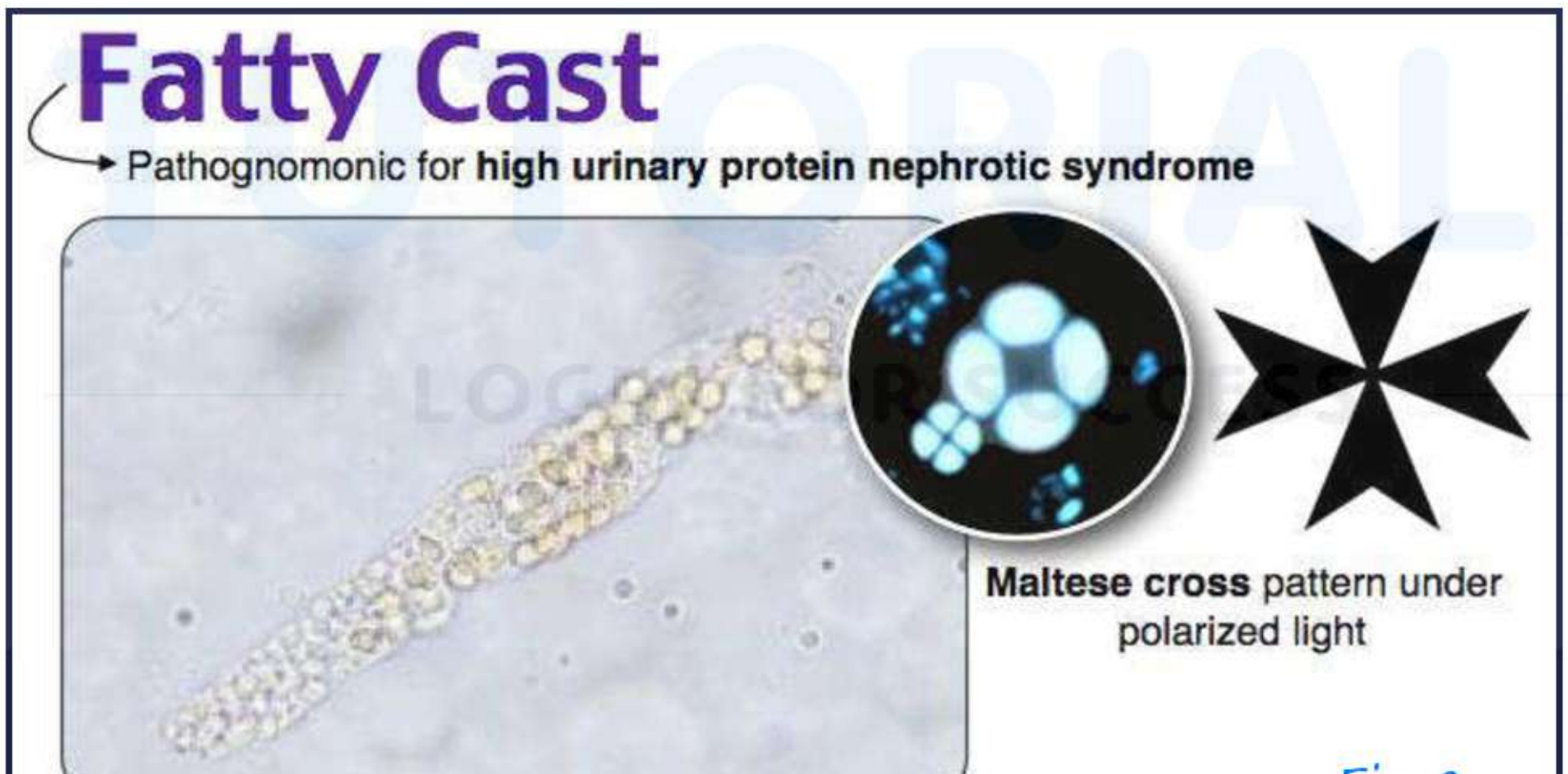

Fig: 2

- Show Maltese Cross Patten appearance under polarized light
- Remember: All 4 margins of Maltese cross appear equal in fatty cast.

AfraTafreeh.com

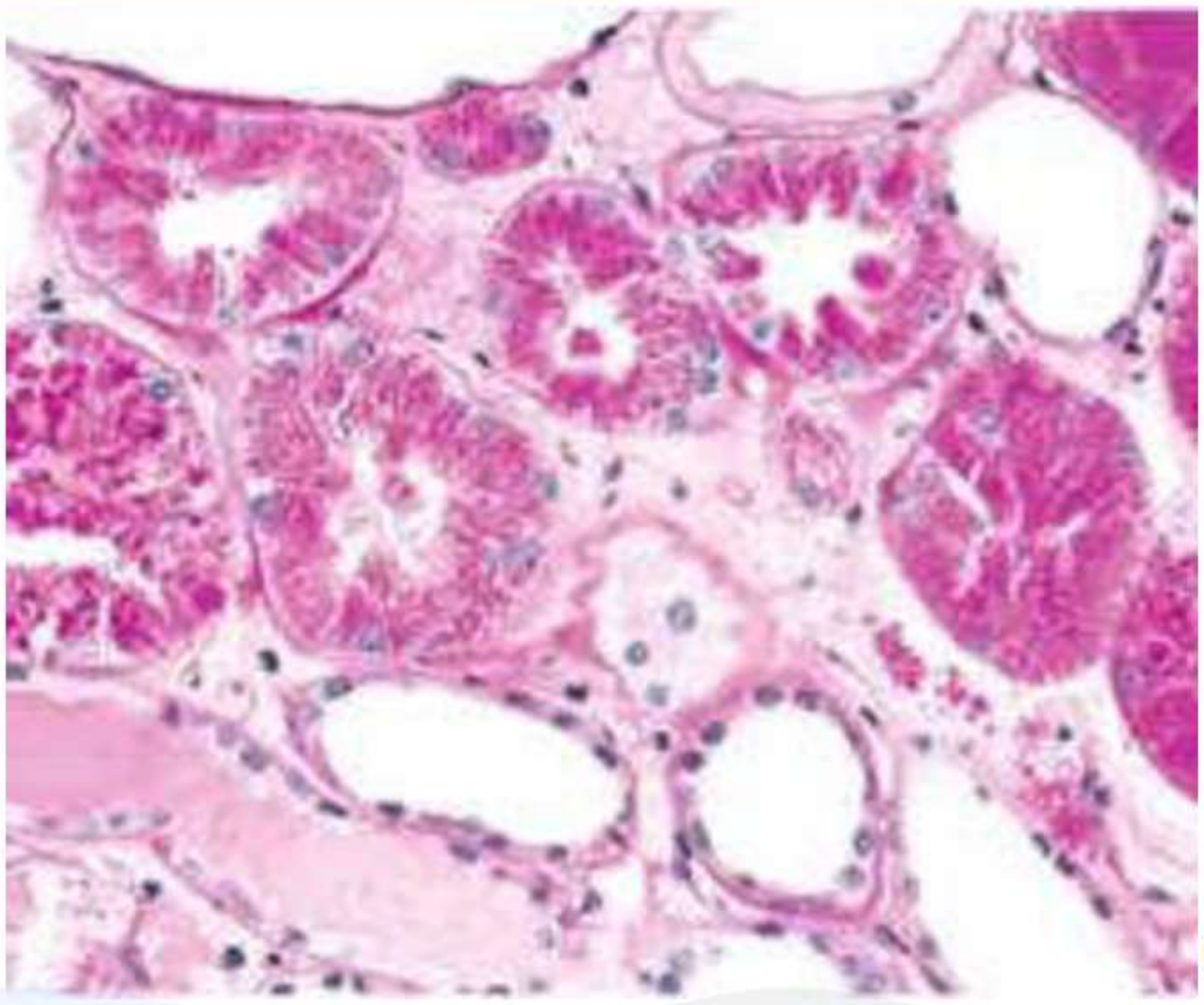

Fig: 3

- Resorption droplets in PCT

TUTORIALS
LOGIN FOR SUCCESS

MINIMAL CHANGE DISEASE (NEPHROTIC SYNDROME)

1.Most common cause of Nephrotic Syndrome in Child

2.Not an immune complex mediated disease.

3.Etiology – Idiopathic

Hodgkins lymphoma

4.Pathogenesis:

T cell Dysregulation

↓

Release abnormal Cytokines

Cause effacement of foot process of VEC	Loss of sialoproteins from BM. Negative charge of BM is lost LMVU proteins Example: Albumin – 70K Da Transferrin – 76 k are lost in urine ↓ Highly selective proteinuria

5.Responds excellently to steroids because steroids stop T cell dysregulation and release of Abnormal Cytokines

6.On Light Microscopy.

AfraTafreeh.com

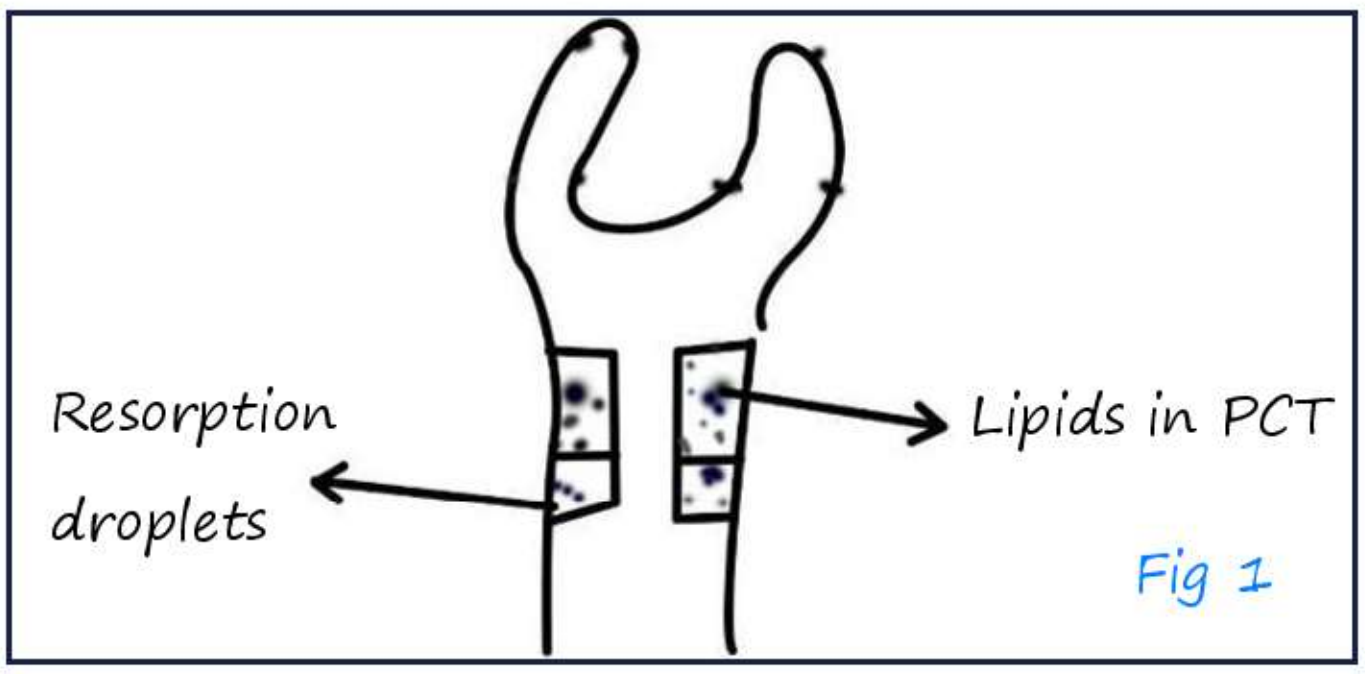

Fig 1

- Previously called LIPIOD NEPHRONS due to Lipid accumulation in PCT Cells

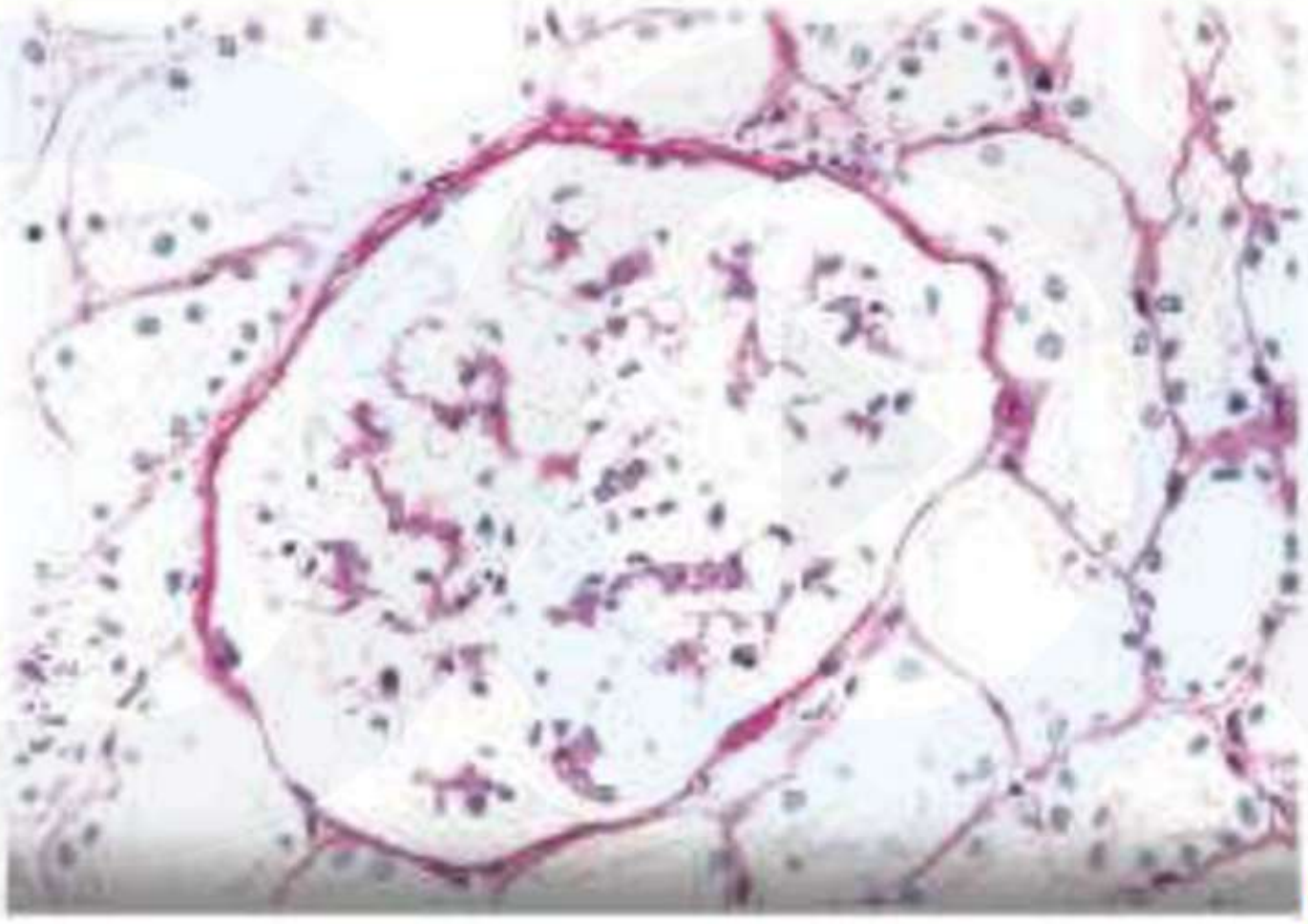
Fig 2

7.On electron microscope of foot processes

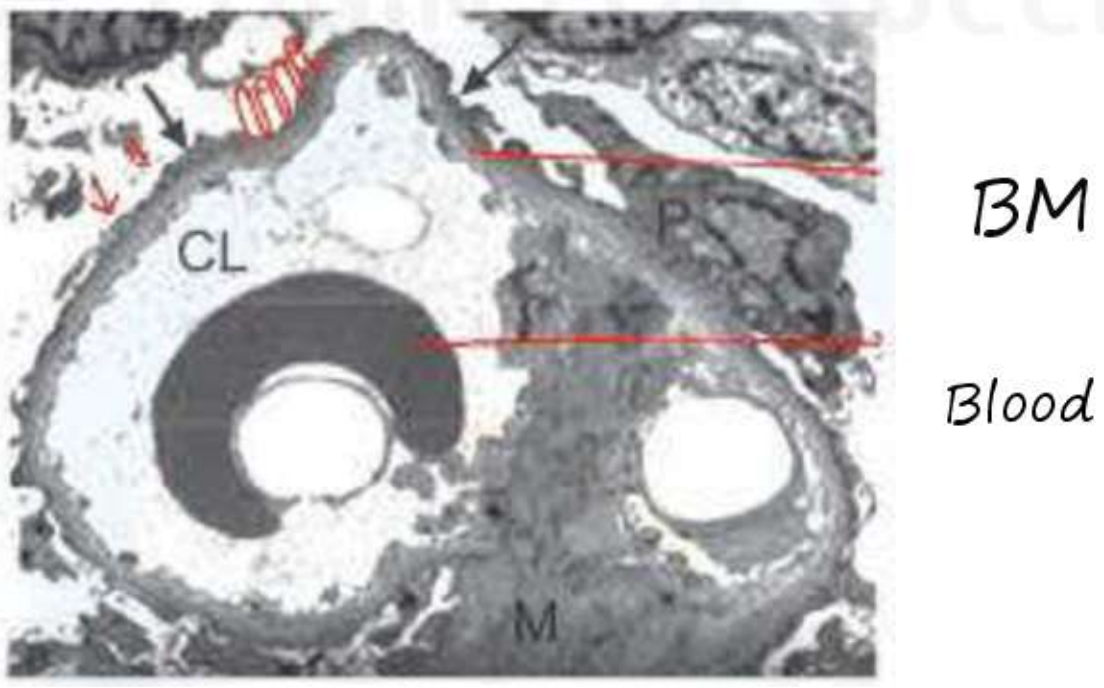

E/M of MCD
Fig 3

8.Immune Fluorescence – No findings there are no immune complex deposits.

FOCAL SEGMENTAL GLOMERULO SCLEROSIS

1.Most common cause of Nephrotic Syndrome in Adults

2. Hallmark -> Damage to Visceral epithelial cells

3.Cause:

- HIV
- Heroin Abuse
- Massive obesity
- Obstruction
- Reflux nephropathy
- Renal Ablation
- Sickle cell anemia

Causes FSGS and Papillary necrosis in kidney	
classical FSGS	HIV FSGS
Direct damage of VEG podocyte injury (Podocytopathy)	causes podocyte proliferation massive proliferation of podocytes ↓ collapse of Glomerulus

On L/M:

1) <50% Glomeruli involved = Focal disease
2) Single Glomerulus partially involved = Segmental
3) Hyalinosis of Capillaries

AfraTafreeh.com

- Endothelial cells become foamy and swollen
- Sclerosis Occurs Cells start adhering to Basement Membrane
- So, there is Focal Segmental Glomerulosclerosis

Columbian Classification → 5 subtypes of FSGS

I. Collapsing Nephropathy

- Most severe, worst prognosis
- Cause

  1.HIV

  2.Pamidronate therapy
- Collapsing Nephropathy is now included in HIVAN -> HIV associated Nephropathy
- On L/M

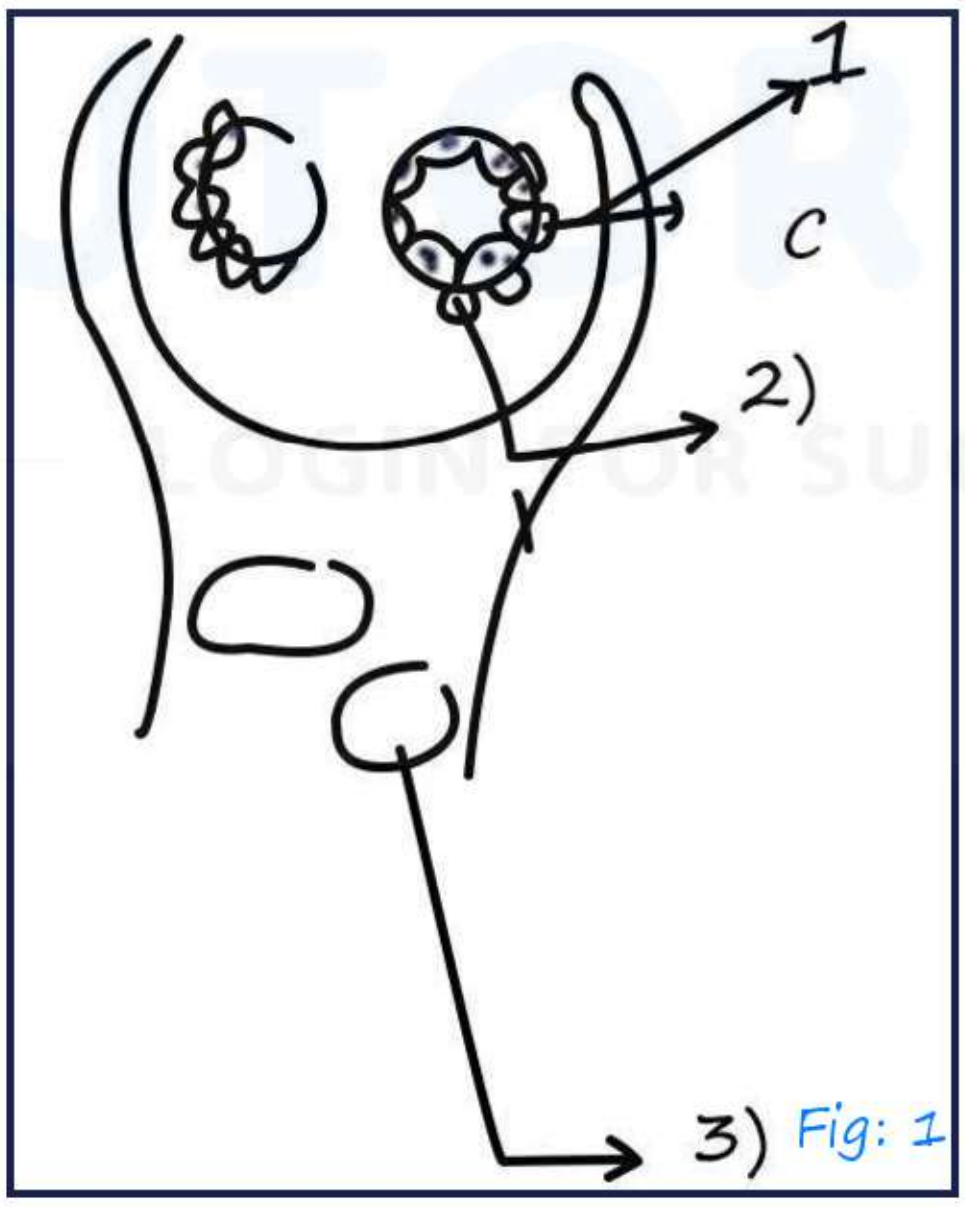

Fig: 1

i. Podocyte Proliferation Causing Collapsing Nephropathy

ii. Tubulo – reticular inclusions in endothelial cells (a modification of Endoplasmic reticulum due to IFN alpha

- Also seen in SLE

iii. Cystic change in Tubules

II. Perihilar Type FSGS

– Sclerosis around Hilum

III. Tip type FSGS

– Sclerosis near the beginning/ Tip of PCT

– Good Prognosis

AfraTafreeh.com

IV. Cellular Variant

V. Not otherwise Specified

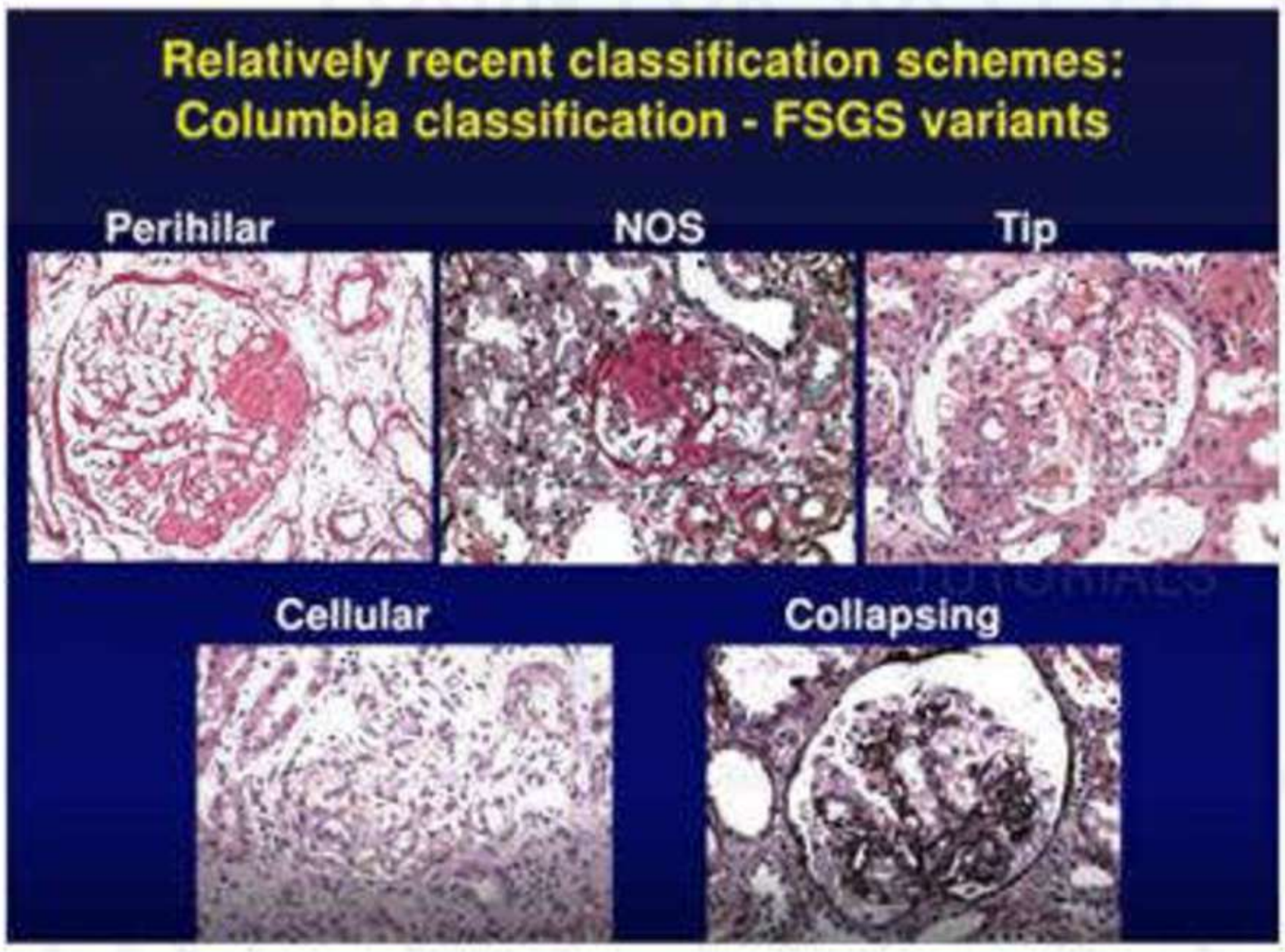

Fig: 2

AfraTafreeh.com

- Stain to see sclerosis - Masson's Trichrome

Genes involved in FSGS

1) NPHS2 -> Codes for podocin
- Most common cause of Steroid Resistant nephrotic syndrome
- AR type of FSGS

2) α Actinin 4 mutation AD type of FSGS

3) TRPC6

4) APOL1 gene on Chromosome 22 — Acquired mutation to protect from trypanosomia in people of African descent.

TUTORIALS
LOGIN FOR SUCCESS

MEMBRANOUS NEPHROPATHY

- Immune complex mediated disease
- Antigen – PLA2R (Phospholipid A2 Receptor)
- Occurs in people with HLA D1 polymorphism
- Pathogenesis – Ab against PLA2 R

↓

Ab – Ag complex deposit in sub epithelium



Proliferation of Basement membrane in spike and Dome pattern

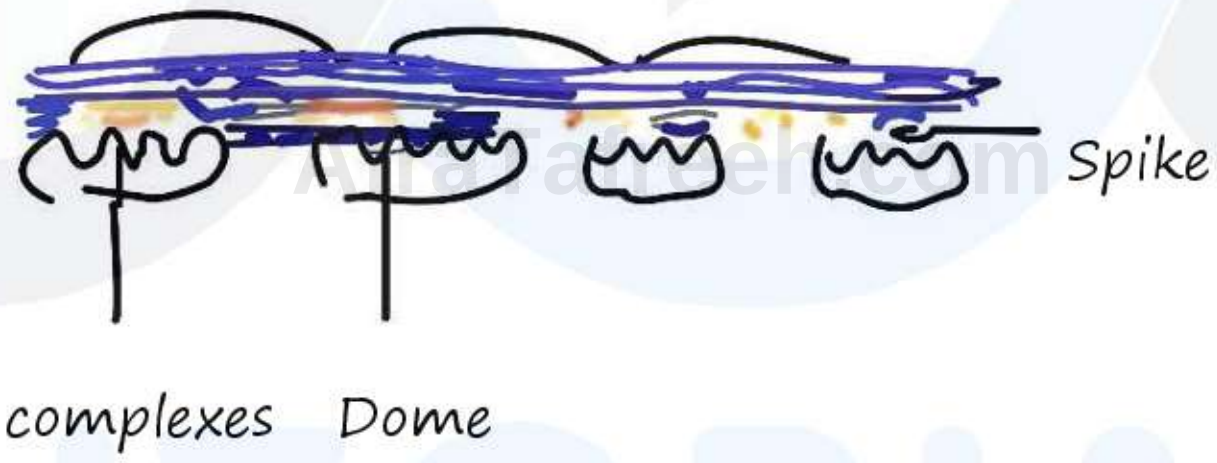

TUTORIALS

On L/m: 1) Thickened B.M

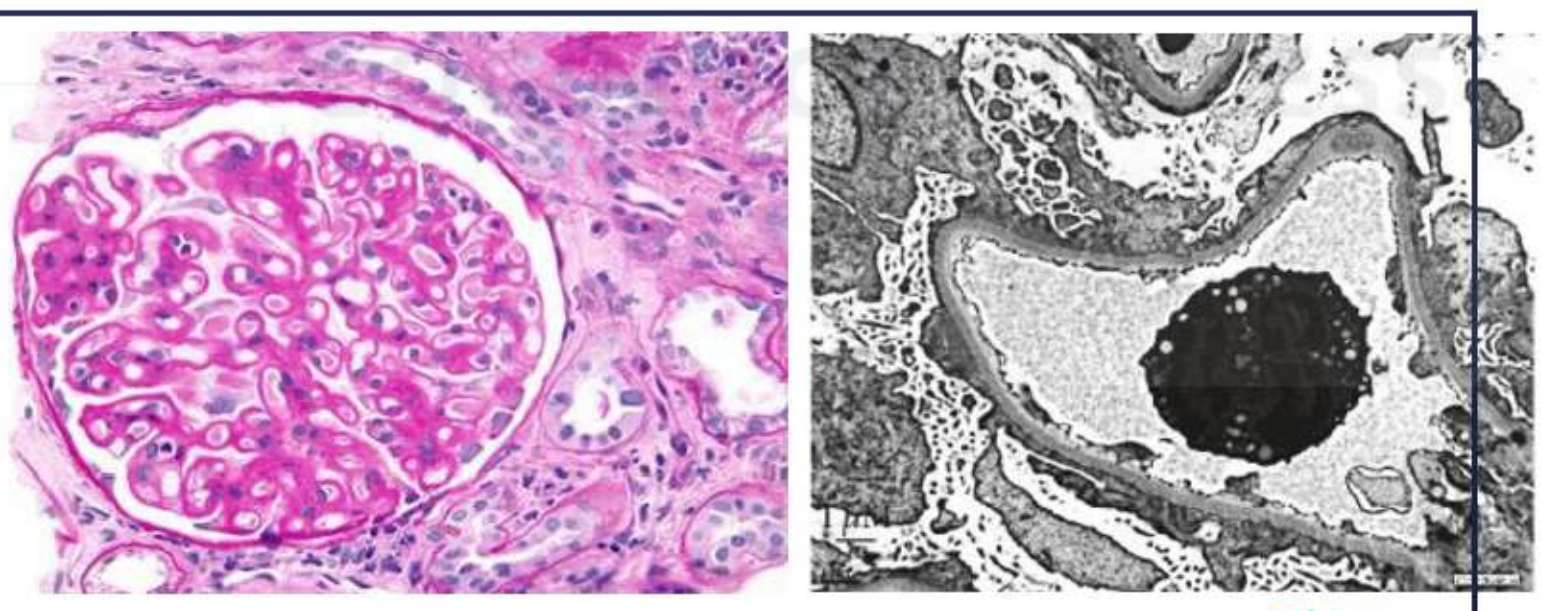

L/M

Fig 1

To see B.M

PAS   Silver stain

AfraTafreeh.com

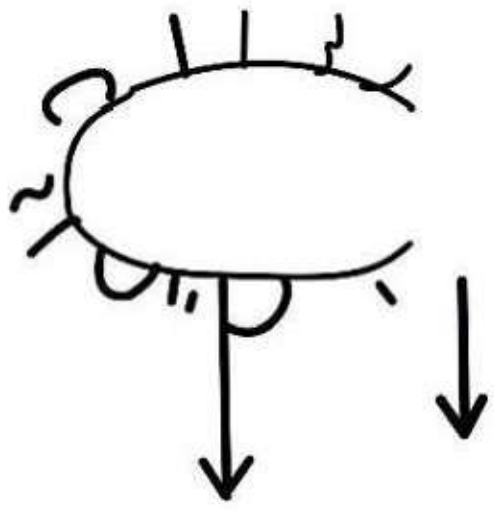

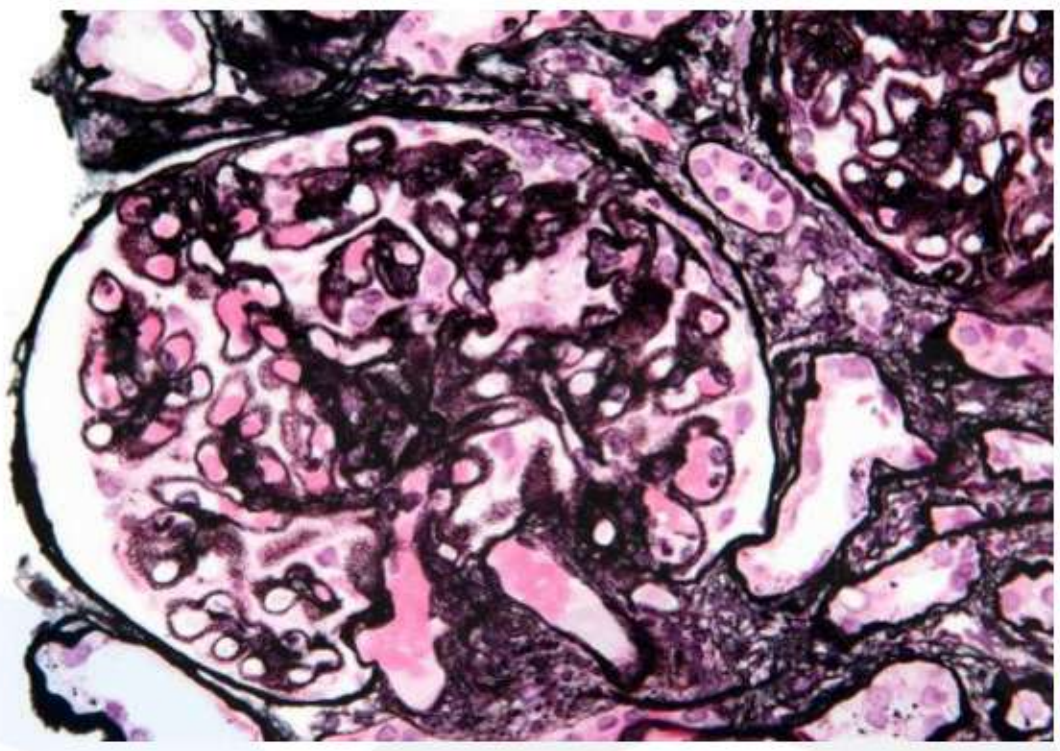
Fig 2

On E/M: 2) Sub epithelial deposit

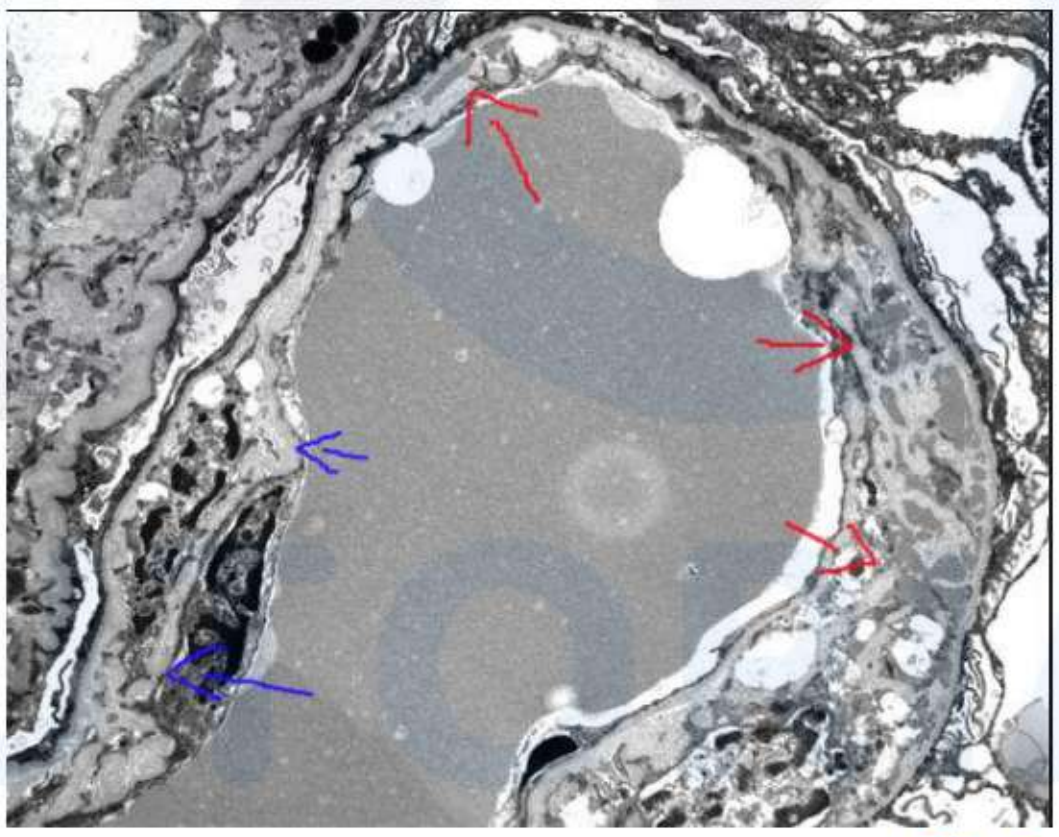
Fig 3

On immunofluorescence → Granular IF

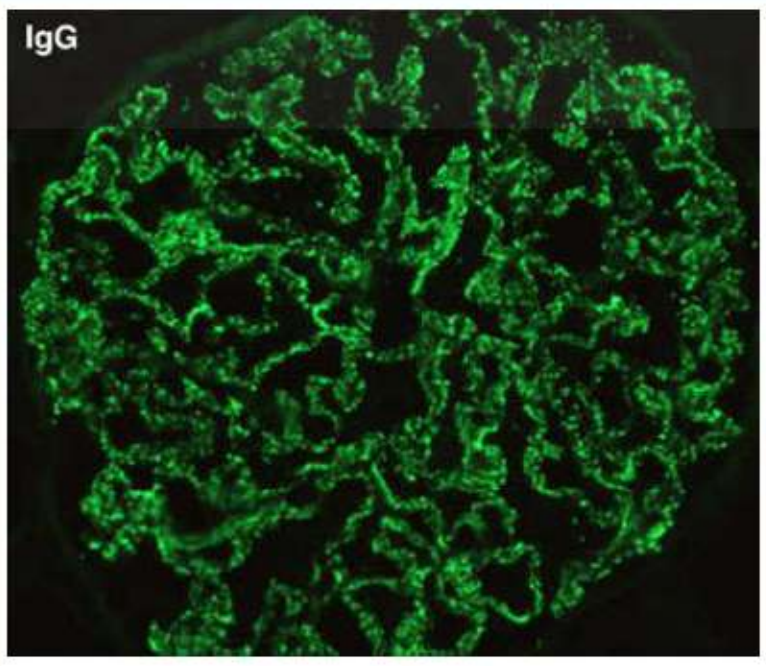

Fig 4

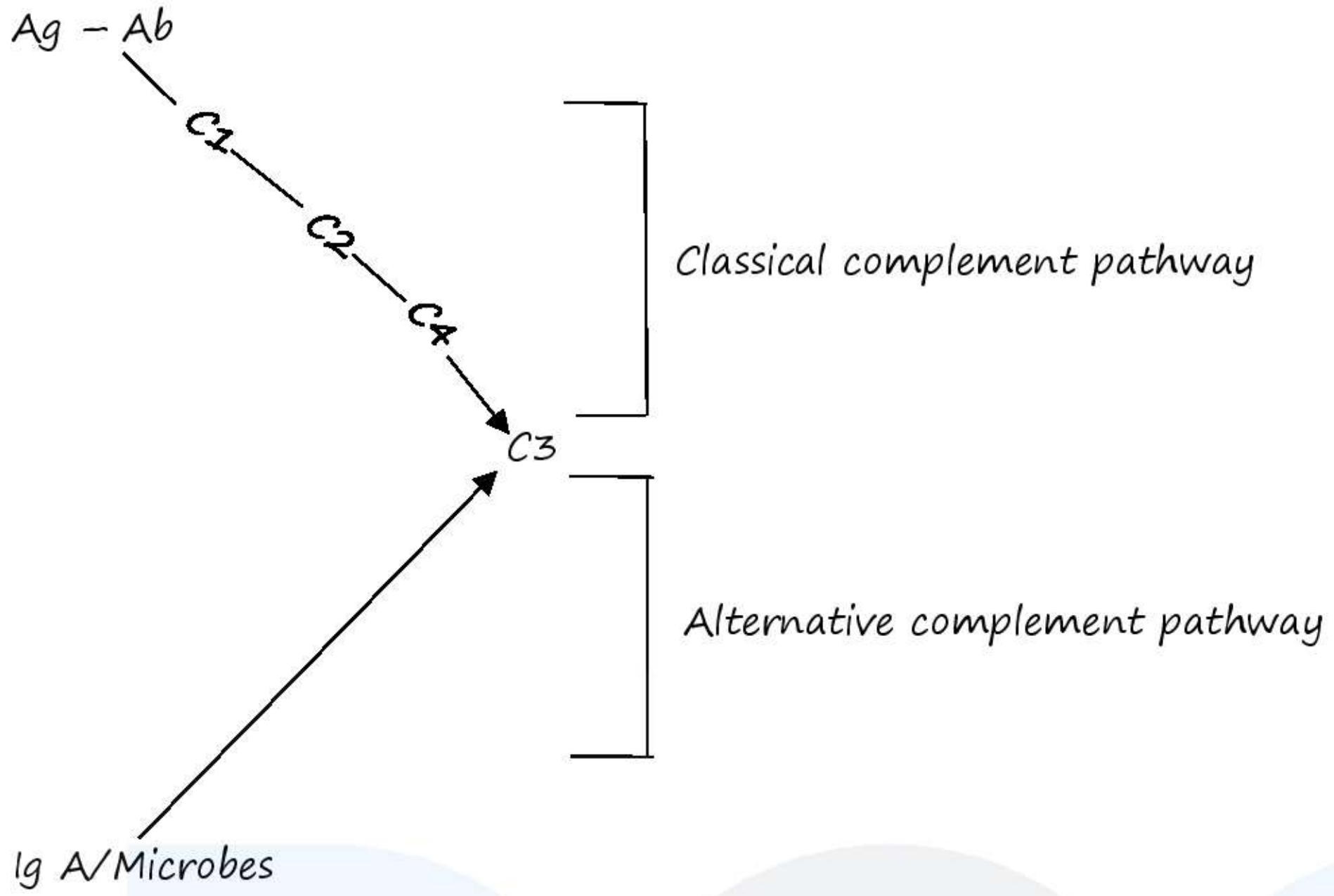

- So granular immunofluorescence is due to deposition by Ig G Ab, C1, C2, C3, C4 in subepithelium

Causes of membranous Nephropathy

AfraTafreeh.com

<u>1° Membranous Nephropathy</u>	<u>2° Membranous Nephropathy</u>
• Idoiopathic • More common than 2° • HLA DQ2 polymorphism causing antigenicity / of PLAZR	• Drugs – Penicillamine, Gold • Cancers – Ca colon, ca lung and melanoma • Autoimmune disease • Injections – HBV, HCV, Syphilis, Malaria, Leprosy

AfraTafreeh.com

NEPHRITIC SYNDROME CLINICAL FEATURES AND URINE FINDINGS

Presents with

- Hematuria
- Oliguria
- Hypertension
- Azotemia – increase in BUN
- Oedema, mild proteinuria

Hematuria

Glomerular cause	Other causes
Dysmorphic RBC	Normal RBC Morphology

Causes

Most common cause of GN in world	Most common cause of GN in India	Most common cause of rapidly progressive GN
↓	↓	↓
IgA Nephropathy	Post infective GN (PSGN)	Crescentic (GN or RPGN)

Causes of Nephrotic syndrome

- Child → Minimal Change Disease
- Adults → FSGS
- Elderly → Membranous Nephropathy

Note: Membrano – Proliferative Glomerulo Nephritis (MPGN) can present as either Nephritic or Nephrotic syndrome

- Smoky urine in Glomerulonphritis due to Hematuria

Fig: 1

- Frothy urine due to proteinuria seen in nephrotic syndrome

Fig: 2

TUTORIALS
LOGIN FOR SUCCESS

AfraTafreeh.com

- Dysmorphic RBC in Glomerulonephritis red cell casts
  → Fusion of dysmorphic RBC's
- Lipid cast → Nephrotic syndrome
- Remember: RBC cast → Nephritic syndrome

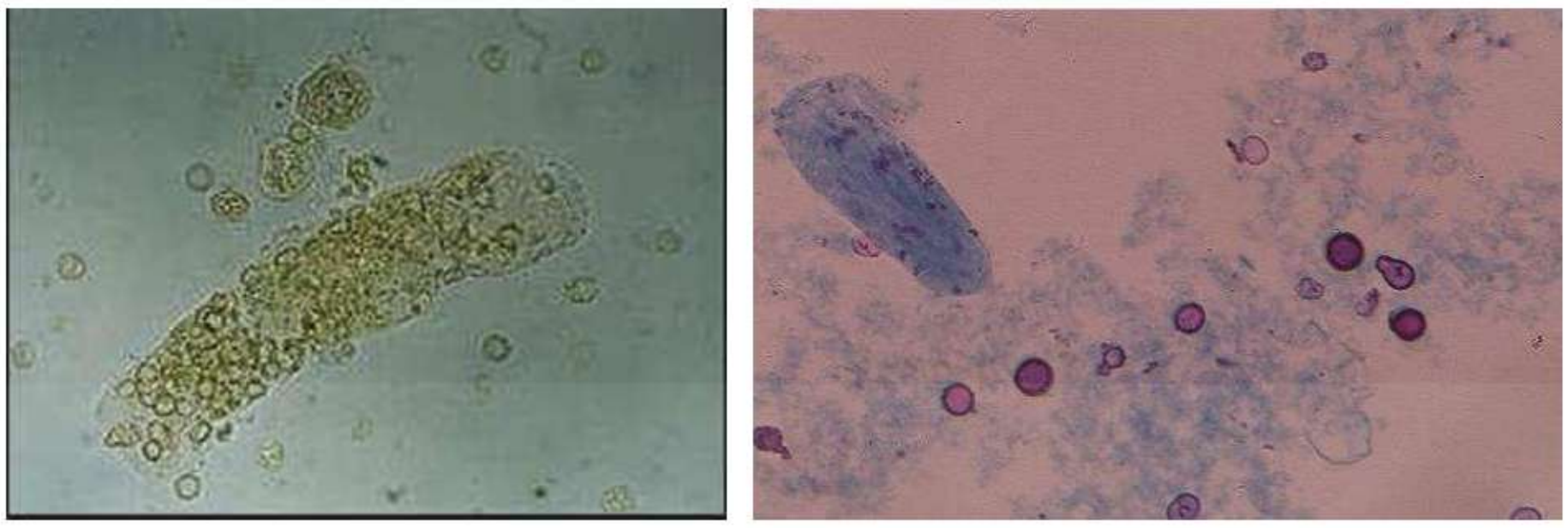

Fig: 3

TUTORIALS
LOGIN FOR SUCCESS

IGA NEPHROPATHY

- Most common cause of GN in the World.
- Now Classified under Isolated glomerular disease.
- Immune complex mediated.

Pathogenesis 00:00:05

- Normally polymeric form of IgA Ab is quickly cleared by the liver
- In patients of IgA Nephropathy, due to some infection URTI, polymeric form of IgA increases and becomes abnormally Glycosylated
- This Ab is now called polymeric IgA, antibody our body treats this Ab and forms IgG antibodies against polymeric glycosylated IgA1

IgG Ab + IgA1 = Immune complex

↓

Deposits in mesangial matrix

↑

IgG Ab → C3 complement

So there is deposition of [IgG, IgA1, C3] in mesangium

AfraTafreeh.com

AfraTafreeh.com

On L/m:

- Mesangial cells->Modified macrophages of kidney

Macrophages eating the IC

↓ Fig 1

Unable to phagocytose, they proliferate

Therefore, IgA Nephropathy is also called as Mesangio- proliferative Glomerulonephritis

On L/m:

- Immune complexes in mesangial matrix.

On L/m:

- Granular immunofluorescence located in Mesangium.

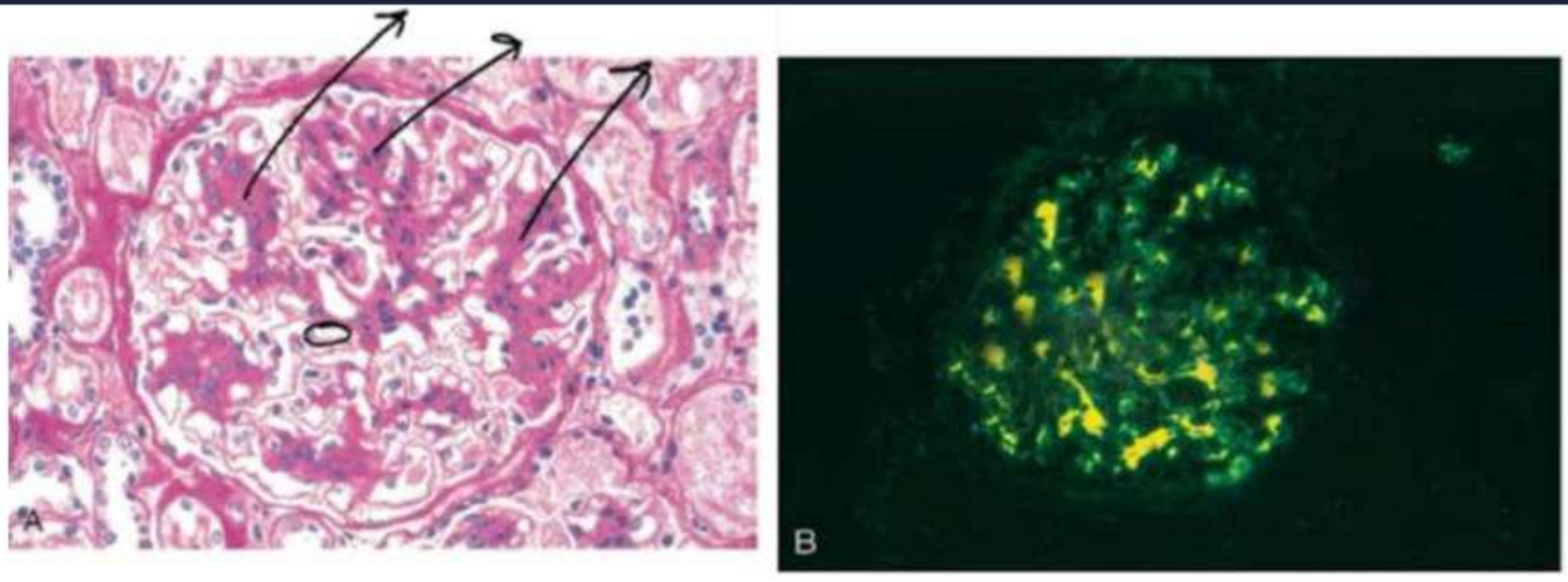

L/M I/F Fig 2

Cause of IgA Nephropathy

1°
- MHC II Polymorphism
- idiopathic

2°
- celiac disease
- Henoch schonlein purpura
- liver disease
- colonic diseases, GI disease

(Diseases with Raised levels of Ig A in blood)

Unique features of IgA Nephropathy

- Antibodies formed against self IgA.
- This disease recurse after Transplantation.
- Typical clinical features of Nephritic syndrome not seen.
- They usually present with Gross hematuria after 1-2 days of infection.
- Type III HSR
- Typically affects young adults.
- Sometimes can even be associated with Nephritic syndrome
- Now put under category of Isolated Glomerular diseases.

AfraTafreeh.com

POST STREPTOCOCCAL GLOMERULONEPHRITIS

- Also known as post Infective Glomerulonephritis (PIGN)
- Most common cause of GN in India
- Child 6-10 Years
- Immune complex mediated
- Antigen-Group A β hemolytic streptococci

  ↓
- SPE-B->Streptococcal pyrogenic exotoxin B produced by strains 12/4/1 of streptococci also called as Nephritogenic strain

Pathogenesis

Ab – and Ag streptococcal pyrogenic exotoxin B

↓

Immune complex deposition

↓

1st – subendothelial deposit in blood vessels

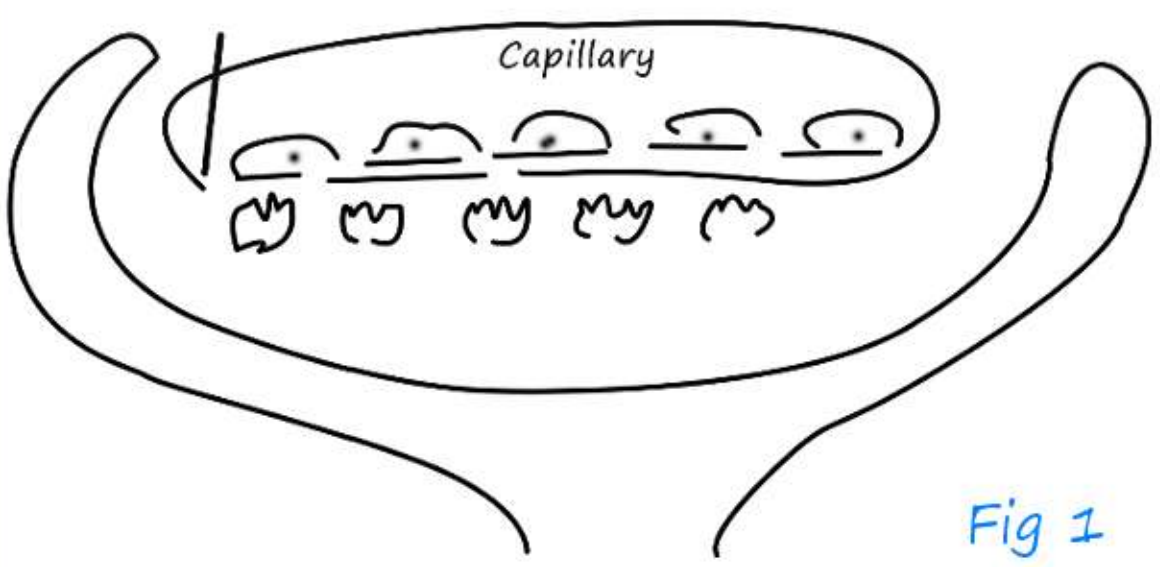

Fig 1

- Sub-endothelial deposits
- Capillary lumen full of Neutrophils

  ↓
- Endocapillary proliferation

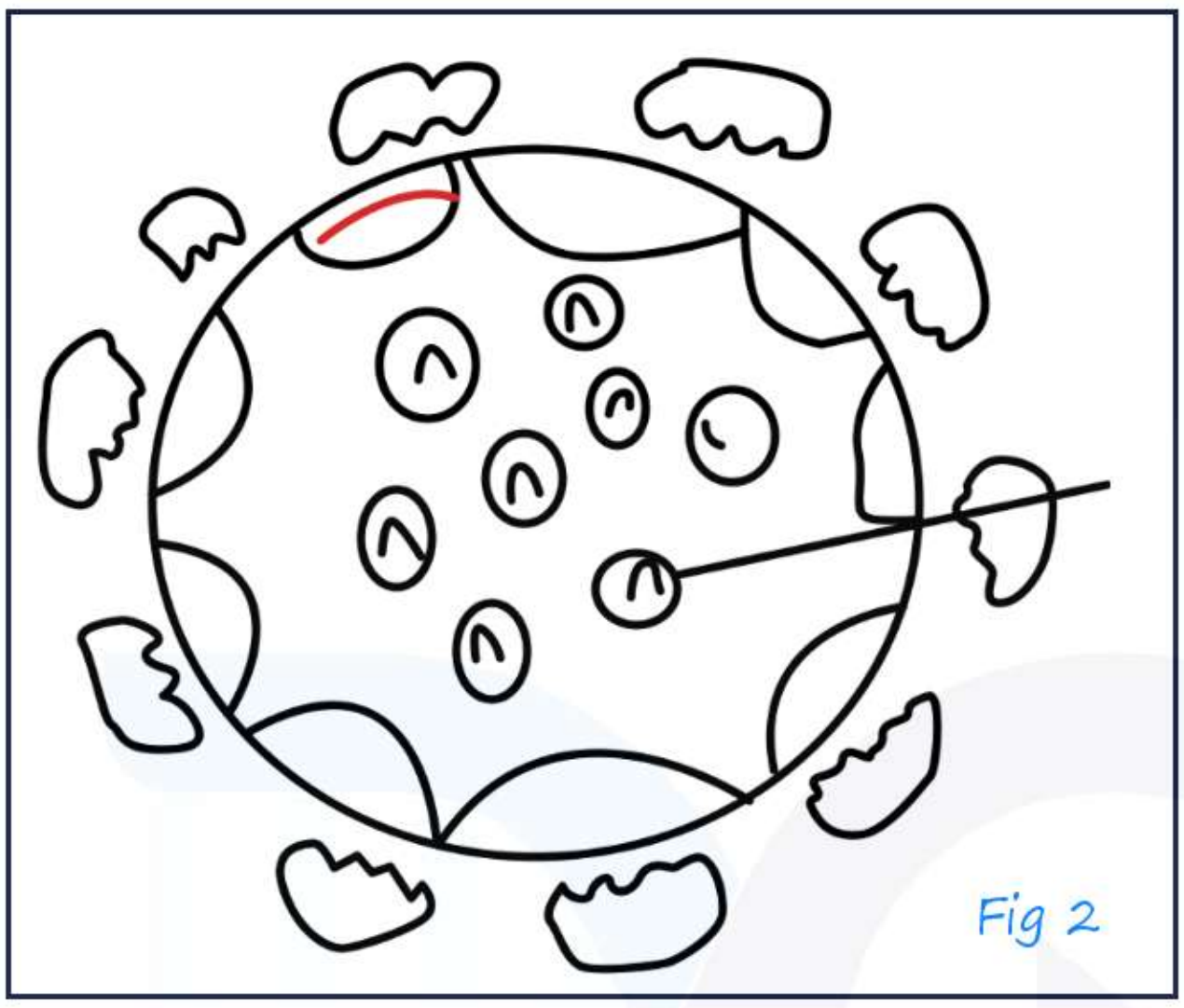

Fig 2

- Mesangial cells being the macrophages of kidney, also proliferate-> Mesangial Proliferation
- Later on in the disease. Immune complex deposits on subepithelial space

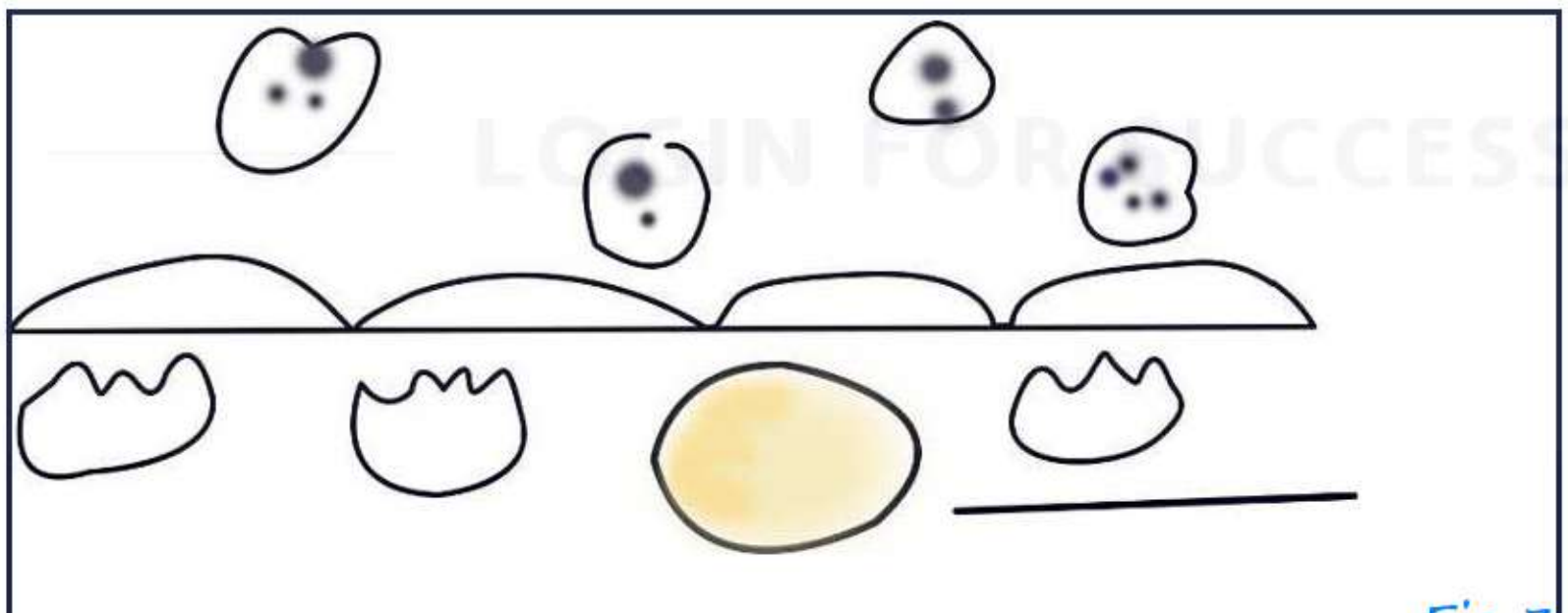

Sub epithelial deposits as HUMPS

Fig 3

On L/M: - Hypercellular Glomeruli:

a)Endocapillary proliferation

b)Mesangial proliferaction

AfraTafreeh.com

PSGN is also called Acute Proliferative Glomerulonephritis ✓✓

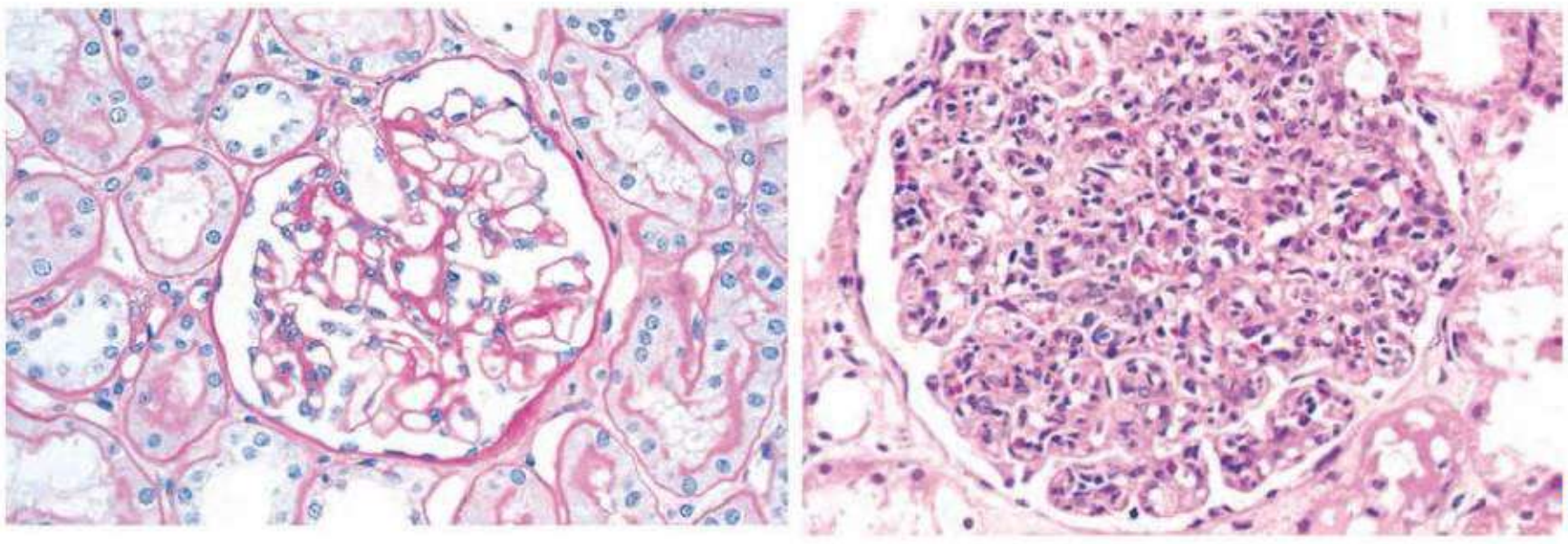

Fig 4

On E/M: -

- Initial part of disease → sub endothelial deposits
- Later part of disease → Sub epithelial

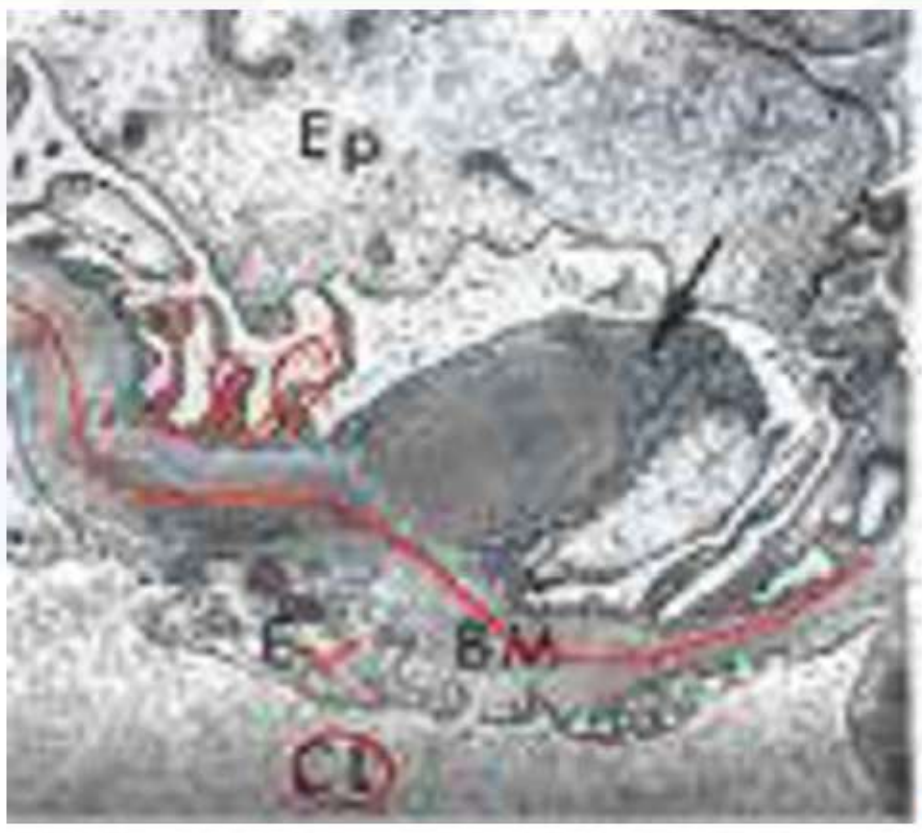

Fig 5

On I/F:

I. Granular IF

- Normally Ag-Ab → C1 → C2 → C4 → C3 → Classical complement pathway
- But in PSGN C4 is not activated
- So, levels of complements C1, C2, C3 fall in blood while stays normal

- This hypocomplementemia is very transient and resolves within 6 weeks

II. Starry-Sky immune fluorescence & Mesangial-Garland pattern

- granular IF

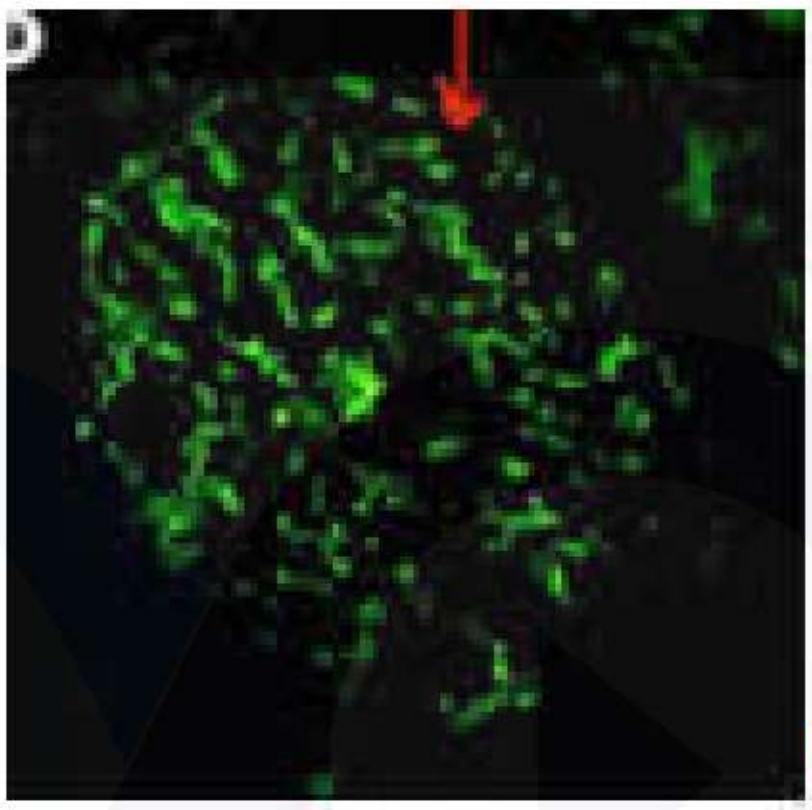

Fig 6

- mesangial Garland pattern

Afroafreeh.com

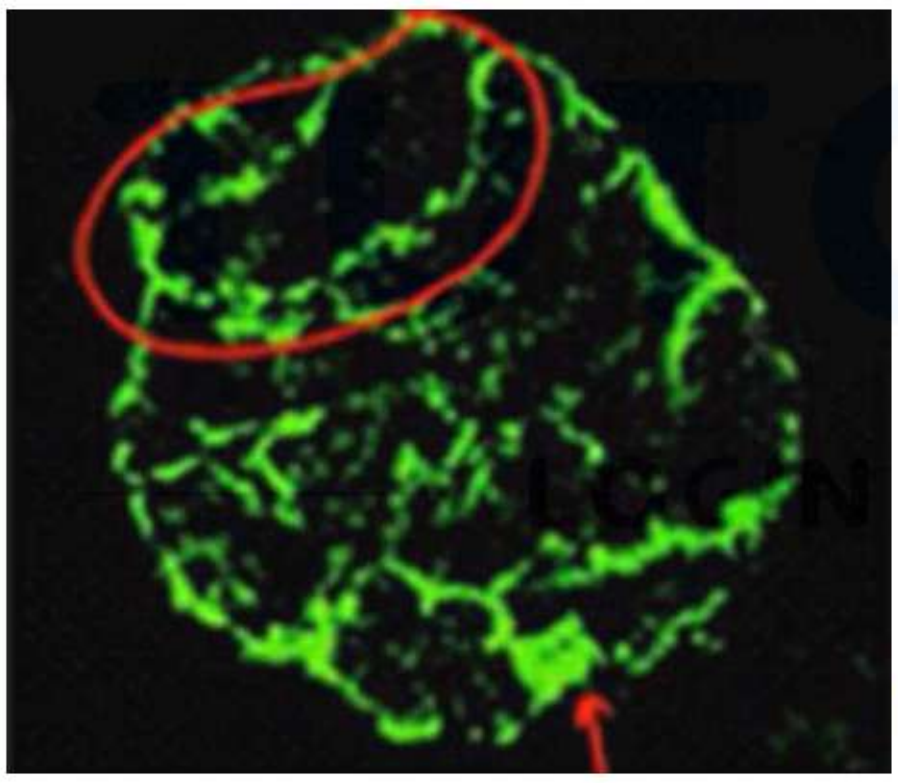

Fig 7

- starry sky IF

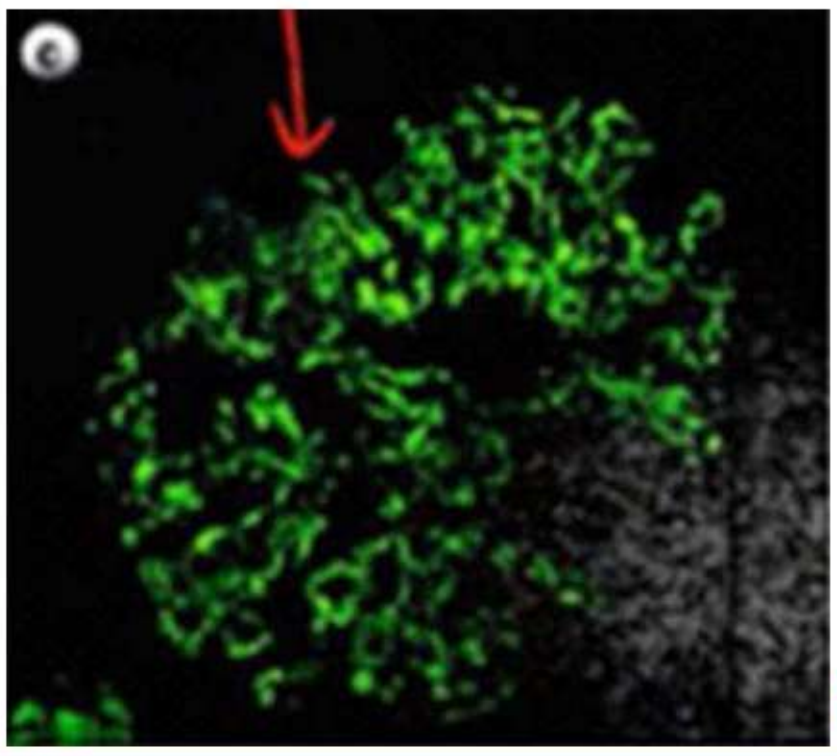

Fig 8

AfraTafreeh.com

- In PIGN by Staphylococcus ->Ig A deposition is more while in PIGN by Streptococcus->Ig G deposition is more
- **Prognosis**->Acute PSGN has good prognosis and usually resolves within 6 weeks
- But if there is breach in Basement membrane, PSGN can progress to RPGN.

RAPIDLY PROGRESSIVE GLOMERULONEPHRITIS

Rapidly progressive glomerulonephritis

Hallmark of RPGN: Basement Membrane damage

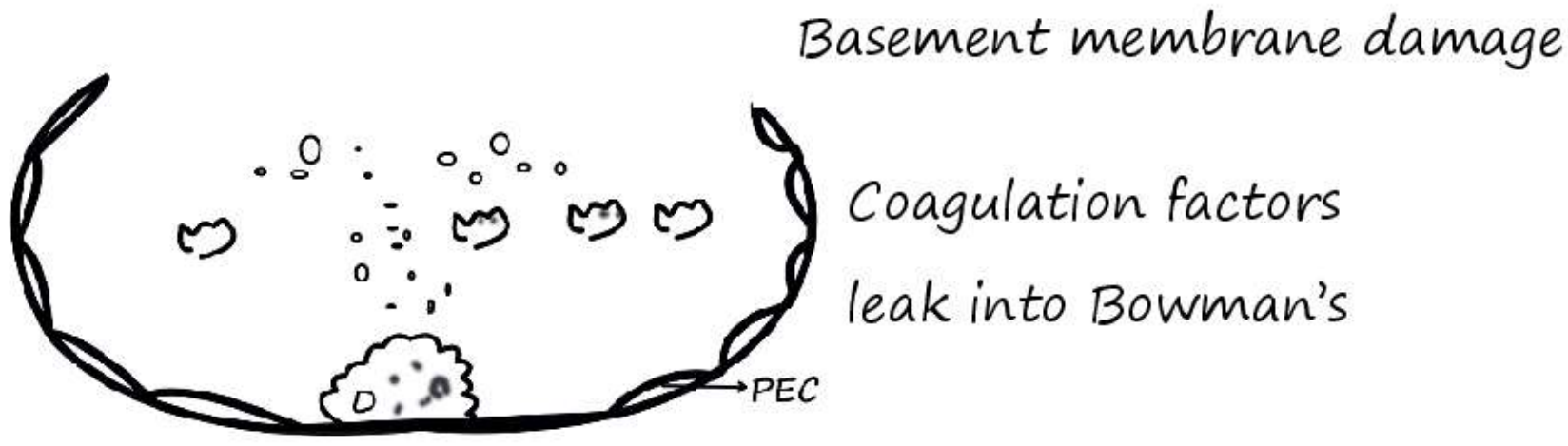

Proliferation of PEC (parietal epithelial cells)

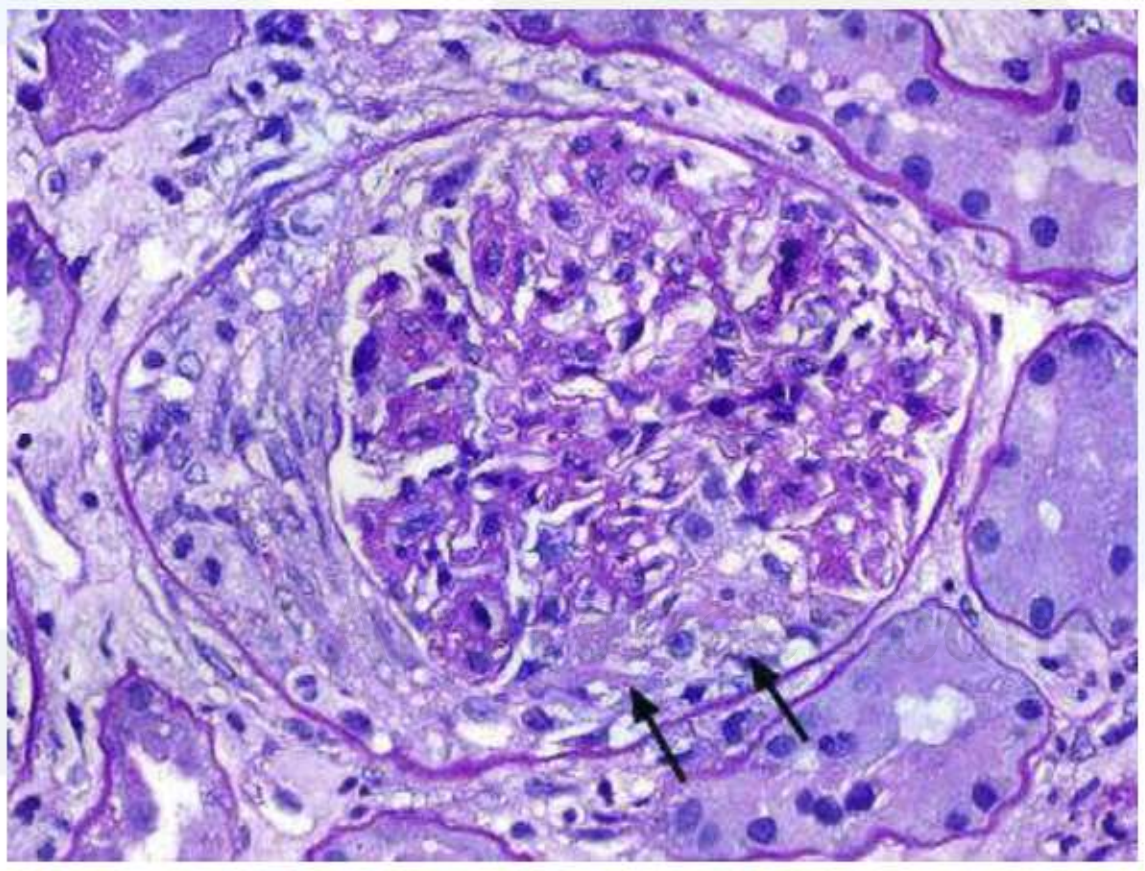

Fig: 1

- Accumulation of Fibrin + Inflammatory cells + prolifered PEC together form **Crescents**
- Most important component → Fibrin
- Crescents can obliterate Bowman's space and entrap VEC
- Quickly progresses to Renal failure.
- This disease is called Rapidly progressive Glomerulonephritis
- Crescent are most characteristic histologic finding of RPGN

TUTORIALS
LOGIN FOR SUCCESS

AfraTafreeh.com

- Number of crescents corresponds to the prognosis of the Disease. They can be identified by Antibody Fibrinogen Immunofluorescence

Causes of BM damage

I. Anti GBM disease
- α3 Nc -col4 (Antigen)
- antibodies formed against this compared of B.M

Immune Complex Mediated

example: PSGN IgA nephropathy Henoch scholiein purpura, SLE

Pauci Immune

ANCA(anti neutrophilic cytoplasmic Ab) mediated

II.good pasture syndrome ↓ RPGN Type I ↓ Treatment: removal of Ab by plasmaphoresis

purpura, SLE ↓ Type II RPGN

most common type ↓ Type III RPGN

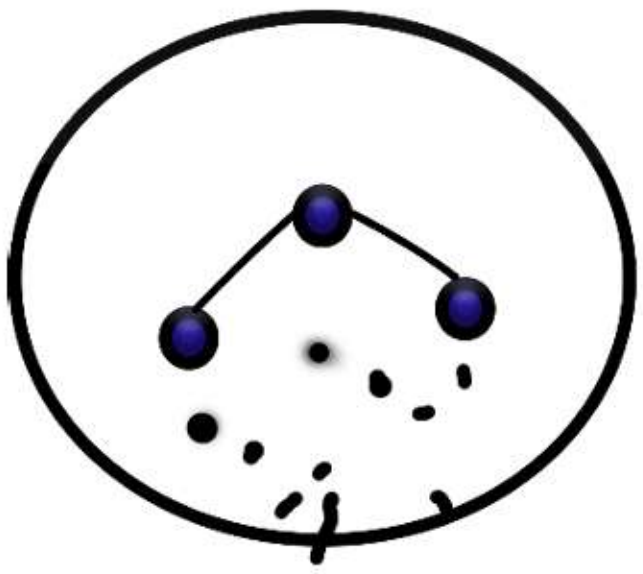

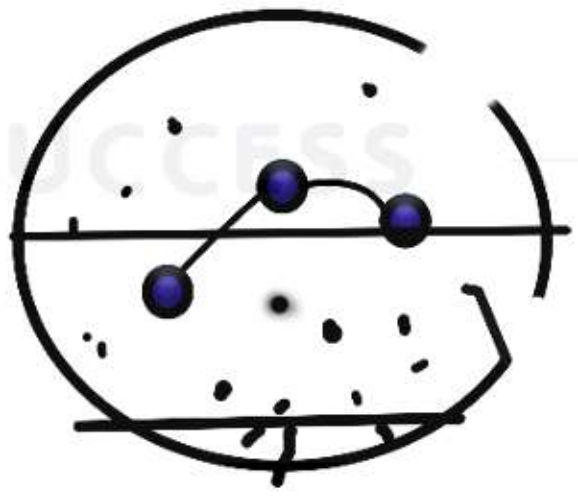

proteinase 3

Ab against proteinase 3

↓

C-ANCA on IFt

(MPO) Myeloperoxidase

Ab against MPO

↓

P-ANCA On IF

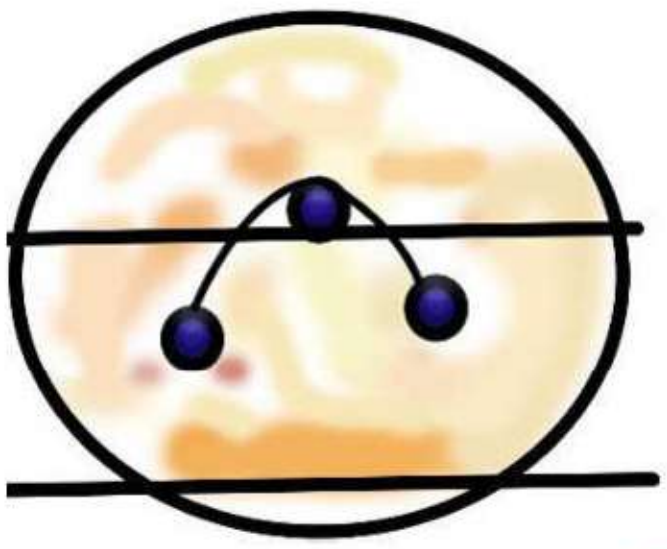

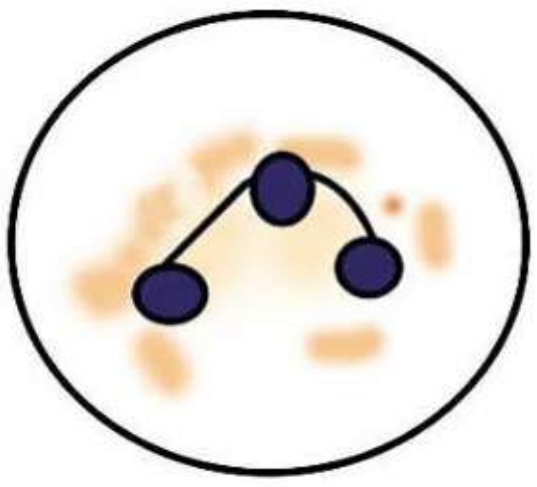

cytoplasmic IF C-ANCA

Perinuclear IF P- ANCA

PANCA postitive in
- Microsopic polyangitis
- chrug strauss syndrome

CANCA Positive in
- Wegeners Granulomatosis now named (Polyangitis and Granulomatosis)

I	II	III
L/M: - ←	Crescents (morphologic Hallmark of RPGN)	→
E/M: - ←	i. basement membrane breaks hallmark of RPGN)	→
	ii. wrinkling of B.M	→

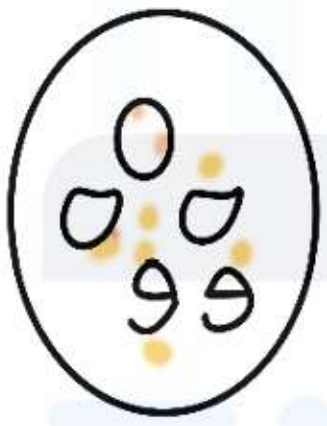

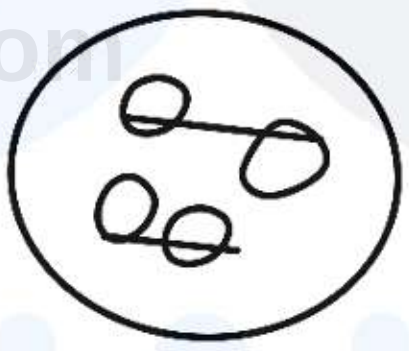

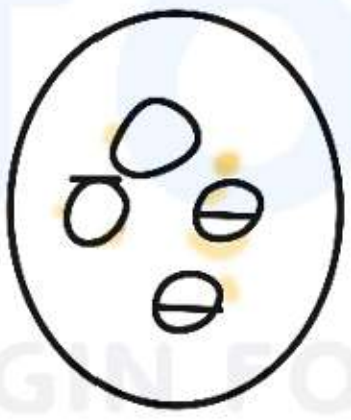

I/F: Linear IF

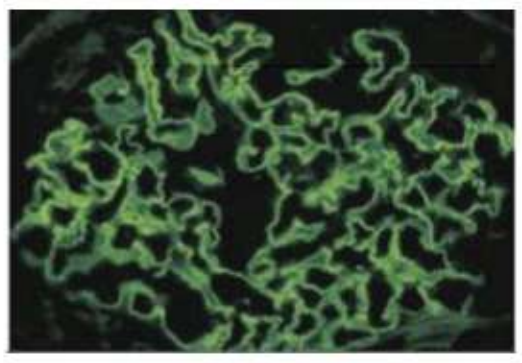

Granular IF

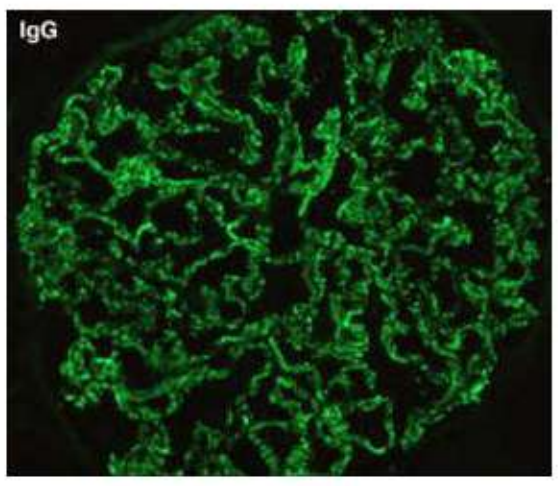

No Deposits
indirect IF of blood shows

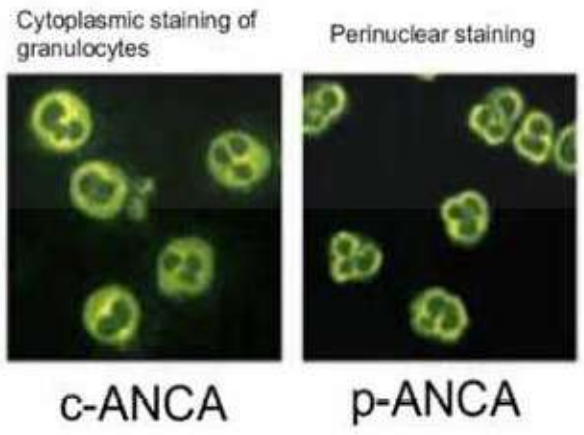

AfraTafreeh.com
TUTORIALS
LOGIN FOR SUCCESS

- E/M Image
  - Showing break and wrinkling of B.M

AfraTafreeh.com

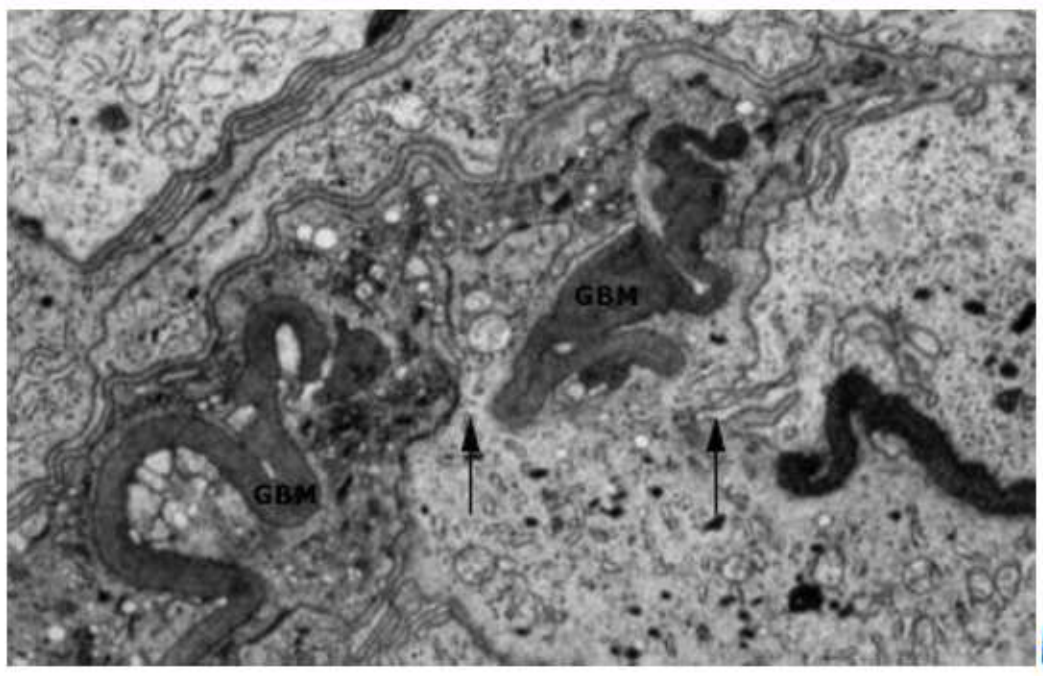

Fig: 2

- Flea bitten kidney → small pinpoint petechial hemorrhage

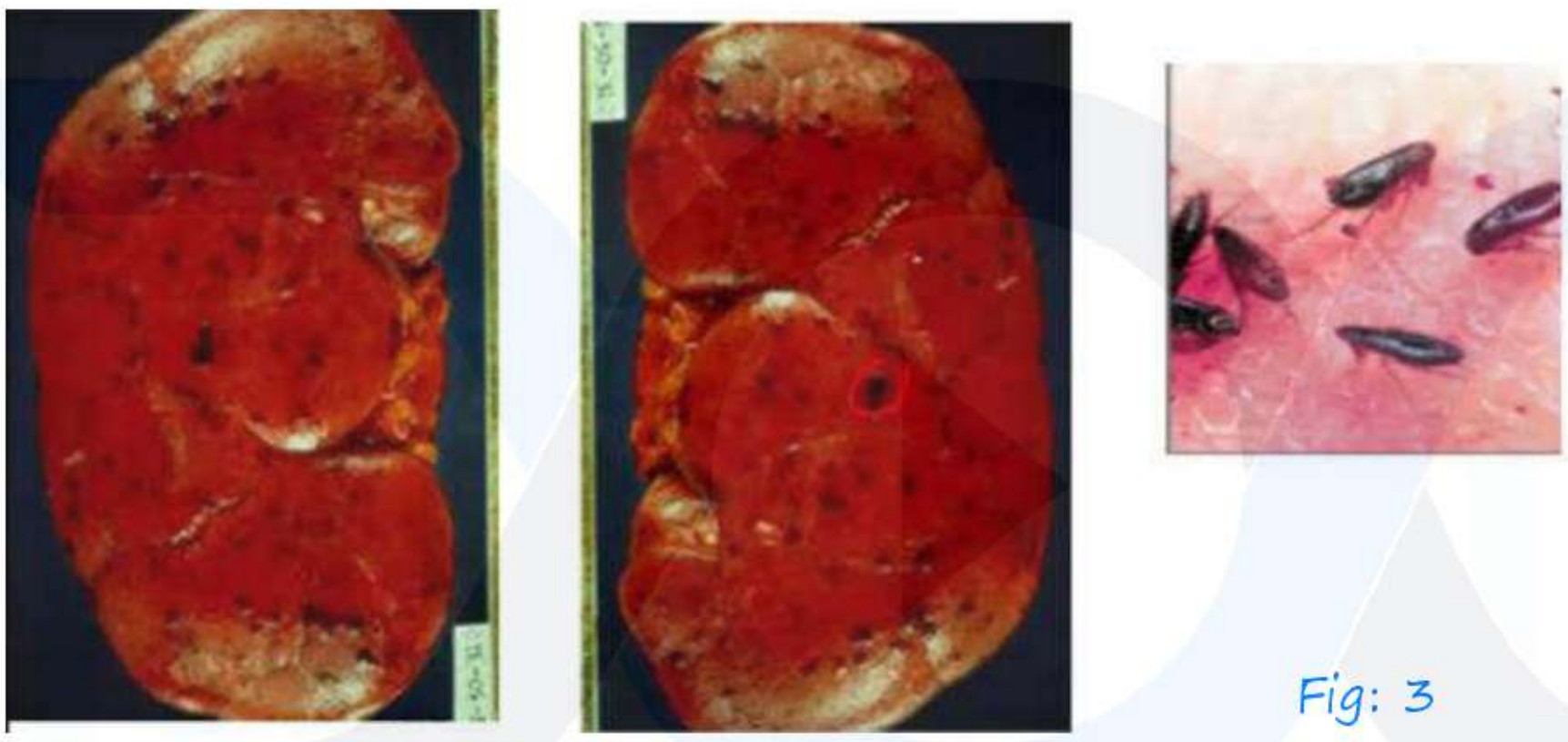

Fig: 3

Differential diagnosis:

I. Malignant hypertension
II. RPGN
III. Infective endocarditis

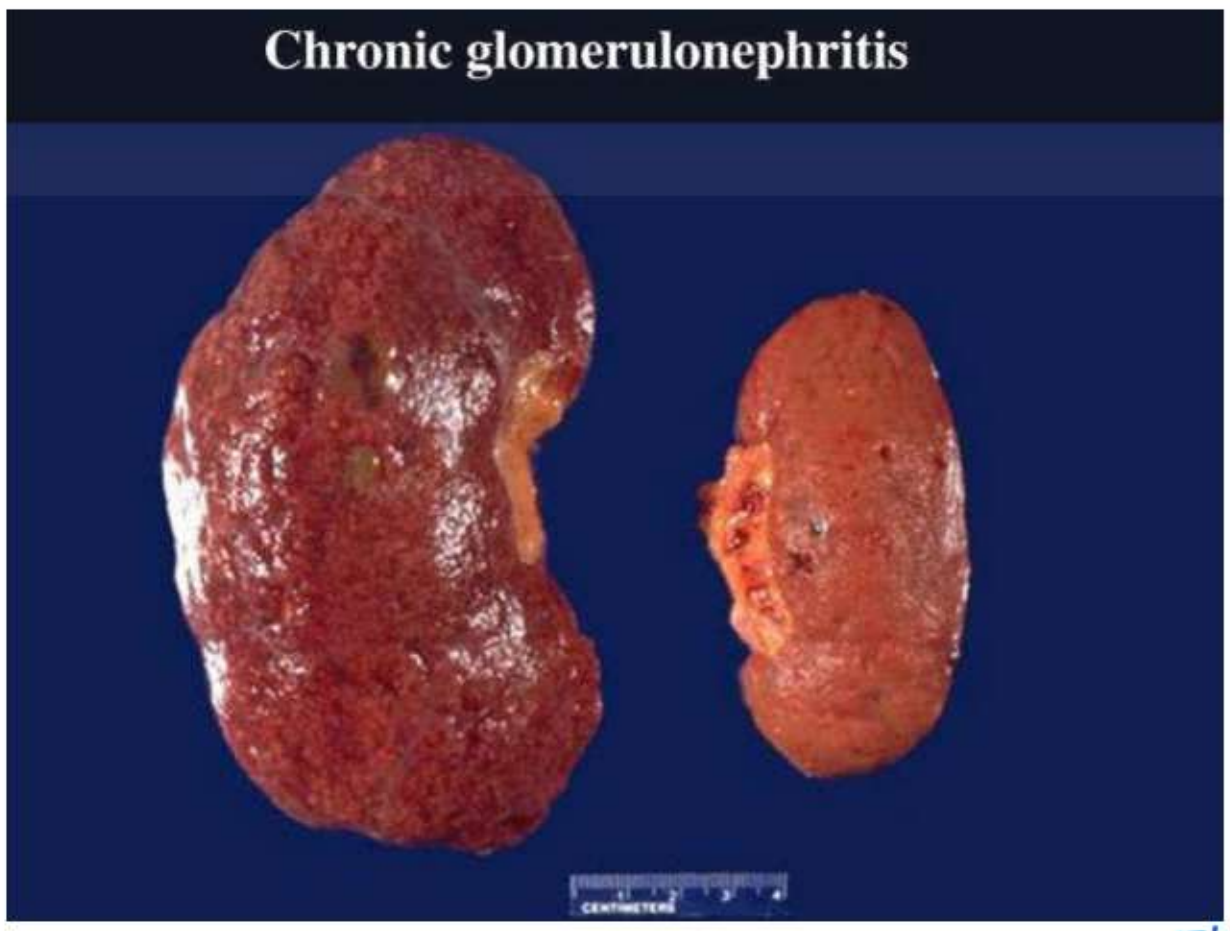

Fig: 4

Chronic Glomerulo Nephritis

- Masson Trichrome showing sclerosed Glomeruli.
- Gross: symmetrically decreased like of kidney with Granular appearance

- (Growth factor & cytokines released from crescents can cause complete fibrosis of kidney causing chronic Glomerulonephritis)

AfraTafreeh.com
TUTORIALS
LOGIN FOR SUCCESS

AfraTafreeh.com

MEMBRANO PROLIFERATIVE GLOMERULO NEPHRITIS

- Immune complex mediated disease
- Antigen-PLA2R (Phospholipid A2 Receptor)
- Occurs in people with HLA DQ, polymorphism
- Pathogenesis- Ab against PLA2 R

  Ab-Ag complex deposit in sub epithelium

Type 1 – IC: C1,C2,C3,C4

Hypocomplimentemia is seen

Type 2- C3 decreased

Persistent hypocomplementemia

MPGN Type 1 -Classical MPGN

- IC mediated But Antigen unknown
- Ag-Ab complex deposits in sub-endothelium

On L/M:

1) Thickened B.M
2) Lobular accentuation of Glomeruli

} Mesangio-proliferative GN
↓
(Also known as Mesangio-capillary GN]

3) Silver stain of BM shows Duplication of Basement membrane or Tram Track appearance

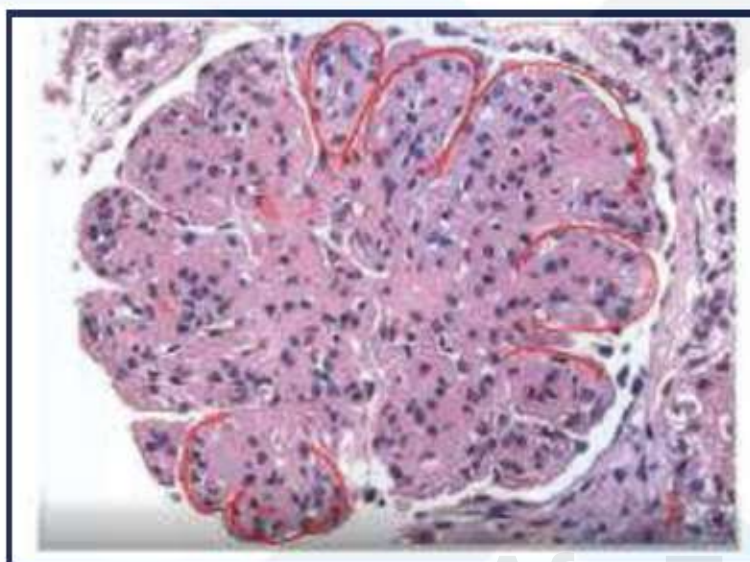

Fig 1

AfraTafreen.com

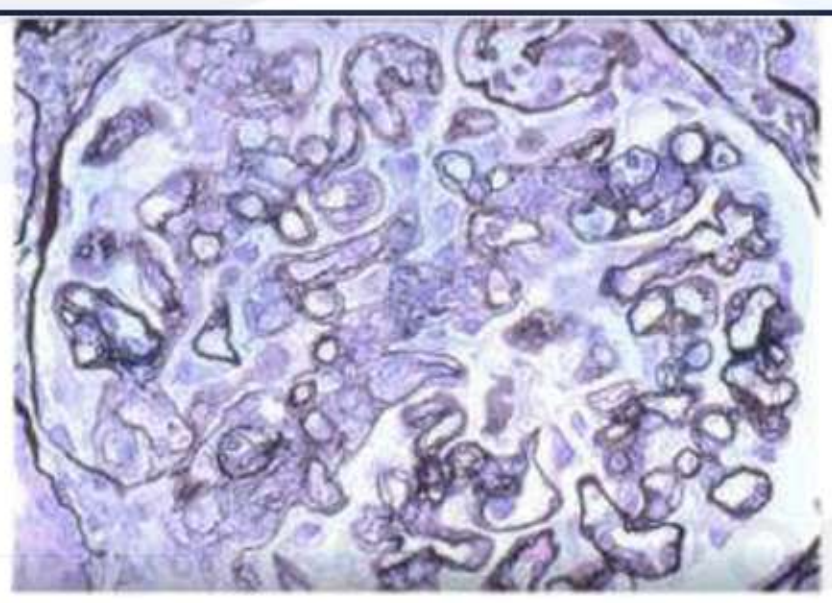
Silver stain showing tram – track appearance Fig 2

On E/M:

- Sub-endothelial deposits

On I/F:

1) Granular IF
2) IgG, C1, C2, C3, C4 deposited

AfraTafreeh.com

Subendothelial deposits

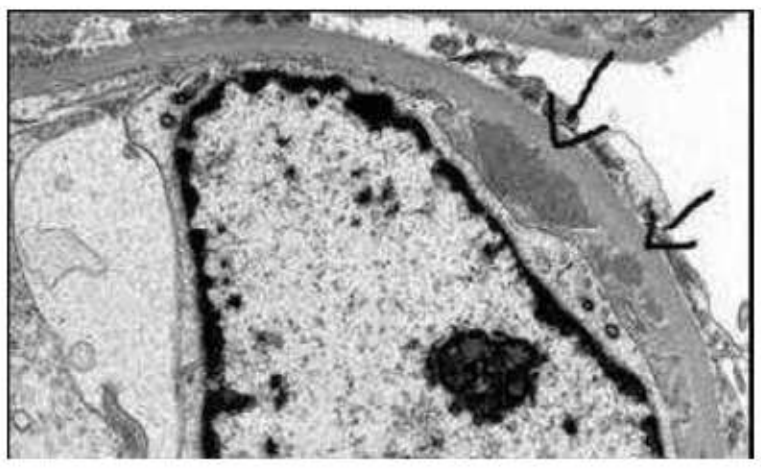
Fig 3

Causes of MPGN

1°	2°
Idiopathic	• Infections-HCV cryoglobulinemia, HBV, Leprosy, Schistosomia • Drugs • Infective endocarditis, Ventricular Shunts • CLL • α Antitrypsin deficiency,

TYPE II MPGN Now called as C3 Glomerulo Nephritis

- Dense deposit disease
- In the Blood these patients there is a unique factor called C3 NeF (C3 Nephritic Factor)

C3

↓ (Activation of C3)

C3a

C3b

- C3 Convertase

  ⊖ ↑

- Factor H&I breck dean C3 Convertase after activation of C3
  C3 NeF stabilizes C3 Convertase So there will be constant breakdown of C3 -> Hypocomplementemia of C3. Also called Complementopathy
- Lamina dense of B. M is completely replaced by dense ribbon like material whose composition is not known
- Usually occurs in Children and Young adults
- E/M Dense deposit in Lamina Dense.
- **EM:**

AfraTafreeh.com

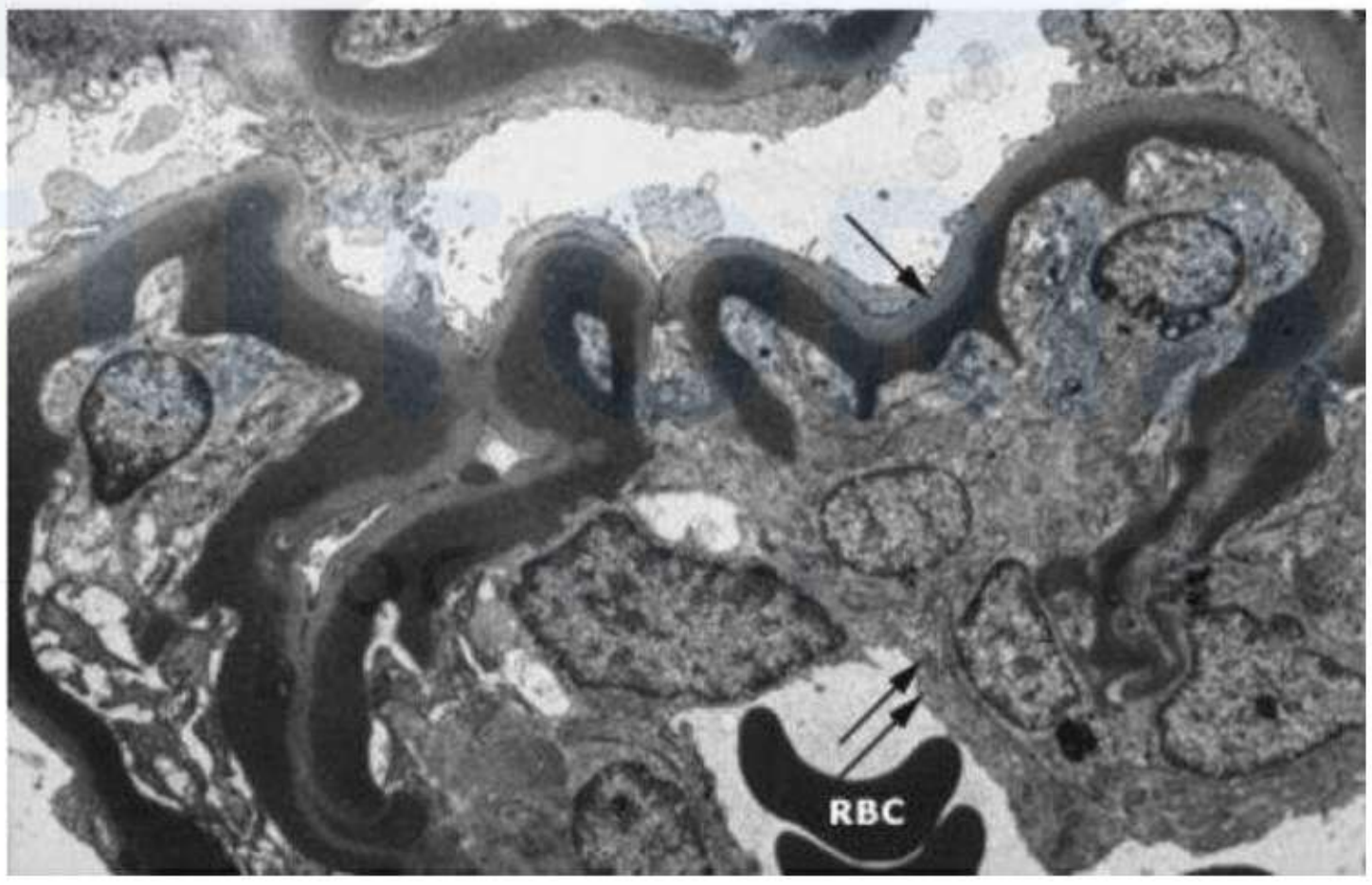

Fig 4

AfraTafreeh.com

DIABETIC KIDNEY

System diseases affecting kidney

- DM
- HTN
- SLE
- Amyloid kidney

Diabetic kidney

Involves Glomerulus, Tubules and Blood vessels

Glomerulus

Classical lesions	insudative lesions
↓ Earliest change B.M Thickening ↓ Formation of Well detailed Nodule called **Nodular Glomerular sclerosis** ↓ Nodules (Rich in Glycogen) ↓ Most specific Finding of Diabetic Kidney	↓ Capillary loops ↓ Fibrin attached to capillary called **Fibrin caps** ↓ Capsular Drop (Fibrin fallen into capsule) ↓ Both afferent and efferent arterioles show hyalinosis

Glycogen stained by

i. PAS (Most common used)

ii. Best carmine (Best stain)

When >50% of Glomeruli show nodules,

it's called **Diffuse Glomerulosclerosis**

kimmelstiel – Wilson lesion / nodular glomerular sclerosis

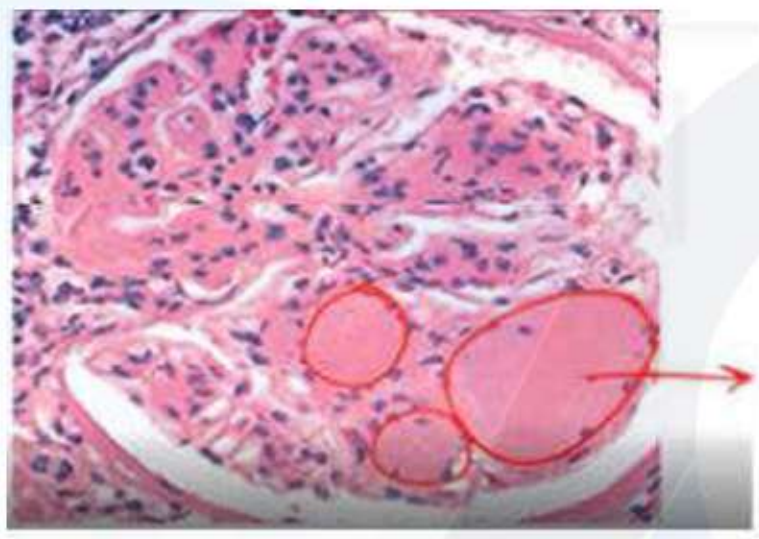

Fig 1

- Nodular Glomerulosclerosis or Kimmelstiel – wilson lesion

Insudative lesions

- Hyalinosis within bowman's capsule ("capsular drop" lesion)
- Hyalinosis in glomerular capillaries. Fibrin cap lesions
- Afferent and efferent arteriolar hyalinosis

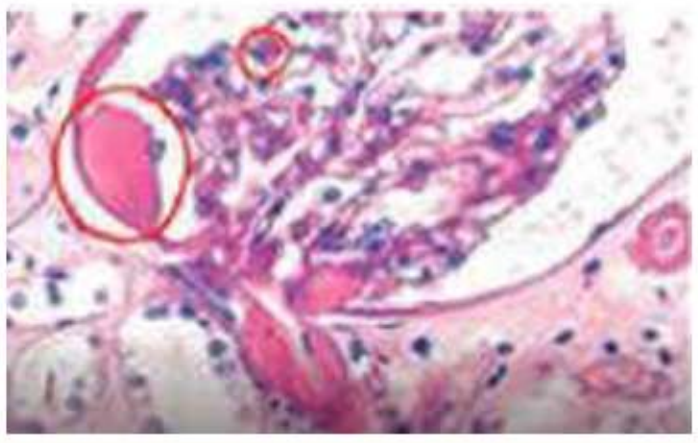

Fig 2

DM affecting vessels of kidney → vessels show hyaline arteriosclerosis

- Involvement of Tubules →

i. Pyelonephritis

ii. Papillary necrosis

Causes of papillary necrosis: (Pneumonic – DOSA)

- Diabetes M/C/Cause
- Obstruction
- Sickle cell anemia
- Analgesics – most specific Cause

iii. Glycogen looded in PCT cells Armani Ebstein cells are shed in urine

- Gross of Diabetes Kidney-Granular contracted Kidney (Symmetrical contraction)
- If Pyelonephritis entues Asymmetrical Contraction By the time a person develops Diabetic Kidney, he has already developed Diabetic Retinopathy

PAS stain ←

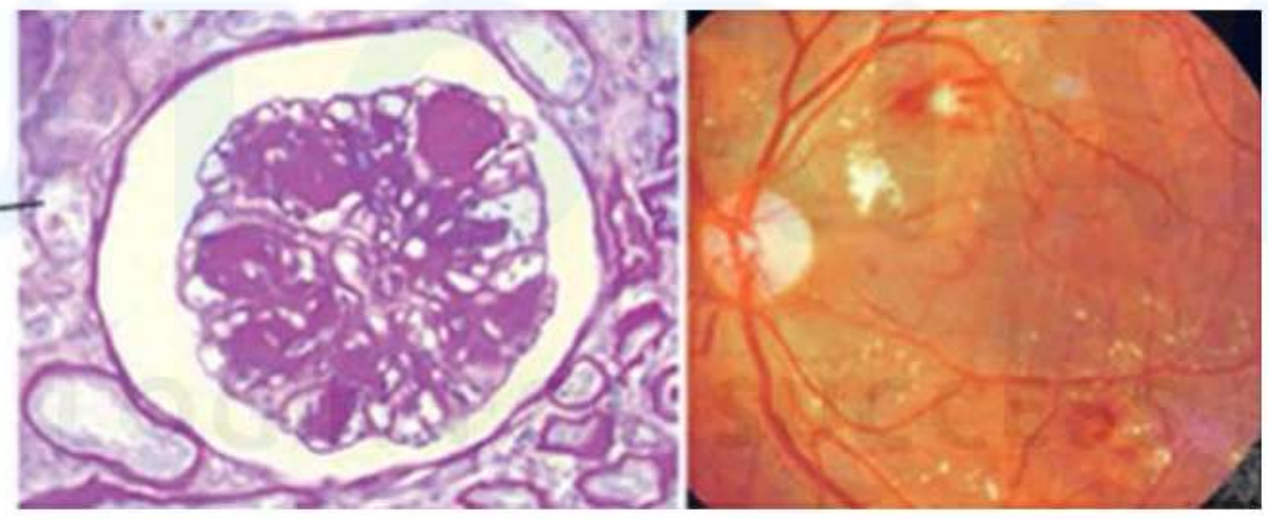

Fig 3

Causes of Basement Membrane Thickening

i. Membranous Nephropathy

ii. MPGN

iii. Diabetic Kidney

AMYLOID KIDNEY

I. Amyloid typically deposits around Glomerular capillaries causing thickening of arterial wall & narrowing of lumen

Amyloidosis of kidney

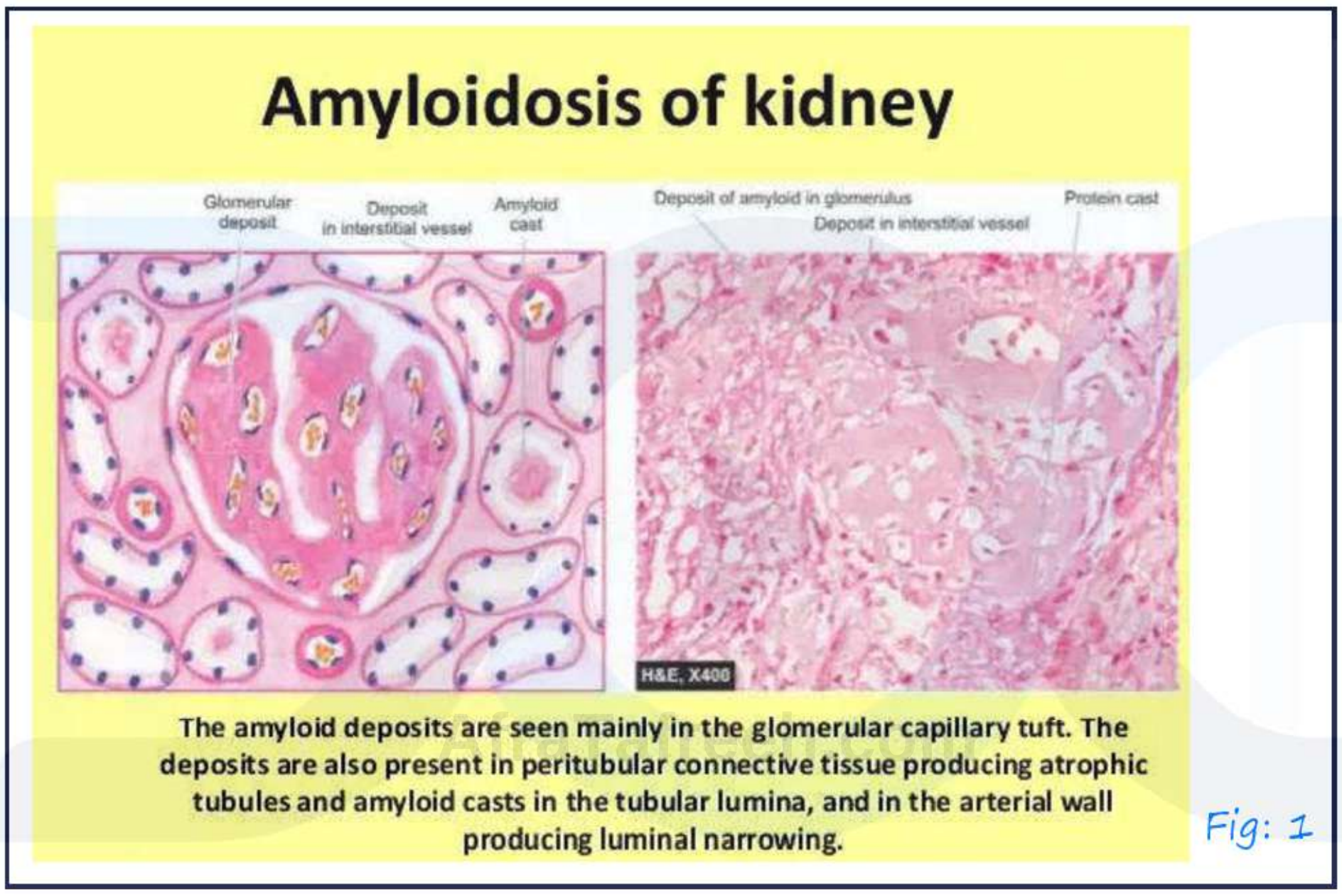

Fig: 1

II. Can produce atrophy of tubules amyloid depositing amyloid peritubular connective tissue

III. Amyloid casts seen in tubular lumen

IV. Special stain – congo red → salmon red appearance

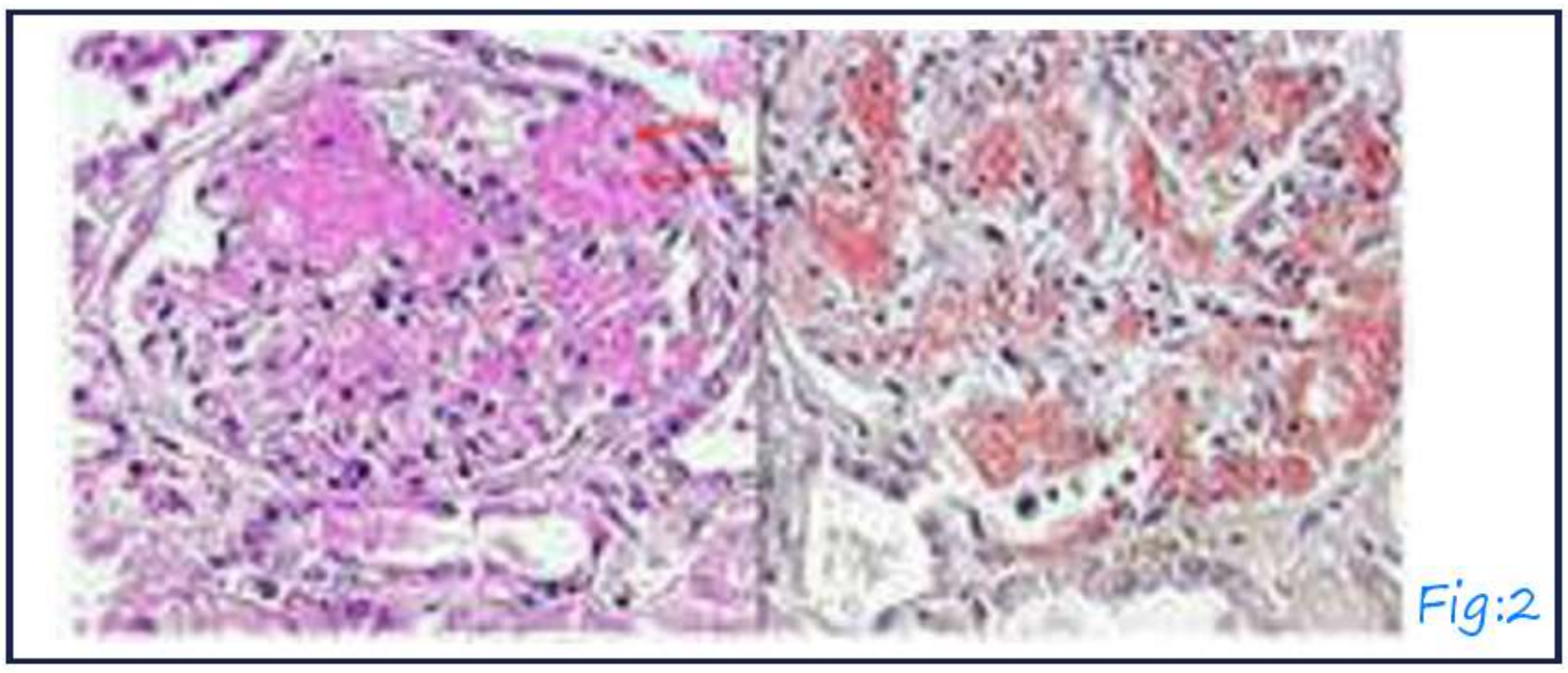

Fig:2

Amyloid deposits in glomeruli. Left section is stained with H and E a one with congo red stain

AfraTafreeh.com

↓ polarizing microscopy

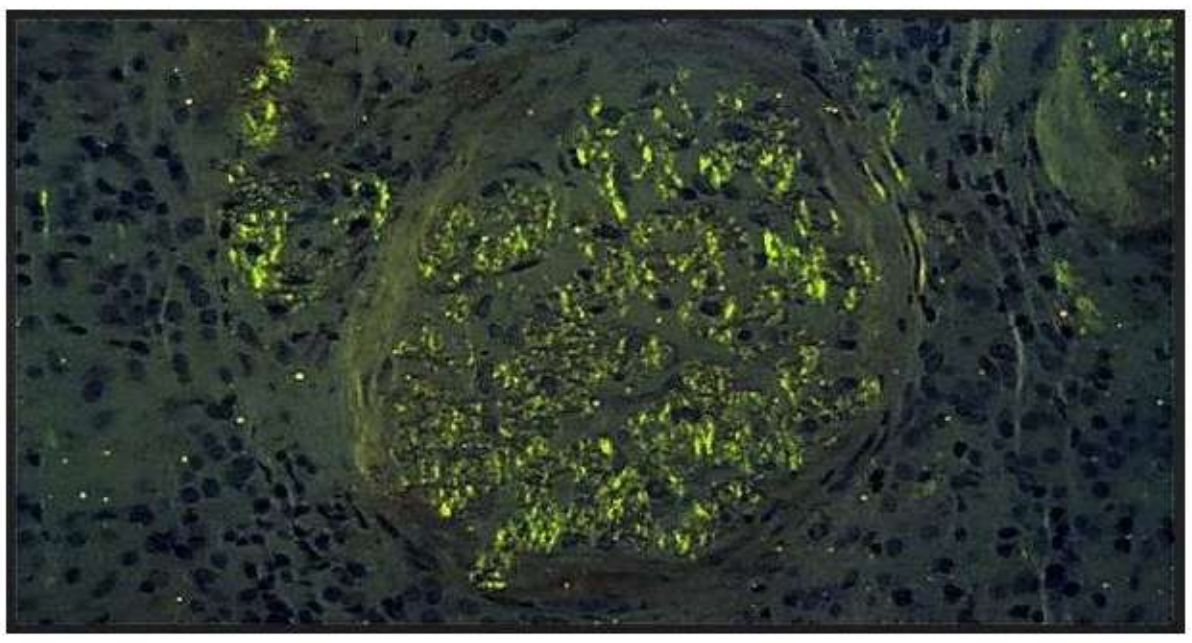

Apple Green Birefringence Fig: 3

V. Gross:

i. Kidney becomes smaller in size because of ischemia

ii. Waxy consistency

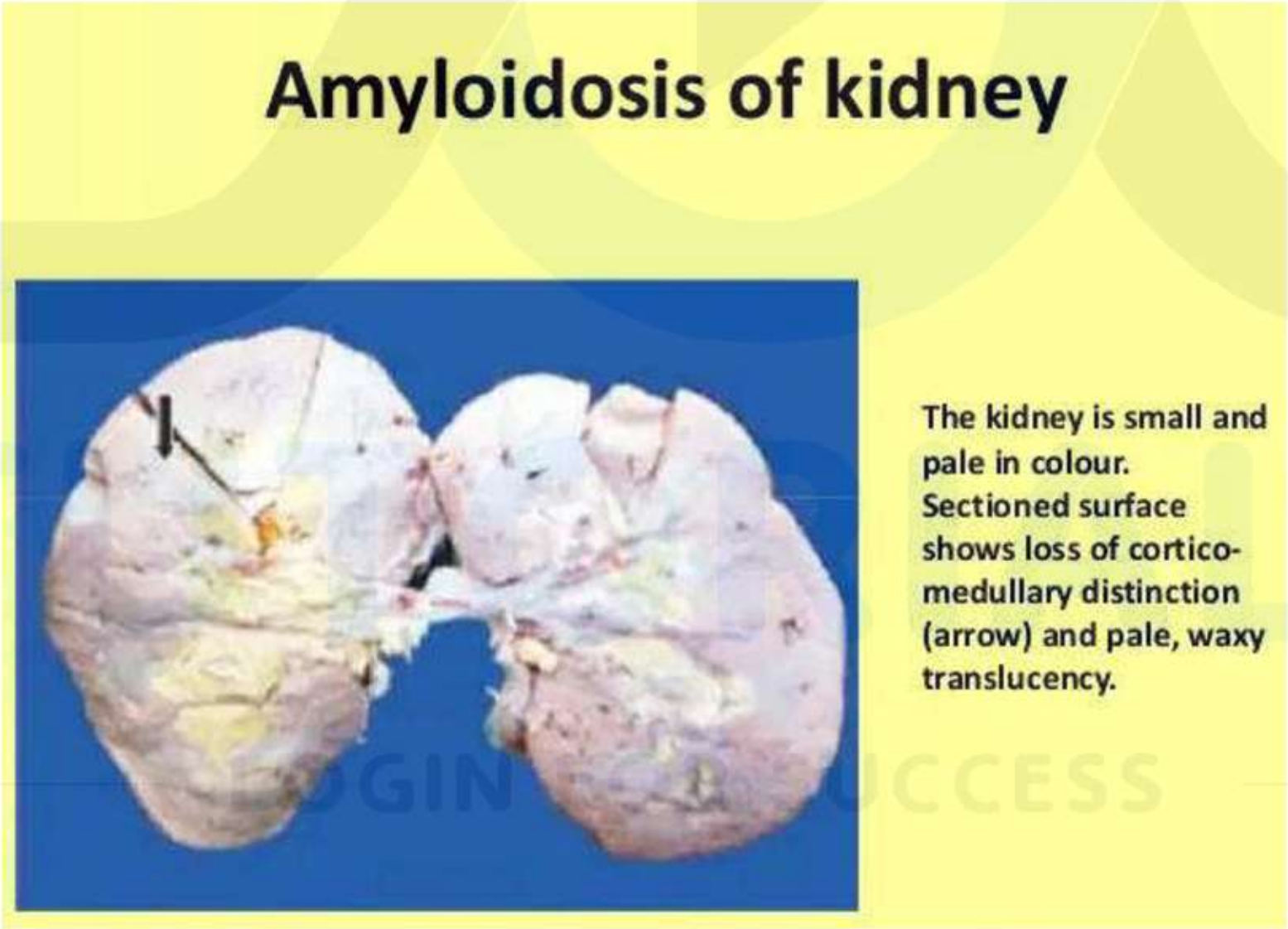

Fig: 4

SLE KIDNEY

SLE kidney

Lupus Nephritis

- Stage I
  - Minimal Mesangial lupus Nephritis
  - Deposition of IC in mesangium
- Stage II
  - Mesongio-proliferative lupus Nephritis
  - Proliferation of Mesangium due to IC deposition
- Stage III
  - Focal lupus Nephritis
  - IC in sub endothelium of < 50% of Glomeruli
- Stage IV
  - Diffuse lupus Nephritis
  - IC in sub endothelium of >50% of Glomeruli
  - Most common
  - Most severe
  - Mesangial proliferation causes splitting or Duplication of Basement membrane Forming wire loop lesions
- Stage V
  - Membranous lupus Nephritis
  - Subepithelial deposits
  - IC deposition in sub epithelial -Proliferation of Mesangium in Spike and Dome pattern similar
- Stage VI

AfraTafreeh.com
TUTORIALS
LOGIN FOR SUCCESS

AfraTafreeh.com

- Sclerosing lupus Nephiritis
- (Sclerosis of more 90% of the dlomeruli)

Characteristic Immunofluorescence finding

Full House effect:

i. All antibodies are positive IgG, IgA, IgM

ii. Complements-C3, Clq

iii. Fibrinogen

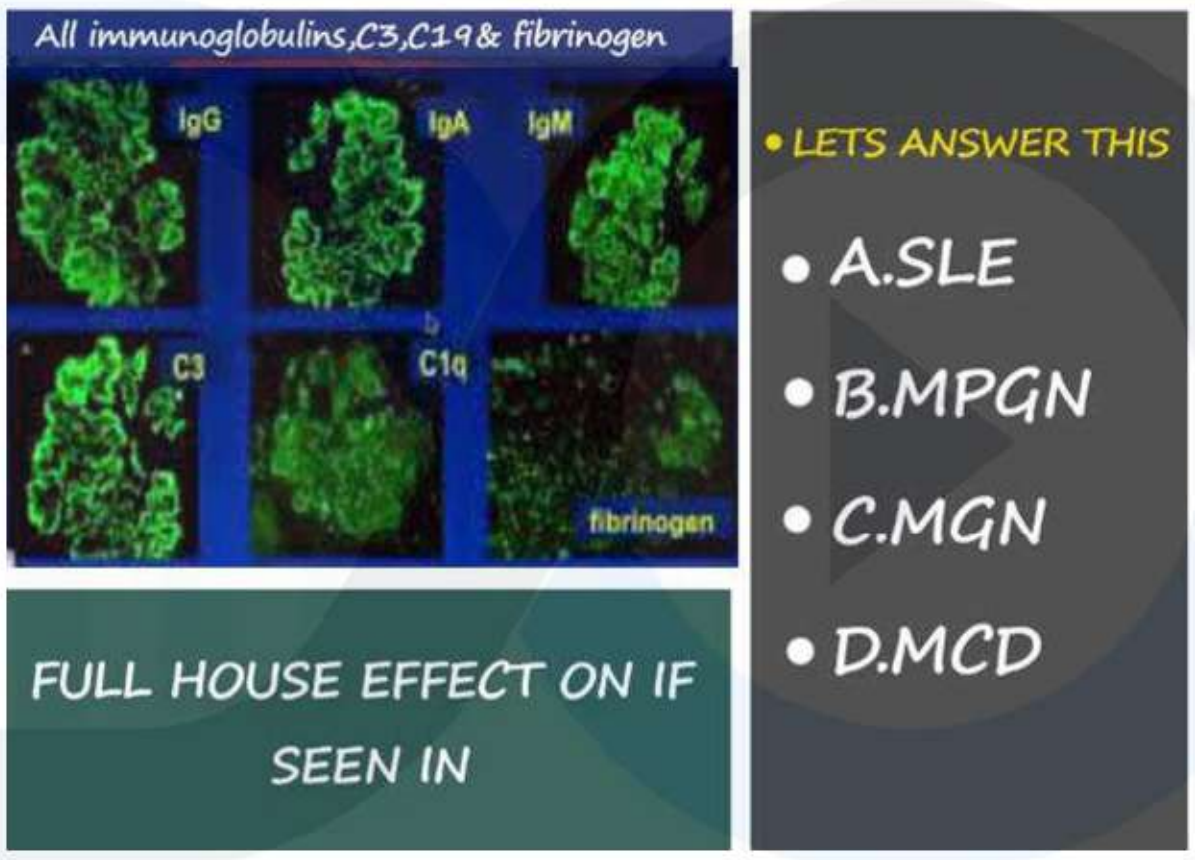

Fig 1

Wire Loop Lesions

- Seen in type III, IV & V
- M/C in type IV
- Indicate active disease
- Poor prognosis
- Seen in >50% of the Glomeruli.

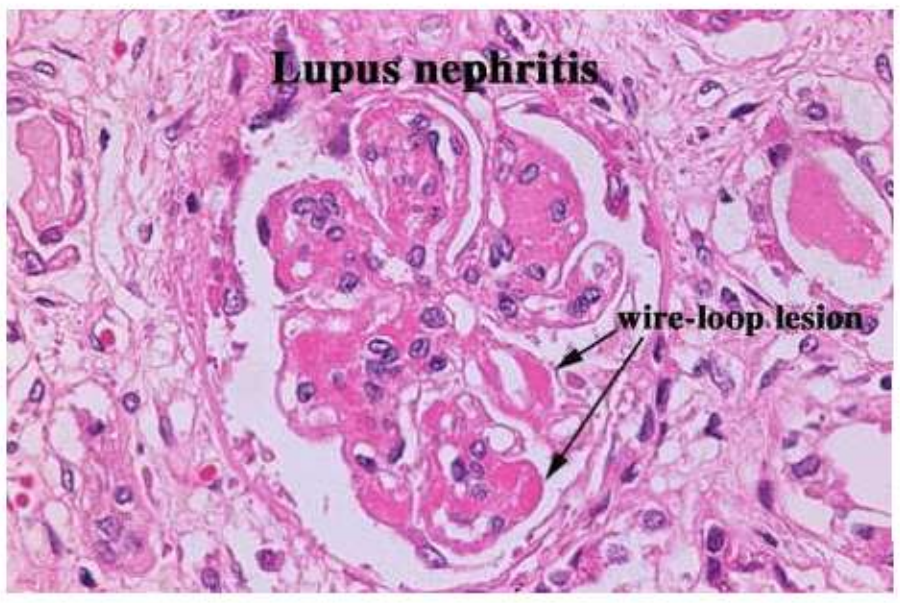

Fig 2

HYPERTENSION INVOLVING KIDNEY

Benign Nephrosclerosis	Malignant Nephrosclerosis
• Seen in Benign hypertension • Gross: B/L Symmetrical contraction (due to chronic ischemia) • Leather gain appearance or granular kidney **D/D of Granular kidney** • symmetric - Chronic Glomerulonephritis - Benign Nephrosclerosis • Asymmetric - Chronic pyelonephritis Thyroidisation of Tubules – seen in chr pyelonephritis 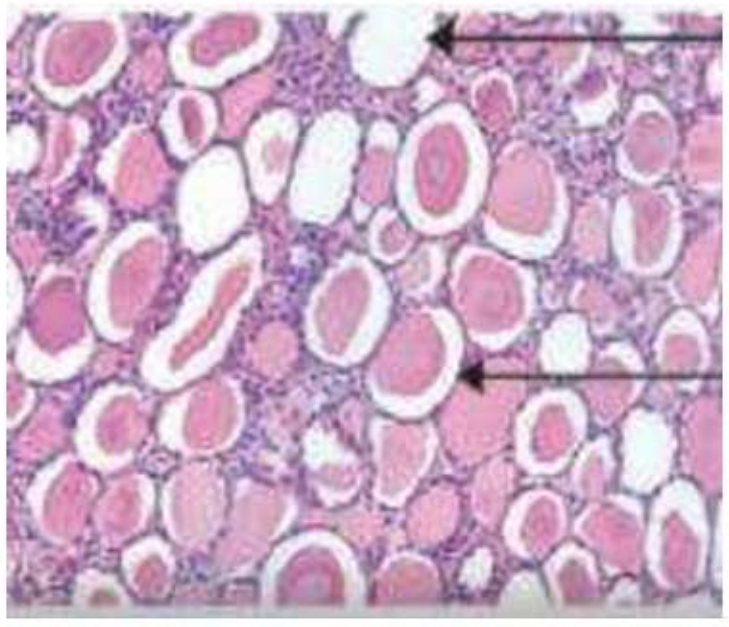	• Seen in malignant HTN • Gross: Size of kidney variable • Petechial pin – point hemorrhages ↓ Flea bitten appearance **D/D of Flea-bitten kidney** i. Malignant HTN ii. Infective endocarditis iii. RPGN - Microscopy: 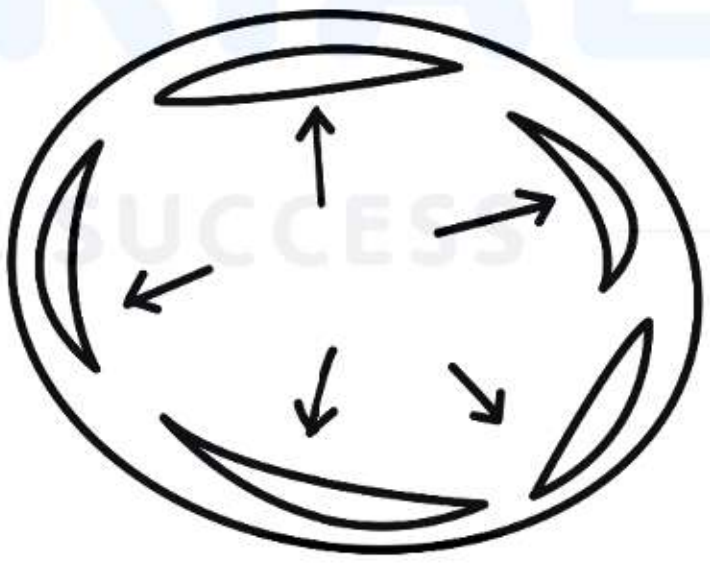 Rapid flow + pressure of blood flow ↓ endothelium damaged ↓ release of fibrin

AfraTafreen.com

AfraTafreeh.com

• L/M: Hyaline arteriosclerosis Arteriole with narrowed lumen because of hyaline deposition in wall 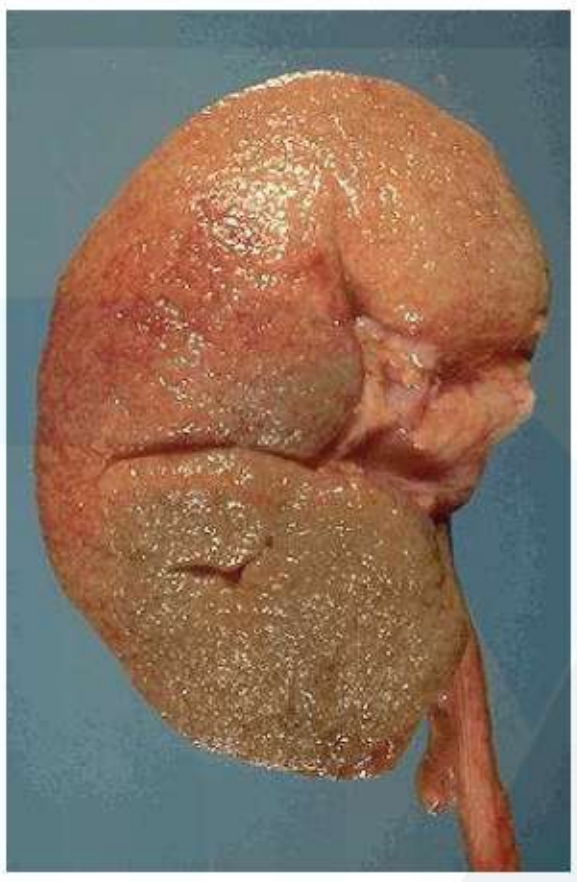 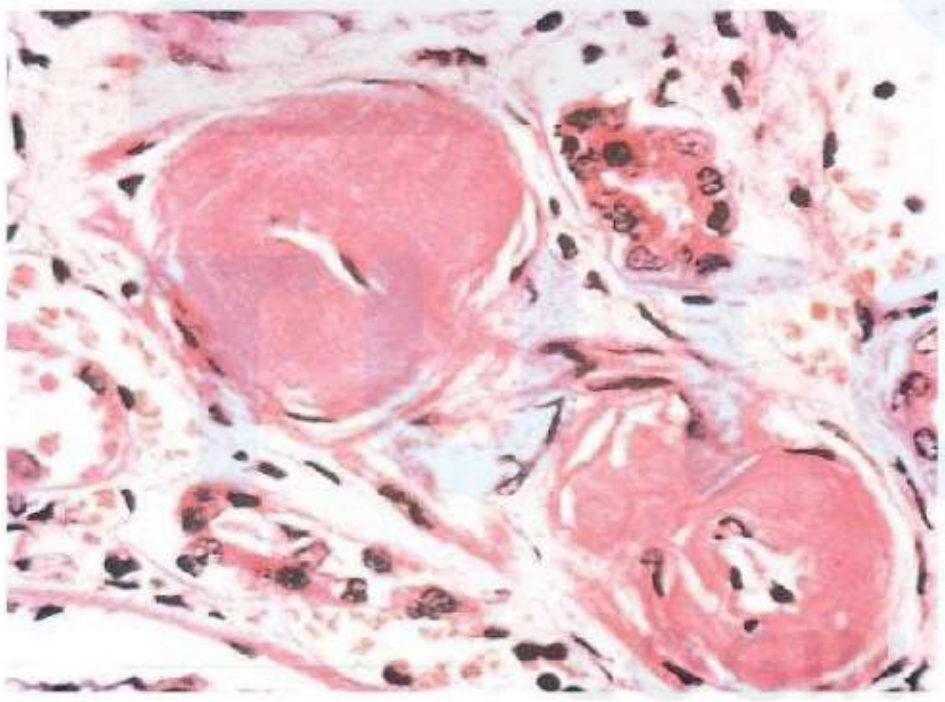 **Benign Nephrosclerosis**	I. Hyperplastic arteriosclerosis II. Onion – skin appearance due to hyperplasia of smooth muscle of tunica media 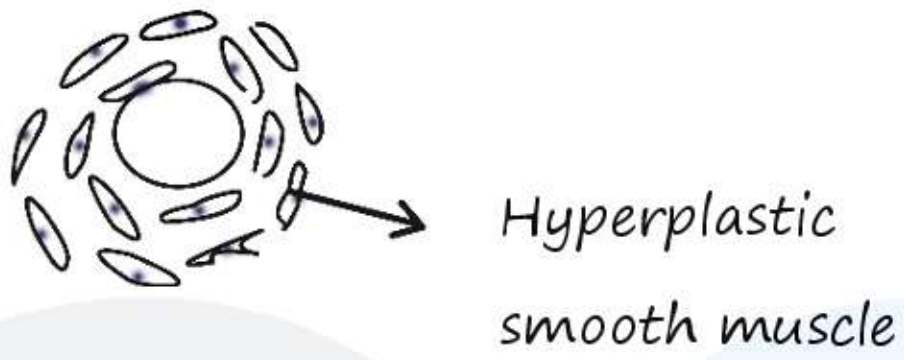 **Remember:** Onion skin appearance of Biliary tract seen in primary sclerosing cholangitis III. Fibrin deposits in hyperplastic smooth muscle → fibrinoid necrosis

IMMUNOFLUORESCENCE IN KIDNEY

Procedure

- Tag an Antibody with fluorescent stain usually FITC stain (fluoro isothiocyanate)
- This FITC tagged Antibody then binds to Antigen and emits green color under fluorescence microscope

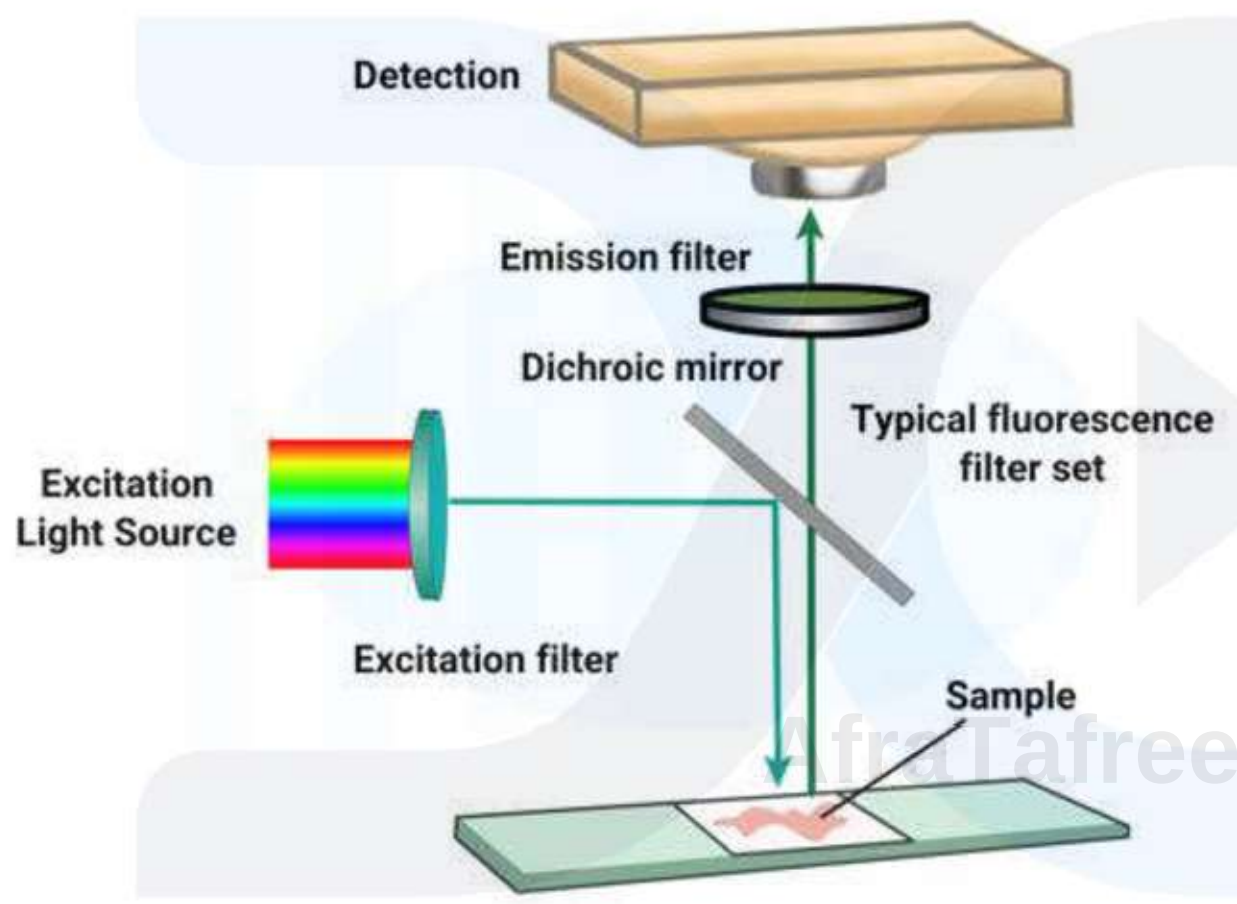

Dichroic mirror – allows light of only one wavelength to pass through

Principle of fluorescence microscopy

Fig 1

AfraTafreeh.com
TUTORIALS
LOGIN FOR SUCCESS

Patterns of GRANULAR IF

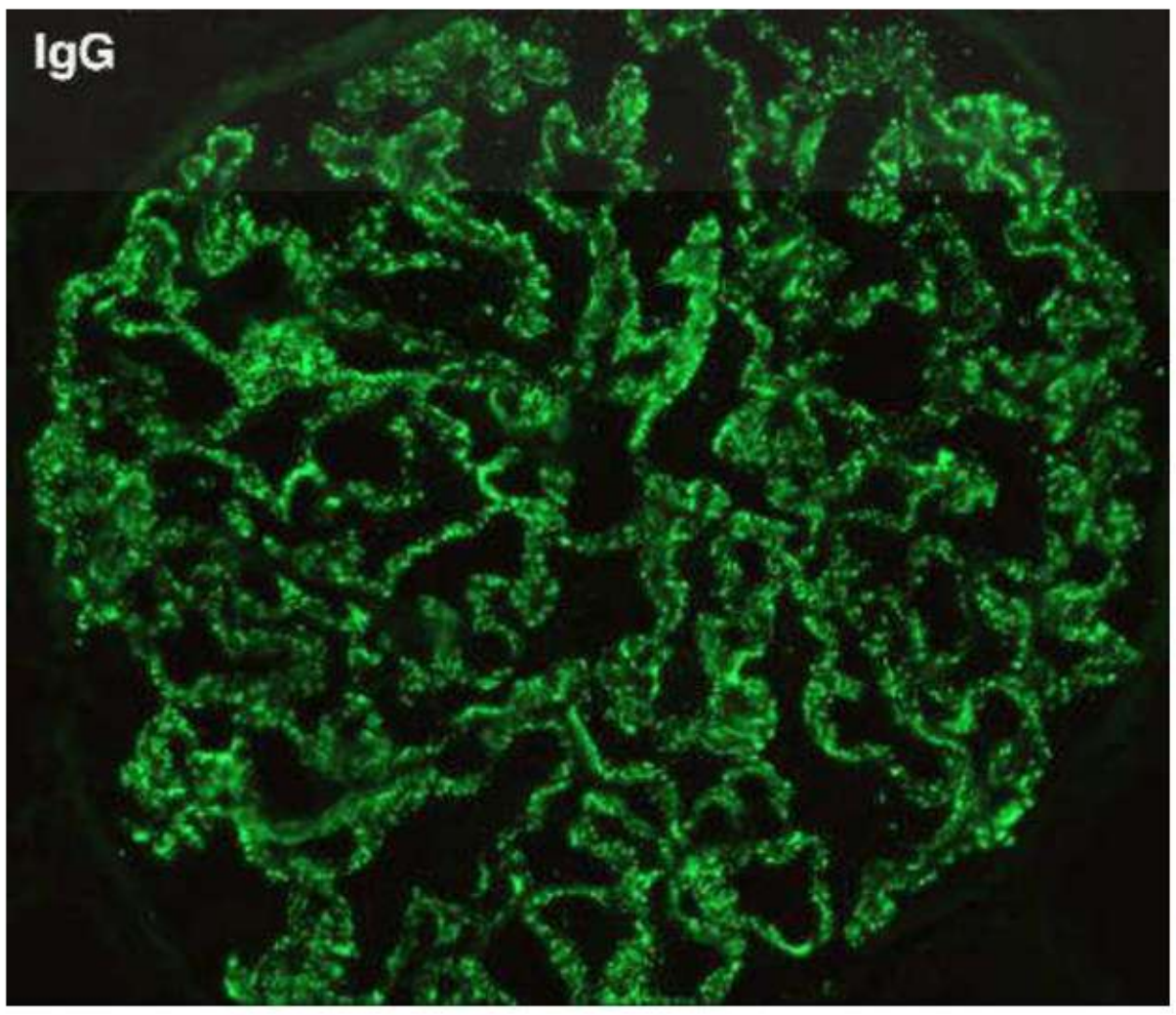

Fig 2

AfraTafreeh.com

I. Mesangial Pattern-> Mesangial Hyper cellularity in IgA nephropathy

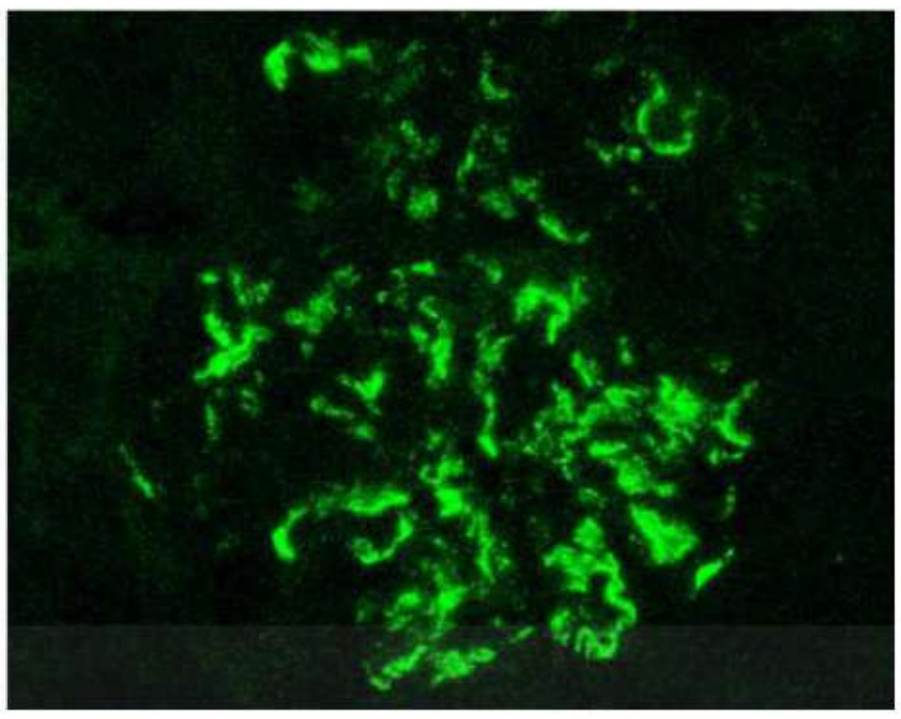

Fig 3

II.Garland Pattern Pericapillary IF

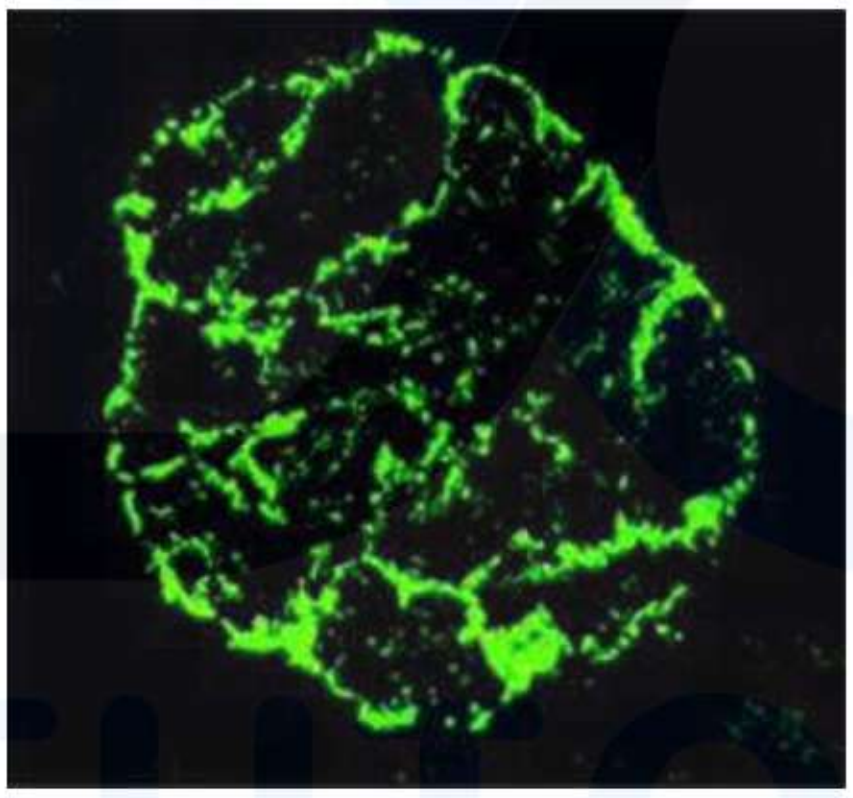

Fig 4

III. Starry sky IF Seen in PSGN

TUTORIALS LOGIN FOR SUCCESS

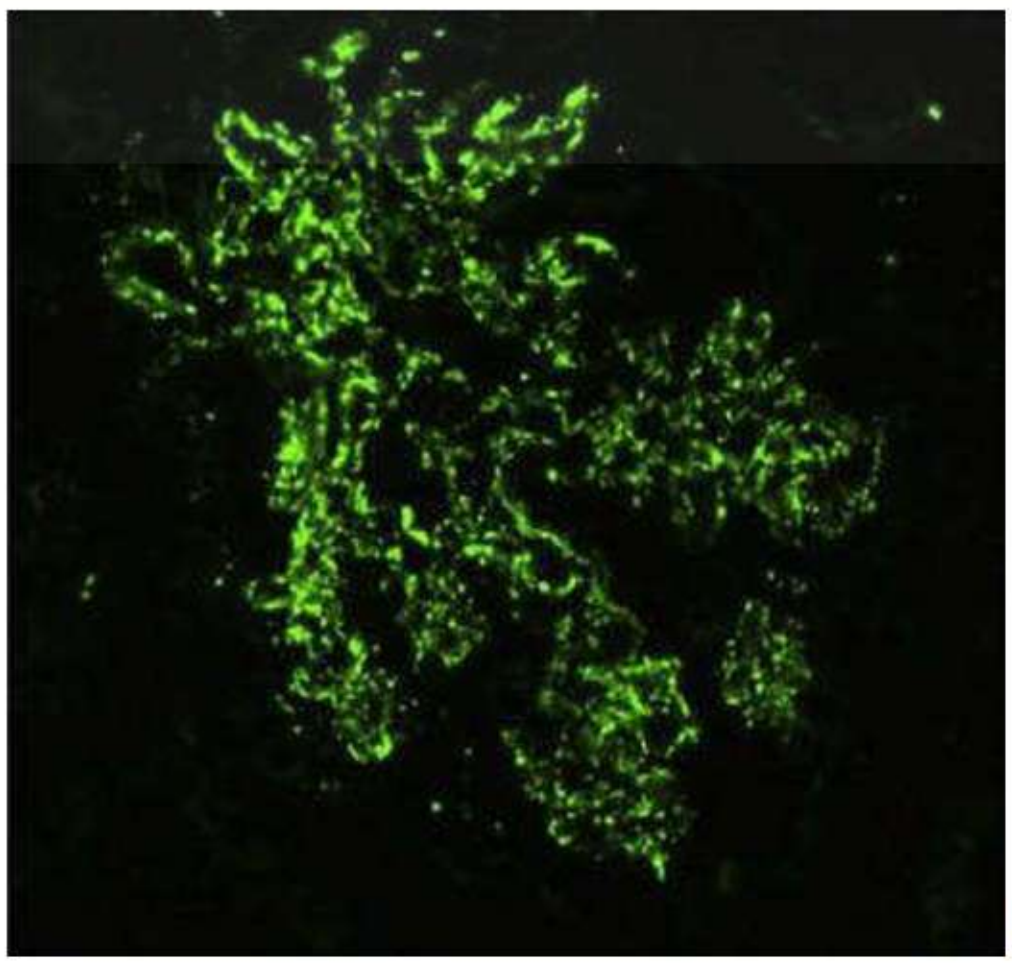

Fig 5

IV. Full House effect <u>Seen in SLE</u>

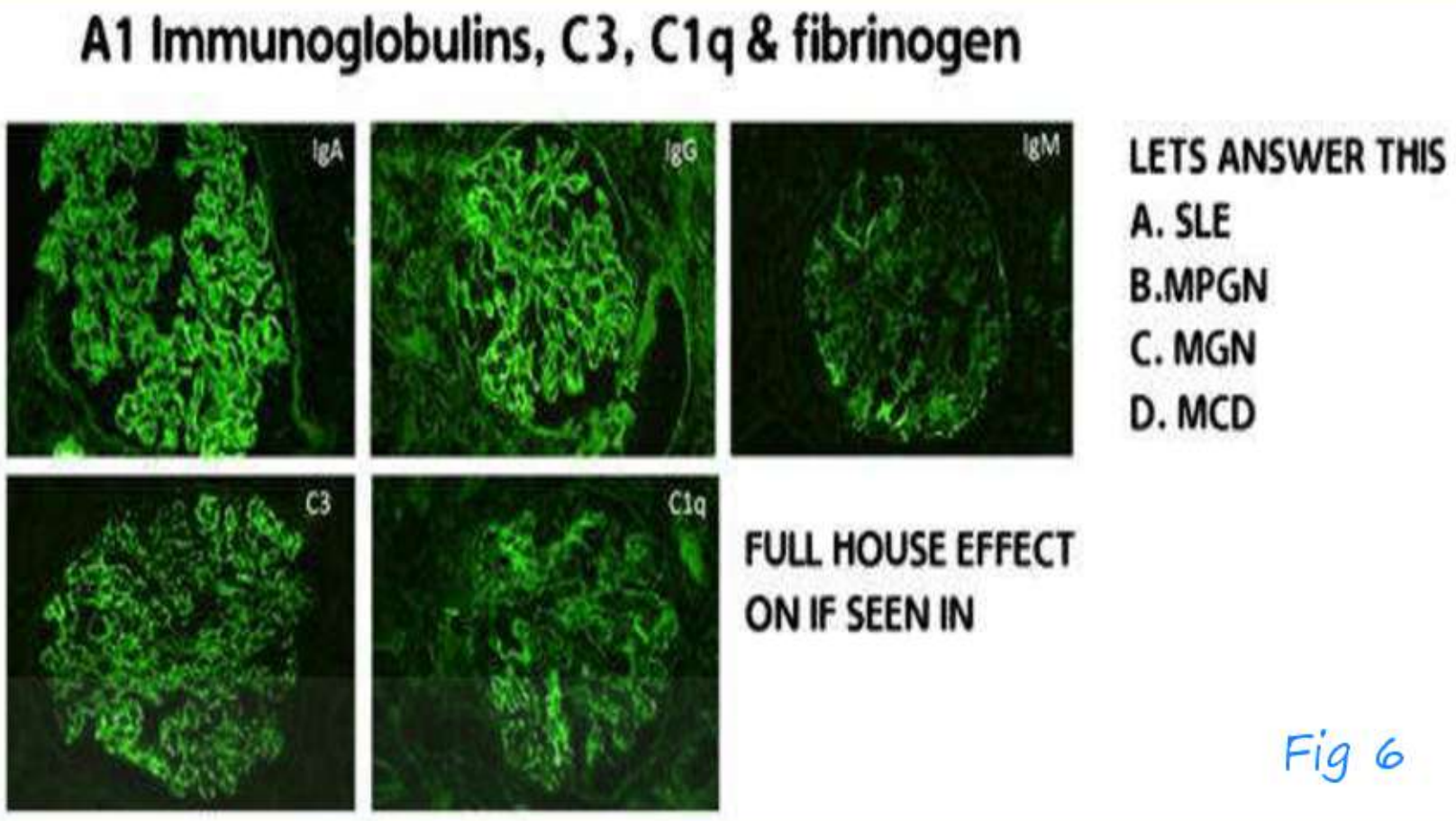

Fig 6

<u>LINEAR IF</u> – In Anti GBM disease

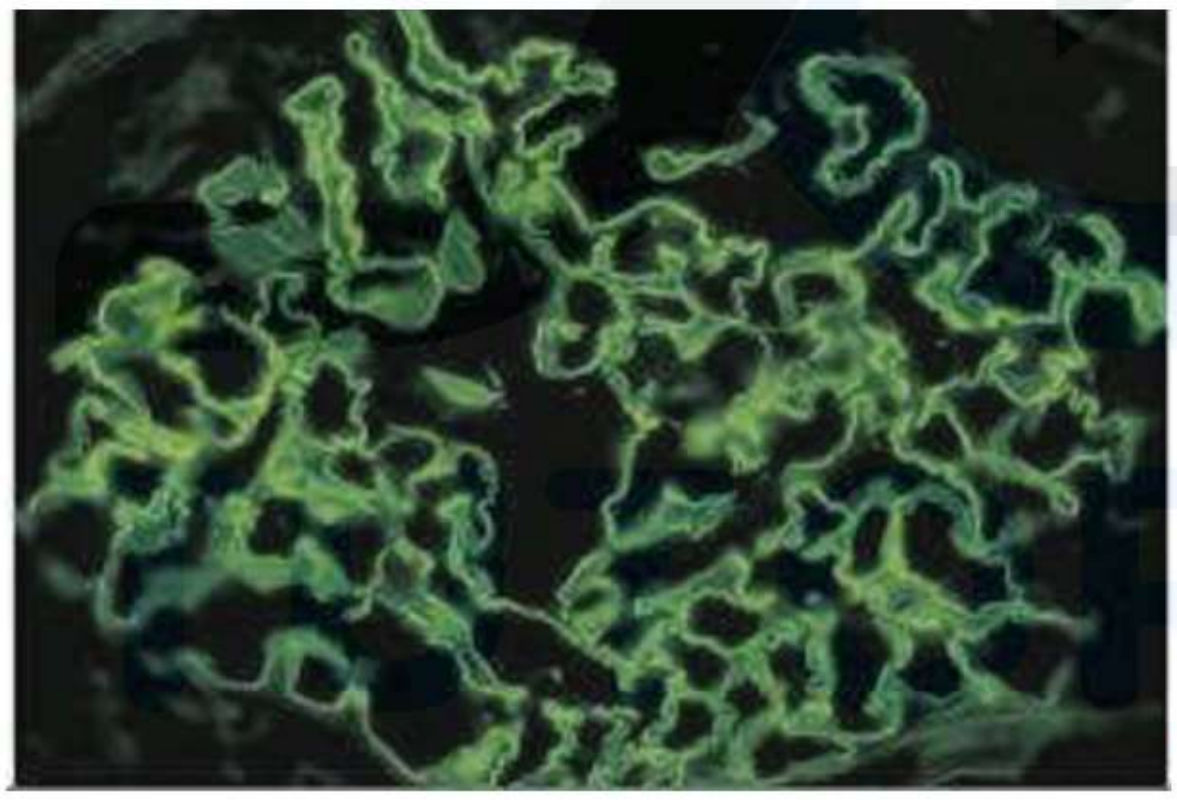

Fig 7

LOGIN FOR SUCCESS

Cresent –

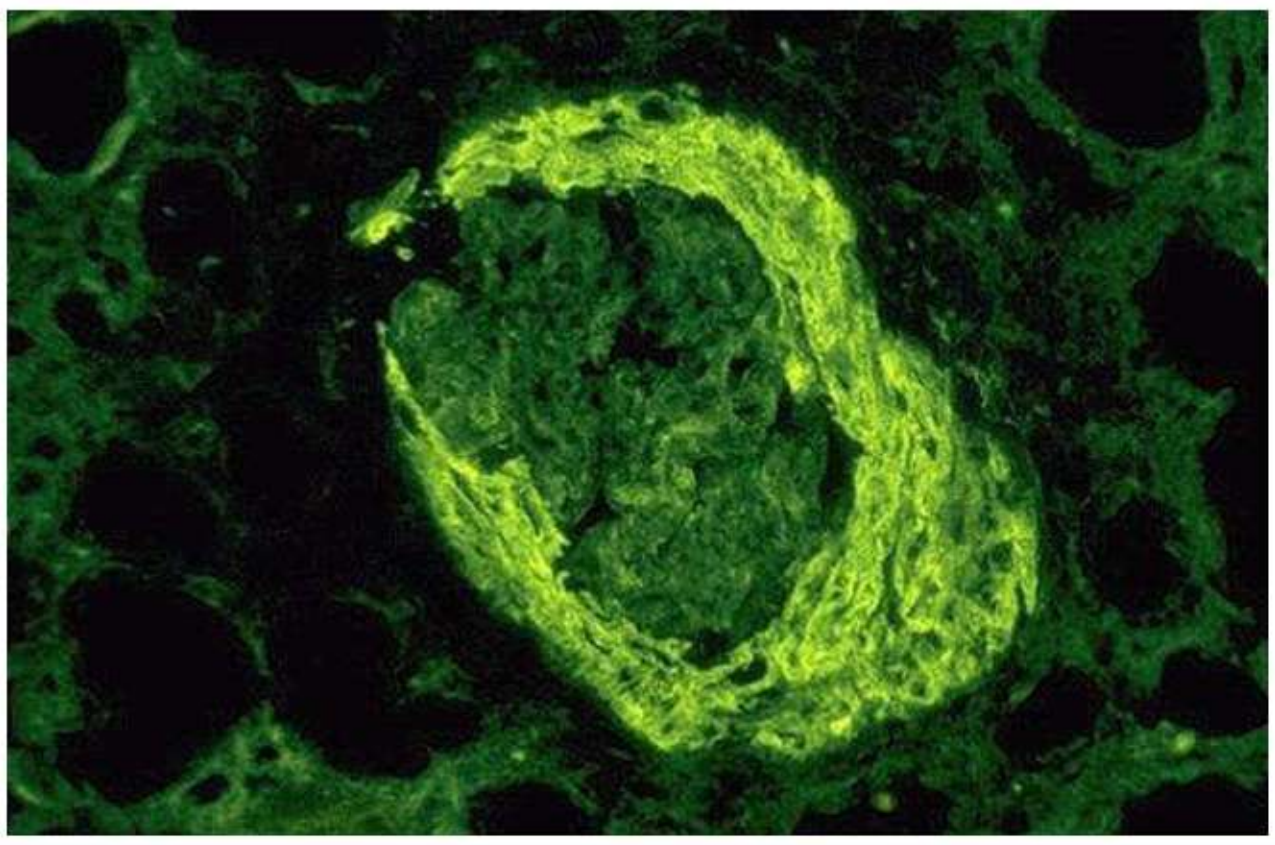

Fig 8

AfraTafreeh.com

POLYOMA TB, MALAKOPLAKIA

POLYOMAVIRUS, TB, KIDNEY, MALKOPLAKIA

POLYOMA VIRUS

An elderly male presents 2 months after renal transplantation with nephropathy. Which of the following can be a viral etiolo agent?

a. Polyoma virus B

b. HSV 6

c. Hepatitis C

d. HPv

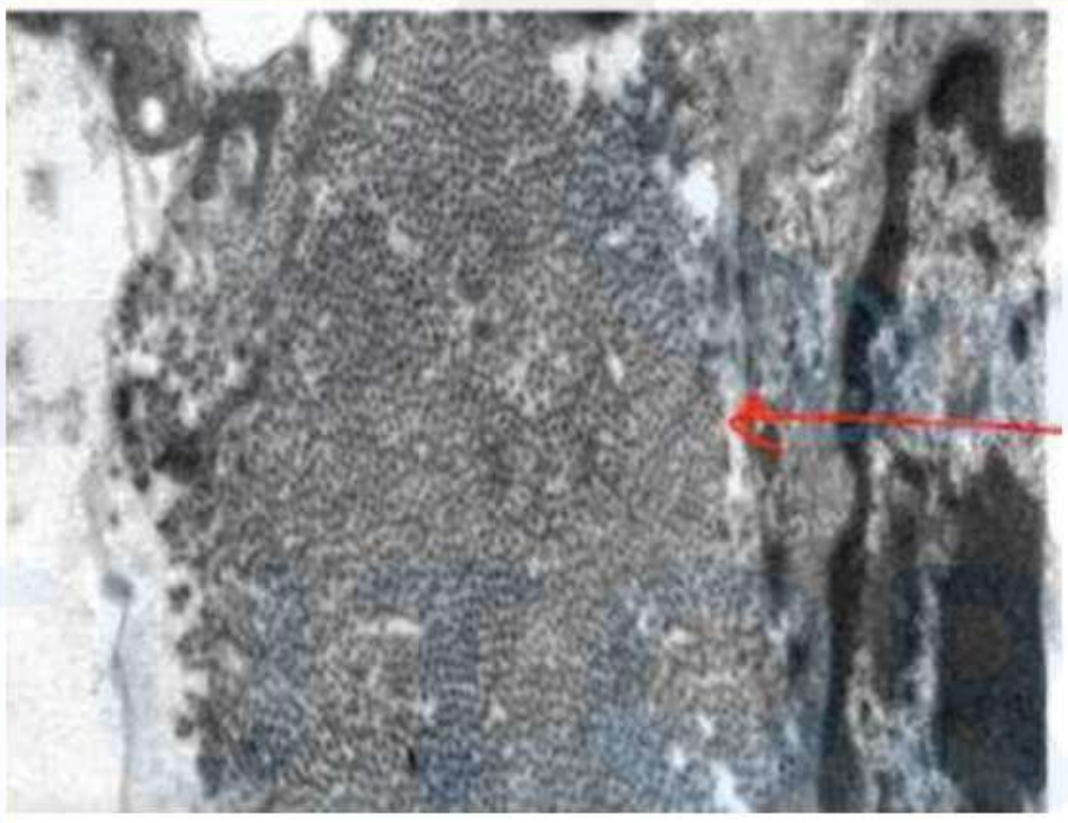

Virions filling the tubules is seen Fig 1

- Tubular nucleus appears very large and shows pale intranuclear inclusions. (Ground –glass inclusions) these are called as Decay cells.

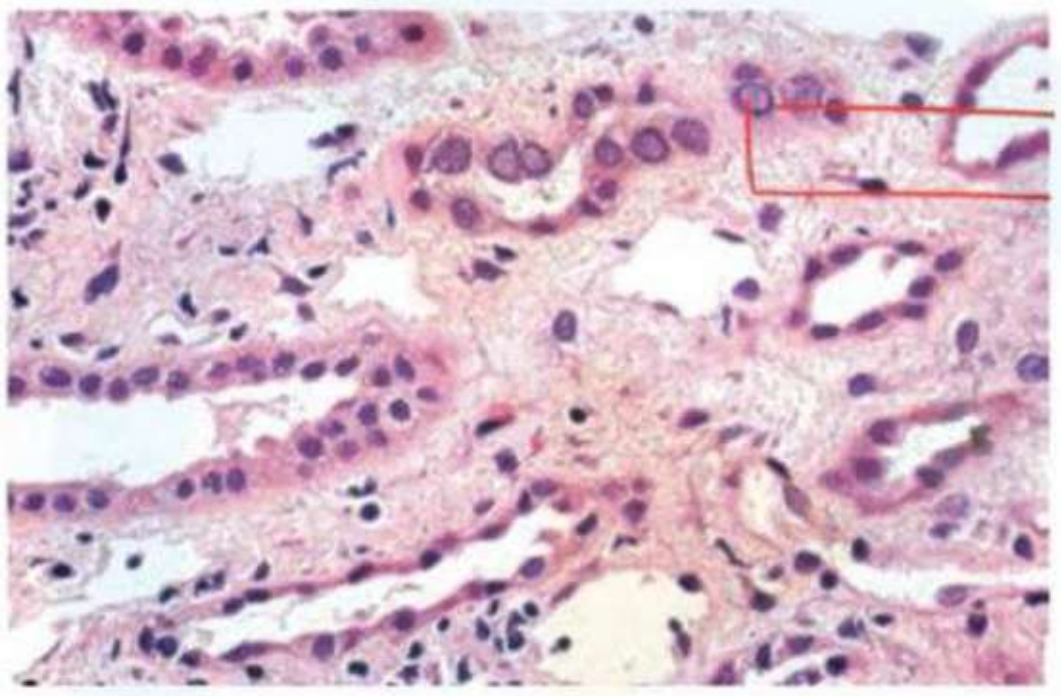

Fig 2

- Urine examination showing Decay cells of polyoma virus infections.

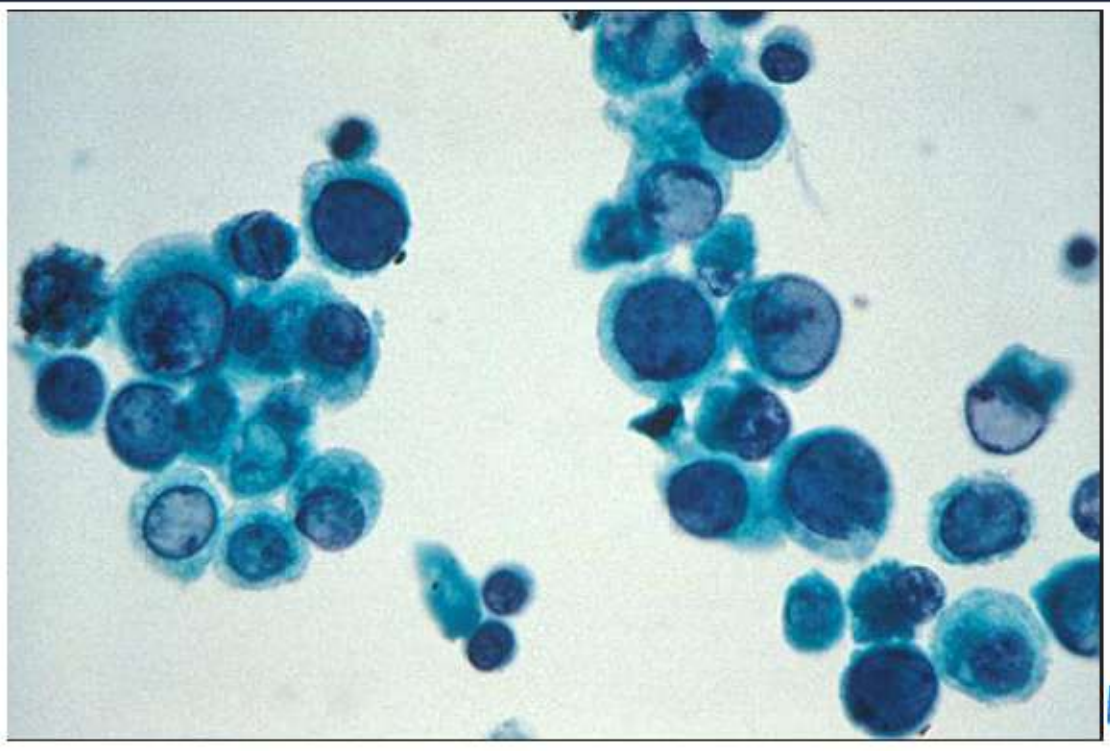

Fig 3

Diagnosis:

1. Cell culture
2. Electron microscopy
3. Polyoma virus structural protein by immune histochemistry
4. Messenger RNA expression of late genes (Eg: VP1)
5. Cytological (Example: Decoy cells)

AfraTafreeh.com
TUTORIALS
LOGIN FOR SUCCESS

TB KIDNEY

- Putty kidney – Radiological finding – homogeneous ground glass like Calcified caseous necrosis.
- Putty implies cement like kidney

Fig 4

AfraTafreeh.com

Malakoplakia 00:04:00

- Macrophage defect
- Macrophages engulfs but unable to kill E Coli.
- These are macrophages Laden with E Coli Calcify.
- These Calcified bodies appear as Target cells i.e Inside Macrophages there are Target like inclusions known as michelis Gutman Bodies.
- Discovered by von Hansenman hence these macrophages are called von Hanseman macrophages with Michelis Gutman body inclusions within them.

  Malakoplakia – Von Hanseman macrophages, michelis Gutman Bodies.
- On scopy –yellow colour 3-4cm plaques seen on Bladder Mucosa
- On biopsy- Calcification confirmed by stain Alizarin Red
- Alizarin Red stain used to identify small amount of calcium.

TUTORIALS LOGIN FOR SUCCESS

- Soft, yellow, slightly raised mucosal plaques, 3 to 4 cm in diameter in urinary bladder are seen in

  a. Xanthogranulomatous pyelonephritis

  b. Malakoplakia

  c. Nail patella syndrome

  d. Chronic pyelonephritis

Fig 5

GROSS

Von Haseman Histiocytes

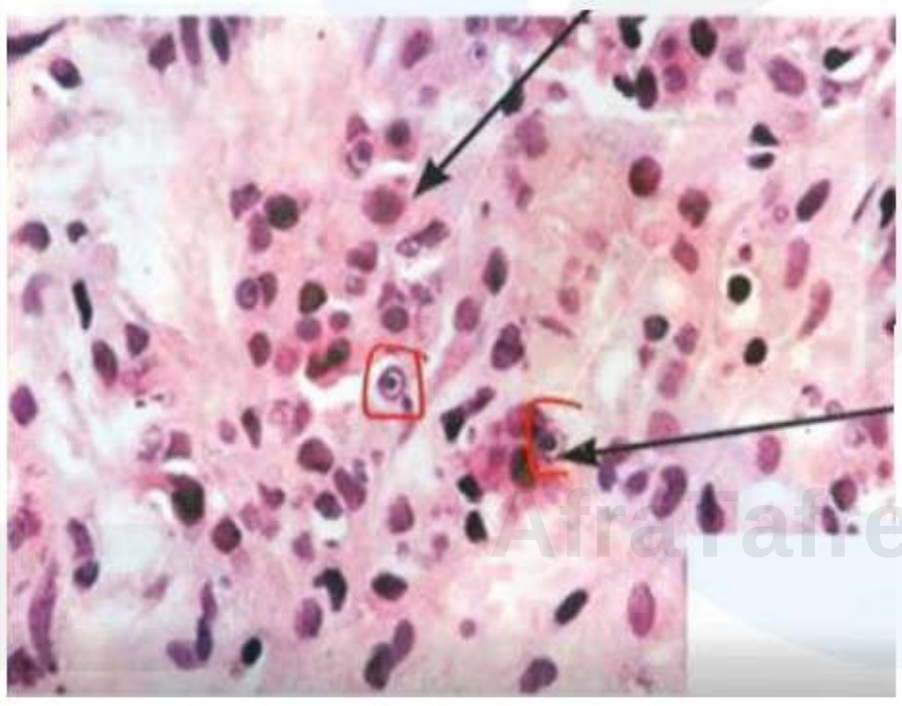

Michelis Gutman Bodies

Microscopy

Fig 6

AfraTafreeh.com

RENAL TUMORS

- In child
- Adults
  - Benign
    - Oncocytoma
    - Angiomyolipoma
  - Malignant → RCC

Renal cell Carcinoma

- M/c kidney Tumor – RCC

RCC arises

- PCT
  - Clear cell ca (M/c)
  - Papillary ca
- Collecting Duct
  - Chromophobe
  - Bellini Duct ca (Rarest)

Clear ca Cytogenetics	Papillary ca / Chromophilic RCC	Chromophobe	Bellini duct ca
i. M/C gene Mutation → VHL gene deletion on chr 3p	i. Trisomy 7,16,17 ii. Loss of y chr iii. Activation of MET protooncogene iv. Loss of Y chr is a/w sporadic ca v. Familiar papillary ca	- Best prognosis Cytogenetics - Associated with extreme	- Worse prognosis - Mutation not known yet - Associated with Desmoplasia ↓ - Increased collagen deposition with in tumor mass

	have Trisomy 7, MET mutation vi. Patients on long term dialysis develops cysts ↓ - These acquired Cysts can give rise to papillary ca ↓ - Heredity <u>Leiomyomatosis syndrome</u> ↓ - Mutation of Enzyme Fumarate hydratase ↓ - Papillary RCC& Multiple Leiomyomas	hypoploidy ↓ - Loss of multiple chromosome chr 1,2,5, 7	(Formed by tumor cells itself) ↓ - Because of desmoplasia no penetration of chemotherapy and radiotherapy ↓ - Worse prognosis <u>Tumors with Desmoplasia</u> i. Pancreatic Ca-M/C ii. Cholngio ca iii. Bellini Duct ca

AfraTafreeh.com

AfraTafreeh.com

Renal cell carcinoma of young

Xp 11 translation carcinoma

- T(X,1)
- X chr has gene- TFE3
- Mixture of clear cell & Papillary
- Papillae lined by clear cells

Medullary Ca kidney

- Mean age -26 years
- Occurs in pts with sickle cell trait
- Mutation of SMARCB/INI-1
- 7th manifestation of Sickle cell anemia

Remember

- 7 manifestation of sickle cell in kidney

i. Infarct

ii. Papillary Necrosis

Iii. FSGS

Iv. Pyelonephritis

V. Isosthenuria

Vi. Isolated Hematuria

Vii. Medullary ca kidney

Clear cell ca

Multifocal tumor

← Both arise from PCT →

Clear cell ca:

Unifocal tumor
↓
Yellow in colour
↓
Contains Glycogen & Lipid
Disappears when put in Formalin & cells become clear

Multifocal tumor:

Papillae lined by cuboidal cells t
↓
Psammoma bodies
Psammoma Ca-also known as Chromophilic RCC

Pathogenesis of clear cell carcinoma

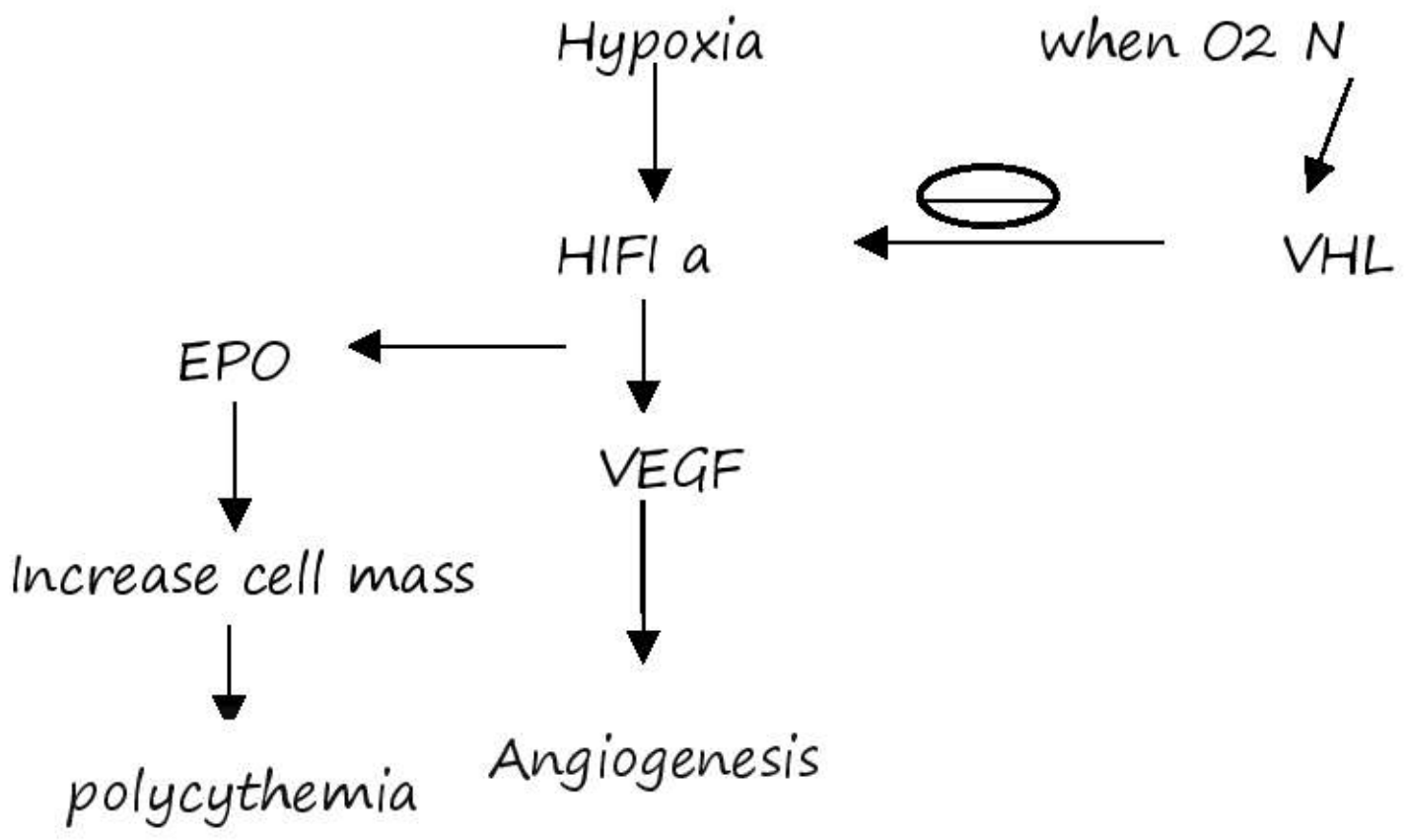

- If VHL deleted → Angiogenesis and Increases in RBC mass continues
- Therefore polycythemia & HTN are the paraneoplastic manifestation of RCC especially clear cell carcinoma
- Because of continued Angiogenesis → tumor mass shows lots of proliferating Blood vessels in between clear cell

  Fuhrman Grading in a clear cell Ca to know Grade of tumor and how aggressive is the tumor

AfraTafreeh.com
TUTORIALS
LOGIN FOR SUCCESS

AfraTafreeh.com

Chromophobe RCC	Bellini Duct cancer
Chromo phobe ↓ Colour phobia Perinuclear area does not Take up colour → Perinuclear halo ↓ Very typical of chromophobe RCC ↓ Raisinoid Nucleus ↓ Perinuclear Halo	- Nucleus pushed to called HOB – Nail cells - Surrounded by Extensive Desmoplasia

- Grows like a plant with very Well-defined margin
- Halo colloidal iron stain for Mucin stain, chromophobic cells pink except the perinuclear area

i. Clear cell carcinoma

- Yellowish tumor unifocal

Fig: 1

- Microscopic appearance of clear cell carcinoma

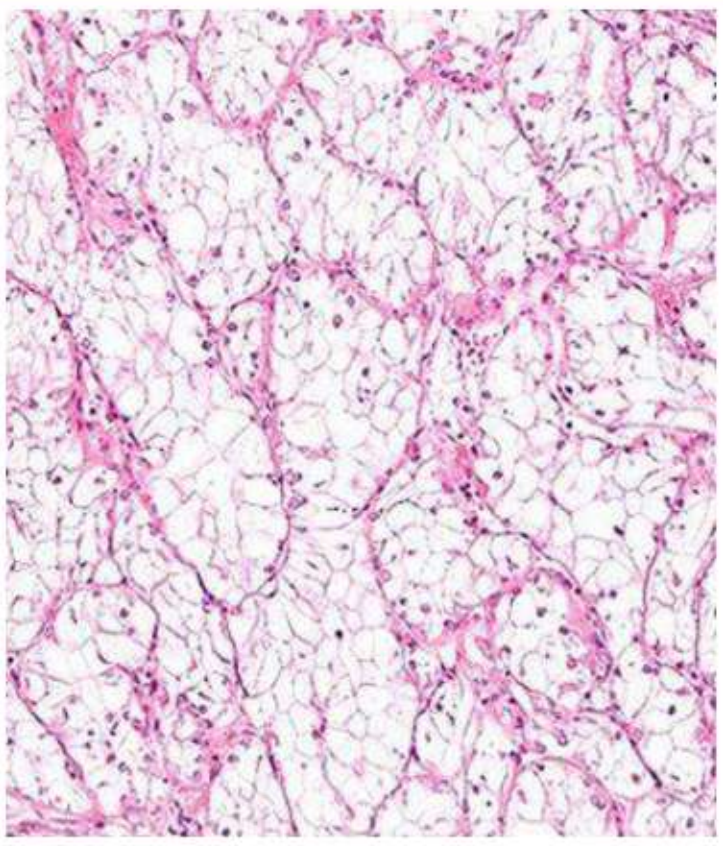
Fig: 2

ii. Papillary carcinoma

- Papillary projections

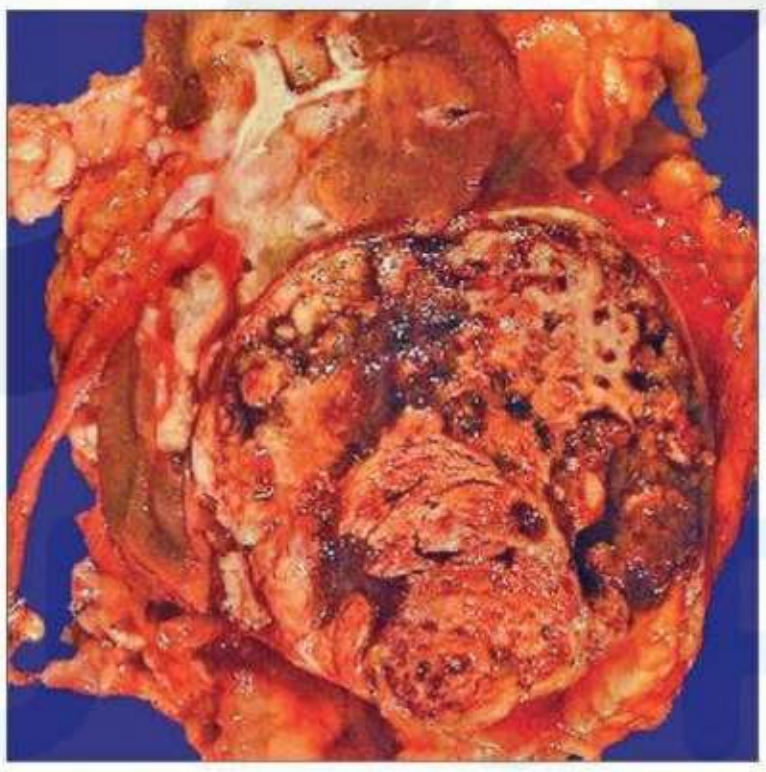
Fig: 3

- Microscopy of papillary carcinoma

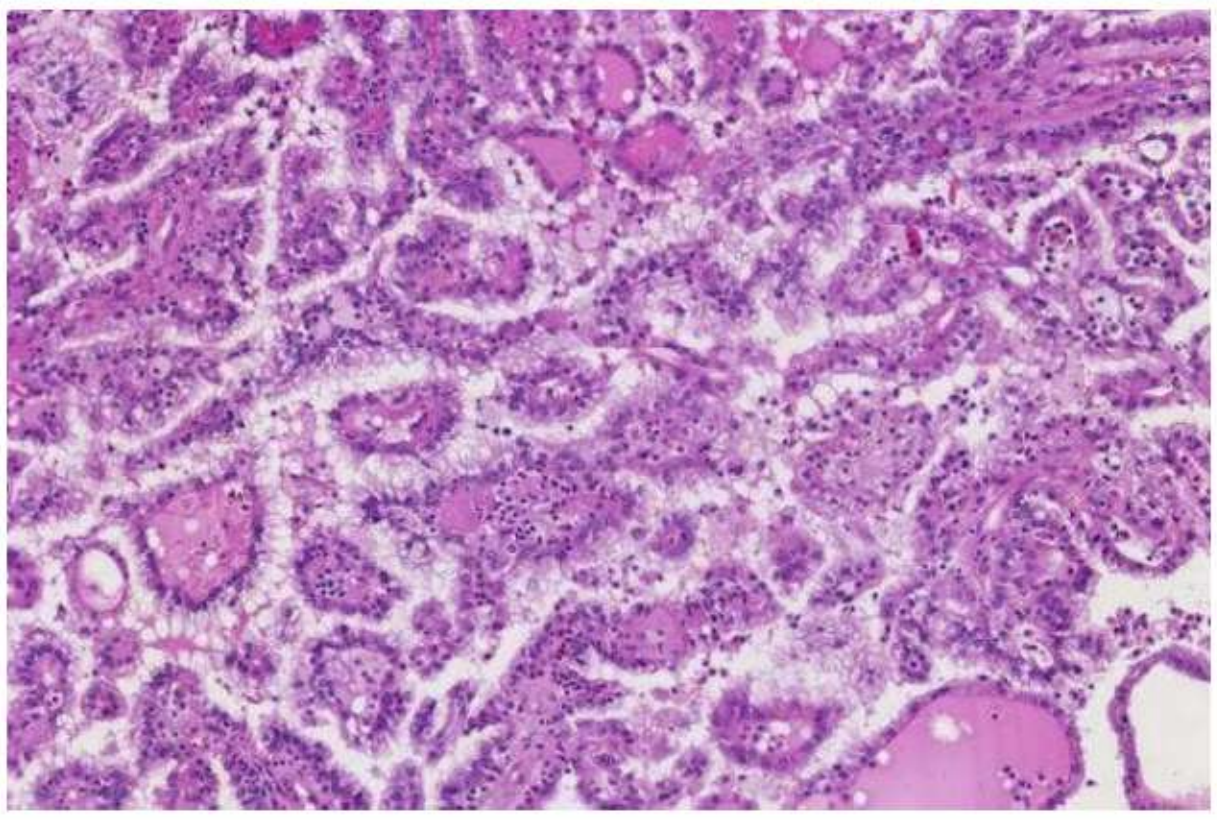
Fig: 4

AfraTafreeh.com

- Psammoma bodies

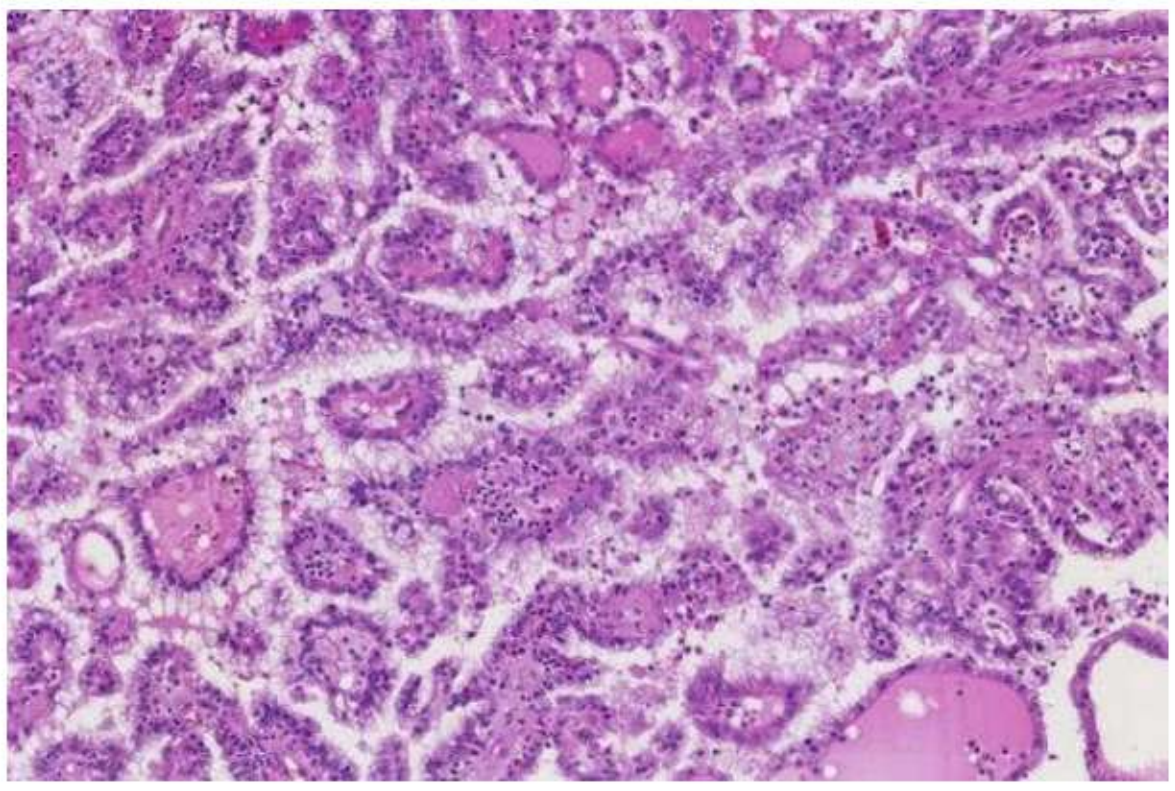

Fig: 5

iii. Chromophobe RCC

- Homogenous Tan tumor

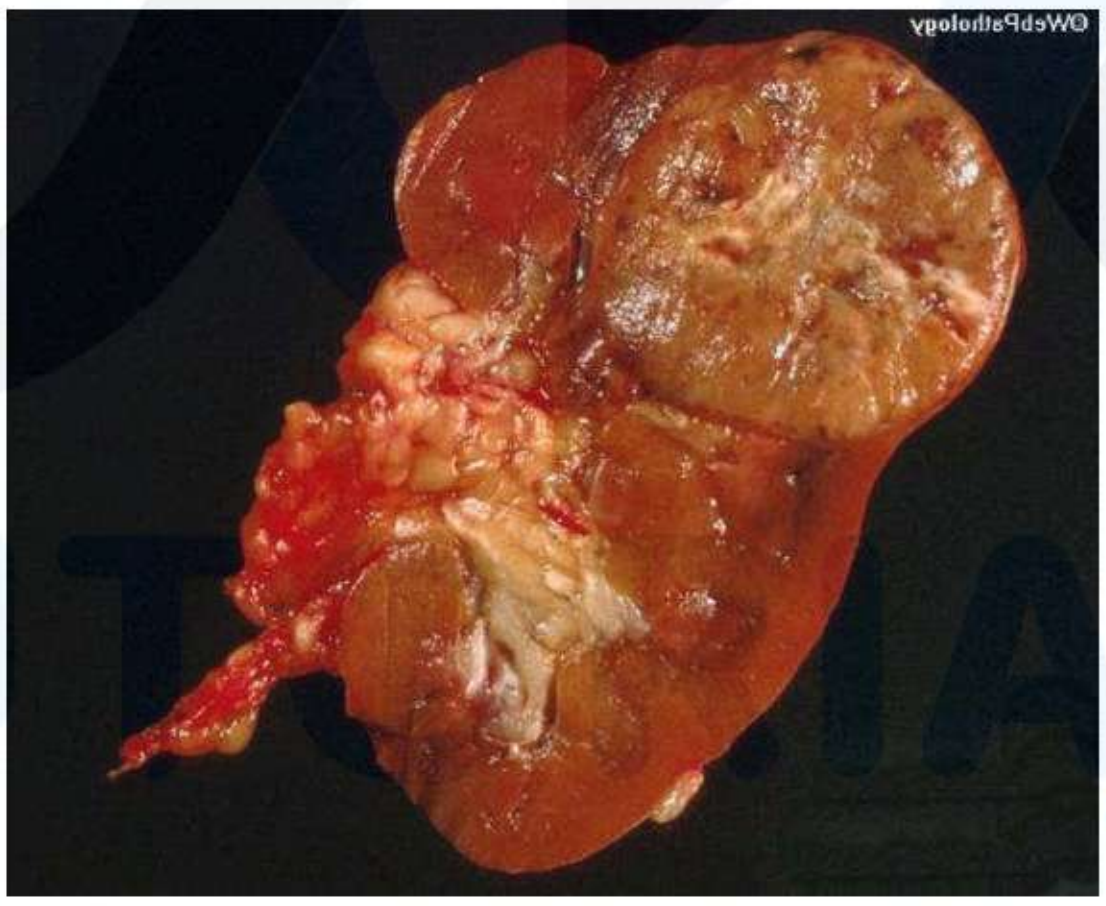

Fig: 6

- Microscopy- Hyperchromatic nuclei w/peri nuclear Halo

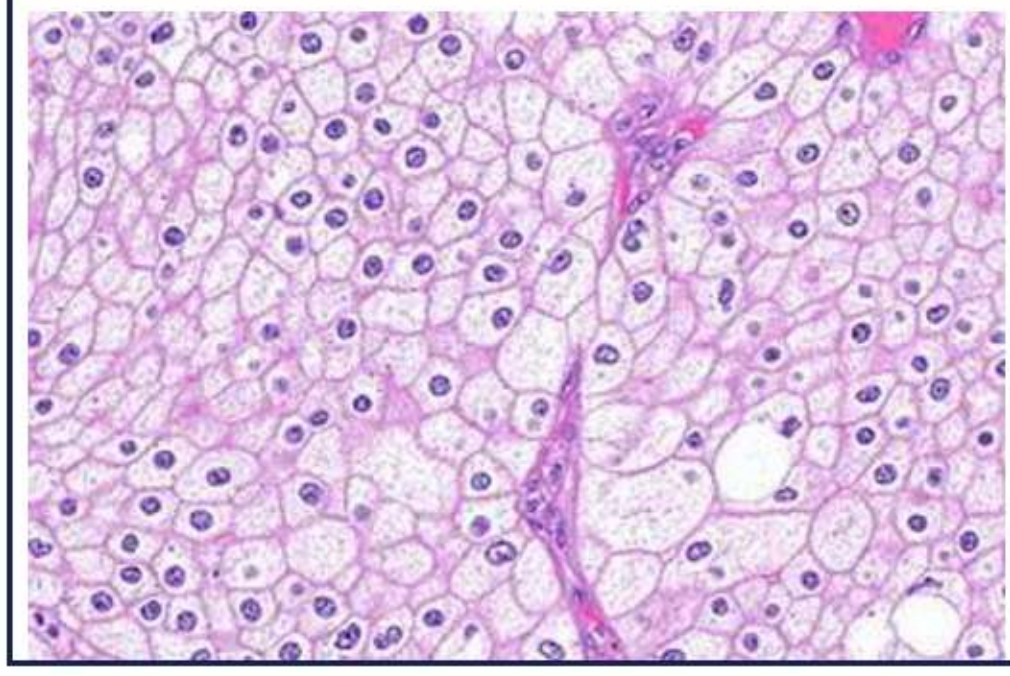

Fig: 7

- Colloidal Iron stain

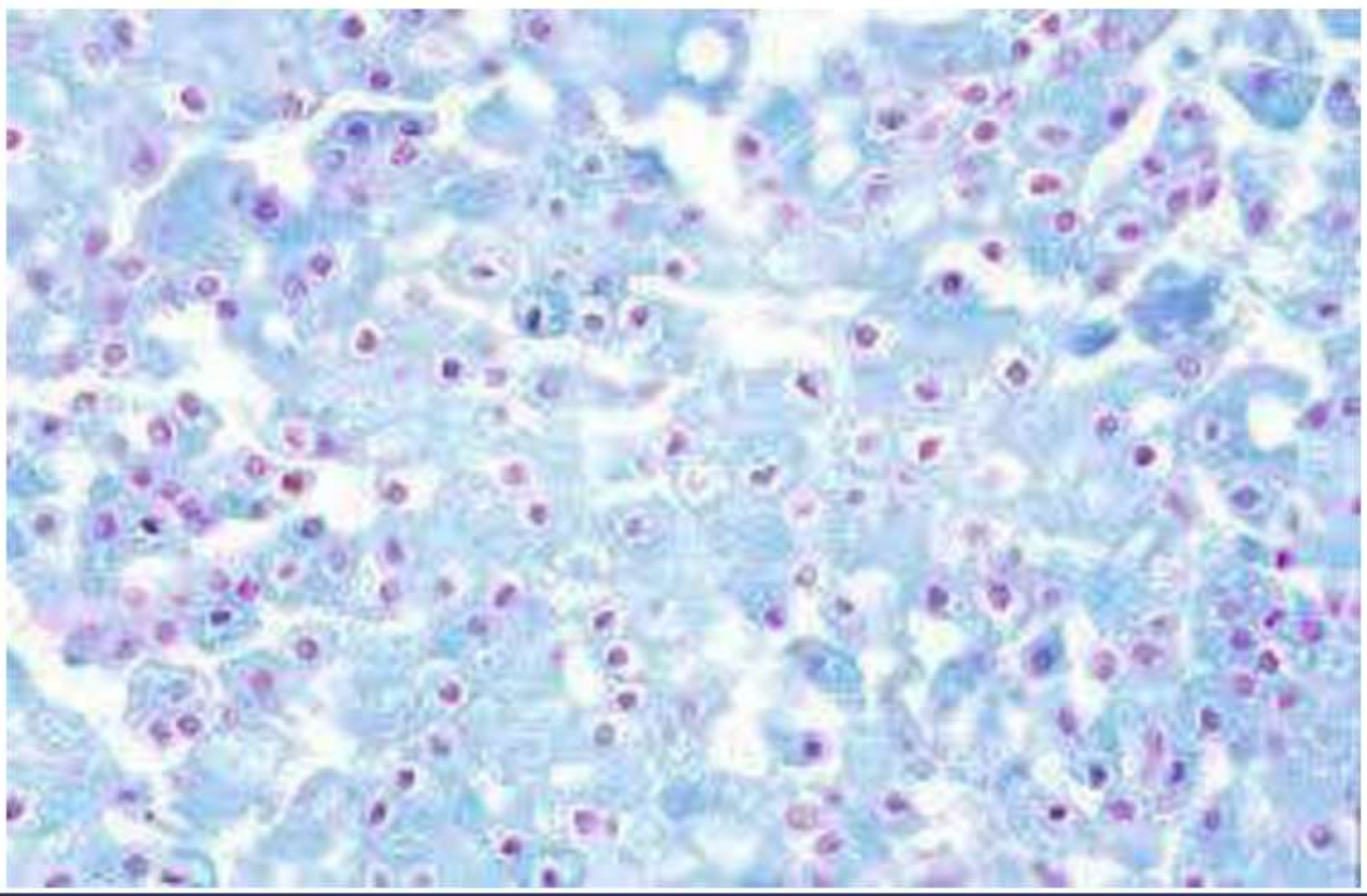

Fig: 8

- Bellini Duct carcinoma Hobnail cells w/extensive desmoplasia

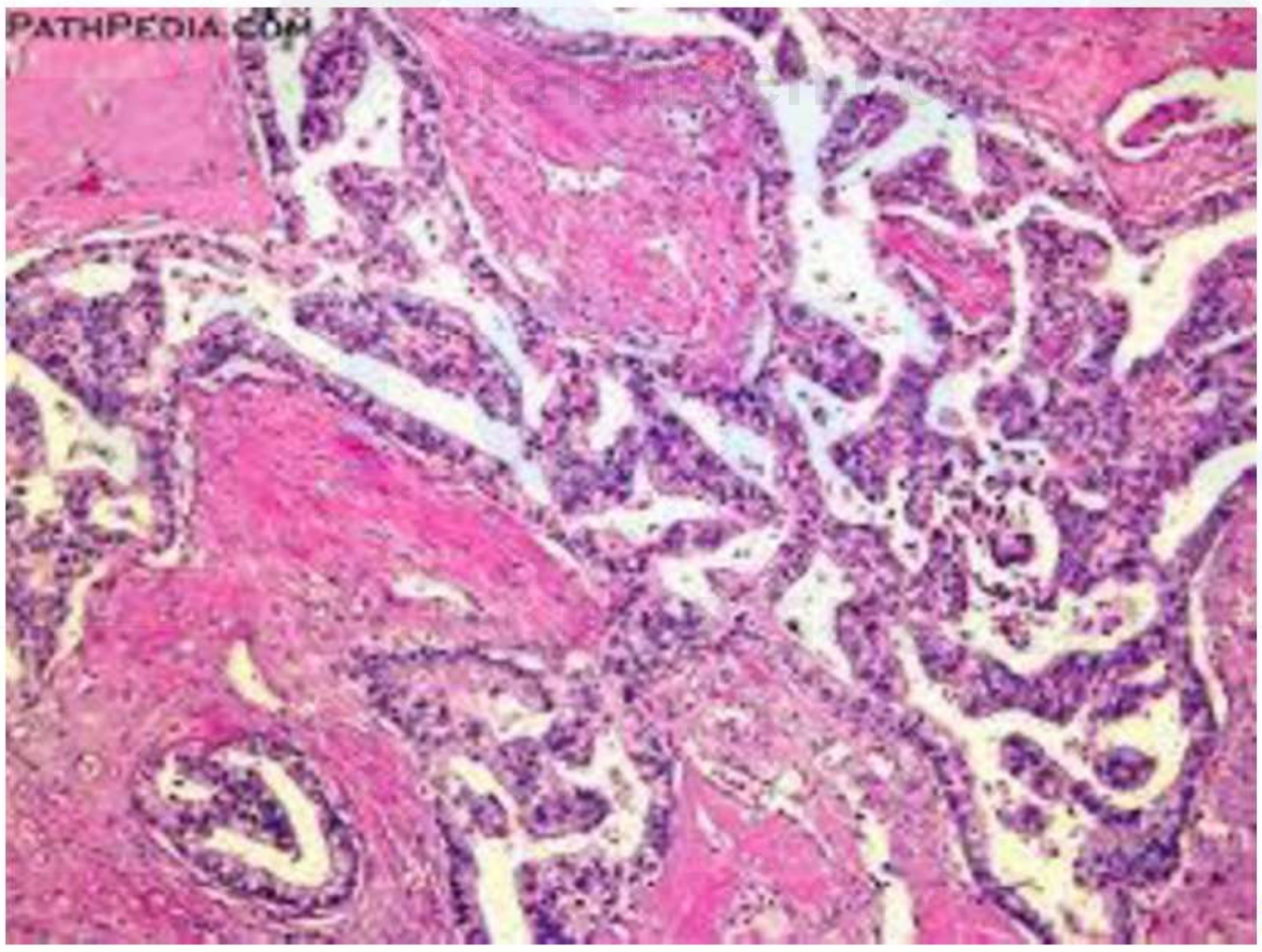

Fig: 9

Note on **<u>Birth Hogg Dube syndrome</u>**

- BHD gene codes for Folliculin Location – Chr 17p
- Present with → chromophobe RCC, pulmonary cysts Fibrofolliculomas

AfraTafreeh.com

GIST

Renal cancers

	Clear cell	papillary	chromophobe	Collecting duct
Associated syndrome	MC VHL (3p) deletion	Trisomy 7 (Met) hereditary leiomyomatous syndrome	birt hogg dube syndrome (follicular gene) extensive hypoploidy	Least commont <1%
orgin	pct	pct	inter calated cells of CD	CD of Belline
Mc	High lipid Content	Papillary	peri nuclear Halo	Hobnail cells
Gross	Single mass Ipsum	psammoma bodies	welll defined outlines (plant like)	+
sp stain		multivv focal	Hale's colloidal iron	Extensive desmoplasia

Benign tumors of kidney

Oncocytoma

↓

- Arises from Intercalated cells of calleting duct
- Closest Differential is Chromophobe RCC
- Oncocyte means cells with Lipoma Fat

Lots of mitochondria

Mahogany Brown

Angiomyolipoma

- Also called AML of kidney

Angio→ proliferation of Blood Vessel

Myo → Muscle

- seen in patients' tuberous sclerosis
- – Positive for HMB 45

Central scar

Mahogany Brown on pathology
i. Oncocytoma
ii. Iodine staining

- Central scar Mahogany Brown with

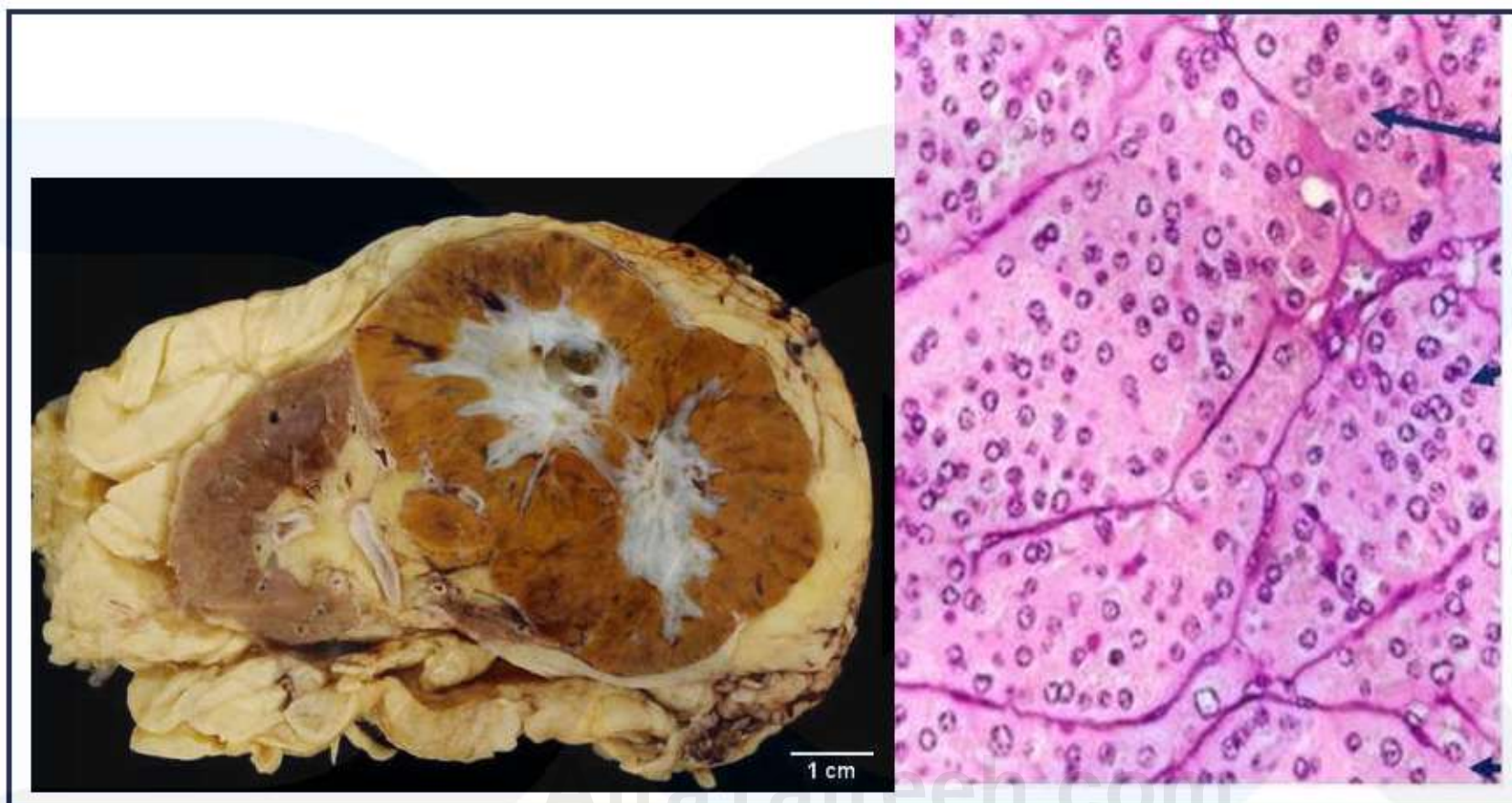

Fig: 10

Oncocytes shows Abundant pink colour

Cytoplasm with small nuclei

↓ **Chromophobe RCC**
- **Homogenous Brown**

↓ **Oncocytoma**
- **Central scar**

Fig: 11

AfraTafreeh.com

WILMS TUMOR

- M/C Primary Renal tumor of childhood
- 90% sporadic, 10 % familial
- Usually occurs at 3–4 years

FAMILIAL:

- Gene –wt gene –associated with three syndrome presentation

<table>
<tr><th>WAGR</th><th>Denys drash syndrome</th><th>Beckwith Weideman syndrome</th></tr>
<tr>
<td>- Deletion of WTs on chr 11p,13
- WT 1 PAX6 very important for normal development of Tris and Gonads Chr11</td>
<td>- Deletion of only WT1
- Zinc finger TF – DNA binding domain affected
- Dominant negative mutation</td>
<td>- WT_2 Gene on 11p 15-5 locus undergoes loss of genomic imprinting (loss of maternal imprinting)
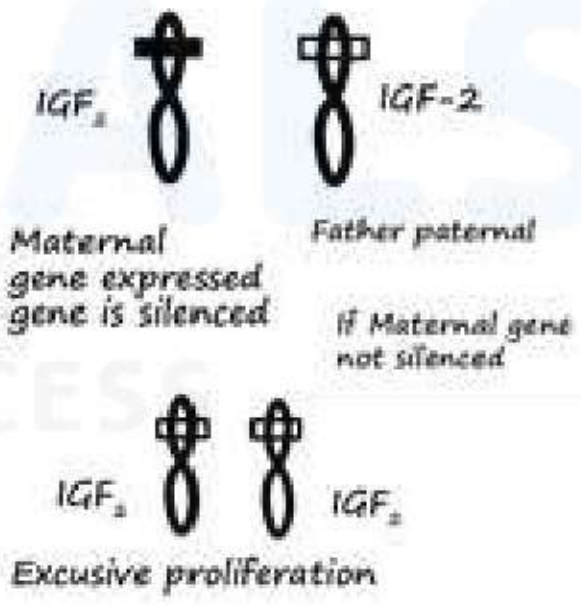

• Uniparental Paternal Disomy can also cause even when imprinting is normal</td>
</tr>
</table>

	- Gonadal dysgenesis and diffuse mesangial sclerosis	• Both copies of IGF2 received from Father • Child presents with hemihypertrophy • Omphalocele • Macroglosia • Microcephaly • Hepatomegaly • Adrenomegaly
- Both WT1 and PAX6 are deleted	-risk of gonadoblastoma	• High chance of developing i. Wilms tumor ii. Adrenal cortical carcinoma iii. Hepatoblastoma iv. Rhabdomyosarcoma
-WAGR W – Wilm's tumor A – Aniridia G – Genital abnormality R – Mental Retardation		

AfraTafreeh.com

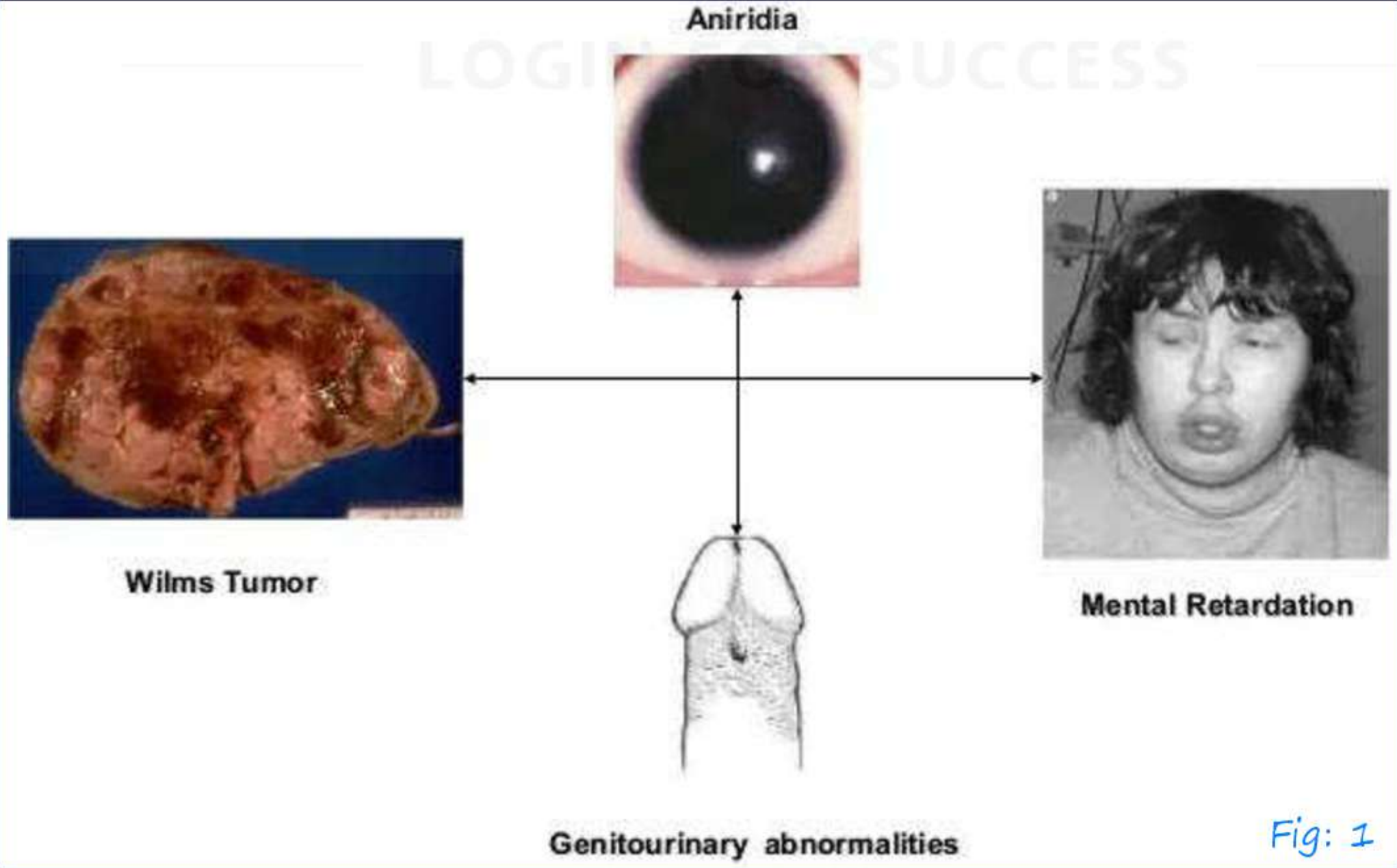

Fig: 1

AfraTafreeh.com

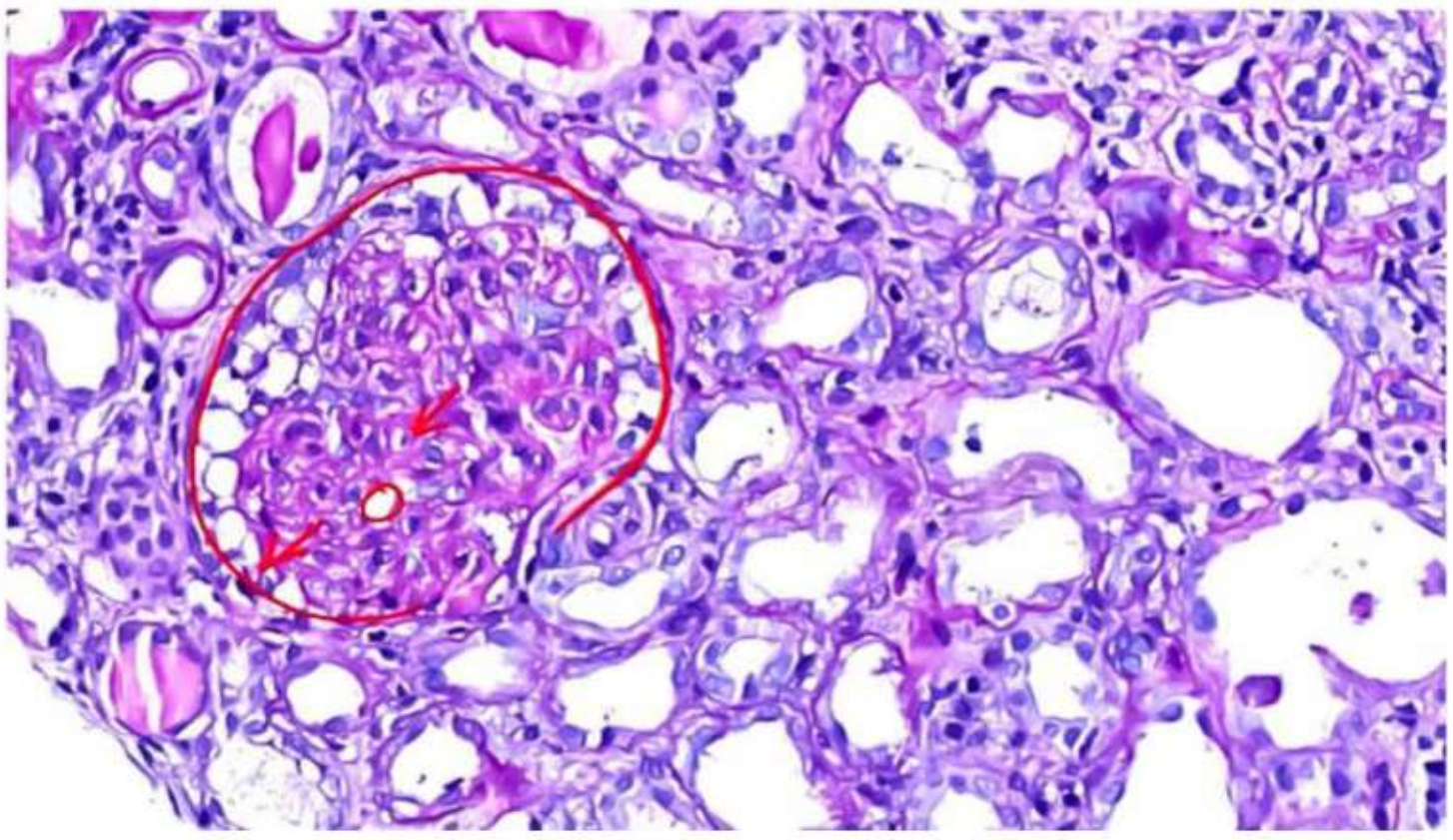

Stain- mason trichrome stain Fig: 2

Denys Drash Syndrome

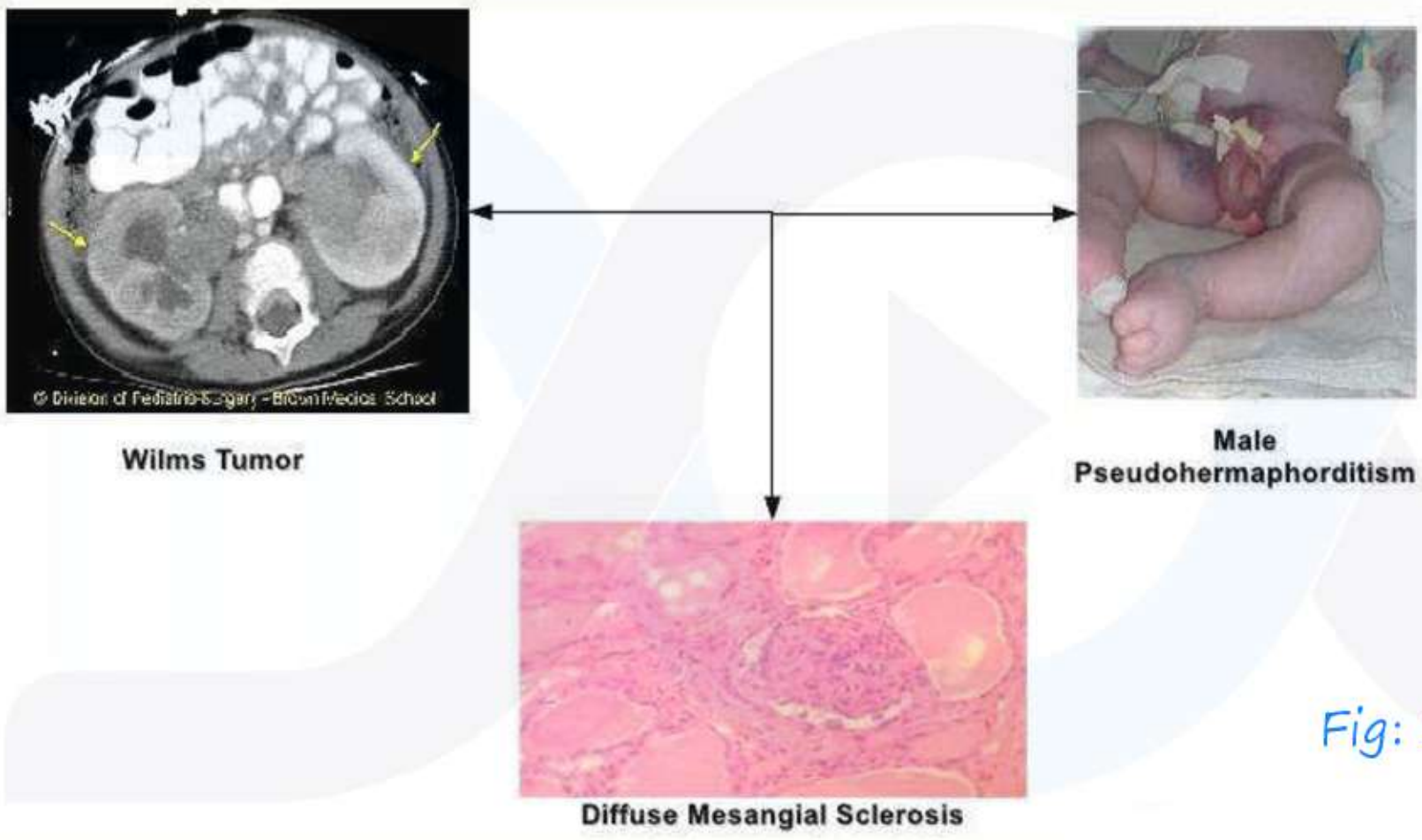

Fig: 1

Beckwith-Wiedemann Syndrome

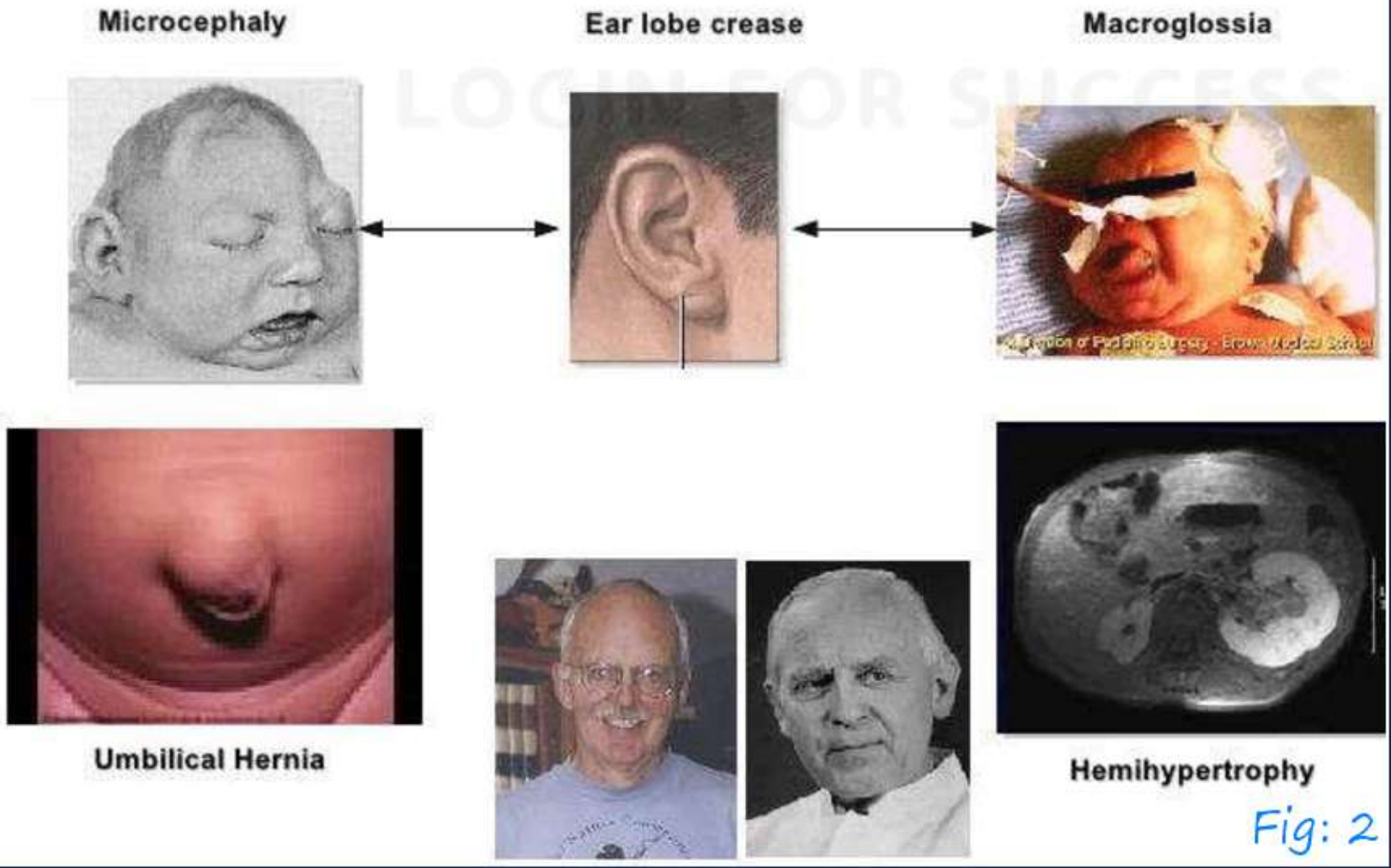

Fig: 2

SPORADIC

- Genes associated in sporadic cases – 1) gain in beta catenin gene , miRNA 200 mutations (blastemal variant)
- Mesenchymal epithelial transition is affected (miRNA 200 functional loss)
- 2) DICER -1 mutation are also involved
- 3) P53 mutation. - causes a aplastic wilms tumor (worst prognosis)

Gross appearance of Wilms Tumor

- Fleshy tumor
- 'Fish flesh appearance' because of excess Mesenchymal component
- Pseudo capsule

AfraTafreeh.com

Fig: 3

- Microscopically – 3 Components – Triphasic tumor

  i. Epithelial – Abortive tubules, Abortive Glomeruli

  ii. Mesenchymal – Spindle shaped cells

  iii. Blastemal – Sheets of small blue cells

AfraTafreeh.com

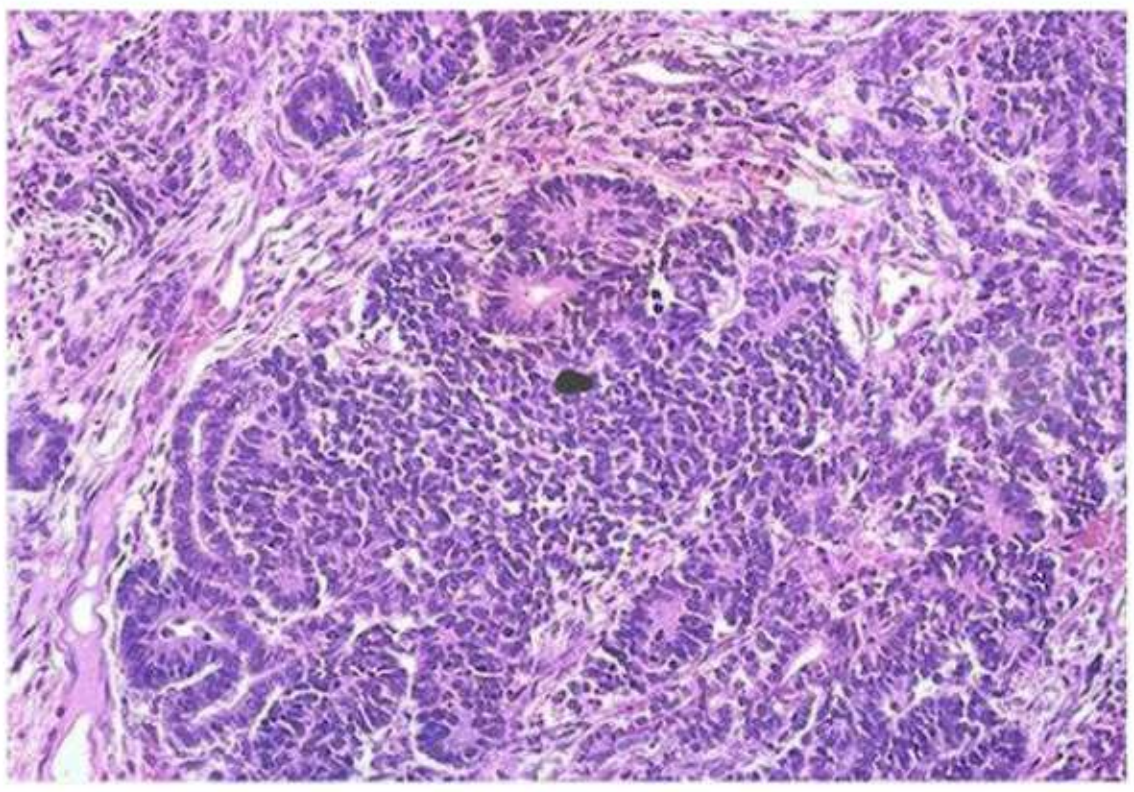

Fig: 4

- Prognosis – Good
- LOH 1p and 16q mutations- poor prognosis
- Histologic anaplasia indicates poor prognosis
- Anaplasia is indicated by –

  1) nuclear enlargement 3x

  2) nuclear hyperchromasia

  3) abnormal mitosis

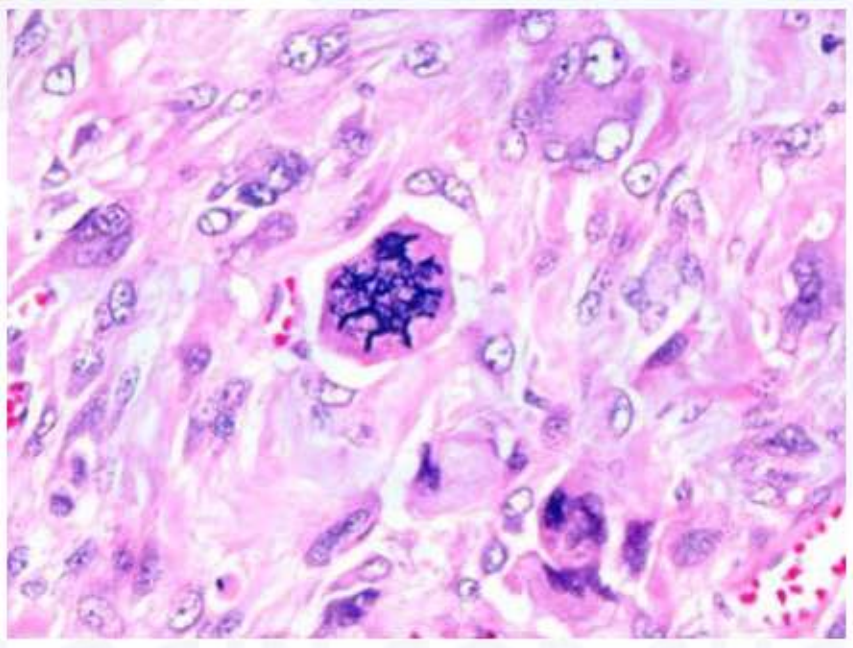

Fig: 5

Nephrogenic rests: 00:13:21

- Indicate remnants of embryonic counterparts
- If seen on histology of Wilms's tumor – Implies patient will develop contralateral Wilm's
- More the number of Blastemal cells – poorer the prognosis
  - ➢ Radiotherapy increases risk of leukaemia, lymphoma, soft tissue sarcoma

CASTS AND CRYSTALS IN URINE

1.Calcium oxalate crystals(mc)

- Envelop shaped(dihydrate)
- Acidic urine

Fig 1

AfraTafreeh.com

- Monohydrate crystals- dumbbell shaped

2.Calcium carbonate crystals

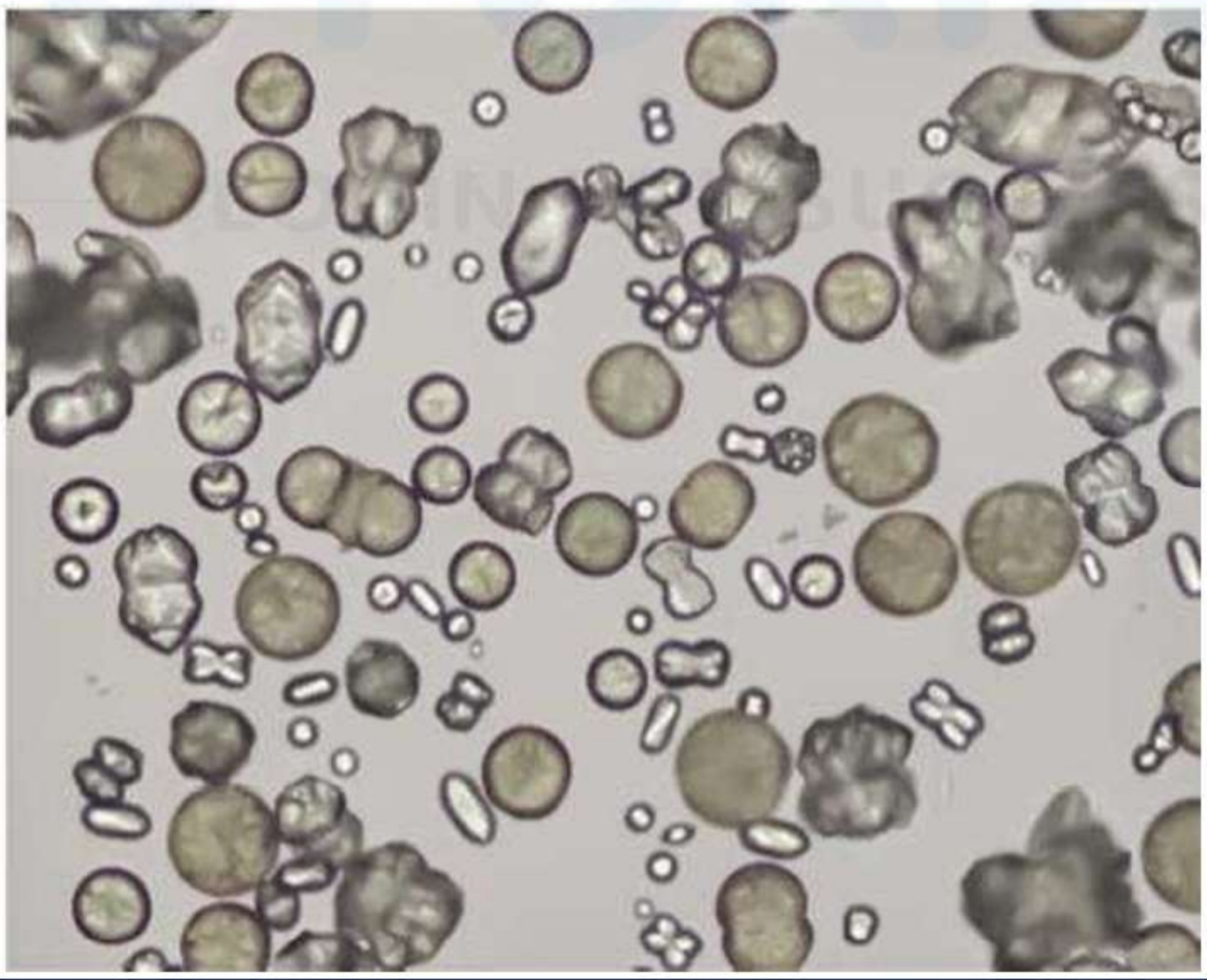

Fig: 2

- Spheres with radial striations
- Alkaline urine

AfraTafreeh.com

3.uric acid crystals



Fig 3

- Brown color , prism/ parallelogram shaped
- Acidic urine

4.Cysteine crystals

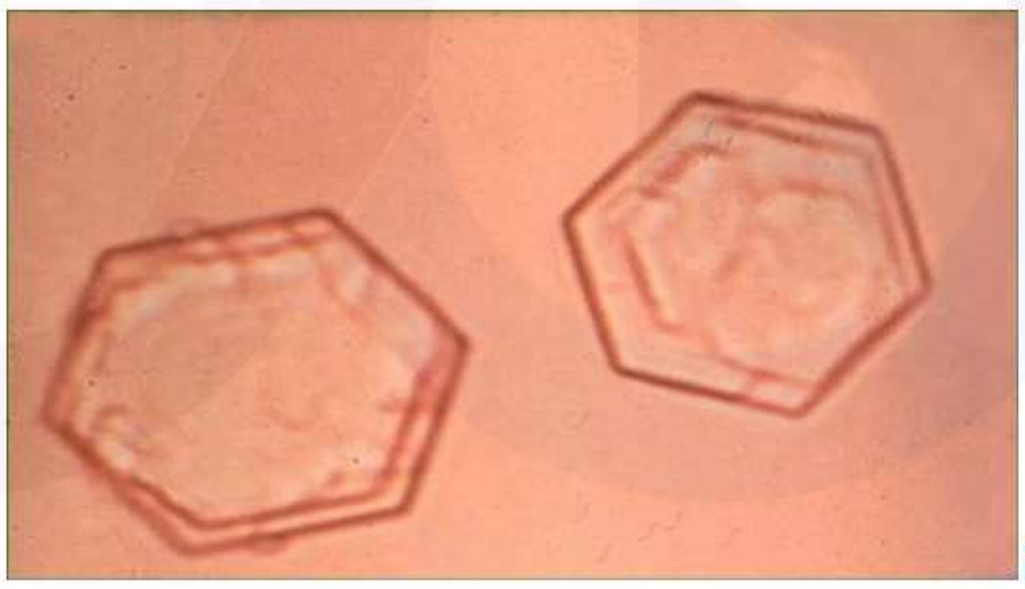

Fig 4

- Stop sign like shape
- Acidic urine

5.Struvite crystals

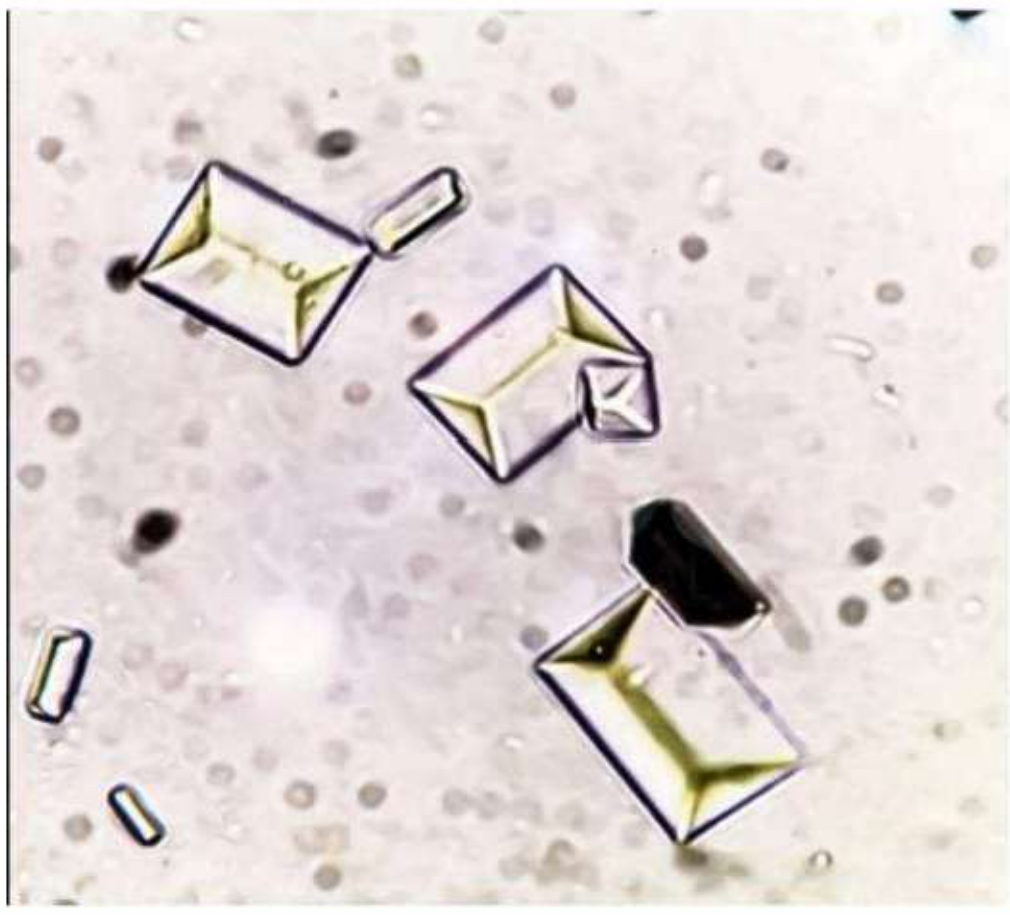

Fig 5

- Triple phosphate crystals
- Magnesium, ammonium and phosphate
- Alkaline urine
- Coffin lid appearance

6)

- <u>Ammonium Biurate</u> Crystals
- Apple thorn Crystals
- Seen in alkaline urine

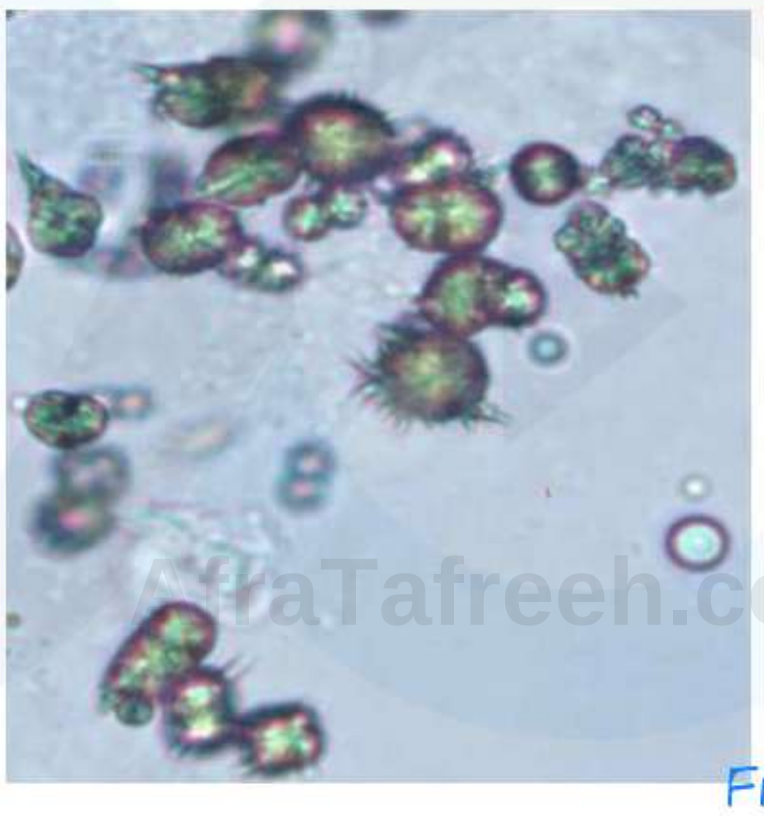

Fig 6

7)

- <u>Cholesterol Crystals</u>
- Colorless rectangular Plates
- Seen in patient of Nephrotic Syndrome

Fig 7

AfraTafreeh.com

8)

- Tyrosine Crystals
- Needle like crystals – colorless / yellow
- Acidic / Neutral urine
- Seen in FNAC of Parotid in Pleomorphic Adenoma

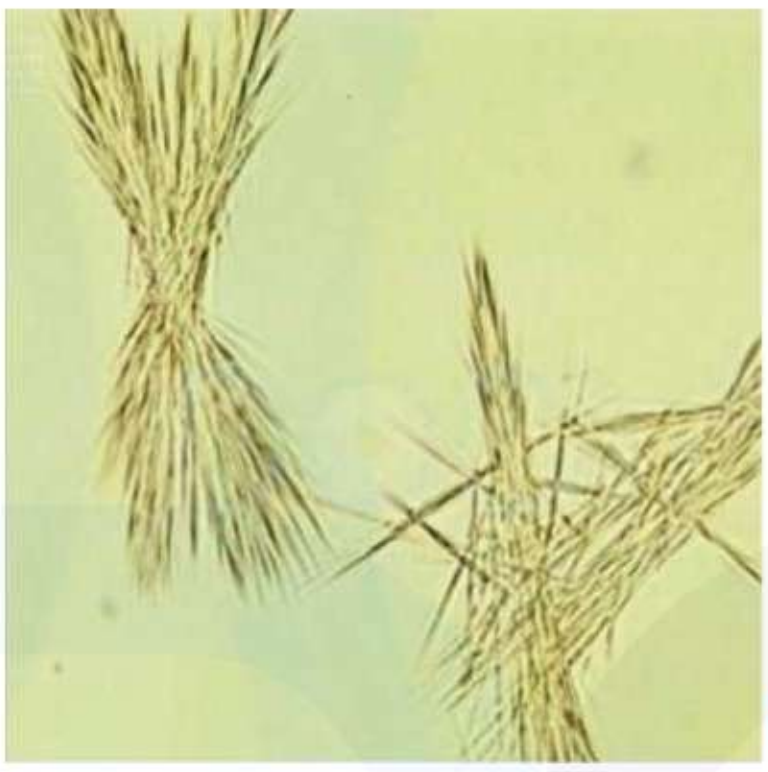

Fig 8

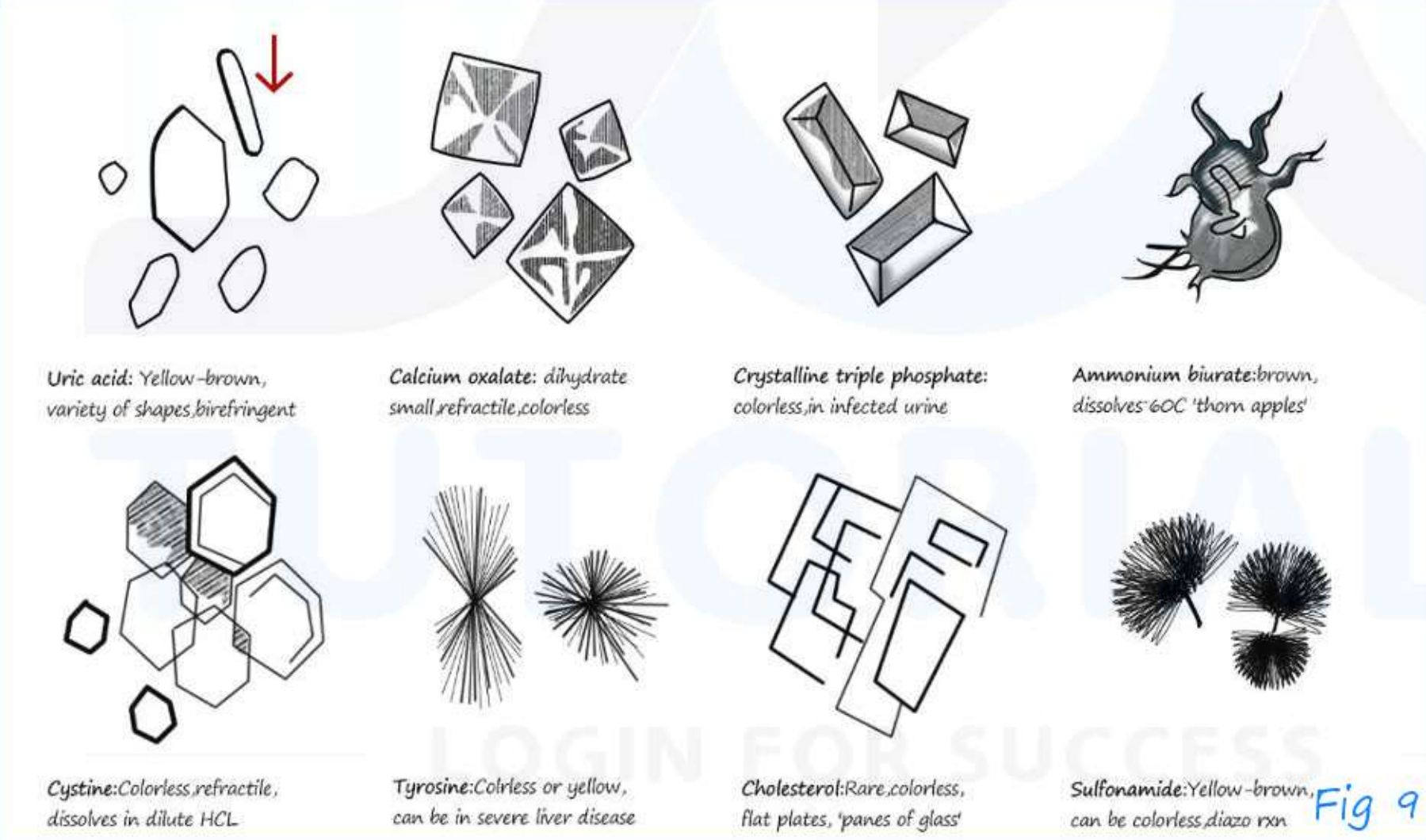

Fig 9

Casts In Urine 00:07:27

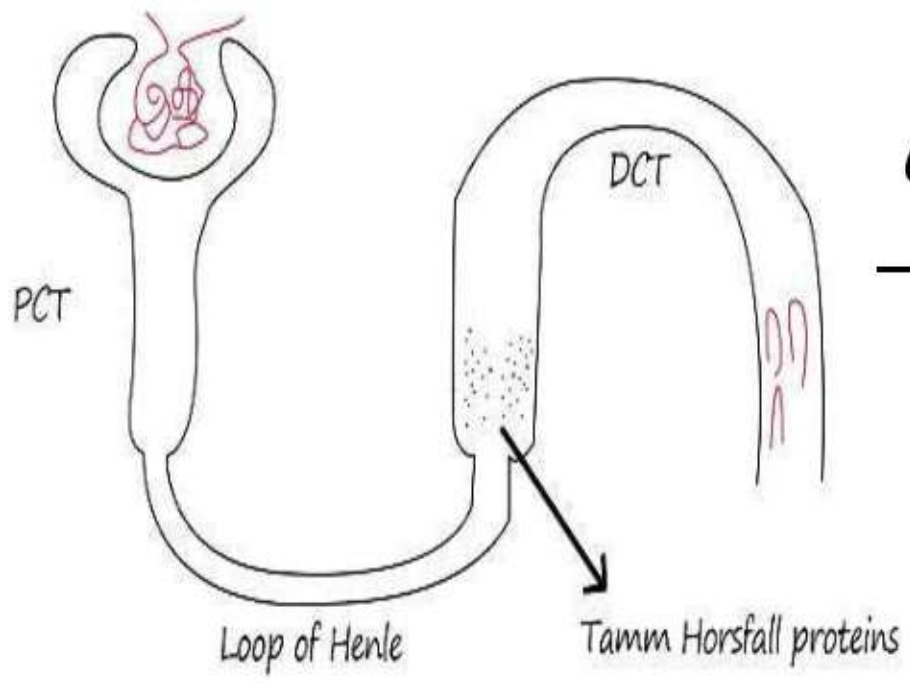

Collecting duct

→ Tubule shaped casts of Tomm Horsfall protein

Tamm Horsfall proteins in Ascending limb of loop of henle

- Excess proteins, lipids or cells filtered by the Glomeruli entrap with Tomm Horsfall Proteins and are excreted via urine as respective casts

Acellular casts	Cellular casts
i. Hyaline cast ii. Waxy cast iii.Fatty	i. RBC ii. WBC iii.Tubular cells

I. HYALINE CAST

- Benign cast / Transparent cast
  i. Composition – Proteins – tamm Horsfall Proteins with other proteins in Proteinuria
  ii. Cause
     a. Proteinuria
     b. Dehydration
- Microscope settings: condenser racked down; iris diaphragm closed

AfraTafreeh.com

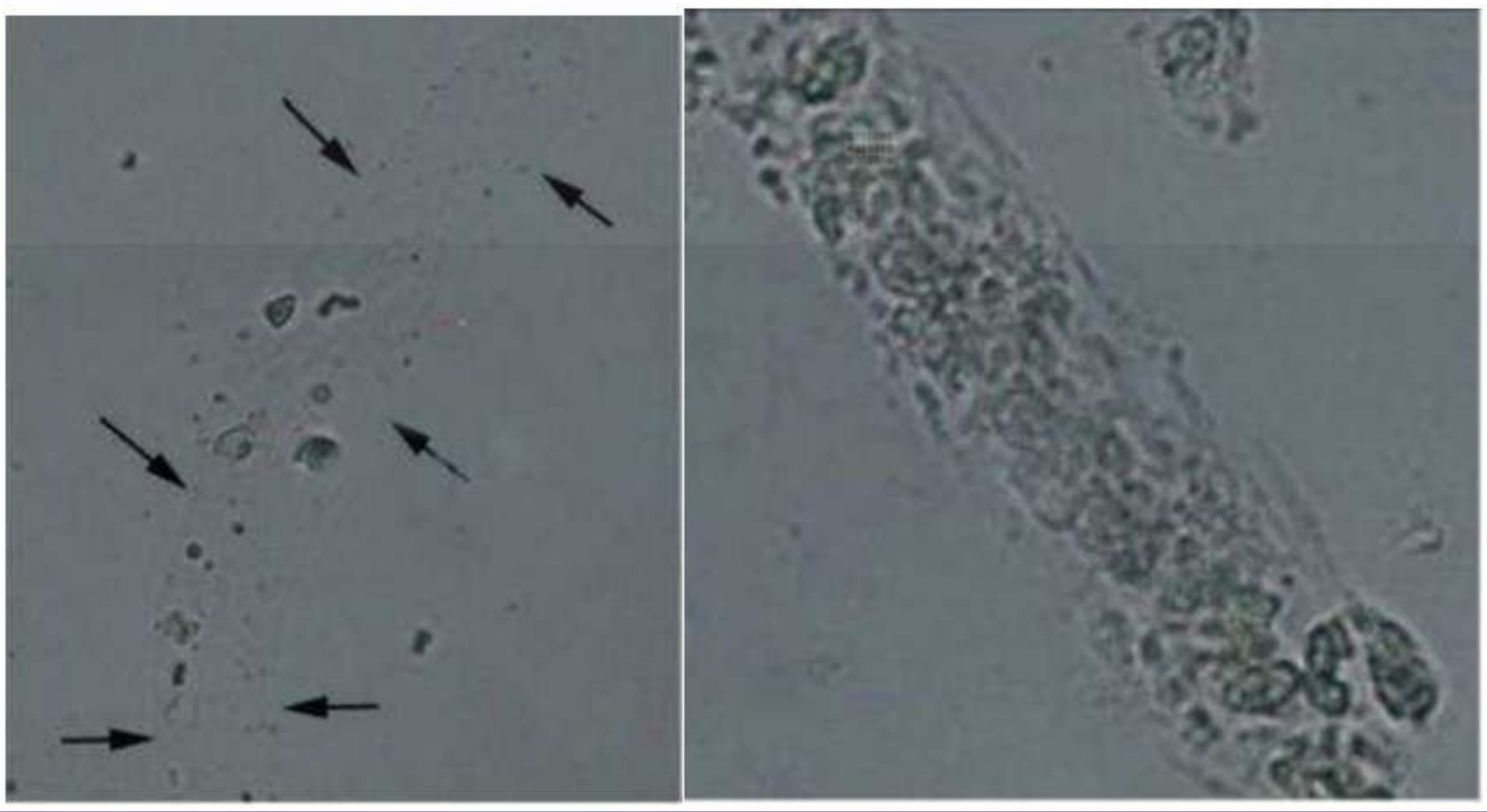

Fig 10

AfraTafreeh.com

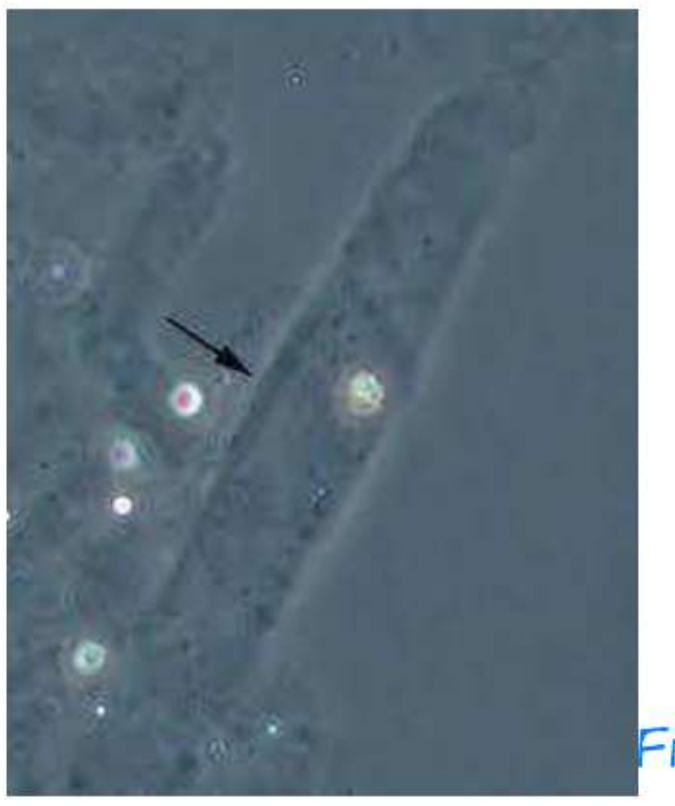

Fig 11

II. Casts In Acute Tubular Necrosis

i. CELLULAR CAST

a. Composition – Tubular epithelial cells entrapped with Tomm Horsfall Proteins

b. On Microscopy – Tubular cells with Central Nuclei seen

Fig 12

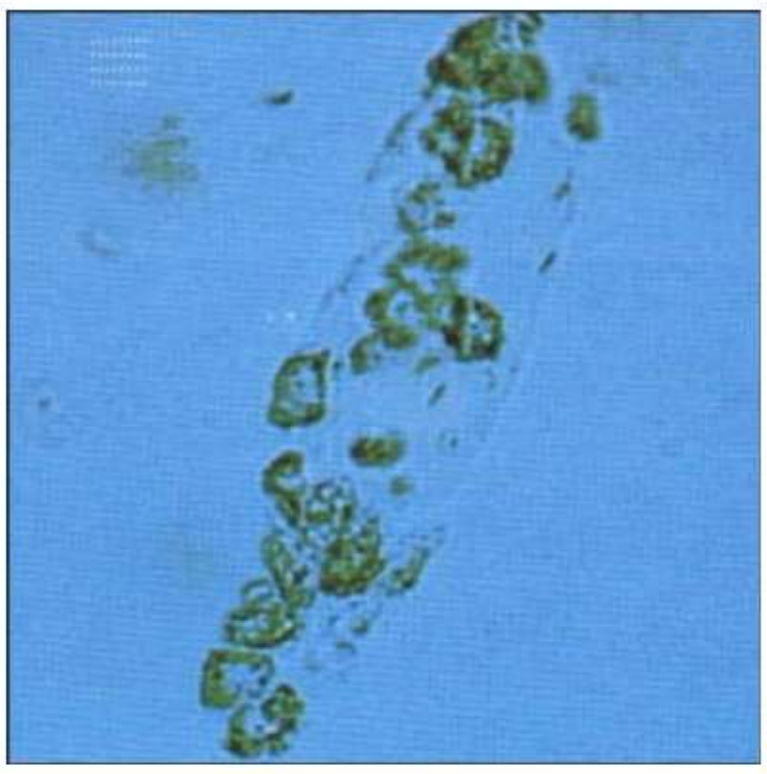

Fig 13

c. Cause

- Acute Tubular Necrosis (muddy brown cast)
- Tubular – interstitial disorders

ii. MUBBY BROWN CAST – seen in ATN

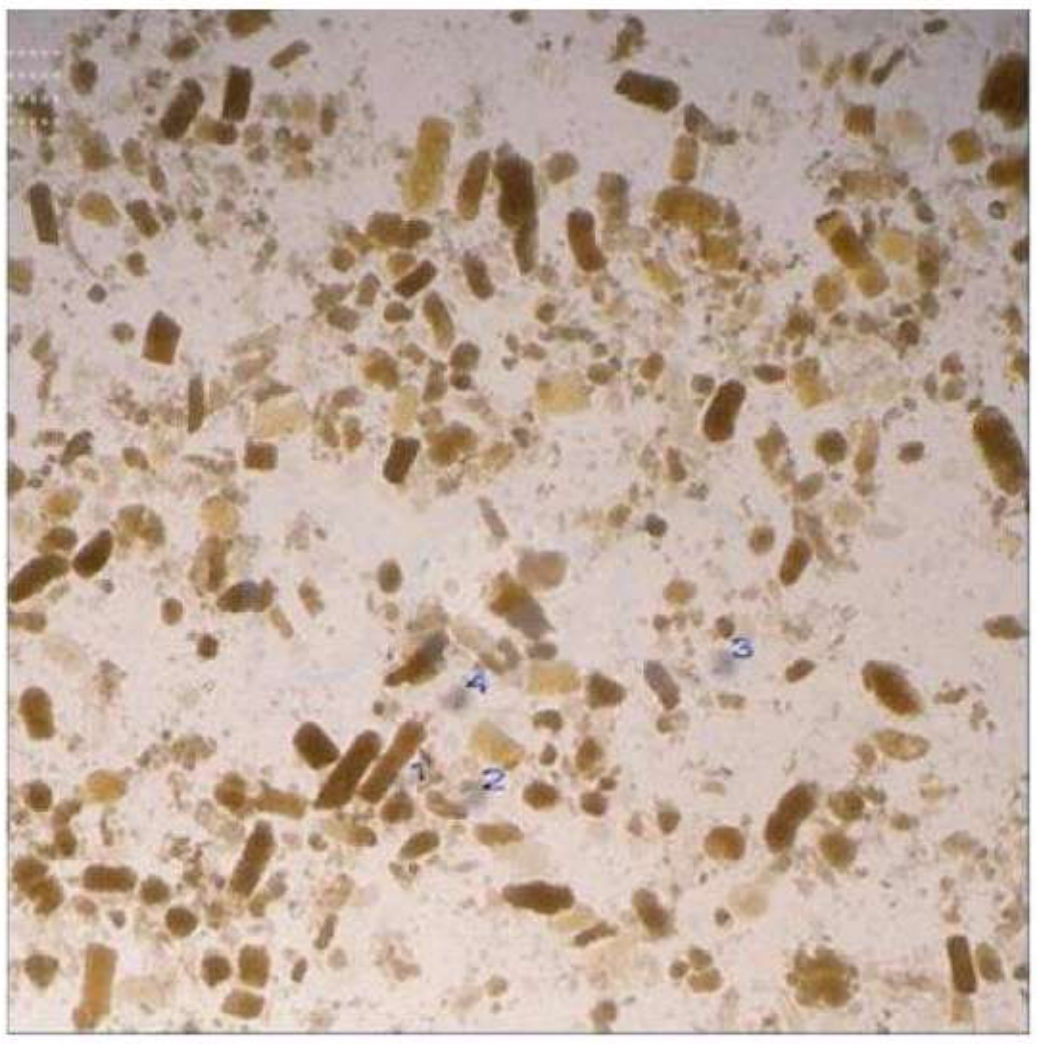

Fig 14

iii. GRANULAR CAST

- Degeneration of Cellular casts

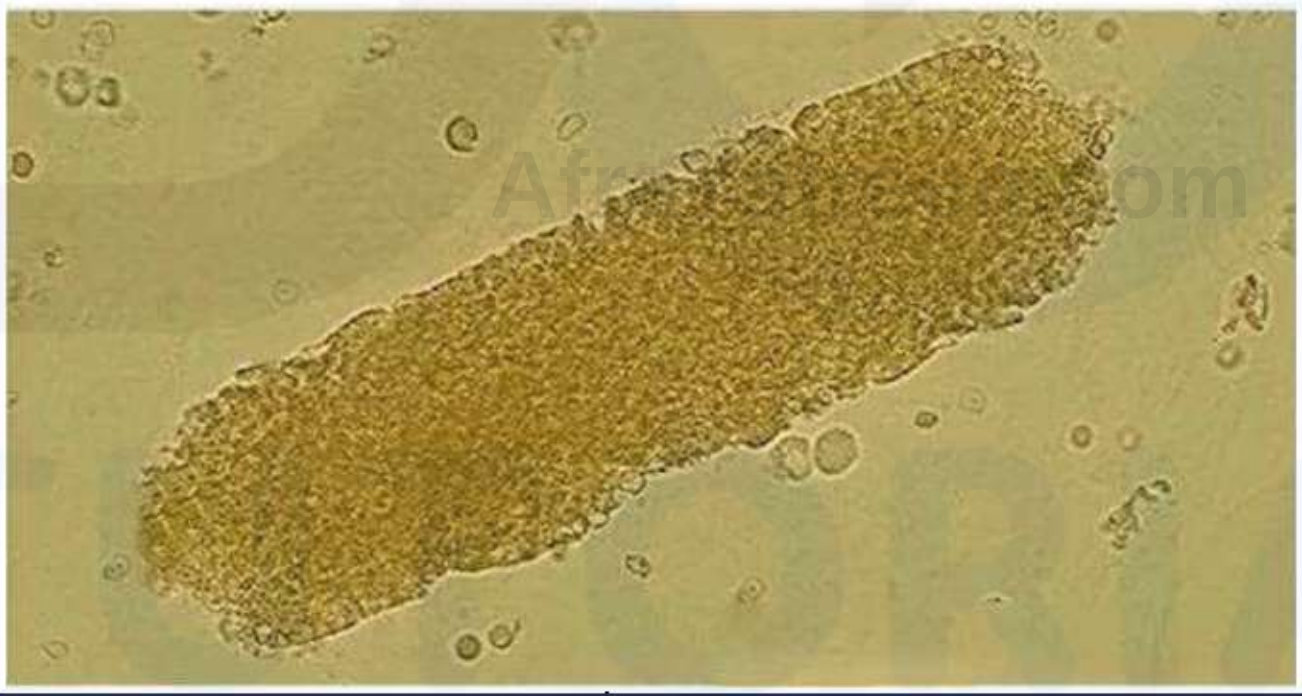

Fig 15

Fine cast
- After strenuous exercise

Coarse cast
- In tubular injury

- So Casts in Acute Tubular Necrosis
  a. Cellular cast
  b. Muddy Brown
  c. Cast Granular Cast

AfraTafreeh.com

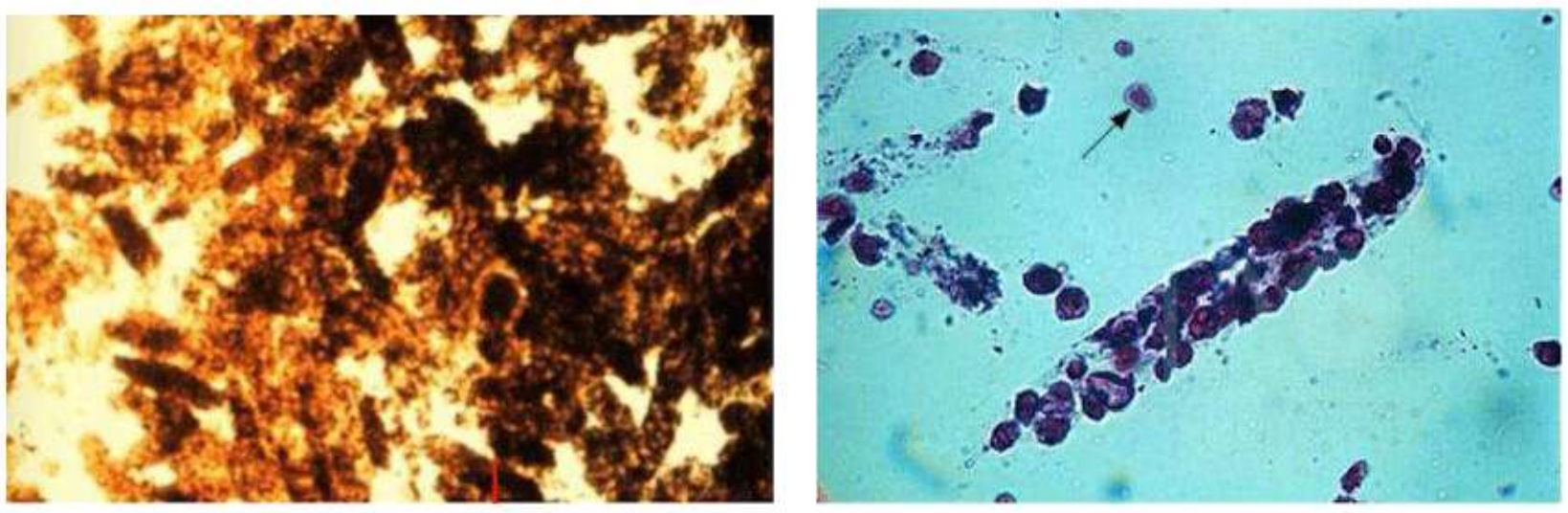

Muddy Brown Cast Cellular Cast Fig 16

III. Cast In Chronic Tubular Injury Or Chronic Renal Failure

i. WAXY CAST

- Final stage of cast degeneration of Granular and Cellular casts
- Compared to Hyaline Cast, they are readily Observable
  a. Smooth in appearance
  b. No internal texture
  c. More retractile than surrounding urine
- Seen in Chronic Tubular injury

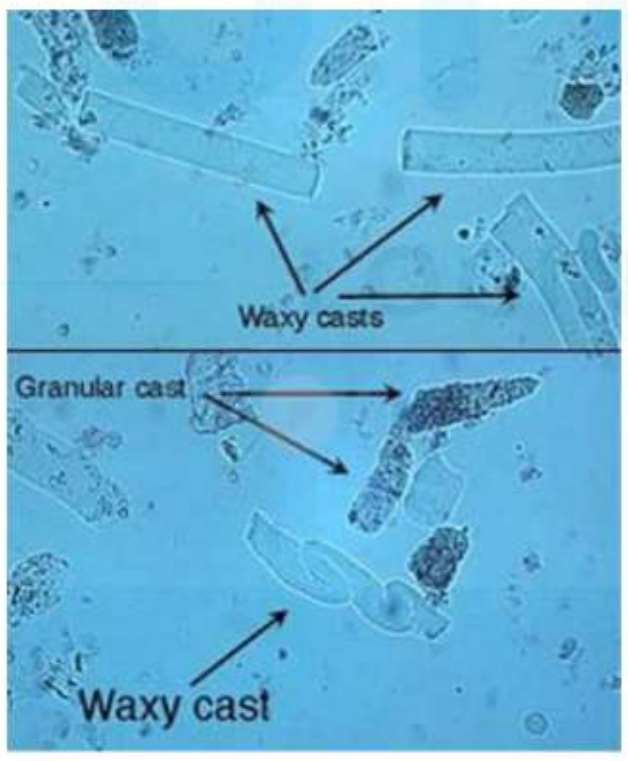

Fig 17

ii. BROAD WAXY CAST

- Interstitial fibrosis in Chronic Renal failure
- Cause widening of Tubules
- Casts to formed are Broad

- Interstitial fibrosis in Chronic Renal failure
- Cause widening of Tubular
- Casts to formed are Broad

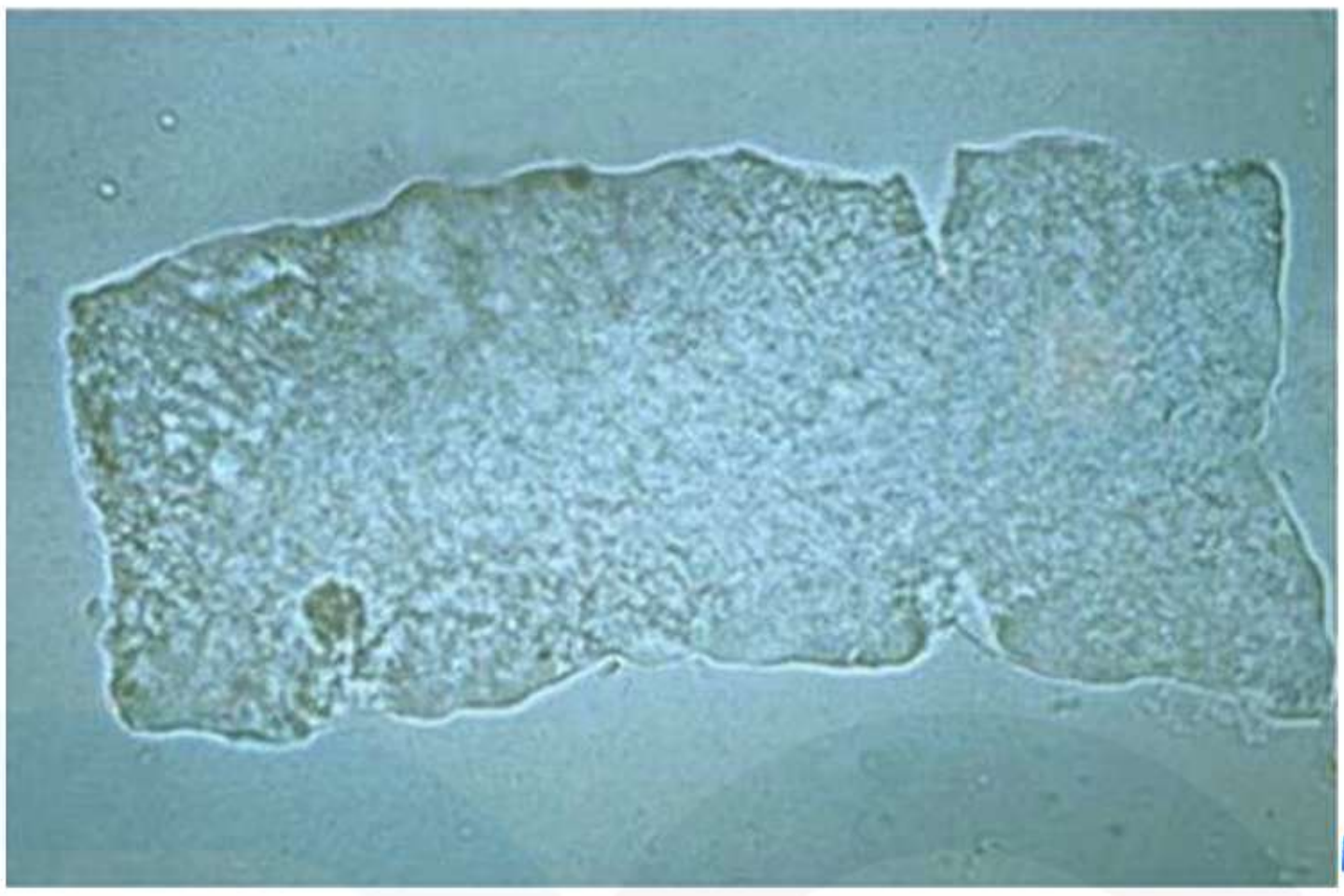

Fig 18

IV. WBC Casts

- Composition – WBC – Neutrophils
- Cause – Pyelonephritis

AfraTafreeh.com

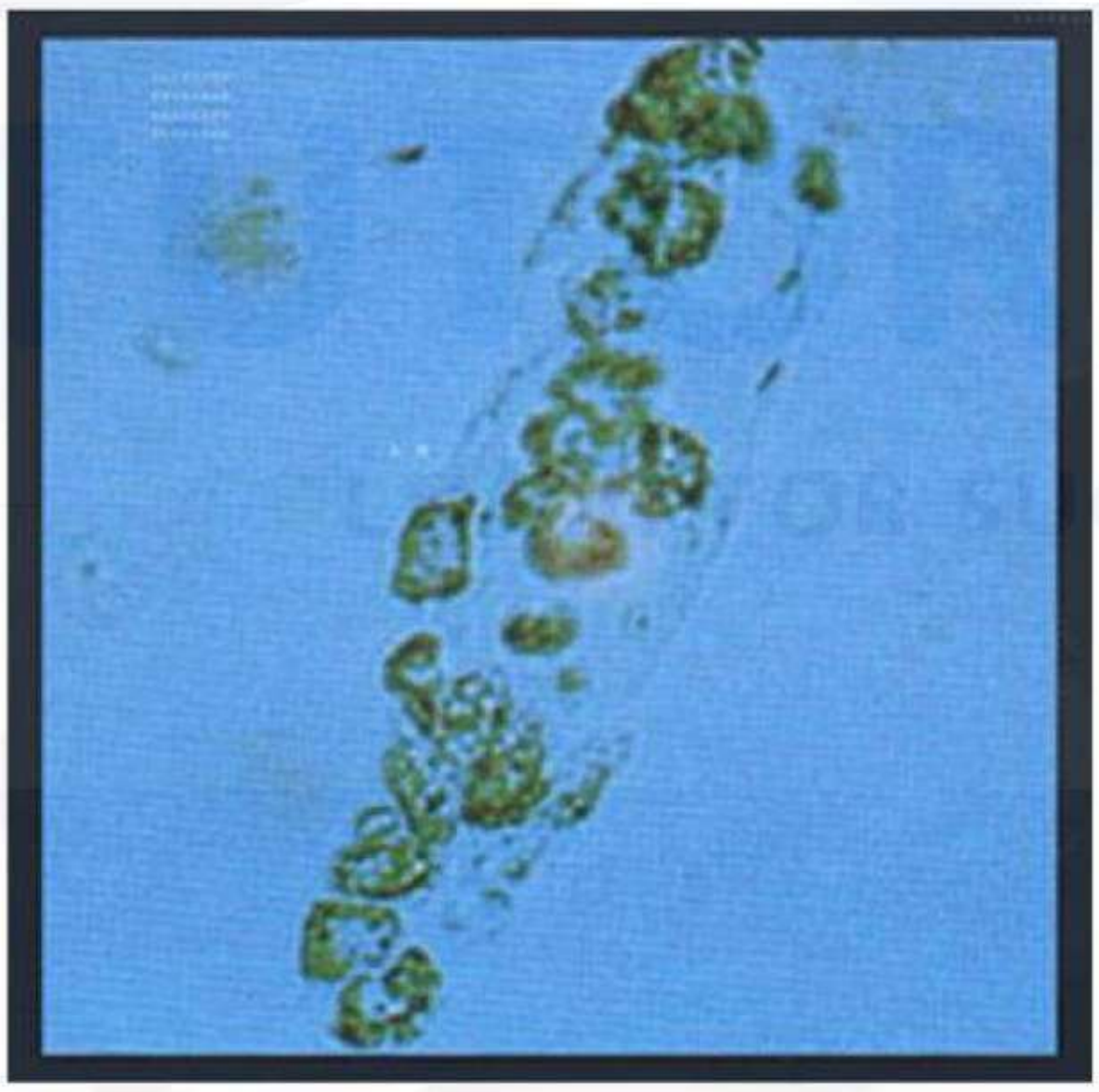

Fig 19

AfraTafreeh.com

V.RBC Casts

- Composition – RBC
- Cause – Glomerulonephritis

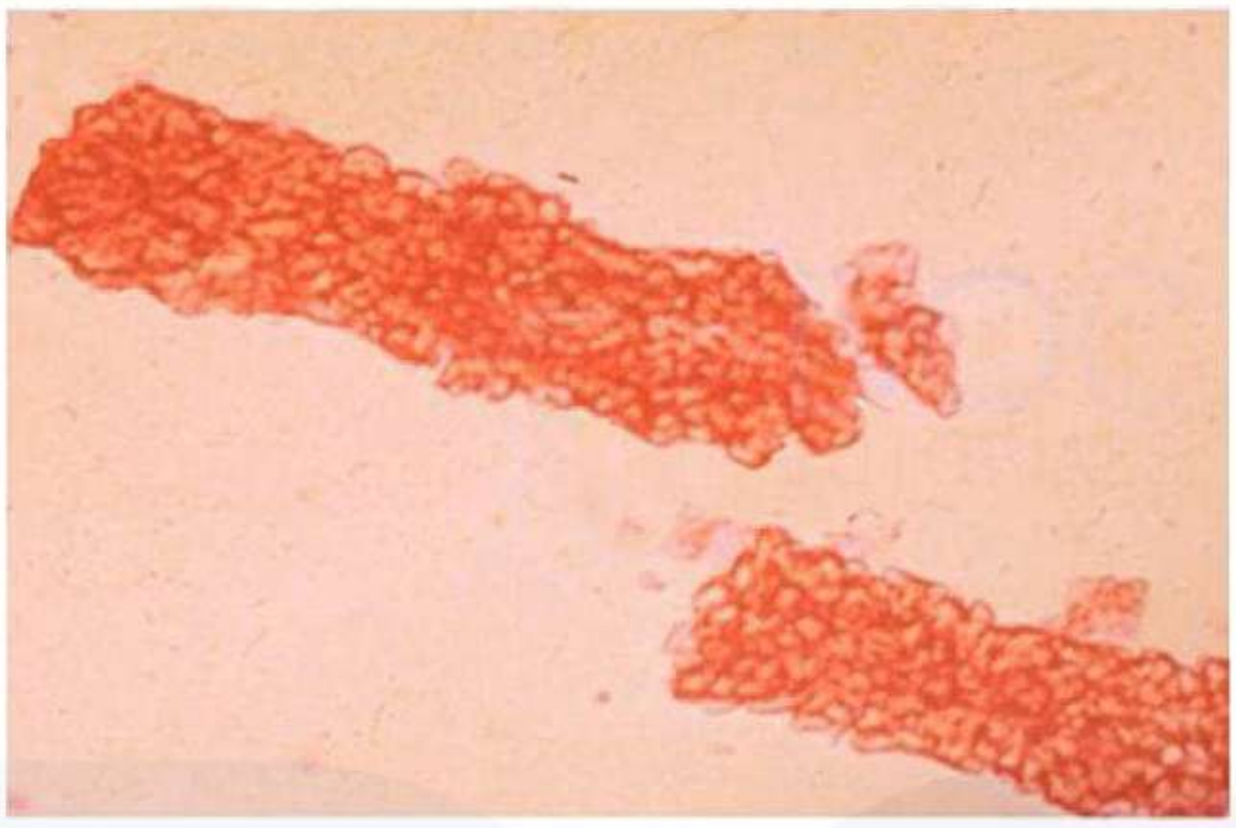

Fig 20

VI. Fatty Cast / Lipid Cast

- Composition – Cholesterol
- Cause – Lipiduria eg. In Nephrotic Syndrome

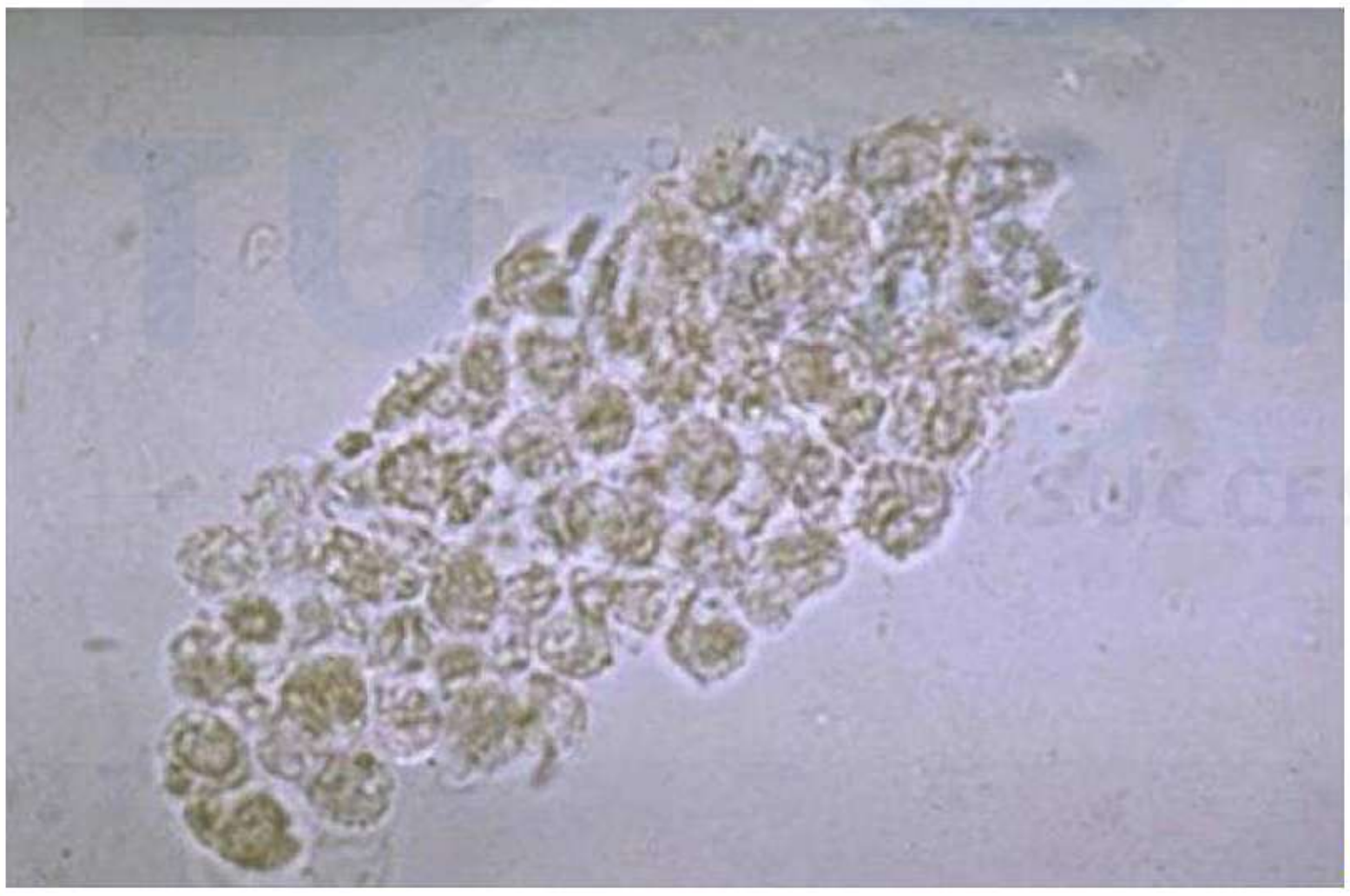

Fig 21

INTRODUCTION TO LIVER

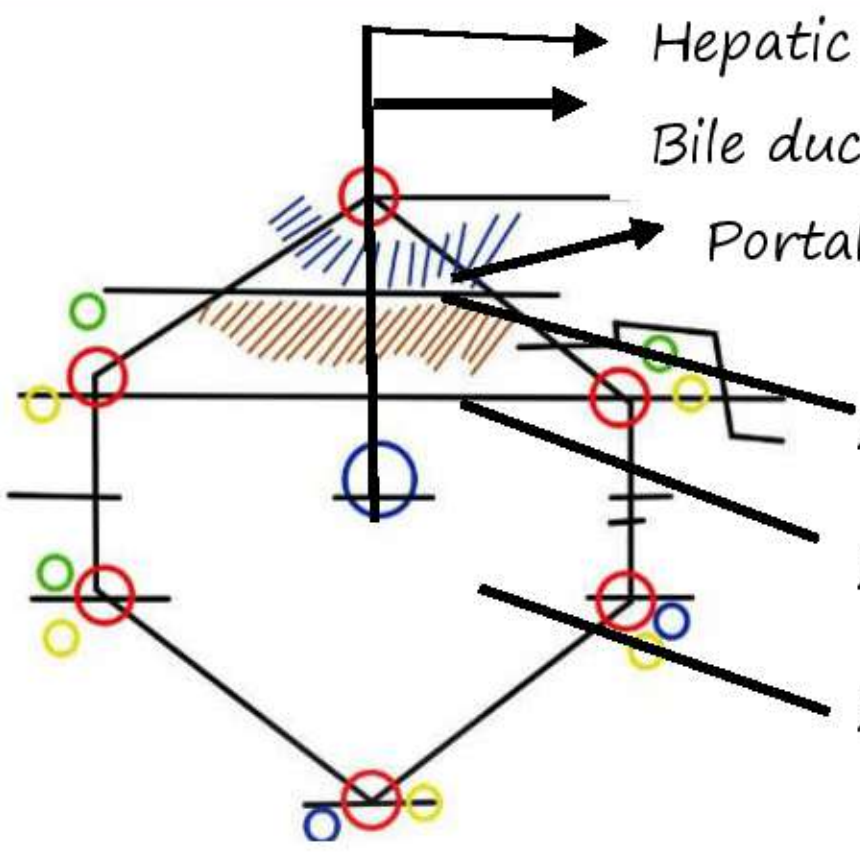

Fig: 1

- Most susceptible to ischemic/hypoxic damage in Zone 3 (less blood supply)
- Most susceptible to toxin induced damage is zone 3
- Toxicities – phosphate toxicity → zone 1
  - CCL4 toxicity } zone 3
  - Paracetamol toxicity } zone 3
- Nutmeg liver –Central venous congestion of liver most commonly seen in zone 3.

Fig: 2

- Eclampsia is most commonly seen in Zone 1
- Mid zonal area is affected by yellow fever.

AfraTafreeh.com

Microscopic view 00:08:26

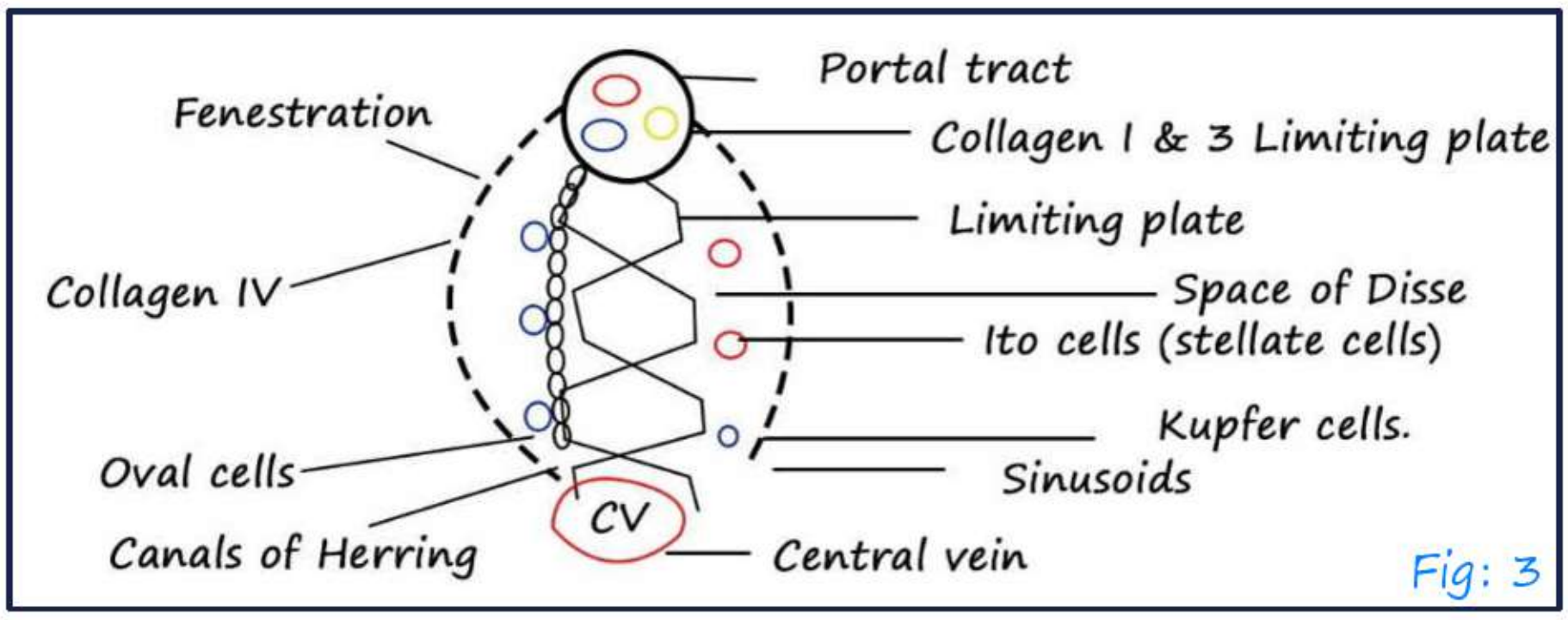

Fig: 3

- It is line up hepatocytes surrounding portal tract cords it contains collagen 1 & 3
- One cell (plate) thick in adults
- Two cells (plate) thick in newborns

Sinusoids in liver 00:09:48

- It decreases the pressure in hepatocytes
- It helps in uniform distribution of blood to all hepatocytes
- Sinusoids are spaces lined by endothelial cells having Fenestrations.
- The fenestrations are made of collagen IV.
- Collagen present around the portal tract is collagen 1 and 3 (non permeable collagen)

Space of Disse 00:14:49

- Potential cell between sinusoids and hepatocytes.
- It contains special cells called Ito cells (stellate cells)
- The Ito cells store vitamin A.
- Ito cells on stimulation

  Activate TGFβ &FGF which cause Fibrosis

Kupfer cells 00:17:06

- These are resident macrophages present in the liver lining the sinusoidal Walls.

Canals of Herring 00:18:16

- Tracts carrying Bile from central Vein to bile duct.
- They are lined by oval cells of liver which can give rise to Cholangiocytes and Hepatocytes
- Maker of canals of herring is CK7

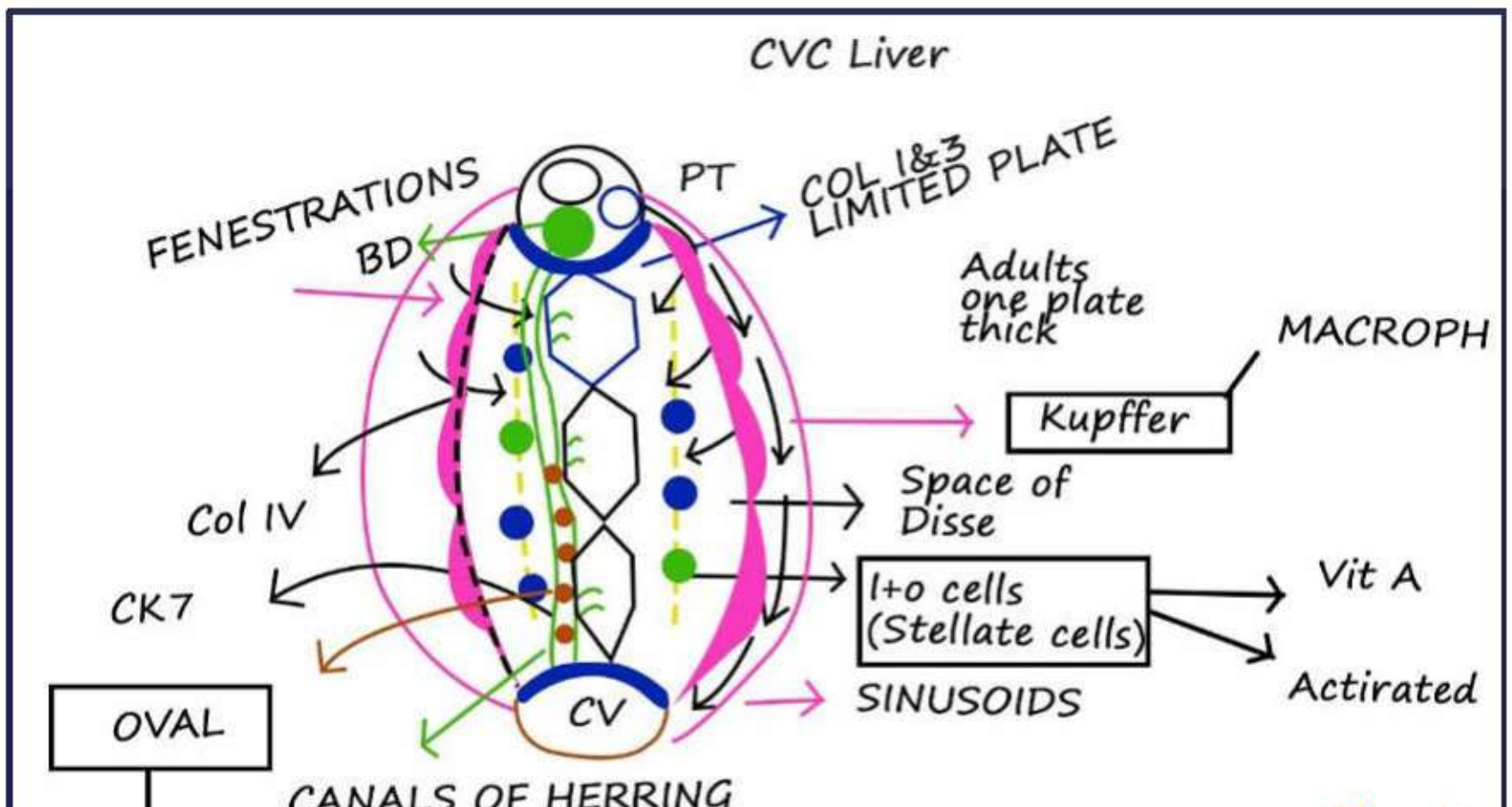

Fig: 4

AfraTafreeh.com

AfraTafreeh.com

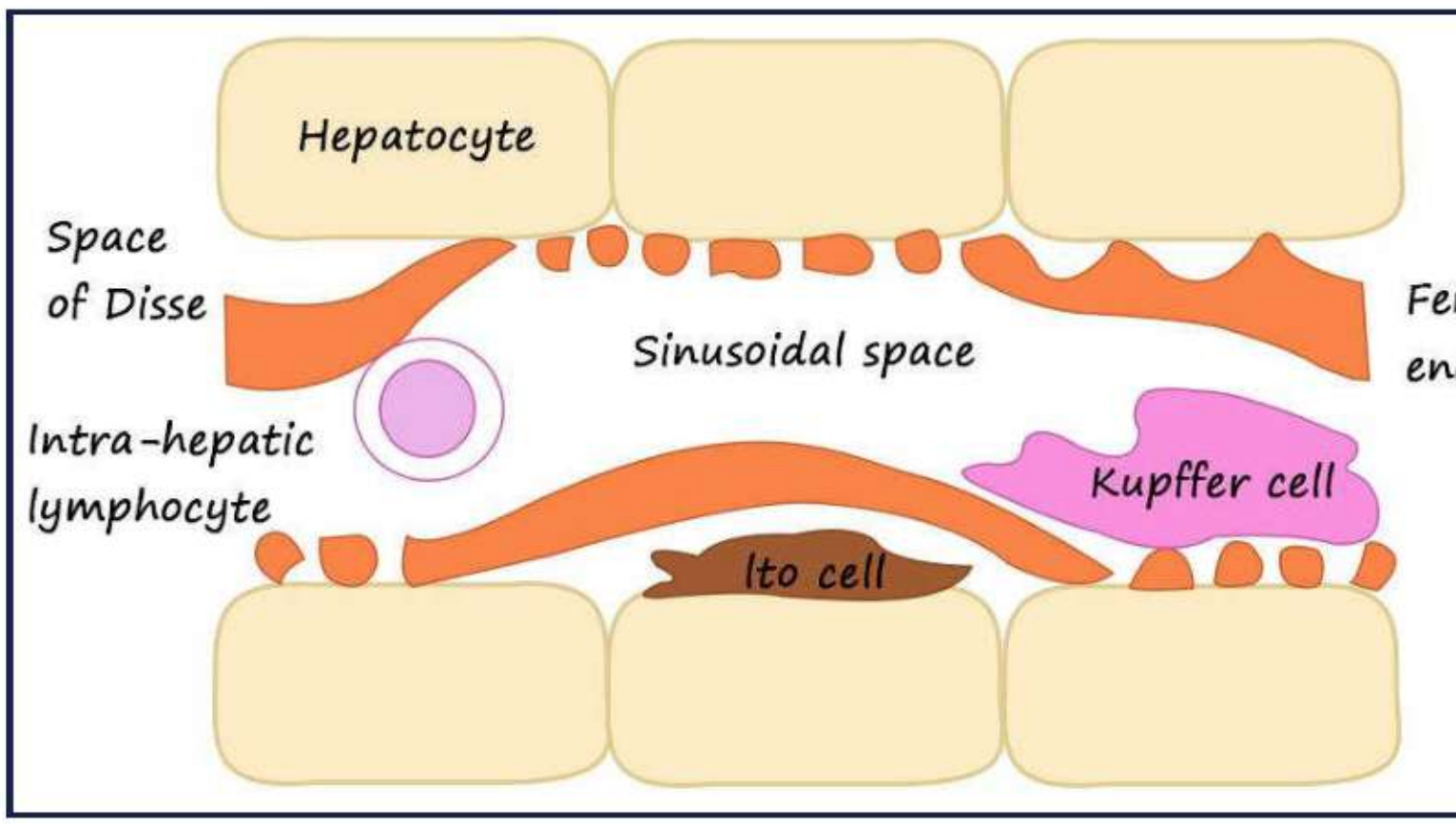

Fig: 5

TUTORIALS
LOGIN FOR SUCCESS

CLASSIFICATION OF HEPATITIS

Hepatitis

Inflammation of liver

Causes of Hepatitis

i. Viral
ii. Alcoholic
iii. Non Alcoholic steato Hepatitis (NASH)
iv. Autoimmune
v. Neonatal

Classification of viral hepatitis 00:01:56

Viral Hepatitis

i. HAV – Hepatitis A virus
ii. HBV – Hepatitis B virus
iii. HCV – Hepatitis C virus
iv. HDV – Hepatitis D virus
v. HEV – Hepatitis E virus
vi. HGV – Hepatitis G virus

- HGV – It is not Hepatotropic
  - it infects mononuclear cells of blood
  - It is a good virus
  - It transfers via Blood transfusion
  - It coinfects with HIV and protects against it.

AfraTafreeh.com

AfraTafreeh.com

i. HAV

- HAV most common cause of Acute viral hepatitis.
- It causes Acute viral Hepatitis
- It is most common cause of Hepatitis in children
- It has numerous plasma cells.
- It transmits by feco oral route

ii. Hepatitis E (H&V)

- It transmits by feco oral route.
- It is the most common Hepatitis is pregnancy associated with high morbidity.
- Most common acute hepatitis (sporadic/ epidemic in adults- Hepatitis E)
- cholestatic changes high.

iii. HCV –Hepatitis C virus

- There virus is highly mutable.
- It has high genomic instability
- It shows phenomenon of quasispecies
- Due to quasispecies and genomic instability which causes chronic hepatitis

iv. Hepatitis D virus (HDV)

- It is defective virus
- HBV +HDV → Coinfect

- When both viruses simultaneously coinfect a healthy Individual
- Co infection clears and rarely leads to chronicity expect in iv drug abusers where co infection leads to acute fulminate hepatitis.
- HBV ← HDV → superinfection HDV infection occur in an individual previously infection with HBV leads to chronicity and then to cirrhosis.
- Superinfection commonly leads to chronicity

v. Hepatitis B virus (HBV)

- It has 8 genotypes (A-H)
- In india D is most common, in east (adr), in north and south (ayw) is mc.
- It has double stranded DNA genome
- It is transmitted perinatal, parenteral and sexual contact
- Most common cause of viral hepatitis causing HCC (Hepatocellular carcinoma) is Hepatitis B.
- Most common cause g carious is Hepatitis B

AfraTafreeh.com
TUTORIALS
LOGIN FOR SUCCESS

<u>Viral Hepatitis</u>

- Most common acute viral Hepatitis (world/India)-Hepatitis A
- Most common acute viral hepatitis (world/ India) in children- Hepatitis A

AfraTafreeh.com

- Most common cause of chronic viral Hepatitis causing HCC (world/India) -Hepatitis C
- Most common viral hepatitis causing HCC (world/ India) – Hepatitis B.
- Most common cause of cirrhosis -Hepatitis C.
- Most common Hepatitis associated with transfusion -Hepatitis B.
- Most common cause for fulminate Hepatitis - Hepatitis D.

Classification of Hepatitis 00:15:01

Acute Hepatitis	Chronic
• Councilman Bodies • Eosinophilic/Acidophilic • Bodies-Apoptotic Bodies • Spotty necrosis • Kupffer cell Hyperplasia • Drop out Necrosis • Lobular Disarray • Mild cholestasis • Interface Hepatitis:	• Hallmark of chronic • hepatitis is fibrosis. • It is shown by Hepatitis B, • Hepatitis C and • Hepatitis D **<u>Hepatitis B virus</u>** • Ground Glass • Hepatocytes **<u>Hepatitis C virus</u>**

• Damage to limiting plate, it has poor Prognosis, It is a type acute hepatitis	• Lymphoid follicles are seen portal tracts. It causes Bile duct injury. • It leads to activation of oval cells causing Bile duct proliferation • Macro vesicular steatosis **<u>Hepatitis D virus</u>** • Micro vesicular Steatosis

For any chronic Hepatitis

i. Staging
   - On the basis of Fibrosis

ii. Grading
   - On the degree of inflammation & necrosis

AfraTafreeh.com
TUTORIALS
LOGIN FOR SUCCESS

Updates

- HBV
- S gene → codes for HBsAg
- Pre core gene → codes for HBeAg
- Cure → codes for HBcAg
- P gene → codes for DNA polymerase
- X gene → Trans activation of Host & viral genome leading to Hepatocellular carcinoma

AfraTafreeh.com

HbsAg

- First Antigen to arise in seen
- Ground glass Hepatocytes is due to accumulation of HbsAg
- H is stained by shikata orcein stain

HBeAg

- It is the marker of infectivity.

Anti HBc

- It is the first antibody found in serum, feature of acute phase.
- It is found in window period

Anti HBe

- Patient is not infective any more
- It is called seroconversion.

TUTORIALS
LOGIN FOR SUCCESS

Anti Hbs

- It appears after vaccination; person has developed immunity.

Pre core mutants

- It does not have HbeAg, hence, now to detect infectivity of potential DNA copes are counted, DNA copies >1000 meaning high infection

Surface Mutants

- HbsAg undergoes mutation at point 145
- It is common is health worker
- In these mutant Hbs antibody is unable to neutralize HbsAg

AfraTafreeh.com
TUTORIALS
LOGIN FOR SUCCESS

AfraTafreeh.com

ALCOHOLIC LIVER DISEASE

Alcoholic Liver Disease 00:00:30

- 3 phases seen in Alcoholic Liver Diseases
- Phase I – Fatty live
- Phase II – Alcoholic Hepatitis
- Phase III – Steatohepatitis
- Final stage - cirrhosis

I. Fatty change. 00:01:23

- Alcoholic liver diseases can show micro and macro vesicular steatosis
- It is a reversible change

II. Alcoholic Hepatitis 00:01:44

- Ballooning of Hepatocytes is a reversible change which progresses to irreversible damage leading to necrosis.
- Neutrophilic statellitosis – Neutrophils aggregates are formed in the hepatic lobules which phagocyte the dead Hepatocytes.
- Mallory Denk Bodies
- There are Bodies found within hepatocytes made of misfolded proteins CK8 & CK18 +u
- Mallory Denk bodies are in Alcoholic liver disease, NASH, Indian child cirrhosis, alpha1 AT deficiency.
- Mallory Denk bodies are not seen in secondary Biliary cirrhosis

- Alcohol having a toxin maximum injury occur in Centrilobular area

Alcoholic hepatitis	Viral hepatitis
• Centrilobular area involved • Necrosis + Apoptosis • Neutrophil cells are main • Mallory denk bodies seen predominantly • Lennecs cirrhosis	• Periportal area involved • Necrosis • Kupfer cells are main • Not so predominant • Postnecrotic cirrhosis

- Tests for Alcoholic Hepatitis

  i. AST > ALT

  ii. GGT ↑↑ (gamma Glutamyl transferase)

AfraTafreeh.com

III. Steatohepatitis. 00:11:20

- Central Venous sclerosis– peri sinusoidal
- Chicken wire Fibrosis → When the area a fibrosis starts enhancing the hepatocytes
- This progress to Laennec cirrhosis
- Laennec's Cirrhosis is a special type of cirrhosis seen in Alcohol liver disease
- Laennec's Cirrhosis is micro nodular cirrhosis and post necrotic cirrhosis is macro nodular Cirrhosis
- Stain used to detect chicken wire fibrosis is Masson trichome stain
- Electron Microscopy of Alcoholic liver diseases
- Mega Mitochondria are seen

AfraTafreeh.com

NAFLD

- Non-Alcoholic Fatty liver diseases
- Non-Alcoholic steatohepatitis (NASH)
- Non-Alcoholic consumption of Alcohol less than 20g of Alcohol per week morphological clinical presentation of NAFLD

i. Fatty change

ii. NASH

iii. Fatty change with mild inflammation

NASH 00:02:39

- Pathogenesis –Two hit theory
  - Insulin Resistance develops in individuals with unhealthy diet and poor exercise, most commonly patient suffering from metabolic syndrome
  - Free Radical injury accumulate in there individuals of Metabolic syndrome
  - Insulin Resistance leads to steatosis which causes Apoptosis and Necrosis due to free radical injury.
  - TNF alpha and **IL-6** are activated which stimulate Kupffer cells which activate ito cells causing cirrhosis

> - *Hedgehog pathway*
> - *It is found that Fibrosis correlates with Hedgehog pathway*

- Cryptogenic cirrhosis

- Most common cause is NASH

- NASH –Most common chronic liver disease of the west
- Most common cause of death is NASH –cardiovascular complication

IL-6 levels are increased in
i. Amyloidosis
ii. Myeloma
iii. NASH

Triad of NASH 00:02:00

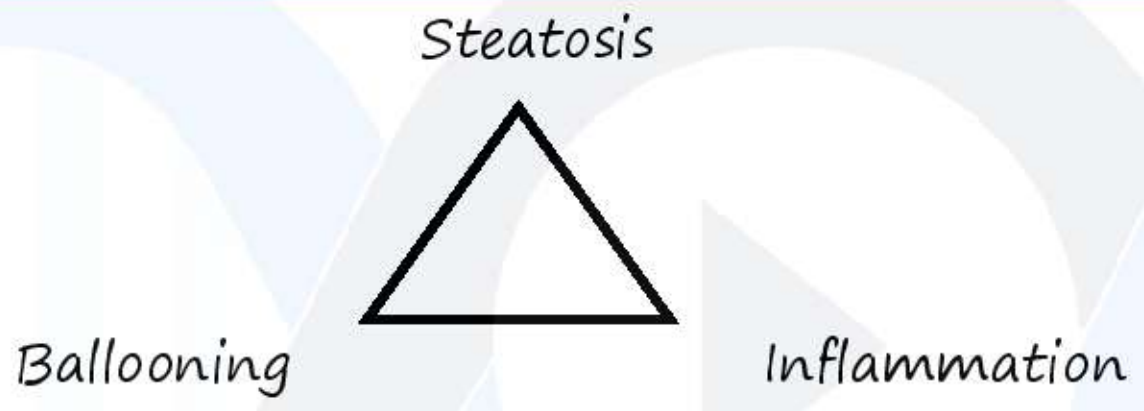

Criteria of NASH

AfraTafreeh.com

i. 5 % of Hepatocytes should undergo steatosis

ii. Inflammation should have predominant mononuclear cells.

TUTORIALS
LOGIN FOR SUCCESS

Pediatric NASH

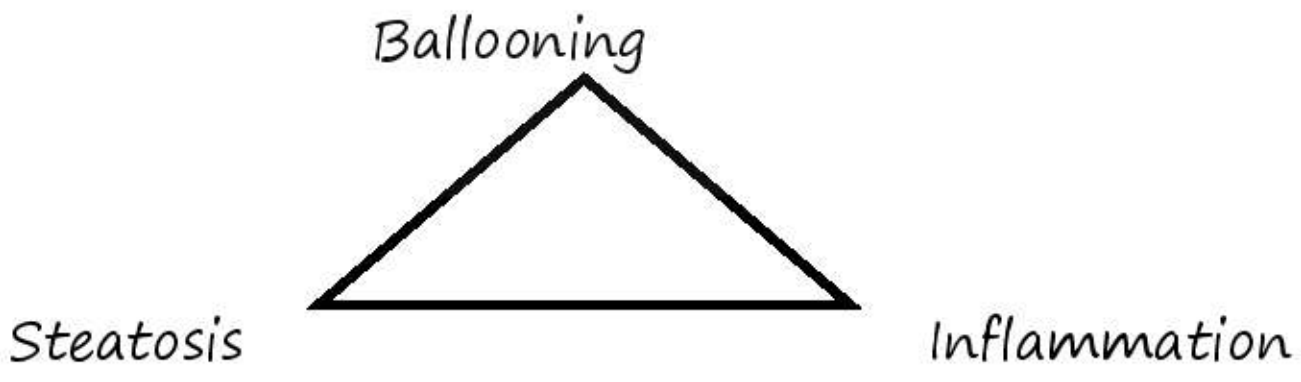

Criteria

i. Diffuse steatosis.

ii. Mononuclear cells are more predominant than adult NASH.

iii. Mallory Denk Bodies are less

- Most common acquired metabolic syndrome – NAFLD.

AfraTafreeh.com

AUTOIMMUNE HEPATITIS

Classification

Type I Type II Type III

Type I Autoimmune Hepatitis 00:00:50

Antibodies

- ANA (most common)
- Anti Mitochondrial Ab's
- Anti SMA (Smooth Muscle antigen)
- Anti SLA /LP-1(Soluble Liver antigen)

Type II

- Anti LKM-1 (Liver Kidney Microsomal) (most Common)
- Anti LC-1

TUTORIALS LOGIN FOR SUCCESS

Type III

- Anti SLA/LP1
- Also Classified as Type I Autoimmune Hepatitis
- Type I – More Common in Adults, females are more affected.
- Type II – More common in Children, relapses are common.

Microsomal Feature/Morphological Feature

00:04:38

- Periportal necrosis leads to confluent necrosis (Burnt out Cirrhosis)
- Infiltration of Plasma cells – Produce excessive IgG Antibodies
- Hepatic Rosettes are formed
- Entosis occur (Hepatocytes kill T Lymphocytes)
- CD4 T cells activate plasma cells hence main culprit
- They respond with steriods.
- Burnt out Cirrhosis – Autoimmune Hepatitis
  - Non Alcoholic Fatty Liver Disease – cryptogenic cirrhosis

AfraTafreeh.com

TUTORIALS

LOGIN FOR SUCCESS

AfraTafreeh.com

BASICS OF RESPIRATORY SYSTEM ALVEOLI & BRONCHI WITH IMAGES

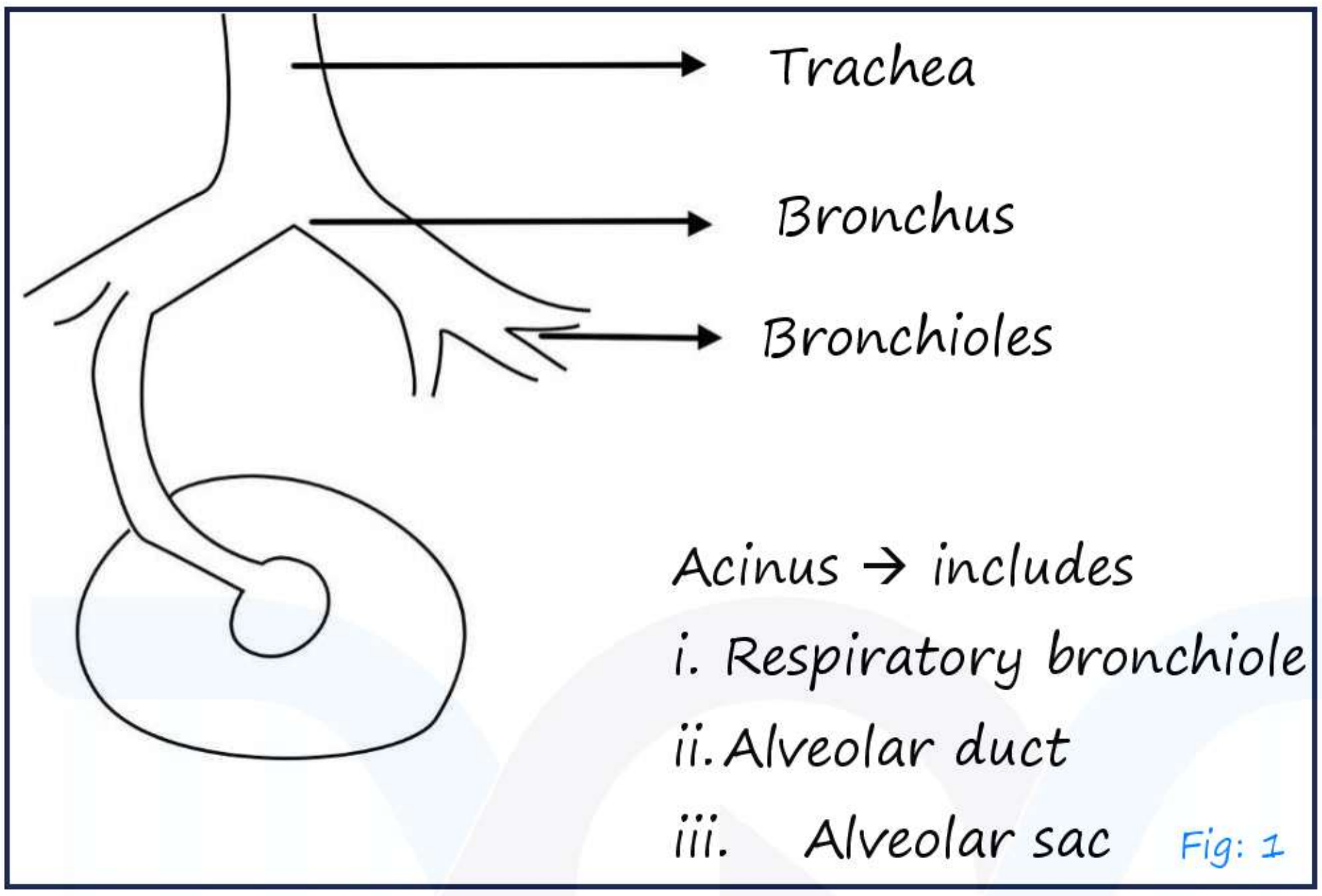

Fig: 1

- Terminal bronchiole + acinus = respiratory lobule
- Respiratory epithelium -> pseudostratified ciliated columnar epithelium
- Alveoli -> lined in squamoid Flattened cells type I pneumocytes

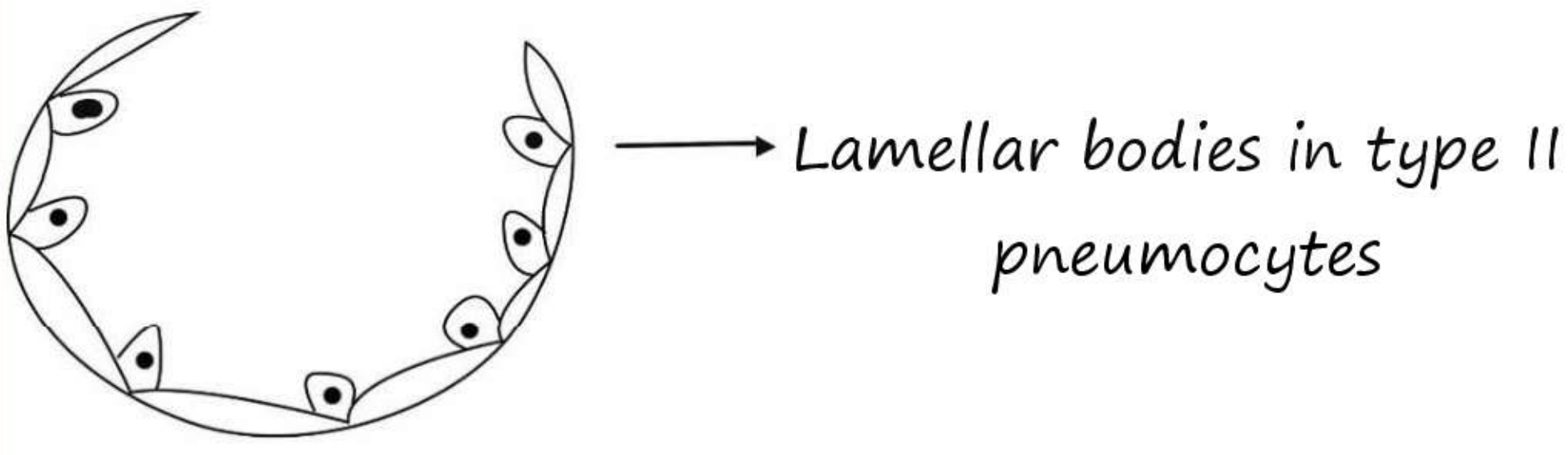

Fig: 2

- In between type I pneumocytes there are cuboidal cells called type II pneumocytes

- Function of type I pneumocytes should be well formed for surfactant production

Difference between bronchi and bronchioles

- Cartilage is present only till trachea and bronchi and not in bronchioles
- Goblet cells are present majorly in larger airways like trachea &bronchi their number decreases in bronchioles
- Goblet cell help in proper beating of cilia
- Neuroendocrine cells of lungs – Kulchitsky cells are present in trachea & bronchus. Therefore, NET of lung occur in bronchus

AfraTafreeh.com

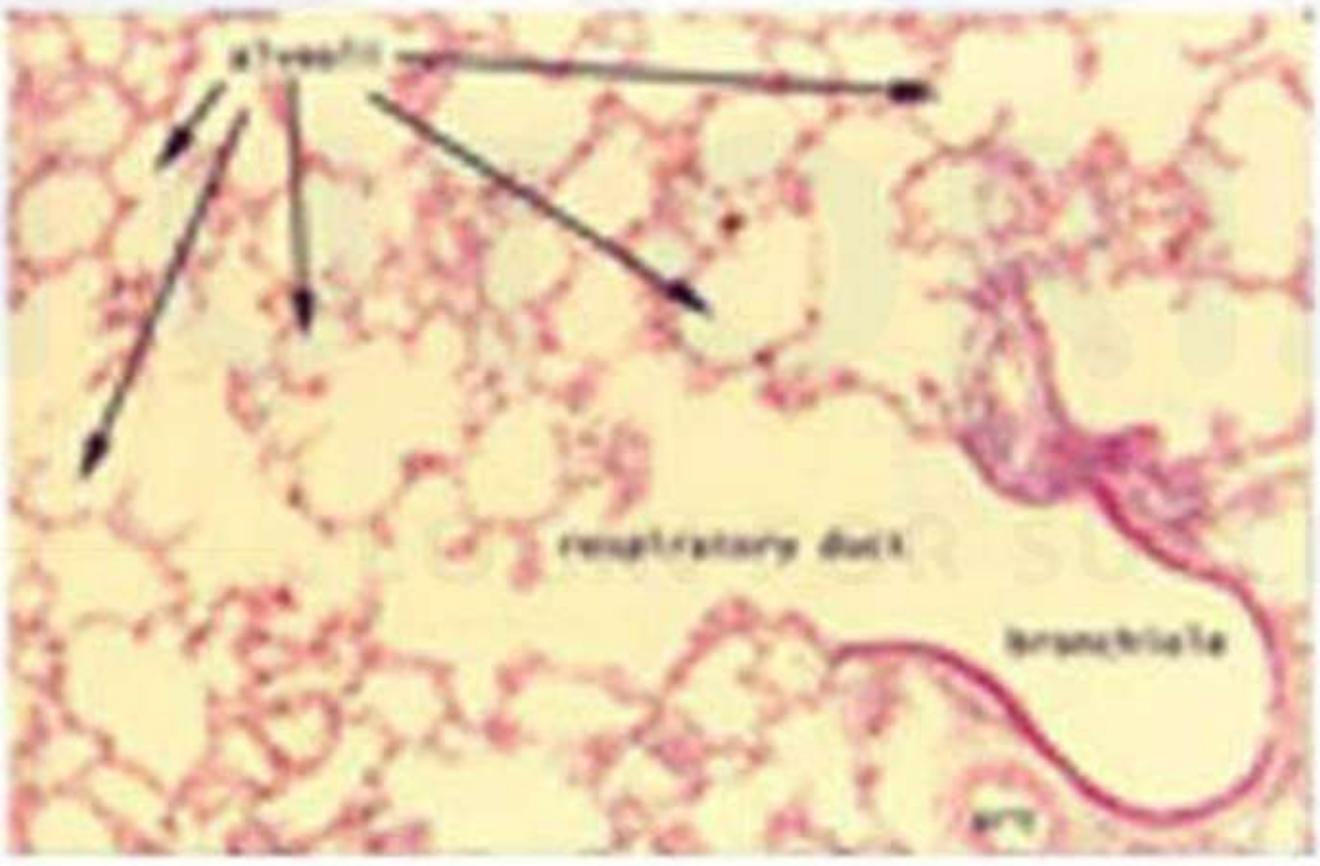

Fig: 3

AfraTafreeh.com

Acinus

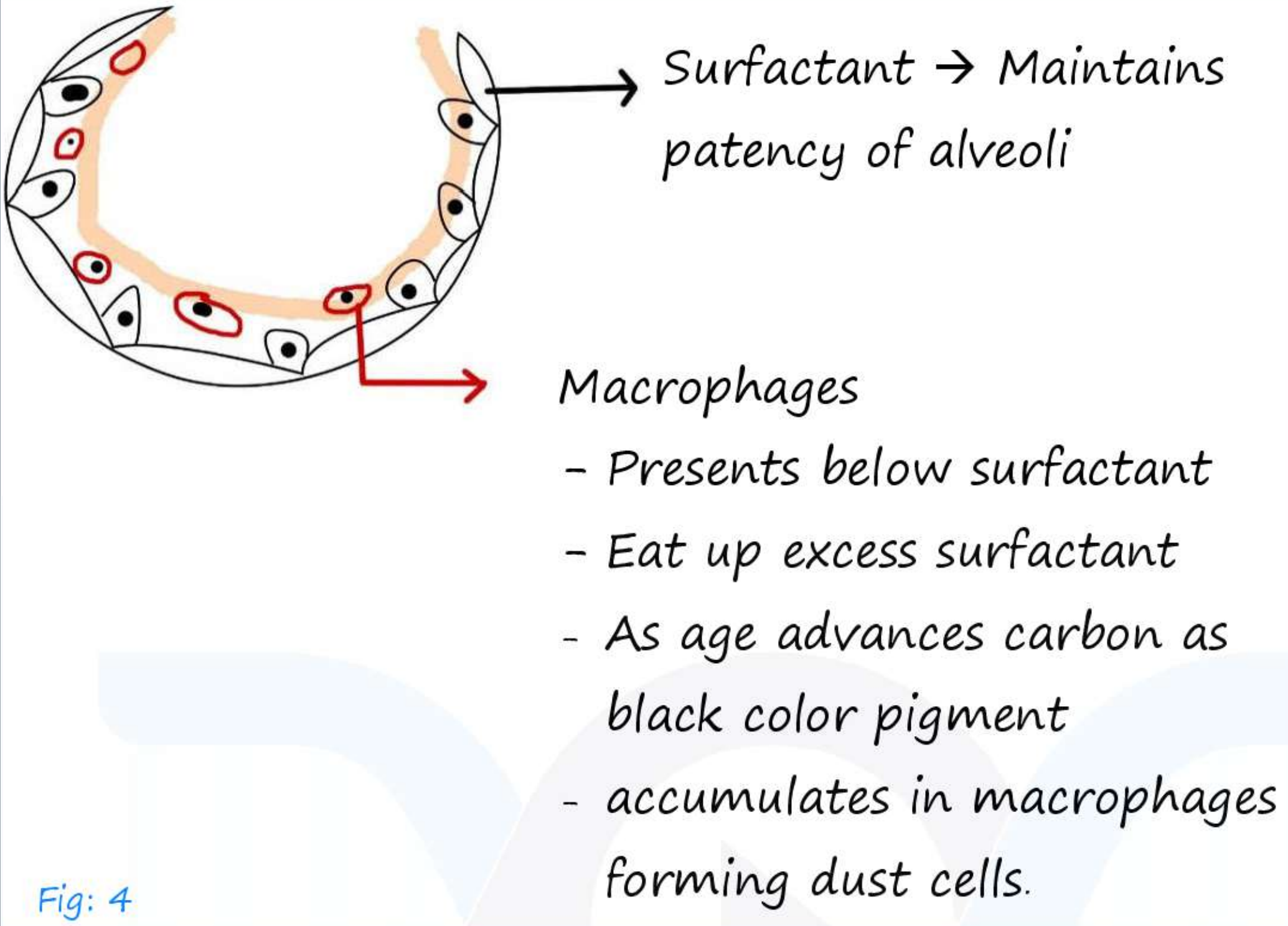

Fig: 4

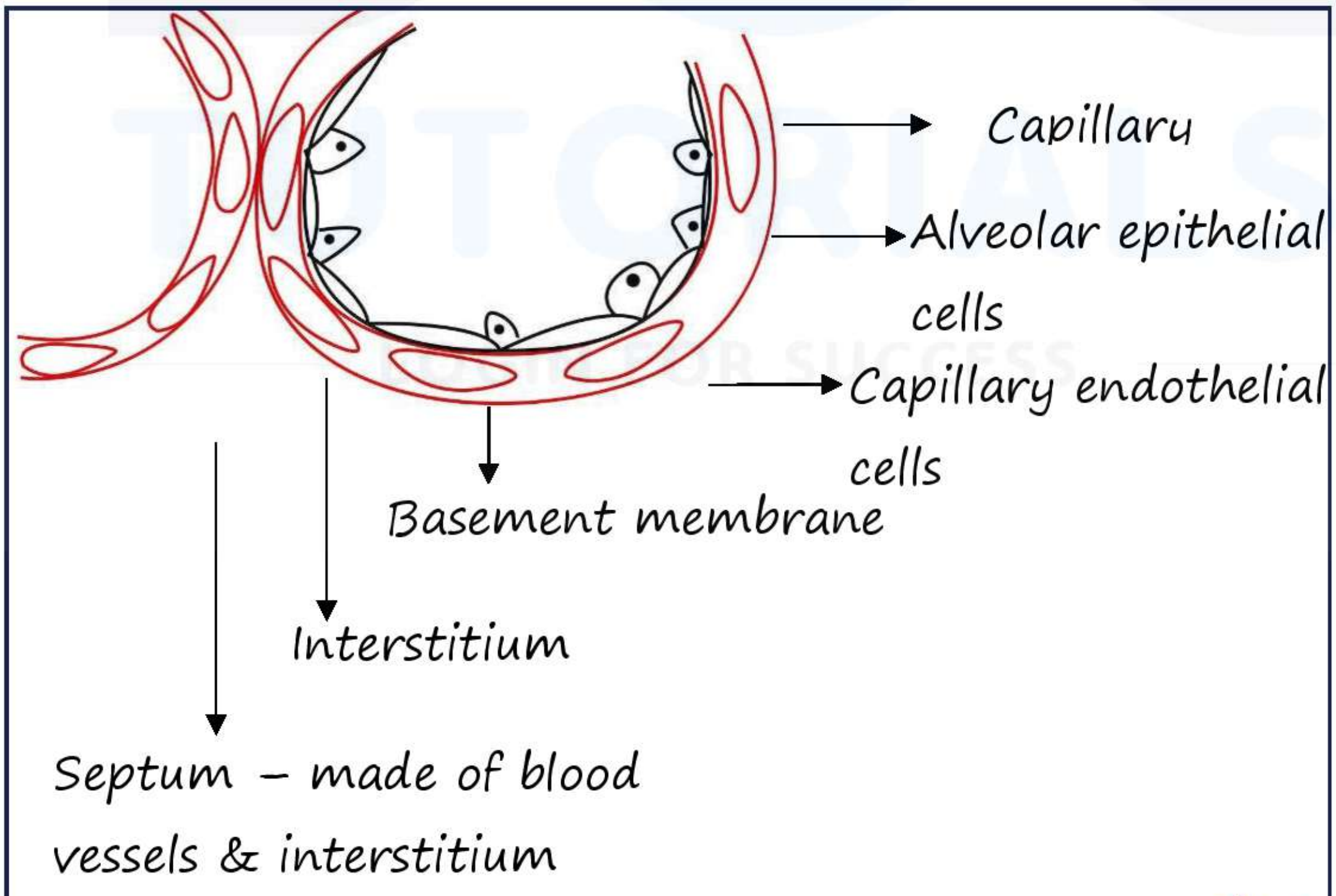

Fig: 5

- Interstitium widens in interstitial lung disease

Collateral ventilation 00:14:36

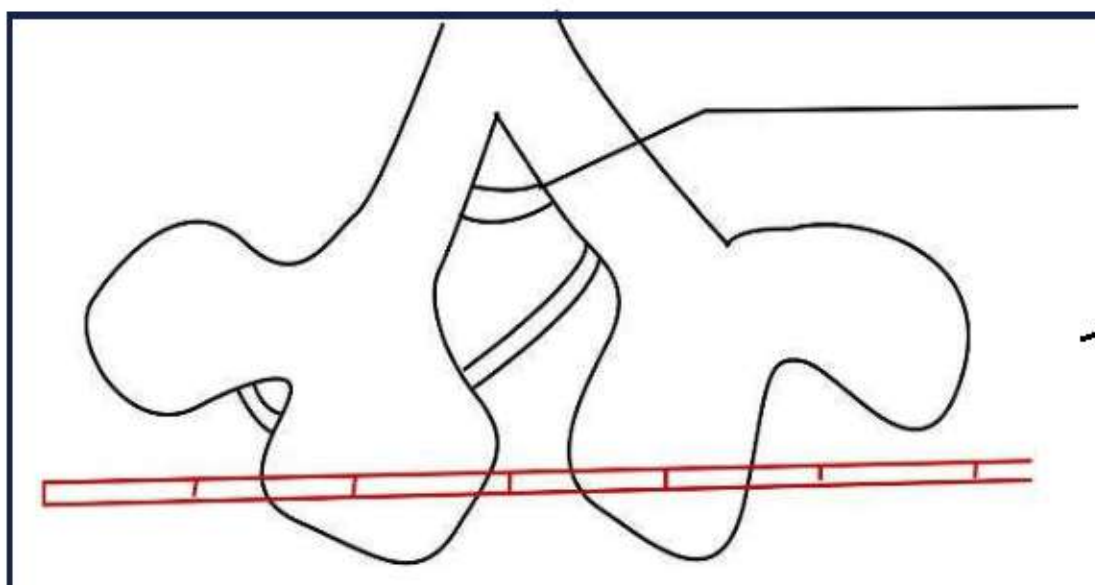

Fig: 6

- Interalveolar ventilation through pores of kohn
- Bronchiole – alveolar ventilation through channels of martin
- Interbronchiolar ventilation through channels of martin

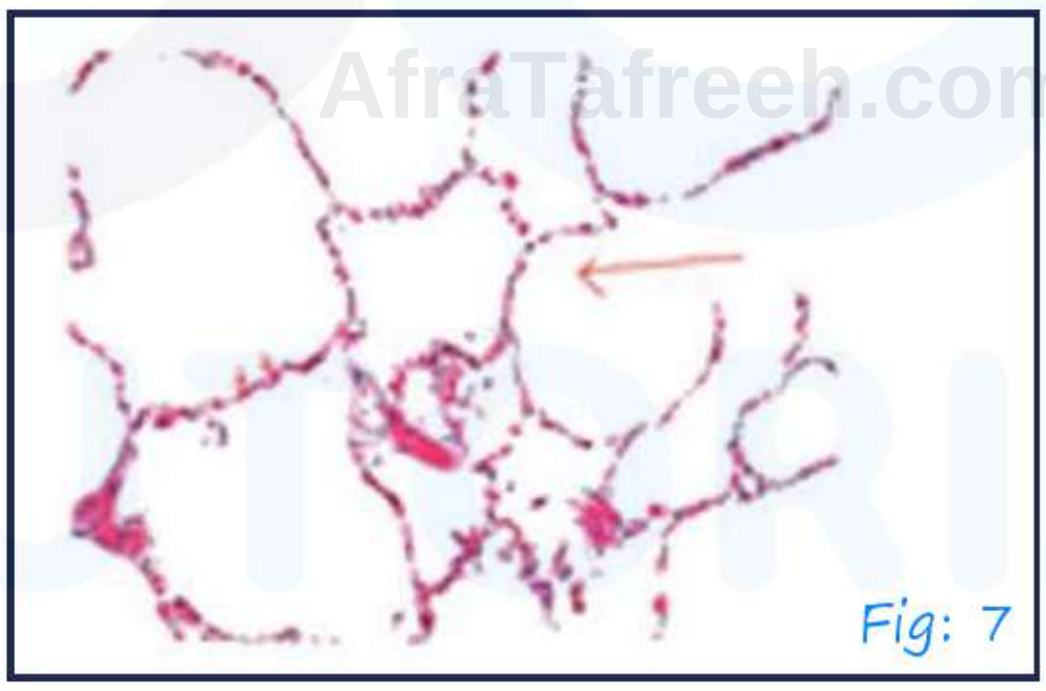
Fig: 7

- Normal HPE of lung showing alveoli and septa
- Pulmonary alveolar proteinases: -
  - Presentation in either adults or neonates
  - Neonatal pulmonary alveolar proteinases present with h/o death of previous babies despite uncomplicated pregnancy and delivery. Gene ABCA3 is important for lamellar body of development -> mutation of ABCA3 association with pulmonary alveolar proteinases

AfraTafreeh.com

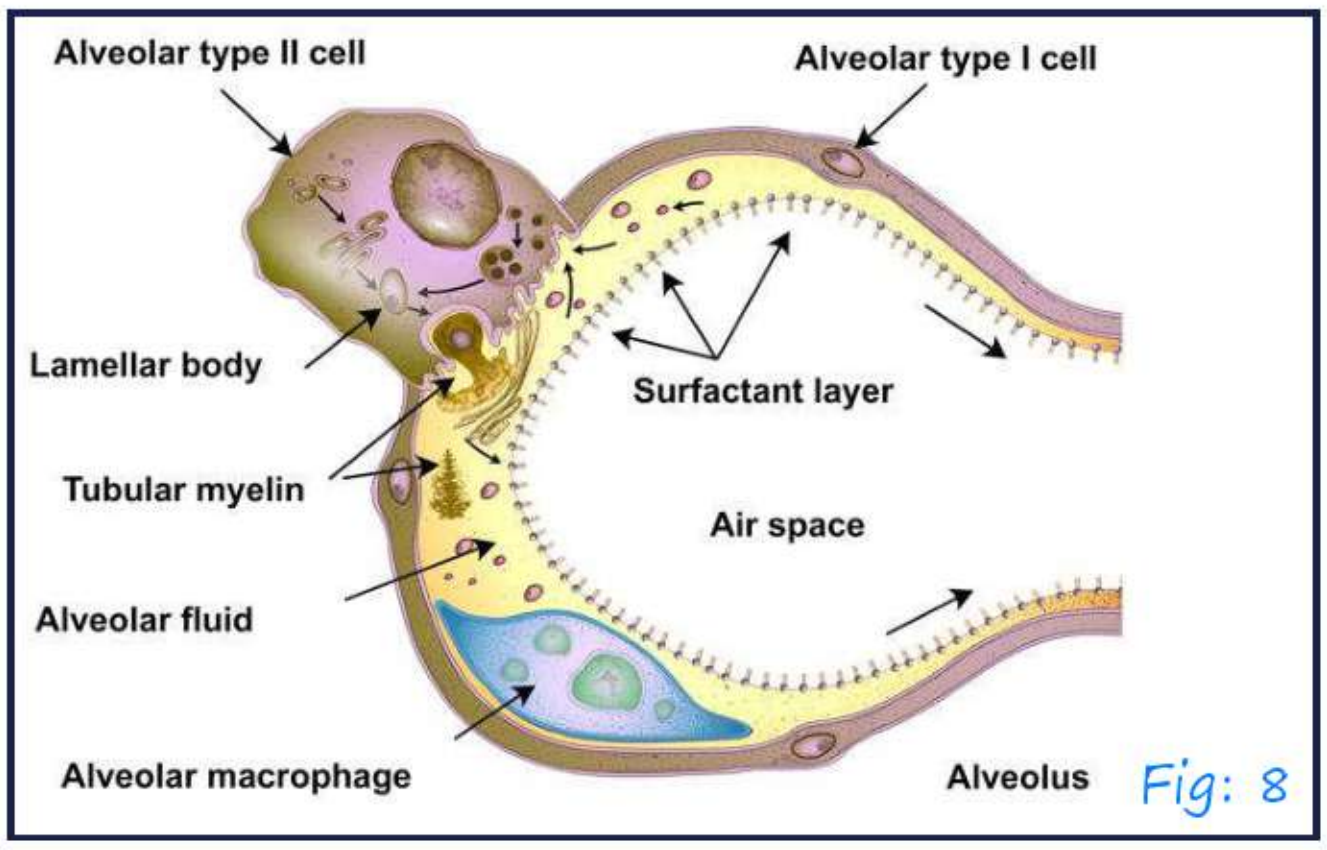

Fig: 8

Causes of pulmonary alveolar proteinases

Child	Adults
ABCA 3 mutation Impaired lamellar Body formation	- Loss of GM-CSF signaling - Blocks the terminal - Differentiation of alveolar - Macrophages impairing their ability to catabolic surfactant ↓ Lung will be filled with pink proteinaceous material.

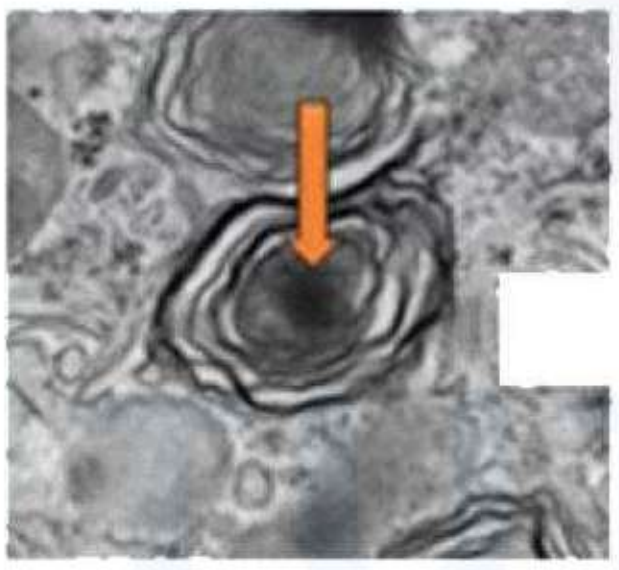

- Show target cell body with concentric lamination in type II pneumocytes

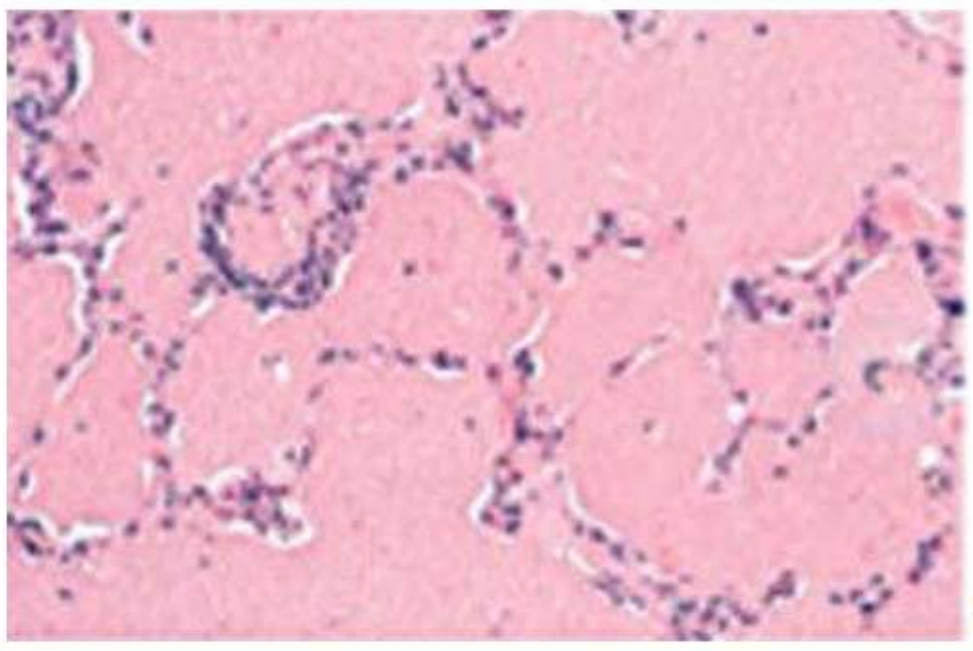
Fig: 9

- Alveoli filled with granular material surfactant builds up and is coughed out as white powdery substance

CXR Shows – Bat Wing Appearance

- CT chest -> Diary pavement / crazy pavement appearance -> ground glass appearance of alveoli

Histological examination of normal bronchioles

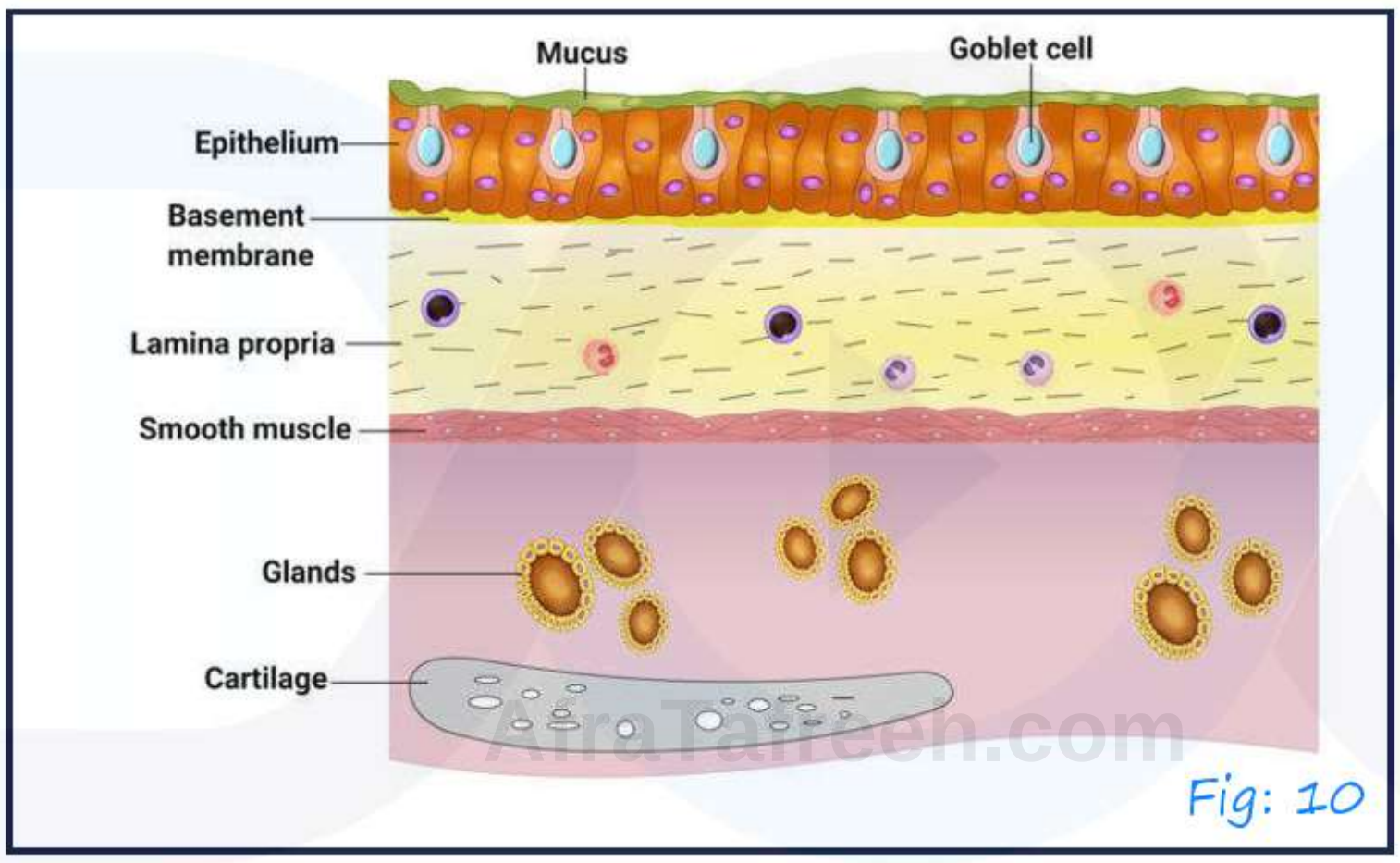

Fig: 10

1. Mucosa – Epithelium, Lamina propria, smooth muscle
2. Submucosa – submucosal gland (serous or mucinous), cartilage

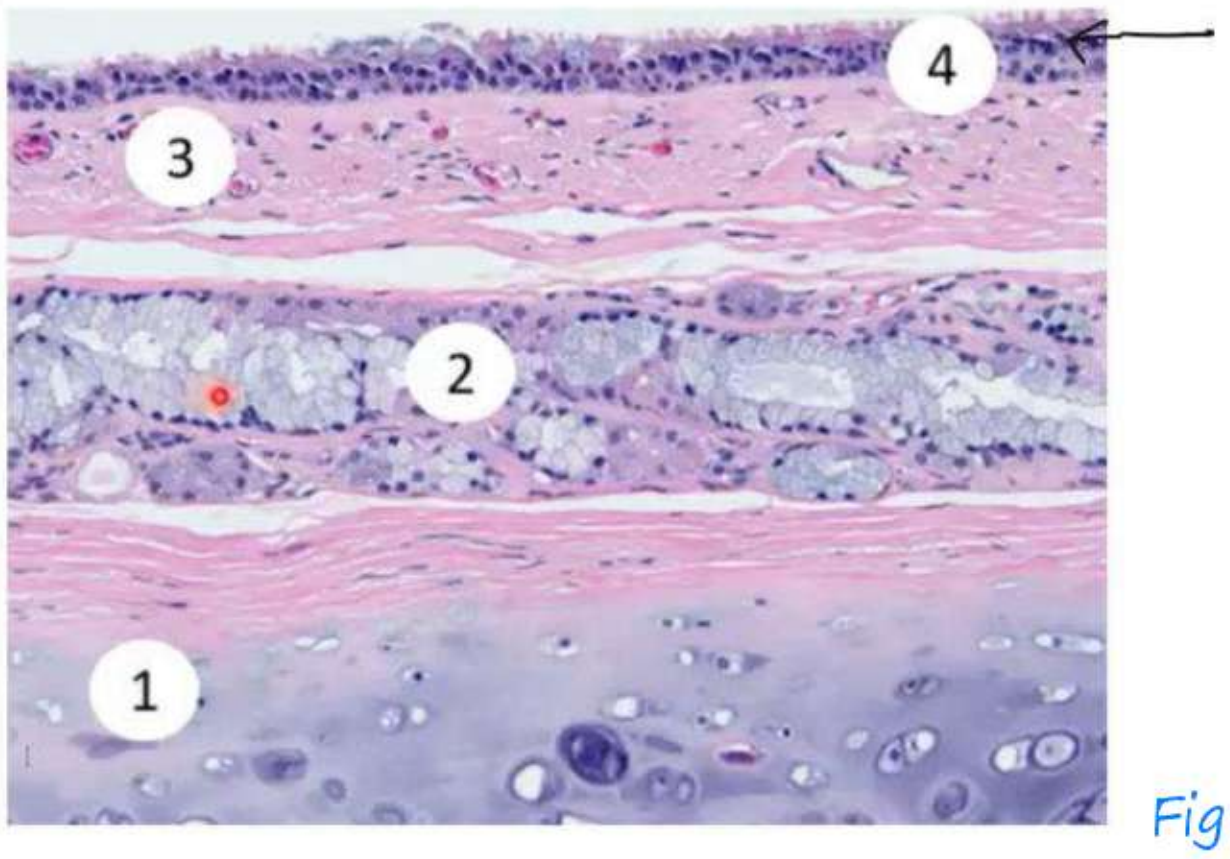

Fig: 11

AfraTafreeh.com

ACUTE RESPIRATORY DISTRESS SYNDROME

- Also known as acute lung injury
  - Diffuse alveolar damage (DAD)
  - Hyaline membrane disease
  - Shock lung
- Clinical feature – dyspnea with normal cardio – vascular system

Pathogenesis of ARDS 00:00:05

- Hallmark of ARDS – endothelial injury / endothelial activation

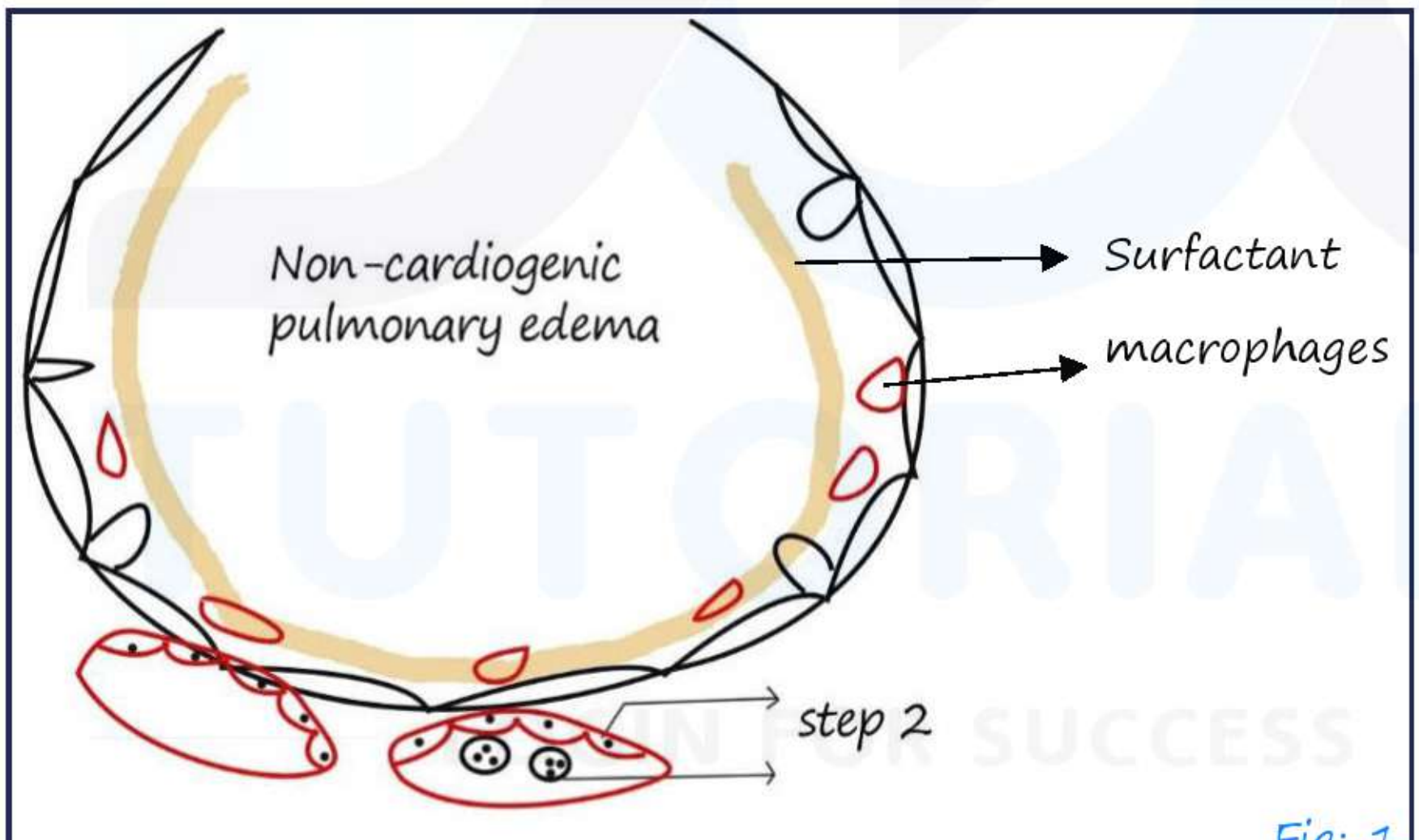

Fig: 1

Steps:

1. Endothelial cell activation
2. Neutrophils adhere to endothelium
3. Damaged endothelium causes fluid accumulation in interstitium followed by aloveolar edema -> non-cardiogenic pulmonary edema.
4. Accumulated fluid in alveoli activates macrophages

5.Activated macrophages release cytokine

TNF, IL8

TNF causes | IL8 attracts neutrophils

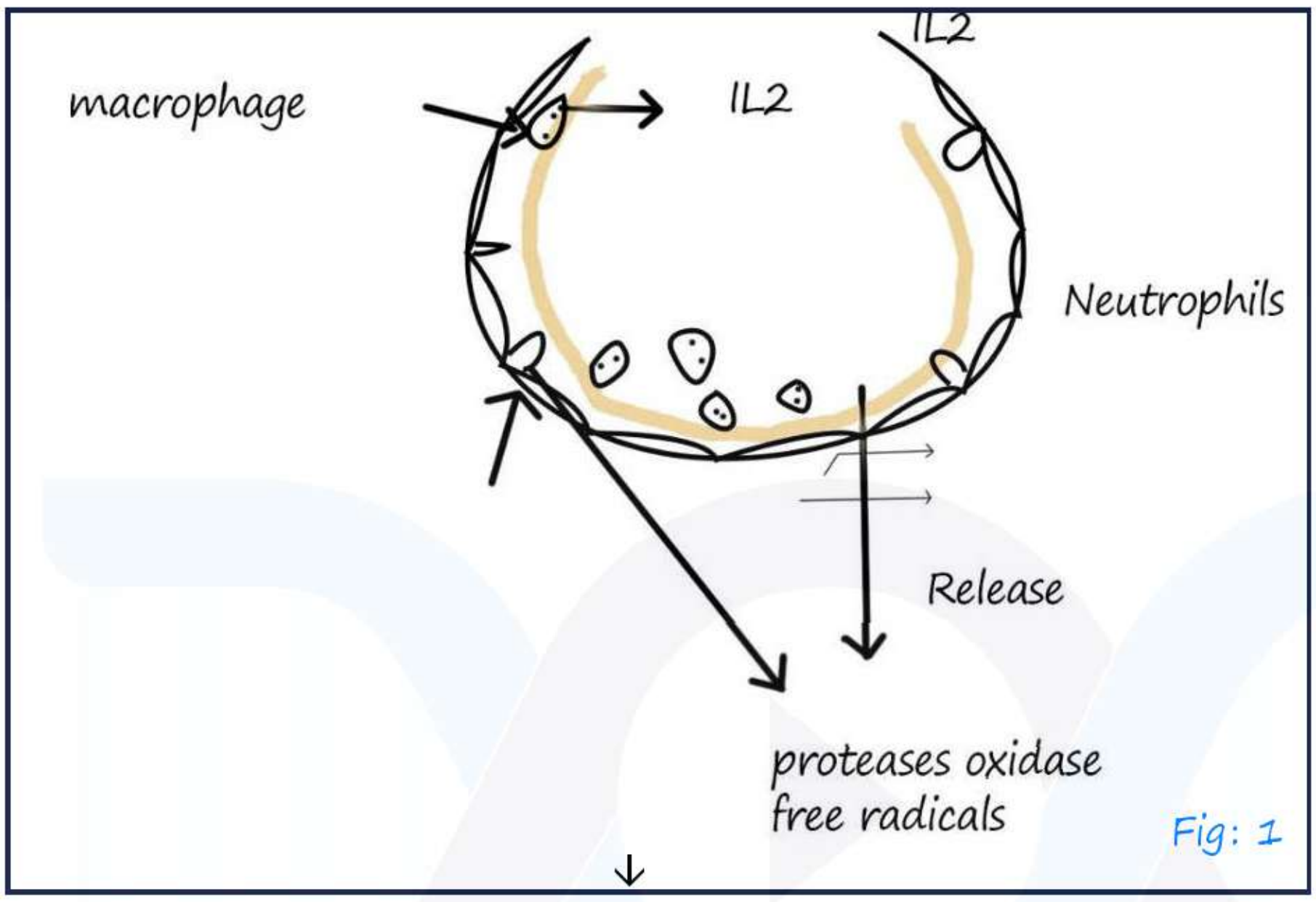

Fig: 1

↓

Damage type I pneumocytes

(no glucose exchange occurs)

↓

With time type II Pneumocytes are also damged

↓

Surfactant not produced

↓

Collapse of alveoli

- Dead alveolar epithelial cells (type I, TYPE II) + Edema fluid for membrane called hyaline membrane

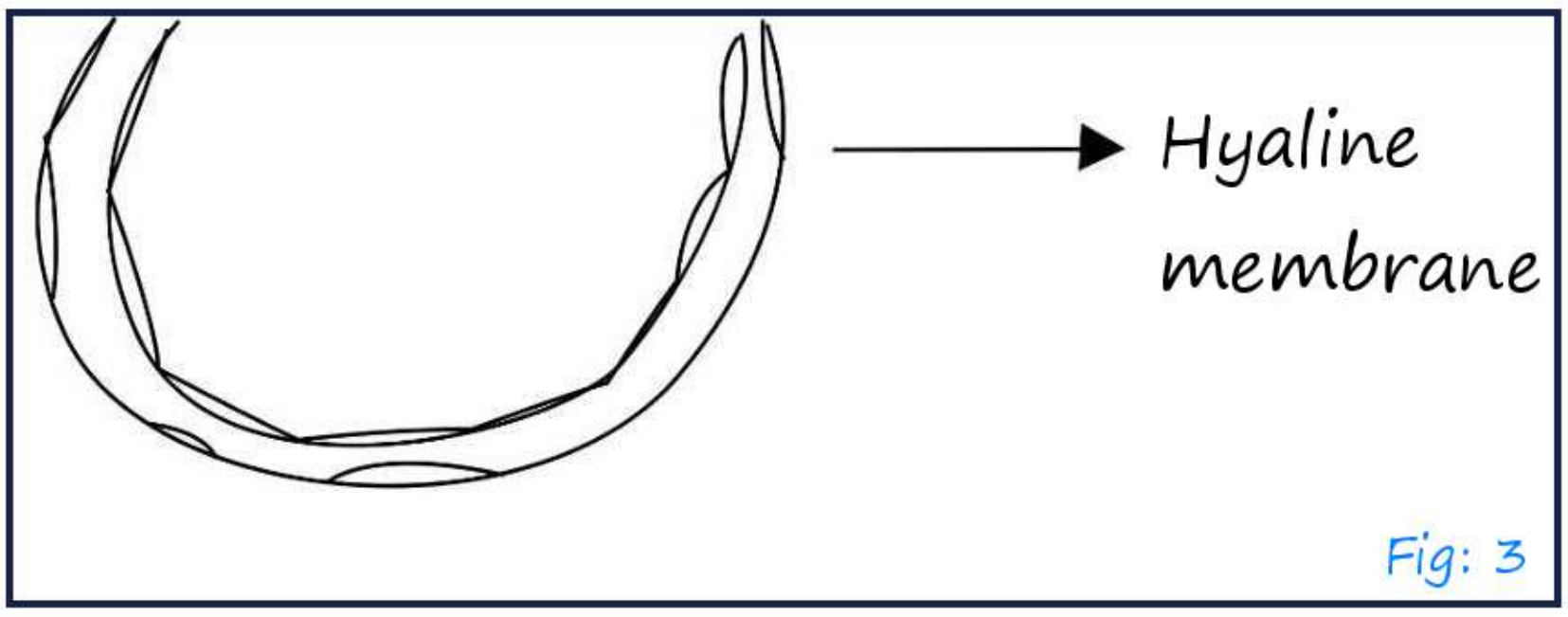

Fig: 3

AfraTafreeh.com

- Characteristic histology > diffuse alveolar damage seen on CXR – white out lung

Sequence

- Endothelial activation

  ↓

  Neutrophil adhesion

  ↓

  Endothelial damage

  ↓

  Fluid → interstitium → alveoli

  (non – cardiogenic primary edema)

  ↓

  Macrophages → IL8, TNF

  (macrophage migration inhibitor factor also released keeps the macrophage persistent in the lung)

  ↓

  Neutrophils enter into alveoli

  ↓

  Proteases, free radials

  ↓

  Damage to type I pneumocytes (hypoxemia)

  Damage to type II pneumocytes → collapse of alveoli

  ↓

  Debris + proteins form hyaline membrane

  ↓

  Repair phase left out type 2 pneumocytes start proliferating

  ↓

  Release PDGF, TGF

  ↓

  Fibrosis

Histology of diffuse alveolar damage (DAD)

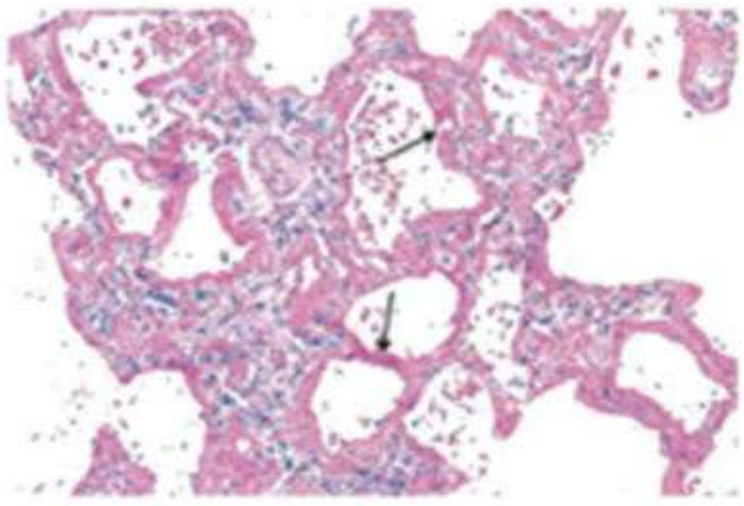
Fig: 4

- Widened interstitium with neutrophilic infiltration
- Alveolar size decreased
- Pink color material lining alveoli -> hyaline membrane

Causes of ARDS 00:18:00

- Sepsis
- Near Drowning
- Viral infections e.g. Covid 19
- Gastric aspiration
- TRALI (occurs within 6 hours of transfusion)
- Cardio pulmonary bypass

Inhaled toxins → macrophages activated
↓
TNF
↓
Endothelial activation

Indirect activation of endothelium e.g. In smoke induced ARDS

AfraTafreeh.com

AfraTafreeh.com

BASICS OF BREAST PATHOLOGY

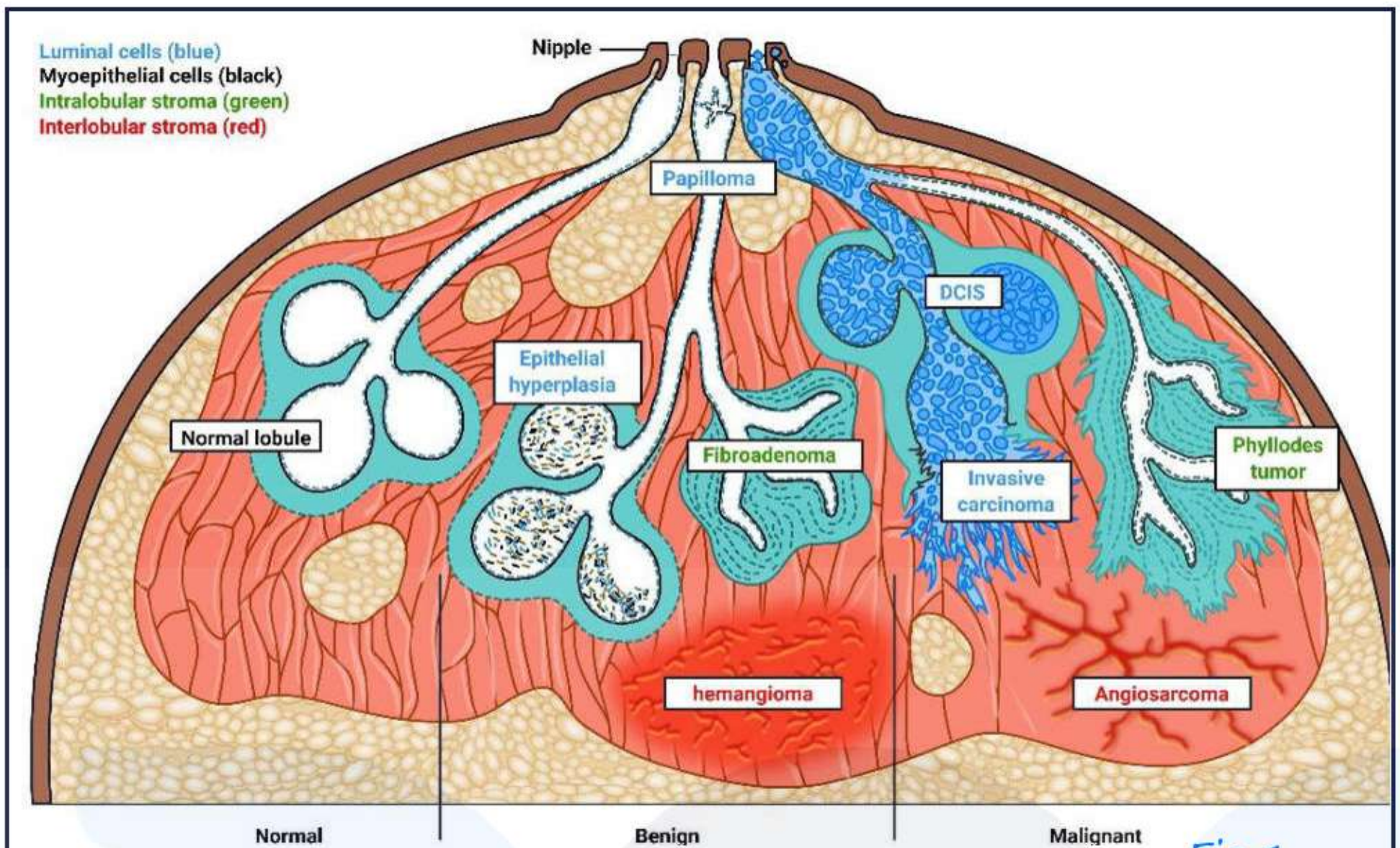

Fig 1

I. Benign hyperplasia

- Example: During pregnancy
- There is proliferation of both luminal (Ductal) and myoepithelial cells

II.Fibro adenoma 00:05:19

– most common benign tumor of the female breast

- Interlobular stroma proliferation causes compression of acini → slits
- Gross-Rubbery well circumscribed palpable masses bulging above the surrounding tissue and contains slit-like spaces
- Microscopy-Ducts surrounded by myxoid stroma (Peri canalicular pattern) or compressed and distorted by it (intracanalicular patterns)

- Fibrocement's epithelium is hormone responsive and increases in size during pregnancy
- Mostly affects females in 20s and 30s
- Frequently multiple and B/L
- Increased risk of Cancer is seen in
  i. Fibroadenomas associated with cysts larger than 3cm
  ii. Sclerosing adenosis
  iii. Epithelial Calcifications
  iv. Papillary apocrine changes ("complex fibrroademoma")
- Phyllodes tumor – (Phyllodes leaf like)
- Also known as cyst sarcoma Phyllodes, but most behave in benign fashion and are not cystic
- Most commonly after 60 years

AfraTafreeh.com

- Cytogenetic changes -
  i. Cytogenetic changes Gain of chromosome lq (most commonly)
  ii. Over expression of homeobox transcription factor (HOX-B 13)

Pathogenesis 00:06:12

- Interlobular stroma proliferates and either

Pushes interlobular stroma (or) Infiltrates interlobular stroma

↓ Benign phyllodes

↓ malignant phyllodes

AfraTafreeh.com

- They have abundant myxoid cellular stroma separated by long clefts of compressed epithelial tissue the long clefts are the key features that differentiates there from Fibroadenoma breast

iii. Ductal carcinoma in situ (DCIS) 00:06:12

- Proliferation of only luminal cells / ductal cells
- No breach of myoepithelial cells.
- If myoepithelial cells breached → **Invasive carcinoma**
- Involvement of Nipple by DCIS or Invasive Carcinoma is Paget's disease

Carcinema of Breast:

- All Breast malignancies are adenocarcinomas
- Breast Ca risk increases with

  i. Oral contraceptives

  ii. Hormone replacement therapy

  iii. Alcohol

  iv. pesticides

  v. Obesity

Pathogenesis

- Major risk factors for breast cancer are genetic & hormonal

Hereditary Breast Ca

i. BRCA1 & BRCA 2 mutations account for majority of Ca

ii. TP53 mutations

- Most frequent in Triple negative cancers
- Most common mutation in sporadic breast cancer

iii. CHEK-2 mutations-May increase risk of breast Ca after radiation exposure.

Paget's disease of Nipples 00:09:27

- Rare presentation of breast cancers
- Presents as a unilateral erythematous eruption with a scaly crust
- Pruritis is common presentation
- Malignant cells extend from DCTS into nipple skin without crossing the basement membrane.
- to 60% Paget's have underlying invasive carcinoma
- These carcinomas are poorly differentiated ER negative and overexpress HER2
- **Angiosarcoma**
- Most common Stromal malignoncy of breast
- Arises in interlobular stroma
- Breast, liver, skin are most common sites of Angiosarcoma,

Sclerosing Adenosis

AfraTafreeh.com

- Increased number of acini in a lobule with central distortion, compression and peripheral dilation.
- If myoepithelial cells breached Invasive carcinoma
- Involvement of Nipple by DCIS or Invasive Carcinoma is Paget's disease.

TUTORIALS
LOGIN FOR SUCCESS

NEONATAL HEPATITIS

Neonatal Hepatitis

- Two forms

I. Neonatal Hepatitis	II. Extra Hepatic Biliary Atresia
• It is caused by Virus • It is treated medically **Pathogenesis & Morphology** - Giant cell transformation of hepatocytes due to virus 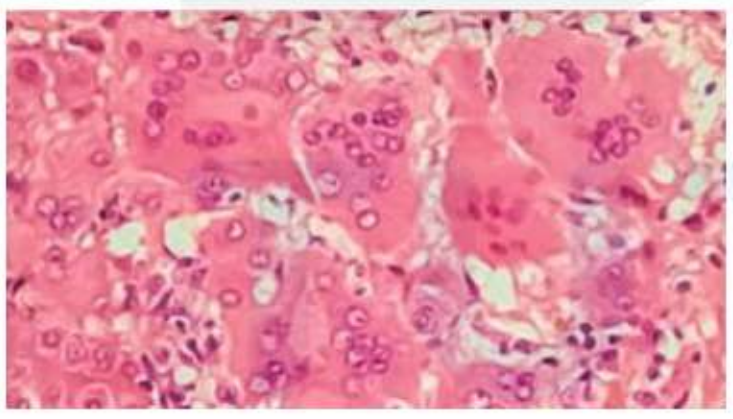	• It is structural abnormality • It is treated surgically i. Artesia at common Hepatic Bile Duct ii. Artesia at common Hepatic Duct iii. Artesia at porta Hepatis-Most common **Pathogenesis & Morphology** - Due to bile duct block Bile plugs accumulated It will be seen in Canalicular plugging, portal Triad level, there is Ductular reaction & Bile ducts increase in number. - Hepatocytes also show bile tinge-Known as Feathery degeneration - Ito cells stimulation of bile leads to biliary Cirrhosis. - Kasai procedure. 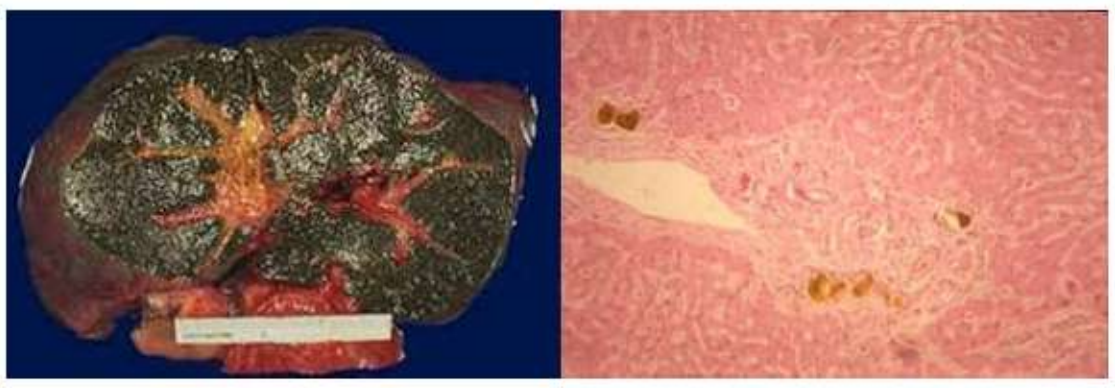

AfraTafreeh.com

Fulminant Hepatitis. 00:08:59

- It means acute liver failure
- It is Rapid detonation of liver function
- If it occurs in 1 week –Hyper Acute Fulminate
- 1 Month –Acute Fulminant
- 3 Month –Sub acute Fulminant

Pathogenesis & morphology

- Massive loss of Hepatocytes weight of liver reduces from 1500 g to 500g
- Only portal triads seen.
- Most common cause of Fulminant Hepatitis is drugs (paracetamol)
- Most common cause of Fulminant Hepatitis in pregnancy - HEV
- Most common cause of Fulminant Hepatitis in IV uses –HDV
- Interface Hepatitis – Hepatitis Involving limiting plate most commonly seen in chronic hepatitis

CIRRHOSIS

Cirrhosis

- It is the end stage of chronic liver disease with
  a. Entire liver architecture damage
  b. Bridging Fibrosis septa
  c. Regenerating parenchymal nodules

A. Entire liver architecture damaged Pathogenesis of cirrhosis

- Injury to hepatocytes leads to Repair where collagen III + I is deposited around triads & collagen IV gets deposited in sinusoids → This forms Banal Lamina which leads to loss of fenestration
- This process is called as Capillarisation of sinusoids
- Hall mark of cirrhosis → Capillarisation of sinusoids
- Fibrosis sequence of Cirrhosis

Capillarisation of sinusoids
↓
Hepatocytes dead
↓
Kupffer cells (phagocytes)
Dead Hepatocytes
↓
Kuppfer cells release
TnF alpha
↓
Stimulates I to cells – myofibroblasts / stellate cells
↓ ↓ ↓

AfraTafreeh.com
TUTORIALS
LOGIN FOR SUCCESS

AfraTafreeh.com

TGF FGF PDGF

Fibrosis

Causes & types of cirrhosis 00:10:30

i. Alcoholic – Laennec cirrhosis
ii. Viral - post necrotic Cirrhosis
iii. Crypto genetic – NAFLD
iv. Congentic cardiac Failure –Cardiac cirrhosis

- Burnt out cirrhosis – Occurs in Autoimmune Hepatitis and NAFLD
- Alcoholic, Viral, cryptogenic & CCF are type of portal Cirrhosis

- Portal Hypertension in cirrhosis

Pathogenesis 00:16:30

- Fibrosis leads to increase sinusoidal resistance.
- Periportal fibrosis leads to formation of collateral channels between Hepatic artery to central vein also channels are formed between portal vein & central vein.
- This vascular Remodeling is a high measure system which leads to portal Hypertension
- These collateral channels hepatocytes and further cause ischemia to hepatocytes.

Stages of Fibrosis

i. Periportal fibrosis

ii. Portal to portal Fibrosis

iii. Bridging Fibrosis-portal to central vein fibrosis

Regeneration Parenchymal Nodules 00:23:33

Nodules Formation

- Bridging Fibrosis leads to Nodule's formation
- Oval cells in canals of having stimulated which leads to ductules formation (Ductular Reaction) and excess hepatocytes formation in Nodules
- There Nodules consist of hepatocytes which have lost their normal architecture

AfraTafreeh.com

TUTORIALS
LOGIN FOR SUCCESS

- Masson trichrome stain also used to detect collagen Type I-seen in portal Fibrosis
- Reticulin stain (Sweet / Gordon Reticulin stain)
  ↓
  Detects collagen type 3 is portal fibrosis and sinusoids
- Masson trichrome stain unable to see sinusoids

AfraTafreeh.com

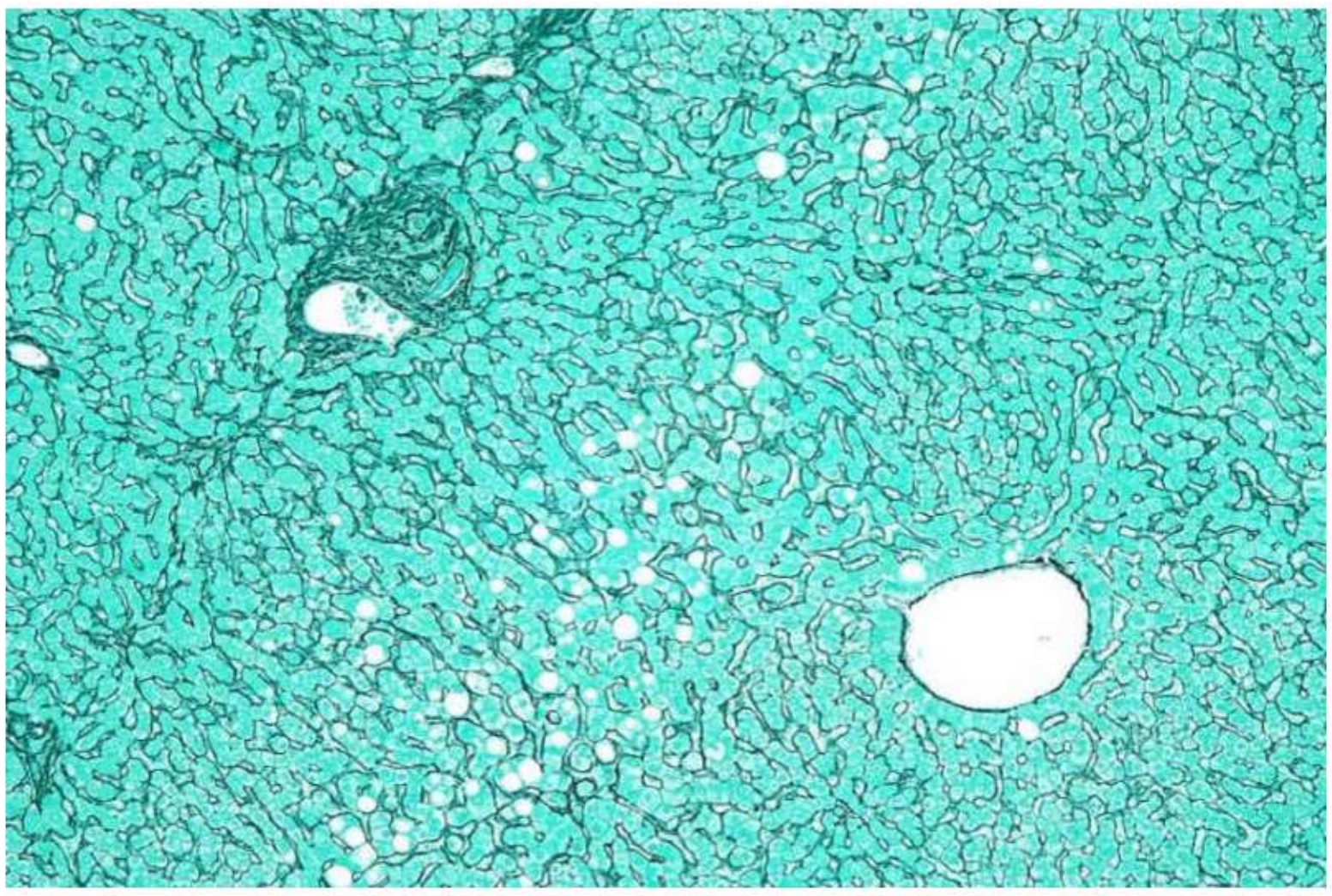

Fig 1

- The microscopic view shows nodules of varying sizes in blue – staining fibrous tissue. The liver capsule is at the top (Masson trichrome).

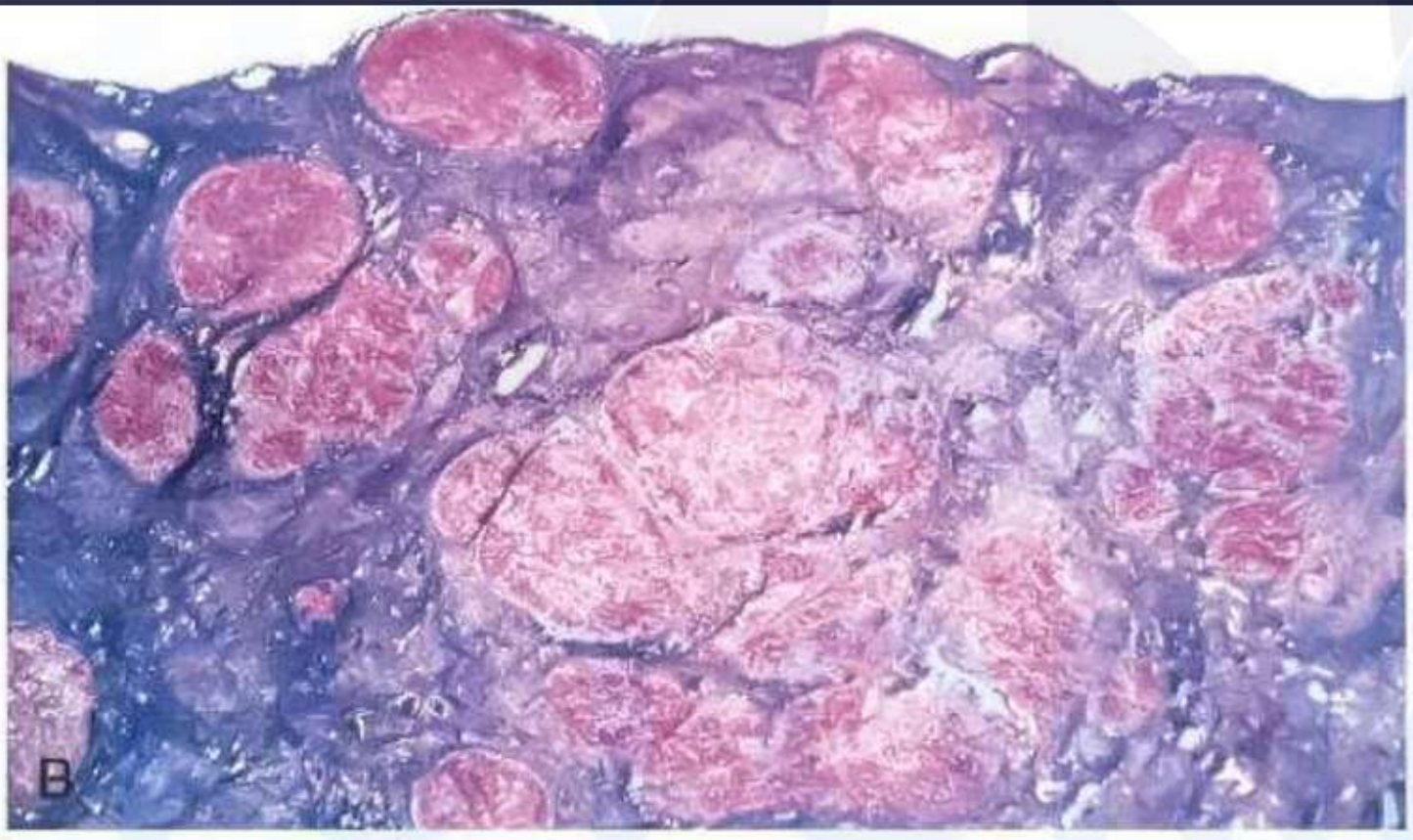

Fig 2

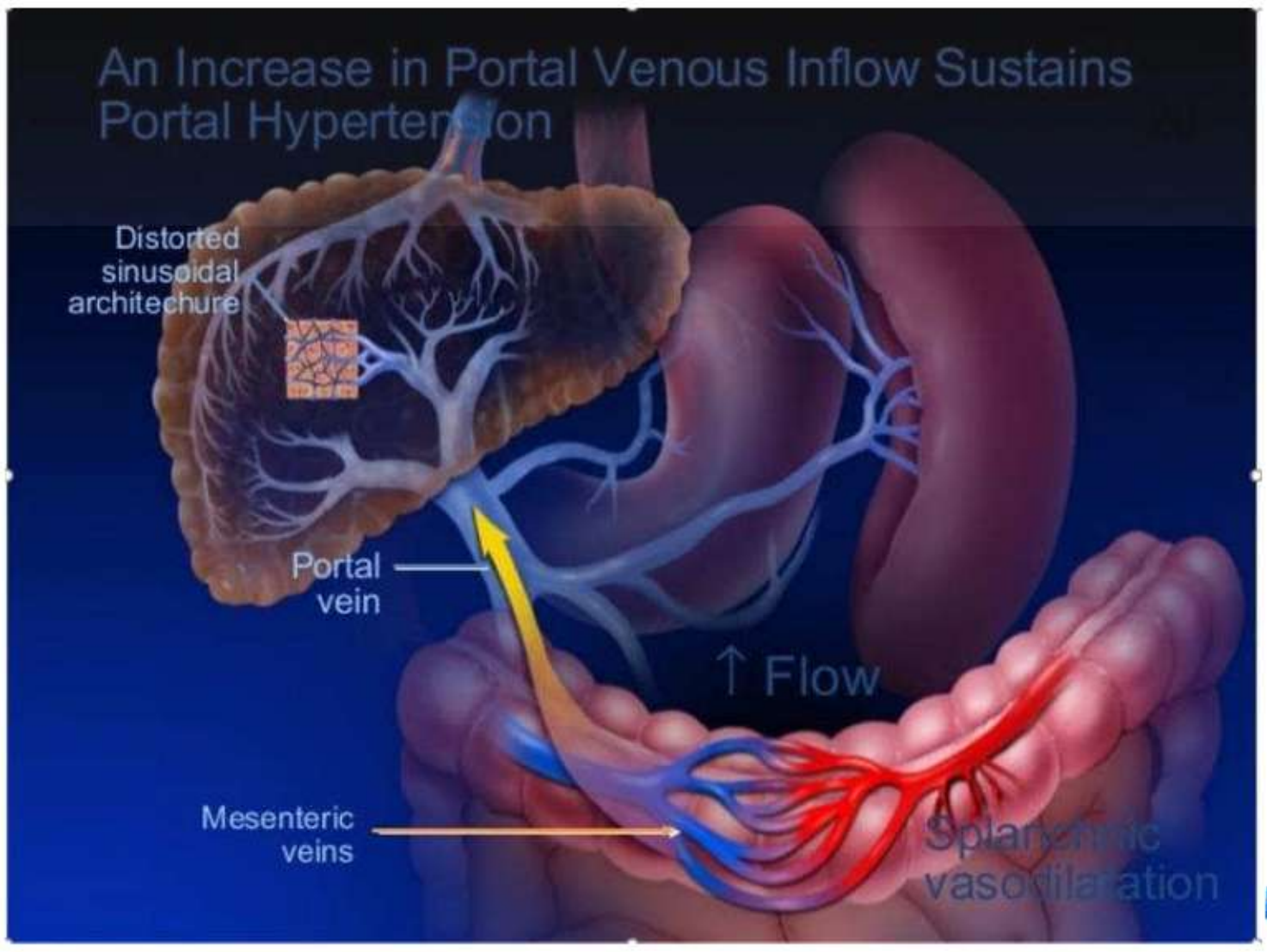

Fig 3

- Macro nodular cirrhosis seen in
- Wilson disease
- Alcoholic liver Disease (predominantly micro)
- Post Necrotic cirrhosis
- Clinical classification of cirrhosis –Child pugh score

Biliary cirrhosis

- Bile ducts damaged leads to cholestasis and extensive ductular proliferation and forms Bile plugs and Bile Lake Grossly
  - Liver appears green in Biliary cirrhosis
  - Nodules of liver in biliary cirrhosis appear as
  - Jigsaw puzzle shapes

AfraTafreeh.com
TUTORIALS
LOGIN FOR SUCCESS

AfraTafreeh.com

OBSTRUCTIVE LUNG DISEASE WITH FOCUS ON EMPHYSEMA

1. Emphysema
2. Chronic bronchitis.
3. Asthma
4. Bronchiectasis

COPD

Criteria FEV1/FVC < 0.7

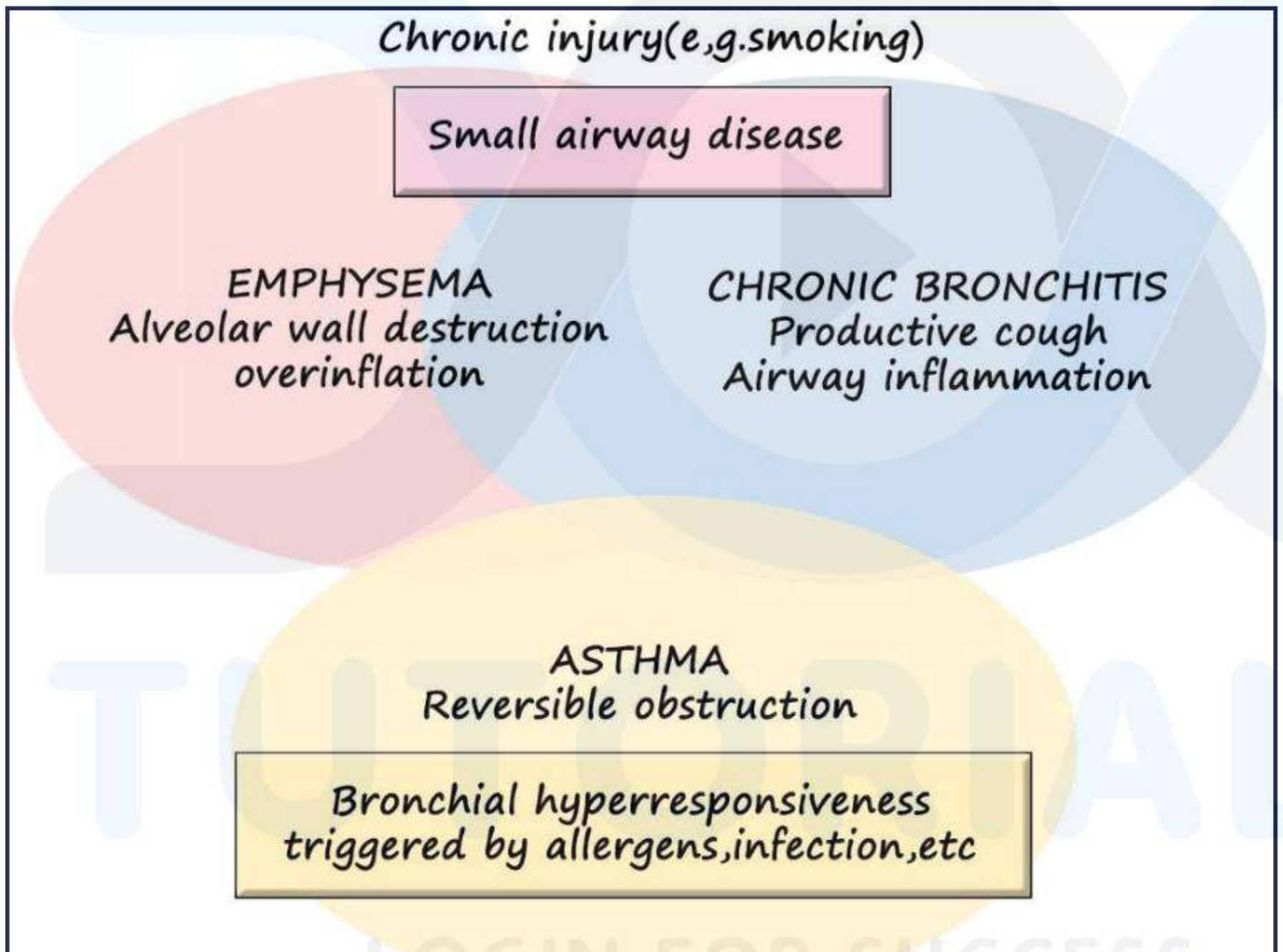

Fig: 1

Emphysema & chronic bronchitis have obstruction in small airways both are implicated with chronic smoking therefore both are grouped under chronic obstructive pulmonary disease

EMPHYSEMA 00:03:08

- Permanent destruction and dilation of acini
- Rupture of septa due to abnormal dilation of pores of kohn
- Minimal or no fibrosis

Pathology

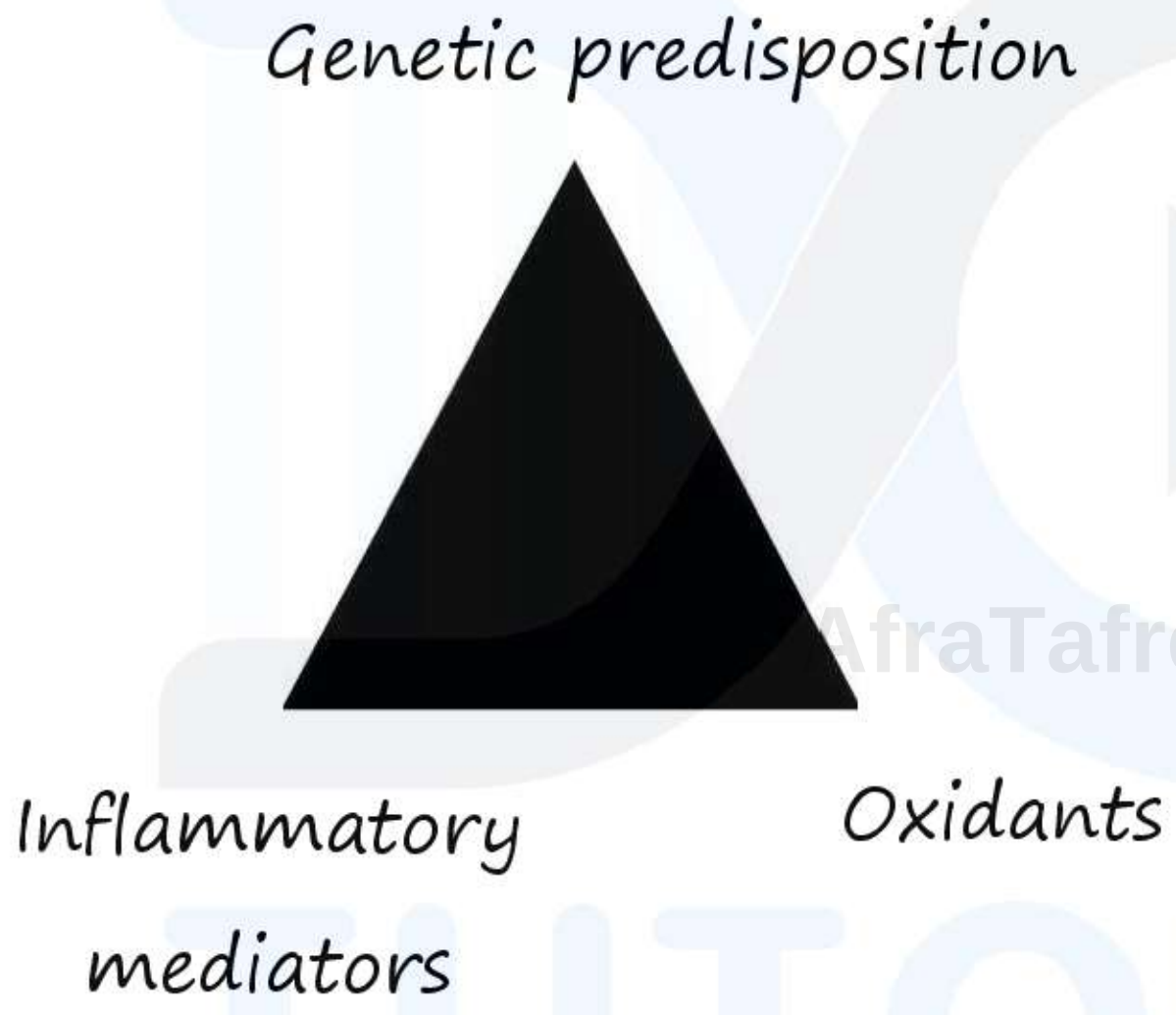

AfraTafreeh.com
TUTORIALS
LOGIN FOR SUCCESS

GENETIC

NRF2 gene

- Sensor of oxidants / free radicals activates anti-oxidants
- Patients of emphysema have deficiency of NRF2

AfraTafreeh.com

ALPHA 1 – antitrypsin

- Alpha 1 – antitrypsin (anti- protease)

  ↓ ⊖

- Smoking → proteases
- If deficiency of alpha 1 – antitrypsin, proteases damage elastic fiber of lung causing obstruction & emphysema

Causes: -

- Excessive smoking → excessive protease
- Alpha 1 – antitrypsin deficiency

Inflammatory mediators

Smoking → Resident macrophages of lung activated

↓

Inflammation mediators

↓

Activation of neutrophils

↓

Release of proteases elastases

↓

Damage of elastic tissue in lung

"Imbalance of"

- Proteases
  - Elastases ← Neutrophils, Macrophages
- Anti-proteases

Alpha 1 anti tryphin

Coded by Pi locus on chromosome 14

- Normal locus – PiMM
- Mutated – PiZZ → they have very low levels of alpha 1 antitrypsin
- PiMz -> also have low levels of alpha 1 antitrypsin but more than that of piZZ genotype

TUTORIALS
LOGIN FOR SUCCESS

Alpha 1 antitrypsin either due to

- ER stress
  - Misfolding of alpha 1 – AT causes liver disease
- Deficiency
  - ↓
  - Pan – acinar emphysema

AfraTafreeh.com

Types of emphysema

Acinus

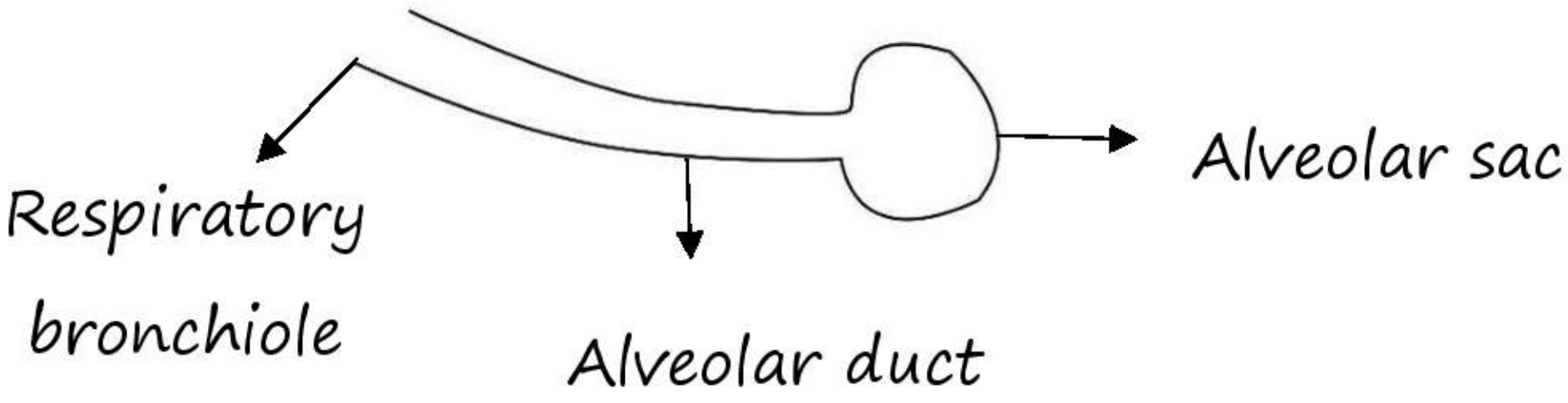

Affected in empyema

- Based on part affected emphysema divided into four parts

Centri – acinar

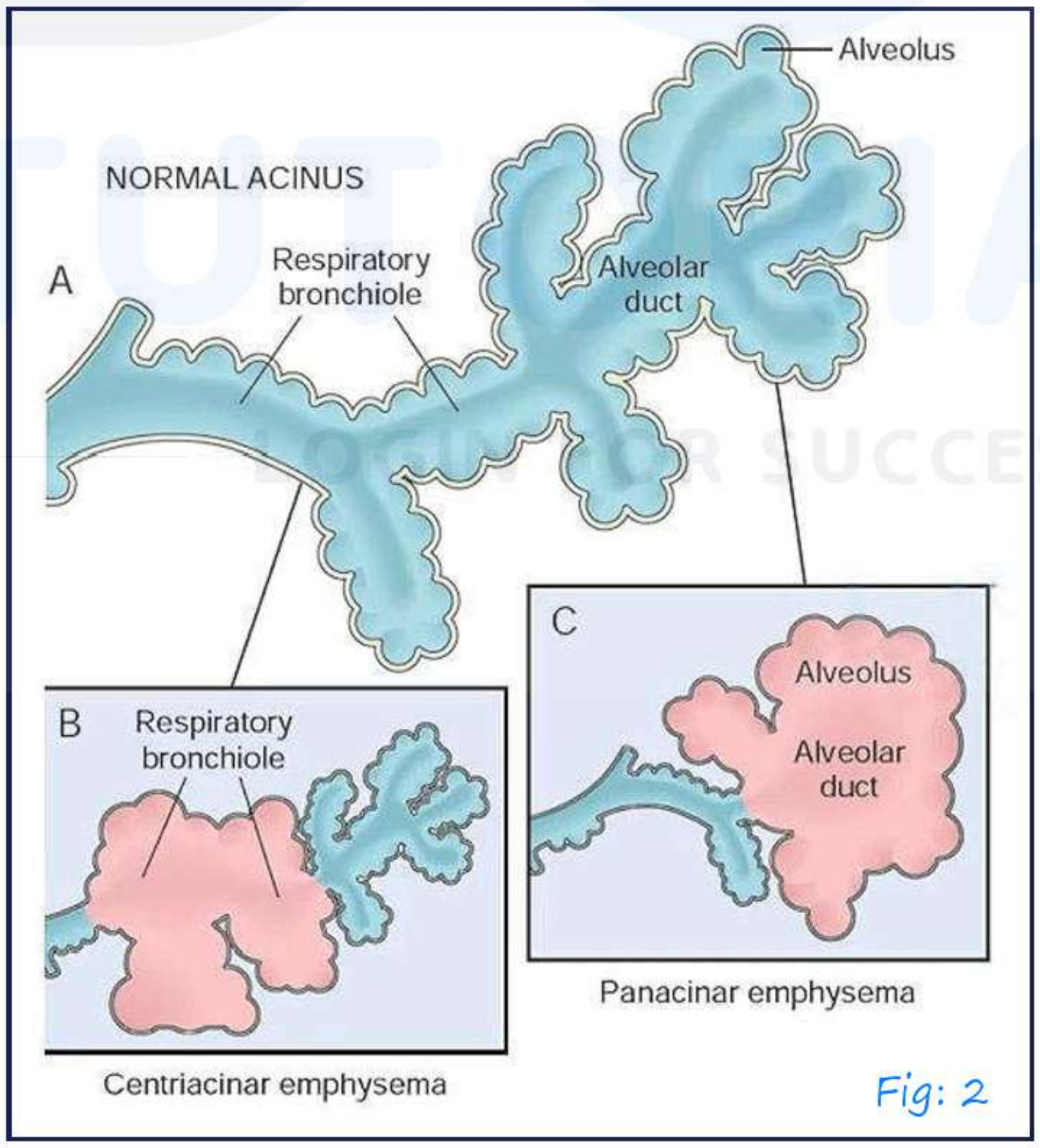

Fig: 2

Respiratory bronchiole massively dilated

- Distal part of acinus normal
- Only proximal part of acinus involved
- M/C type of emphysema
- Associated with smoking, coal workers pneumoconiosis
- upper lobes of lung affected
- M/C symptomatic emphysema

Pan acinar

- Whole acini involved
- Associated with congenital deficiency of alpha 1 – anti trypsin
- Basal part of lung affected

Distal acinar

- Occur near the pleura
- Distal part of acinar involved
- Usually present with spontaneous pneumothorax in young

Irregular emphysema

- Asymptomatic
- Identified at autopsies
- Occur due to scaring of alveoli
- Irregular emphysema only at sites of scarring of acinus

AfraTafreeh.com
TUTORIALS
LOGIN FOR SUCCESS

AfraTafreeh.com

Microscopy of emphysema

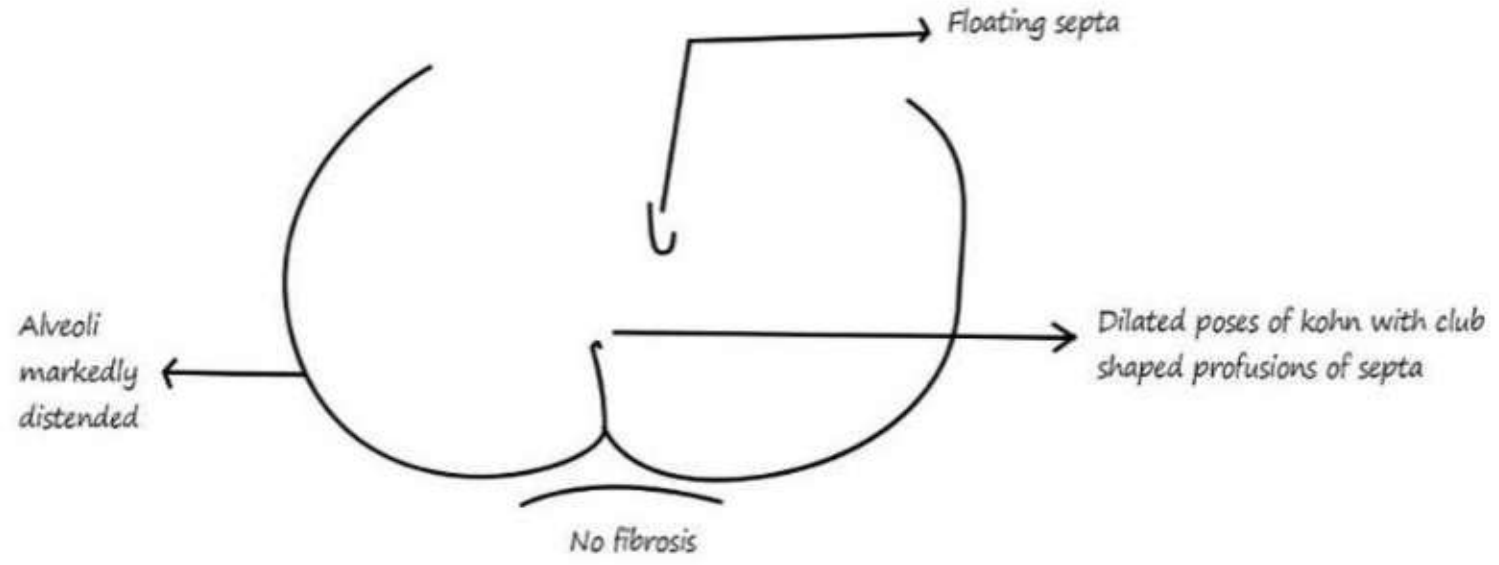

Fig: 3

- Markedly enlarged air spaces with floating septa —> highly suggestive of emphysema

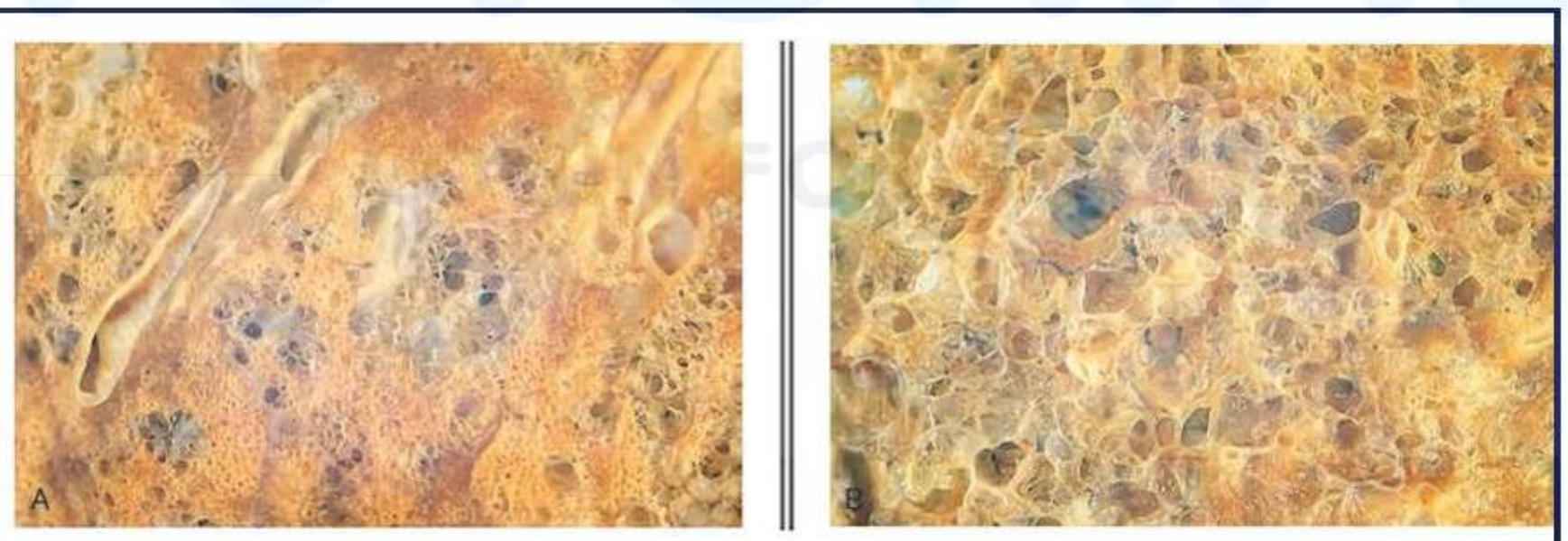

<u>**Centri acinar**</u>

Smaller cavities with pared areas in between

<u>**Pan acinar**</u>

Large cavities

Fig: 4

- Patients with emphysema are also called as pink puffers white patients with chronic bronchitis are called blue bloaters.

CHRONIC BRONCHITIS

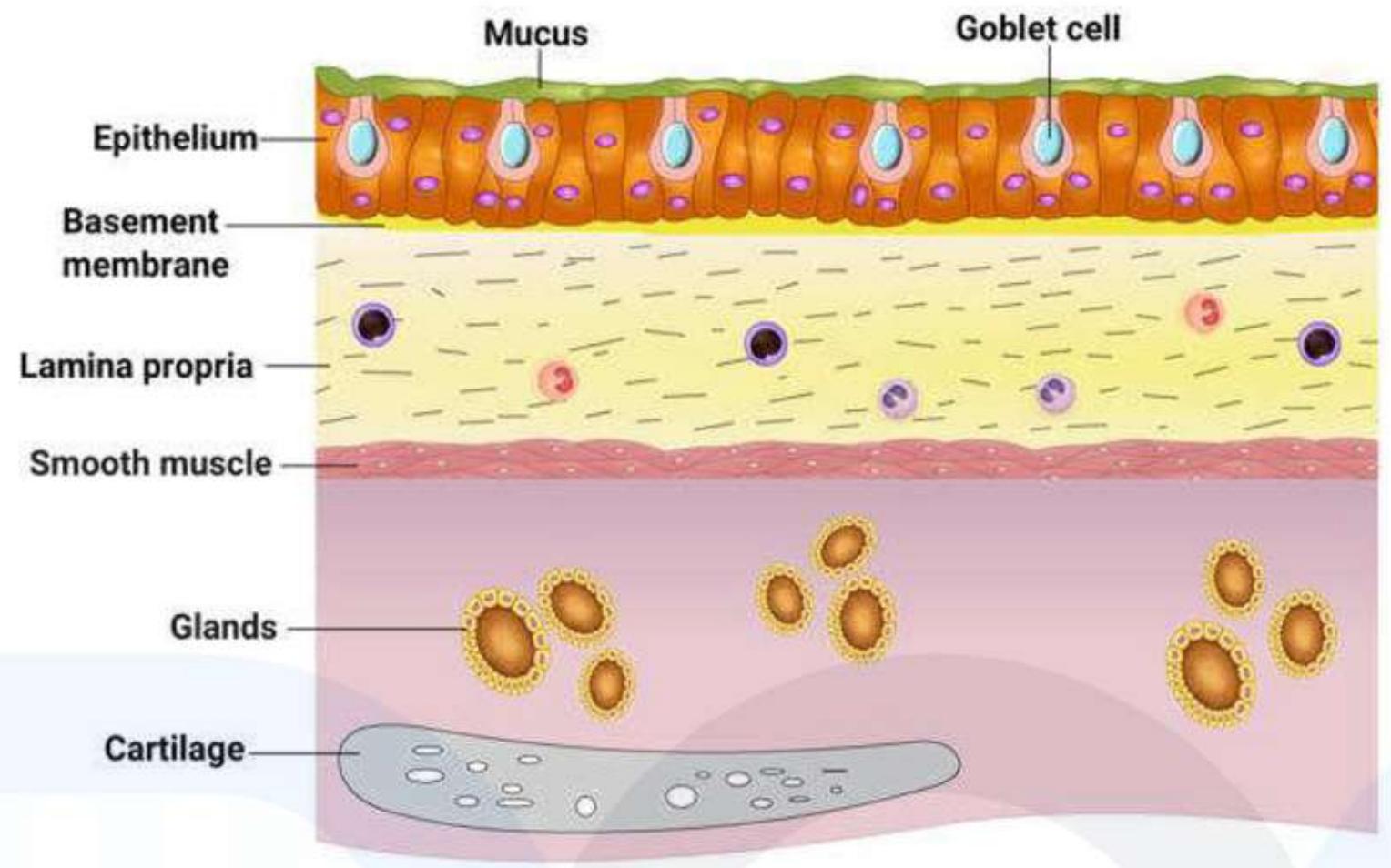

Fig: 1

- Productive cough for > 3 months for > 2 consecutive years without any identifiable cause
- But is M/C a/w smoking

AfraTafreeh.com
TUTORIALS
LOGIN FOR SUCCESS

Pathogenesis

Smoking

IL 13
↓
Mucus gland hyperplasic
↓
mucus hypersecretion

Resident macrophages of lung activated
↓
Release of inflammatory mediation

AfraTafreeh.com

- Chronic obstruction of smaller airways

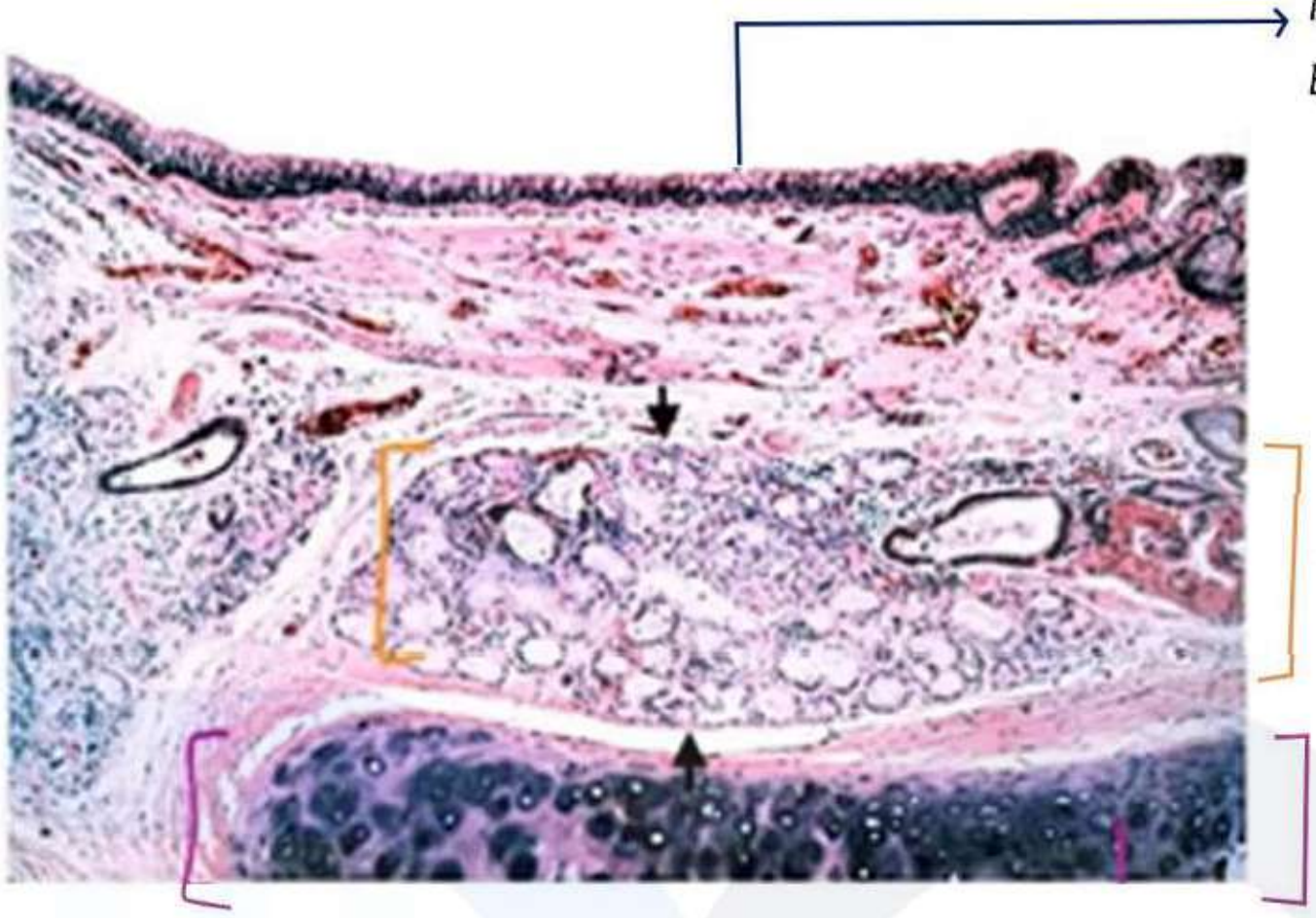

Fig: 2

- Reid's index :: $\frac{B}{A+B+}$; ratio of thickness

of = $\frac{\text{Mucus of lung activated A+B+C}}{\text{Total thickness of bronchial cell}}$

In chronic bronchitis –

- Cough for more than 3 months in 2 years
- Reid's index > 0.4
- Also called blue bloaters
- Chronic bronchitis -> metaplasia -> dysplasia -> lung cancer
- M/C cancer arising from scared lung -> adenocarcinoma

BASIC UNDERSTANDING OF GIT

Functions of GIT 00:01:53

i. Protective

ii. Secretive

iii. Absorption

Entire GIT is lined by columnar epithelium except esophagus and part of anal canal which have squamous epithelium layers of GIT – from inside to outside

Layers of GIT 00:04:40

a. Mucosa
- Epithelium
- Lamina propria
- Muscularis mucosae

b. Sub mucosa
- Contains Meissner's plexus (Sub mucosal plexus)
- Strongest layer of gut wall containing large bundles of collagen

c. Muscularis propria
- Inner circular

  [myenteric plexus (Auerbach's) plexus in between]
- Outer longitudinal

d. Serosa (Adventitia or mesothelium)

AfraTafreeh.com
TUTORIALS
LOGIN FOR SUCCESS

AfraTafreeh.com

Important features in esophagus

- Epithelium → stratified squamous non – keratinized epithelium
- Lacks a serosal layer
- Submucosa is the toughest and strongest layer

Muscles

- Upper cervical region: Stratified muscles
- Middle → gradual transition from stratified to smooth muscle
- Lower → smooth muscle
- **Gall Bladder – doesn't have lamina propria**

Auerbach's/Myenteric Plexus

- Collection of inter connected neurons in muscularis propria spanning from esophagus to the rectum
- Develops from the neural crest cells
- Ganglion cells of Auerbach's plexus

Fig: 1

- Large nucleus and prominent nucleoli labelled as vesicular nucleus

- Secrete excitatory neuropeptides like Acetylcholine and inhibitory neuropeptides like NO, VIP

Identification of Auerbach's plexus

- Morphologically
- immune histochemistry
  - DAB linked at Ach stains ganglion cells brown

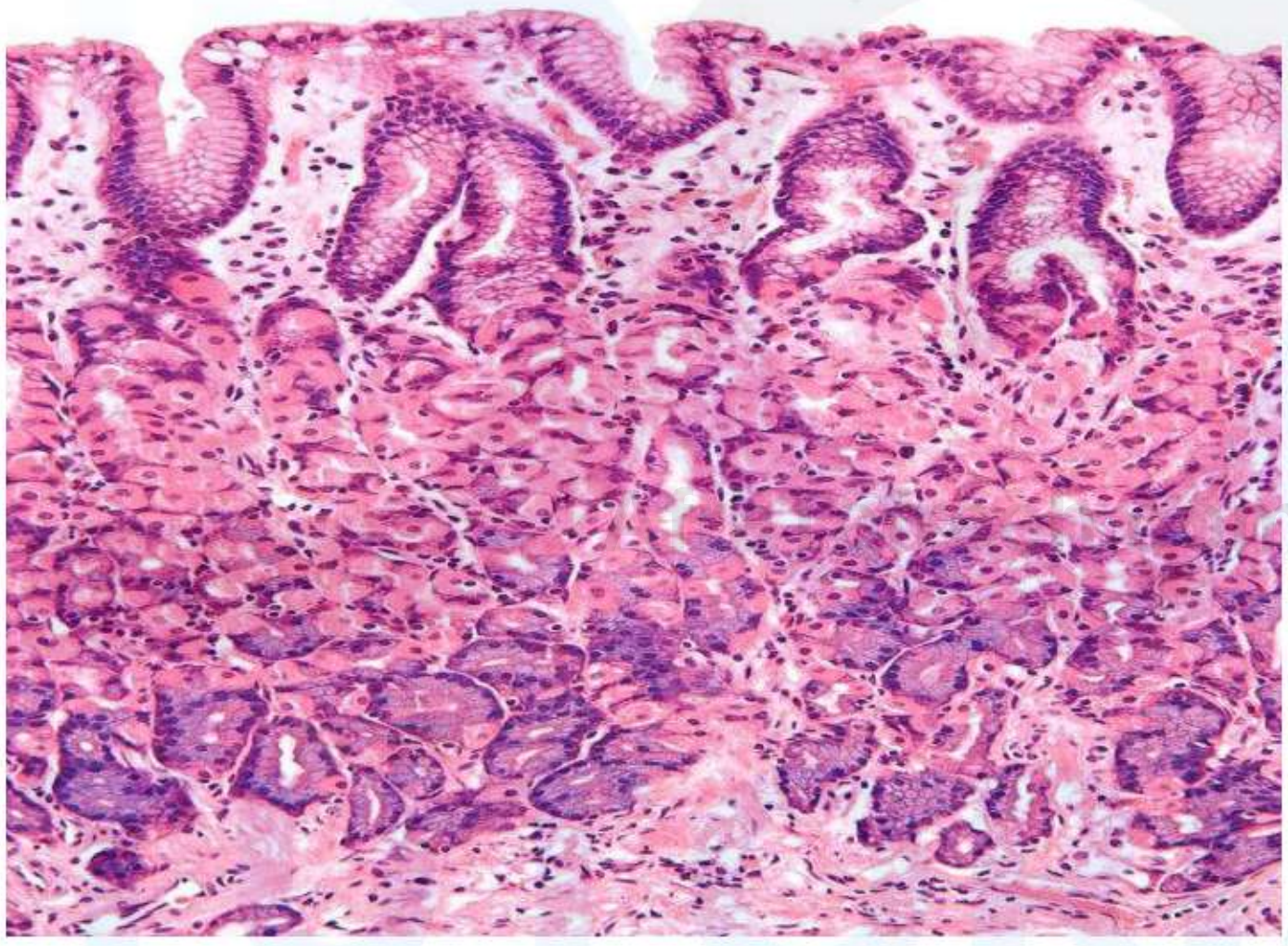

Fig: 2

- **Important features in stomach**
- Lining – simple columnar epithelium with small irregular gastric pits
- Gastric glands – 3 groups
  i. Pyloric glands – mucus secreting cells predominate, also contains neuroendocrine G cells (Secreting gastrin) and cells which secrete lysozyme

AfraTafreeh.com

ii. Cardiac glands – mainly contain mucus secreting cells

iii. Principal (main) glands found in body and fundus contain mainly

chief cells (Peptic or zymogen)	parietal (oxyntic) cells
↓	↓
produce pepsinogen	produce hydrochloric → converts pepsinogen to pepsin
	acid intrinsic factor → β12

- Hydrochloric acid helps in <u>conversion of pepsinogen to pepsin</u> that is why few parietal cells are present in between the chief cell layer

TUTORIALS
LOGIN FOR SUCCESS

Pernicious Anaemia 00:21:47

Pernicious anemia

- Megaloblastic macrocytic anemia resulting from failure of secretion of intrinsic factor due to destruction of IF by the antibodies

  ↓

  Reduced secretion of IF

  ↓

  Reduced binding of IF to vitamin B12

  ↓

Failure of absorption of vitamin B12

↓

Deficiency of vitamin B12

Clinical features

- Elderly female
- Megaloblastic anemia
- Hypochlorhydria

Investigation: Very low serum B12 levels

- Anti- intrinsic factor antibody in 70% of patients – highly specific
- Anti-parietal cell antibody in 85-90% - less specific
- On immunofluorescence – antibodies against parietal cells seen

AfraTafreeh.com

Mucus cells

Immunofluorescence Staining pattern of gastric parietal — In pernicious anemia

Abnormal vitamin B12 absorption test → schilling test

AfraTafreeh.com

Small Intestine 00:24:38

I. Small intestine histology

Mucosa

a. Epithelium – simple columnar epithelium with microvilli

Three types of cells

- M cells (Microfold cells) → antigen presenting cells
- goblet cells → secrete mucin surface
- enterocytes → absorptive cells

b. Lamina propria – contains numerous intestinal glands or crypts of Lieberkühn

Which contain following types of cells

- stem cells
- mucous cells
  - Rich in Zinc, RER,
  - These cells exceptionally migrate towards the base of crypts instead of
- **Paneth cells** – produce defensins → for innate immunity
  - Located in lower half of intestinal glands (Crypts of Lieberkühn)
  - Responsible for continued renewal of villous epithelium every 2-5 days

going towards
the tip of villi

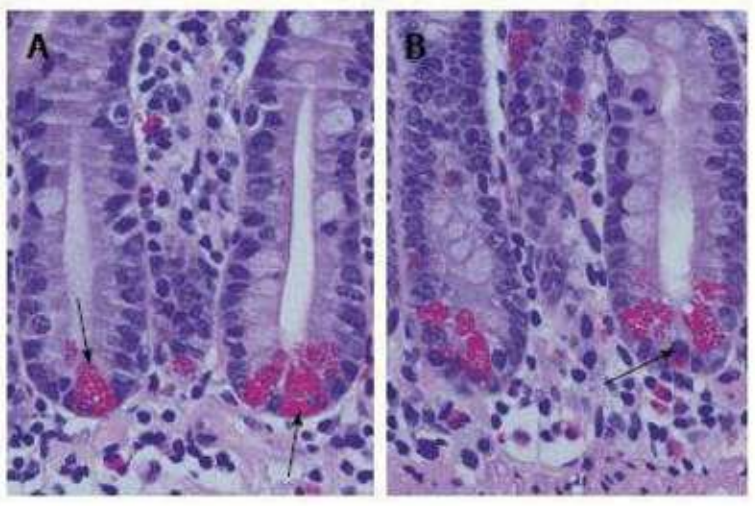

II. Submucosa

- Brunner's glands in proximal (upper) part of duodenum
- Peyer's patches in Ileum

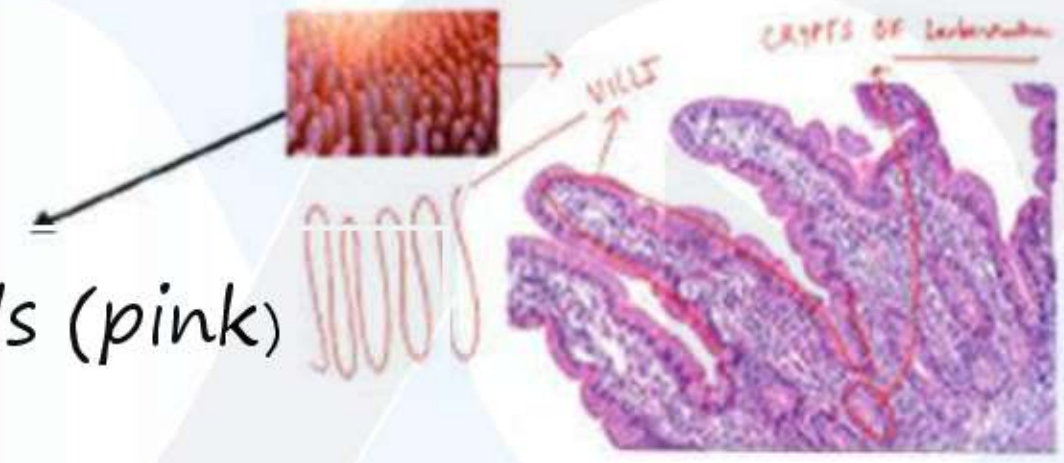

Paneth cells (pink)

Intestinal epithelium

Fig: 3

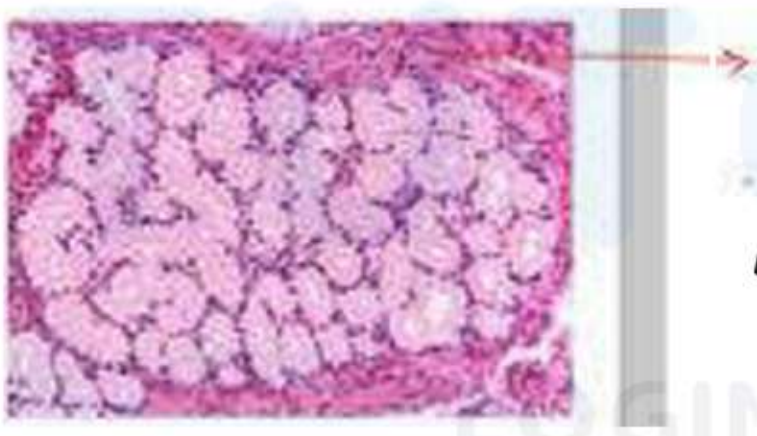

Brunner glands → present in duodenum

Fig: 4

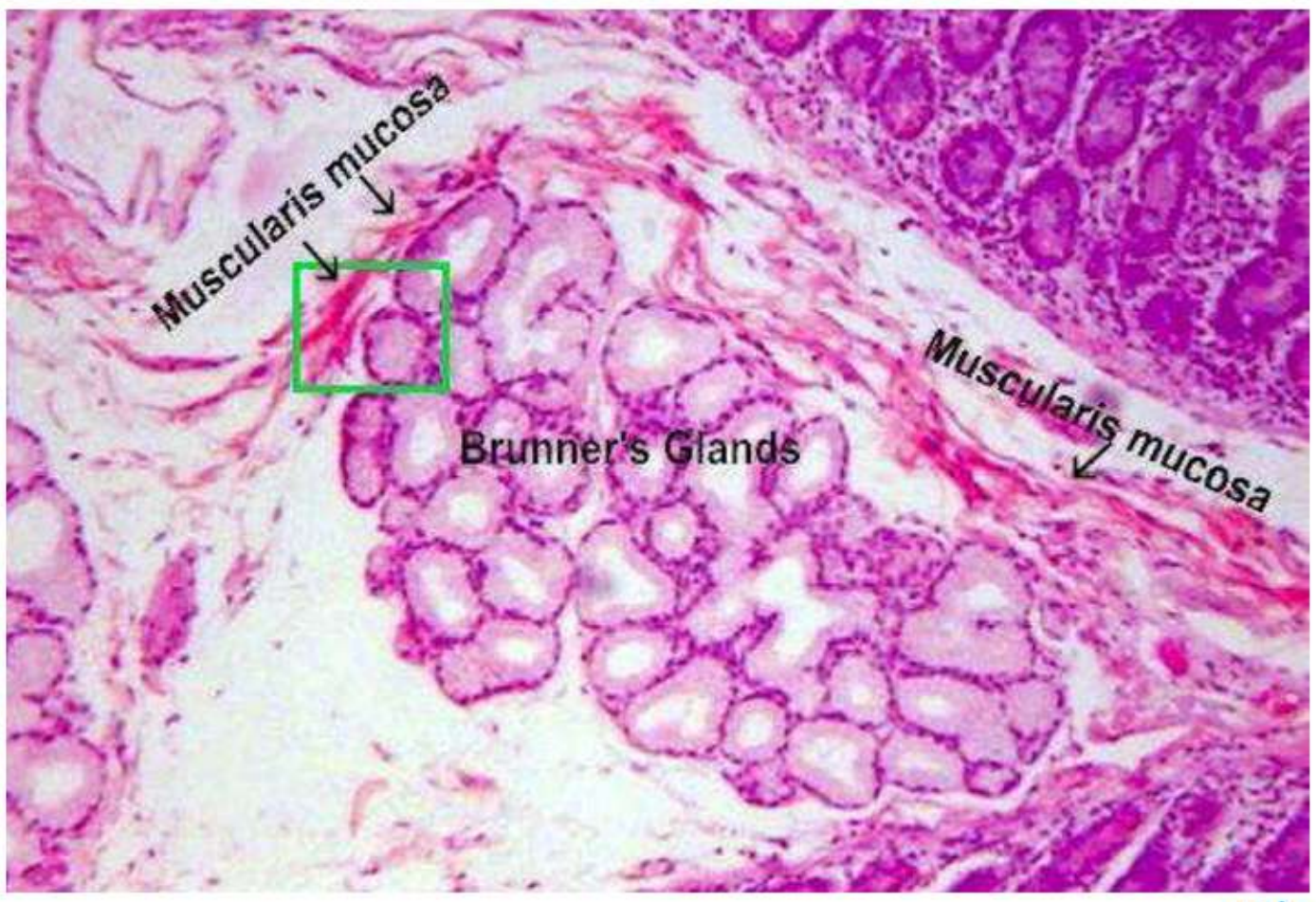

Fig: 5

AfraTafreeh.com

Fig: 6

Large intestine 00:33:43

Important features of large intestine

- Epithelium of appendix, caecum, colon, rectum and upper part of anal canal up to pectinate (Dentate) line is simple columnar epithelium
- Epithelium of middle transitional zone of anal canal → stratified squamous non – keratinizing
- In lower end of anal canal → stratified squamous keratinizing
- Alcian Blue is used to stain Acidic mucin; Ph-2.5

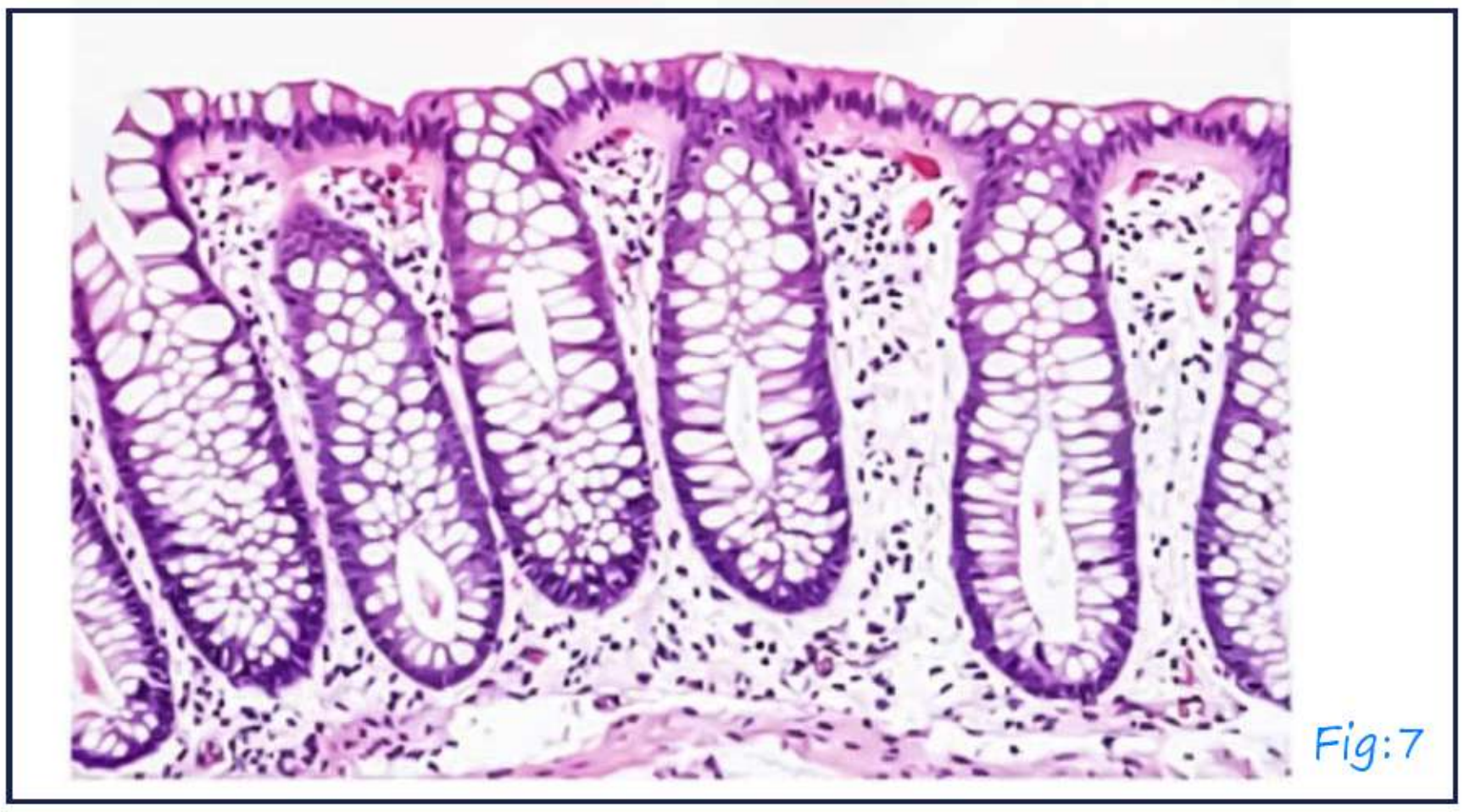

Fig:7

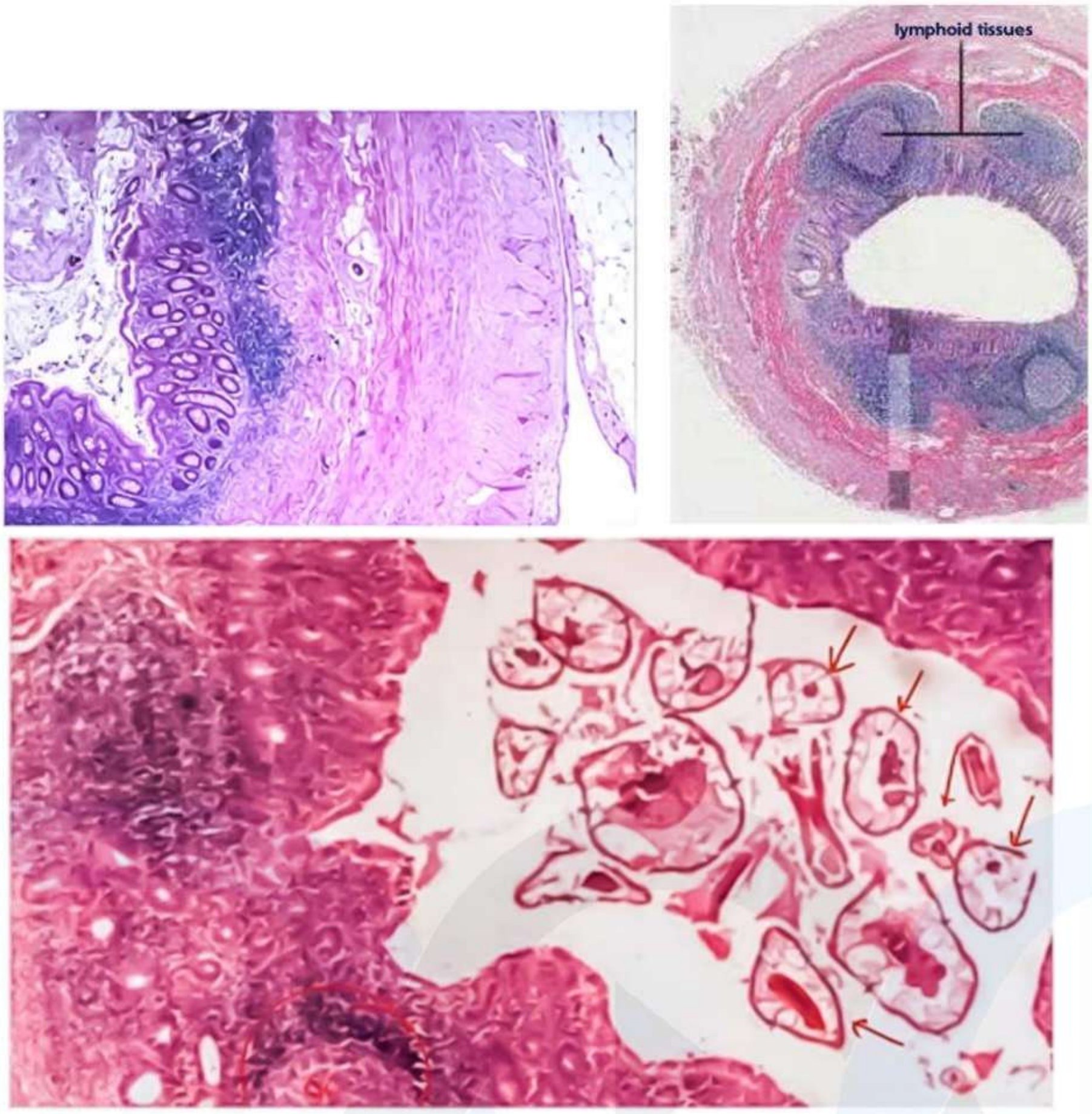

Fig: 8

AfraTafreeh.com
TUTORIALS
LOGIN FOR SUCCESS

AfraTafreeh.com

ESOPHAGUS PART - I

Achalasia Cardia 00:01:59

- Most common disorders of esophagus
- Most common hypo motility disorder of esophagus
- Achalasia means "failure to relax"
- Both the muscle of esophagus and LES are affected
- Premalignant condition → leading to squamous cell carcinoma

Pathogenesis

Myenteric plexus

Excitatory neurons → Release acetylcholine → contraction

Inhibitory neurons → Releases NO, VIP → Relaxation

- In achalasia there is progressive inflammation and selective loss of inhibitory myenteric neurons
- Failure of relaxation of LES and peristalsis of esophageal body [increase tone of LES]
- Functional obstruction at GE junction and gradual dilatation of upper part of esophagus
- Clinical feature – classic triad of <u>Dysphagia, Regurgitation</u> and <u>Weight Loss</u>

Diagnosis

I. Barium swallow dilated esophagus with distal narrowing –Bird Beak appearance

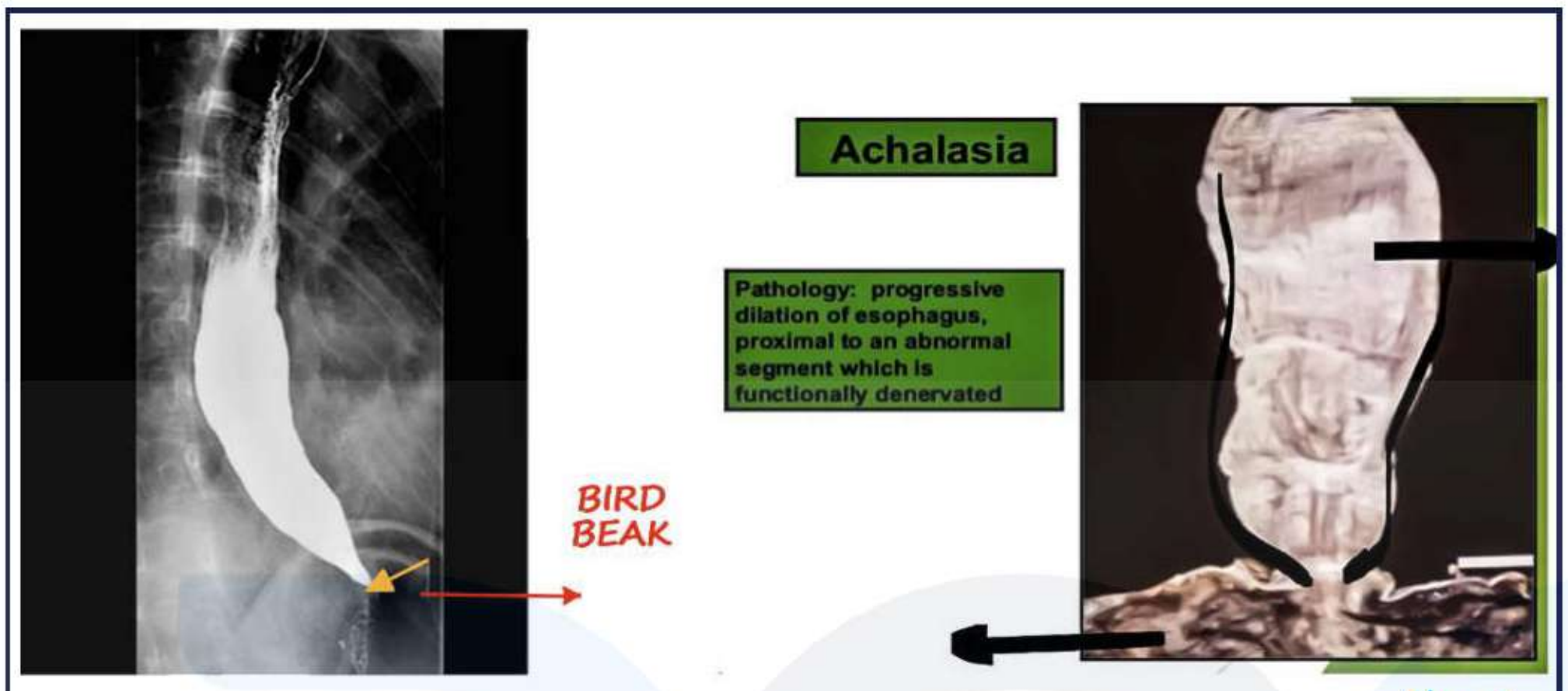

Fig: 1

II. Manometry – Gold standard test

III. Cholecystokinin (CCK) test – Increased tone of LES

IV. Treatment – Laparoscopic Heller's myotomy → operation of choice

AfraTafreeh.com

Esophagitis-Types 00:06:43

DQI TUTORIALS LOGIN FOR SUCCESS

Esophagitis

Types –

i. Reflux esophagitis

ii. Infective esophagitis

iii. Chemical/physical esophagitis

iv. Eosinophilic esophagitis

AfraTafreeh.com

I. Reflux esophagitis

Acute reflux –

i. Mild erosion of epithelium

ii. Basal cell hyperplasia

Chronic Reflux

– columnar metaplasia in esophagus by stem cell reprogramming

Barrett's Esophagus-Pathogenesis 00:07:40

Barrett's Esophagitis

Stem cell reprogramming

↓

Distal squamous mucosa

↓

intestinalized columnar epithelium in the esophagus

↓

Columnar metaplasia (Alcian blue +vie)

or

intestinal metaplasia

- **Metaplasia usually occurs > 1 cm above GE junction**
- Intestinal columnar epithelium of Barrett's – more resistant to acid pepsin and bile,
- Most common cause of Barrett's is chronic GERD> this metaplasia is a type of cellular adaption and is reversible if injurious stimulus is removed.
- Clinical feature = Higher incidence in whites, males and obese

- Long history of heartburn and other reflux symptoms
- major risk factor for adenocarcinoma

Barrett's Esophagus-Diagnosis 00:11:51

Diagnosis

i. Endoscopy

- **<u>Red velvety</u> GI type mucosa (Salmon red appearance** between pale <u>squamous mucosa of lower esophagus</u> and lush pink gastric mucosa
- May have tongues extending up from GE junction
- Can show Barrett's ulcer

Fig: 2

ii. Biopsy

- 8 random biopsies recommended
- Report should include presence/absence of dysplasia, grade of dysplasia and extent of dysplasia

iii. Positive stains

AfraTafreeh.com

- Intestinal goblet cells contain acid mucin usually sialomucin → stained with alcian blue at PH 2.5

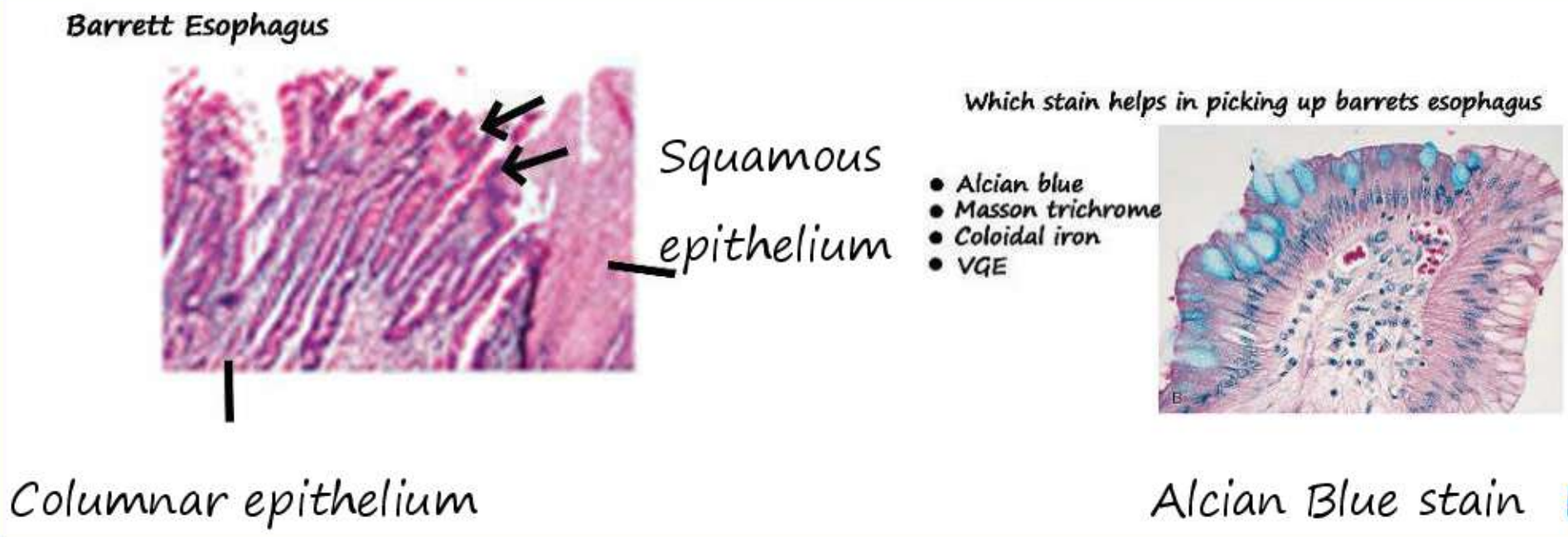

Fig: 3

Alcian Blue/PAS Stain

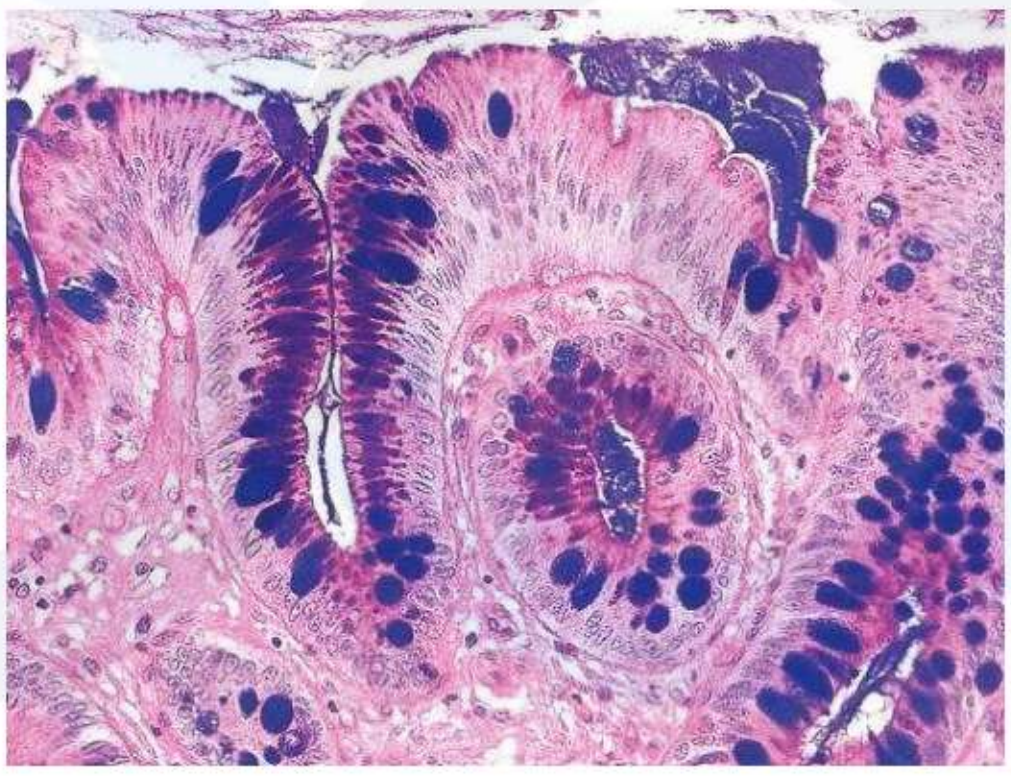

Fig: 4

Barrett's esophagus classification 00:21:06

Classification of Barrett –

I. Long segment – > 3 cm of metaplasia

II. short segment – < 3cms of metaplasia

Riedel and Vienna classification

1. No dysplasia
2. Indefinite/Indiscriminate
3. Low grade dysplasia
4. High grade dysplasia
5. Carcinoma

- In [85% presentation is as intramucosal Carcinoma], while [15% present with invasive carcinoma].
  Note: H. Pylori infection is protective against Barrett's esophagus
- Therefore, H. pylori infection is protective against adenocarcinoma esophagus

Treatment

- Anti-reflux therapy
- Endoscopy every 1-2 years to detect dysplasia or early adenocarcinoma.

AfraTafreeh.com
TUTORIALS
LOGIN FOR SUCCESS

AfraTafreeh.com

ESOPHAGUS PART – II

Infective esophagitis 00:00:05

Cytomegalovirus infection (CMV)	Herpes Simplex Virus (HSV)	Candidial esophagitis
1) Shallow Linear Ulcer Pathology 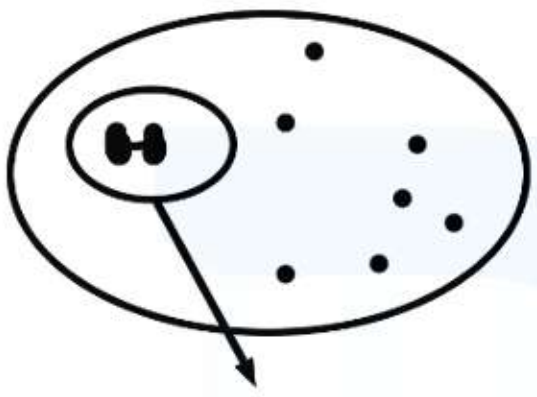 a) Dark Basophilic owl-eye like inclusions. In nucleus with perinuclear halo. b) Coarse inclusions in cytoplasm CMV are seen at the base of ulcer in endothelial or stromal cells. 	1) Punched out ulcers /Volcano ulcers 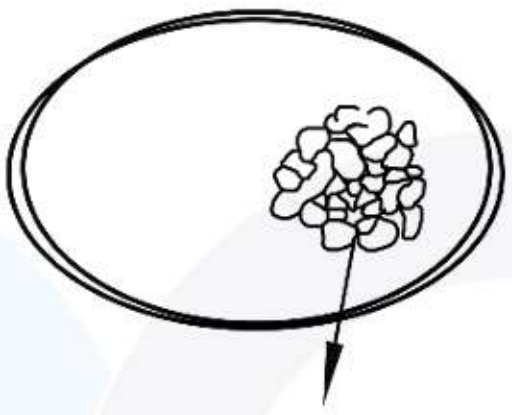 a) Multinucleated b) Margination of chromatin c) Moulding HSV is seen at the margins of the ulcer 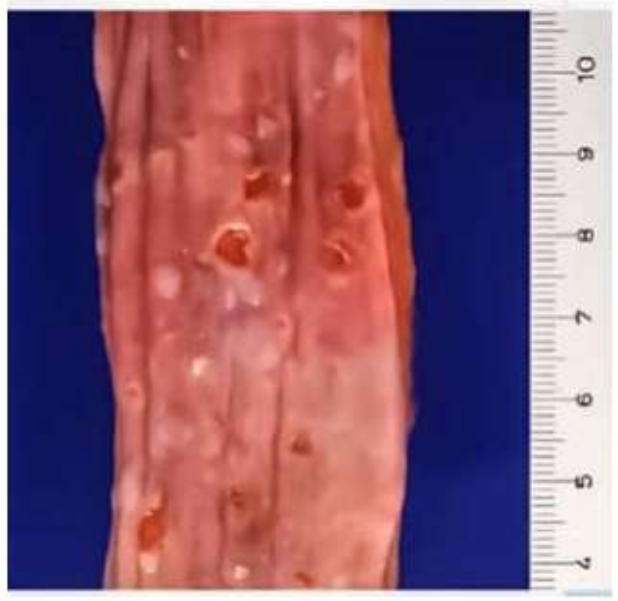	1) Pseudomembrane formation 2) Commonly affects immunocompromised individuals 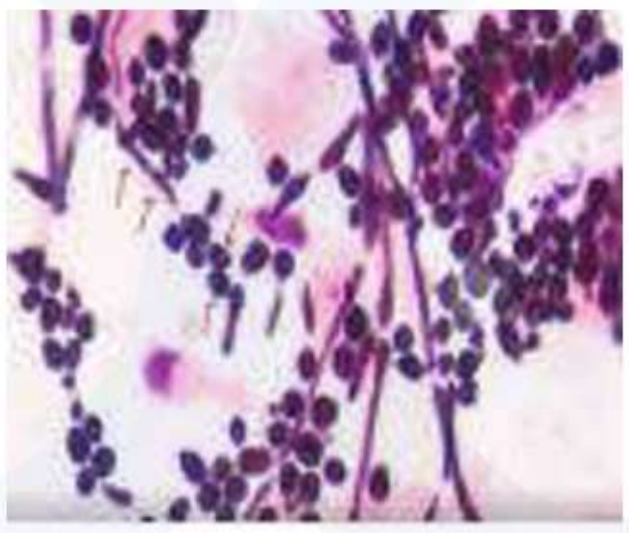 a) Spores b) Pseudo hyphae

Eosinophilic Esophagitis 00:11:00

- Caused by presence of large number of eosinophils in the esophagus
- The production and accumulation of eosinophils may be caused by immune hypersensitivity responses to particular goods or environmental proteins (allergens)

Pathogenesis:

- Immune cells especially TH2 activated

↓ Release

IL5

↓ activates

Eosinophils

↓ Release

PDGF

→ Eosinophilic cationic proteins → Cause injury and inflammation of esophagus

→ TGE β → Cause fibrosis in esophagus

→ PDGF → Cause fibrosis in esophagus

→ INFLAMMATION + FIBROSIS

- It is an important cause of dysphagia in adults and GERD in children

AfroTafreeh.com

AfraTafreeh.com

Diagnosis

- Microscopically: - At least 15 Eosinophils/high power field should be present
- Gross: Horizontal bands seen in esophagus because of fibrosis -> Labelled as Feline esophagus

Fig: 1

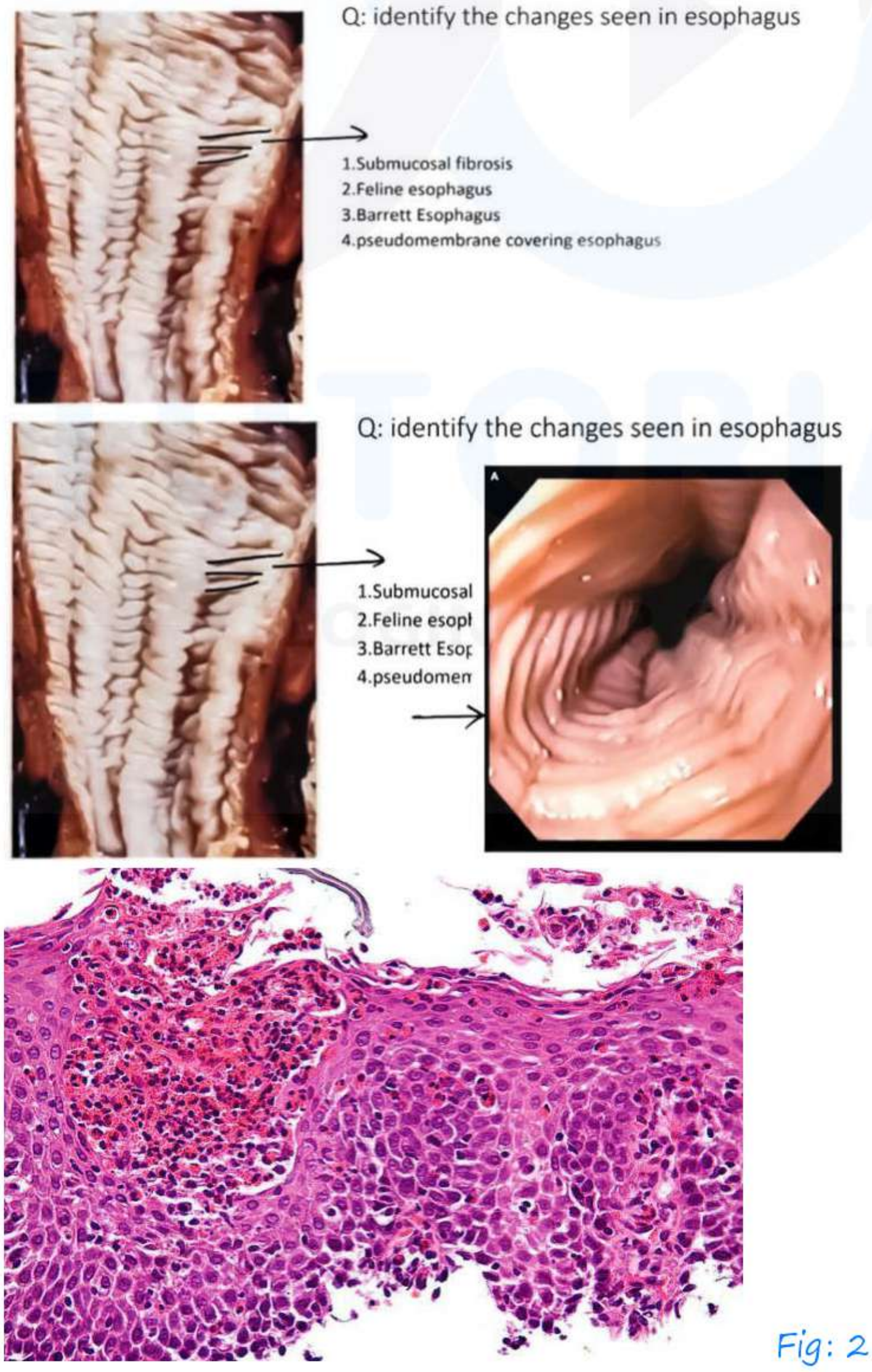

Fig: 2

Oesophageal tear 00:17:30

Tear in esophagus

Mallory Weis Tear	Boerheave Syndrome
•Tear in mucosa and sub mucosa only Related to forceful vomiting, retching. coughing or straining causing linear tear (alcoholic intoxication) •Results in disruption of gastric mucosa high on lesser curve at cardia (just below GE junction) •Clinical features Hematemesis Rx- Supportive Therapy because 90% of bleeding episodes are self-limited and the mucosa often heals within 72 hours	•Spontaneous rupture usually on left posterolateral side of distal esophagus into left pleural cavity •Typically, male 40-60 years •History of recent emesis Clinical features: Mackler's Triad 1.Thoracic pain and shock 2.Vomiting 3.Cervical subcutaneous emphysema (Mediastinal emphysema and pleural effusions are common Rx-Resuscitation, Broad spectrum antibiotics ICU management

AfraTafreen.com

AfraTafreeh.com

Esophageal webs and rings 00:22:15

Esophageal webs and Rings

Plummer-Vinson syndrome	Schatzki Ring
• Also known as Patterson- Kelly syndrome • Characterized by 1) Dysphagia to solids 2) Iron deficiency anemia 3) Koilonychia 4) Angular stomatis 5) Glossitis-> Beefy red tongue • Dysphagia is due to thin webs in post-cricoid area at upper esophagus • Webs are either mucosal web or fibro mucosal web. • Usually seen in postmenopausal females • Increased risk of squamous cell Carcinoma upper GIT	• Concentric Symmetric narrowing of lower esophagus precisely at the squamo-columnar mucosal GEJ • Narrowing or ring involves the mucosa and submucosa. Does not have a component of true esophageal muscle nor is it associated with esophagitis. • Consists of esophageal mucosa above the constriction and gastric mucosa below • Barium swallow image showing Schatzki Ring Schatzki Ring type 'B' is located at GE junction

ESOPHAGUS TUMORS

Esophageal Tumors

- Benign
  - Most common benign tumor of esophagus → leiomyoma
- Malignant
  - Lower segment ↓ Adenocarcinoma ↓ Upper and middle segment ↓ Squamous cell carcinoma

AfraTafreeh.com

Leiomyoma 00:02:00

- Most common Benign esophageal tumor
- Average age 4th-5th decodes more common in males
- Originate in smooth muscle, 90% are located in **lower two thirds of the esophagus**
- Usually solitary & typically ovel
- They remain intramural with the bulk of their mass protruding towards the outer wall
- The overlying mucosa is freely movable and normal in appearance Clinical features Dysphagia and pain are Most common symptoms

AfraTafreeh.com

Diagnosis

i. Endoscopy-Freely movable mass, bulging into the lumen

Fig: 1

ii. Barium swallow IOC-Classical smooth contoured punched-out defect

iii. On Cut Section-Benign interlacing spindle shaped cells with Cigar shaped nucleus arranged in whorls

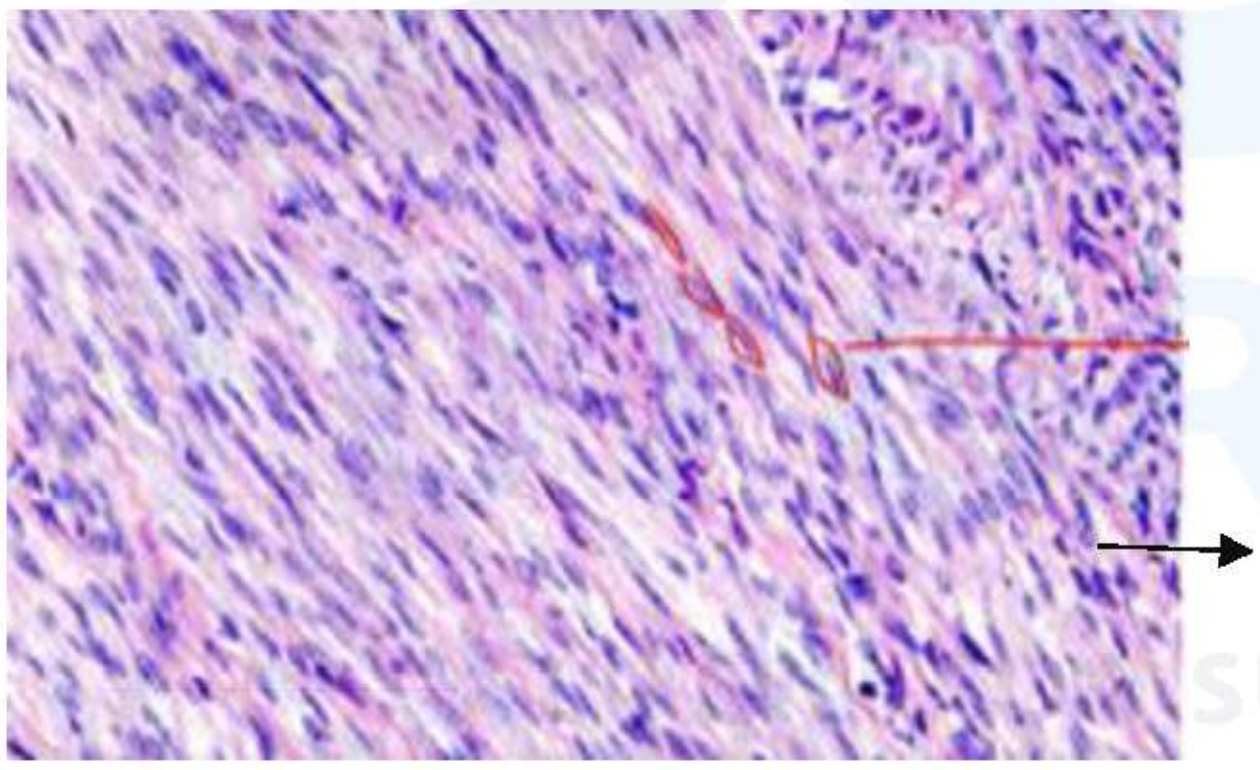

Spindle shaped cells

Cigar shaped nucleus

Fig: 2

- THC-positive for Smooth muscle Actin (SALA) and Vimentin
- SMA is a better marker for Smooth muscle tumors
- Special stain-On Mats Trichome muscle appears red in color

Remember

- Leiomyomas in esophagus should not be biopsied because of an increased chance of mucosal perforation at

Malignant lesions of esophagus

1. Adeno carcinoma esophagus
   - Predisposing factors
     i. GERD (Leading to Barrett's esophagus)
     ii. Obesity
     iii. Scleroderma

   Scleroderma – smooth muscle atrophy in Lower 2/3rd of esophagus

   ↓

   Incompetent LES

   ↓

   GERD

   ↓

   Stricture

   ↓

   Adenocarcinoma

     i. Diet deficient in fruits and vegetables
     ii. Diet high in animal protein and cholesterol
     iii. Theophylline

Protective: -

i. H. Pylori CAG-A strain is protective
ii. Diets rich in fruits and vegetables

AfraTafreeh.com
TUTORIALS
LOGIN FOR SUCCESS

AfraTafreeh.com

Pathogenesis

- Genetic mutation in adenocarcinoma

1st mutation → **P53 mutation**

↓

Loss of **Rb gene** and loss of **P16 gene** — early mutations

↓

Her t2 neu/ERB-B2 Amplification

↓ — Late mutations

Cyclin D1 mutation

- Gross: - Circumferential papillary lesion or ulcerative polypoidal lesion
- Microscopy: - Atypical glands infiltrating stroma
- Gross of adenocalinoma

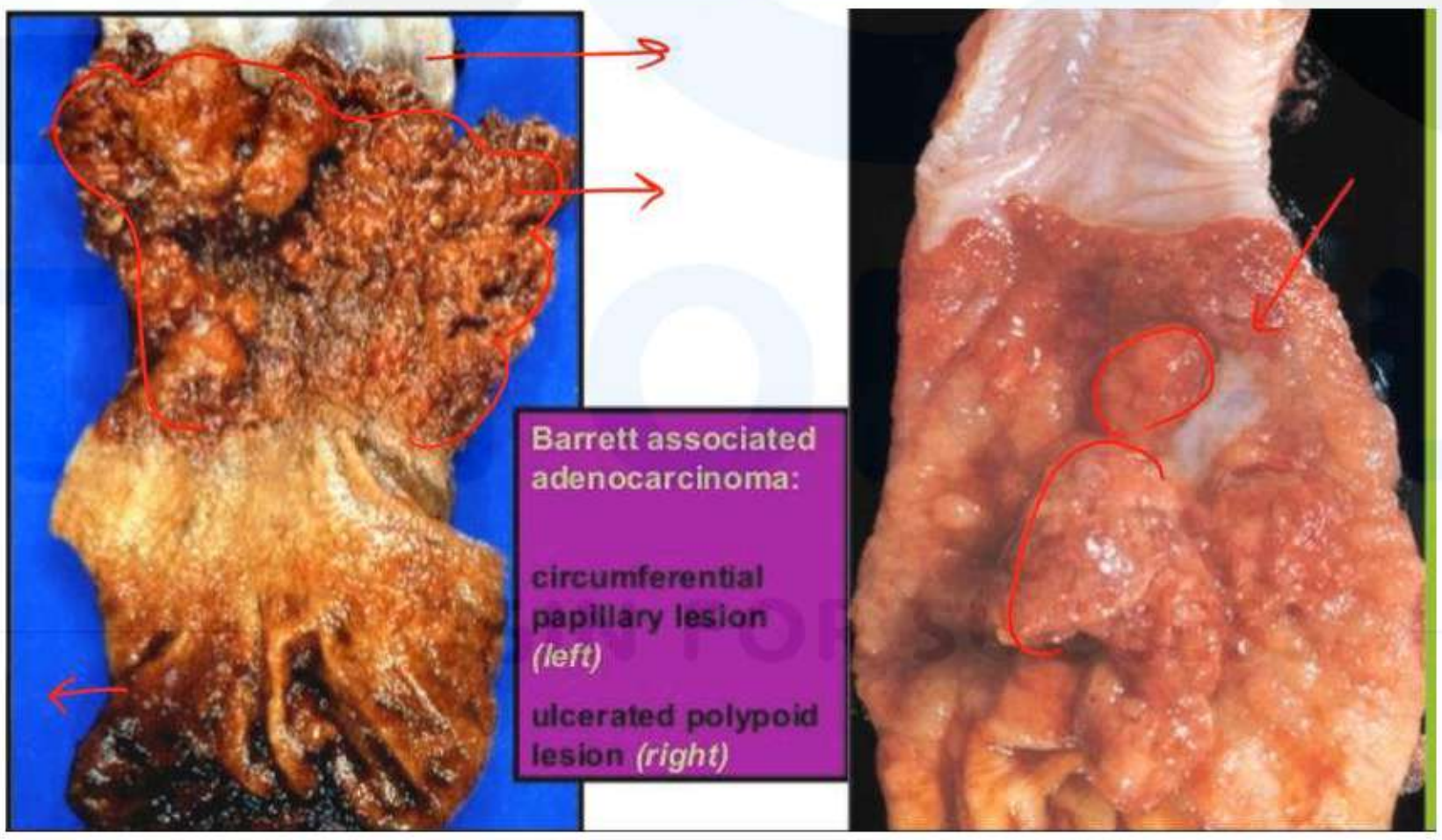

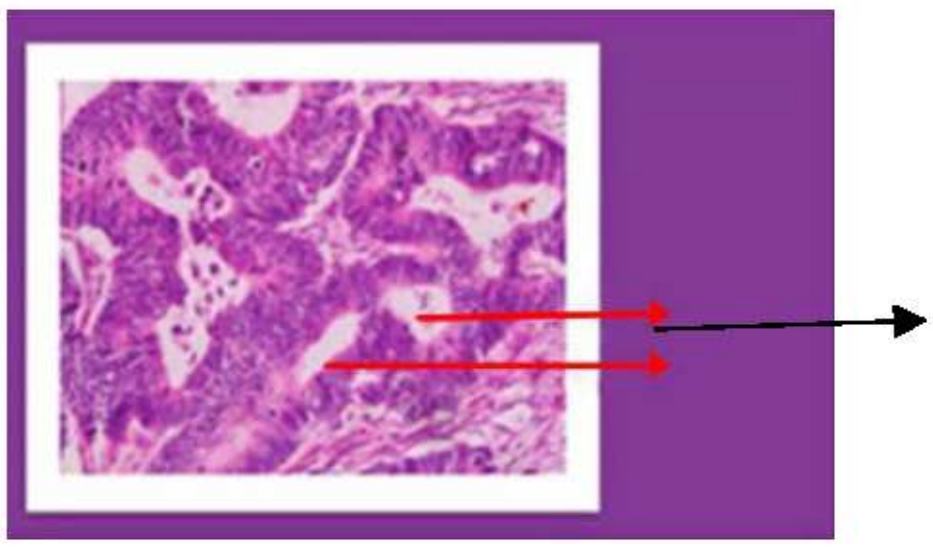

Fig: 3

Squamous cell carcinoma esophagus 00:10:49

Predisposing factors - ABCDE

i. Alcohol, smoking
ii. Hot beverages
iii. Celiac diseases, carbons
iv. Chronic achalasia
v. Ingested carcinogen
- Nitrates – nitrosamines
- Smoked opiates
- Fungal toxins in pickled vegetables

vi. Lye (caustic) ingestion
vii. Radiation
viii. Deficiency of vitamin A, Zinc
ix. Ectodermal dysplasia
x. Epidermolysis bullosa
xi. HPV infection
xii. Plummer Vinson syndrome
- Tylosis palmaris at plantaris – Congenital hyperkeratosis and pitting of palms and soles
- Gross: - Ulcerative lesions – present with dysphagia
- Exophytic lesions – present with symptoms of obstruction

AfraTafreeh.com

AfraTafreeh.com

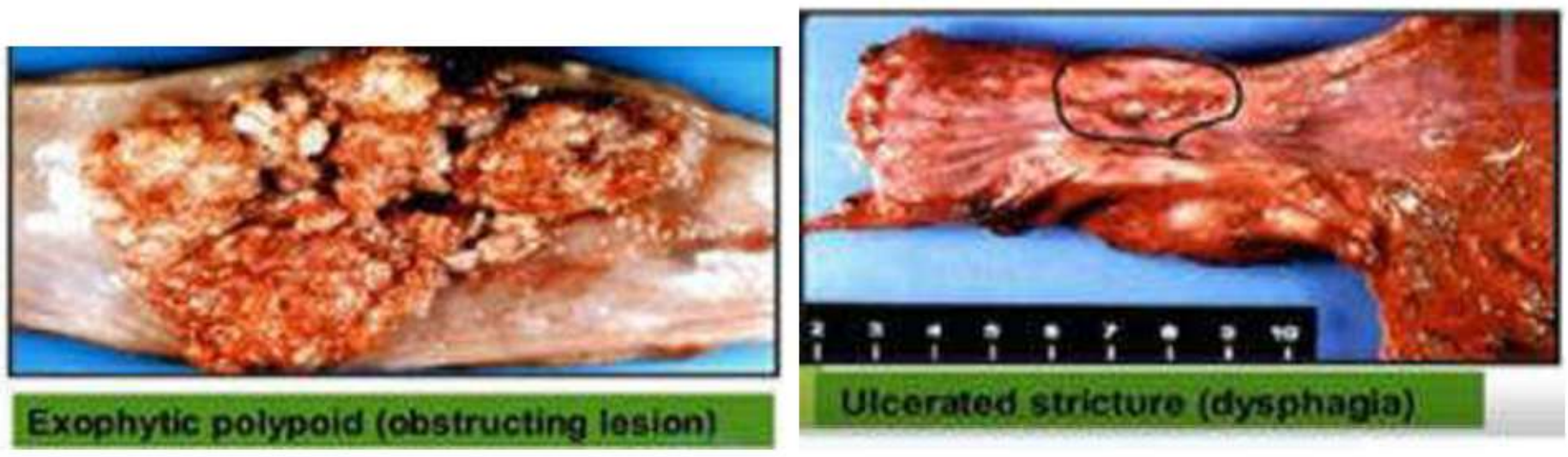

Fig: 4

- Microscopy – Keratin earls indicate well differentiated SCC

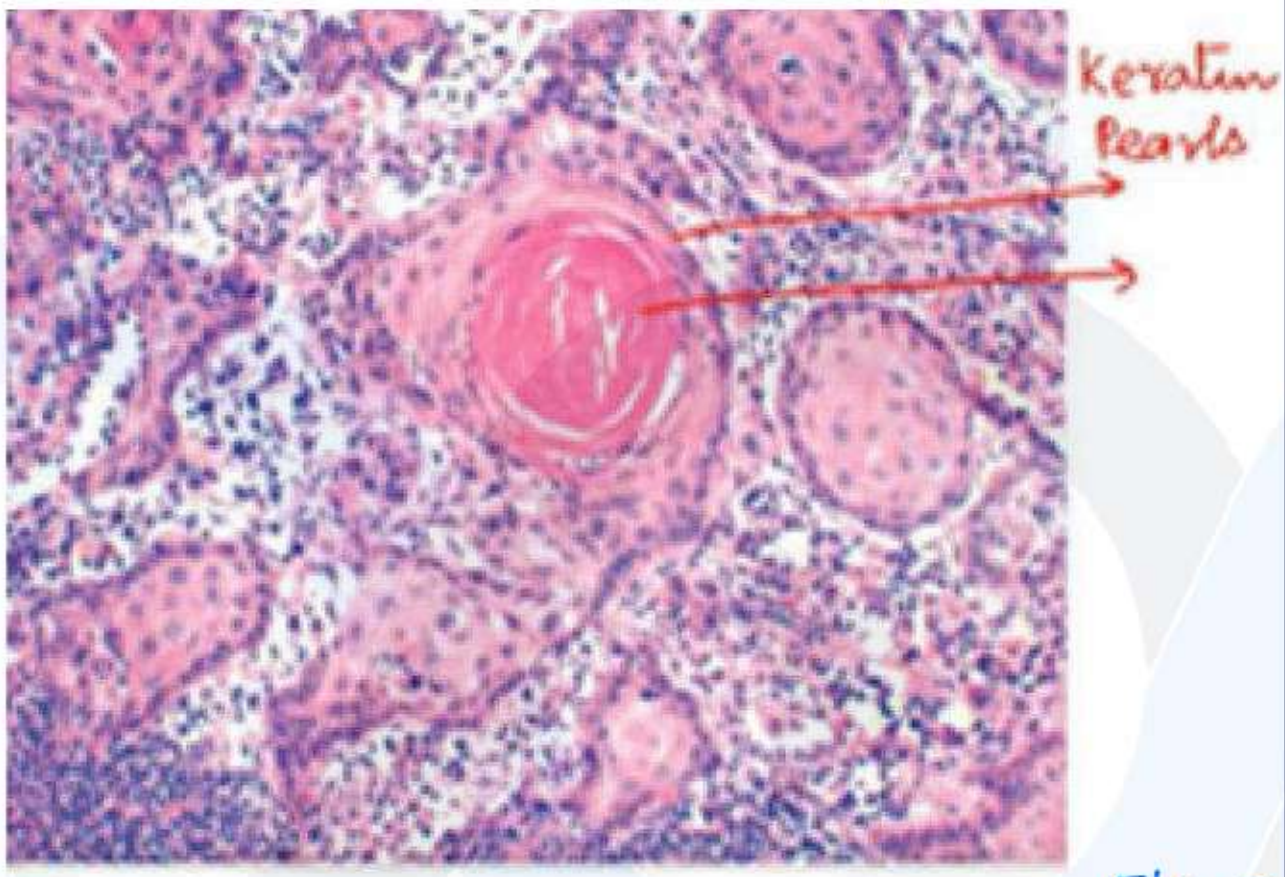

Fig: 5

- Well differentiated SCC
- Remember – SPX2 mutat6ions are seen in SCC of esophagus

Update

- MURSIK – Type of traditional fermented milk variant sold in kenya
- MURSIK has acetaldehyde which causes SCC Esophagus there by it is infamously also called kenya poison or kenya weapon
- SOX2 mutation → causes SCC of esophagus.

GASTRITIS, GASTRIC ULCER AND H PYLORI

Gastritis 00:00:30

- Inflammation of Gastric Mucosa

Acute Gastritis
↓
Infiltration of Neutrophils into epithelium

Chronic Gastritis
↓
mononuclear cell infiltration (Lymphocytes and plasma Cells)
↓
Results in Gastric Atrophy

AfraTafreeh.com
TUTORIALS
LOGIN FOR SUCCESS

Acute Stress Ulcers/ Gastritis 00:06:35

<u>**Curling Ulcers**</u>	<u>**Cushing Ulcer**</u>
• Seen in Burns involving >35% of BSA • Ulcers are seen in **Proximal Part of Duodenum** • Usually, Superficial ulcer	• Due to intracranial disease (Head Trauma • Ulcers are seen anywhere in GIT – Oesophagus, Stomach, Duodenum Increased acid secretion in Cushing's ulcer but not in Curling ulcers • In Stomach, **Cardia is most commonly involved** • The Ulcers are deep and risk of preparation is high.

AfraTafreeh.com

Chronic Gastritis

Type B Gastritis

- Due to H. Pylori Infection
- Gram negative Flagellated Bacteria
- Gastric antrum is M/C site of Colonization.
- Survives deep in mucus layer near epithelial surface

Virulence Factors

i. Flagella

ii. Bab A Toxin-Sticks to blood group antigen Preference for Blood group-O and Lewis b (acts as a receptor for H. Pylori

iii. Cag A, Vac A – Proliferation of epithelial cells

iv. Urease - Provides ammonia to buffer acid

Urea —Urease→ Ammonic (NH3)

Urea Breath test based on Urease activity

Radiolabeled Urea

Type A Gastritis

- Autoimmune
- Ab against parietal cells (H+ K+ ATPase Pump)

↓

Atrophy

↓

Chronic Atrophic Gastritis

- Presents with Pernicious anemia Hypochlorhydria
- Many have other autoimmune diseases including Vitiligo Hashimoto's
- Affects Fundus and body spares Antrum

urease

Urea ⟶ NH3 ⟶ CO_2

CO2 Detected in breath

Pathology of H. Pylori colonization

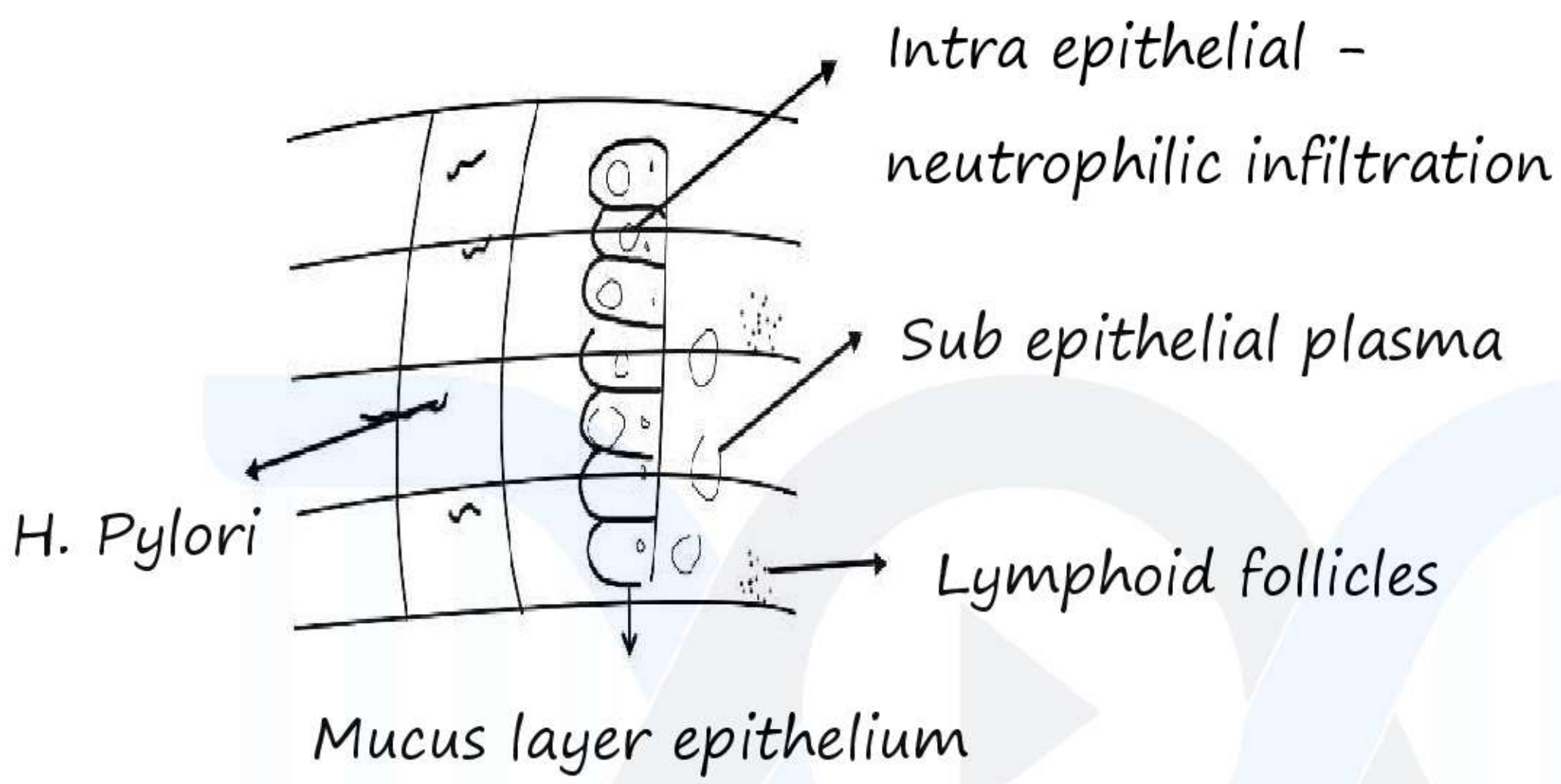

AfraTafreeh.com
TUTORIALS
LOGIN FOR SUCCESS

AfraTafreeh.com

H-Pylori Causes

Pan Gastritis	Type B Gastritis (most common)	Adenocarcinoma Stomach
Low Gastric acid More cytokines ↓ **Pan Gastritis with multifocal atrophic gastritis** ↓ Increased risk of **adenocarcinoma stomach**	Increased Gastric acid Lees Inflammatory cytokines **(TNF/IL1B)** ↓ High chance of **duodenal ulcers** ↓ **Antral** Predominant Gastritis	(Following pan gastritis) i. MALToma + (11,18) ii. 90% of Duodenal Ulcer 75% of Gastric Ulcer iii. Extra intestinal Pathologies Linked To H-Pylori •Cerebrovascular disease •IHD

DOC TUTORIALS LOGIN FOR SUCCESS

GIST

Involvement of **Fundus Body** Antrum Spared → Autoimmune Gastritis type A

Antrum Involved → type B gastritis Type B Gastritis Most common with H. Pylori

Pan gastritis →H. Pylori – When gastric acid is lees but cytokines are high

Diagnosis of H-Pylori Infection 00:27:22

i. Biopsy is the gold standard diagnostic test for H. pylori

Special stains are used

- silver stains
  - Stainer (Preferred)
  - Warthin Starry (also used for spirochetes)
- Giemsa/Acridine Orange (also used for detection of malaria

ii. Biopsy – Rapid urease test on Gastric mucosal biopsy is 100% specific test

AfraTafreeh.com

iii. IHC against H. Pylori

Recent update: H. Pylori implicated with **idiopathic thrombocytosis**

TUTORIALS
LOGIN FOR SUCCESS

AfraTafreeh.com

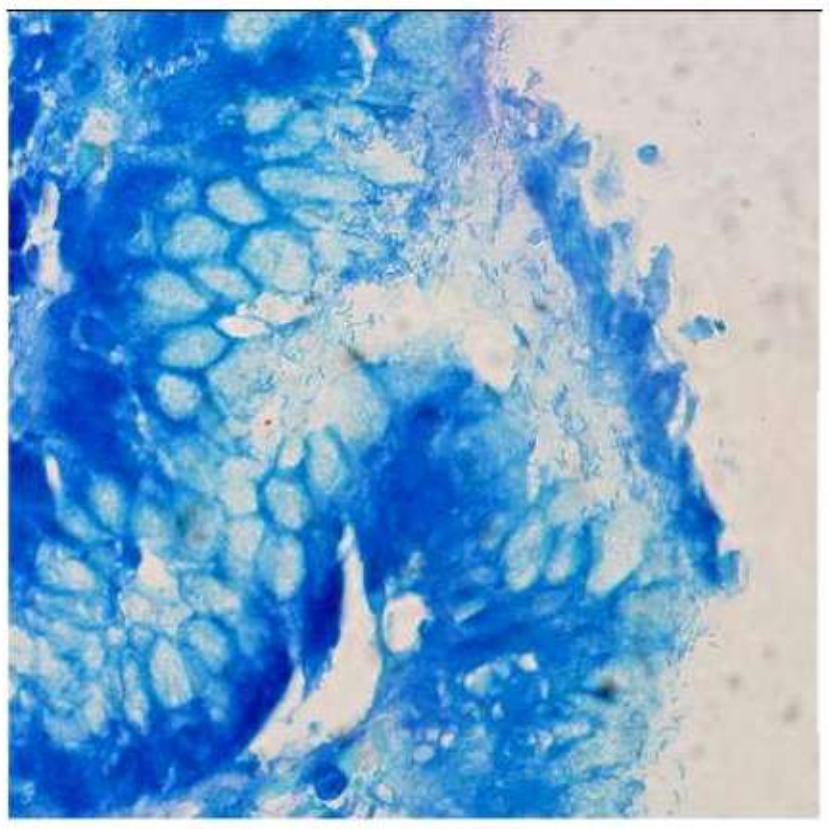

purpura (ITP)

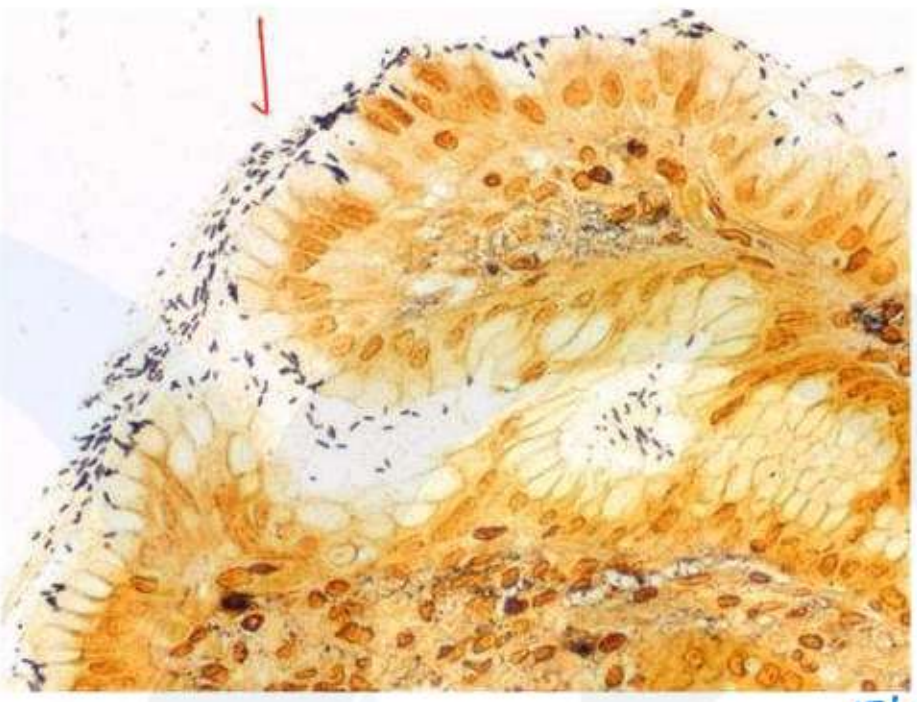

Fig: 1

Gastropathies

- Unlike Gastritis, Gastropathies are not characterized by inflammation

<u>Menetrier Disease</u>	<u>Zollinger Ellison Syndrome</u>
•Increased TGF-alpha ↓ Excessive Proliferation of Gastric Foveolar (mucus) cells ↓	• ZES occurs in two forms Sporadic 75% MEN-I associated 25% -Gastrinoma is MC Functioning malignant NET of Pancreas

Foveolar Hyperplasia with absent parietal cells ↓ Massive Gastric Folds in the Fundus And corpus of Stomach ↓ Cobblestone or Cerebriform appearance • Associated with CMV infection in children and H-Pylori Infection in Adults • Excessive Mucus production. • Hypochlorhydria or achlorhydria • Protein loss On Biopsy – Typical gastric mucosal changes	– M/C site of Gastrinoma ↓ Duodenum > Pancreas Gastronome → ↑ Gastrin secretion ↓ Stimulation of Parietal cells of Stomach ↓ Gastric Acid hypersecretion ↓ Peptic Ulcer On Biopsy-Stomach appears very pink due to Hyperplasic Parietal Cells

AfraTafreeh.com
TUTORIALS
LOGIN FOR SUCCESS

AfraTafreeh.com

Watermelon Stomach (Gastric Antral Vascular Ectasia)

- Presence of Both inflammatory and Vascular components in mucosa

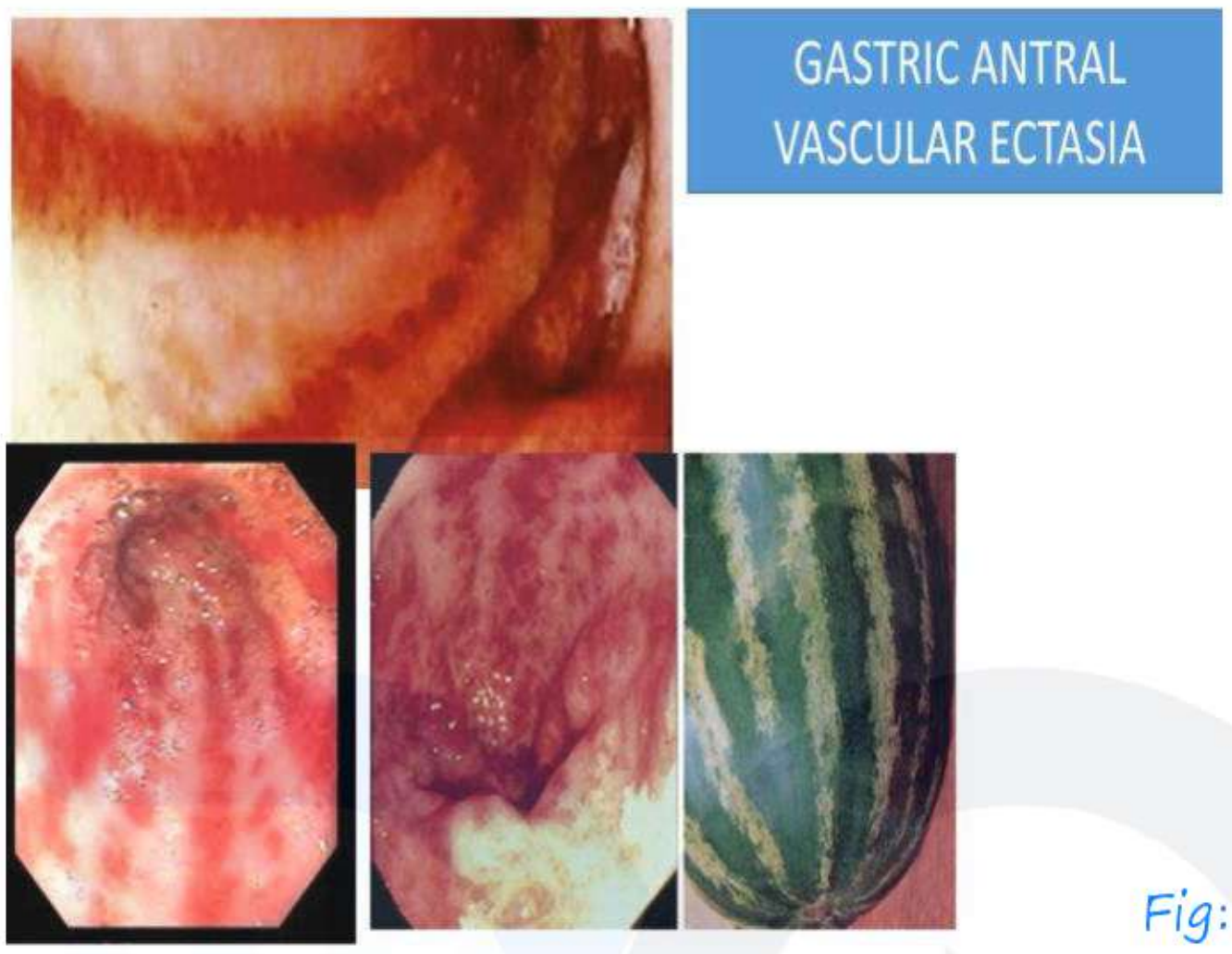

Fig: 2

Pathology

- Dilated mucosal blood vessels in the lamina propria, often containing thrombi
- Predominantly affects Distal portion (Antrum) of the Stomach
- At least 25% have chronic liver disease or systemic Sclerosis
- Clinical features - Presentation is generally of elderly women with chronic bleeding, iron deficiency anemia
- Diagnosis-Typical endoscopic and biopsy appearance of mucosa
- Endoscopic Appearance - Prominent longitudinal folds with parallel striking red stripes alternating

with pale mucosa in the distal stomach much like the rind of a watermelon

Gastric Ulcer

Benign Ulcer	**Malignant Ulcer**
•Generally, at lesser Curvature •Mucosal rugae project outwards from margins of ulcers •Overhanging margins •Penetrating sign (Ulcer crater projects into stomach wall) •Punched out ulcer, Solitary	•At Greater Curvature •Mucosal rugae stop far from the ulcer •Heaped up Margins •Carman meniscus sign (meniscoid appearance of Trapped Barium in ulcer bed)

AfraTafreeh.com
TUTORIALS
LOGIN FOR SUCCESS

AfraTafreeh.com

GASTRIC POLYPS AND STOMACH TUMORS

Gastric neoplasms

- Polyps
- Cancers

Gastric Polyp		
Fundic polyp Becoming commoner due to Rampant use of PPI PPI → acidity decreased ↓ gastrin levels ↑ ↓ Proliferation of parietal cells Fundic polyp	**Hyperplastic polyp** M/C type in response to H. pylori infection H pylori ↓ ↓ Cog AVOCA \ / Proliferation of epithelial cells in stomach typically occurs in **Antrum Usually solitary**	**Adenomatous polyp** • Premalignant • Common site is Antrum

NEOPLASMS

Benign

N/C Benign tumor of stomach is Leiomyoma

Malignant

Epithelial

1) Adenocarcinoma
2) Diffuse stomach cancer

Stromal

malignancy GIST

Lymphoma

MALToma

Follicular – lymphoma

- New addition by WHO in Gastric malignancies is **Lymphoepithelial type Carcinoma**-usually associated with EBV
  - Most Common Cancer with EDV is Stomach Cancer (Lymphoepithelial type Gastric Carcinoma)

Lauren Classification of Carcinoma stomach

Intestinal	Diffuse
• Environmental • Gastric atrophy, intestinal metaplasia • Man > Woman • Increasing incidence w/ age • Gland formation • Hematogenous spread • Microsatellite instability • APC gene mutations • P53, p16 inactivation • Distal part of stomach	• familial • Blood group A • Younger age group • Poorly differentiated **signet ring cells** 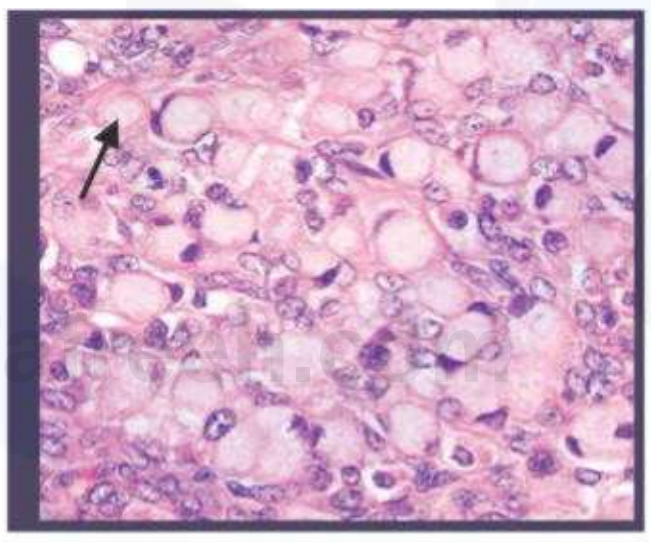 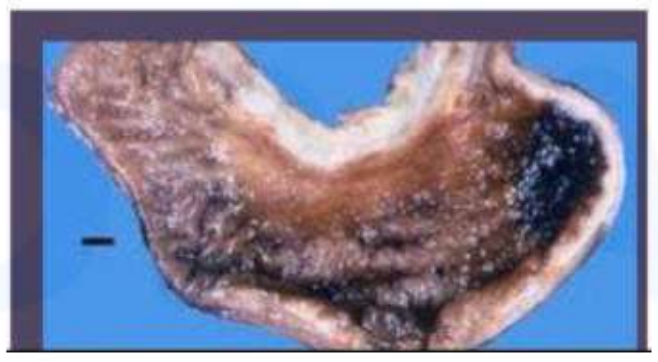 • Transmural/lymphatic spread • Loss of CDH1-loss of E-Catherin calls leads contact inhibition • P53, p16 inactivation • endemic • proximal part of stomach • Extensive Desmoplasia of stomach wall Linitis plastica • Metastasis of B/L ovaries-krukenberg /tumor Metastasis to umbilicus **sister Mary joseph nodule.**

AfraTafreeh.com

GIST-Gastro Intestinal Stromal Tumors

00:08:50

- M/C Mesenchymal tumor of GI tract
- M/C Primary site for GIST-Stomach

Pathology

- Arises from Intestinal cells of Cajal
- Mutations- **KIT>PDGFRA> WILD TYPE GIST(10PERCENT)**
- M/c mutation is of **Receptor Tyrosine kinase KIT (CD 117)**

So, KIT mutation PDGFRA

- PDGFRA mutations confer a very favorable prognosis with low risk of recurrence
- Gross: - Submucosal mass with intact overlying mucosa

Fig: 1

- Microscopy-Proliferation of spindle shaped cells. But no whirling

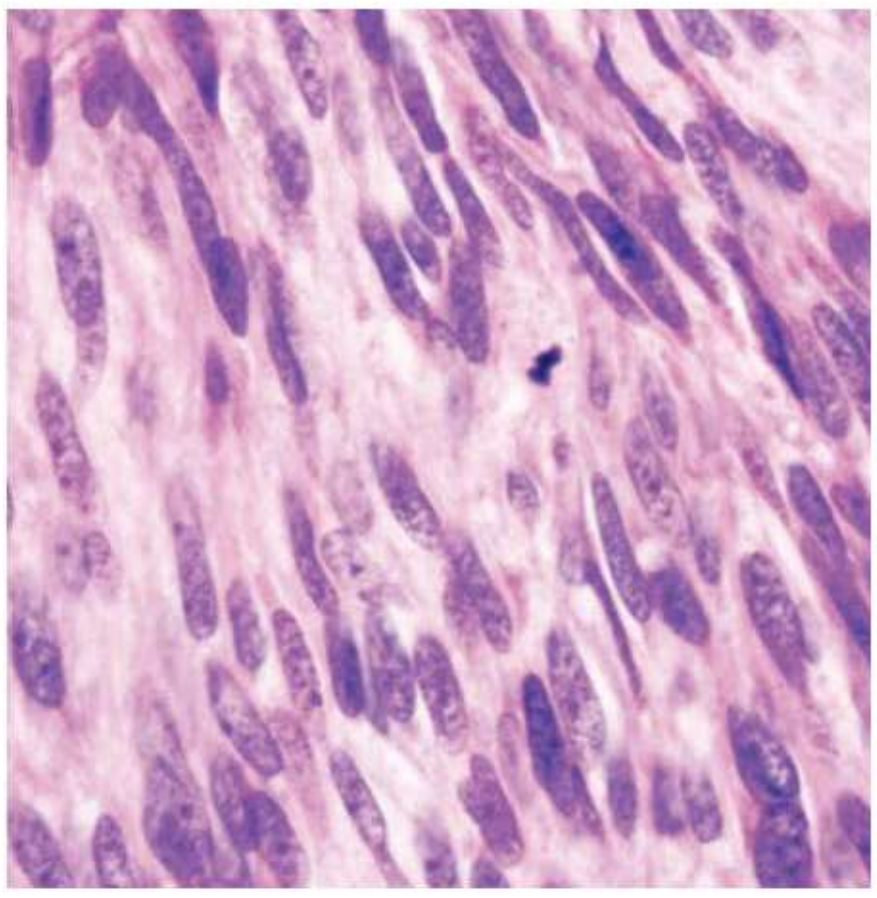

- Most common site (>50% is stomach; > small intestine (30%) colon and rectum
- Most common mutation is KIT (80%) > PDGFRA (8%) > SDH mutations

- **IHC – positive for KIT/ DOG-1**
- DHC-positive for KIT/DOG-1
- (DOG-Diagnostic of GIST)
- Rx-Imatinib (Selective inhibitor of Type 3 Tyrosine Kinase KIT)

Wild type gist/SDH deficient GIST 00:12:56

AfraTafreeh.com

- Do not have KET/PDGFRA mutation
- They lack enzyme **SuccinylDehydrogenate Type B (SDH-8)**
- Typically occur in children Girls >Boys
- Associated Syndromes-Carney's Triad or Carney Stratakis Syndrome

  Carney's Triad: -Para-gangliomas; GIST; Pulmonary Chondromas

  Carney Stratakis Syndrome-Paraganglioma- GIST; Good Prognosis
- Resistant to Imatinib
- Onco-metabolic Therapies under Trials

AfraTafreeh.com

Gastritis lymphoma 00:16:35

- Stomach is most common site for lymphoma in GIT
- Most common site of gastric lymphoma – Antrum
- Most common gastric lymphoma is diffuse large B cell lymphoma > MALToma> follicular lymphoma
- DLBL is most common type of NHL extra nodal lymphoma and GI lymphoma
- Stomach is the most common site of MALT lymphoma t (11,18)
  - Clinical features – older patients (6th to 7th decade)
  - More common in men
  - Vague symptoms like epigastric pain, anemia
  - MALT → confined to gastric wall for long time
  - Reverses with therapy.

DX TUTORIALS
LOGIN FOR SUCCESS

MALABSORPTION SYNDROMES WITH FOCUS ON CELIAC DISEASE

Celiac sprue	Whipple's disease	Tropical sprue
• Auto immune • HLA DQ2 >HLADQ8 polymorphism	• Due to infection by trophyrema Whippeli	• Infective etiology • Most common causative organism is – endemic E. coli • Also known as Environmental enteropathy.

AfraTafreeh.com

Celiac sprue 00:04:30

- Gluten – induced enteropathy caused by intolerance to gluten
- Gluten is present in wheat, Rye, Oats, Barley [WROB]- Gliandin is the alcohol soluble component of gluten.

Gluten

↓ Breaks down to

Gliandin

↓

Processed by **Tissue Transglutaminase (TTG)** in enterocytes

↓

TTG

AfraTafreeh.com

Gliadin → Deamidated Gliandin

B cells
↓
antibody production
↓
1) Ab against Deamidated Gliandin
2) Anti TTG Ab
3) Anti – endomysial anti body either IgG or IgA

Picked by APC [DQ2/DQ8 polymorphism]
↓
CD4 cells
↓
IFN gamma
↓
Damages villi

- In patient's intolerant to Gluten → intestinal cells start producing lots of IL15 response to Gliadin

GLIADIN
↓
Intestinal cells → IL 15 ↑↑
⊕ ↓
CD 8 cells – NKG2D
(CD8 cells expressing activating receptors of NK cells)
↓
CD8 cells infiltrate epithelium

WROB foods

(CD4)
↓
IFN-GAMMA
↓
villi damage

CD8
↓
intraepithelial lymphocytes

B cells
↓
Antibodies

Histo-Pathology

- Site of Biopsy-2nd part of duodenum In Celiac disease

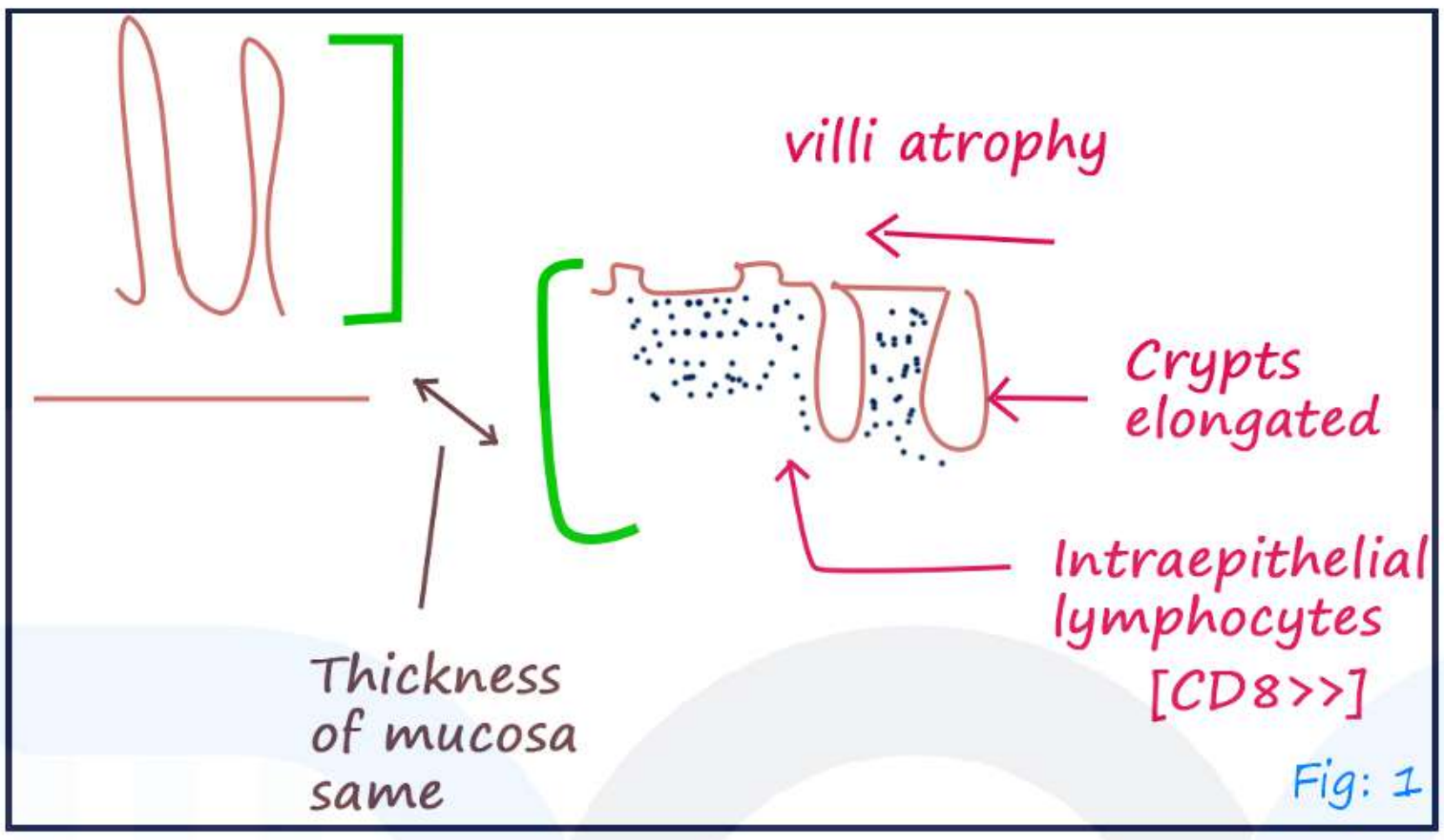

Fig: 1

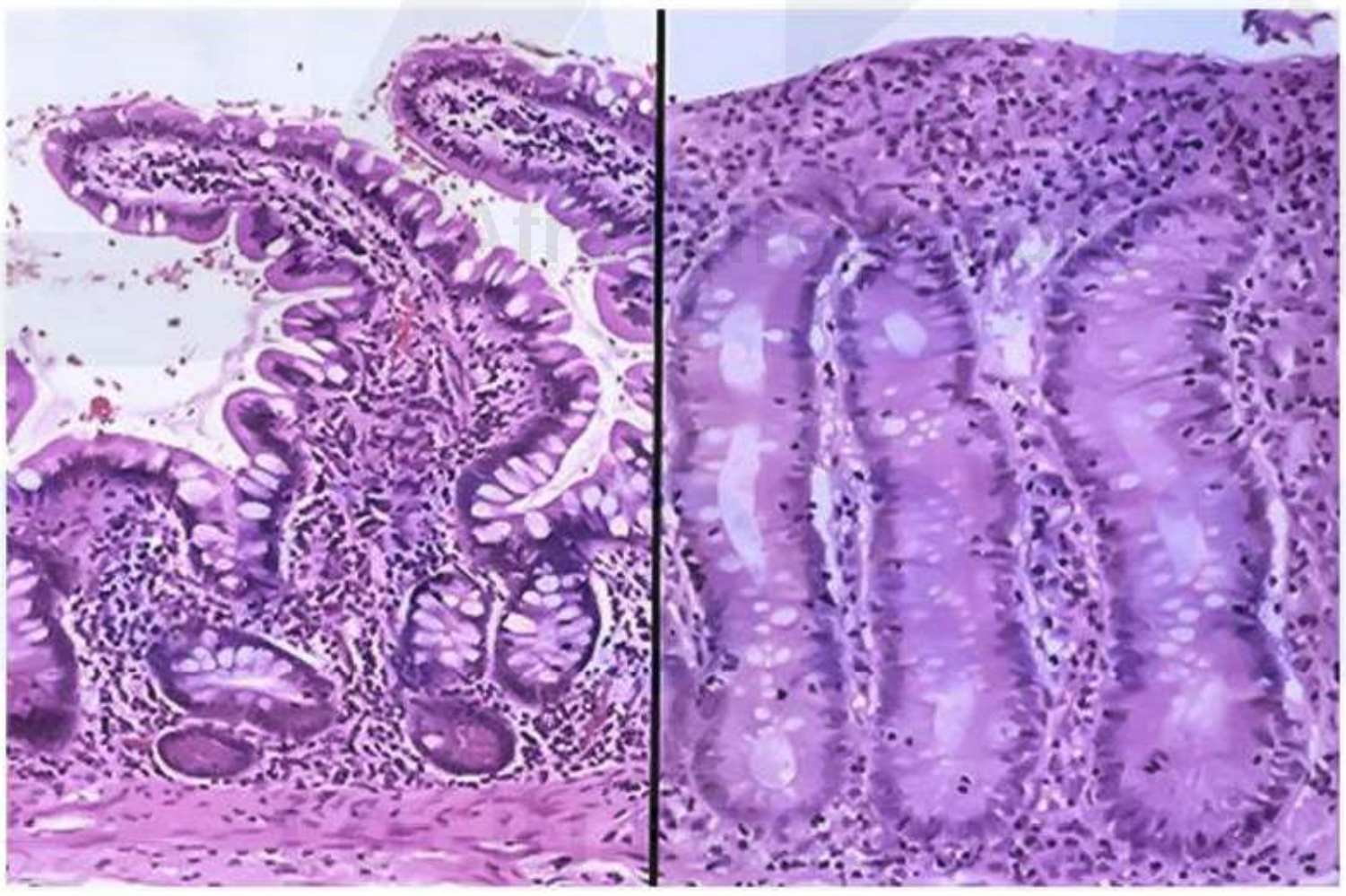

Fig: 2

1) Villous atrophy
2) Crypt Hyperplasia
3) Intra epithelial lymphocytes [CD8 >> CD4]

Remember: -Overall Mucosal Thickness remains same

Diagnosis: - Histopathology + Serology -Clinical features

AfraTafreeh.com

Serology IgG/IgA Ab

- Anti TTG-> Most sensitive (IgA)
- Anti-deamidated Gliadin If IgA deficiency → IgG Anti Gliandin Antibodies
- Anti-Endomysial Most specific

Clinical Features:

1) More common in children
2) Symptoms of malabsorption -Diarrhea, Weight loss, Abdominal distension
3) Diagnosed typically in early childhood around the age of 2 years. A second peak is found around the age of 40 years.

Complications

1) Dermatitis Herpetiformis-Chronic pruritic skin disease
2) Malignancies - particularly Lymphomas-> Enteropathy associated T cells lymphoma.

Scenarios

Serology

Histology

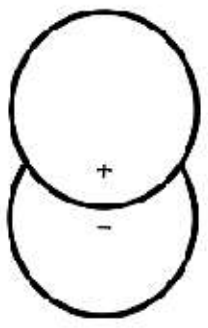

→ Latent Celiac disease

Serology

Histology

But No Symptoms

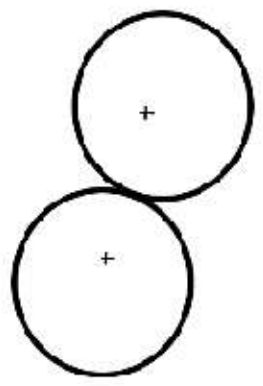

→ silent Celiac disease

MALABSORPTION SYNDROMES WITH FOCUS ON WHIPPLE DISEASE AND TROPHICAL SPRUE

Whipple disease 00:00:30

- Malabsorption diarrhoeas caused by Trophyrema Whippeli, a gram positive actinomycete

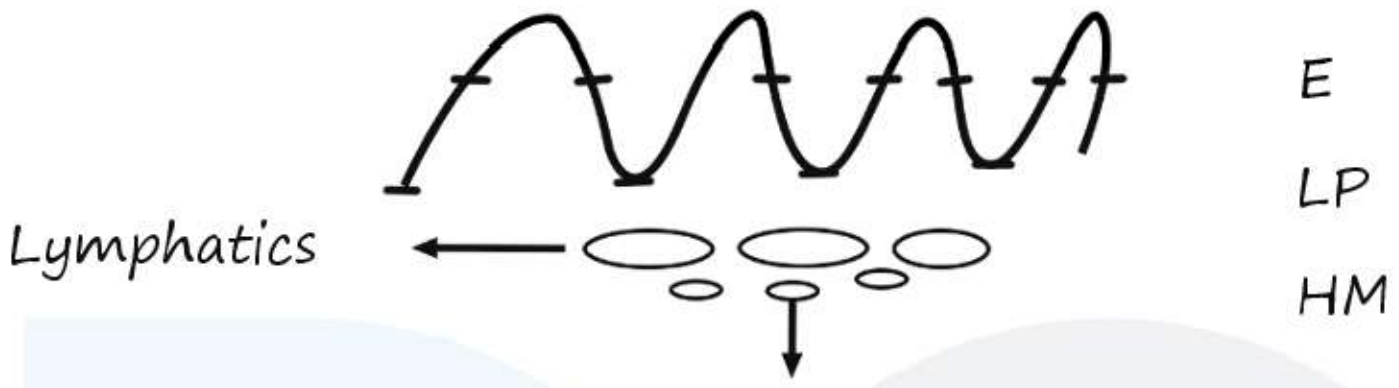

Trophyrema engulfed by macrophages

↓

Change into foam cell

In Whipple's due to lymphatic defect the foam cells are not cleared from lamina propria (LP)

↓

LP stuffed with Macrophages widening of UP

↓

Lymphatic pulled open

Marked widening of lymphatics

Macrophages enter the widened lymphatics and circulate to other organs CNS, LN joints

AfraTafreen.com
TUTORIALS
LOGIN FOR SUCCESS

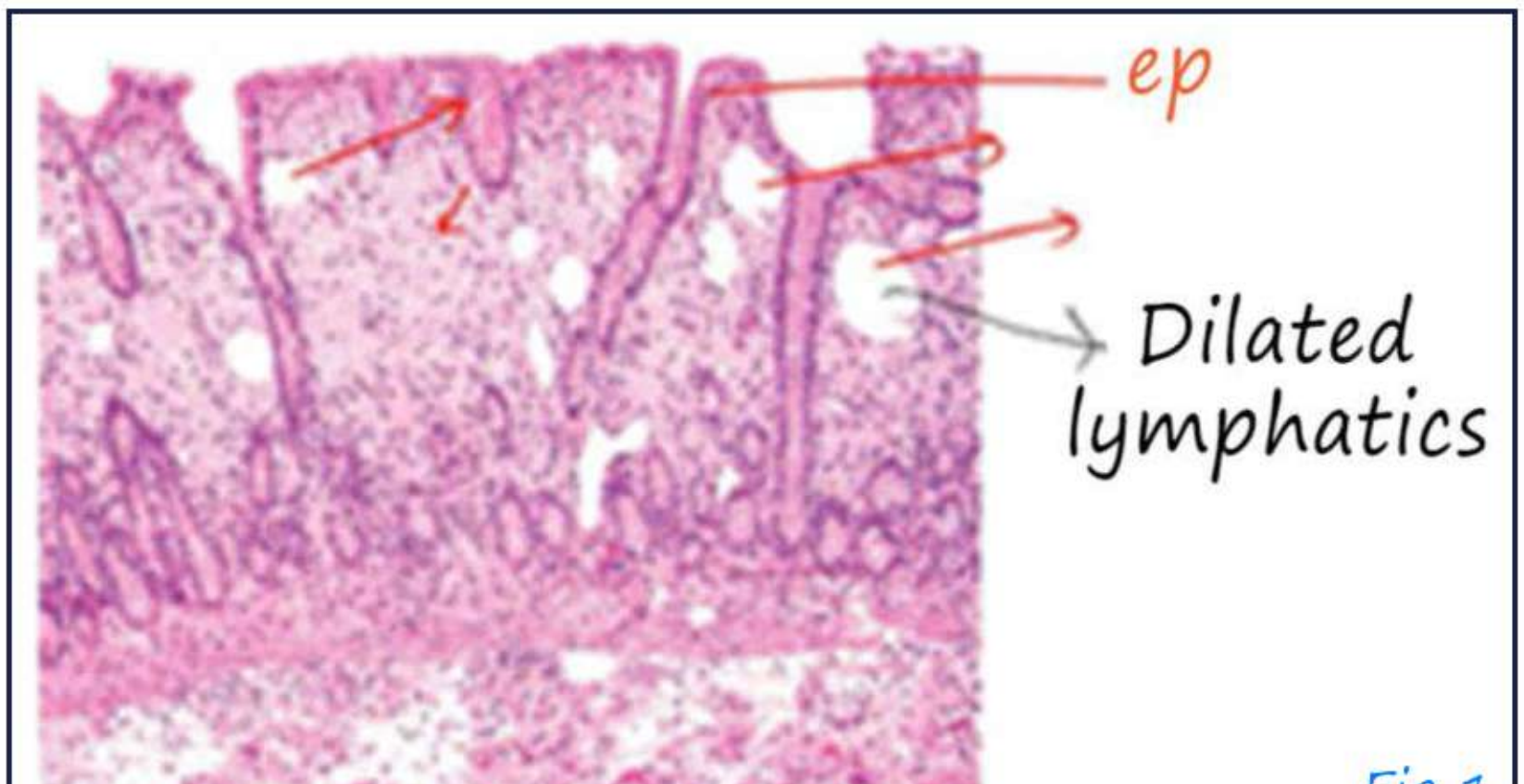

Fig 1

AfraTafreeh.com

Differential of foam cell in lamina propria

MAC	whipple's disease
↓	↓
AF Positive (ZN staining)	PAS positive macrophages Acid fast negative

Clinical Manifestation

Acute infection	Chronic infection
1. Acute Gastro enteritis 2. Pneumonia	1. Most common Joint involvement arthritis → Steroids worse this while antibodies improve 2. CNS: a) M/C manifestation is dementia b) Most specific-convergent/Divergent Nystagmus with masticatory jaw muscle involvement ↓ oculo-masticatory myorhythmia c) Encephalopathy d) Supranuclear ophthalmoplegia 3. CVS – most common pericarditis 4. Eye – most common uveitis

Diagnosis

1. Histopathology

- Foamy macrophages
- PAS positive macrophages in lamina propria
- Gram positive
- Acid fast negative

2.Electron microscopy – Remnants of Bacilli in macrophage

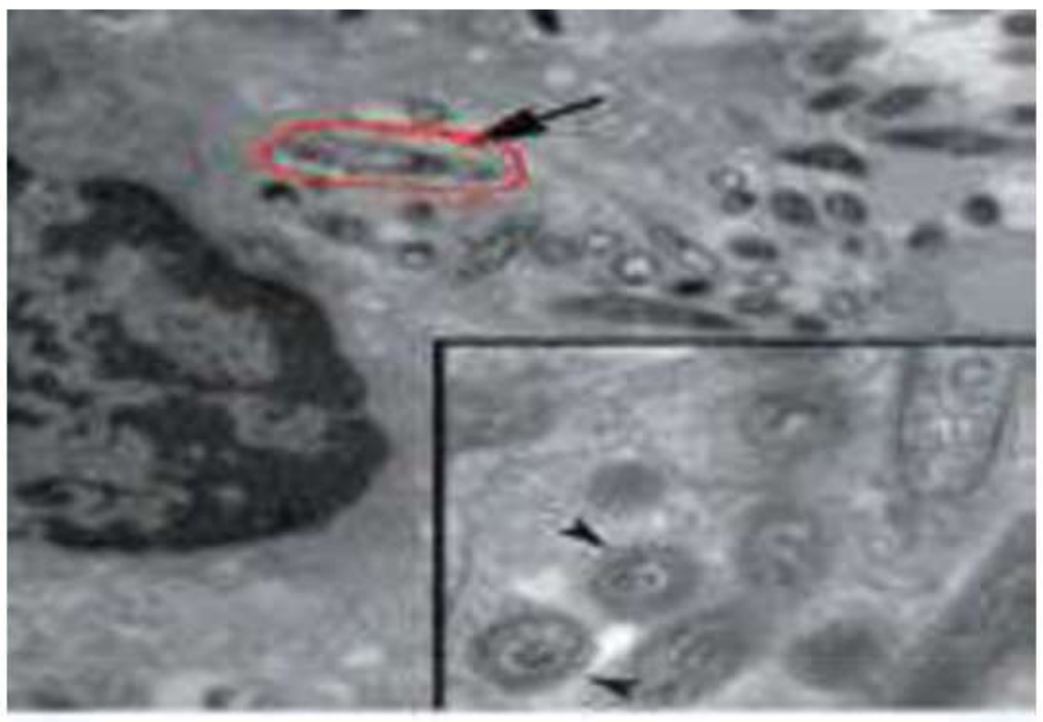

Fig 2

3.PCR

Whipple's is a benign disease showing metastasis i.e presents

Like a malignant disease.

AfraTafreeh.com
TUTORIALS
LOGIN FOR SUCCESS

Tropical sprue

- Now known as environmental enteropathy
- Etiology – Endemic organisms implicated, most common – E. coli

Pathology:

- Jejunal biopsy shows – villi atrophy
  Crypt's enlargement
  Intraepithelial lymphocytes

Serology is used to differentiate celiac sprue from tropical sprue.

AfraTafreeh.com

UNUSUAL CAUSES OF MALABSORPTION

Aβetalipoproteinemia 00:01:54

- Defect in microsomal triglyceride transport protein (MTP)
- Lipoproteins not transported from intestine
- Accumulate in epithelium of intestine

On Histopathology

- Epithelial cells with a clear cytoplasm (due to lipid accumulation)
- Vacuolated/bubbly epithelial cells
- Oil red O stain positive
- Acanthocytes seen on peripheral smear of blood
- Steatorrhea on ingestion of fatty foods

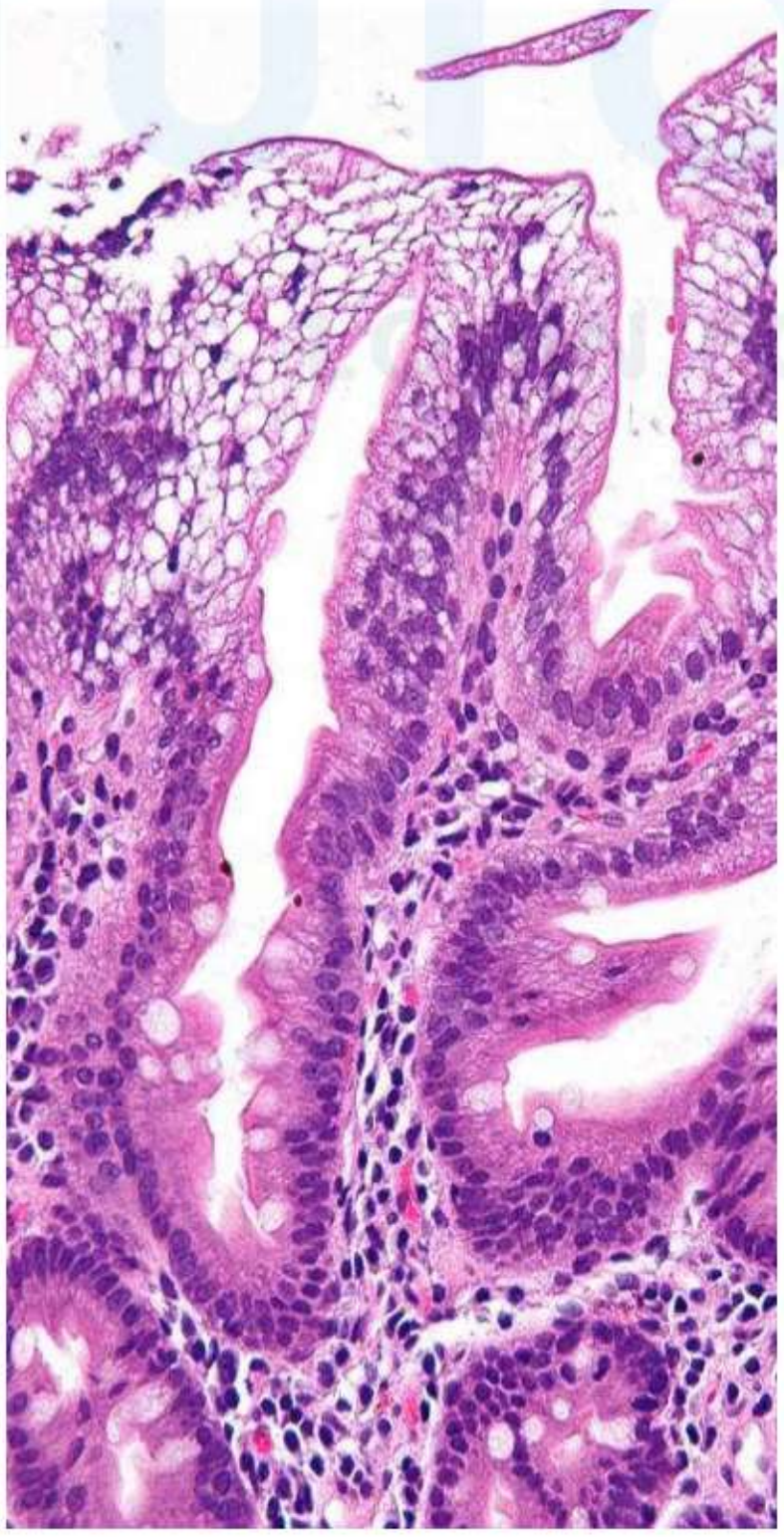

A of fatty food micrograph showing enterocytes with a clear cytoplasm (due to lipid accumulation) characteristic of abetalipoproteinemia. Duodenal Biopsy. H&E stain.

Fig: 1

Giardiasis 00:04:40

Organism is giardia lamblia

- Pear shaped parasite inhabiting small intestine
- Decreases lactase expression on epithelial cells causing malabsorption
- Sticks to brush border of epithelium without local destruction or invasion causes chronic diarrhea
- Causes chronic diarrhea
- Seen most commonly in duodenum

AfraTafreeh.com

Fig: 2

Differential of pear-shaped organism

Giardia

mnemonic – 'Staring Boy'

Trichomonas

mnemonic – 'Tricky Mona'

DOC TUTORIALS LOGIN FOR SUCCESS

- Giardia on HPE

Fig: 3

AfraTafreeh.com

- Sickle like structure over top of villi due to curling up of giardia

COCCIDIAL INFECTION 00:06:19

4 typical coccidia affecting GIT

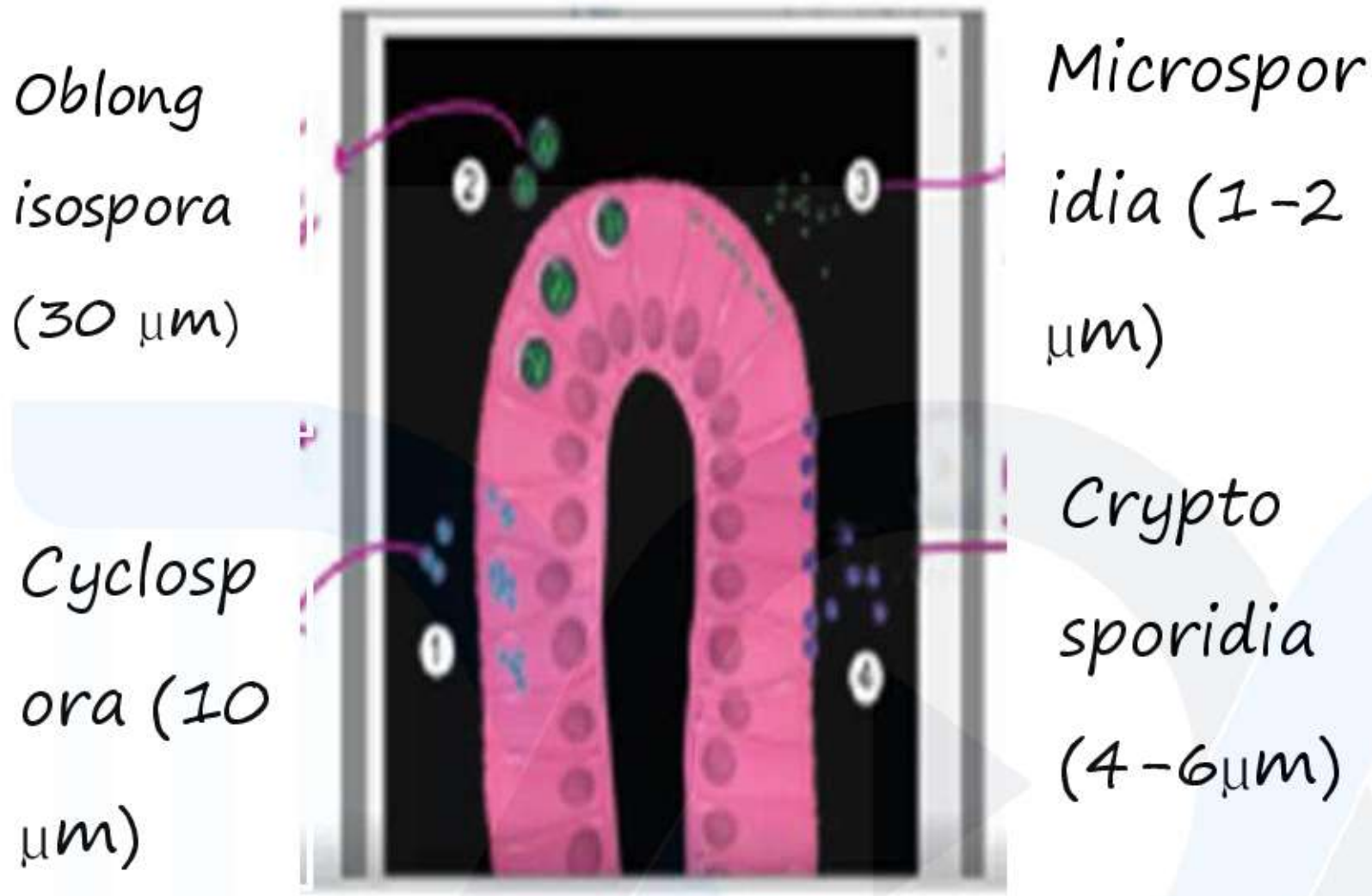

Fig: 4

1.Microsporidia – (1-2 µm)

- Lives inside epithelial cells
- ZN stain under polarizing microscopy shiny parasite in epithelium

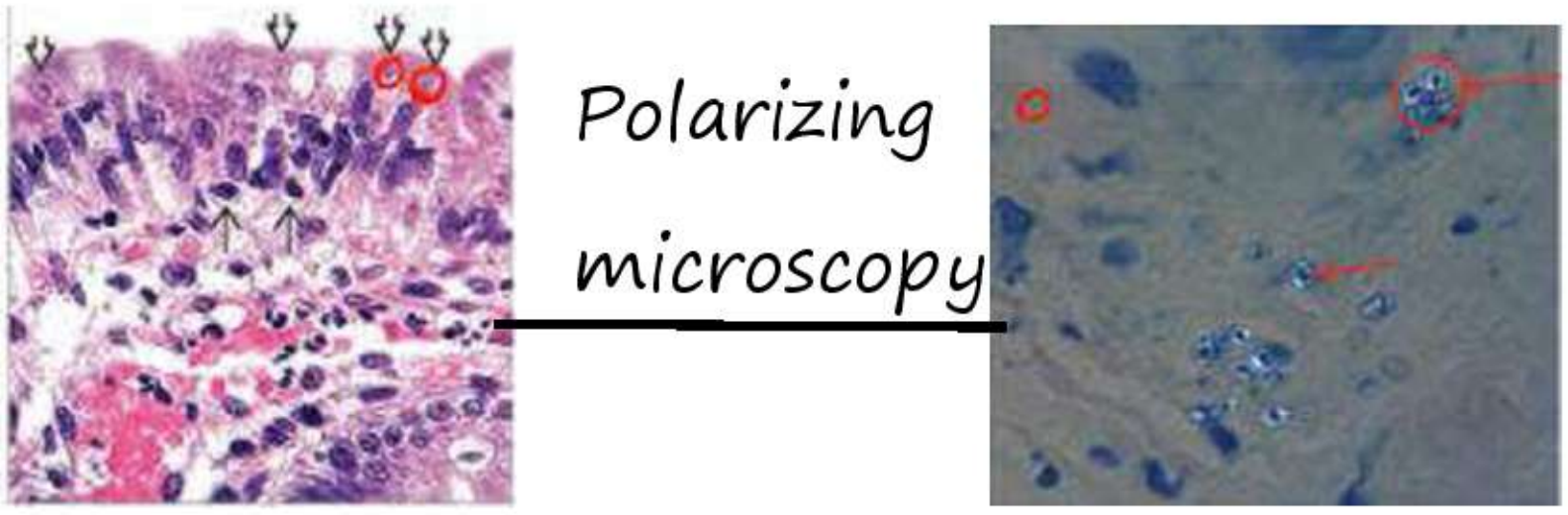

Fig: 5

2.Cryptosporidia – (4-6 µm)

- Sticks strongly to brush border of epithelium

- Affects ileum or colon. Ileum > colon

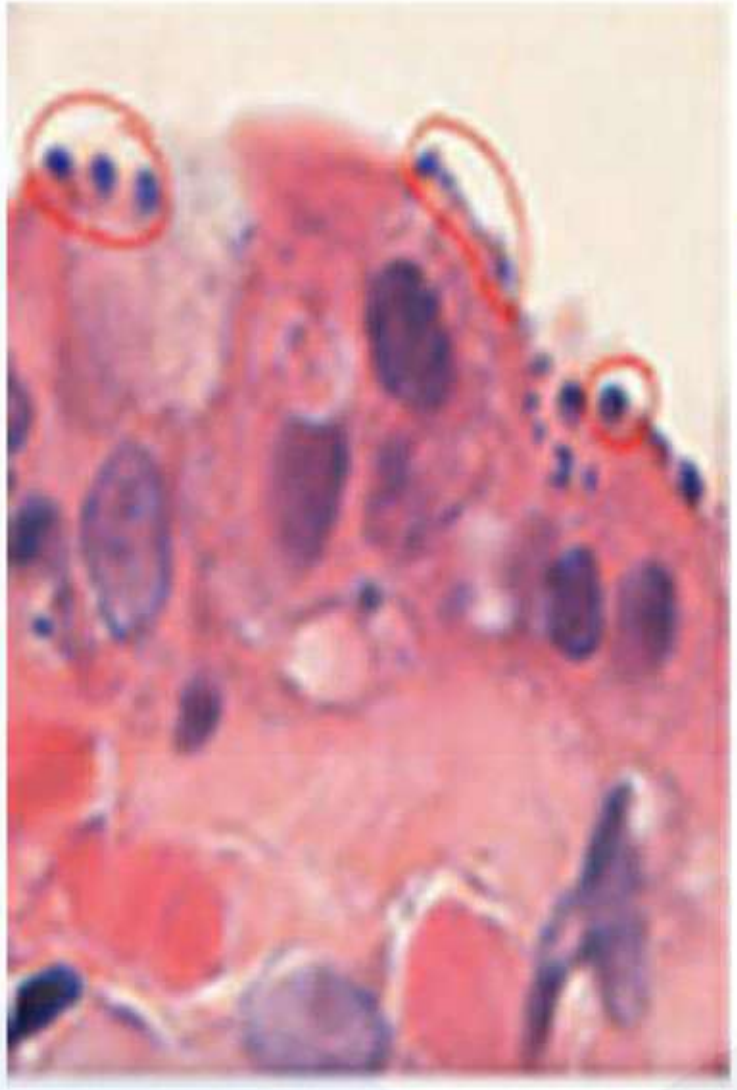

4-6 midometer basophilic spherical structures (pocysts adhere to the apical brush border of the abscoptive epithelial cells of the intestine.

Fig: 6

3.Cyclospora – (10 µm)

- Seen in various stages of development in epithelial cells

AfraTafreeh.com

4.Isospora – (30 µm)

- Oblong parasite inside epithelium
- Coccidial infections are common in immunocompromised and HIV patients
- Seen by modified ZN stain kinyoun method.

TUTORIALS LOGIN FOR SUCCESS

AfraTafreeh.com

ULCERS OF INTESTINE: WITH IMPORTANCE ON PSEUDOMEMENRANOUS COLITIS

Ulcers of intestine

Duodenal ulcer 00:00:06

- Duodenal ulcer-rounded and sharp edge necrotic slough in Centre

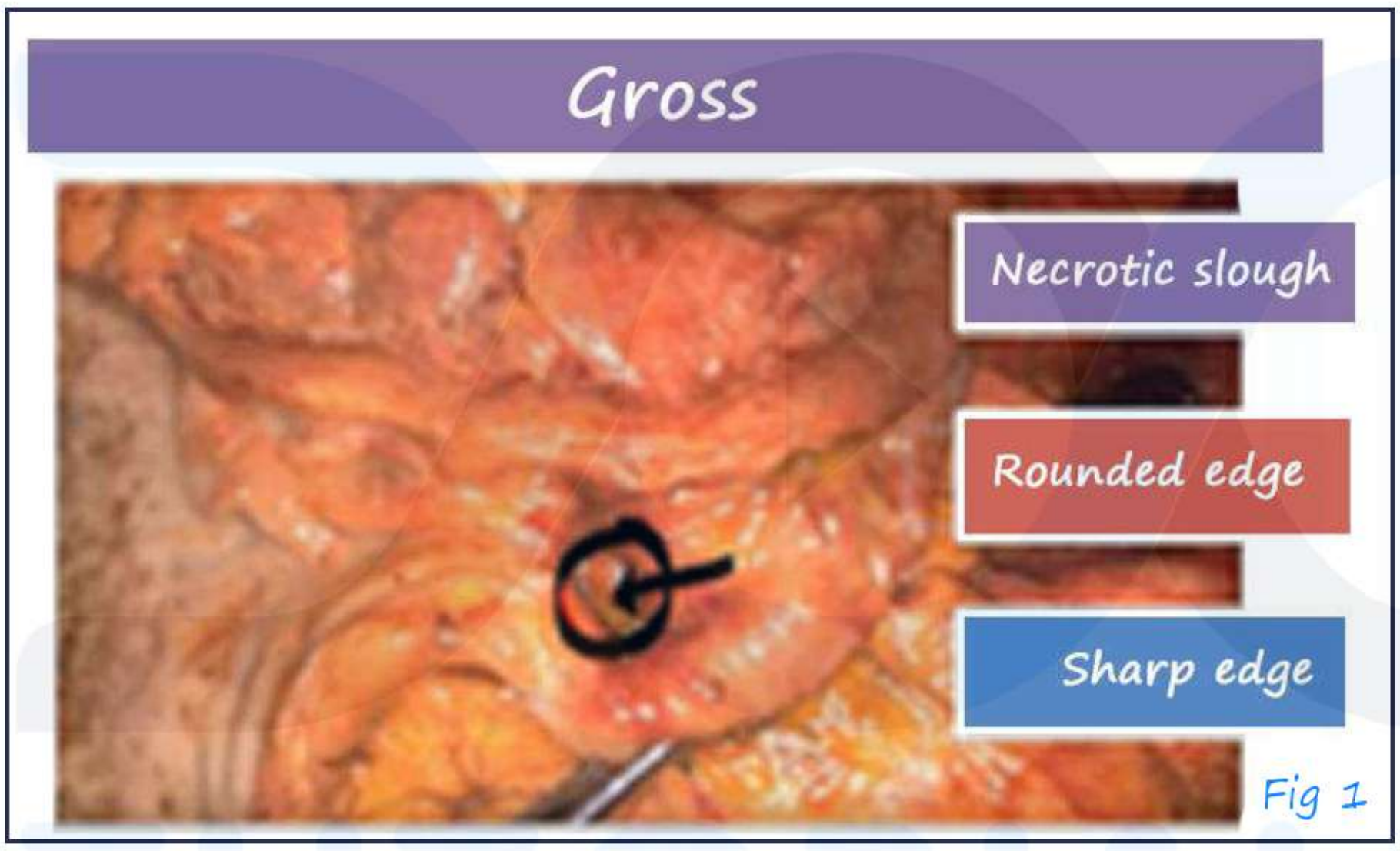

Fig 1

- On Histopathology – 4 layers-

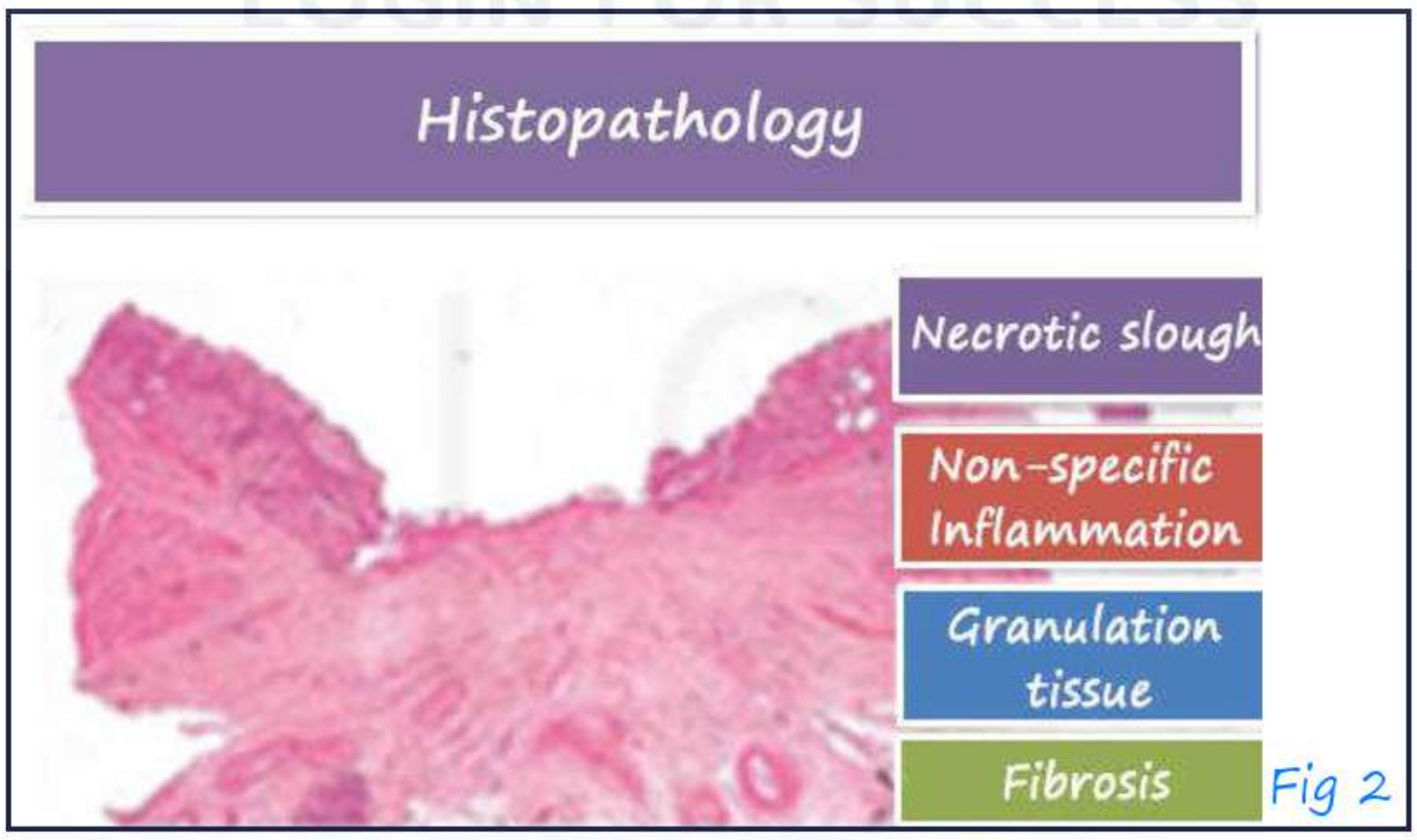

Fig 2

1.Necrotic slough

2.Inflammation

3.Granulation tissue

4.Fibrosis

Be

- **Intestinal ulcer**

Typhoid ulcer 00:01:29

- Typhoid bacilli reach the small intestine, penetrate the mucosa enter intestinal lymphatics via peyer's patches

Peyer's patches → lymphatics → mesenteric lymph nodes

↓

AfraTafreeh.com

Blood [1° Bacteremia]

↓

Organs

↓

Blood [2° Bacteremia]

↓

Peyer's patches

↓

Hypertrophy of peyer's patches

↓

Hypertrophy of peyer's patches causes break in epithelium

↓

Oval ulcers along long axis of intestines

AfraTafreeh.com

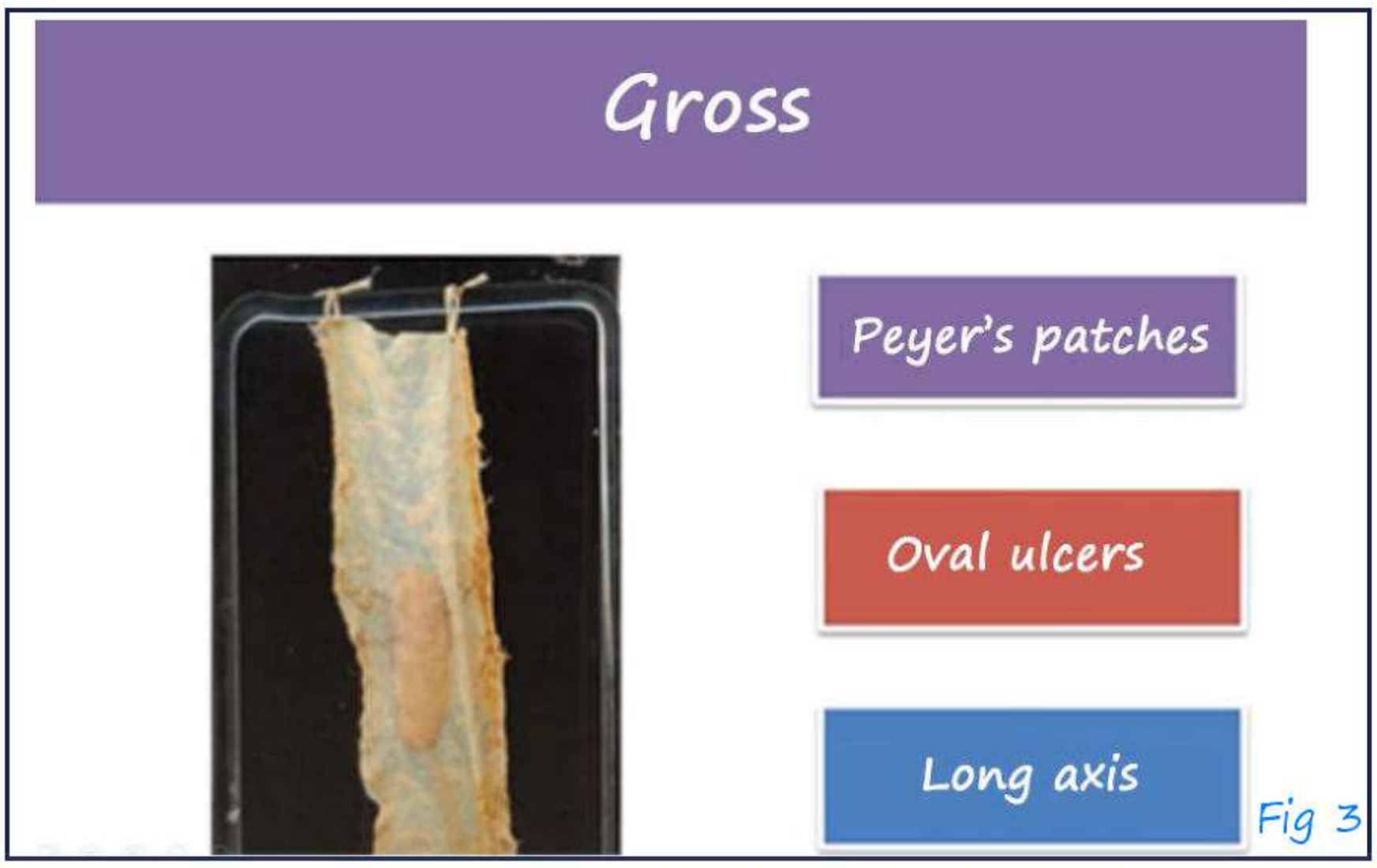

Fig 3

Typhoid ulcer → longitudinal ulcer

Tuberculous ulcer 00:04:38

- Transverse ulcer in the direction of lymphatics

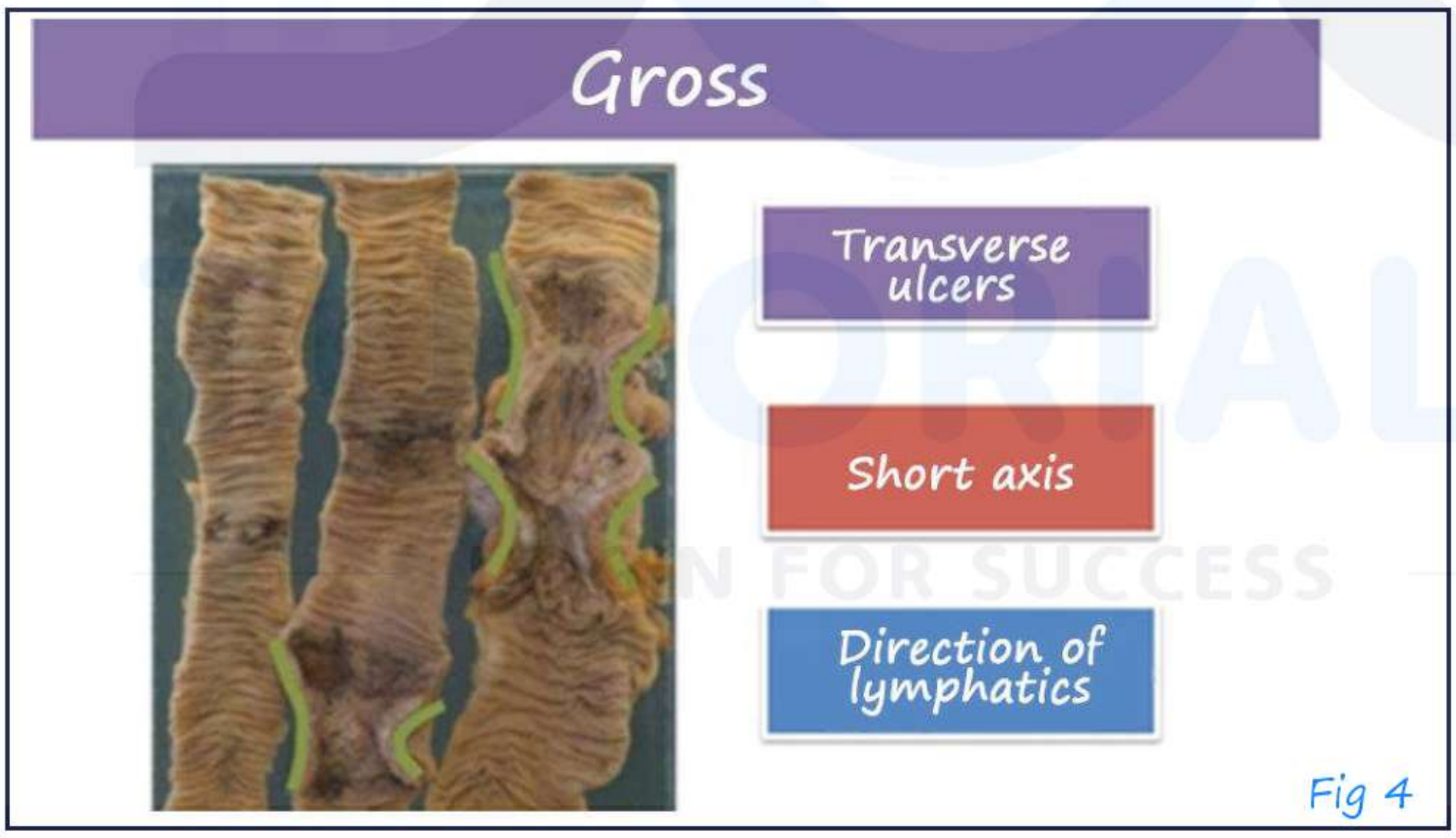

Fig 4

- Associated with structure formation

↓

Fibrosis

↓

Strictures

Pseudomembranous Colitis 00:07:23

- Diarrhea due to toxin produced by Clostridium difficile
- Clostridium difficile when the normal bacterial flora of gut is altered or suppressed by antibiotics. Dysbiosis

Gross view of intestine cap lesion- pseudo membrane

Fig 5

- Toxins stimulate monocytes and macrophages which in turn release IL-8 resulting in tissue infiltration with neutrophils.
- Neutrophils and mucus connecting with glands of intestine.
- Form slough ever ulcer-seen as cap lesions. Pus lining ever epithelium forms a pseudo membrane.

AfraTafreeh.com
TUTORIALS
LOGIN FOR SUCCESS

Histopathology

Focal explosive lesion appearing like expansile mushroom/Volcanic eruption

Fig 6

Amoebic colitis 00:10:46

- Trophozoites of entamoeba histolytica produce characteristic flask shaped amoebic ulcerations
- Amoeba secrets histolysis which being a weak enzyme. Cannot destroy muscularis instead spreads in submucosa forming flask shaped ulcers.

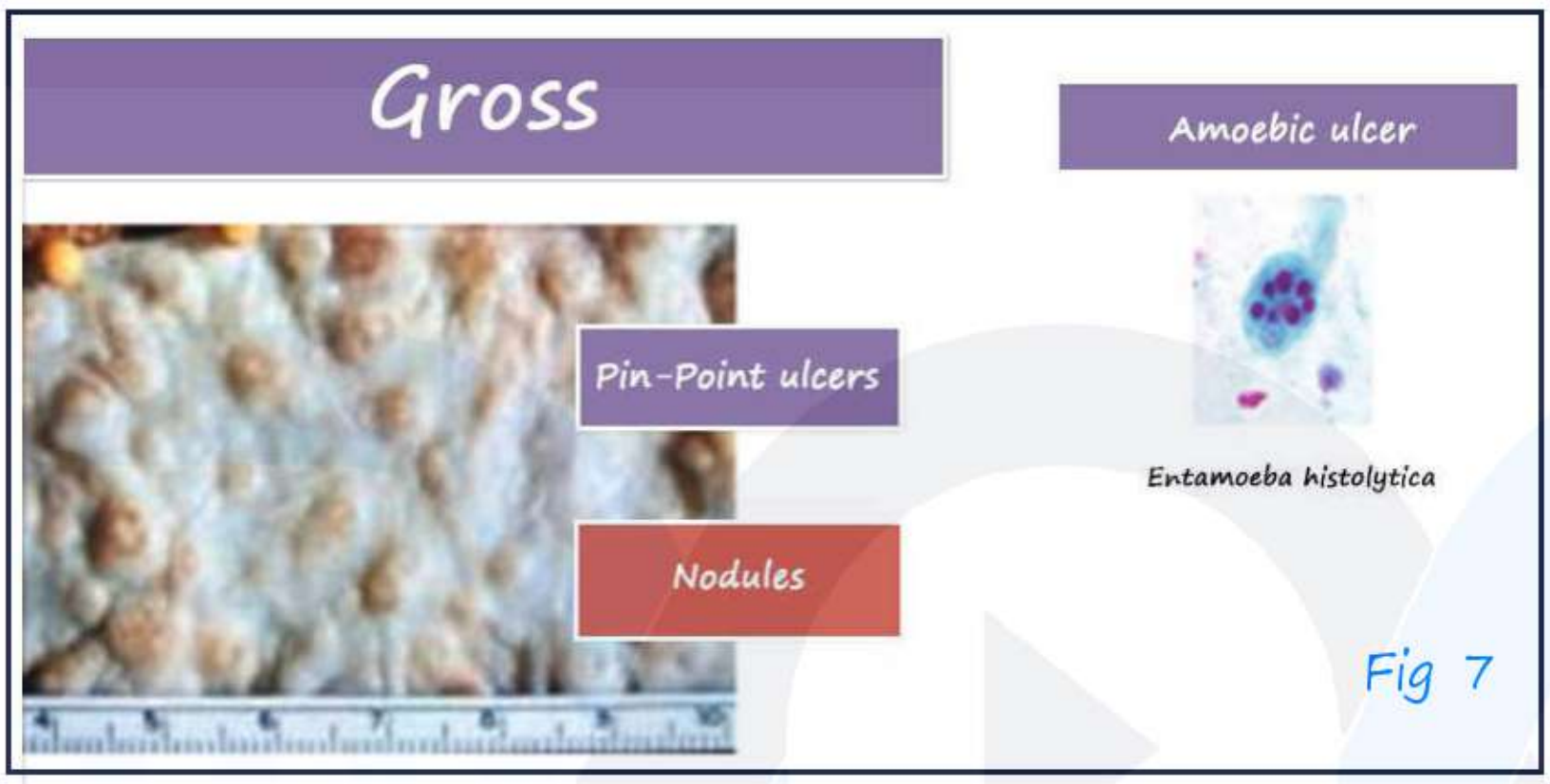

Fig 7

- On Histo path-Trophozoites of amoeba showing erythrophagocytosis

CMV Colitis: 00:13:52

- Ulcer with an erythematous base on HPE-CMV inclusions

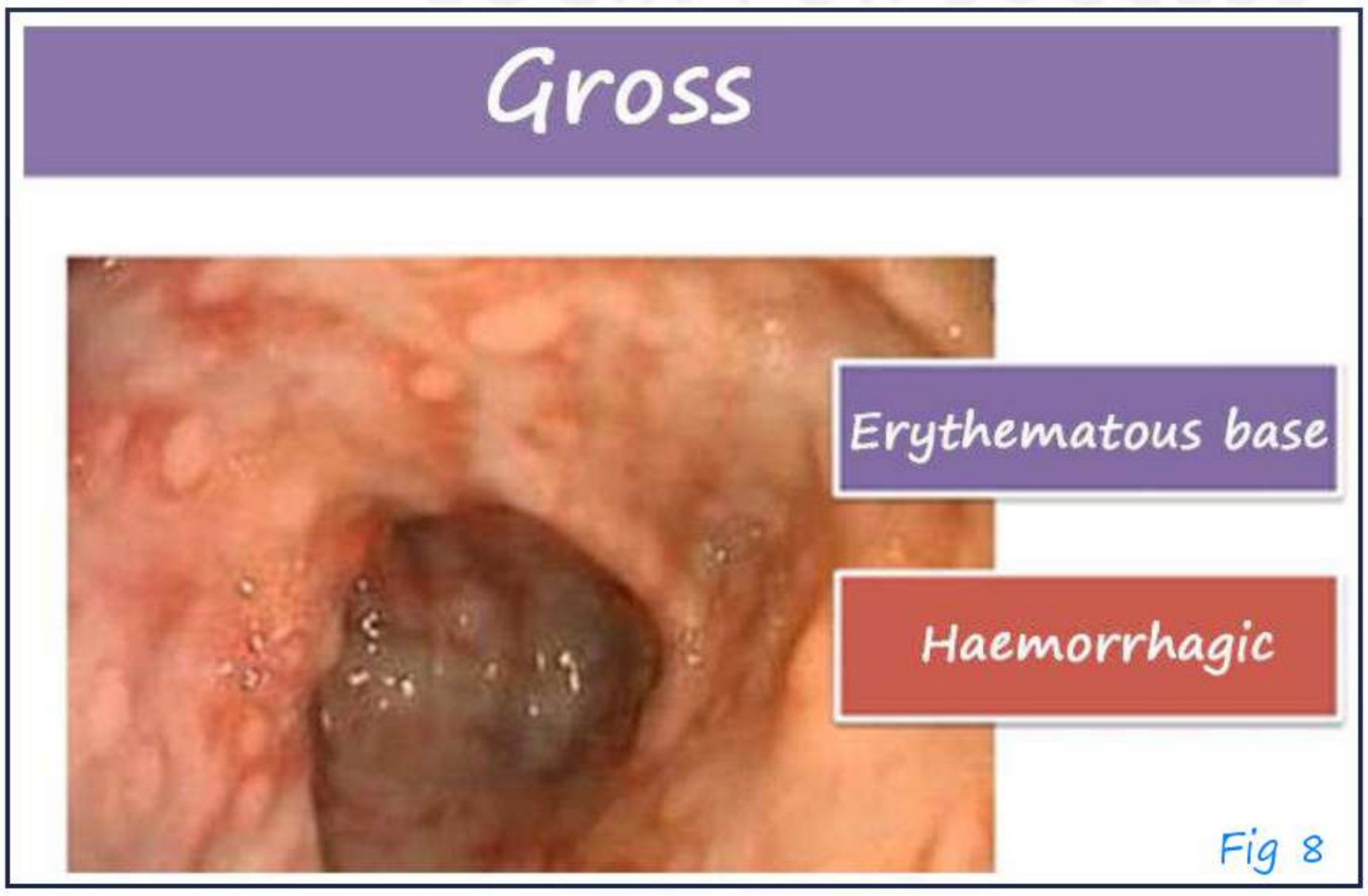

Fig 8

Basophilic owl-eye like inclusions in nucleus.

Graft versus Host Disease (GVHD) 00:15:15

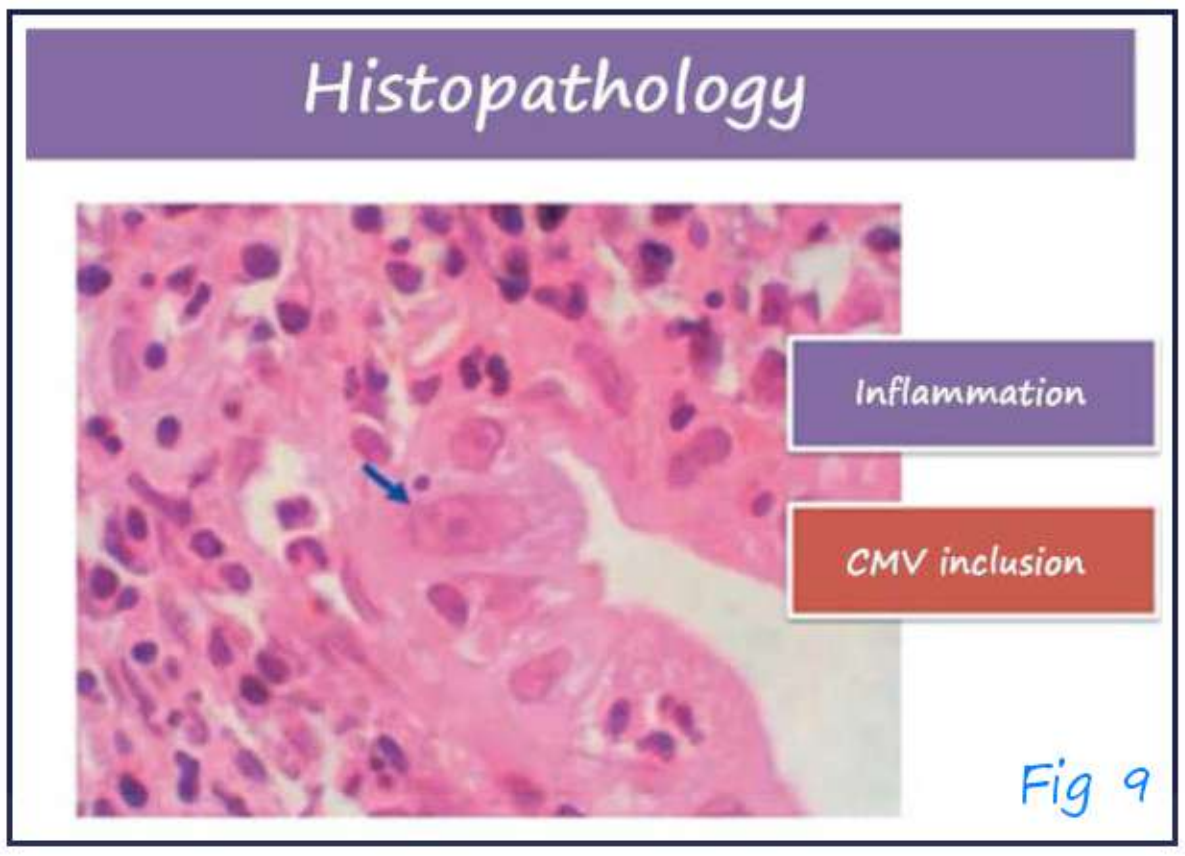

- Pin point Hemorrhage ulcers.

  On HPE- Intra epithelial lymphocytes

  Apoptotic bodies

  Crypt abscess

Malignant Ulcer 00:17:10

AfraTafreeh.com

- Heaped up indurated margins
- Ulcero proliferative lesions

On HPE of Adenocarcinoma Intestine

- Irregular glands infiltrating stroma.

AfraTafreeh.com

Summary of Ulcers of intestine 00:18:10

Ulcers	characteristics
Tuberculous ulcer	Transverse ulcers
Typhoid ulcer	Longitudinal
Amoebic ulcer	Flask shaped ulcer appearing as a pin point lesions on gross
CMV Ulcer	CMV Inclusions, Immunocompromised
Pseudo membranous colitis	Focal explosive lesions
Malignant ulcer	Heaped up indurated margins
GVHD	Intraepithelial lymphocytes and apoptotic bodies

TUTORIALS
LOGIN FOR SUCCESS

INTESTINAL POLYPS AND SYNDROME

Polyps – classification 00:00:06

- Neoplastic polyp
  - ↓ Adenomas
    - Tubular adenoma
    - Villous adenoma
    - TV
    - FAP (Familial Adenomatous Polyposis)
      - ↓ classical FAP (polyp>100)
      - Attenuated FAP (Polyp count <100)
      - ↓ APC gene mutation
    - Sessile serrated adenomas
      - ↓ Associated with
      - -MSI pathway
      - -BRAF mutation
- Non – Neoplastic polyp

Follow classical Adenoma-carcinoma sequence

AfraTafreeh.com
DOC TUTORIALS
LOGIN FOR SUCCESS

2 FAP Syndrome (APC Mutation)

Gardner syndrome	**Turcot syndrome**
•Super numerary teeth •Osteomas •CHRPE	•Brain tumors – typically medulloblastoma

AfraTafreeh.com

Adenomas 00:08:38

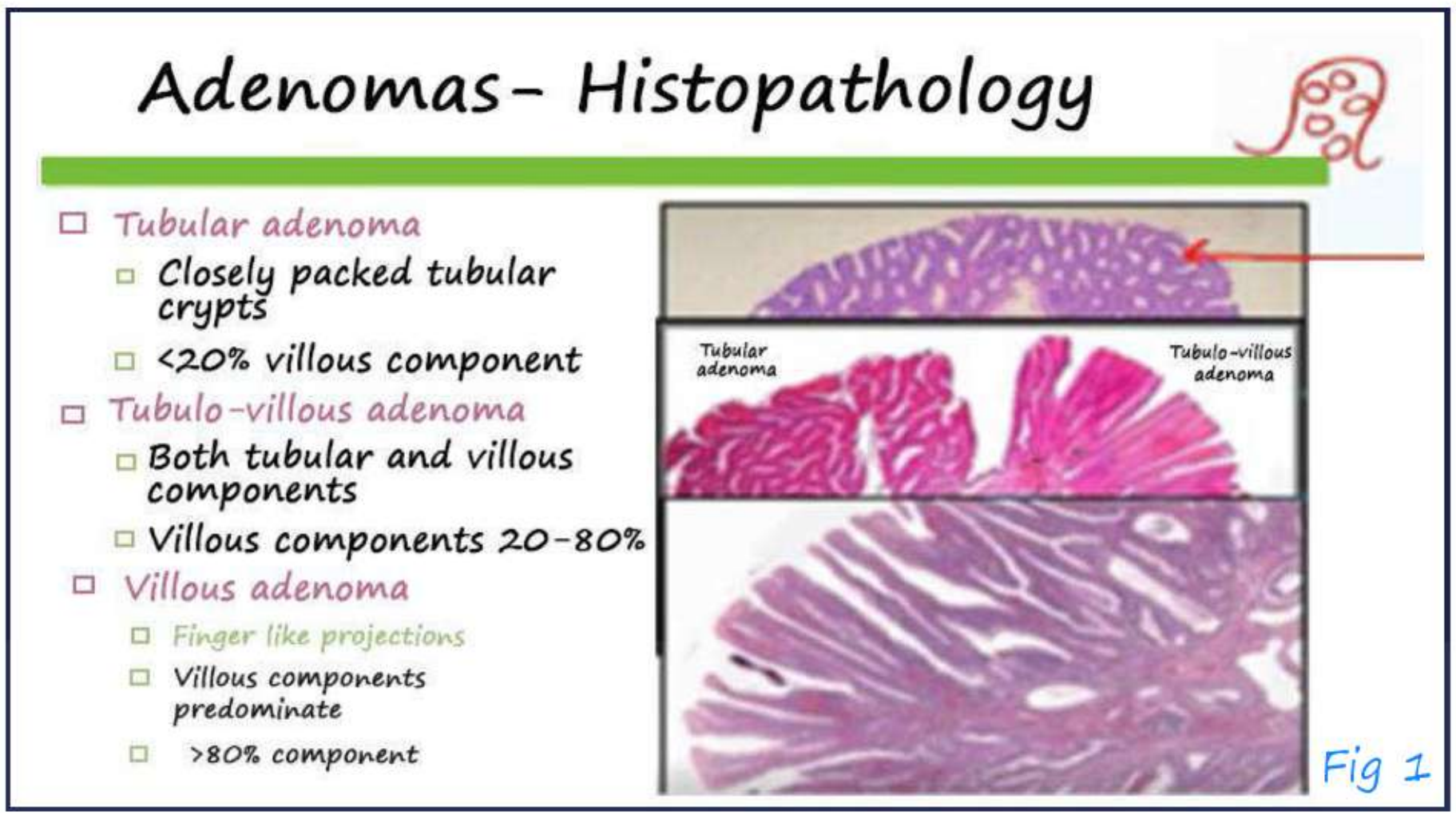

Fig 1

Tubular adenomas – Well defined tubular glands in polyps <20% villous component

Villous Adenoma: →

- >80% villous component
- Higher chances of malignant transformation
- Secrete lots of mucus rich in K+ present with diarrhea, hypokalemia.

Tubular villous – Both tubular and villous components >20%

TUTORIALS
LOGIN FOR SUCCESS

Non – Neoplastic polyps 00:11:53

Non- Neoplastic polyps

Inflammatory polyps
- Typically occur in rectum
- Due to repeated cycles of ulcer and healing

  Example: - solitary rectal ulcer syndrome

Hyperplastic polyps
- Due to decreased epithelial turnover
- Excessive epithelium results in serrated lumen
- Shows piling of goblet cells

Hamartomata's polyps

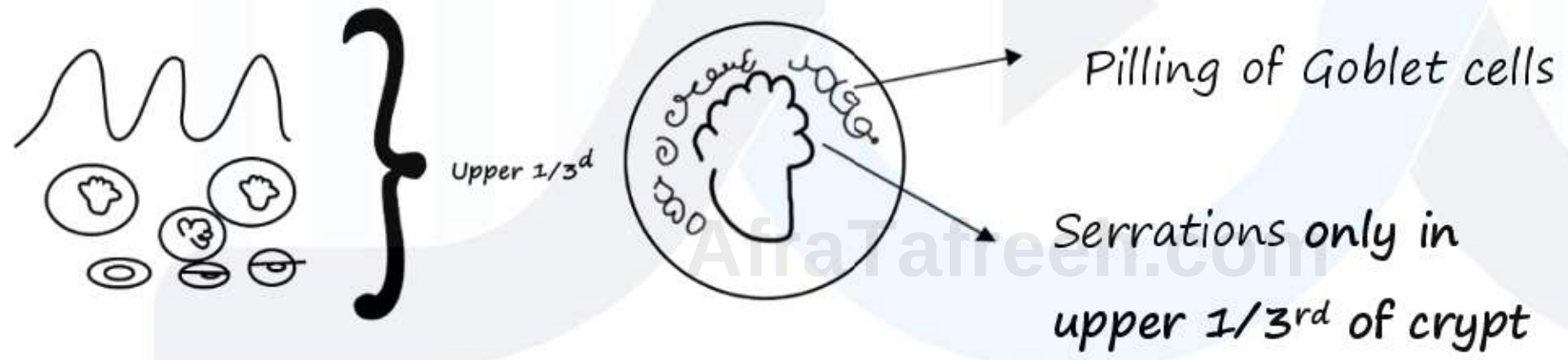

- Normally the lumen of Crypt is round

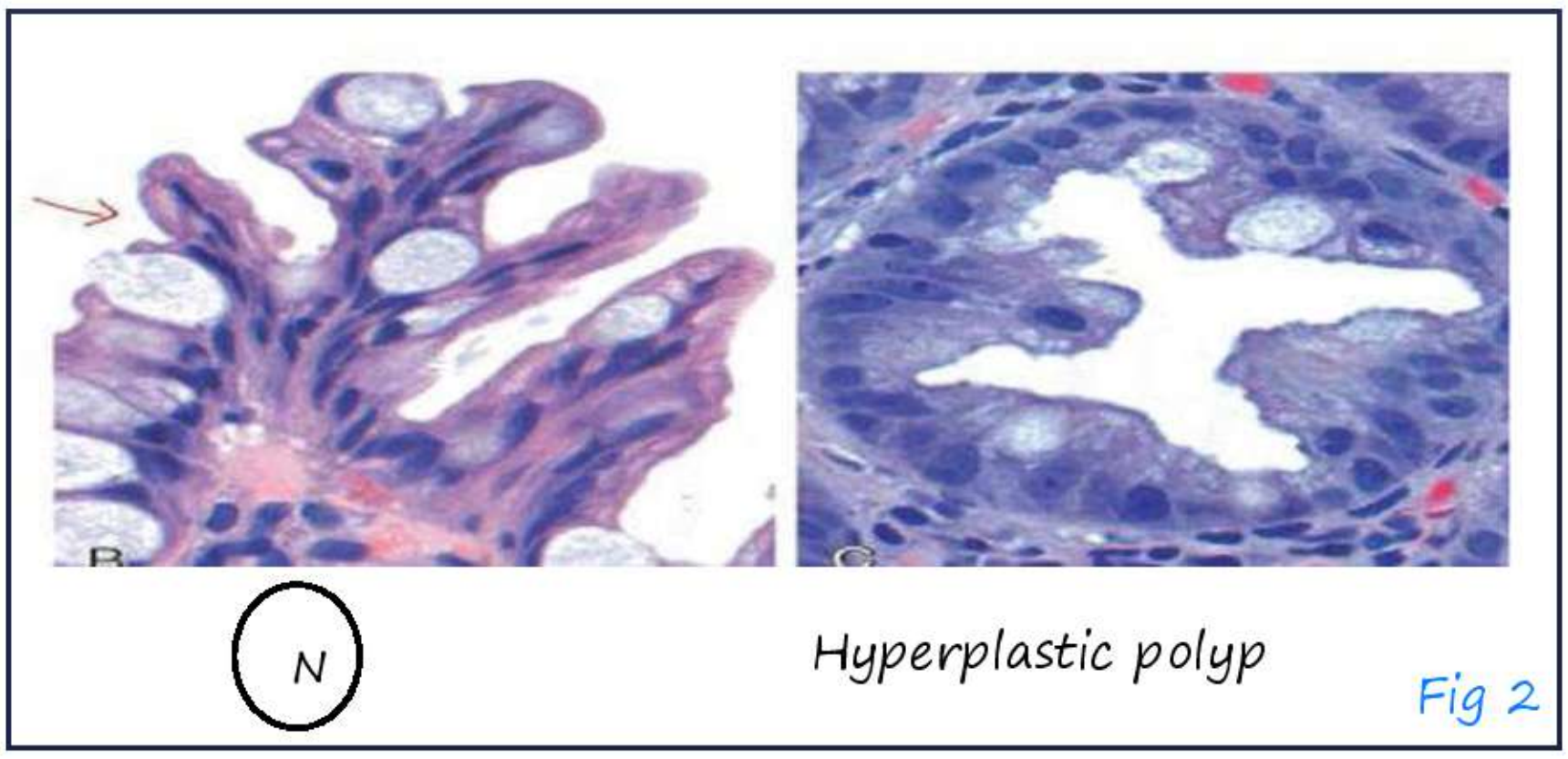

Hyperplastic polyp

Fig 2

AfraTafreeh.com

- If all the crypts are serrate

  ↓

  It is called sessile serrated adenoma

  (A Neoplastic polyps

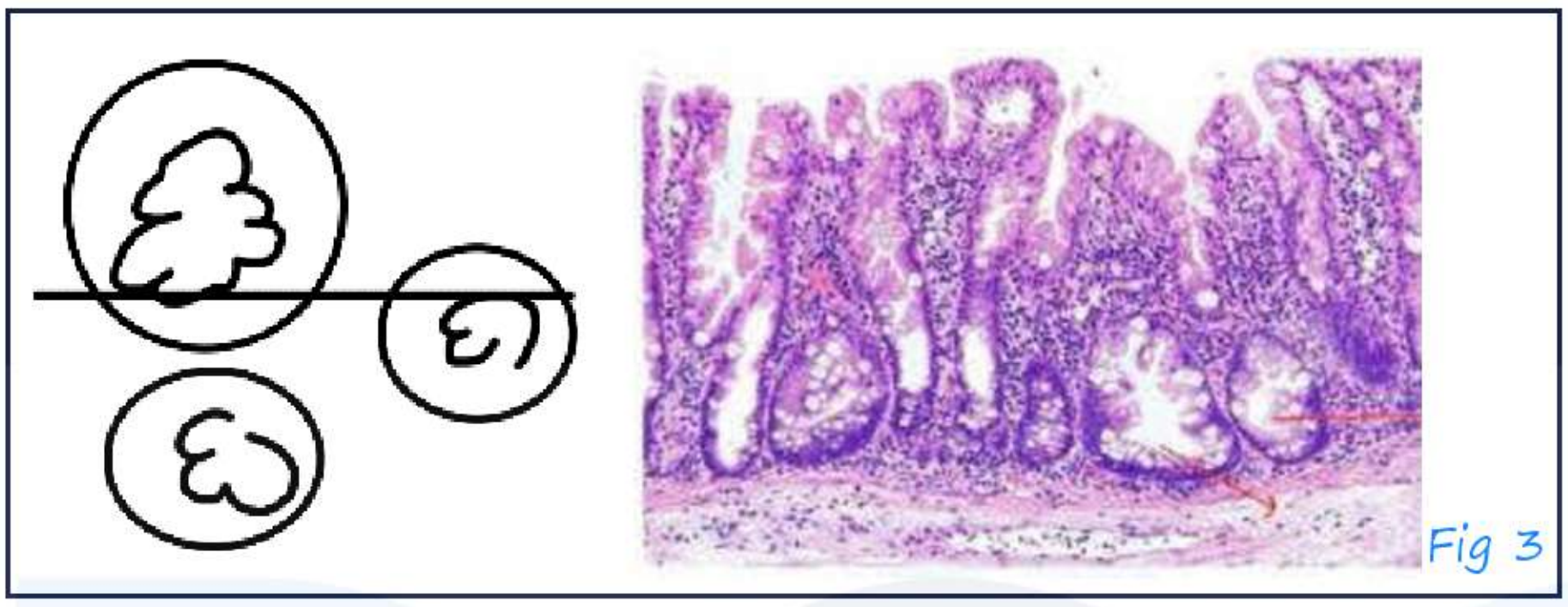

Fig 3

Harmatomatous Polyps 00:22:42

Hamartomatous Polyp

Peutz – Jegher Syndrome	Juvenile Polyps
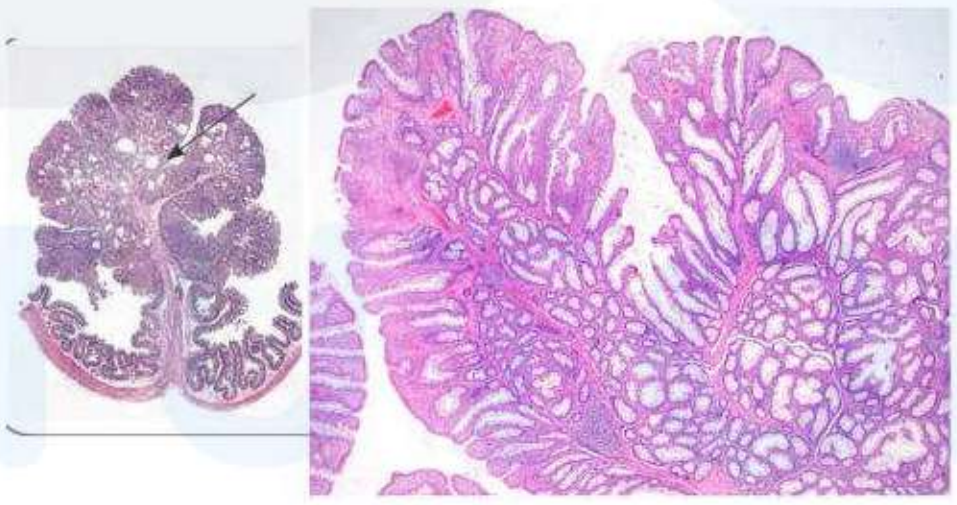	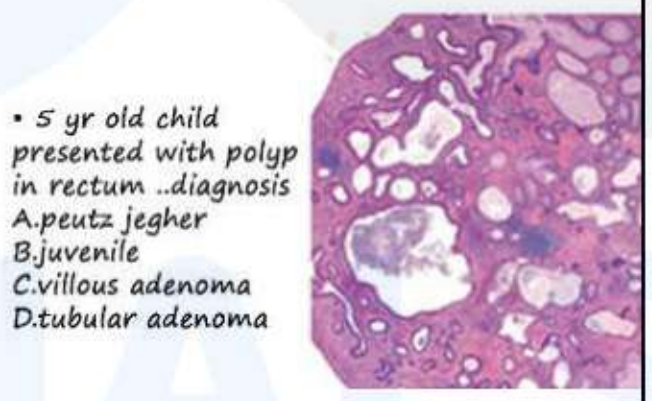

• Smooth muscle from Muscularis extend Muscular extends
Into the superficial Epithelial layer in a tree like manner known as **Arborization,**
• Due to mutation of STK11
• Most common site –**Jejunum**
• Age of presentation–11–22years
  • Presentation–intussusception
  Hyperpigmentation in (Peri-oral region & buccal mucosa)
• Increased risk of B/L sex cord tumors of Ovary and testes,
	• Children <5years
	• SMAD 4 mutation
	SMAD4–controller of TGF Beta pathway
	Presentations–Rectal polyp, P/R Blooding
	• Pulmonary A–V malformation

Hamartomatous polyp syndromes

I. COWDEN Syndrome 00:34:33

- Mutation of PTEN
- Also known as PTEN Hamartomas syndrome
- Presents early in life with multiple Hamartomas arising from all embryonal layers
- M/C feature Multiple Trichilemmoma Skin appendageal tumors
- Hyperkeratosis of hands and feet.
- High risk of (I B E T)

  → Breast → Endometrial → Thyroid malignancies

AfraTafreeh.com

II. Bannayan Riley Syndrome 00:37:30

- Mental retardation, Macrocephaly
- Ocular abnormalities, Lipomas, Hyper pigmentation of penis
- Hashimatous thyroiditis, Developmental abnormalities
- Presents early in life.

III. Cronkhite - canada syndrome 00:38:00

- Acquired Gastrointestinal polyposis disorder associated with
- Skin pigmentory changes b. Hair loss
- Nail atrophy (Onychodystrophy)
- Presents 50years of age -MJC symptom is diarrhea

AfraTafreeh.com

- Most common site polyp is stomach
- Polyps thought out GIT w/ characteristic Esophageal sparing

Note: Tuberous sclerosis can also present with Hamartomatous polyp

Update: MUTYH polyposis 00:41:43

- Associated with Attenuated polyps (100)
- Due to DNA Repair defect
- Autosomal recessive

Note: Rest of all intestinal polyp syndromes are autosomal dominant.

TUTORIALS
LOGIN FOR SUCCESS

OVERVIEW OF IBD AND DETAILED DISCUSSION OF ULCERATIVE COLITIS

Ulcerative Colitis 00:00:06

- More common in developed countries
- Commonly affects patients < 30 years
- More common in females taking OCPs.

Etiology

- Infectious agents – C. difficile & Campylobacter jejuni implicated.
- Smoking and Appendectomy – decrease risk of UC.

AfraTafreeh.com

Pathology

1. Rectal involvement (proctitis) is the **hallmark of the disease.**
2. Typical Gross appearance – Hyperemic and granular mucosa

   ↓

   Earliest change in UC is fine mucosal granularity

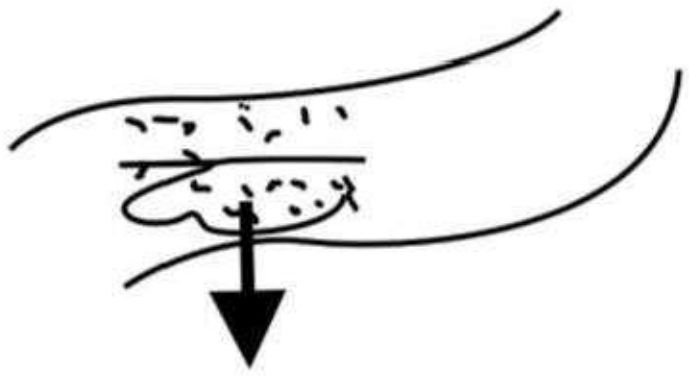

3. Broad based Ulcers involving **mucosa and sub mucosa**

   i.e. superficial Ulceration

AfraTafreeh.com

4.Pseudo-polyps →Pseudo because of regenerating mucosa results in polyp like appearance

5. **Mucosal Bridging**: Tips of pseudo-polyps start fusing

Fig 1

If ulcer involves and damages the ganglion cells of AuerBach's plexus in muscularis and Meissner in sub mucosa.

↓

Abnormal dilatation of intestine.

↓

Toxic mega-colon

6.



Lead pipe appearance due to loss of Haustrations because of continuous ulcers.

7.Continuous uninterrupted inflammation, beginning in distal

Rectum & extending proximally.

Involvement of terminal ileum→ **Backwish ileitis (BWI)**

8. Basal Plasmacytosis

9. Features of active UC

a. Crypt abscess

b. Abnormal branching of crypts

c. Pyloric metaplasia

Pathogenesis 00:09:49

- Exact cause is not known

Antigen → APC → TH2 → IL13 → Epithelial damage

Antigen → Dendritic Cells

Active Disease → Dendritic Cells → IL23 → TH17 → IL17 → Crypt abscess

(Neutrophilic infiltration)

AfroTafreeh.com

If IL23 polymorphism present → No TH17 activation mild UC

Genetic mutation in UC

1. **HNF alpha** mutation causes epithelial barrier dysfunction

Remember HNF α is also implicated in maturity onset diabetes of young-MODY

AfraTafreeh.com

2.ECM-1 inhibits MMP-9(collagenase) → decreases severity of UC

If ECM-1 mutated → More damage in UC

3.Mutation in **IL 10 or IL 10 R**-Severe IBD

4.**P-ANCA positive** 92% specificity for UC

- Neoplasia in UC
  - Depends on duration of disease →8 years
  - Degree and type of inflammation - more the crypt abscess, irregularity, Branching → more the chances of cancer.
  - In UC Repeated involvement of same site

    ↓
  - Higher risk of Malignancy compared to Crohn's
- Indeterminate colitis
  - Overlapping of manifestations of crohn's and ulcerative colitis in 10% cases.
- Update Triad of IBD

Epithelial Barrier dysfunction → HNF- α, TNF; IL 13

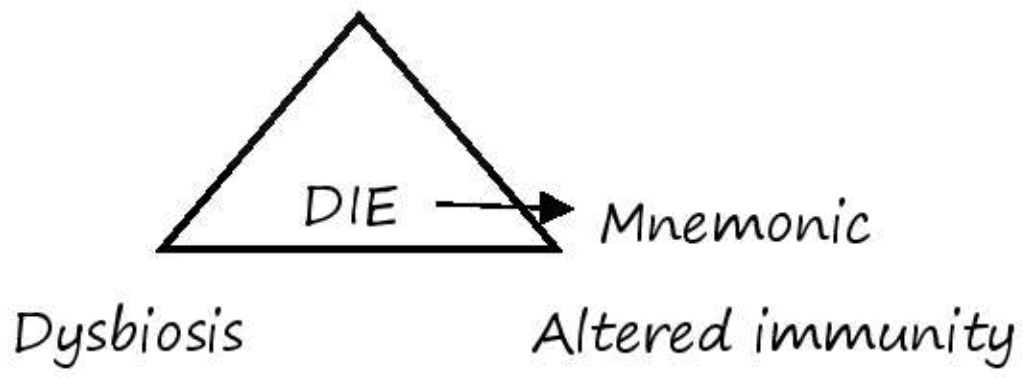

(Pneumonic- 'DIE")

- Microbiota refers to the normal Microbes inhabiting gut.
- Variety of microbes is a determinant of Nutritional status

- Lean people have better nutritional status compared to obese
- Dysbiosis means Alteration of normal microbes of gut → seen in pseudomembranous colitis

Hygiene hypothesis

- States that early childhood exposure to particular micro-organisms protects against allergic disease by contributing to development of immune system.
- In particular, Lack of exposure is thought to lead to defects in the establishment of immune tolerance.

AfraTafreeh.com
TUTORIALS
LOGIN FOR SUCCESS

AfraTafreeh.com

INFLAMMATORY BOWEL DISEASE AND DETAILED DISCUSSION OF CROHN'S DISEASE

Inflammatory Bowel Disease (IBD) 00:00:06

Ulcerative Colitis

- Colitis – so involves colon
- Continuous involvement
- If terminal ileum involved
  ↓
  Backwash Ileitis
- Always involves rectum

Crohn's Disease

↓

Can involve any part of git, but most commonly affects ileum/ileocecal junction discontinuous lesions with skip areas

↓

Giving "cobblestone" appearance

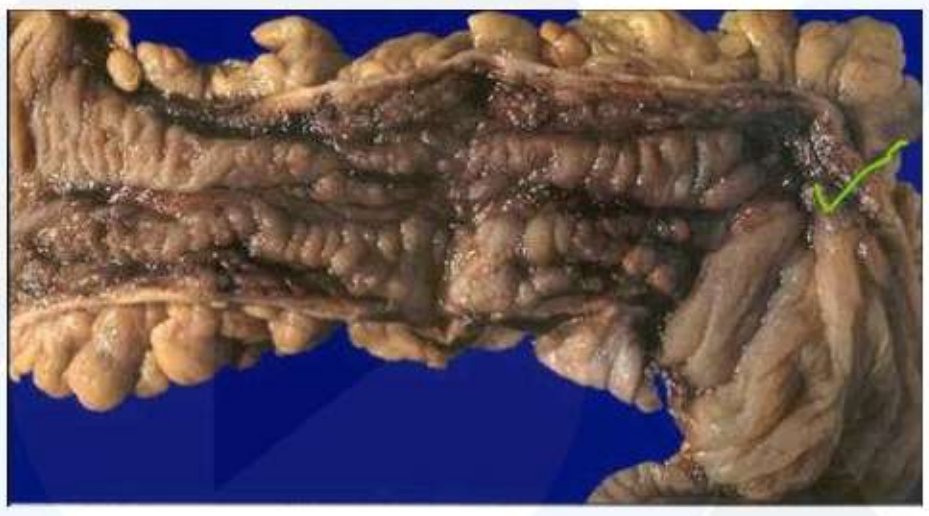

Crohn's disease 00:07:35

1. Chronic transmural inflammatory disease
2. Potential causes
   - Saccharomyces cerevisiae
   - Mycobacterium paratuberculosis
   - Measles virus
3. Earlies gross pathologic lesion is small superficial **Aphthous Ulcer.**

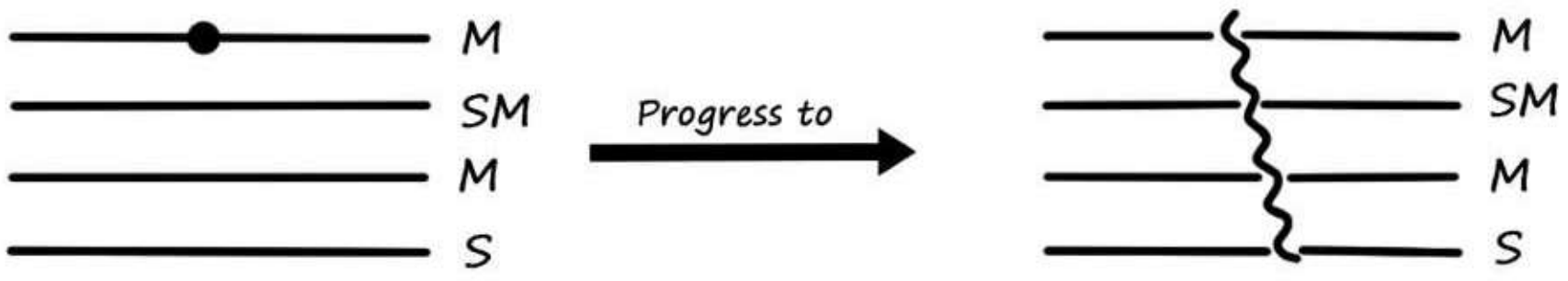

Transmural serpiginous ulcer

↓

Forming fissures, Fistulas and strictures

4. Mesenteric fat pad tries to cover transmural ulcer called **creeping pad of fat**
5. There is hypertrophy of muscularis / Fibrosis of sub mucosa → increased wall thickness (strictures)

Pathogenesis 00:14:08

Pathogenesis

I. Innate Immunity

pathogen
↓
release of DAMP
on stimulation by DAMP, NOD2
Activates inflammasome
↓
caspase 1 and 11
↓
apoptosis

DAMP – Danger associated molecular pattern
PAMP – Pathogen associated molecular pattern

II. Pathogen infected cell undergo, autophagy,
↓↓
if innate immunity fails, adaptive immunity comes into play.

Adaptive Immunity

Ag
↕
APC → Dendritic Cell / Macrophage

I. Dendritic cell

- Present Ag to CD4 cell → IL12 → TH1 Cells → IFN Gamma → Macrophages → Epithelioid cell → Granuloma [non caseating]
- IL-23 → TH 17 → IL17/22 → Neutrophils → Crypt abscess

(In active crohn's disease)

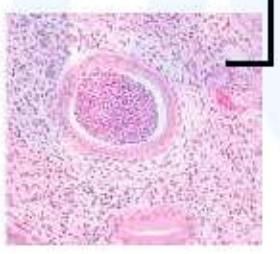

Non caseating granuloma is the morphological hallmark of Crohn's

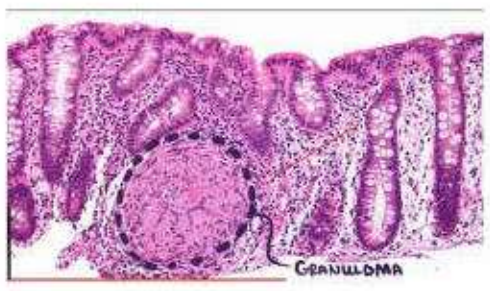

II. Macrophage
↓
TNF
↓ ulcerative colitis
Epithelial Damage

AfraTafreeh.com
TUTORIALS LOGIN FOR SUCCESS

AfraTafreeh.com

Genetic mutations are more common in Crohn's than ulcerative colitis.

Genetic mutation in Crohn's

1. NOD2 Mutation
2. Autophagy gene mutation
   a) ATG 16 L1
   b) IRGM – Immunity related GTPase M

- Main cell implicated in Crohn's – TH1 cells
- 3 main molecular implicated in

1. IFNγ
2. IL 12
3. TNF

Features of active Crohn's 00:29:50

1. Crypt abscess (Feature of Both CD and UD)
2. Irregular crypts with abnormal branching
3. Paneth cell metaplasia

Pseudo pyloric metaplasia

Antibodies in CD:

1. Anti-saccharomyces cerevisiae Ab (ASCA)
   ↓
   Specificity of 92% for Crohn's
2. Anti-flagellin antibody

GIST of Crohn's

mutation → NOD2, ATG16L1, IRGM

IFNγ, TNF, IL12

Active disease IL23

mutation or polymorphism of IL-23 result in milder disease.

AfraTafreeh.com
TUTORIALS
LOGIN FOR SUCCESS

AfraTafreeh.com

CARCINOMA OF COLON AND ANAL CANCER

Carcinoma of Colon 00:00:06

- Most common form is sporadic, without an associated strong family history
- Most common site-sigmoid
- Least Common-Hepatic flexure
- MC site of Metastasis-Liver

Etiology

- Molecular
  - FAP
  - Sessile
  - serrated adenomas
    ↓
    M/c mutation-**APC** on chromosome 5q
- Diet
  - Alcohol
  - decrease fiber
  - increase fatty
    ↓↓
    dysbiosis

Frizzled Receptor

APC → Activation of beta catenin pathway

↓

In nucleus activates Nuclear TF

↓

Cellular proliferation

APC – on chromosome 5q21

- Powerful tumor suppressor Gene
- Gatekeeper of colonic proliferation
- APC deletion → Activation of β catenin→ carcinoma colon

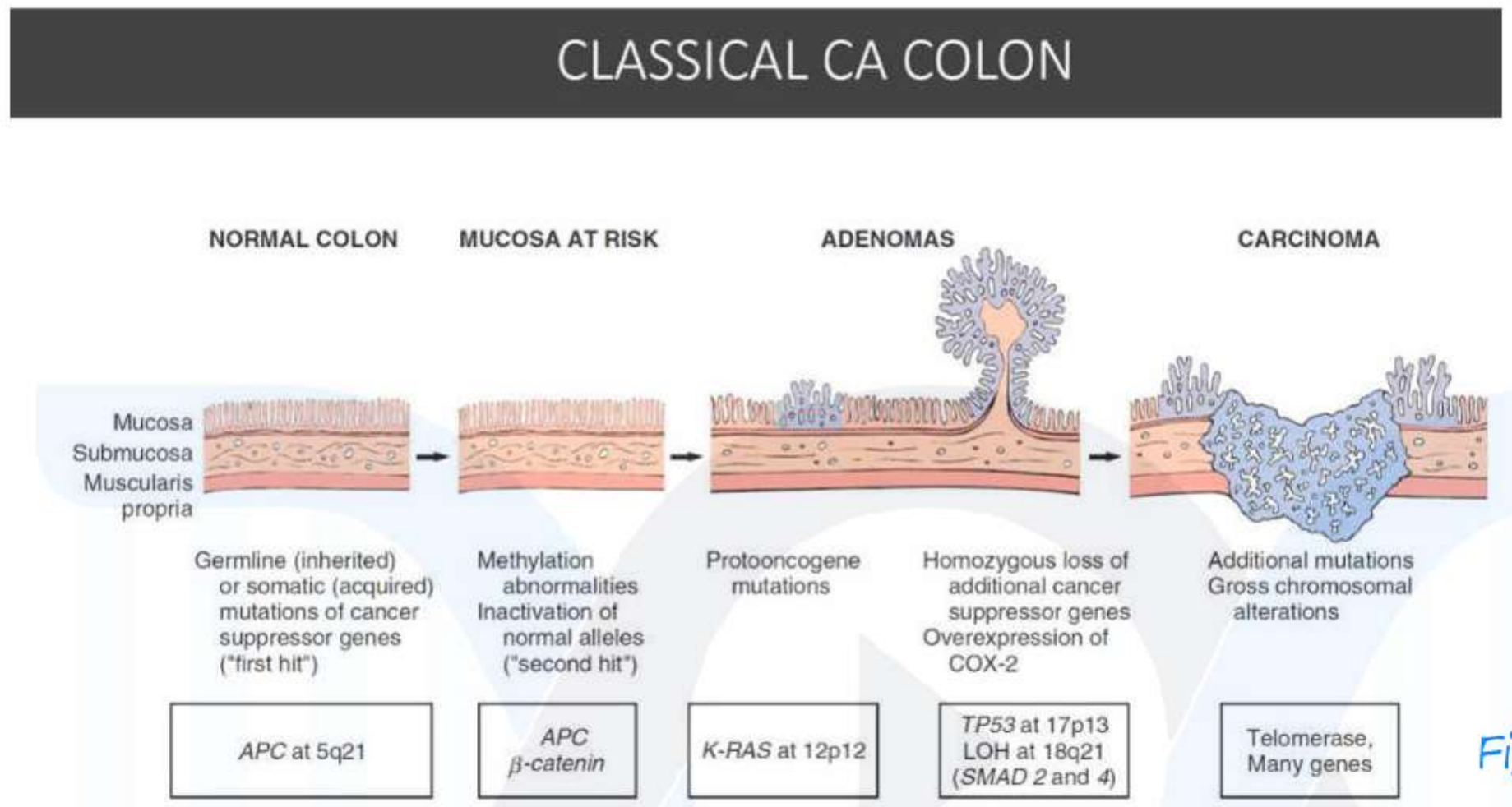

Fig 1

AfraTafreeh.com

Knudson Two Hit Hypothesis of tumor suppressor Genes

APC

↓ ← 1st Hit

APC ↓ ← 2nd Hit

-Loss of Heterozygosity

↓

Cancer

Colonic mucosa at risk

TUTORIALS
LOGIN FOR SUCCESS

AfraTafreeh.com

1st Mutation in causation of colon Ca is less of APC and activation of β catenin (Loss of APC mucosa at risk) → Mucosa at risk

↓

KRAS activation (Proto oncogene to oncogene)

↓ ← **P53 mutation**

↓ ← **SMAD 2& 4 mutation**

Adenoma formation

↓ activation of telomerase

Carcinoma

This is the classical Adenoma Carcinoma sequence

Sessile serrated Adenoma 00:13:16

Involves DNA mismatch Repair defect → Microsatellite Instability pathway

Mutation in **MLHI or MSH2** and MSH6, PMS1, PMS2

↓

Sessile serrated Adenoma

↓ ← TGFA R II

↓ BAX mutation

Carcinoma

- This carcinoma is more mucinous and has peritumoral lymphocytes
- Mucin production worsens the prognosis since mucin aids Tumor extension

CIMP phenotype 00:21:40

No mismatch Repair defect but **microsatellite instability present (MSI)**

↓

Hyper methylation of CpG islands in MLH1 gene

↓

This is called CIMP Phenotype

CIMP → CpG island Methylation phenotype

Has very high chances of BRAF mutation

CIMP path way

- MST
- MLH1 Hyper methylation
- BRAF mutations

AfraTafreeh.com

KRAS Mutation phenotype 00:25:55

- CpG Hyper methylated (CIMP) but no DNA mismatch Repair defect or No MSI
- No Microsatellite instability
- Associated with KRAS mutation
- Remember →

P53 mutations are never associated with methylation phenotype

AfraTafreeh.com

Symptoms of Ca colon

Right colon

- Fungating or cauliflower type Growth
- Patient present with
  - Melena anemia, fatigue
  - Abdominal pain
  - Mass in the rt Iliac Fossa
  - Good prognosis compared to left

Left colon

- Annular, constricting or stenosing growth
- patients present with
  1. Decrease in stool caliber
  2. Alteration of bowel habits
  3. Palpable lump
- poor prognosis (more infiltrative)

Adeno carcinoma colon — Important prognostic factor is
1) Depth of Invasion
2) LN involvement.

Carcinoma Anal canal 00:35:20

- Most common type is SCC, Bcc, Melanoma
- Median age 60 years
- Most common Symptom-Bleeding PR
- Most Common Lite of Metastasis-Lung

Risk factors- HPV infection (16, 18,31,33)

- HIV, Immunosuppression

Smoking

Chronic Inflammation

Cloacogenic carcinoma → Basaloid Type of carcinoma.

SCC: due to HPV and cause abnormal squamous cells development known to be Koilocytes which consists of Rasinoid nucleus and Perinucleus Halo.

HIRSCHSPRUNG DISEASE

Most common Affected site-Rectosigmoid 00:00:30

- Increased Risk with Positive family history &Down Syndrome
- Loss of RET gene is seen in 15-20%.

Pathogenesis -

- Due to defective migration of Neural crest cells to Colonic mucosa.
- Absent Ganglion cells in Myenteric (Auerbach's) & submucosal (Meissner's) plexus with hypertrophy of nerve trunks.
- Abnormal Bowel is the contracted Distal segment, where as normal Bowel is the proximal, dilated portion.

AfraTafreeh.com

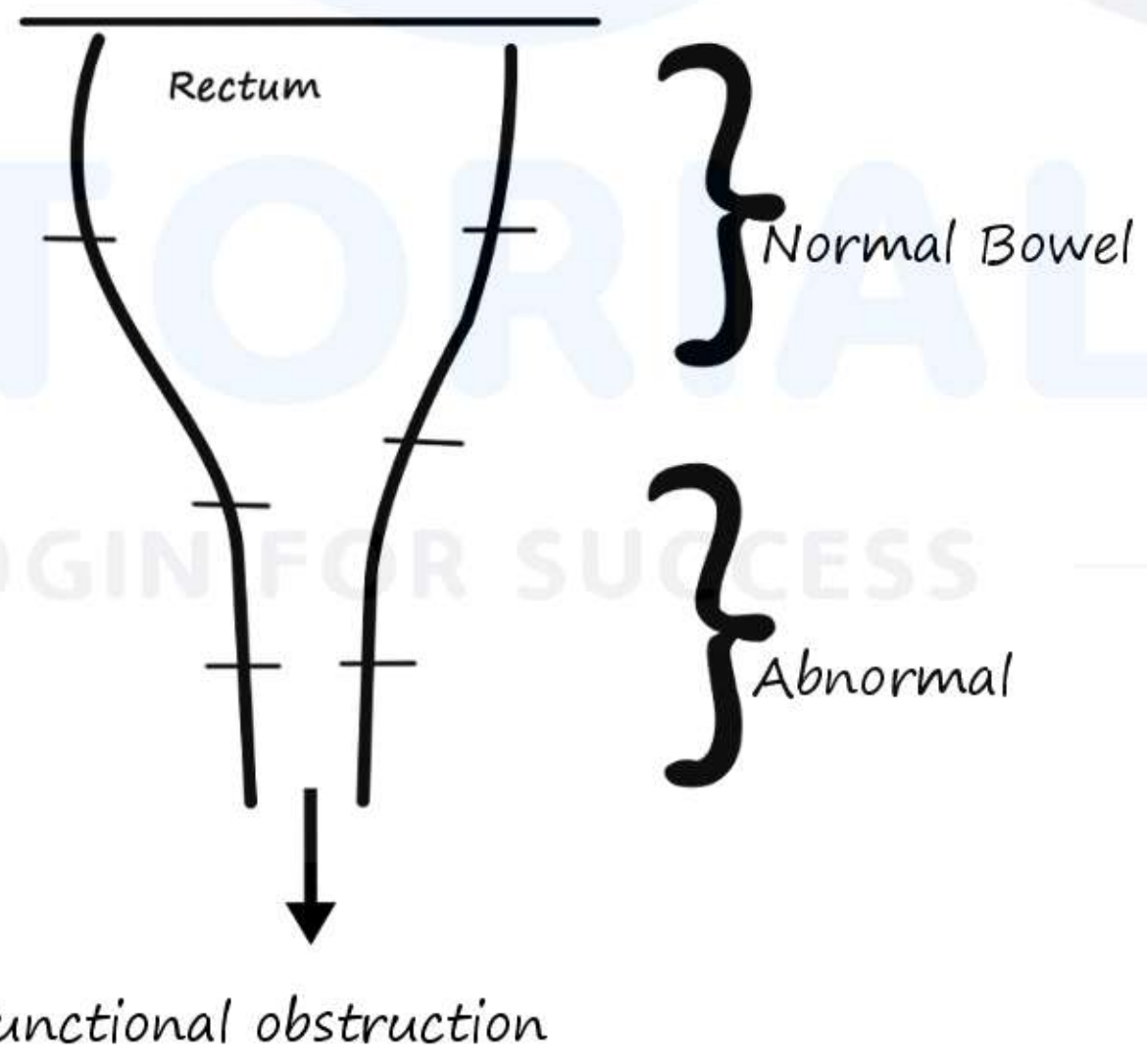

On HPE- Normal Ganglion cells- large nucleus with permanent nucleoli labelled as vesicular nucleus

↓

Absence of Ganglion cells in Hirschsprung's disease.

↓

IHC for Acetylcholine Receptor since Ganglion cells release Ach.

AfraTafreeh.com

OBSTRUCTIVE LUNG DISEASE BRONCHIECTASIS

Ecstatic → dilated

- Bronchiectasis -> irreversible dilation of bronchi

Etiology

Obstruction | Infection

Obstruction
↓
Due to obstruction the part below becomes abnormally dilated
↓
Obstruction bronchiectasis

Types of bronchiectasis

Generalized bronchiectasis (Lower lobes of lung)

- Syndromes
  - Immotile cilia syndromes
  - cystic fibrosis (FTR mutation)
- Debilitated patients

Localized bronchiectasis

Due to viral infection
Eg. Measles, pertussis
↓
Cause focal loss of smooth muscle & elastic tissue of brochi
↓
Abnormal dilatation

Immotile cilia syndromes

(Ciliary dyskinesia)

- **Kartagener's syndrome**
  Sinusitis
- Bronchiectasis
- Dextro cardia
- (With or W/O sipper
  inverse infertility -
- doublet of dysmin defected

Radial spoke deficiency
or sturges syndrome

♂ → Decrease Sperm motility

♀ → Oviductal cilia affected

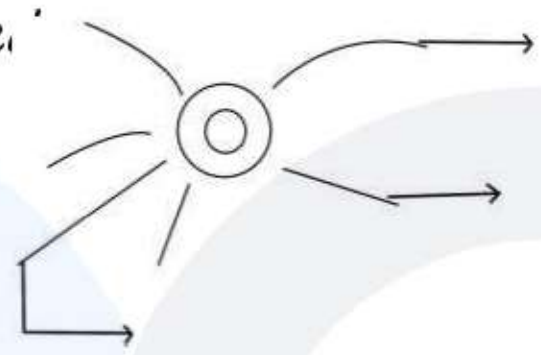

Outer & inner
When arms of dysmin
defective
↓
Causes Korthagen's
syndrome

Dysmin
↓
Central when doublet of
dysmin defective
↓
Causes radial spoke deficiency
A/K/A "Sturgers syndrome"

AfraTafreeh.com

Gross apperence of brochiectossis 00:08:43

Autopsy gross secimen from lungs suggested to the following. What is your interpretation?



Microscopy

- Squamous metaplasia of bronchial epithelium
- With presence of inflammatory cells

AfraTafreeh.com

Normal – Bronchi 2-3 cm away from pleura

A. Chronic bronchitis

B. Bronchiectasis

C. Lung ca

D. Pleural mesothelioma

Answer: B

- In brochiectasis abnormal & ieerversible diation of bronchi reaching upto pleuro Complications of bronchiectassis

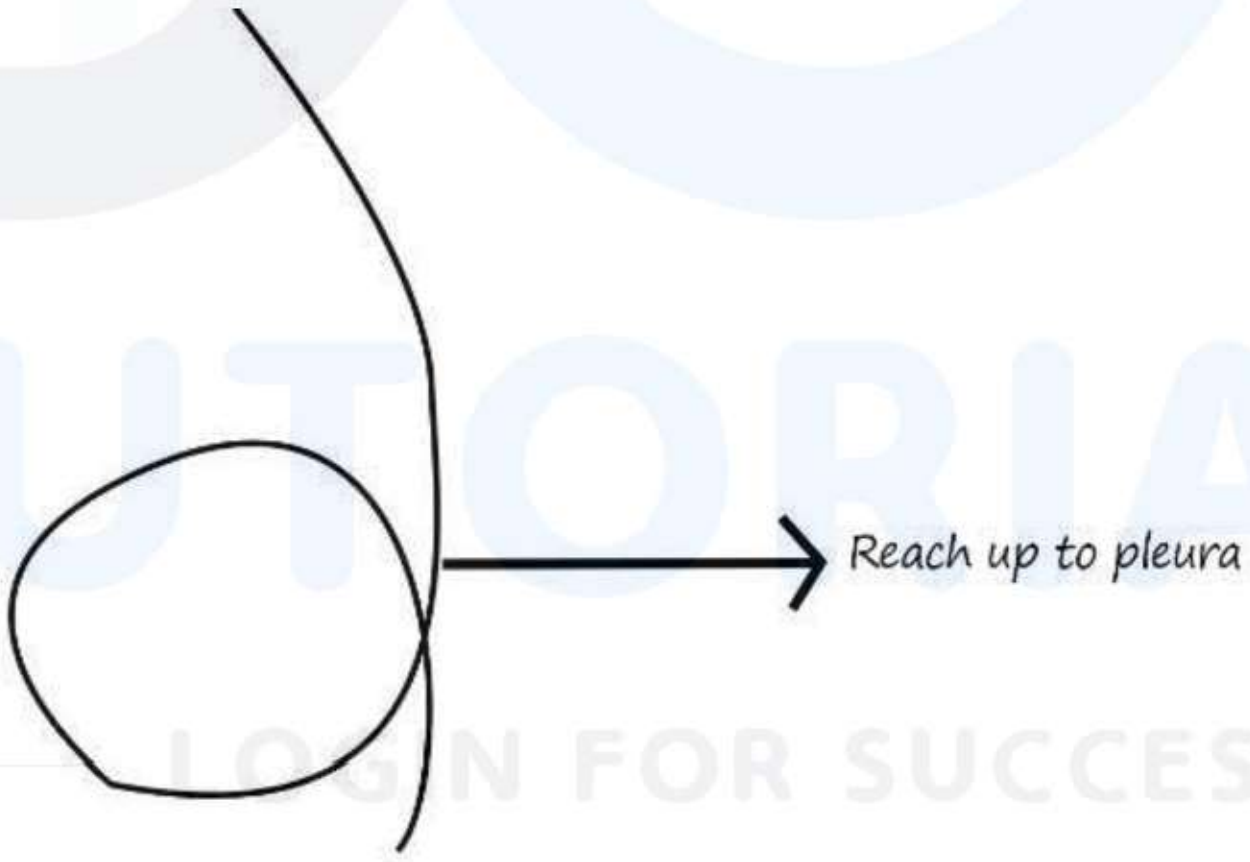

Lung abscess

Brain abscess | Synovitis | Amyloidosis

- Not a pre-cancerous lesion

OBSTRUCTIVE LUNG DISEASE ASTHMA

Types of asthma 00:01:56

Allergic asthma

- Most common type
- Occurs in children < 20yrs
- Positive family history of allergy
- Serum – IgE Ab increase
- Example: allergic Broncho-pulmonary aspergillum allergic bronchial asthma

Infectious asthma

- Childhood asthma
- RSV infection usually at < 2 Years of age
- Reversible

Exercise induced asthma

- Increased ventilation, cold

Occupational asthma

- Direct release of mediators of smooth muscle contraction after contact with an offending agent
  Example: - byssinosis (brown lung) – occupational lung disease of cotton workers due to hypersensitivity to cotton fibres

AfraTafreeh.com

Drug – induced asthma

- With aspirin
- Samter's triad – aspirin sensitivity
  Nasal polyp
  Asthma

Air pollution

- Airway remodelling findings

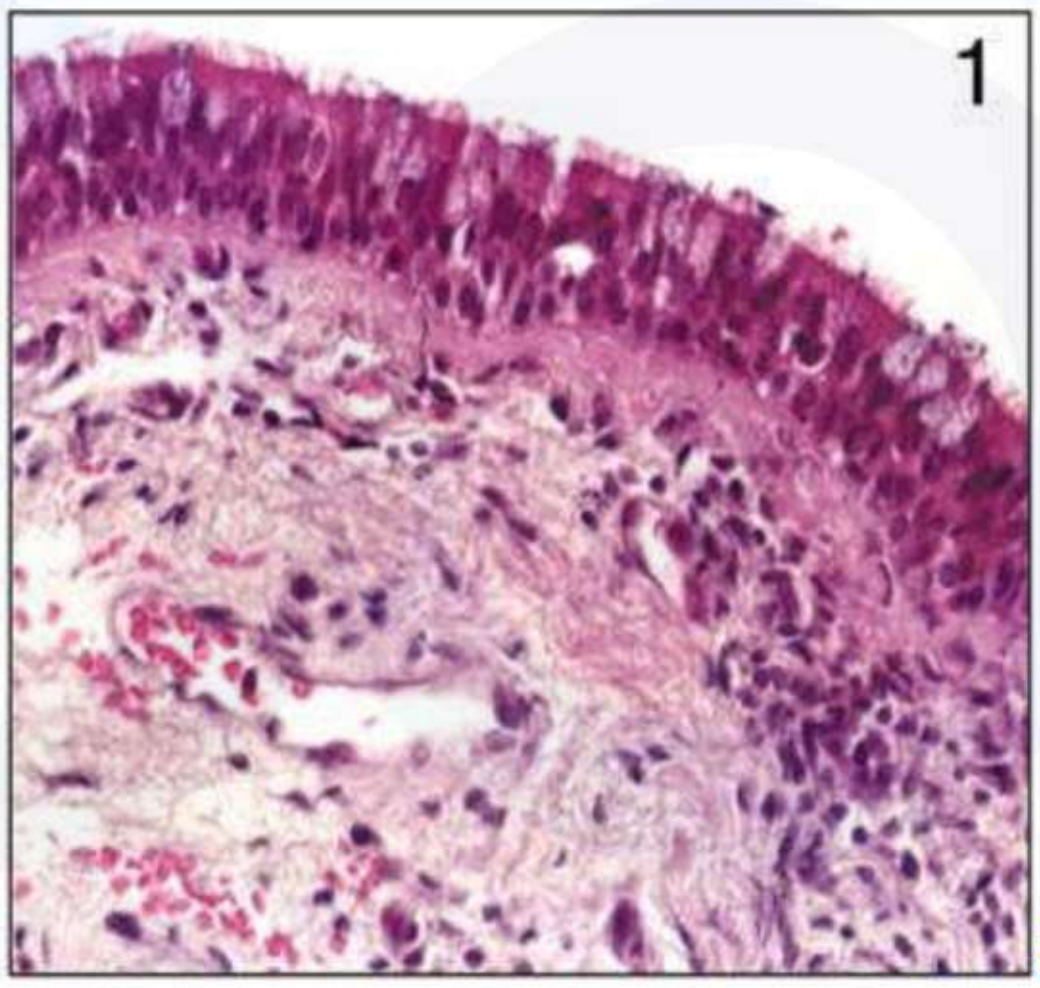

Fig: 1

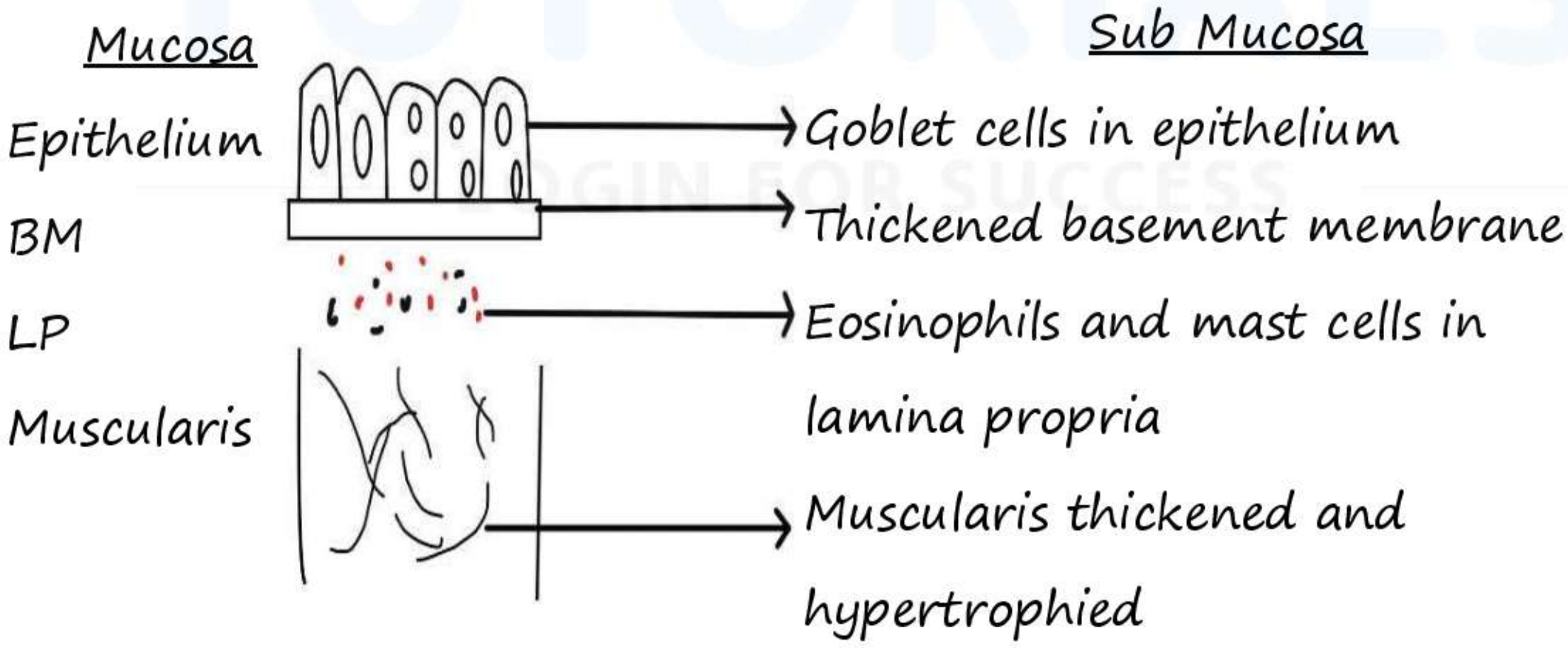

- Reid's index is normal since ratio of submucosal glands and total bronchial epithelium is normal
- Both mucosa & sub mucosa hypertrophied

Sputum cytology 00:13:22

- Fixative – Saccomano fixative (ethanol + Carbowax + water)
- Early morning sputum samples

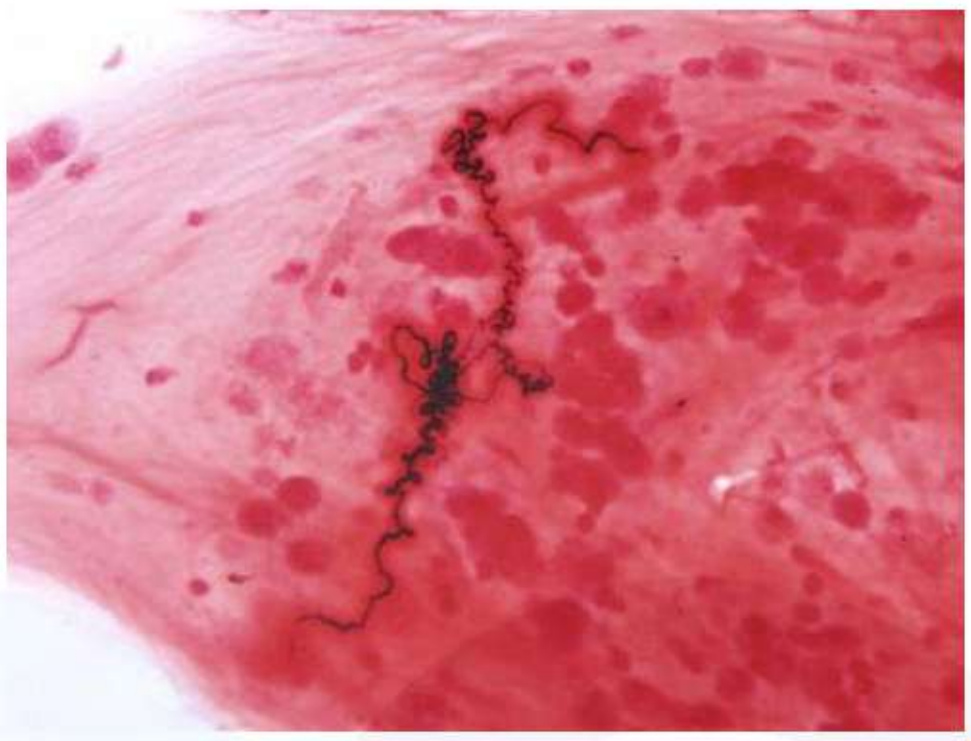

Fig: 2

Mucus plugs → churchman spirals

- Appear spiral became mucus takes the shape of bronchi
- Shedding of columnar epithelial cells → Creola bodies collection of respiratory epithelial in mucus plugs

AfraTafreeh.com

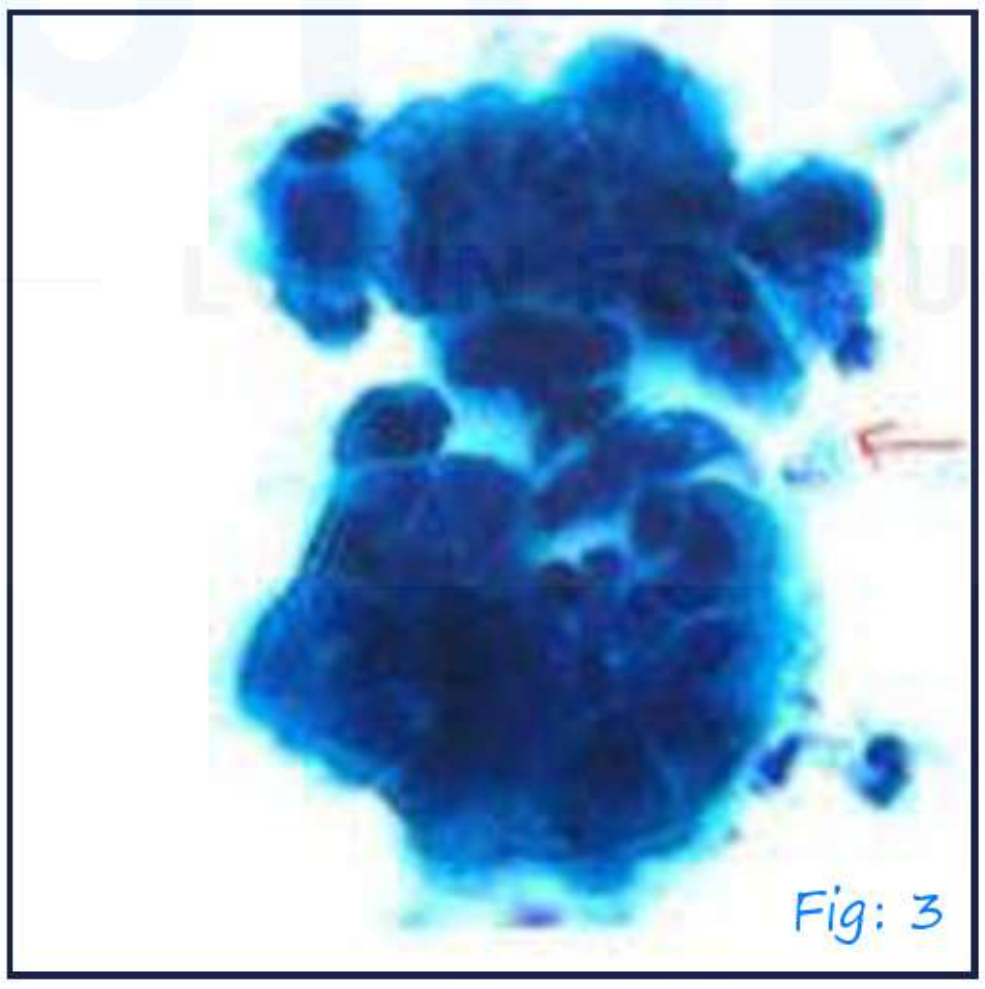

Fig: 3

AfraTafreeh.com

Charcot – Leyden crystals

- Bipyramidal structures
- Made of eosinophilic protein called Galectin-10 (Eosinophilic membrane protein)

Updates in asthma

Genes

- Chromosome 5q polymorphism with IL-13 mutation

↓

- Most common and most strong genetic association with asthma
- YKL-40 gene associated with airway remodelling
- ADAM-33 gene polymorphic characteristically associated with airway Hyper-responsiveness

↓

- Thickening of Muscularis & fibrosis → narrowing of tumor

↓

Wheezing

RESTRICTIVE LUNG DISEASE WITH FOCUS ON PENUMOCONIOSIS

- Lung expansion is restricted
- $\frac{FEV_1}{FVC}$ (N) or > 0.7
- $FVC < 80\ \%$

Intrinsic Restrictive Lung disease	Extrinsic Restrictive Lung disease
↓	Pulmonary parenchyma not involved
Pulmonary Parenchyma involved	Kyphoscoliosis
↓	Neuro-muscular disorders
Fibrosis / Interstitial Lung disease	Polio
Occupational lung disease	Myasthenia Gravis
Sarcoidosis	GBS
	Amyotrophic Lateral Sclerosis

AfraTafreeh.com

DOC TUTORIALS
LOGIN FOR SUCCESS

I. Interstitial & Infiltrative Disorders 00:01:50

- PNEUMOCONIOSIS

Occupational lung disease caused by organic/ Inorganic dust fibers

- Carbon
- Silica
- Byssinosis → Occupational asthma
- Asbestos
- Berryliosis ↓

AfraTafreeh.com

Type of hypersensitivity disorders

I. SILICA:

Crystalline silica
↓
Damages Macrophage
↓
Release of fibro genic Cytokines
↓
Formation of Fibrotic Nodules

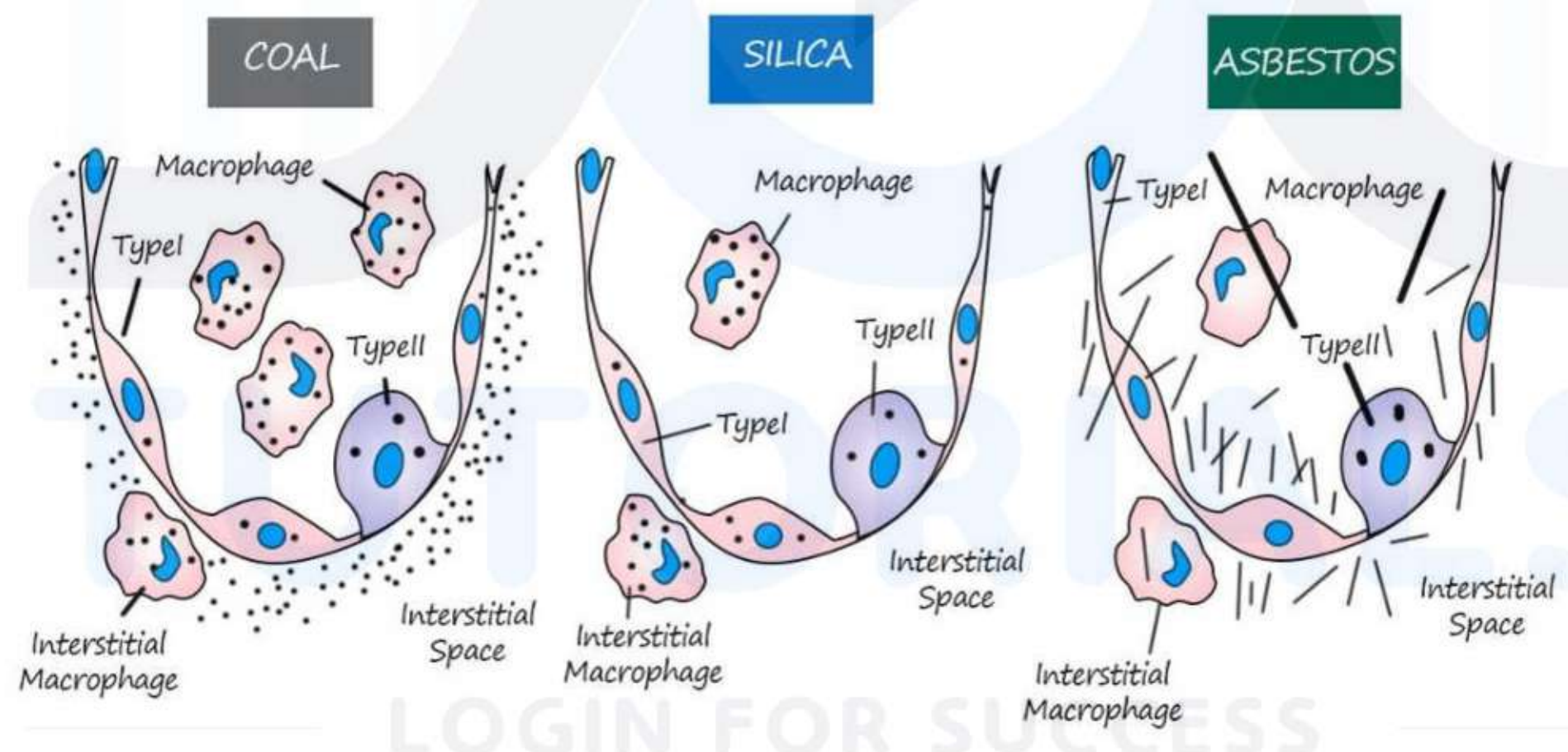

"Collagenous Silicotic Nodule"

Fig: 1

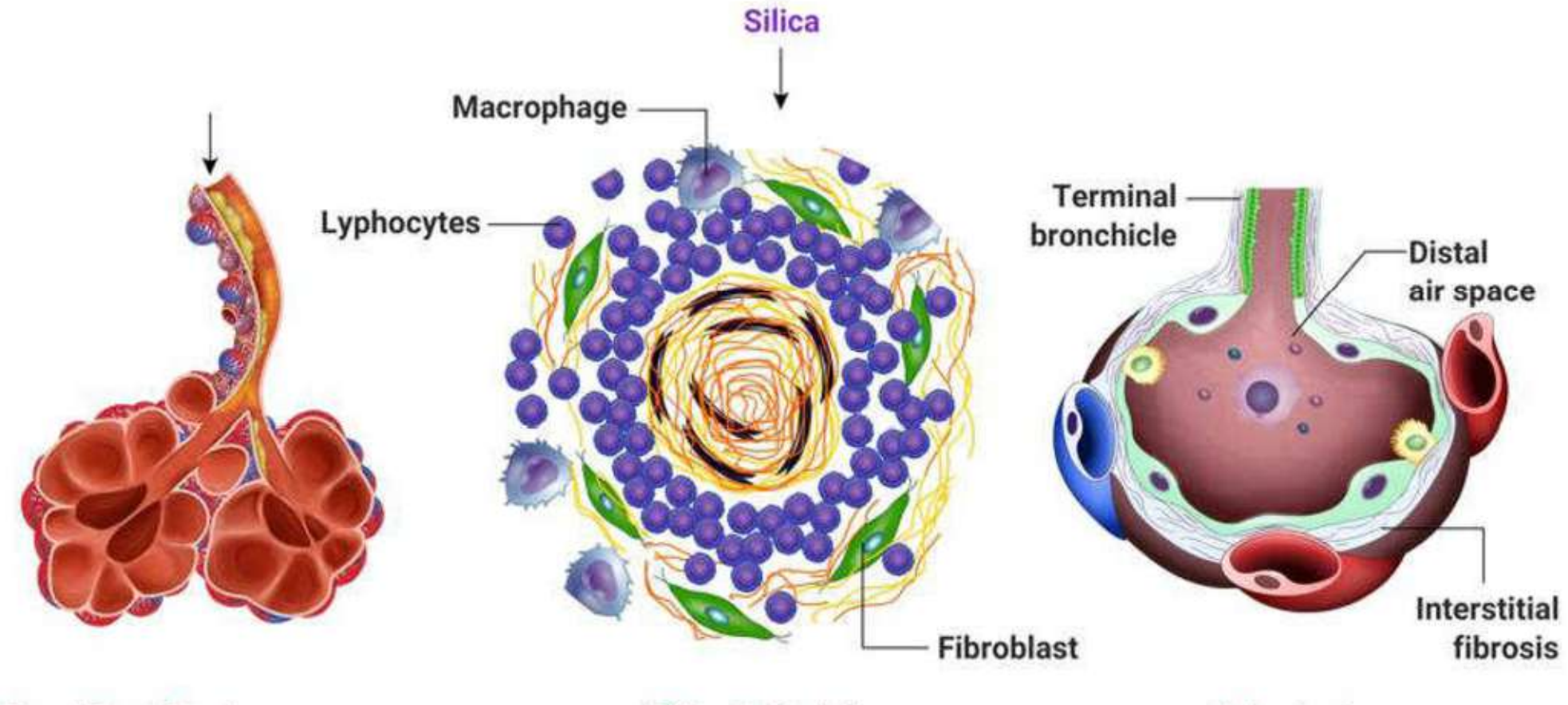

Fig: 2

II. ASBESTOS

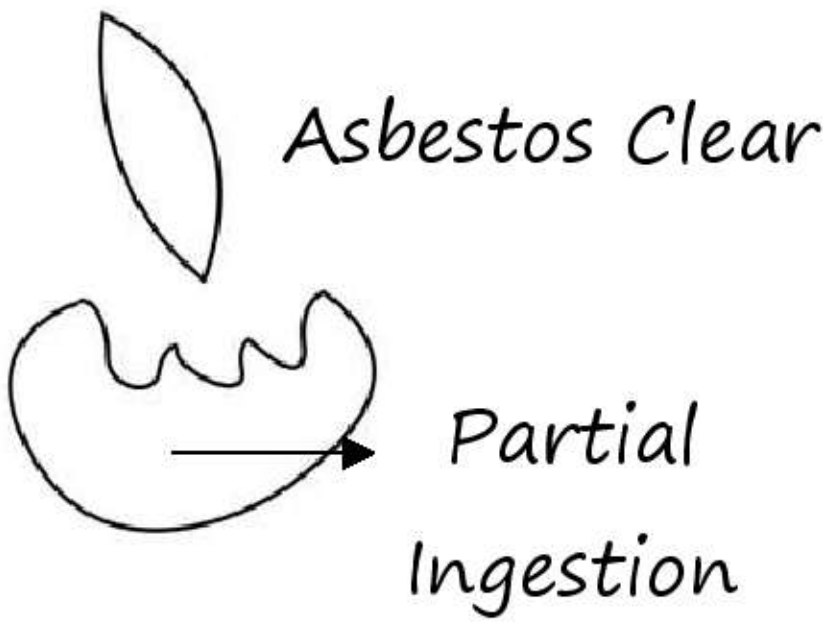

- Clear core

Macrophages try to digest

- Triturates Interstitium
  ↓
  Causing Interstitial Fibrosis
- Cause Partial ingestion and deposition of Iron and Proteinaceous material around and within Asbestos fibers forming Asbestos Bodies / Ferruginous bodies

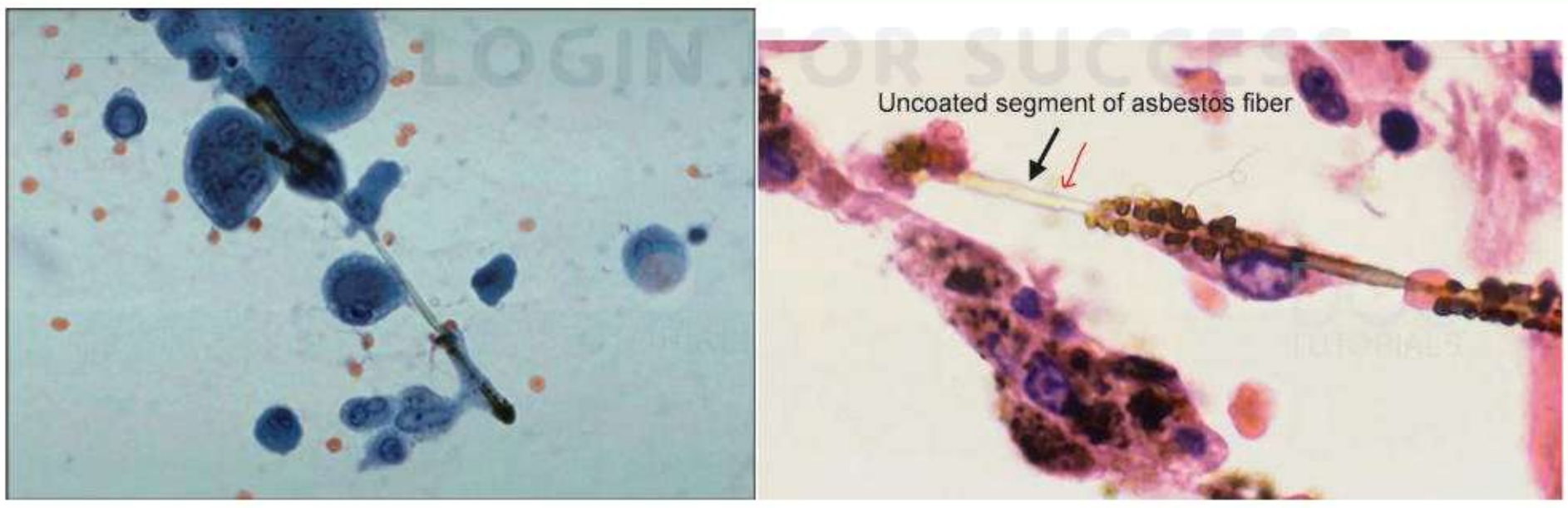

Optically Clear Dumbbell Shaped

Ferruginous Body Stained by Perl's stain

Fig: 3

AfraTafreeh.com

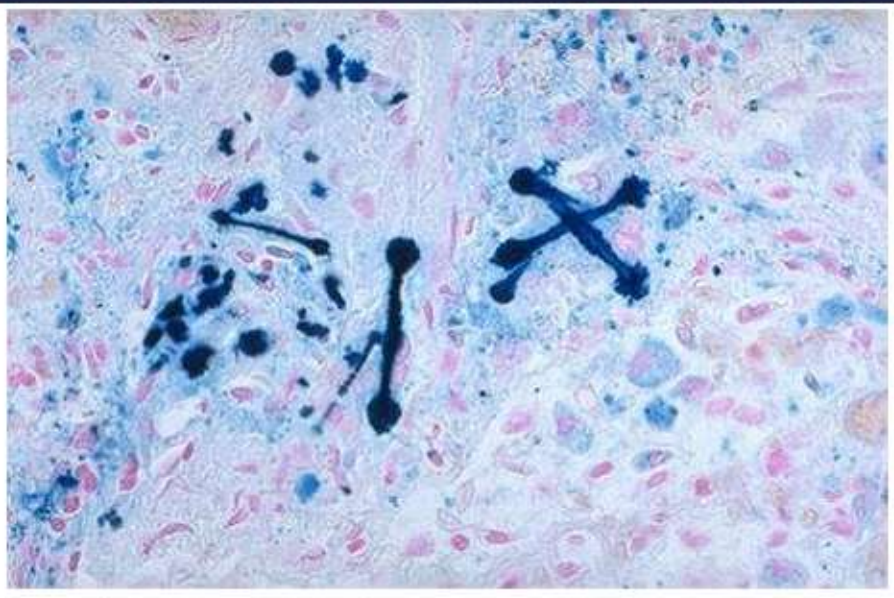

Asbestos Body surrounded by Giant Cells Fig: 4

III. CARBON – Causes Coal Worker Pneumoconiosis

- Macrophages digest Carbon completely and turn Black in colour forming Dust Cells.

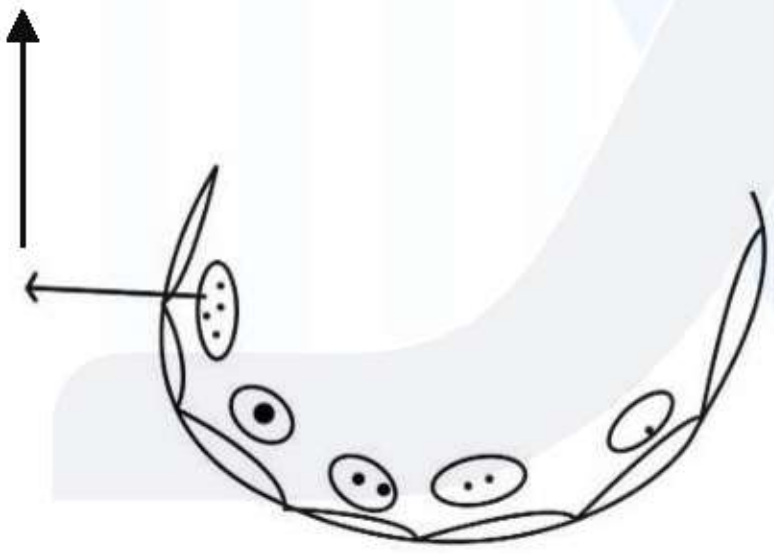

When the exposure is Prolonged and excusive Carbon particles enter Interstitium and deposit around Respiratory Bronchioles forming Macules / Nodules.

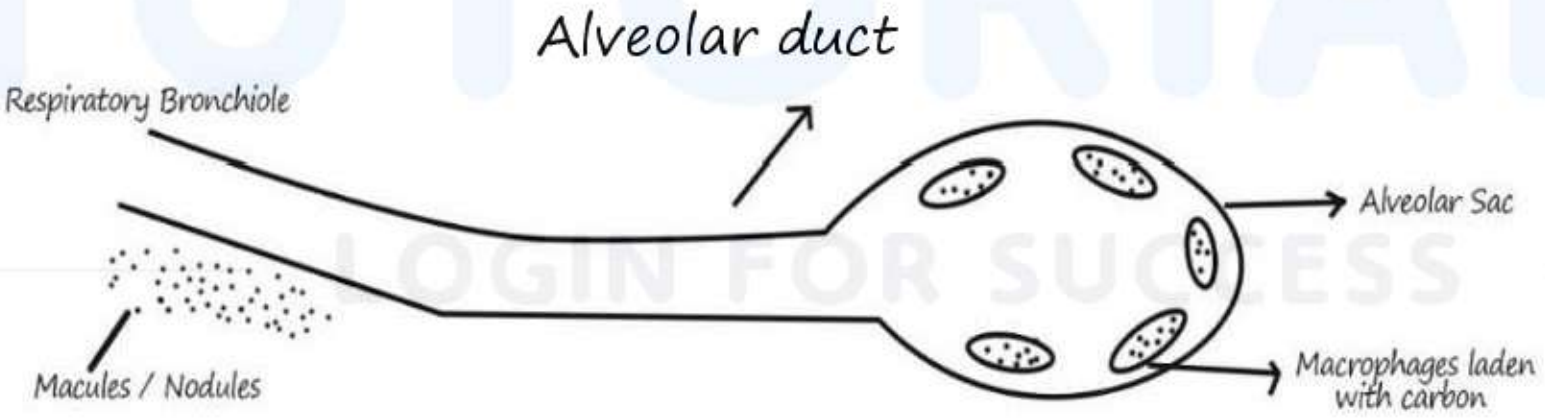

Macules / Nodules

↓

Fibrosis

↓

Dilatation of Respiratory Bronchioles

↓

Centric – acinar emphysema

(Proximal part of Acinus dilated)

RESTRICTIVE LUNG DISEASES CLASSIFICATION (EXCEPT PNEUMOCONIOSIS)

Restrictive lung diseases

I. a/w Fibrosis

i. Idiopathic Pulmonary fibrosis

ii. Non-specific Interstitial fibrosis

iii. Cryptogenic organizing pneumonia/ BOOP (Bronchiolitis obliterans Organizing Pneumonia)

II. a/w Granulomas

Hypersensitivity Pneumonitis

Sarcoidosis

III. a/w Smoking

i. Desquamative International Pneumonia

ii. Bronchiolitis Obliterans

iii. Pulmonary LCH (Now Classified as District entity)

IV. Others

Pulmonary Alveolar Proteinosis

AfraTafreeh.com
TUTORIALS
LOGIN FOR SUCCESS

Hypersensitivity pneumonitis (HP)

- Hypersensitivity of Lungs to Organic dusts
- A/K/A Extrinsic Allergic Alveolitis / Pneumonitis

Pathogenesis

I. Antigen → Antibody → Ag+Ab deposits in Alveoli

AfraTafreeh.com

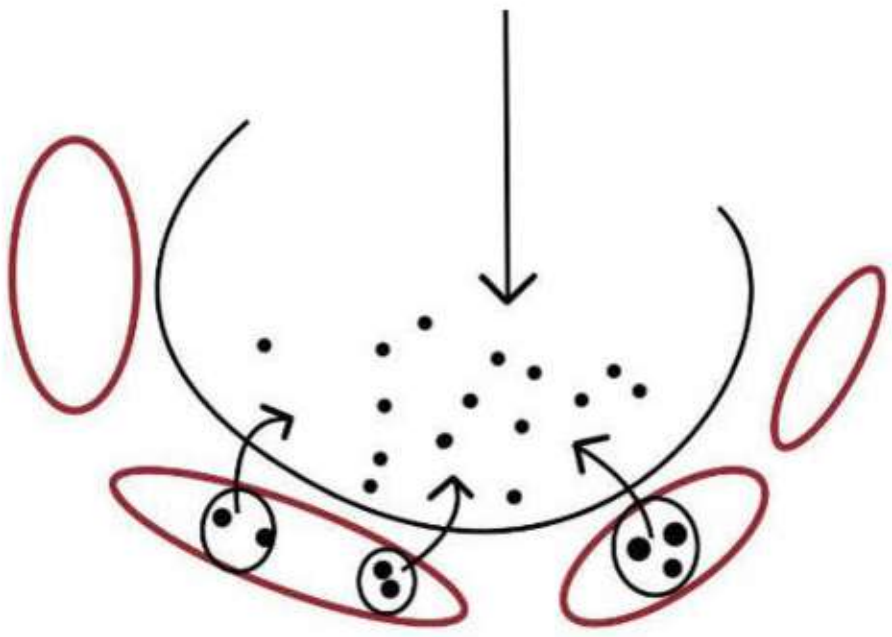

Neutrophils enter alveoli to phagocytose the immune complete

↓

Activation of Complement Proteins

↓

Edema

- Type III HSR

II. Ag → APC

↓

CD4

↓

TH1

↓

IFN8

↓

Macrphager → Epithelioid cell

↓

Granuloma (Non-caseating)

III. Ag

↓

CD8 cells

↓

Kills AG coated cells

- Type IV HSR
- So, Hypersensitivity Pneumonitis → Type III / Type IV HSR

(No Raised IgE or eosinophilia)

Inhalants Causing Hypersensitivity Pneumonitis

i. Farmer's Lungs – Micropolyspora faeni from Moldy Hay

Fig: 1

LOGIN FOR SUCCESS

ii. Bagassosis – Thermoactinomyces sacchari in Moldy sugar cane

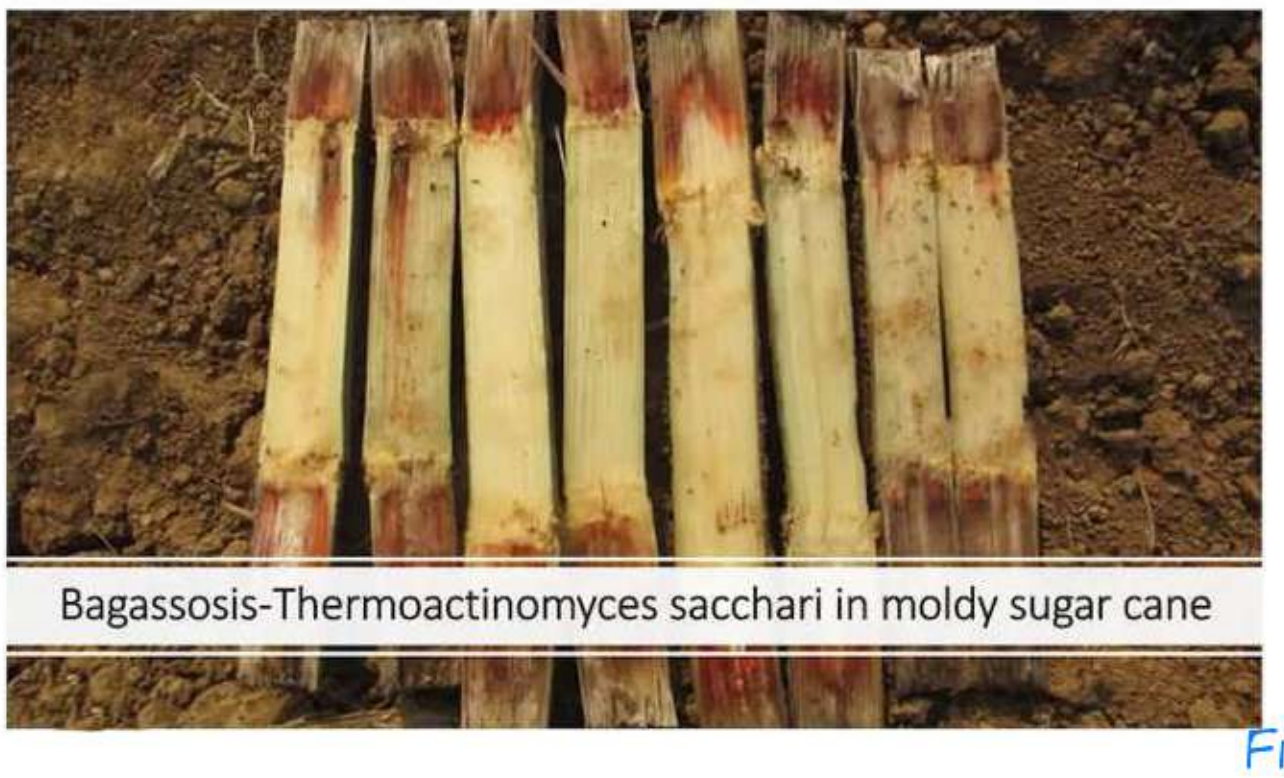

Fig: 2

AfraTafreeh.com

iii. Maple Bark– Stripper's diseas– fungus Cryptostroma corticale in moldy maple bark



Fig: 3

iv. Bird fancier's lung – Proteins from bird feathers.

v. Hot Tub lung – Mist from Hot Tub has Mycobacterium Avium complex (MAC)

vi. Byssinosis – Cotton fibers causing Occupational Asthma

vii. Berryliosis – Inorganic dust Beryllium causes

- Pneumoconiosis
- Hypersensitivity Pneumonitis
- Closest differential of Sarcoidosis

Histology of hypersensitivity pneumonitis

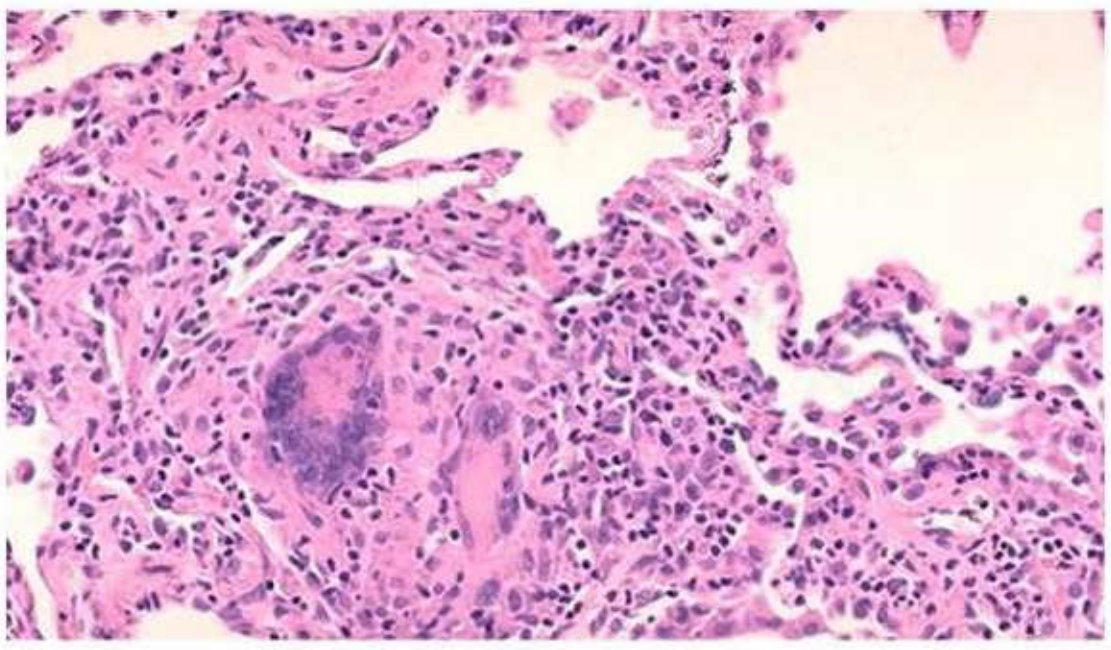

Fig: 4

- Poorly formed Granuloma

- Giant cells
- Granulomatous Interstitial Lung disease with Lymphocytic infiltration.

Diagnosis

- Detect presence of IgG antibodies against the antigen by Fluorescent Enzyme Immunoassay (FEIA)

Ab
↓ → Fluorescence
IgE
+
Ag

- Target Fluorescently tagged Ab against IgG specific for the Antigen.
- CXR/CT scan -

Ground Glass appearance of Mid-zone, lower zone

(patho-Alveolitis)

↓

Reticulo -Nodular shadows

↓

AiraTafreeh.com
DOC TUTORIALS
LOGIN FOR SUCCESS

AfraTafreeh.com

Fibrosis

↓

Honey Comb Lung (due to Traction caused by Fibrosis)

- Broncho alveolar lavage (D8 > CD4

Hypersensitivity Pneumonitis	Sarcoidosis
Poorly formed Non-caveating Granuloma BAL CO 8 > CD4	Well-formed Non-caveating Granuloma BAL CD4 > CD8

TUTORIALS
LOGIN FOR SUCCESS

RESTRICTIVE LUNG DISEASE PART – III SARCOIDOSIS AND ITS DIFFERENTIALS

- Multisystem, chronic Granulomatous inflammatory disorder of unknown etiology

Pathogenesis 00:00:07

Ag
↓
APC
↓
THS Cells
↓
IFN Gamma

Macrophages → Epithelioid cells → Granuloma

Characteristic of Sarcoid Granuloma

i. Non-Caseating epithelioid cell granuloma

ii. Naked granuloma – No lymphocytes



Fig: 1

iii. Concentric Lamellar fibrosis

iv. Involve Submucosa of Bronchi with Protrusions in bronchi

AfraTafreeh.com

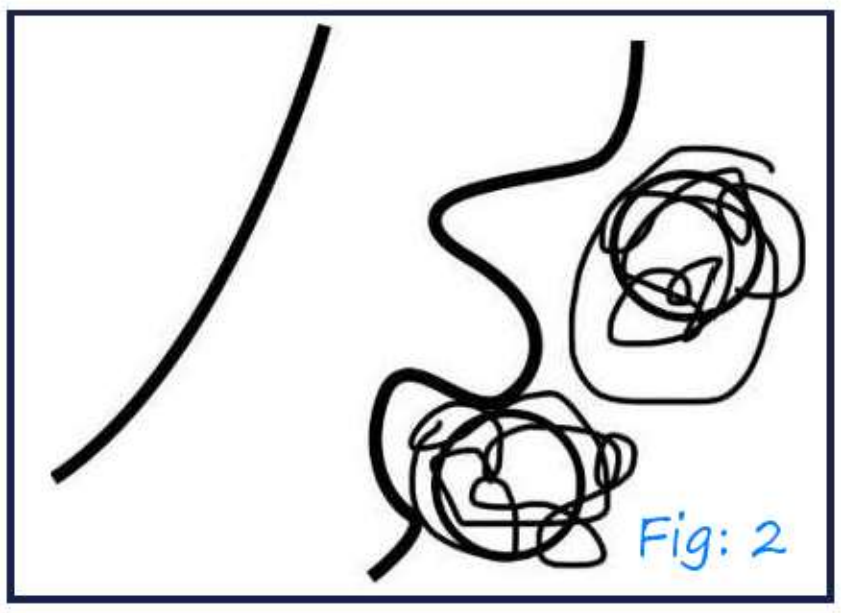

Fig: 2

v. Minimal interstitial fibrosis

vi. Granuloma show typical bodies in Giant cell

- Asteroid - star shaped body
- Schuman - Calcified bodies

vii. Sarcoid Granuloma travel along Broncho vascular bundles and can also involve pleura

viii. Granuloma of Sarcoid has 1 alpha hydroxylase activity

→ ↑ Vit D → ↑ Ca^{2+} → stones

Diagnosis

i. BAL CD4 : CD8 > 10 : 1

ii. Gallium 67 - Finds location of Granuloma

Lambda sign or Panda sign

iii. Increase ACE

iv. Biopsy - Granuloma in submucosa of Bronchus - Story predictor of sarcoidosis

Manifestations

i. Lung – Interstitial Lung disease

ii. Skin – erythema Nodosum Lupus pernio

iii. Uveitis Parotitis

iv. Raised Serum Calcium

Differential Diagnosis of Sarcoidosis

i. Berylliosis

- Hypersensitivity reaction to Beryllium
- Non-Caseating epithelioid cell Granuloma
- These Granulomas also follow Broncho vascular bundles and pleura
  (Except submucosa of Bronchus not involved)
- No Concentric Lamellar fibrosis
- Sequelae of both Sarcoidosis & Berylliosis

↓

Honey -Comb lung

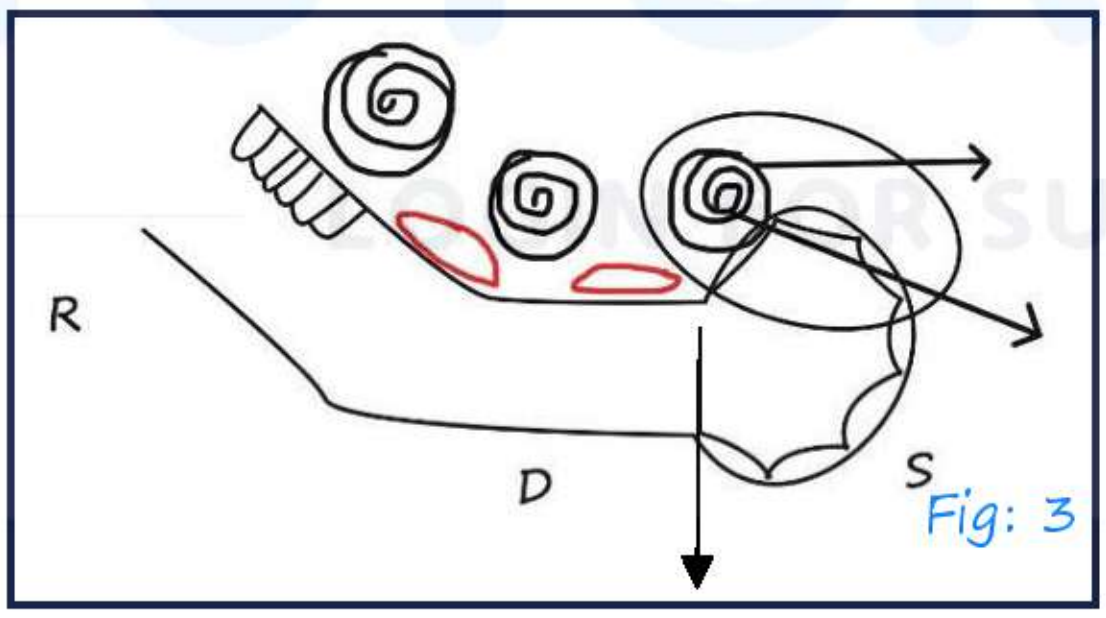

Fig: 3

Granuloma and fibrosis cause decapitation of apical part of distal Acinus

↓

Formation of Cystic space lined by bronchiolar epithelium

↓

Honey Comb lung appearance

AfraTafreeh.com

- Honey comb lung is indicative of Interstitial inflammation

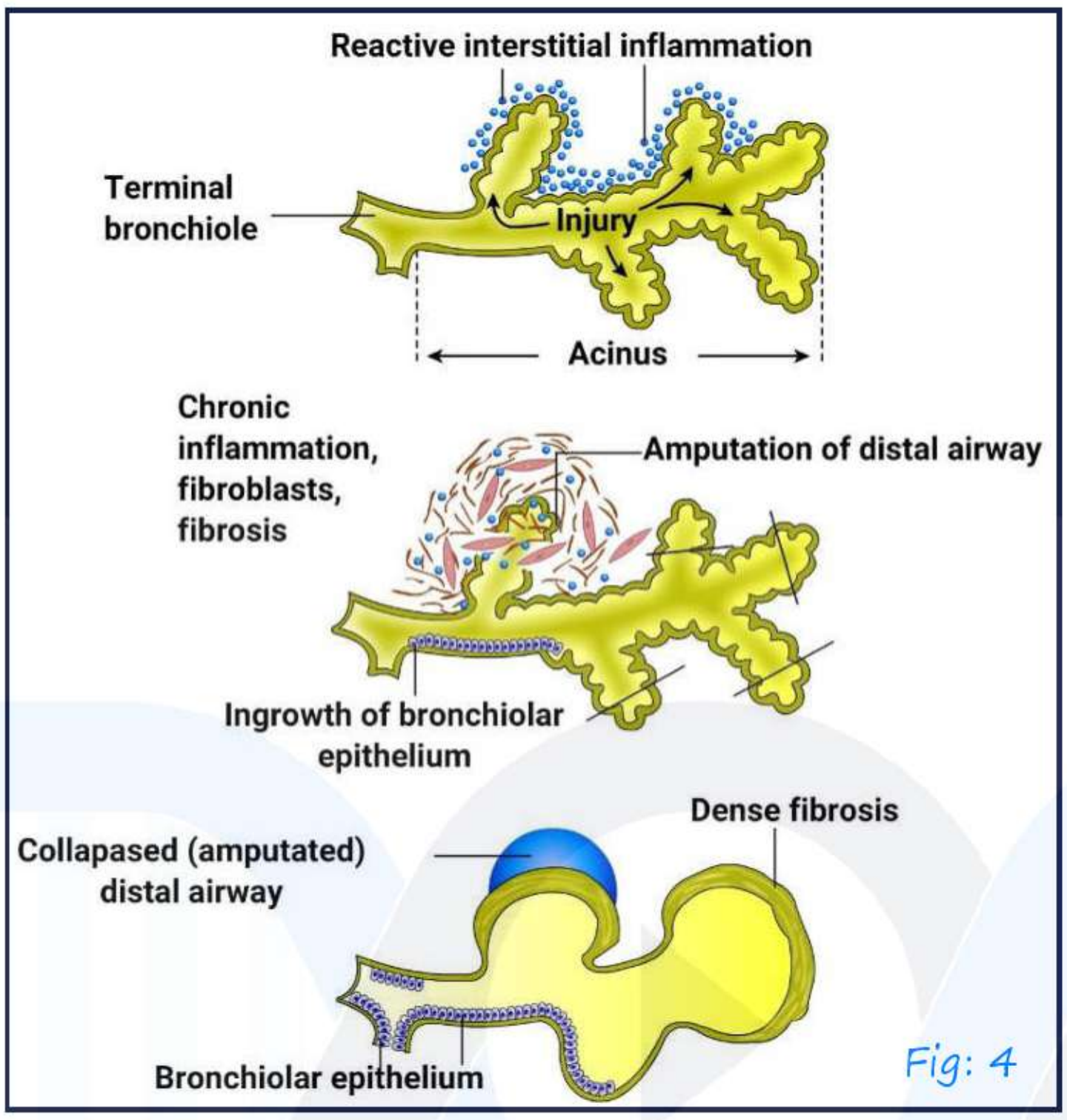

Fig: 4

- Beryllium Lymphocyte Proliferation Test

Incubate

If lymphocytes proliferate → Berylliosis Confirmed

RESTRICTIVE LUNG DISEASE FIBROSING RLD AND HONEYCOMB LUNG

Fibrosing RLD

i. Usual Interstitial Pneumonia / Idiopathic Pulmonary Fibrosis
ii. Non-specific Interstitial Fibrosis
iii. Cryptogenic Organizing Pneumonia / BOOP

I. Usual Interstitial Pneumonia / IPF

Causes

i. Viral
ii. General
iii. Autoimmune – associated with RA

Genetic Mutations

i. Telomerase mutation – TERT / TERC (associated with Abnormal Telomerase shortening)
ii. MUC 5 B gene mutation (associated with excessive fibrosis in lung)
iii. Surfactant Protein C mutations

Pathogenesis

- Release of abnormal cytokines causing Interstitial Fibrosis
- This fibrosis shows–Temporal Heterogeneity

↓

AfraTafreeh.com

Implies both newly formed fibrosis and old collagen scars seen together

New fibroblastic proliferation

Old collagen scars

- These Patients eventually develop Honey Comb Lung [Damage of Distal acinus Causing formation of cystic spaces lined by bronchiolar epithelium]
- IPF usually involves lower lobes more

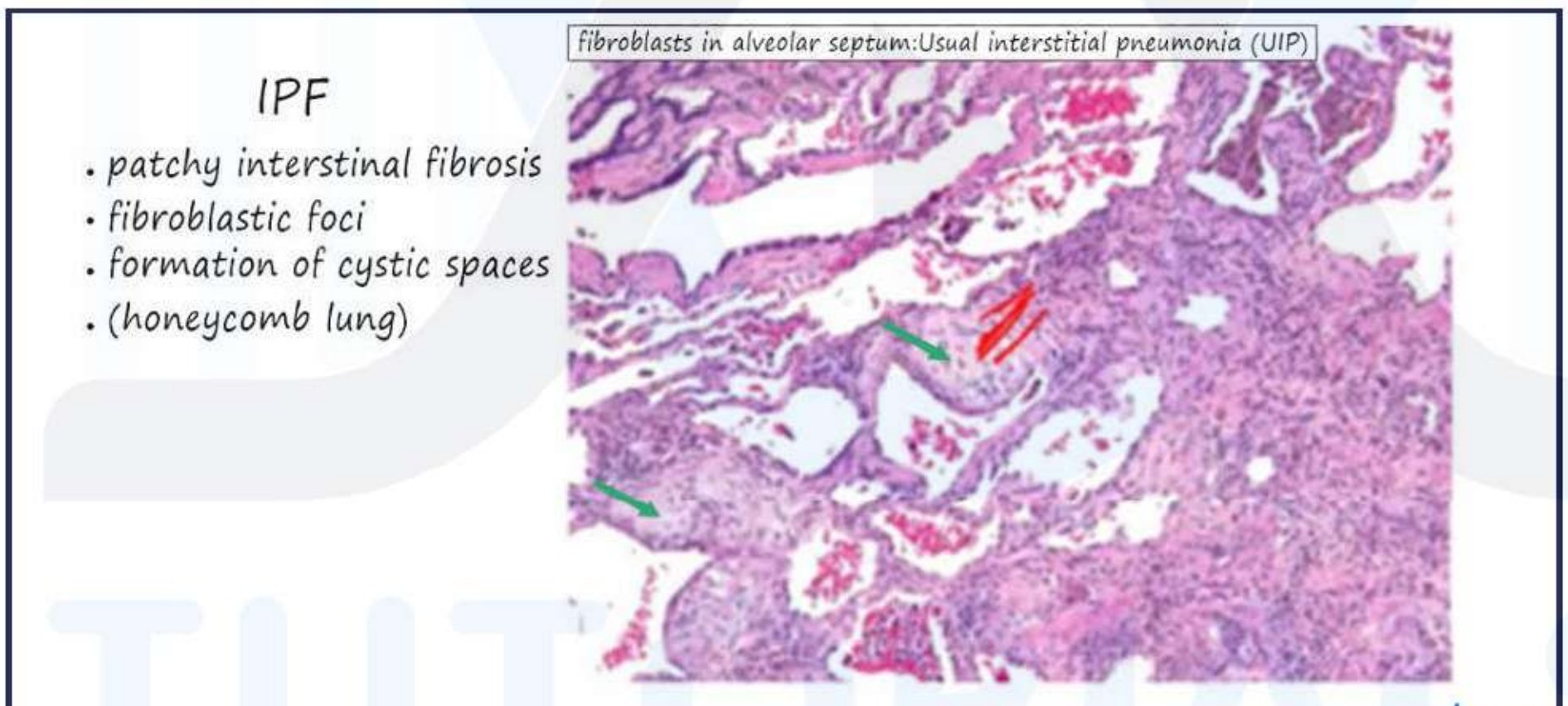

Fig: 1

Interstitial Fibrosis

Fibroblastic foci formation of cystic to arear of Interstitial Fibrosis

- Prognosis is not good

II. Non – Specific Interstitial Fibrosis (NSIF)

- Does not show Temporal Heterogeneity
- Only New Fibroblastic proliferation and Interstitial Fibrosis seen
- No – specific cause known

- Does not show Honey – comb lung

III. Cryptogenic Organizing Pneumonia

Formation of Fibroblastic Foci involving

Bronchioles → Bronchiolitis

Alveoli → Organizing pneumonia

↓

Bronchiolitis obliterans Organizing Pneumonia

- These Fibroblastic proliferations are called MASSON Bodies
- Do not cause Honey comb lung. No interstitial Fibrosis

AfraTafreeh.com

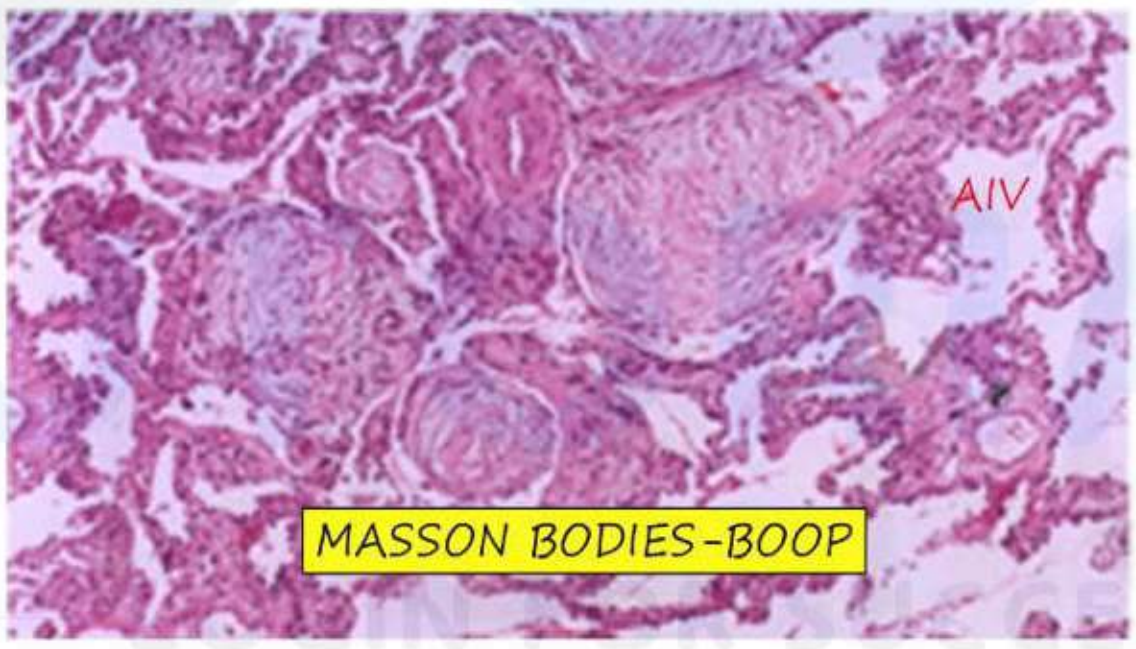

Fig: 2

Large fibrotic Foci entering alveoli and Bronchioles

Honey comb lung

seen	Not Seen
i. Idiopathic Pulmonary Fibrosis	i. NSIF ii. COP / BOOP – Masson Bodies

AfraTafreeh.com

RESTRICTIVE LUNG DISEASE – SMOKING RELATED RLD AND PULMONARY ALVEOLAR PROTEINOSIS AND GIST ALL OF RESTRICTIVE LUNG DISEASE

Smoking

Desquamative Interstitial Pneumonia (DIP)	Bronchiolitis associated interstitial pneumonia	Pulmonary Langerhans cells Histiocytosis

Desquamative Interstitial Pneumonia (DIP) 00:01:15

- Smoking → Damage of Pulmonary type II Pneumocytes

↓

Shed into Alveoli

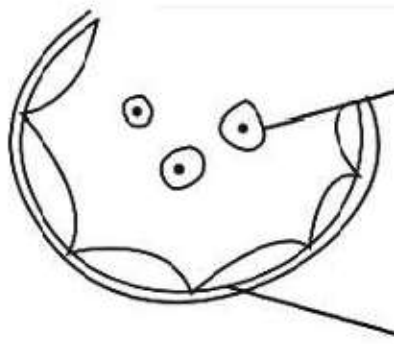

Lamellar Bodies Shed Type II Pneumocytes

Previously called Smoker Macrophages

Thickened Septa

- Equally seen in Males & Females

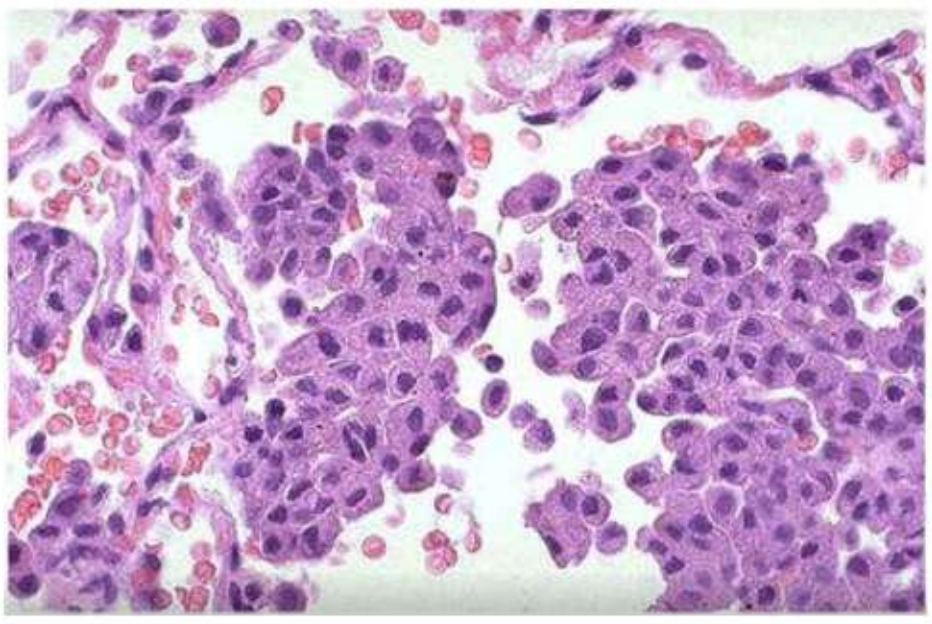

Fig: 1

Bronchiolitis Associated Interstitial Pneumonia 00:03:37

- Seen in 1st and 2nd degrees Bronchi
- Smoker Macrophages clustered around Bronchi i.e **Bronchiocentric Collection**
- Both DIP and Bronchiocentric Interstitial Pneumonia can progress into Centrilobular Emphysema DIP >> BIP

AfraTafreeh.com

Pulmonary Langerhans Cell Histiocytosis 00:05:20

- Associated with BRAF Mutation
- Seen in Smokers
- On Histology: Lot of Langerhans cells with Grooves and lots of Eosinophils.
- Langerhans Cells identified by CD a & CD 207

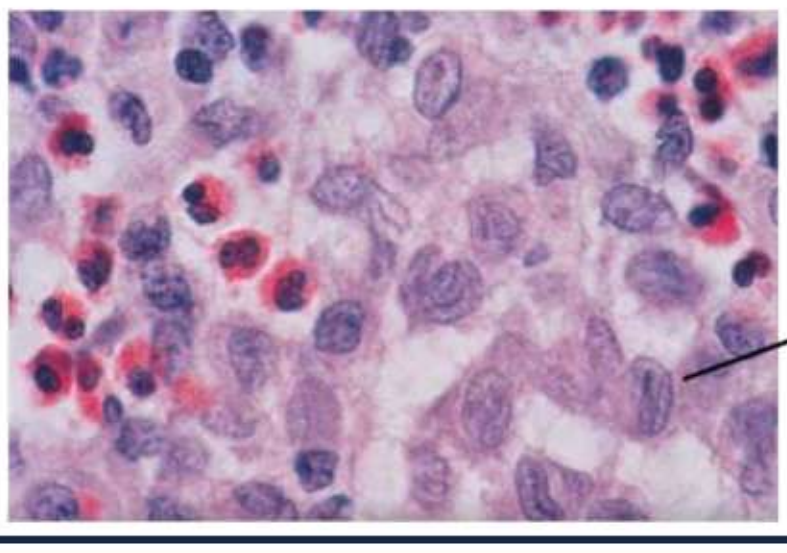

Fig: 2

AfraTafreeh.com

GIST

- Smoking Related Disease
- DIP
- Bronchiolitis associated Interstitial Disease
- Pulmonary LCH

Summary of Pulmonary Alveolar Proteinosis

- Pulmonary Alveolar Proteinosis in adults occur due to Antibodies against GM-CSF- Surfactant not cleared
- Neonatal Alveolar Proteinosis – ABCA3 Mutations

↓

Abnormality of Lamellar body

Onion Skinning of Lamellar Body

DOC TUTORIALS LOGIN FOR SUCCESS

Summary of Restrictive Lung Diseases

i. Pneumoconiosis

ii. Granulomatous RLD – Sarcoidosis, Hypersensitivity, Pneumonitis

iii. Fibrosing RLD – IPF
   - NSIF
   - BOOP

iv. Smoking associated RLD – DLD

-Bronchiolitis associated IP

-Pulmonary LCH

v. Others – Pulmonary Alveolar proteinosis.

PNEUMONIA WITH SPECIAL TYPES OF PNEUMONIAS, ASPIRATION PNEUMONIA, GOLDEN PNEUMONIA

- Inflammation / infection of lung Parenchyma
- Classification of Pneumonia

I. Based on pattern of involvement
   a. Lobar Pneumonia
   b. Broncho Pneumonia

II. Based on Clinical Presentation
   a. Typical Pneumonia
   b. Atypical Pneumonia

III. Based on cause
   a. Bacterial Pneumonia
   b. Viral
   c. Fungal
   d. Pneumocystis
   e. Aspiration Pneumonia

AfraTafreeh.com
TUTORIALS
LOGIN FOR SUCCESS

Typical	Atypical
Signs & Symptoms – more severe	mild/Absent
• Fever ↑ • TLC ↑↑ • CXR – areas of consolidation	Milder / Absent

AfraTafreeh.com

Pathology of Lung

Alveolar Pneumonia

B – Bacteria   Alv – wall

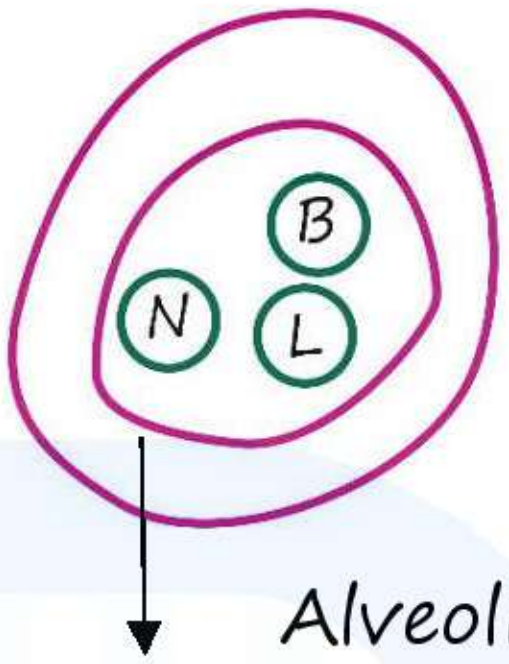

Alveoli

- Alveolar exudates (characteristic) (Inflammatory cells + Bacterial + Cytokines + Damaged epithelial cells)

  Because of exudative nature – good conduction of Cytokines

  Congestion w/o consolidation More C/F

  Congestion + Consolidation

(Because of alveolar exudates)

M/C/C = Strep – pneumonia

Interstitial Pneumonia

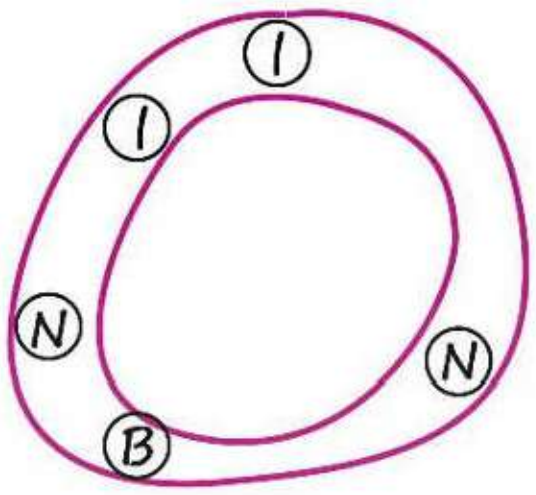

No alveolar exudates

Inflammation cell – alveolar wall / Interstitium

↓

Congestion + Consolidation

↓

M/C/C – Viral infections (group)

Mycoplasma (M/C/C)

Individually

Giant cells can be seen in atypical pneumonia

E.g. Measles – Hecht's Pneumonia

(Warthin – Fenkil dey Giant cells

Typical pneumonia (Streptococcus pneumoniae)

Bronchopneumonia

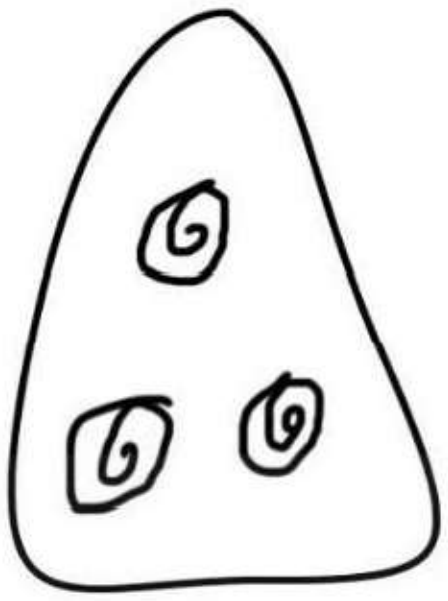

- Partly consolidation (because they follow Bronchi)
- When immunity is good
- Usually Bilateral & Basal
- Cause – Staphylococcus aureus
- Extremes of age

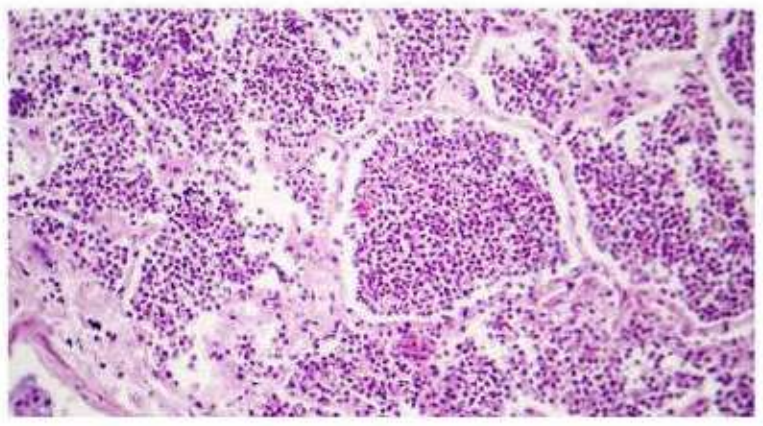

Lobar

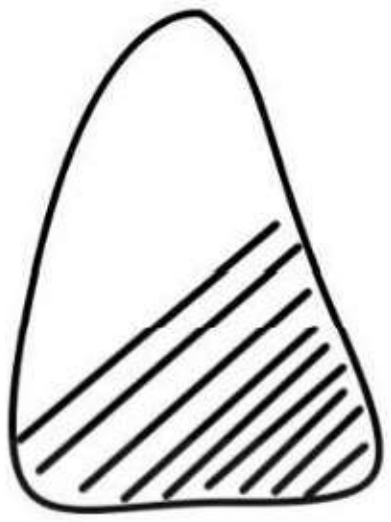

- Lobar pneumonia (lobes affected)
- when immunity is poor
- 4 stage of development

I. Stage of Congestion BC + Bacteria

II. Red Hepatisation

Because Hemorrhagic areas

RBC + WBC + Bacteria

AfraTafreeh.com
DOC TUTORIALS
LOGIN FOR SUCCESS

AfraTafreeh.com

	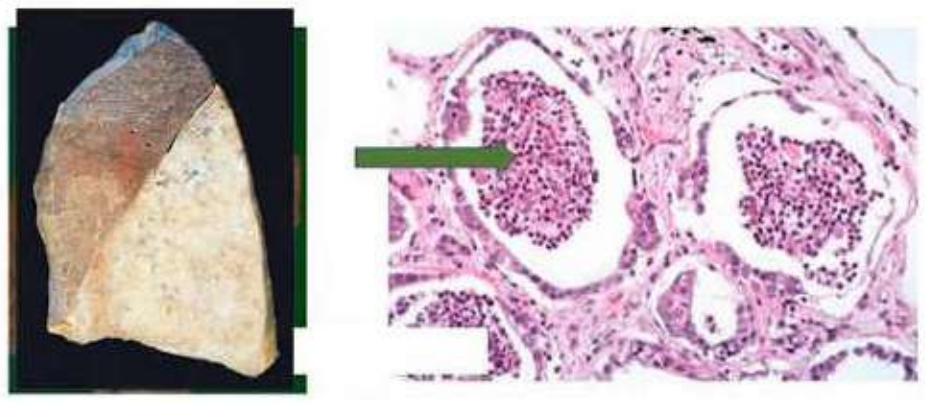 III. Grey hepatization Because of Fibrinous exudates IV. Resolution M/C Outcome

Histology

1. Typical Pneumonia – Due to Streptococcus pneumonia > H influenzas
2. Atypical Pneumonia – Due to Mycoplasma > Chlamydia
3. Nosocomial Pneumonia – due to Gram –ve rods e.g., Enterobacteriase (E coli and Klebsiella)
4. Aspiration Pneumonia – Due to Anaerobic infections
5. Pneumonia with underlying Chronic Alcoholism and COPD is due to Klebsiella pneumoniae
6. With underlying Bronchiectasis and Cystic fibrosis is due to Pseudomonas aeruginosa
7. Ventilator associated pneumonia is due to Pseudomonas aeruginosa

8. M/C/C of Bronchopneumonia – Staphylococcus aurous

Aspiration Pneumonia

- Aspiration in Elderly, debilitated
- Superadded infection by anaerobic micro-organisms

Three Histological features

Foreign body Aspiration	Giant cells in alveoli	Meconium aspiration

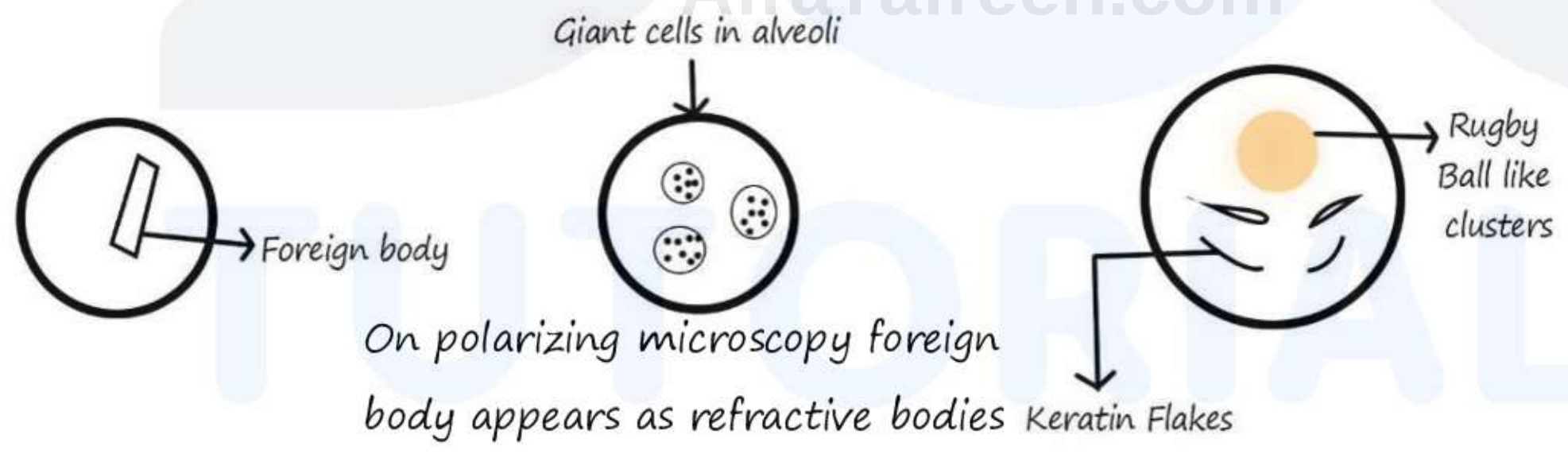

AfraTafreeh.com
TUTORIALS
LOGIN FOR SUCCESS

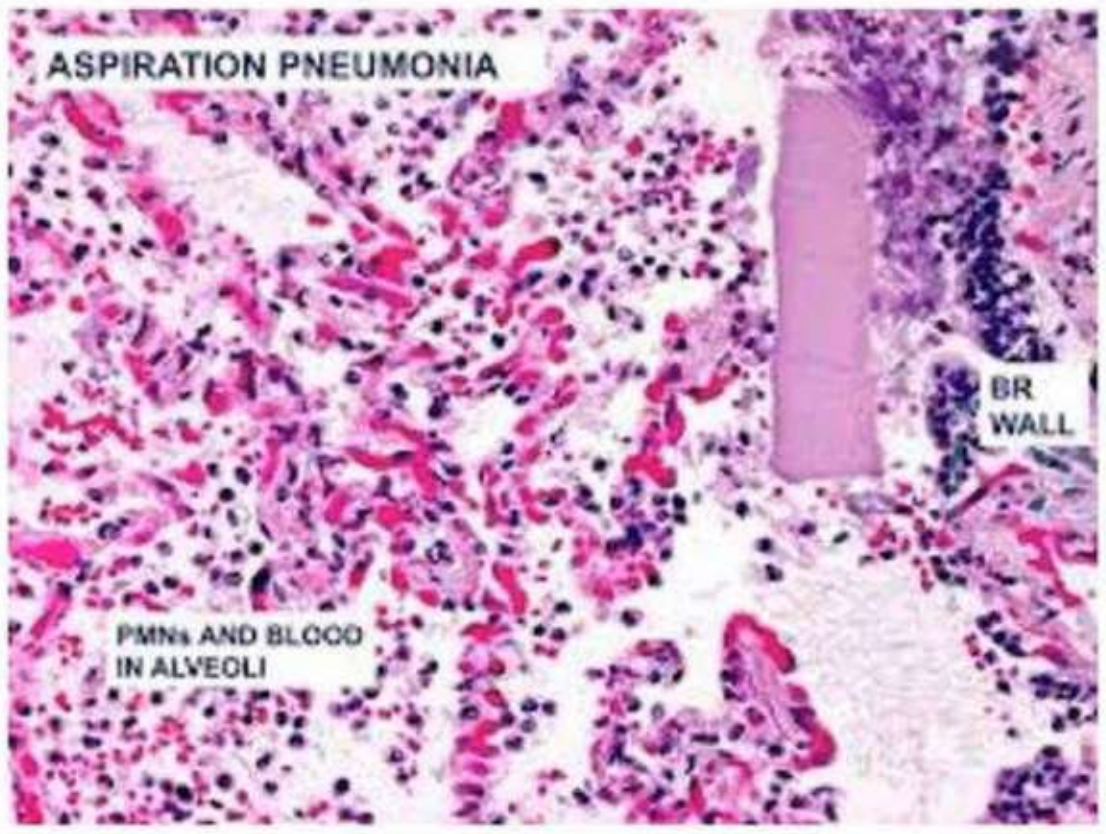

Fig: 1

AfraTafreeh.com

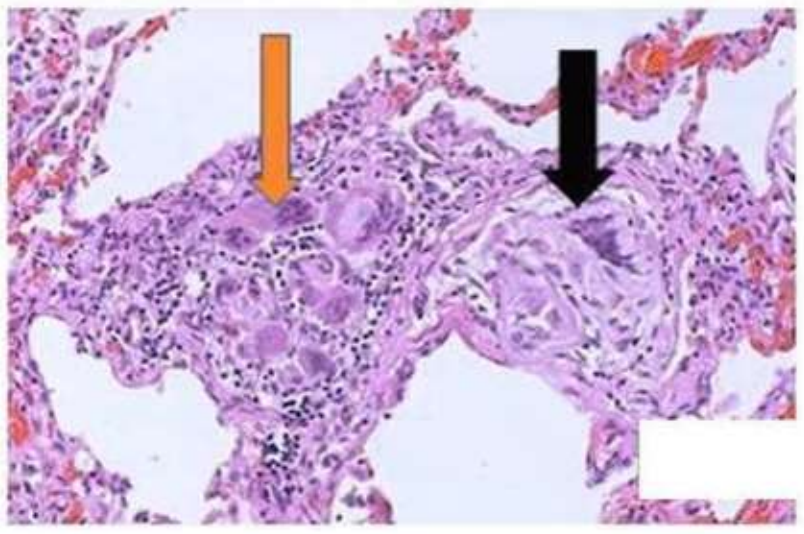

Haphazard arrangement of nuclei

Foreign body type Giant cell

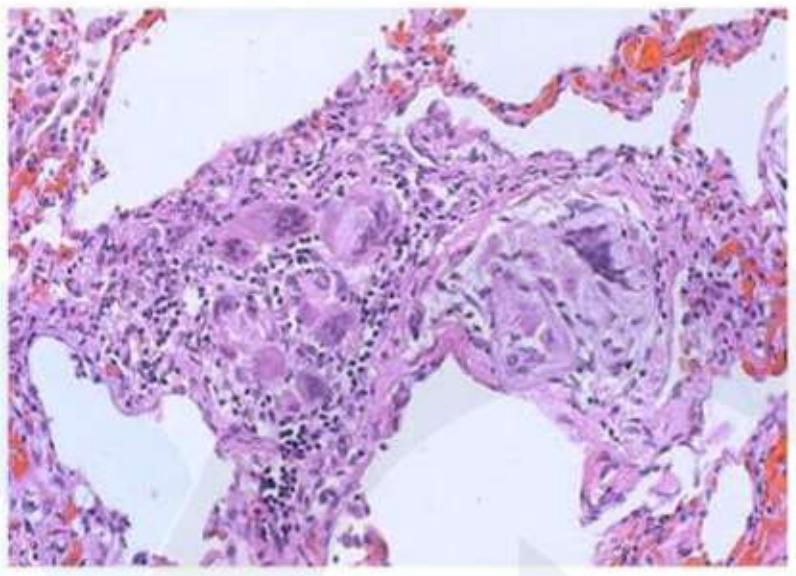

Fig: 2

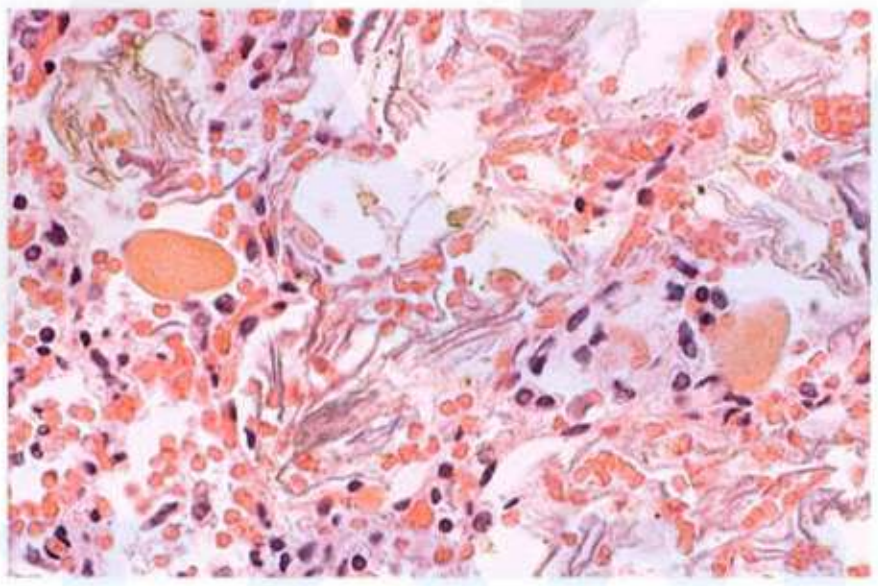

Fig: 3

Golden Pneumonia

- Also known as Lipoid Pneumonia / Cholesterol Pneumonia

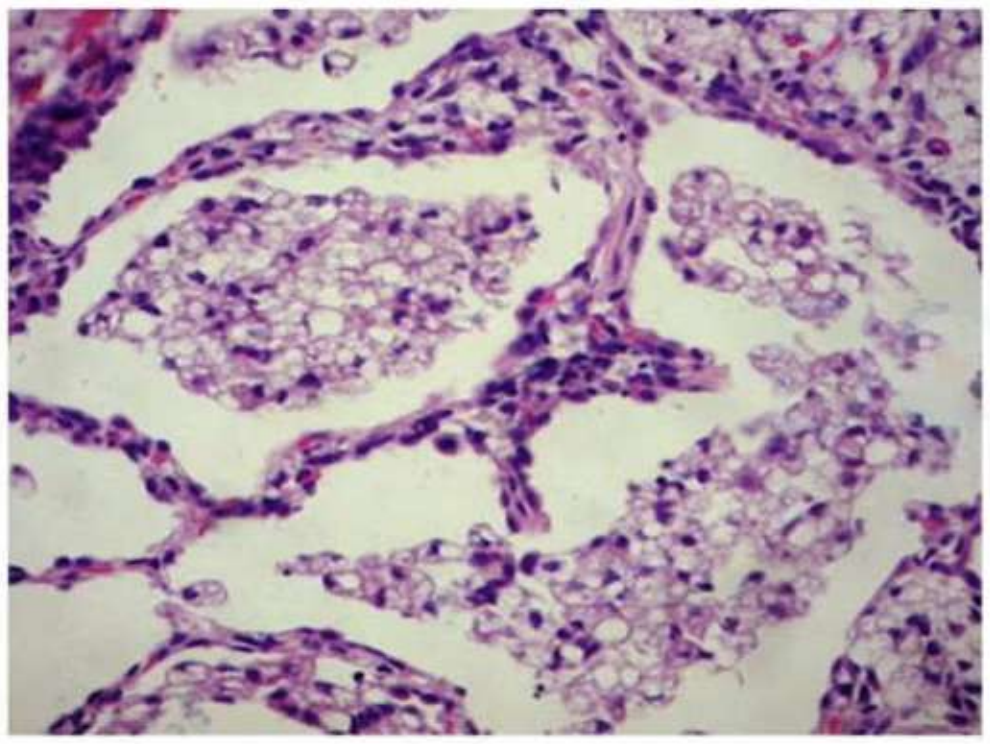

Fig: 4

Causes

Extrinsic	Intrinsic
Aspiration of Oil • Macrophages take up the oil and appear foamy	Due to Obstruction of Bronchus by Tumor or Foreign body ↓ Degeneration of Type II pneumocystis Phagocytosed by macrophages ↓ Foamy appearing macrophages

- Gross: - Yellowish appearance Thus named Golden pneumonia

CMV Pneumonia

- Cytomegalovirus infection Characterized by enlargement of infected cell & prominent intra-nuclear inclusion (Owl's eye appearance)
- Infects the immunocompromised and once infected, individual carry CMV for whole life.
- Leads to Interstitial pneumonia
- Microscopy

AfraTafreeh.com

Fig: 5

Fungal Pneumonia

- Aspergillus
- Mucor
- Pneumocystis

TUTORIALS
LOGIN FOR SUCCESS

ASPERGILLUS

Aspergillus

Aspergilloma	Invasive Aspergillosis	Allergic **Bronchopulmonary** Aspergillosis (ABPA)
↓ Fungal ball in pre existing Cavities of TB, sarcoidosis	↓ - Lung invasion confined almost entirely to immunosuppressed – patients - Characterized by Hyphal invasion of Blood vessel thrombosis	↓ - Hypersensitivity Reaction - Predisposed are patients with asthma cystic Fibrosis - Present with wheeze central Bronchioles

DOC TUTORIALS
LOGIN FOR SUCCESS

Microscopy

- Aspergillus appears as septate fungi with acute angle bricking i. e Dichotomous branching

AfraTafreeh.com

- Thin septal
- Stain to visualize – PAS stain

  Silver stain

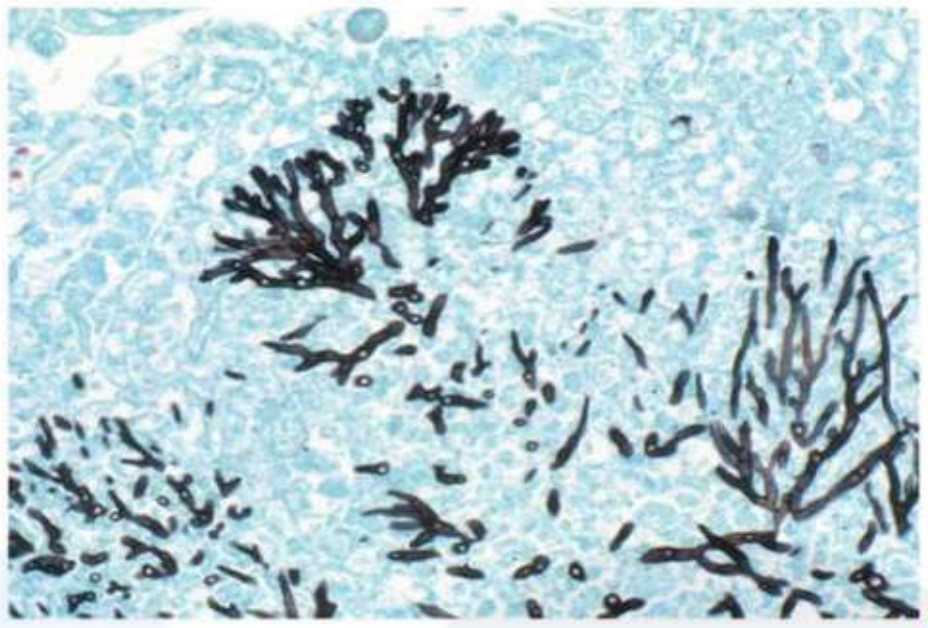

Fig: 1

- Fruiting Body of aspergillus (sexual conidia arranged in chains)

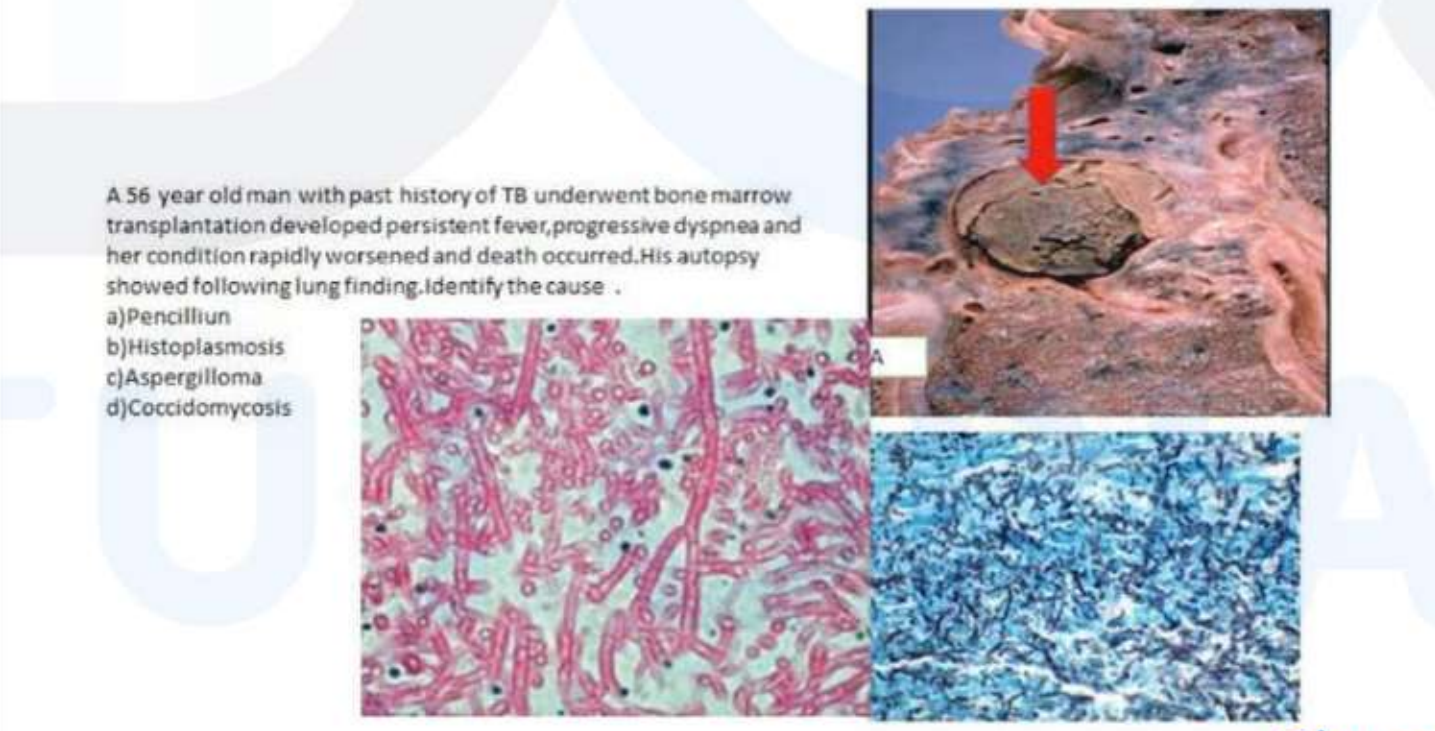

Fig: 2

- Aspergillus fumigates in M / C of aspergillus
- Commonest human disease caused by aspergillus is ostimycosis

II. MUCOR

- Pulmonary Mucormycosis manifests as progressive fever pneumonia
- Microscopy

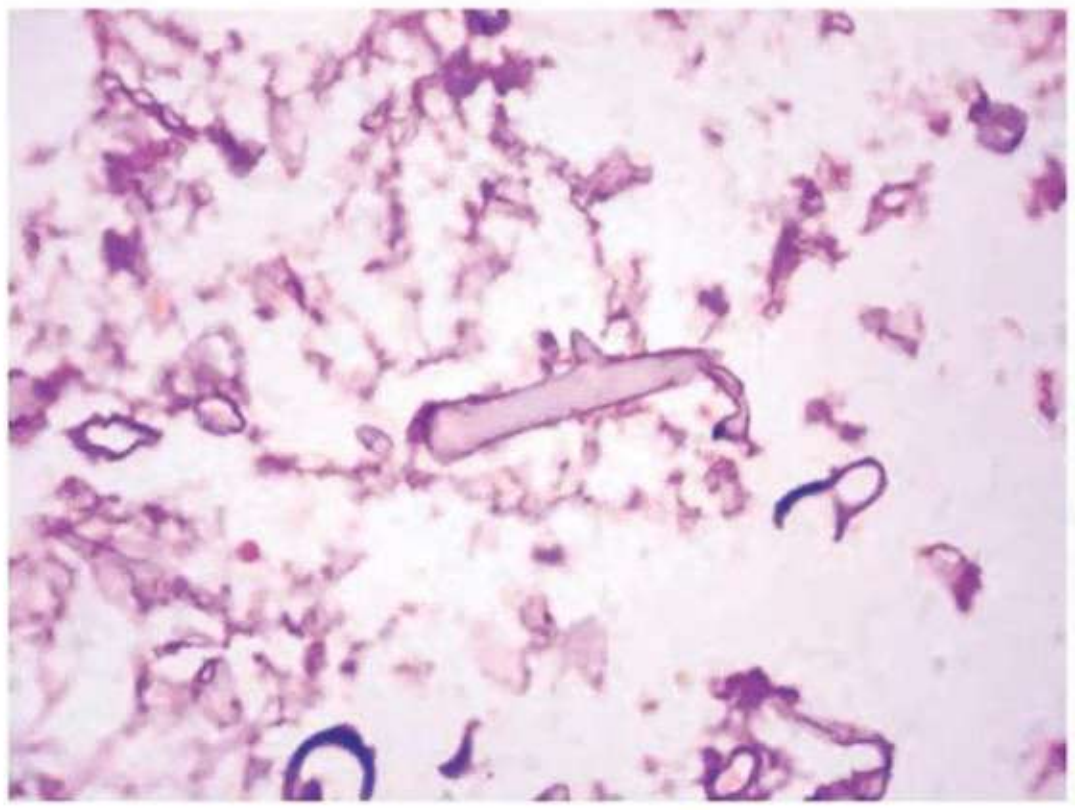

Fig: 3

Broad Ribbon – like

Non – septate Hyphae with Branching at right angles

Pneumocystis Pneumonia

- Pneumocystis Jiroveci – Opportunists fungal pulmonary pathogen
- Preface Interstitial pneumonia
- CXR – Bilateral diffuse Peri – hilar infiltrates

AfraTafreeh.com

TUTORIALS

LOGIN FOR SUCCESS

Pathogenesis

- Attacks to type I Cells extra cellular and damages it
- Hypertrophy of type II cells ocean causing surfactant abnormal ties
- Alveus filled with Typical foamy vacuolated exudate

AfraTafreeh.com

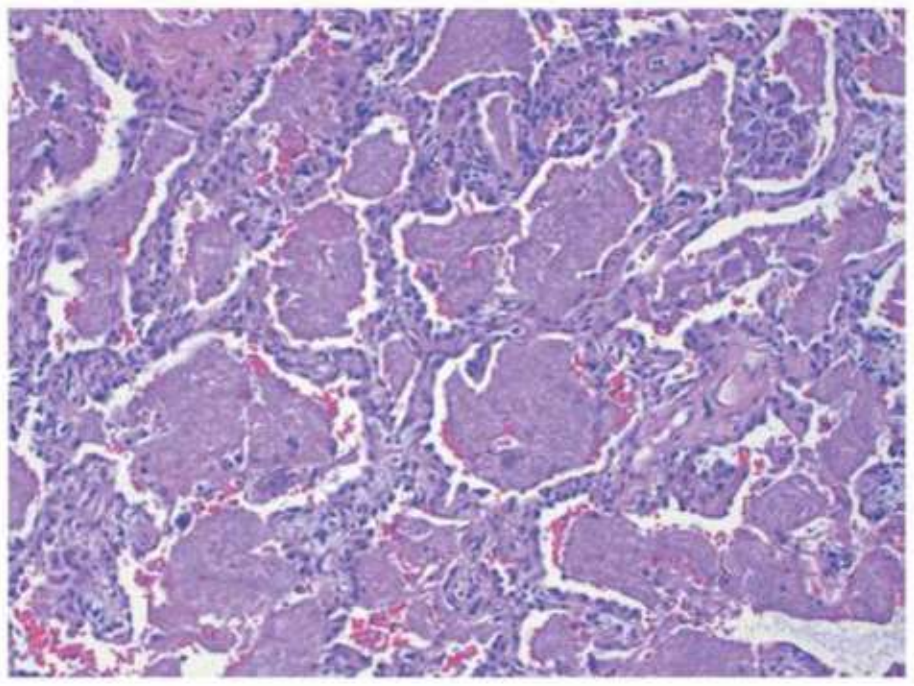

Fig: 4

On silver stain

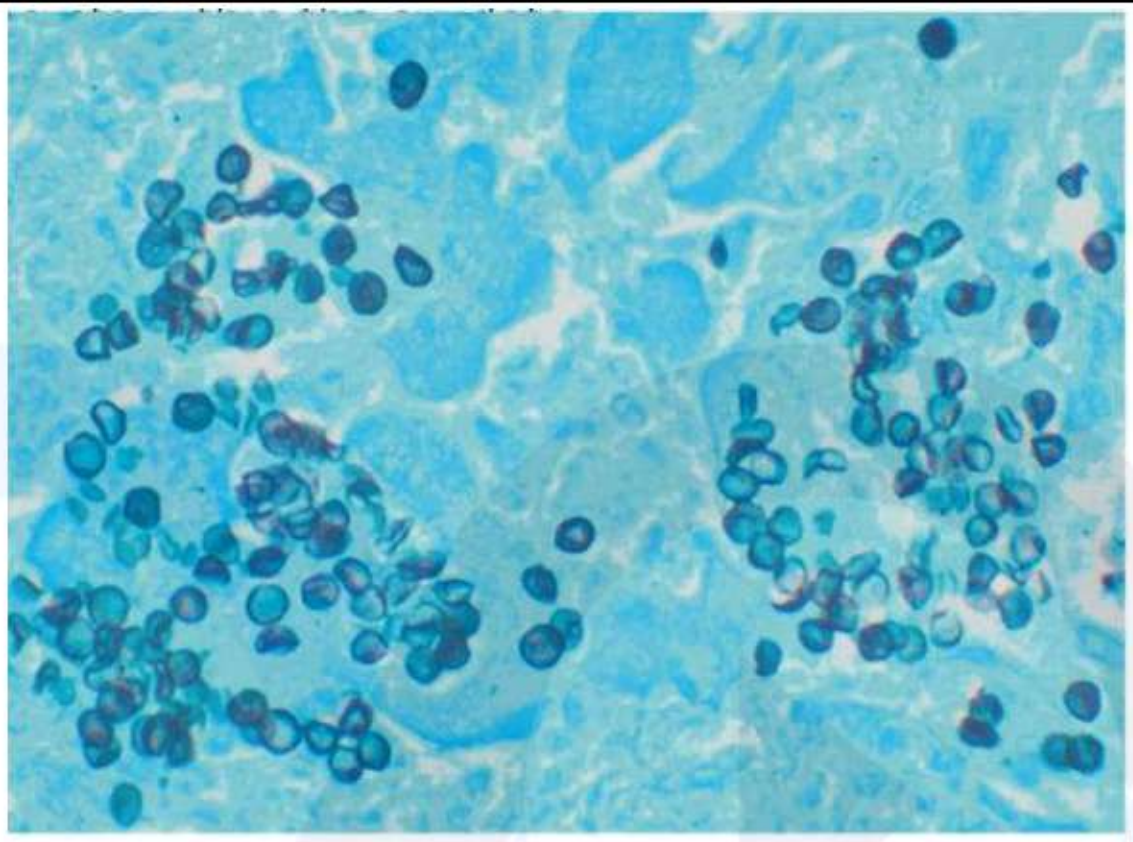

Fig: 5

Ping – pang ball appearance / cup & saucer arrangement

TUTORIALS
LOGIN FOR SUCCESS

BENIGN LUNG TUMORS

- Hamartoma – most common benign tumor of lung
- Carcinoid
- Pecoma
- Inflammatory myofibroblastic tumor (IMT)

Pulmonary hamartoma 00:00:53

- Manifested by over growth of cartilage
- Features of hamartoma i. haphazard arrangement of tissue
  ii. indigenous to the organ
- Associated with chromosome 6 & 12 abnormally
- Benign tumor
- CXR – coin lesion / popcorn calcification
- Typically seen in 40-60 years of age more common in males
- Usually peripheral grow slowly in lungs

AfraTafreeh.com
TUTORIALS
LOGIN FOR SUCCESS

Histology

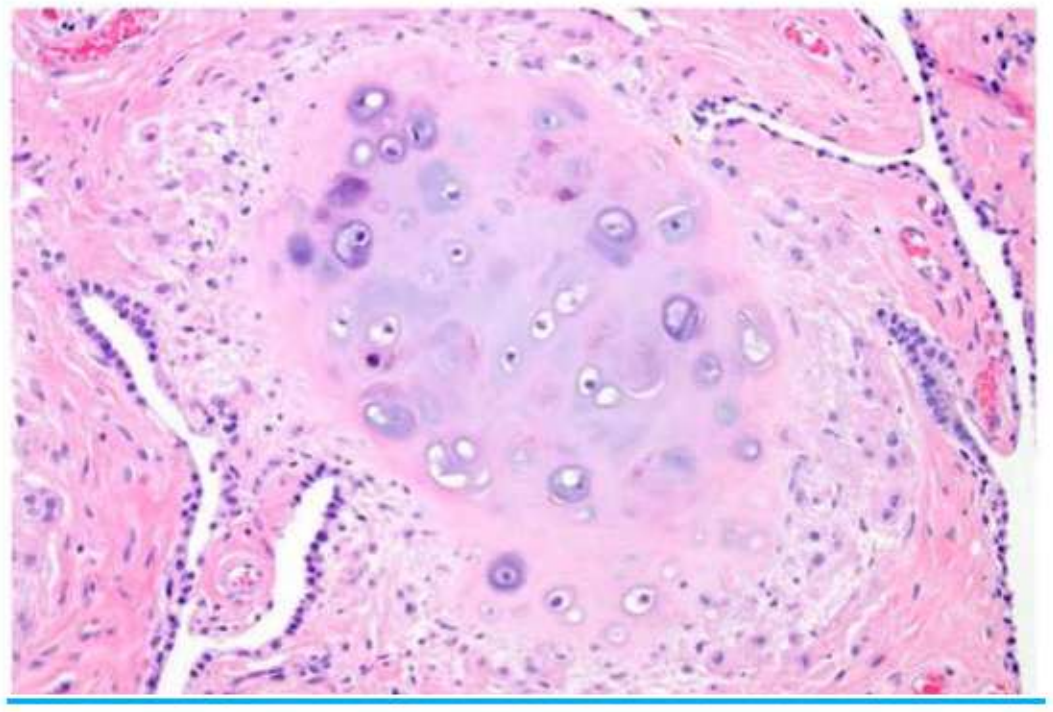

Fig: 1

AfraTafreeh.com

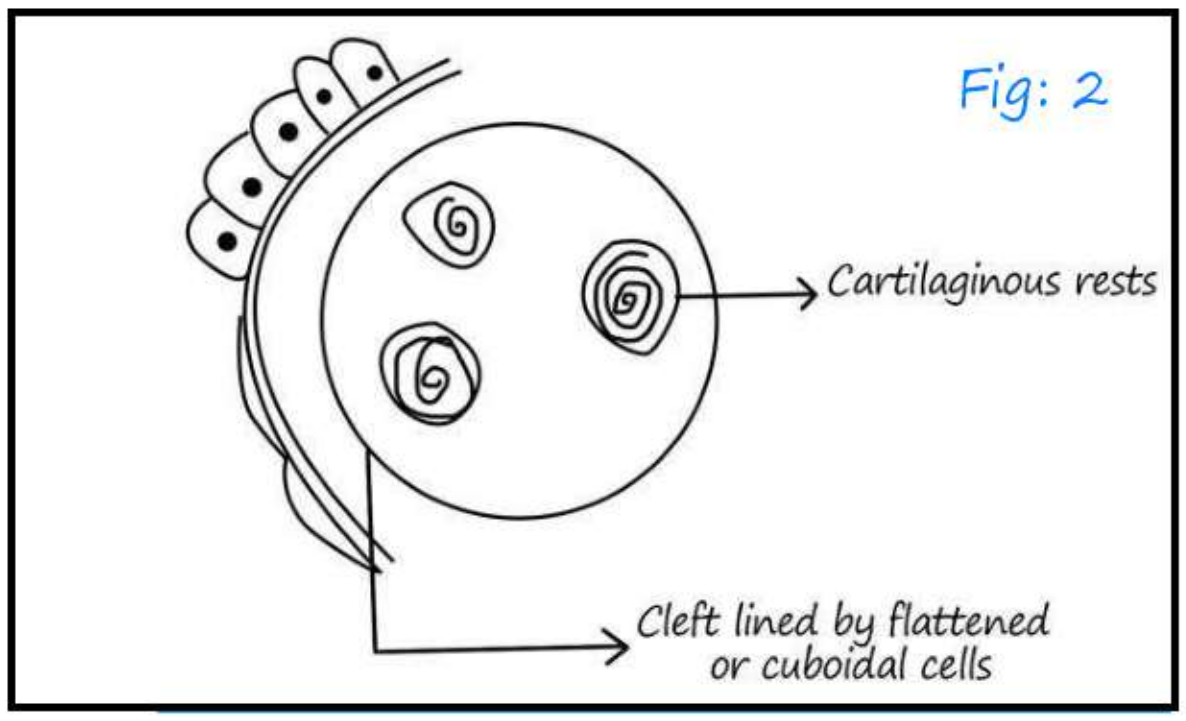

Bronchial carcinoid

- Bronchial carcinoid (left malignant) are the most indolent of the spectrum of pulmonary neuro – endocrine tumor
- Male & female equally involved most patients are <40yrs not related to smoking
- Lower respiratory tract (bronchus > tranche) are the M/C site of carried tumor

Gross

- Growly tumors are mostly Interbronchial, highly vascular, polyploidy mass less than 3-4 cm
- Impart a coat button appearance with intact overlying mucosa

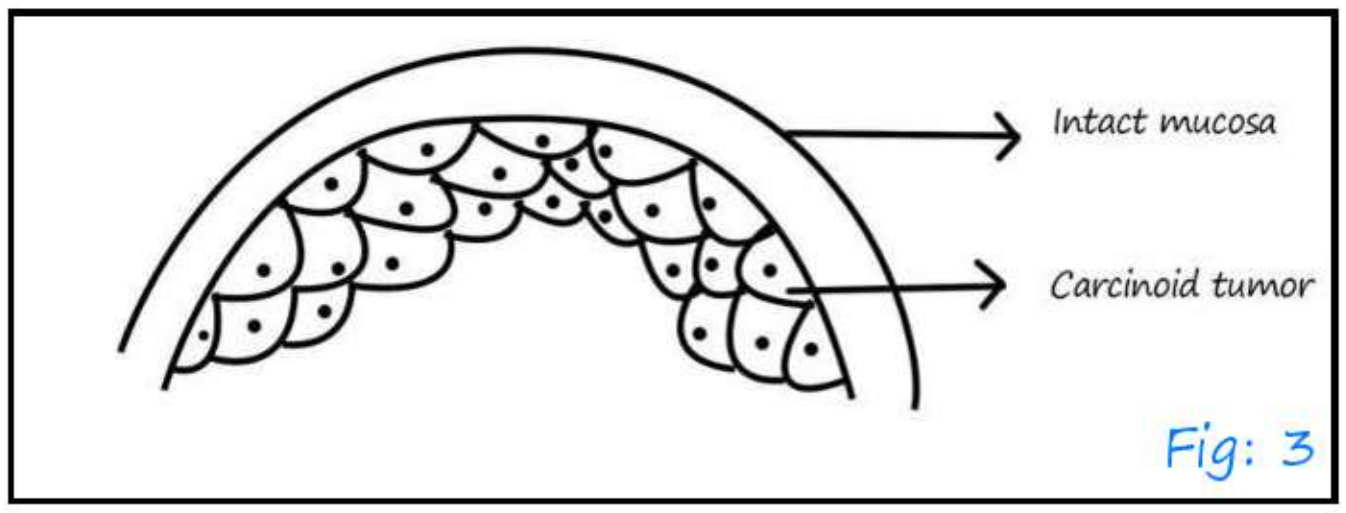

Coat button when seen from the mucoid surface

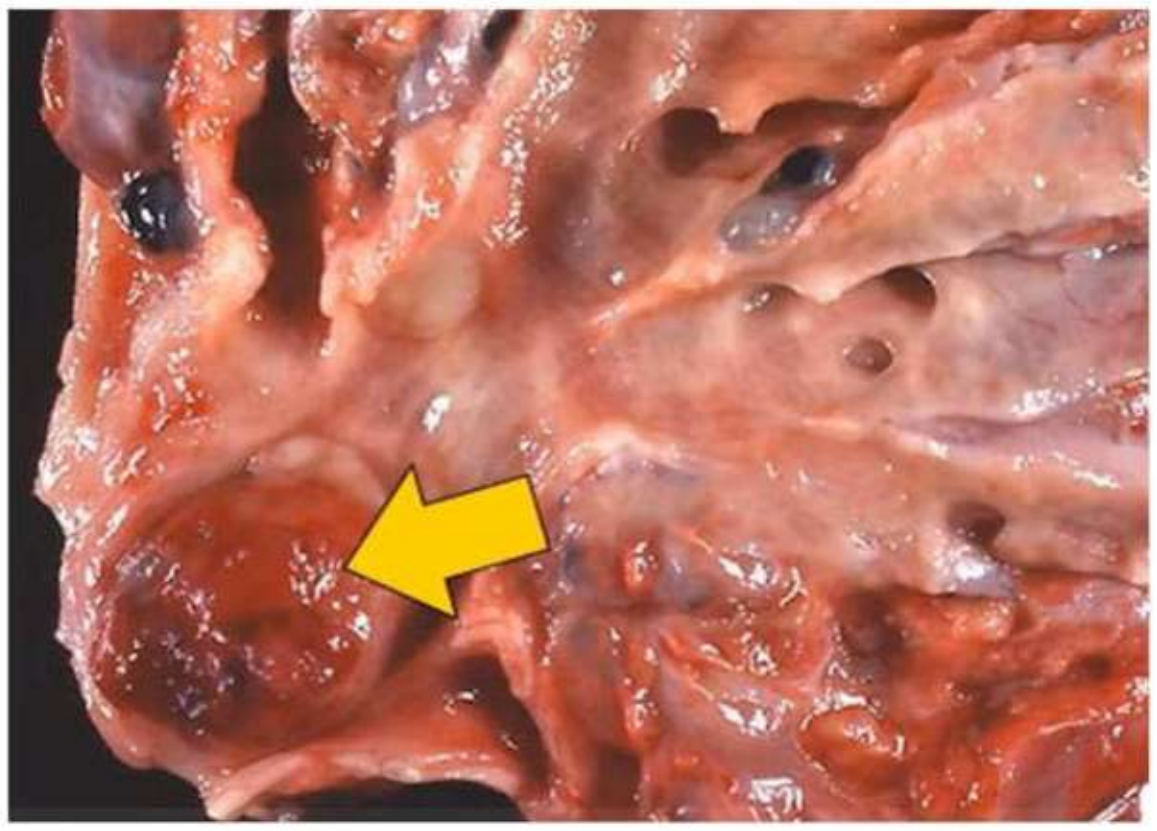

Fig: 4

Microscopy

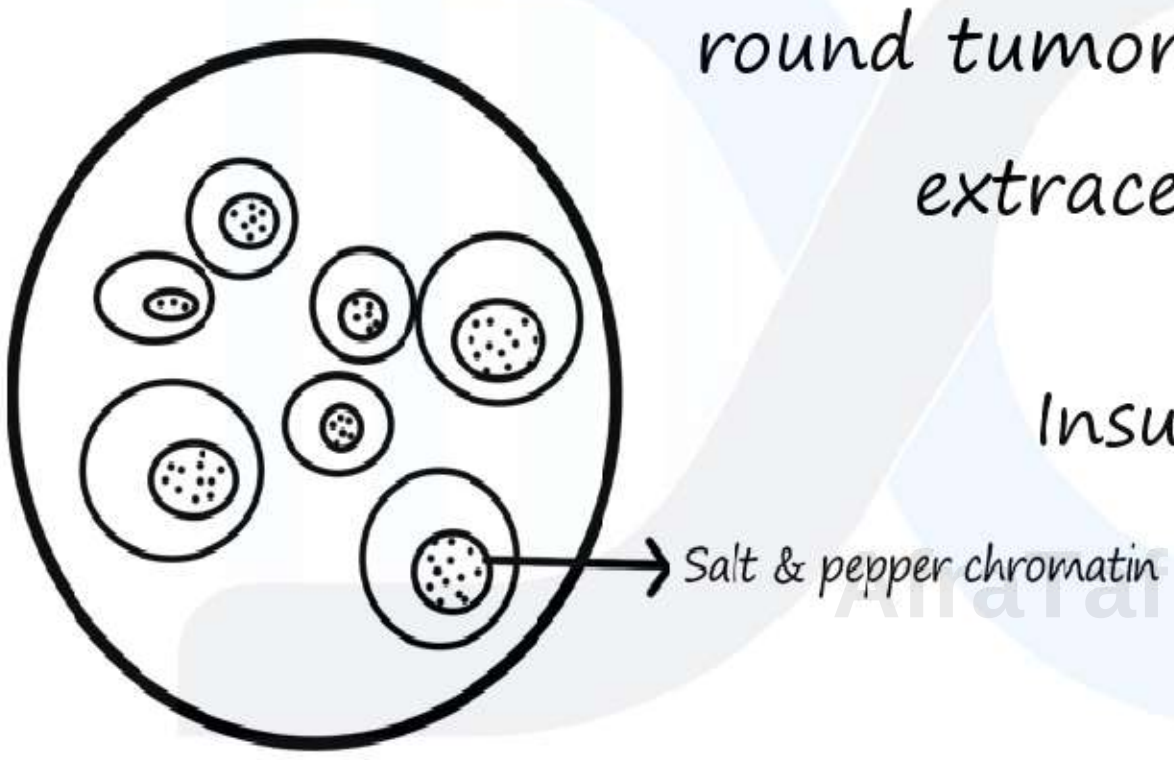

Well defined islands of uniform small round tumor cells separated by extracellular matrix

↓

Insular palter

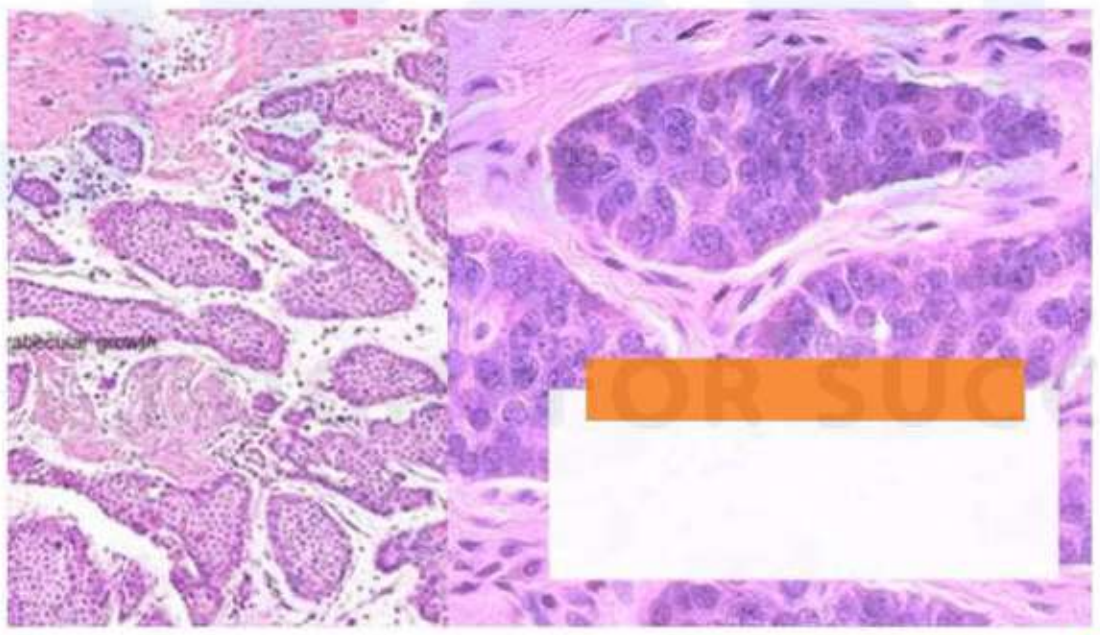

Fig: 5

Typical carcinoid

- Benign
- Mitotic activity < 2 per 10 high power fields
- Do not have necrosis

AfraTafreeh.com

Atypical carcinoid

- Intermediate
- MA- 2-10 per 10 hpf
- Necrosis present

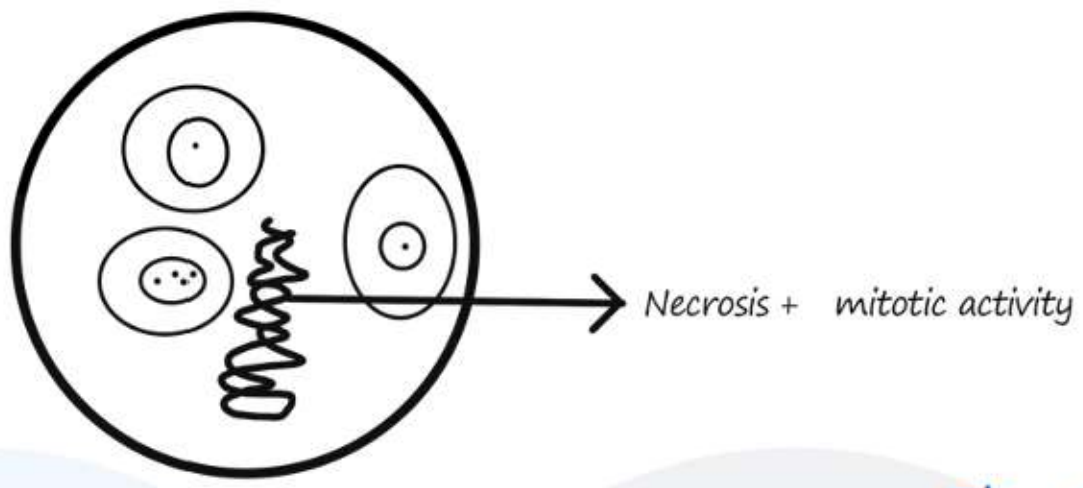

Fig: 6

- Highly pleomorphic
- Propensity for lymphatic invasion

Clinical features:

- functioning lesions capable of producing the classic carcinoid syndrome are characterized by intermittent attacks of diarrhea flushing and cyanosis
- Diarrhea, flushing and cyanosis
- Carcinoid syndrome is a/w 10% bronchial carcinoid only
- Most bronchial carcinoids
- Do not have secretory activity
- Do not metastatize to distant area
- Fallow a relatively benign course

Note-

- Ectopic ACTH production is most commonly associated with lung carcinoid
- M/C site of carcinoid -> GIT (NE cells most in GIT)
  In GIT M/C site appendix > ileum
  If options: lung > appendix > ileum
  GIT > RT
- Lung – M/C individual organ as site of carcinoid
- GIT- M/C system involved in carcinoid

Pecoma

- Tumor arising from Peri-vascular epithelioid cells
- Very rare tumors
- Usually occur in young females with tuberous sclerosis as lymphangio – leiomyomatosis
- In others without tuberous sclerosis – it occurs in presence of lots of glycogen

↓ On formalin

Glycogen washes off and tumor cells very clear

(Similar in appearance to clear cell carcinoma of kidney)

Diagnosis

- Pecomas express melanocytic markers and smooth muscle markers
- Positive for HMB – 45

AfraTafreeh.com

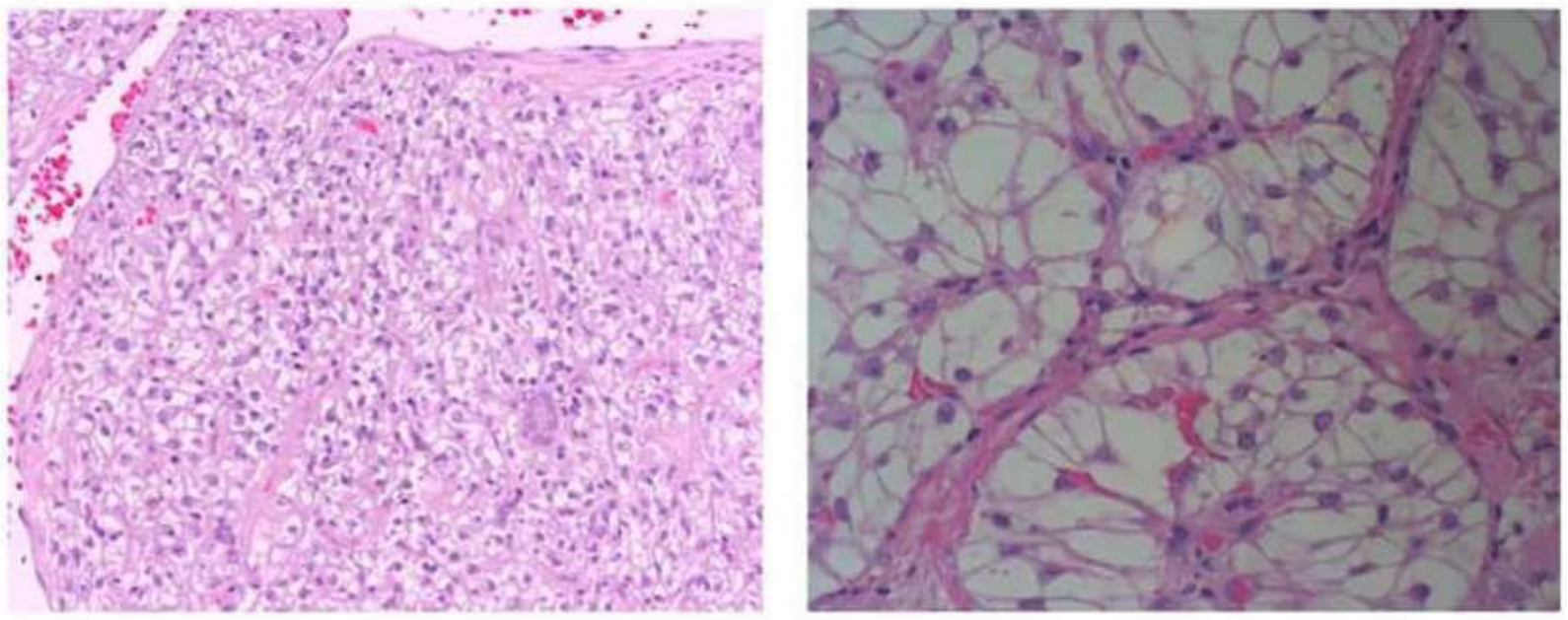

Sugar Tumor of Lung Fig: 7

- Clear appearing cells

Inflammatory myofibroblastic tumor (IMT)

00:12:21

- Associated with ALK mutation on chromosome 2

Note:-

- M/C lung tumor is metastasis
- In children – primary is most commonly Osteosarcoma > Wilm's
- In adults – primary is most commonly breast cancer
- M/C benign tumor of pediatric lung -> inflammatory myofibroblastic tumor
  In adults -> pulmonary hamartoma

M/C malignant tumor of pediatric lung – bronchial carcinoid

In adults India – SCC

M/C in women & non – smokers – adenocarcinoma

- M/C site of metastasis from lung cancer -> brain

Most specific site -> adrenals

AfraTafreeh.com
TUTORIALS
LOGIN FOR SUCCESS

AfraTafreeh.com

LUNG TUMOUR

Malignant Lung Tumors

- Epithelial Tumors
  - SCC
  - Adenocarcinoma
- Neuroendocrine Tumors
  - Benign carcinoid tumors
  - Malignant
    - Small cell Ca
    - Large cell Ca

I. Precursors

- Metaplasia – Dysplasia – SCC
- Atypical Adenomatous Hyperplasia Adenocarcinoma In situ Adenocarcinoma

II. SCC show Desmosomes

Adenocarcinoma shows short and stout villi

III. IHC SCC – positive for p63

- Adenocarcinoma – TTF 1 (Thyroid transcription factor 1)
- Napsin
- CK 7

I. No Precursor Lesions

- Suspected Precursor Tumor let defined as

i. Hyperplasia of NE cell

ii. Size is smaller than 5mm

iii. Lock of Mitotic activity & necrosis

- It is NET of lung arising from Type 2 pneumocystis in response to chronic inflammation and scarring

II. 2 Features of all NET

Salt & pepper chromatin (L / M)

Neurosecretory Granules (Cytoplasm)

On E / M = Dense and Dark colour

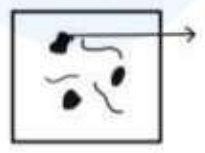

Dense care granules (Stores Neuroendocrine hormones)

- Chromogranin
- Synaptophysin
- Leucine – 7

III. Maximum Paraneoplastic Manifestation especially with small cell carcinoma

IV. Malignant NET have worse prognosis especially small cell carcinoma

V. On IHC NET are positive for

i. Synaptophyim

ii. Chromogranin

iii. Neuron specific Enolase (NSE)- Sensitive marker

iv. CD56

v. CD57 (Preferred over CD56

Malignant Neuro – endocrine Tumor 00:10:29

Small cell carcinoma

- Criteria for small cell size of tumor less than that of 3 small lymphocytes clumped together

  Tumor Cell

  Lymphocytes
- Most Malignant most aggressive, central in distribution
- Tumor cells are small with little cytoplasm called "Oat cell"

Large Cell Carcinoma

- Highly undifferentiated with Cavitating nature
- Metastasize early with poor prognosis
- Associated with gynecomastia as paaraneoplastic manifestation

AfraTafreeh.com
TUTORIALS
LOGIN FOR SUCCESS

Genes

i. L – MYC mutation (Proto oncogenic mutation)

ii. L – MYC is a transcription factor – Mutation

iii. Results in very high proliferation of tumor causing Poor prognosis

iv. Loss of Rb gene

- M/C Tumor supposes gene deleted in small cell Ca

  → Rb gene

AfraTafreeh.com

Shows extensive Metastasis

- Not associated with any Precursor lesson
- Associated with Maximum Paraneoplastic syndrome is small cell Ca
- M / C PNS – S I A D H
- Other Cushing syndrome, lambert Eaton Myasthenic Syndrome
- Small cell carcinoma is most specifically associated with smoking
- Small blue round cells. Thereby small cell Tumor S R C T or Blue
- Individual Boundaries of tumor cell is lost and they get molded into are another

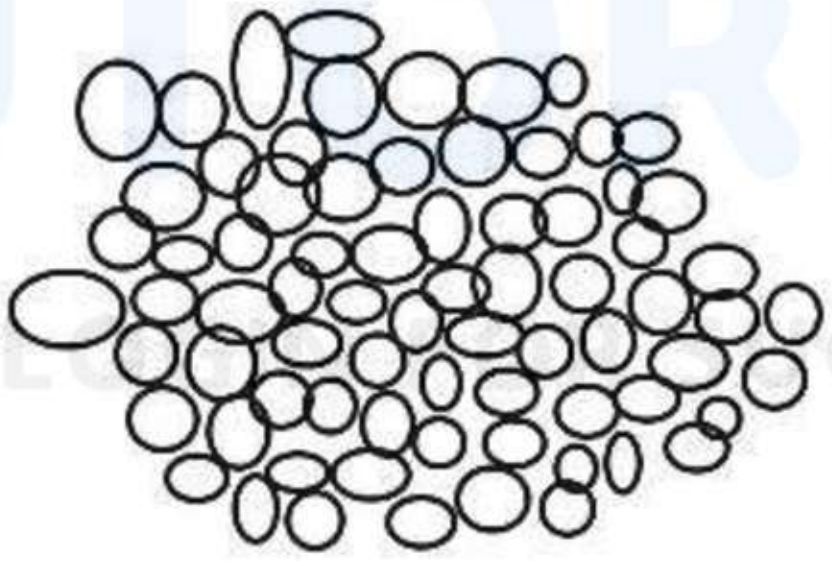

Moulding

Remember Moulding seen in

i. Small cell Carcinoma

ii. Inclusion of herpes simplex virus

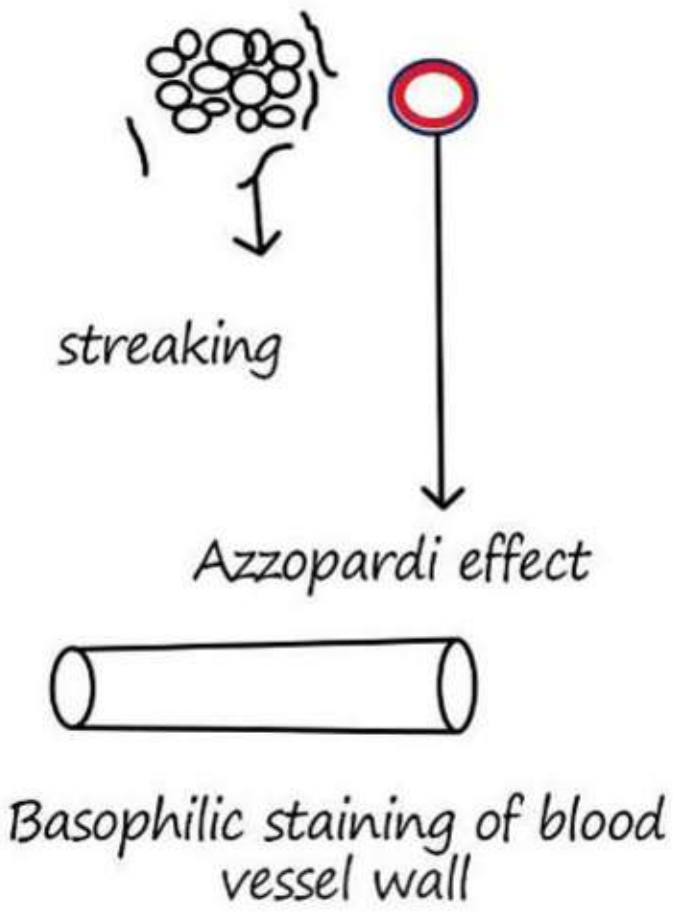

These tumor cells are very fragile Breakage of these cells creates a phenomenon called Streaking wherein DNA of the cells forms streaks around the tumor and around the Blood vessels. A Phenomena called Azzopardi effect

- On IHC – All NET show Synaptophysin,
  Chromogranin
  NSE (most sensitive)
  CD 56,57
  On E/M – Deme Core Granules

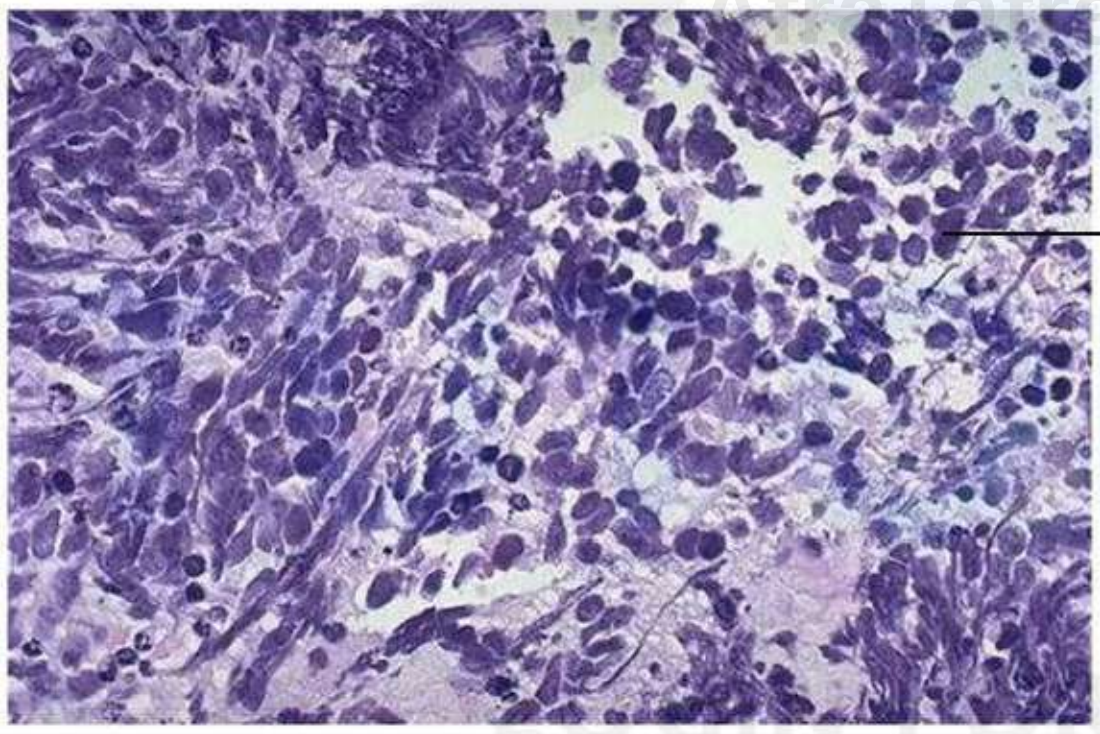

Small Round blue cells showing

Fig: 1

i. Moulding

ii. Streaking

iii. Azzopardi effect

iv. Lots of Necrosis

AfraTafreeh.com

Azzopardi effect

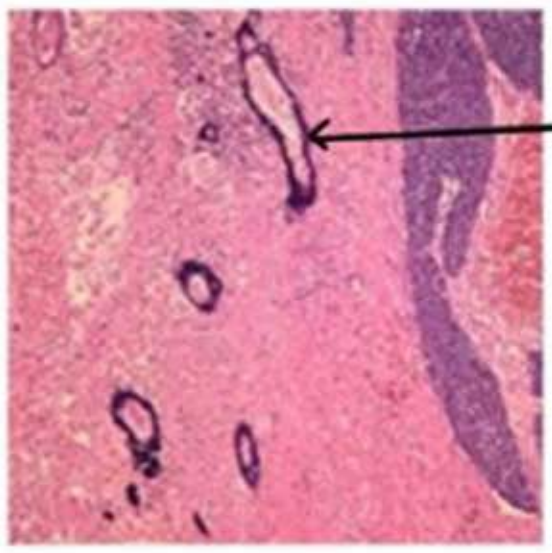

Fig: 2

Electron microscopy

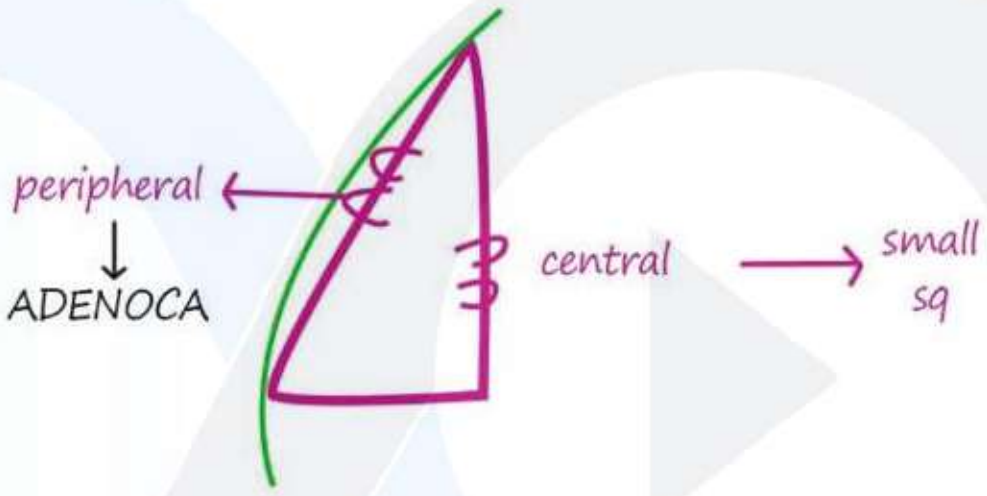

Deme core Granules

- M/C Lung Cancer Associated with SVC Syndrome – Small Cell of lung

Location of Lung Carcinomas

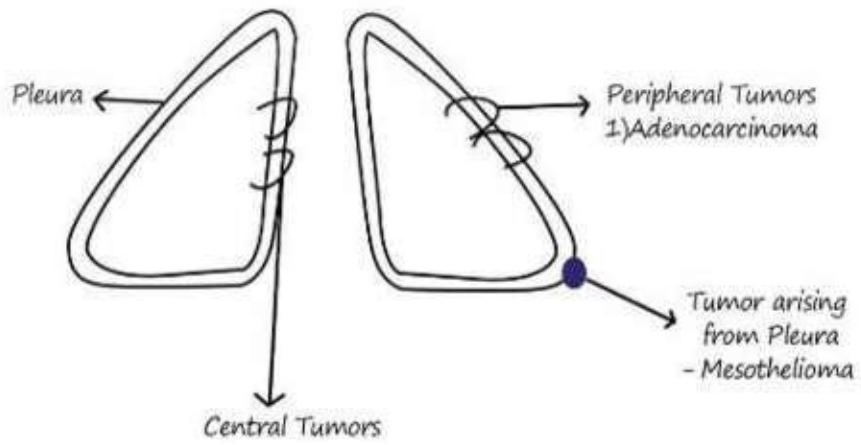

- Small Cell Carcinoma
- Squamous cell Carcinoma (SCC)

Epithelial Tumors

Squamous Cell Carcinoma 00:27:28

- M/C in Smokers
- M/c Type in India
- Central in distribution
- Pancoast Tumor is histologically SCC
- Prone to undergo central necrous and cavitation.
- Definitive Precurosor
- Columnar epithelium: Metaplasia → Squamous epithelium

  ↓ Dysplasia

  SC Carcinoma
- PNS = M / C Hyperkalemia (due to production of parathyroid Hormone – related protein PTH – rp)
- Remember – M / C Cancer to present with Hypercalcemia = Breast Cancer
- Associated with Best Prognosis

AfraTafreeh.com
TUTORIALS
LOGIN FOR SUCCESS

AfraTafreeh.com

Squamous cell carcinoma

Histology – 3 Grades

Keratinizing well Differentiated

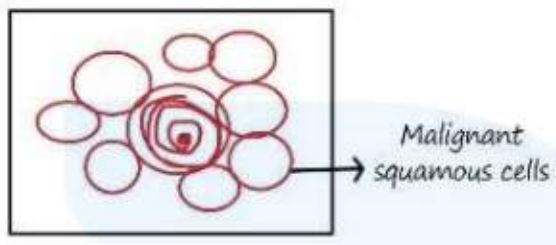

Keratin Pearl alkla Epithelial Pearl

Non-Keratinizing

No keratin Pearl

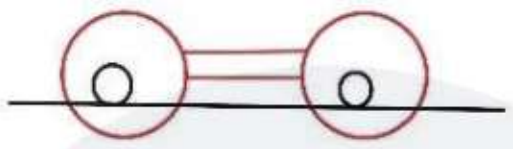

Intercellular Bridging (Desmosome)

DHC → p63, CK+, p41, p61

E/M → Desmosomes

Basaloid

SLC

Resemble Basal Cells

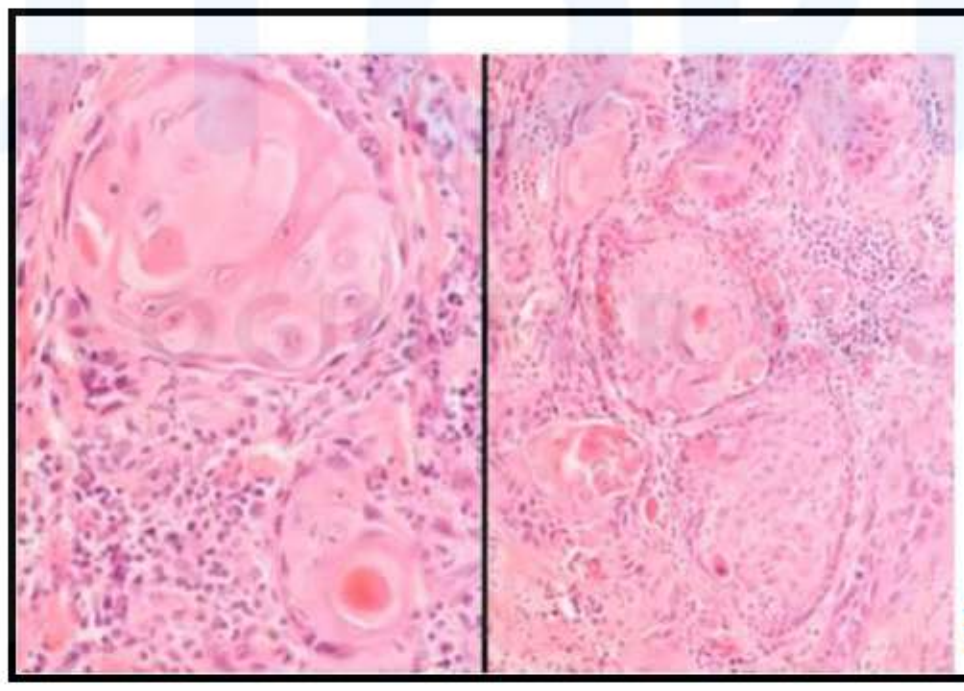

Fig: 3

Gross of SCC

Fig: 4

Adenocarcinoma Lung 00:37:37

- Located Peripherally
- M/C in Non – smokers, young patients, females.
- Mutations

  1.EGFR mutation seen in 30 %

  2.KRAS mutation in 20 % Cases

  3.AlK mutation in 4 %

Never Smokers	Non – smokers
All three mutations can be seen	- Only EGFR mutation - Never KRAS mutation

- Remember: EGFR and KRAS are normally mutually exclusive mutations
- Precursor: Atypical Adenomatous Hyperplasia

↓

Adenocarcinoma in Situ

↓

Adenocarcinoma

AfraTafreeh.com

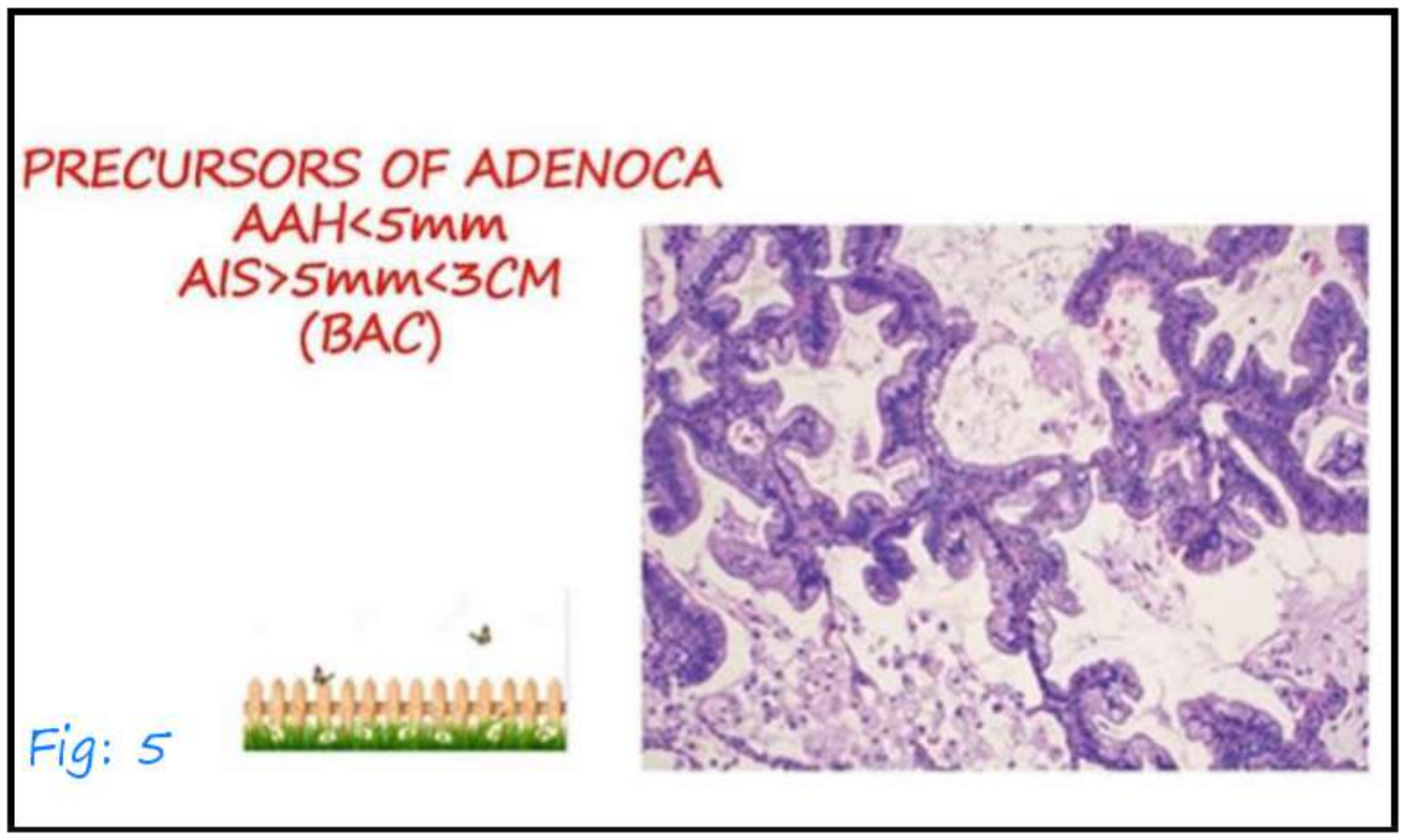

Fig: 5

Normal alveoli

Flattened squamoid cells

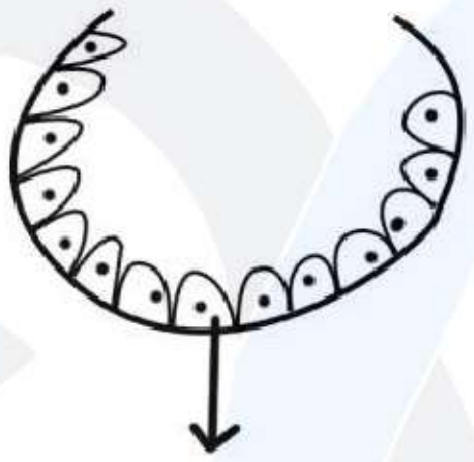

Columnar Cells

- If Columnar cells involvement < 5mm Atypical Adenomatous Hyperplasia
- If > 5mm but < 3cm Adenocarcinoma In Situ

- All these columnar cells appear as Butterfly sitting on fence – This pattern of involvement is called lepidic pattern Typically seen n Bronchi alveolar Ca (BAC) also known as Adenocarcinoma In Situ (AIS)
- Remember – Lepidic cells are stellate mesenchymal cells seen in Mycoma

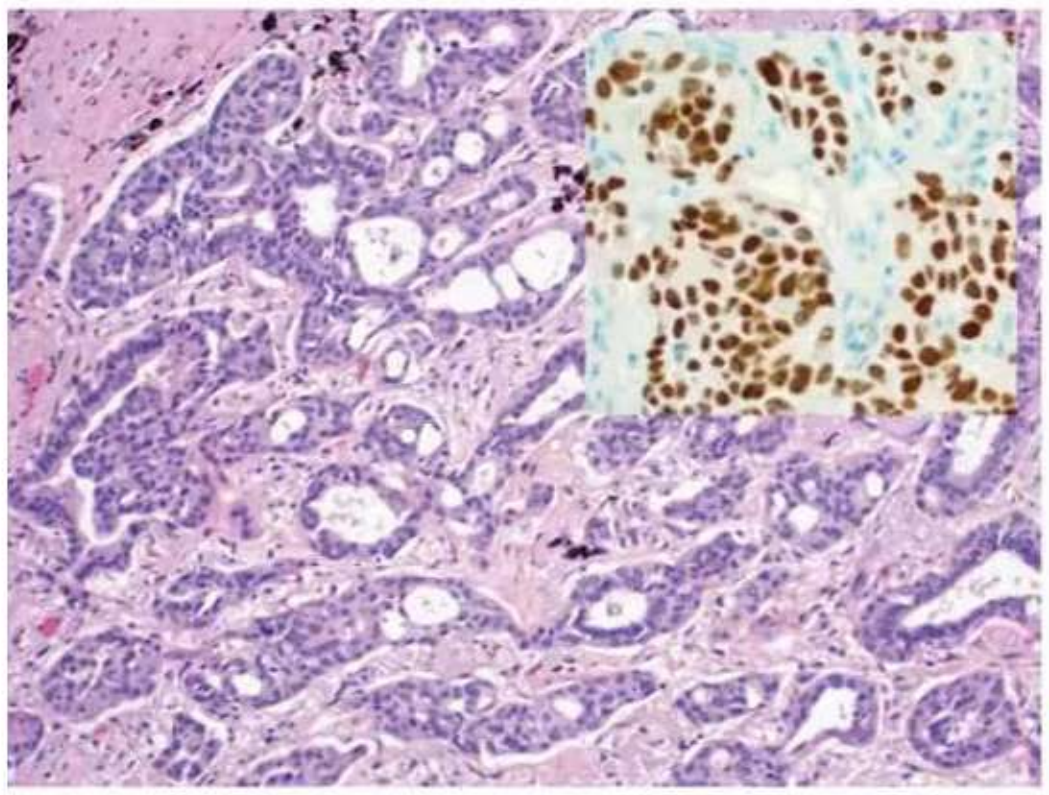
Fig: 6

- Adenocarcinoma – well designed Glands infiltrating into Stroma
- IHC
  1. TTF 1
  2. Napsin
  3. C K 7
- E/M:

AfraTafreeh.com

Short & stout Non- Branching alveoli

TUTORIALS
LOGIN FOR SUCCESS

- Spread: - Aeroginous Spread via Pores of Kohn or channels

AfraTafreeh.com

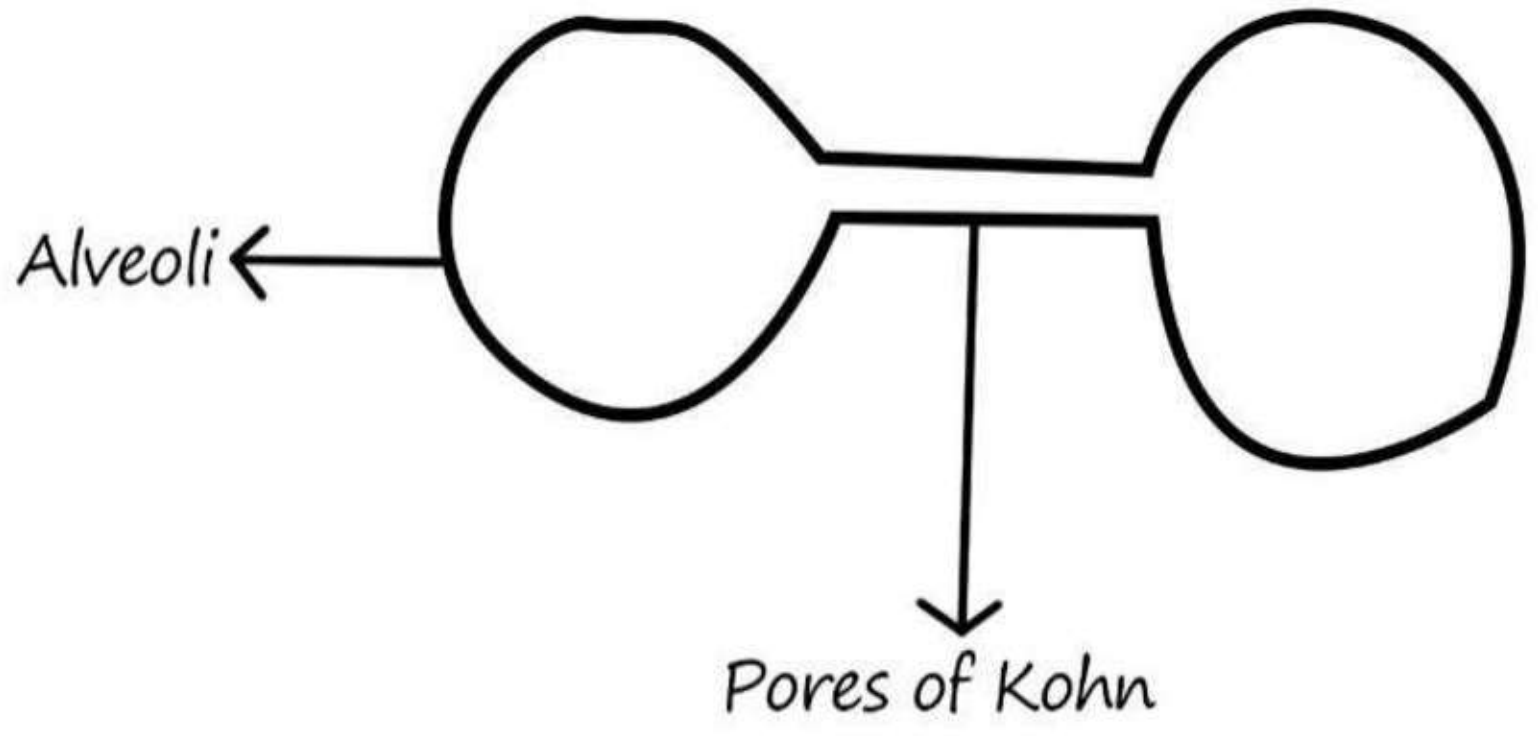

- Propensity to Metastasizes to apposite Lungs

Paraneoplastic Syndromes

- A/S or Broncho – alveolar Carcinoma present with Systemic sclerosis

Mesothelioma 00:51:12

- Peripherally located
- Arising from pleura
- Causes

1. Genes – BAP1 gene mutation
2. Asbestos exposure

Bronchogenic Ca (more common)
IP – 15-20 years
↓
Adenocarcinoma > SCC
↓
3. Virus SV-40 virus

Mesothelioma
(More specific) IP
– 20-40 years

TUTORIALS LOGIN FOR SUCCESS

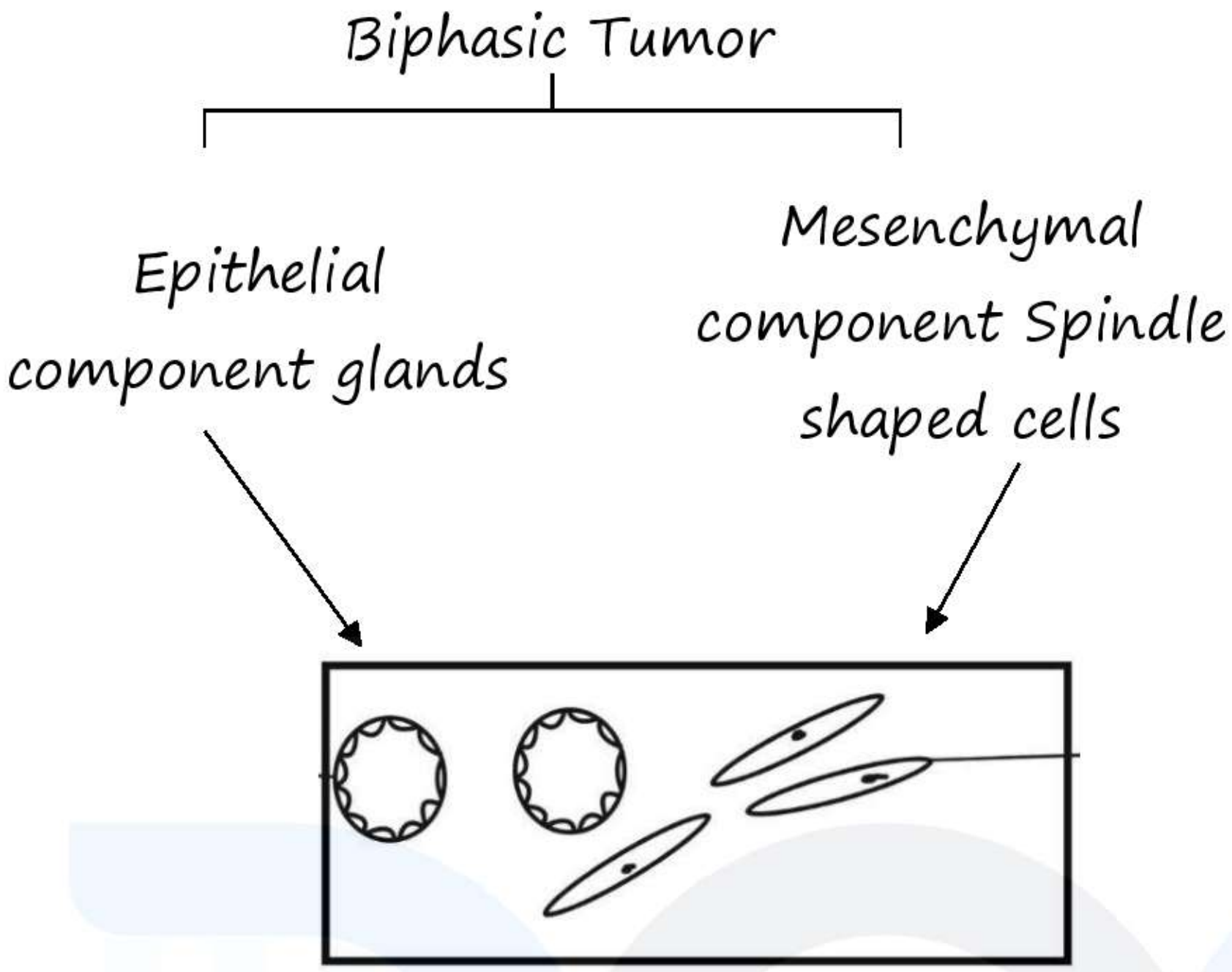

Diagnosis

I. IHC
   i. Calretinin
   ii. CK 5/6
   iii. WT1
II. Electron Microscopy – Long & Thin Branching microvilli

AfraTafreeh.com

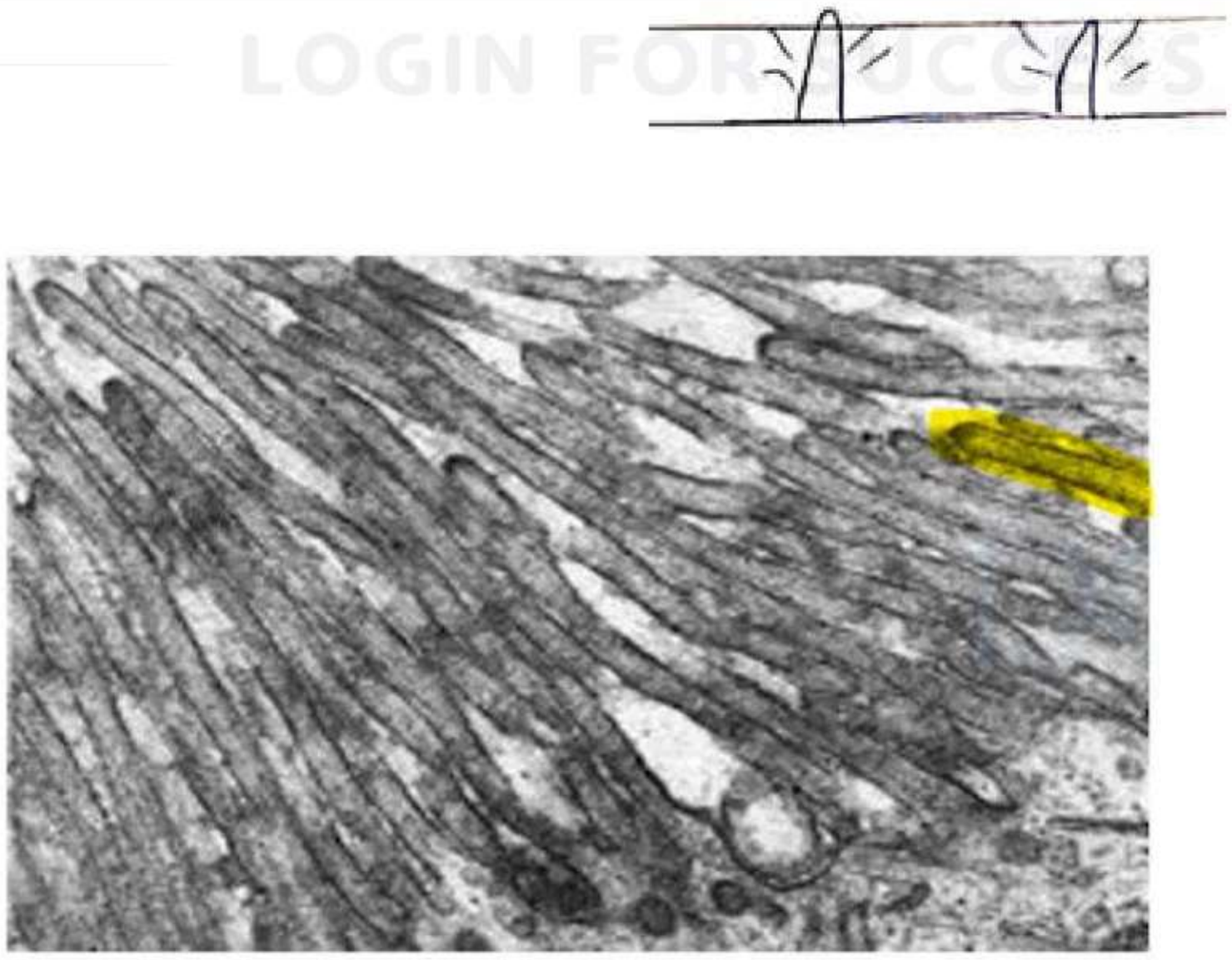

Asbestos Body in Lung Fig: 7

AfraTafreeh.com

Dumbbell Shaped

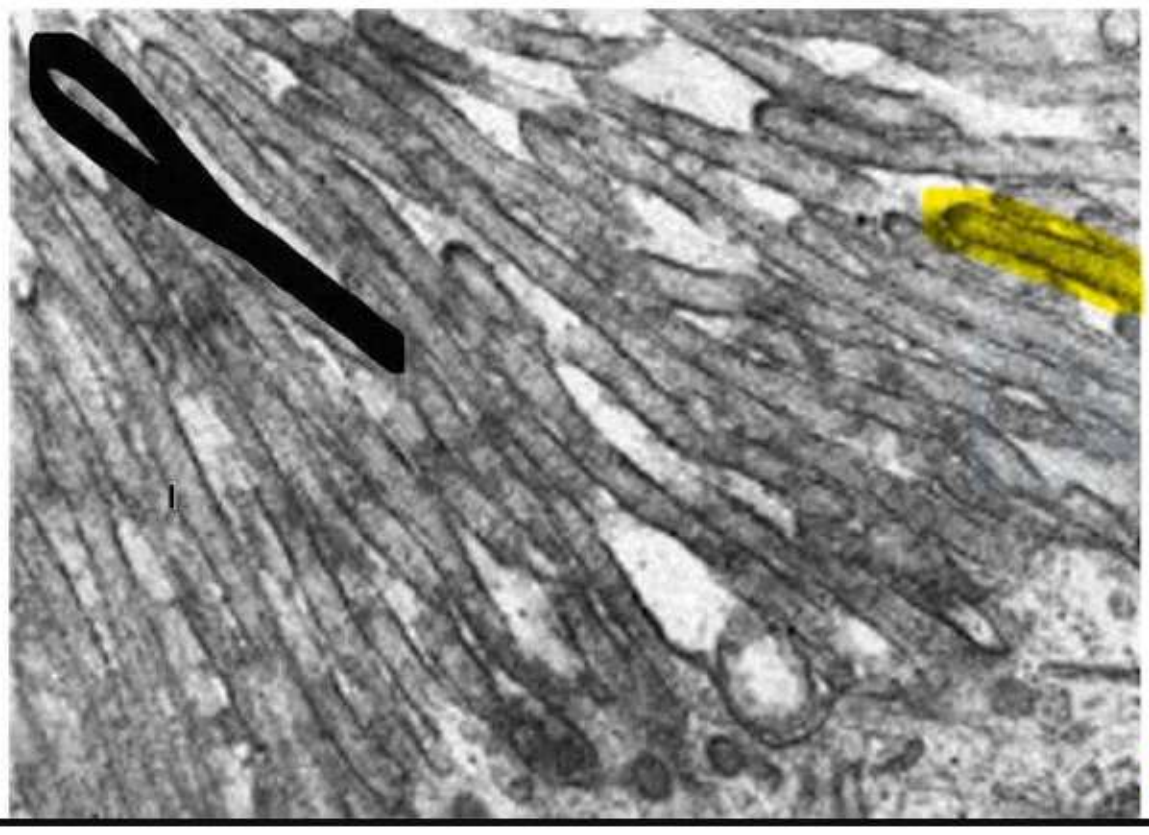

Fig: 8

- Dark core due to Iron deposition
- On Perls Prussian Blue stain – Blue Color due to Iron

Ferruginous Body

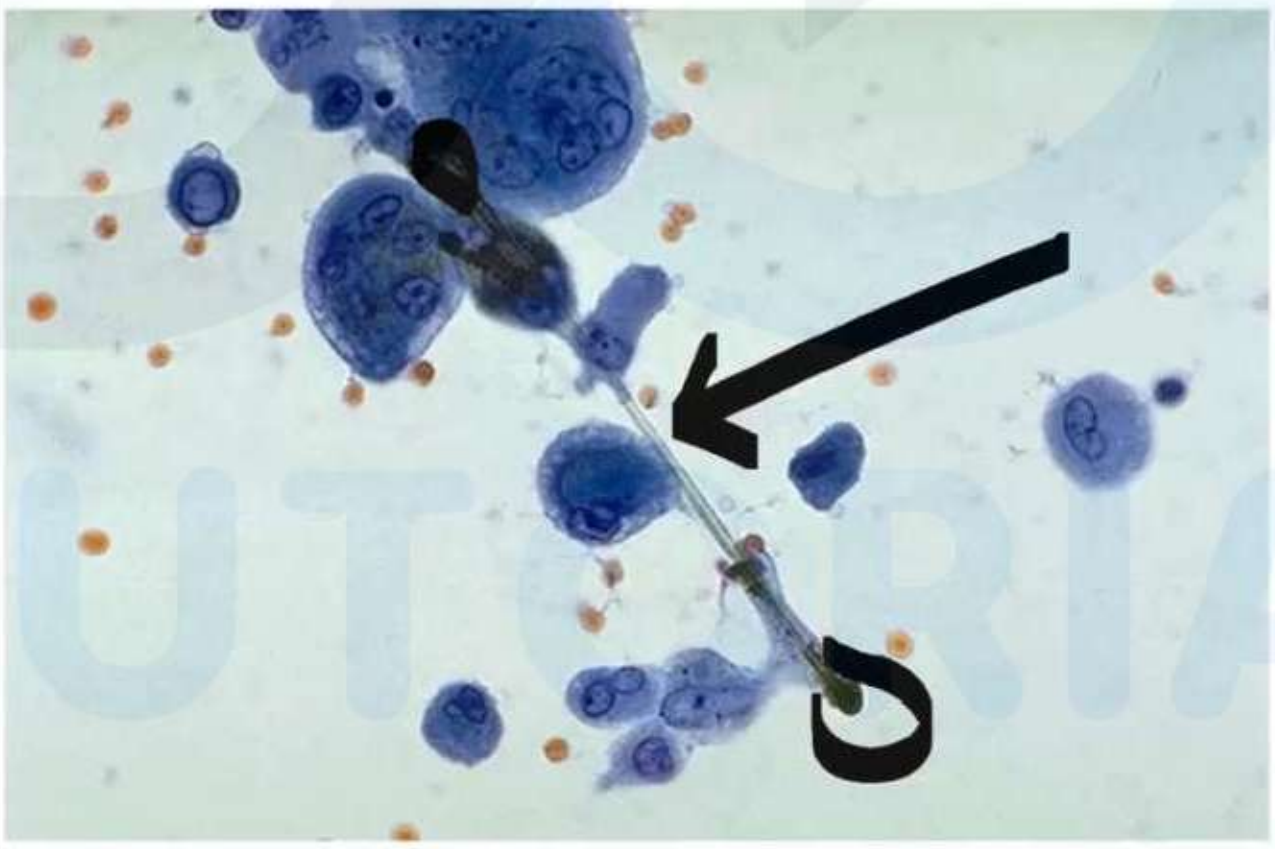

Fig: 9

TUTORIALS LOGIN FOR SUCCESS

GIST Adenocarcinoma - IHC – TTF 1 Napsin CK 7 - Update – New IHC markers B72.3 MOC – 3.1 - E/M : Short, Stout Non – Branching microvilli	Mesothelioma IHC – Calretinin CK 5/6 WT 1 E/M:  Long Branching microvilli

Recent Update

- Genome Wide Association Studies (GWAS)
- All the lung cancers irrespective of type always have 3p deletion as first mutation

AfraTafreeh.com

AfraTafreeh.com

3 p deletation (earliest mutation)

Loss of RB gene	Mutation of GFR	Deletion of p16
Mutation of L-MYC	KRAS	
	ALK	
↓	↓	
Small cell Ca	Adenocarcinoma	

TUTORIALS
LOGIN FOR SUCCESS

UNDERSTANDING BASIC TESTIS STRUCTURE

MALE GENITAL SYSTEM

Histology of Testis 00:01:02

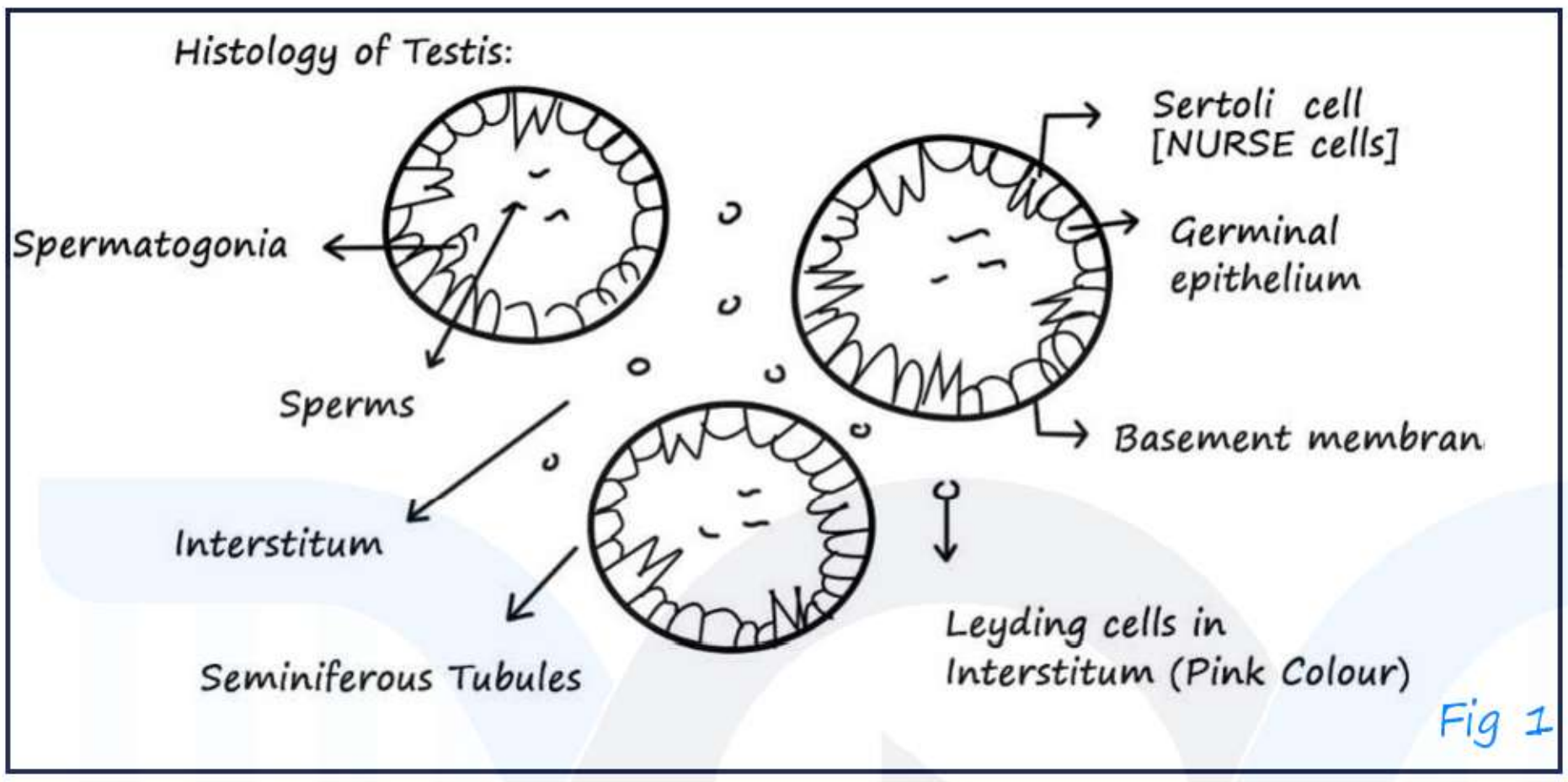

Fig 1

- Normally there are very few Leydig cells in Interstitum
- If Leydig cell number increase possibilities are
- Testicular atrophy – Thickened basement membrane prominent Leydig cells
- Testicular tumors
- On histology, Leydig cell proliferation shows crystals within Leydig cells called crystals of Reinke

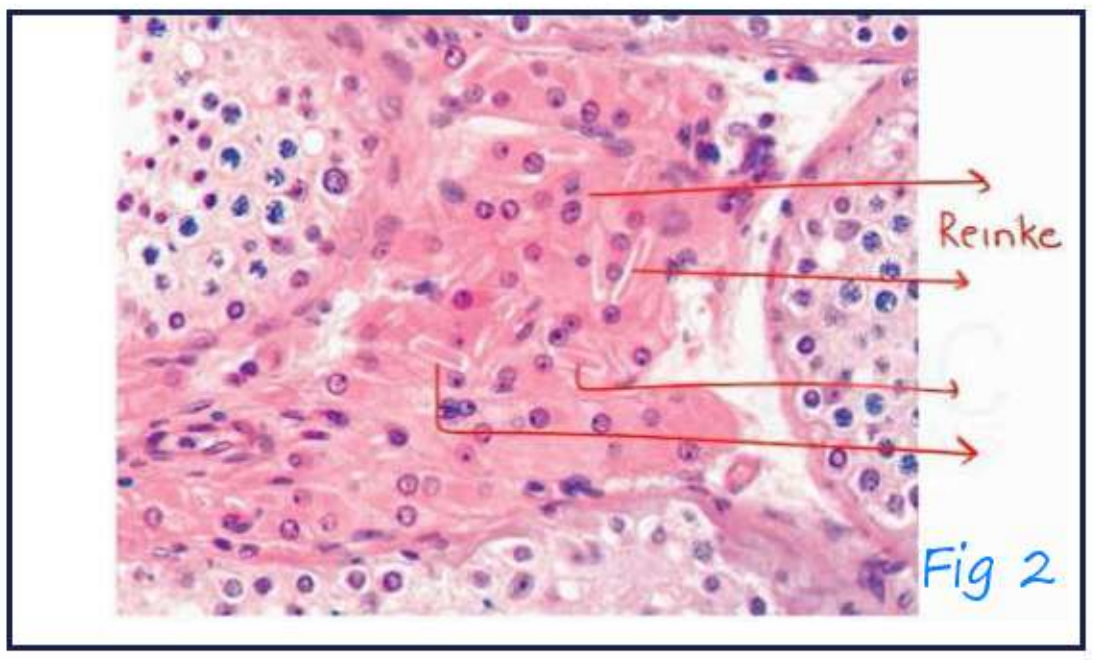

Fig 2

AfraTafreeh.com

Spermatogenesis:

- Spermatogonia

  ↓
- 1° Spermatocyte (2n)

  ↓
- 2° Spermatocyte (n)

  ↓
- Spermatids

  ↓
- (4) Sperms

  ↓
- Spermatogonia are kept in immature state by markers

  SOX2
  Out ¾
  CKIT
  NaNog

  These are called pluripotency markers.

Therapeutic Cloning

- The pluripotent markers were utilized to produce pluripotent cells from mature cells

Mature cells Pluripotent cells

SOX 2

Oct ¾

CKIT

NaNog

- These pluripotent cells produced with the help of immaturity markers are called as inducible pluripotent Stem cells. (iPs)
- This procedure of generating pluripotent cells was called therapeutic cloning

- Normally after puberty, immature cells change into mature cells

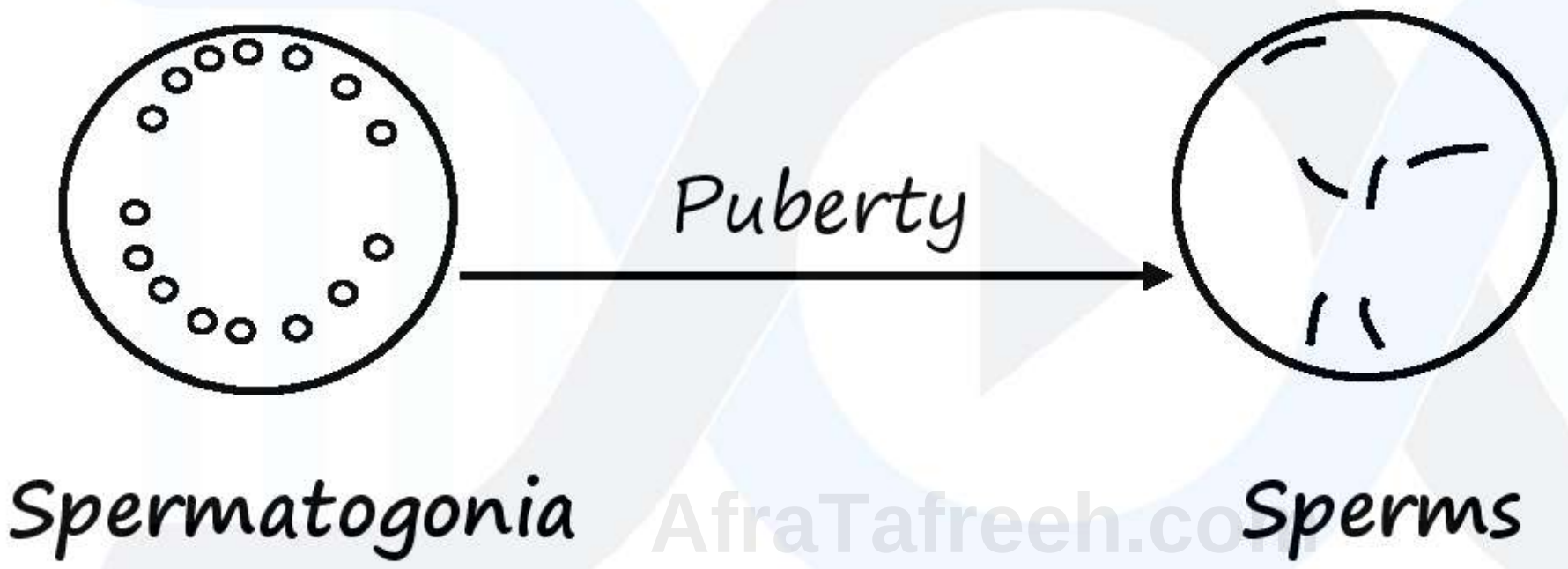

AfraTafreeh.com

- This is because the pluripoteney markers or immature
  Cell markers stop experssing

  ↓

  But if these markers keep on expressing → No mature cells fomed

- Immature cells proliferate and persist even after puberty. This was called as intratubular

AfraTafreeh.com

germ cell neoplasia (ITGCN) Or Germ cell neoplasia in situ

(According to new WHO naming)

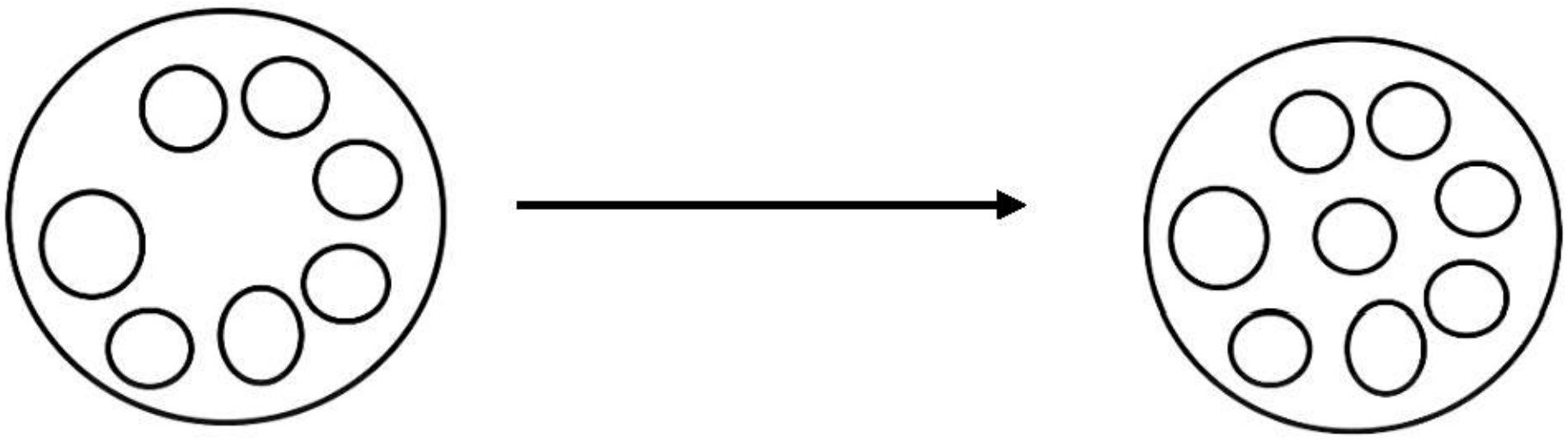

Immature cells → **ITGCN or germ cell neoplasia in situ**

Stay immature because of

↓

SOX 2
Oct ¾
NaNog
CKIT

] If persist

ITGCN or germ cell neoplasia in situ ↓ Aquire mutations like i12 p

- So GCNIS is a precursor lesion of all germ cell tumors of testis except

i. Spermatocytic tumor → occurs in elderly > 60 yr

ii. Yolk sac tumor]
iii. Teratoma] Child

- Spermatocytic tumor has Gain of chromosome 9 mutation.

Classification of Testicular tumors 00:21:31

Classification of Testicular Tumors

- Germ – cell tumors
- Sex cord – stromal tumor
  - Sertoli's cell tumor
  - Leyding cell tumor

Lymphoma

Germ Cell tumors

- Not arising from GCNIS
  - i. Spermatocytic tumors
  - ii. Yolk sac tumor
  - iii. Teratoma
- Arising from GCNIS
  - Seminoma
  - Non-Seminomatous GCT
    ↓
    - Choriocarcinoma
    - Embryonal Carcinoma
    - Teratoma
    - Yolk sac Tumor

AfraTafreeh.com
TUTORIALS
LOGIN FOR SUCCESS

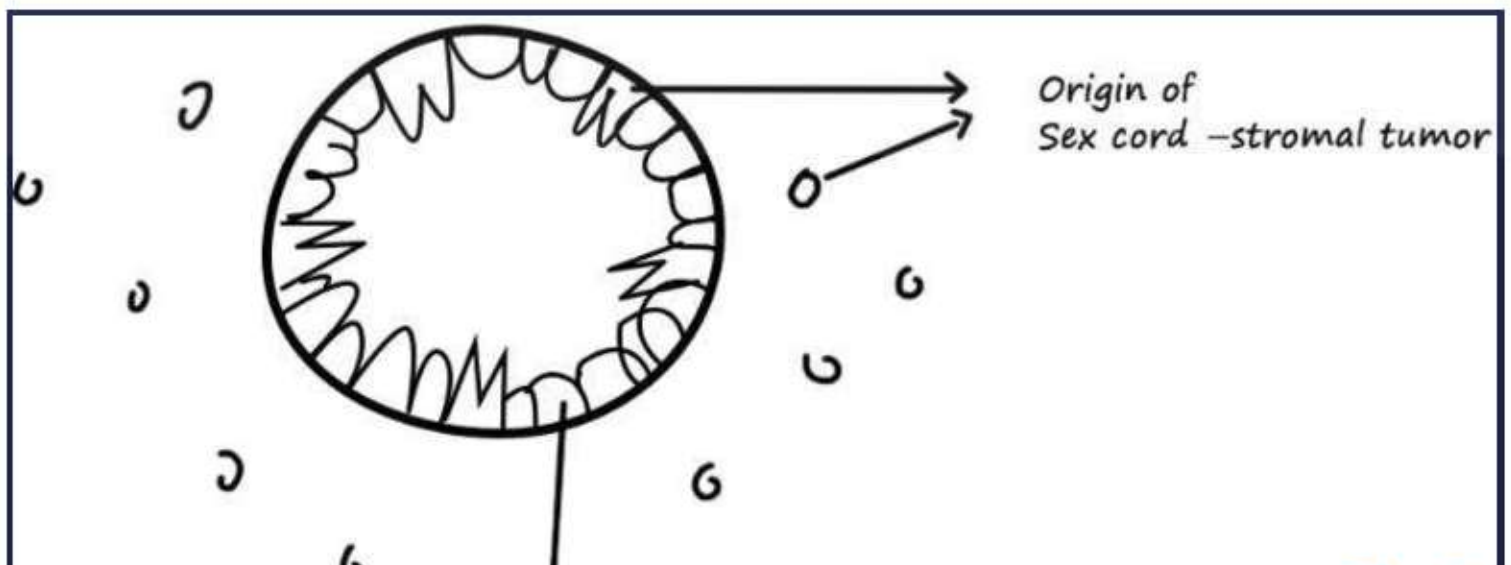

Fig 3

AfraTafreeh.com

CLASSIFICATION OF TESTICULAR TUMOR

Classification of Testicular tumors 00:00:19

Classification of Testicular Tumor

- Germ cell Tumors
- Sex cord tumors
- Combination of Germ cell and sex Cord tumors
  ↓
  Gonadoblastoma.
- Testicular Lymph

- Most common testicular tumor in child <3yr
  Yolk sac tumor > teratoma.
  (Excellent prognosis)
- Middle age – seminoma

(Elderly –Testicular lymphoma (M/C) → worst prognosis
Spermatocyte's tumor → Good prognosis

Germ cell Tumor

- Seminoma
- Non- Seminomatous

Etiology of Germ cell tumors

Genetic
- M/C is i12p
- KIT mutation

Acquired
1) Testicular dysgenesis syndrome

Cryptorchidism

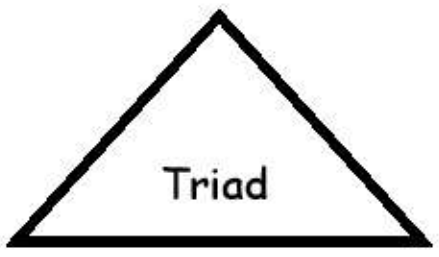

Hypospadias's poor sperm quality

- Occurs when pregnant females are Exposed to pesticides
- High risk of developing testicular Carcinoma

2) Cryptorchidism

Seminomas 00:09:40

- M/C type GCT (50%).
- Peaks incidence between 20-40yr (never occurs in infants)
- Ovarian counterpart is Dysgerminoma

  Gross- Homogenous lobulated gray -white mass → Cut potato appearance

Fig 1

Microscopy-

AfraTafreeh.com

- Sheets uniform polygonal cells with well-defined outline and abundant watery clear cytoplasm

- Divided into poorly demarcated bobbles by delicate fibrous Containing lymphocytic infiltrate (T lymphocytes)

AfraTafreeh.com

Update 00:15:12

- GCNIS markers sox2, NANOG, CKIT. oct ¾

  ↓ I 12p

- Seminoma- 1) No SOX-2 mutation instead expressive SOX17

  2) Unique markers –SALL4

- So, mutations in seminoma → i12p, SOX 17, NANOG, CKIT, oct ¾ SALL4
- Testicular tumors first metastatic to retroperitoneal Lymph Nodes.
- Remember –FNAC is C/I in testicular tumors.

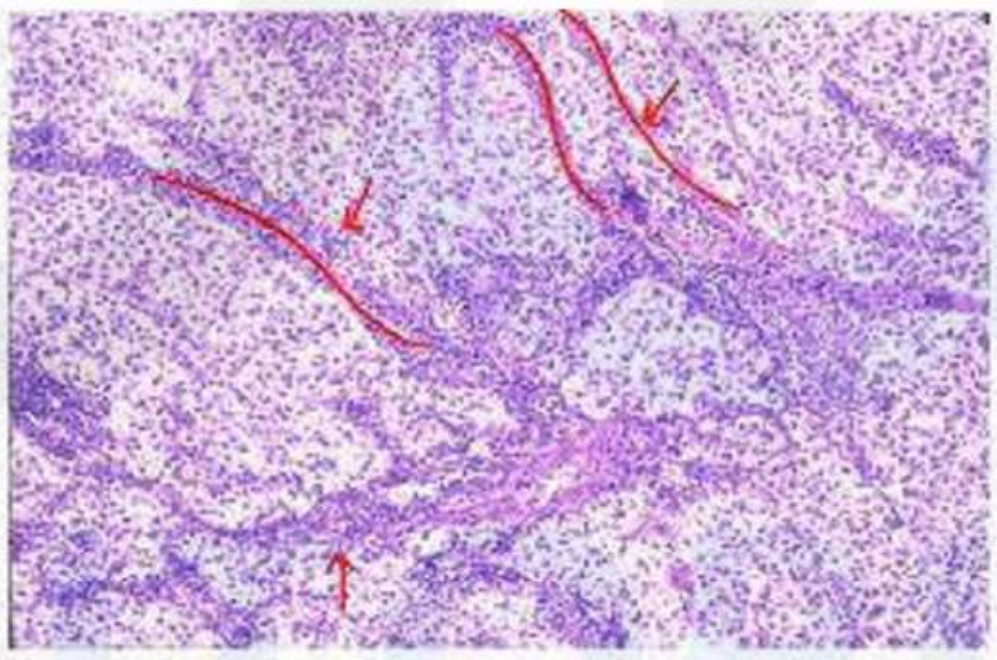

Fig 2

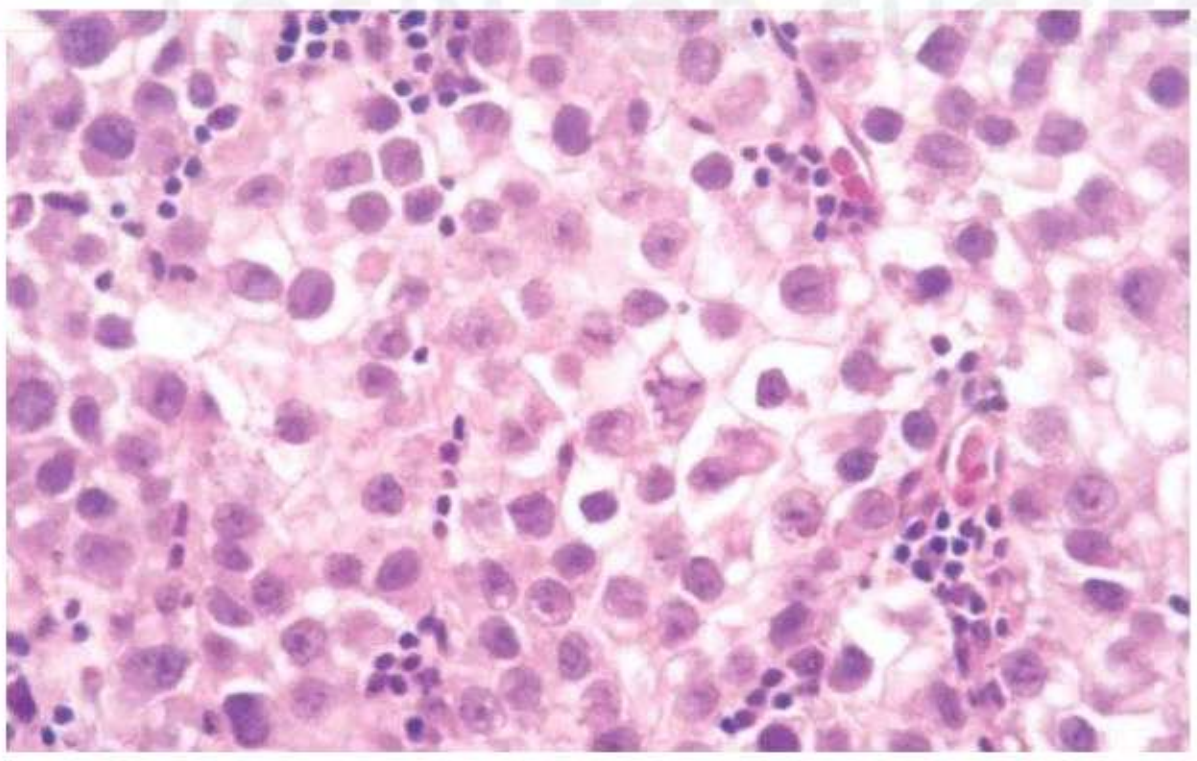

Fig 3

Diagnosis of seminoma 00:20:50

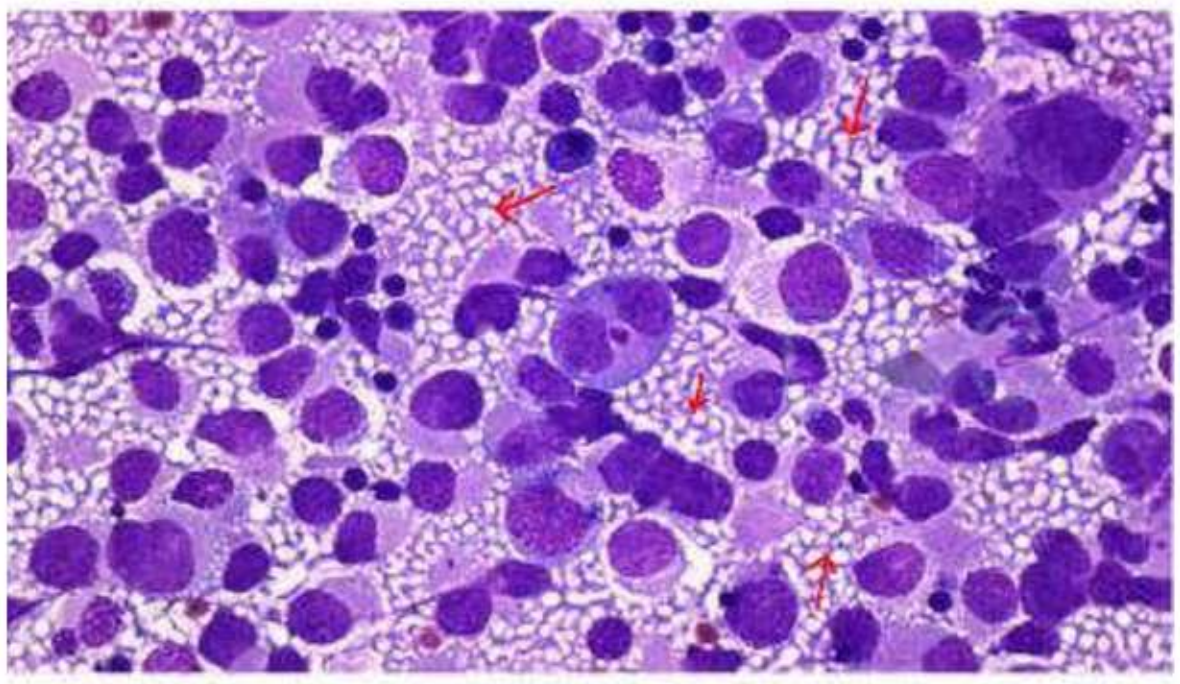

Fig 4

1.On cytology (If FNC done) – Tigroid background

↓

Highly suggestive of seminoma

2.Tumor markers –PLAP, LDH

If giant cells present → positive for β- HCG.

3.Biopsy –Characteristics Histological finding of polygonal cells with abundant watery clear cytoplasm and septae

4.IHC- SOX17, SALL4 oct ¾, NaNOG, CKIT/CD117.

5.Molecular analysis → c12p

AfraTafreeh.com
TUTORIALS
LOGIN FOR SUCCESS

AfraTafreeh.com

SPERMATOCYTIC TUMOR

- Not arising from GCNIS
- Mutations – Gain of Chromosome 9
  HRAS
  FGFR   Rare mutations
- Tumor of elderly > 65 years
- Good prognosis
- Made of Three Type of cells

- All of them have a very typical chromatin – Spireme chromatin i.e. filamentous chromatin

TUTORIALS
LOGIN FOR SUCCESS

Non – Seminomatous GCT 00:02:43

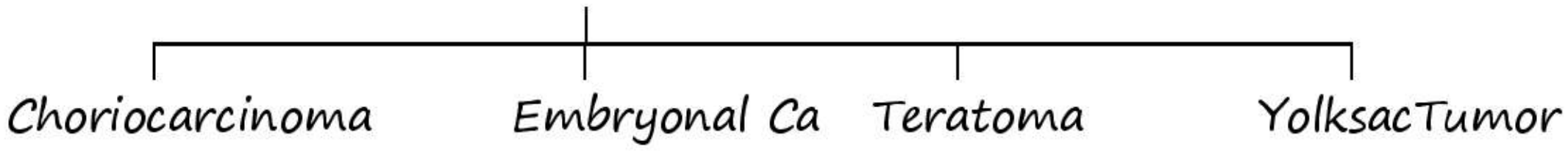

- Pneumonic – CETY

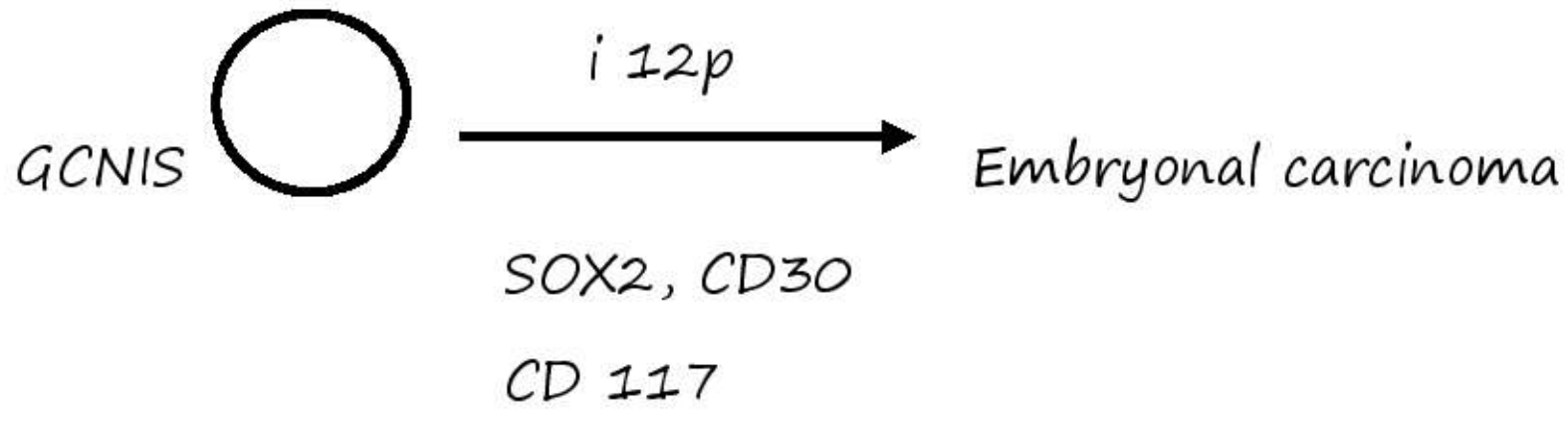

Embryonal Carcinoma

- Commonly presents as Mixed form
- Shows lots of Anaplasia
- Age ~ 30 years
- Poor prognosis'

Embryonal Carcinoma can differentiate into

Embryonic structure
↓
Gives rise to
Post pubertal Teratoma
↓
Teratoma with somatic malignancy

- So 1st tumor formed in Non-Seminomatous tumor lineage is embryonal carcinoma

Extra-embryonic structure
Gives rise to
Yolk sac tumor chorio carcinoma

AfraTafreeh.com
TUTORIALS
LOGIN FOR SUCCESS

Teratoma 00:10:00

GCNIS

⊕

- Post Pubertal Teratoma
- Poor prognosis
- Less organoid arrangement
- Teratoma with Somatic malignancy

⊖

PrePubertal Teratoma

- Better Prognosis
- Better organoid arrangement
- Benign tumors

- Teratomas show differentiation along endodermal, mesodermal and ectodermal lines
- Pure Teratomas are rare (Pure teratomas common in children)

AfraTafreeh.com

- Usually, Ectodermal component becomes malignant malignancy being SCC
- Gross- Commonly large with heterogeneous appearance

  Solid and cystic components



Rokitansky Protuberance □ HPE examination Should be done at this site because in 1% Teratomas with somatic malignancy, site of Origin is Rokitansky Protuberance

- Teratomas with cystic component predominant on section Show proliferation of ectodermal tissue – known as Dermoid cyst

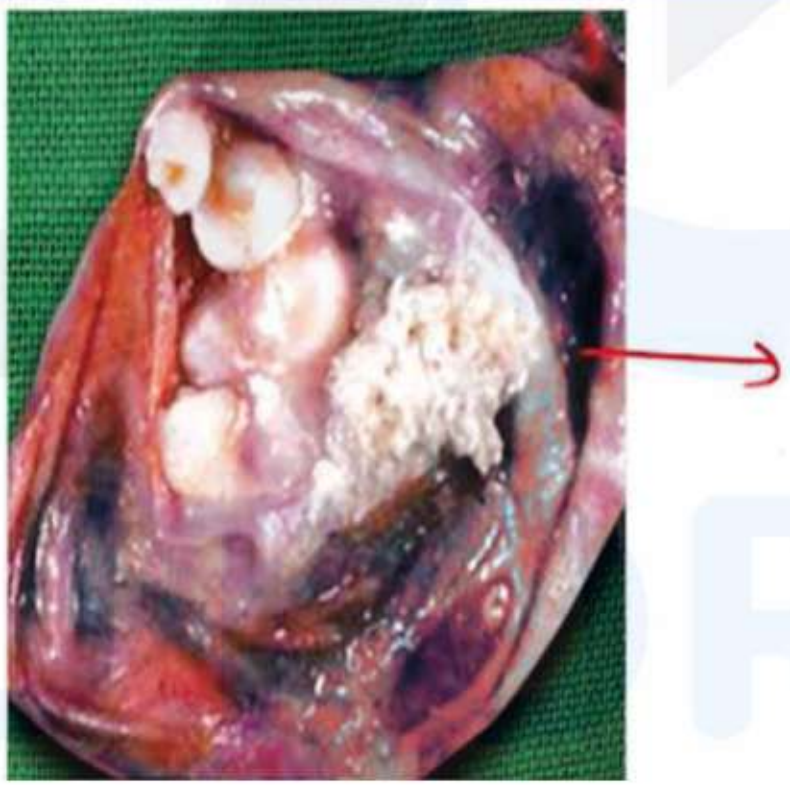

Gross Of Teratoma Fig 1

Choriocarcinoma

- Highly malignant neoplasm composed of both cytotrophoblastic and syncytiotrophoblast cells
- Incidence is less than 1 %
- Size is usually less than 2cm. Does not produce Testicular lump
- Worst prognosis

- Early metastasis to lungs, Brain
- Gross- Extensive areas of hemorrhage and necrosis

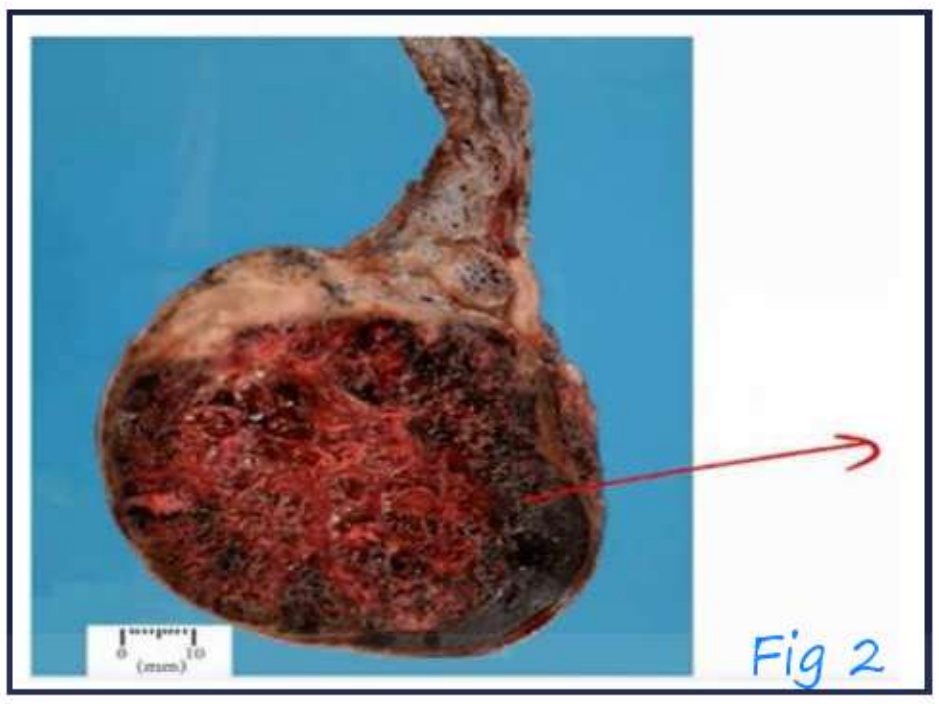

Fig 2

Microscopy – Combination of 2 types of cells

Syncytiotrophoblast   Cytotrophoblast

- Multinucleated
- Secrete Hcg

AfraTafreeh.com
TUTORIALS
LOGIN FOR SUCCESS

- Polyhedral Cytotrophoblastic cells growing in sheets or cords
- Admixed with multinucleated syncytiotrophoblastic cells
- Tumor marker -β HCG

Yolk Sac Tumor Endodermal Sinus Tumor

- M/C testicular tumor in infants and children upto 3 years of age
- Most adult cases occur as a component of embryonal Carcinoma
- Good prognosis
- No GCNIS precursor

AfraTafreeh.com

- Gross – Gelatinous tumor

Fig 3

- <u>Microscopy</u> – Schiller Duval bodies – Resemble fetal glomeruli
- Have a central blood vessel surrounded by tumor cells Enclosed inside a cystic space which is again enclosed by tumor cells

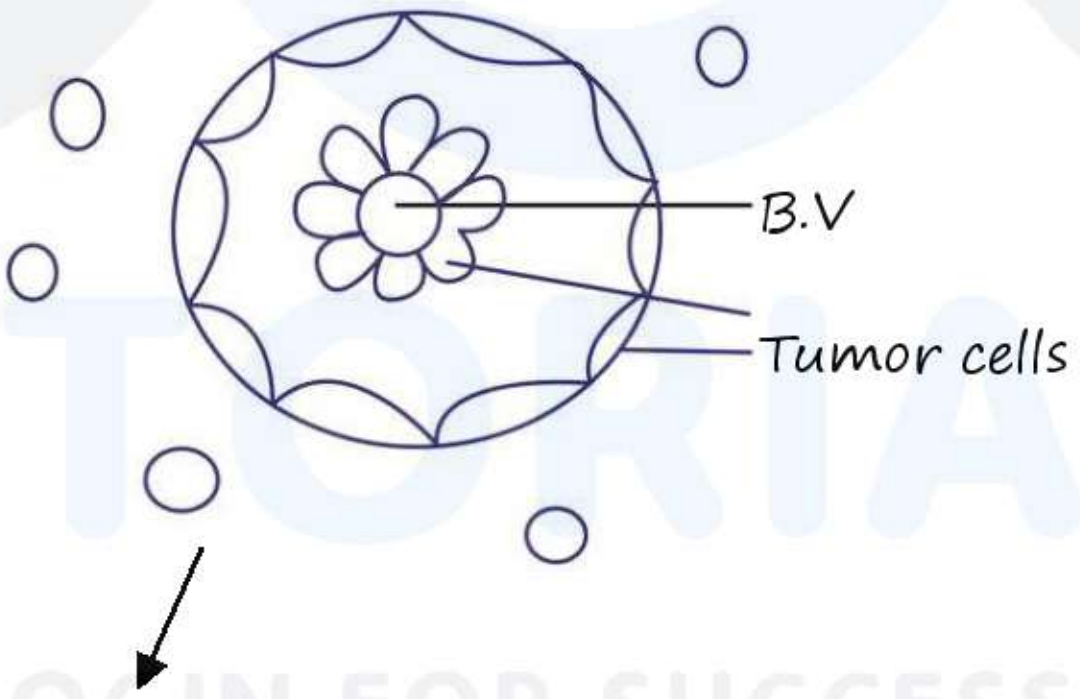

- Hyaline Globules rich in AFP (α – fetoprotein)
- Tumor marker – AFP
- IHC– Glypican 3+ve, AFE

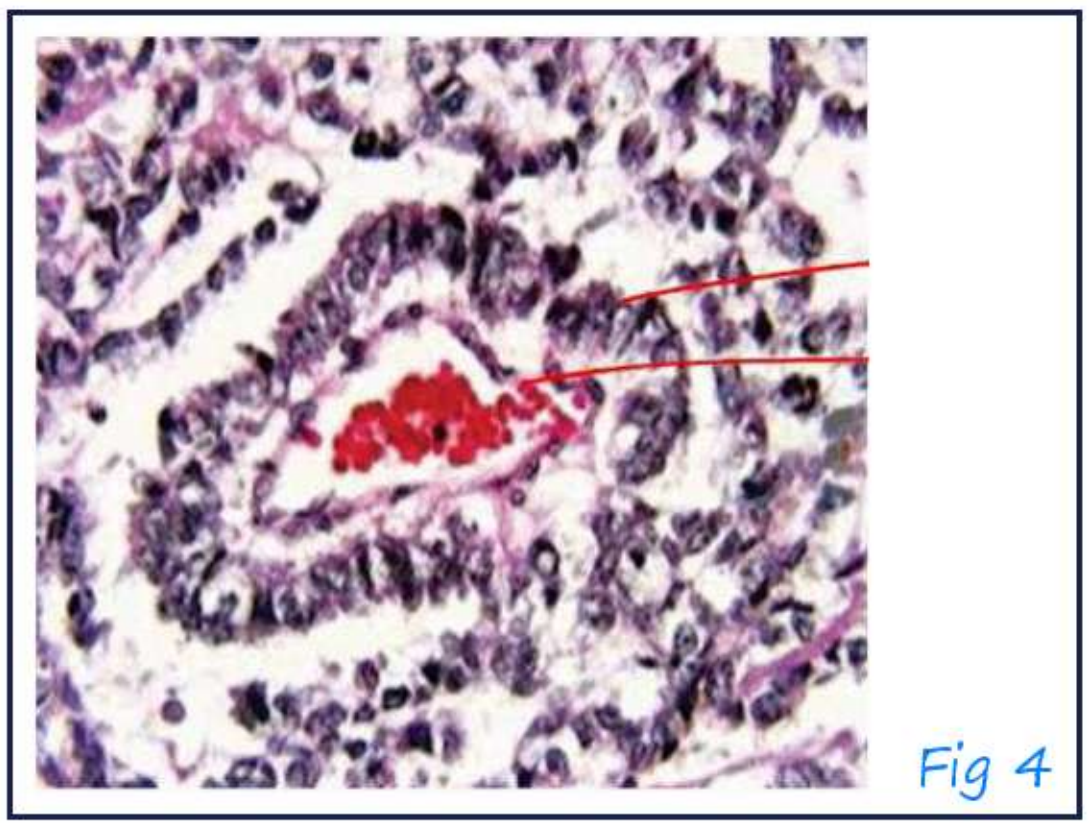
Fig 4

SEX CORD TUMORS

- Have DICER mutations. Mostly benign and can occur at any age
- Sex cord tumors – have dicer mutation Mostly benign and can occur at any age

Sertoli cell Tumor

- Tubules present on HPE

Leydig cell tumor

- Only 2% of all testicular tumor
- Commonly affects b/w 20 & 60 years
- Produce Hormones Androgens, estrogens And corticosteroids
- Mostly presents with testicular mass
- Gynecomastia if estrogen is produced
- Most are Benign
- Gross- Golden Brown cut Surface
- Microscopy –Leydig cell Proliferation
  ↓
- Eosinophilic Crystals of Reinke seen within tumor cells
- Lipofuschin pigment seen

AfroTafreeh.com
DOC TUTORIALS LOGIN FOR SUCCESS

AfraTafreeh.com

Reinke crystal

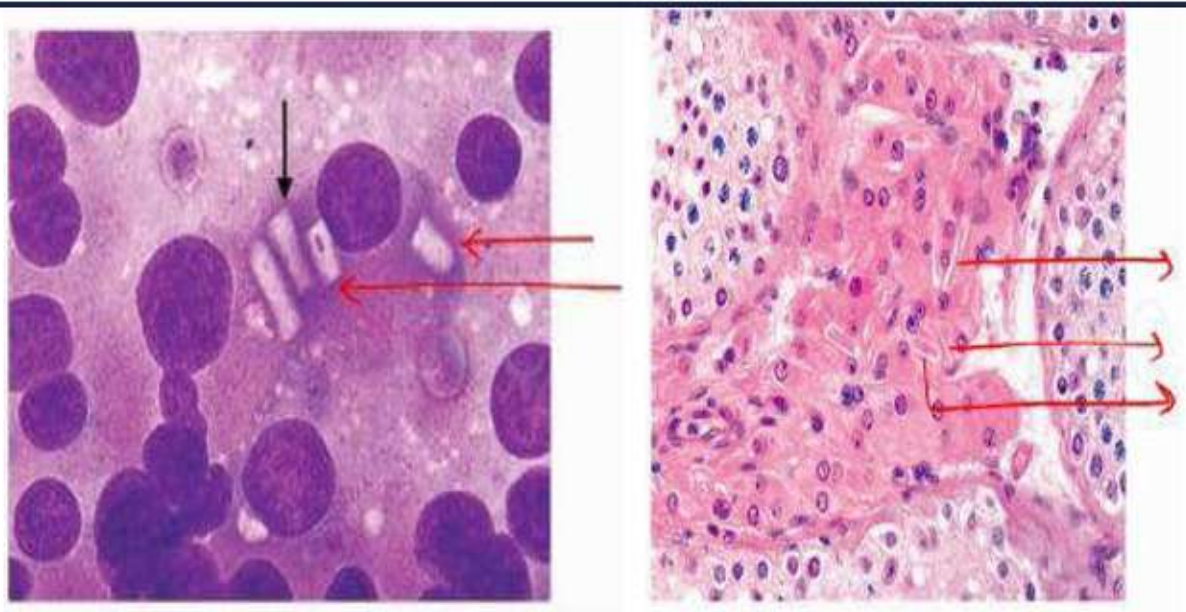

(high power) (Low power) Fig 1

- Note: - Normally lipofuschin is usually present in seminal Vesicles
- Patients with PeutzJegher syndrome have high chances of sex cord stromal tumors.

Testicular Lymphomas

- M/C Testicular tumor in elderly > 60 years
- M/C is DLBCL >Burkitt's Lymphoma > Extra nodal NK/T cell
- Usually positive for CD 20 Therefore Rituximab is used as therapy
- Highly aggressive tumor with poor prognosis

- Note: - GCTs can also occur at extra testicular sites like Mediastinum, CNS-pineal Gland. Labelled as Germanias.

GONADOBLASTOMA

- It is a mixture of germ cell tumor & sex cord stromal tumor.
- Rare Benign tumor with potential for malignant transformation
- Can progress to seminoma in males & Dysgerminoma in Females
- Usually occurs in individuals with abnormal sexual development & Indeterminate gonads usually gonadal Dysgenesis

Etiology: Most common Gene mutation → TSPY gene

AfraTafreeh.com
TUTORIALS
LOGIN FOR SUCCESS

Predisposing syndromes

- Denys dash syndrome –Mutation of WT1 → Wilms tumor, Gonadal dysgenesis
- Tumor syndrome – streak ovaries

Morphology – mixtures of germ cells & sex cord stromal

- X ray Adenoma may reveal Gonadal calcification a classic pathologic finding in Gonadoblastoma
- Excellent prognosis if completely excised.

AfraTafreeh.com

BILIARY CIRRHOSIS – DIFFERENCE BETWEEN PRIMARY & SECONDARY

Autoimmune cholangiopathies

Pathogenesis

- E_2 Component of Pyruvate Dehydrogenase activate TH_1 cells via Antigen presenting Cells
- TH_1 cell secrete IFN Gama – Leads to granuloma formation in bile ducts. Hence, leads to granulomatous inflammation.
- Activation of B Cells which activate plasma cells which secrete antibodies called Anti Mitochondrial Antibodies

Morphology 00:04:41

- Granulomatous inflammation of bile ductulus leads to ductular reaction.
- Progressively granulomatous inflammation leads to cirrhosis – Primary Biliary Cirrhosis
- This Cirrhosis is called Jigsaw Cirrhosis
- Portal tract is markedly expanded by an infiltrate of Lymphocytes and plasma cells surrounding a destructive granulomatous reaction centered on a bile duct

LOGIN FOR SUCCESS

Clinical Features of Primary Biliary Cirrhosis

00:09:38

- Females
- Age 40- 50 years
- Associated with Autoimmune Disorder
- Show Features of Cholestasis

  a. Pruritus

  b. Jaundice

  c. Xanthomas

  d. Xanthelasmas

  e. Dyslipidemia

- Elevated level of serum Alkaline Phosphatase and Gama Glutamyl transpeptidase

AfraTafreeh.com

Secondary Biliary Cirrhosis 00:12:06

TUTORIALS
LOGIN FOR SUCCESS

Pathogenesis

- Incomplete obstruction of bile duct, bacteria more retrograde manner / ascending manner from intestine and lead to ascending cholangitis-Neutrophils accumulate in lumen of bile duct and epithelium.
- Inflammation is associated with Periportal edema
- Ductular reaction also occurs.

AfraTafreeh.com

- In adults' obstruction of bile duct is seen in gall stones and carcinoma of gallbladder. In children EHBA and cystic fibrosis, choledochal cyst.

Secondary biliary cirrhosis	Primary biliary cirrhosis
Extrahepatic bile duct obstruction. Biliary atresia, gallstones, stricture, carcinoma of pancreatic head	Possibly autoimmune AMA=VE
No sex predilection	Female
Conjugated hyperbilirubinemia, increased serum alkaline phosphatase, bile acids, cholesterol	Plus elevated antibodies
Prominent bile stasis in bile ducts, bile ductular proliferation with surrounding neutrophils, portal tract edema	Dense lypghoplasmacytic infiltrate in portal tracts with granulomatous destruction of bile ducts (florid duct lesion)

TUTORIALS
LOGIN FOR SUCCESS

AUTOIMMUNE CHOLANGIOPATHIES –

PRIMARY SCLEROSING CHOLANGITIS - I

Primary Sclerosing Cholangitis 00:00:30

- Autoimmune Disease / MHC-HLAB8
- Associated with Ulcerative colitis.

Pathogenesis

- TH2 Cells activated which activates neutrophils
- TH2 Cells cross react with Antigen of Bile Duct & cause damage to bile duct – leads to Inflammation & obliteration
- Leads to **Beading of Bile Ducts**
- Seen in large intrahepatic & extrahepatic Ducts
- Small Bile ducts show concentric fibrosis - Onion Skinning of Bile Ducts

AfroTafreeh.com
TUTORIALS
LOGIN FOR SUCCESS

Antibodies Seen

- Atypical pANCA (60 - 65% cases) attacks nuclear envelope proteins.
- Anti Mitochondrial Ab (5% cases)

AfraTafreeh.com

Primary sclerosing cholangitis	Primary biliary cirrhosis
• Males 25-35 years • PANCA (Atypical Antibody) • ***Biopsy:*** Onion skinning of small bile ducts, Beading of large bile ducts.	• Females 60 Years • Anti Mitochondrial Antibody • ***Biopsy***: Granulomatous Destruction

TUTORIALS
LOGIN FOR SUCCESS

PENILE LESIONS

Balanoprosthitis 00:00:07

- Inflammation of Glans & prepuce
- Inflammation of Glans → Balanitis
- Inflammation of Prepuce → posthitis
- Causes – i. DM
  ii. Candidiasis
  iii. STDS - Syphilis, Herpes
- chronic Balanoposthitis can cause phimosis Carcinoma penis

AlfaTafreeh.com

Benign Tumors of penis 00:01:00

Condyloma Acuminata

- HPV induced Acuminate lesion Hpv- 6,11
- Typically show kilocytes –Squamous cells with nucleus and perinuclear

TUTORIALS
LOGIN FOR SUCCESS

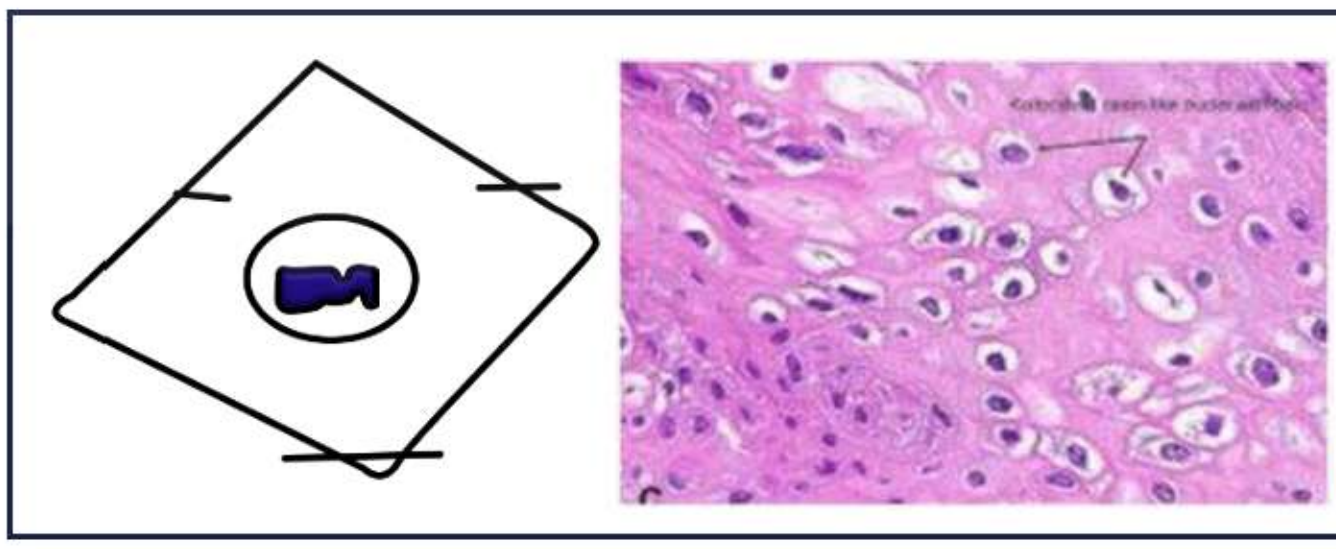

Fig 1

- Usually does not turn malignancy
- But can recur after excision

AfraTafreeh.com

Premalignant Lesions of Penis 00:02:14

Carcinoma in site

- Either in Gland or in the shaft

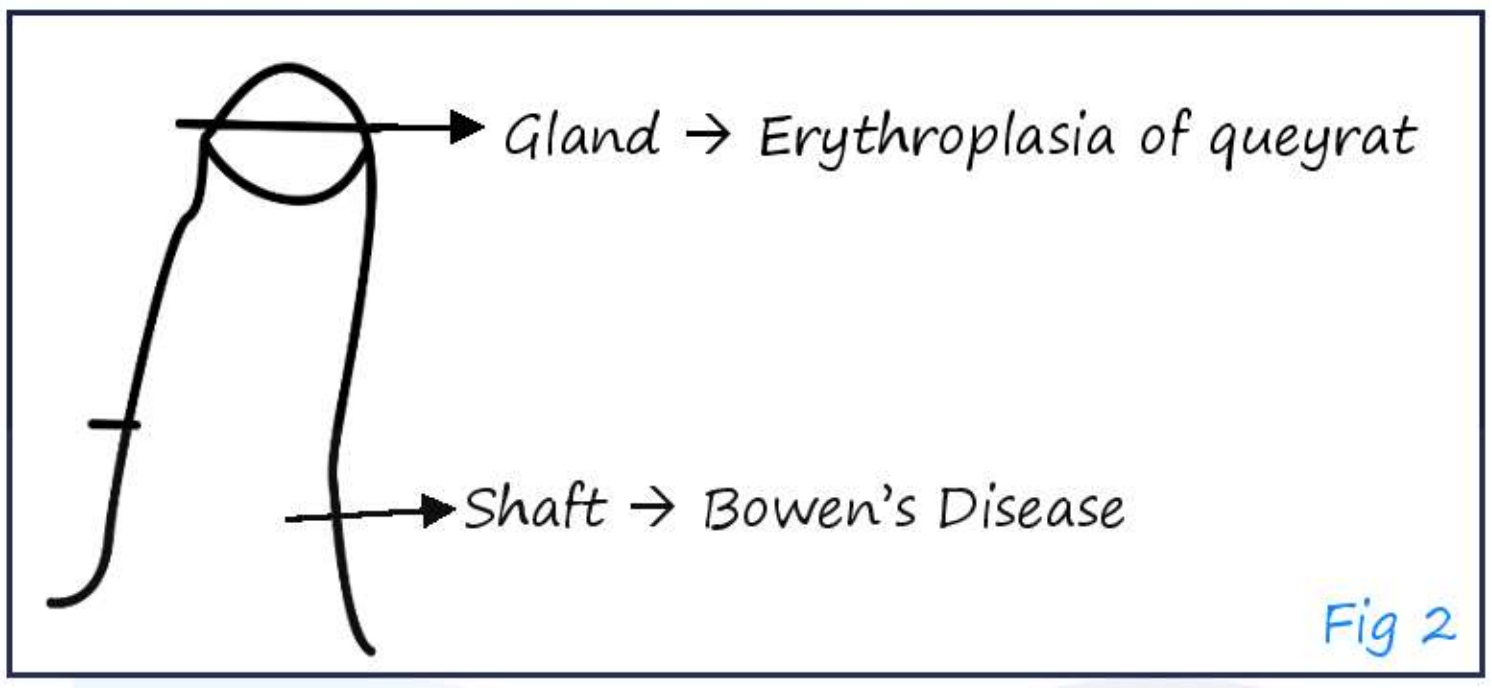

Fig 2

- Show a typical squamous cell, but basement membrane is always intact

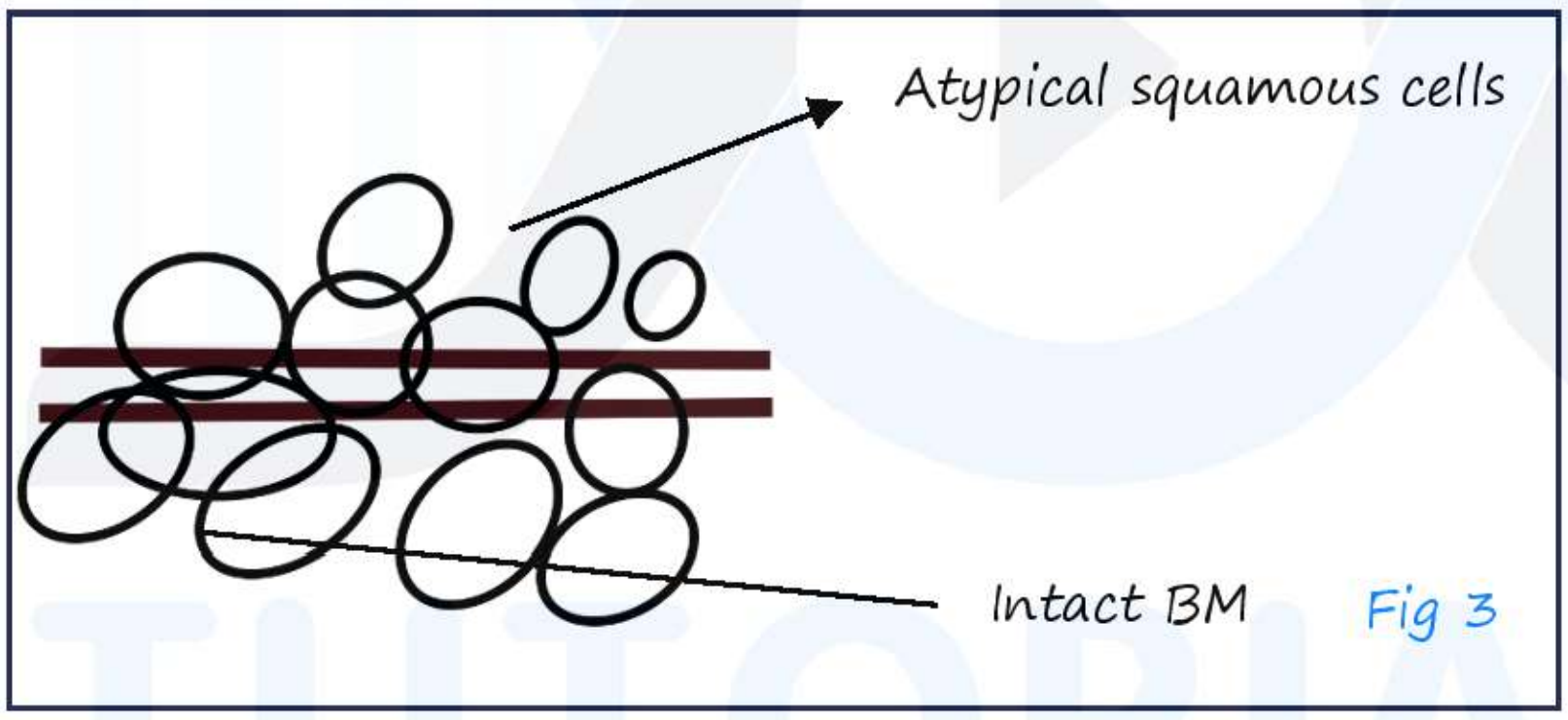

Fig 3

Bowens Disease	Bowenoid papulosis
• Carcinoma in sites • older Males>30yeras • HPV induced • Single lesion active male • Microscopically-CTS • Atypically proliferation of squamous cell With Intact basement membrane • can progress to penile cancer	• clinically resembles warts & Histologically • younger<30sexually • Hpv induced • Multiple lesion • Microscopically 1) Proliferation of Squamous cell 2) Pigmented 3) Inclusions in granular layer - Generally considered Benign

Carcinoma of penis

- Commonly squamous cell Carcinoma

  Etiology – Chronic Balonoposthitis

  - HPV-16, 18
  - STDs
  - Erythoplasia of Queyrat /Bowens Disease

SCC penis	verrucous (wart-like carcinoma)
1)Infiltrating/papilliferous Or Ulcerative type 2)Invasive 3)Glass penis is the most Common site	1) Exophytic lesions 2) Non –infiltrative only in the top layer of skin 3) Also known as Giant condyloma

- Well differentiated SCC shows keratin pearls on Histology

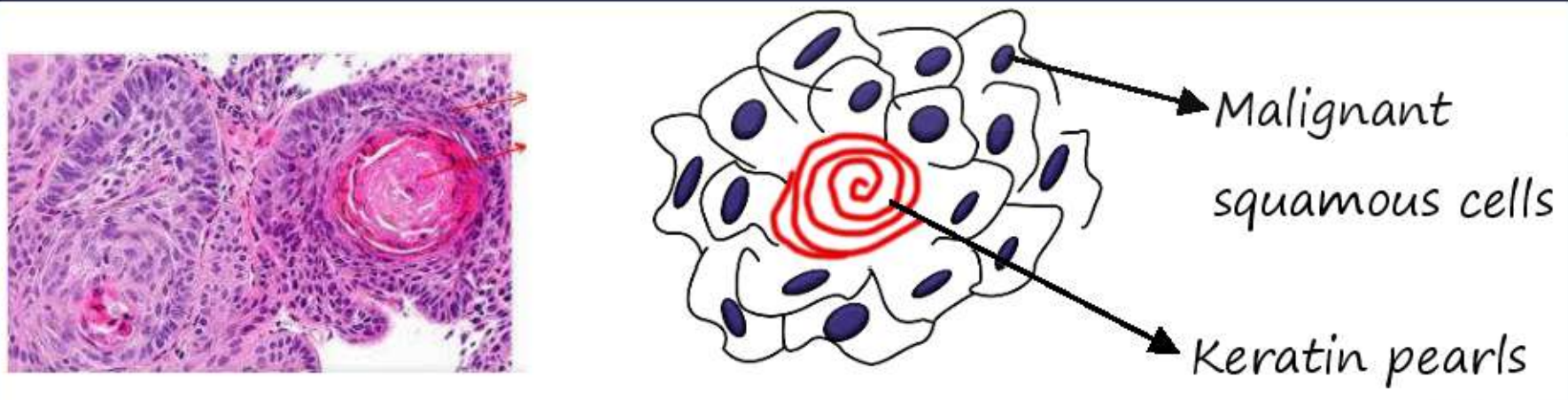

Fig 4

- Spread through lymphatics to horizontal group of inguinal lymph Nodes.

AfraTafreeh.com

PROSTATE CANCER & GLEASON SCORE

Cancer and gleason score Prostate 00:00:30

- 2 lining epithelium

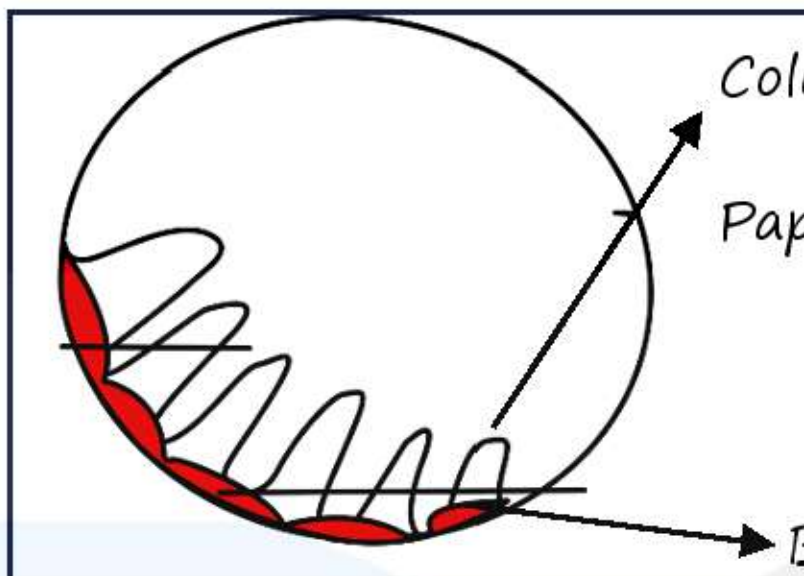

Fig 1

- Loss of Basal cells is seen in prostate cancer.

Identification of Basal cells

Markers: 1) High molecular weight cytokeratin in cytoplasm of basal cells –Ck 34BE12

2) P63 in Nucleus

Benign Hyperplasia of prostate (BHP) or Benign prostatic

Hyperplasia (BPH) 00:04:05

- Originates in the transition zone of prostate
- Incidence is age related 50% in 51-60years. >90% in men older than 80 years

Etiology: Multifactorial and Endocrine controlled

Endocrine: Dihydrotestosterone (DHT) → causes Hyperplasia of both Glands & stroma giving Rise to hyperplastic Nodules

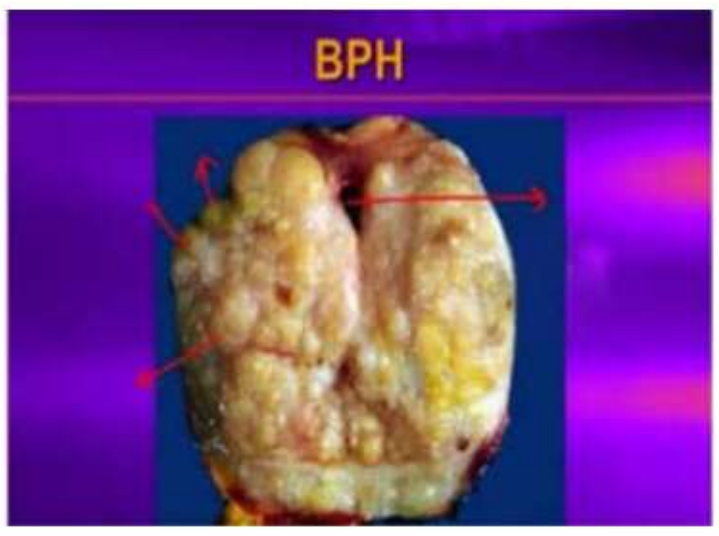

Fig 2

- These nodules compress the prostatic urethra, so the Patients present with obstructive symptoms like Hesitancy, Urgency, sensation of incomplete Bladder emptying, double voiding

Pathological Diagnosis

Prostate Biopsy	TURP Transurethral reaction of prostate Both diagnostic and therapeutic

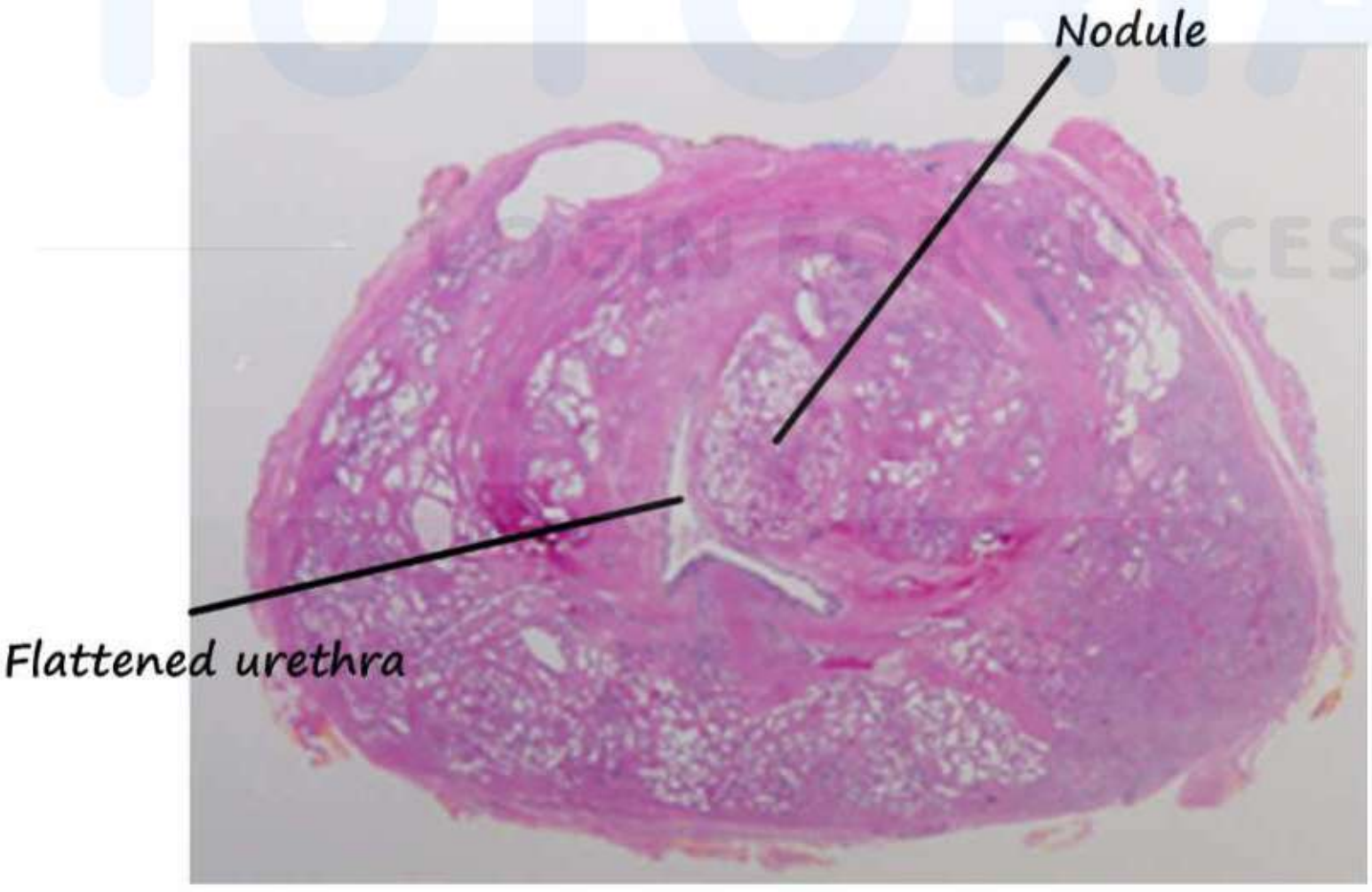

hyperplastic nodules Fig 3

AfraTafreeh.com

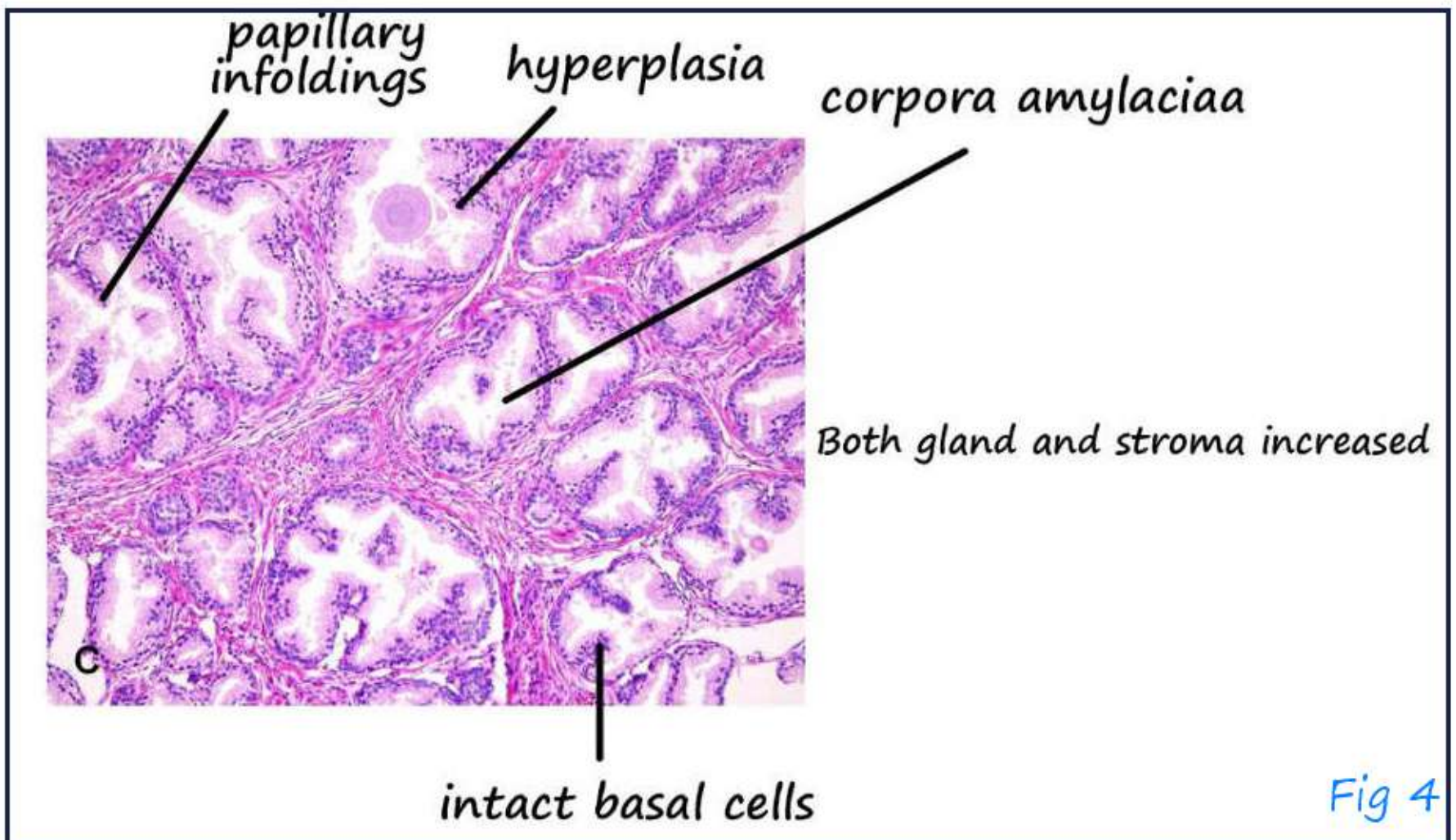

Fig 4

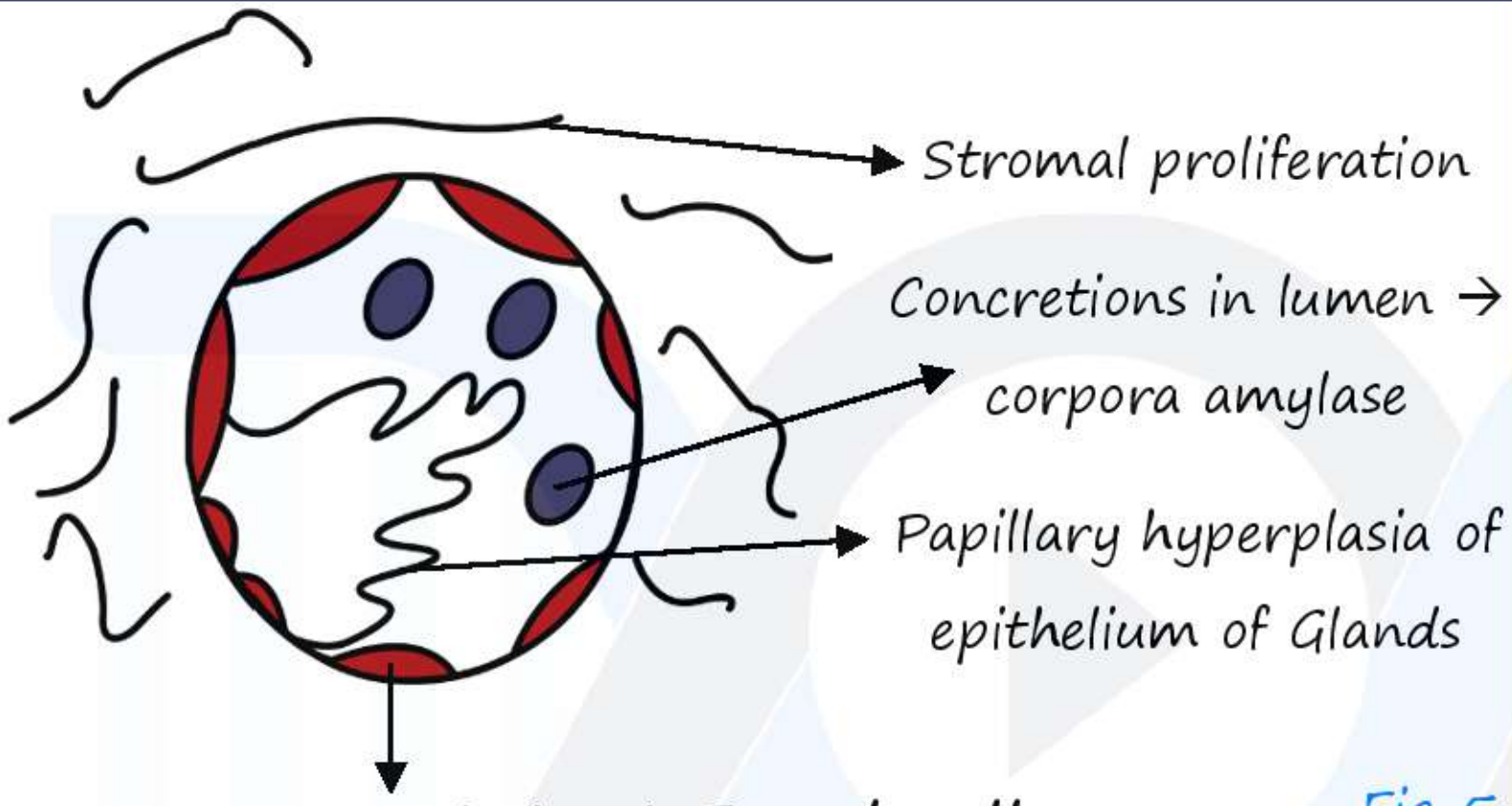

Fig 5

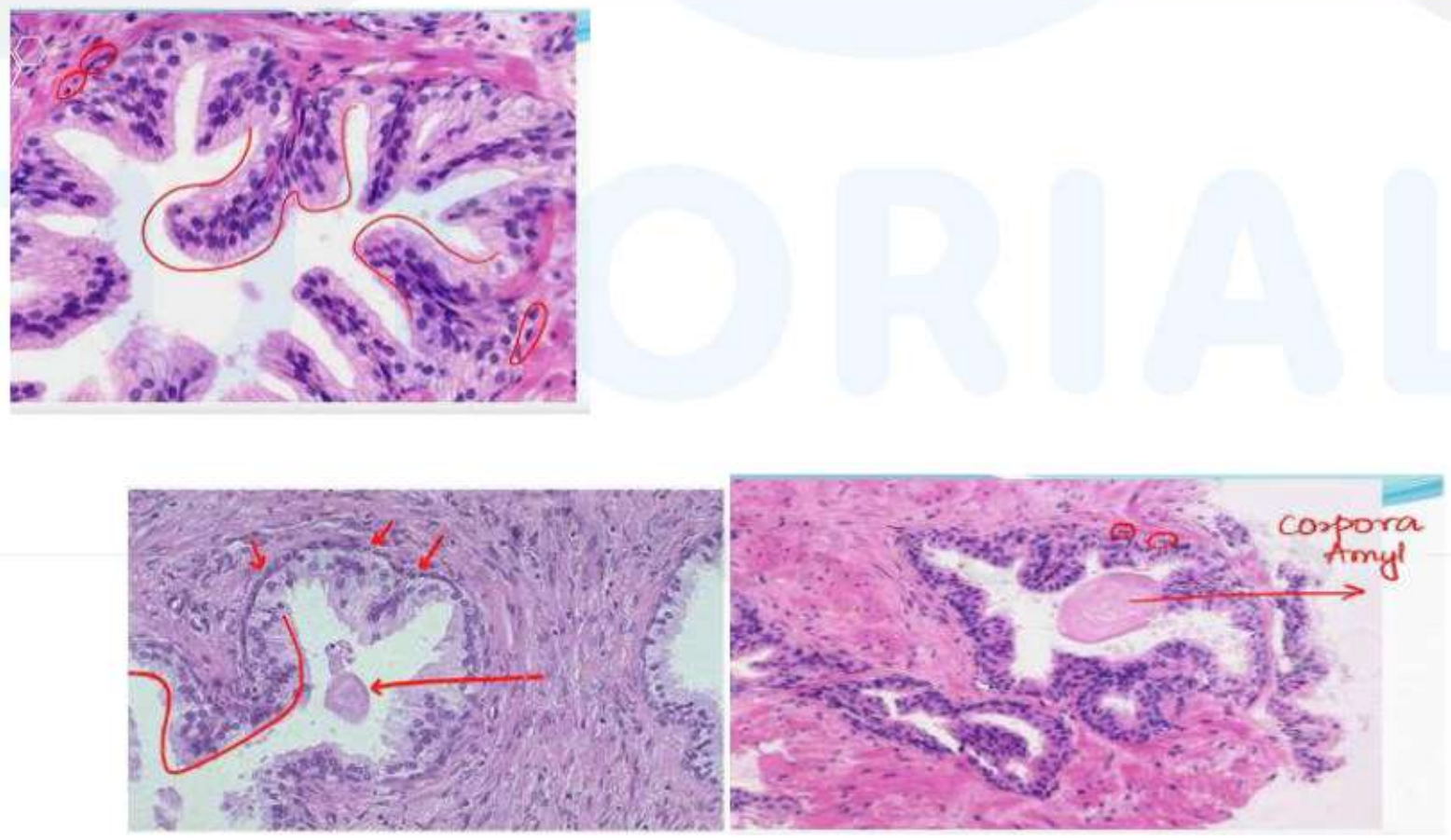

Corpora Amylase

Fig 6

IHC Markers of Basal cells

1. HMW-showing intact Basal cells.
2. P63

Prostatic Carcinoma. 00:12:00

- M/c cancer of males
- M/c cause of Bone secondaries

Risk factors

1. Advancing age & increased fat intake
2. M/c mutation seen in prostate ca = (40-60%): TMPRSS2- ETS (Androgen Receptor)

Characteristics

- M/C type is adenocarcinoma
- Origin peripheral zone of prostate
- show perineural invasion
- Metastasize through vertebral venous plexus forming osteoblastic secondary's
- Best screening protocol for Ca prostate = PSA+DRE
- PSA-Prostate specific Antigen
- DRE-Digital Rectal examination
- PSA is the single test with highest positive productive value for ca prostate

Remember: PSA is prostate specific not the cancer specific

AfraTafresh.com
TUTORIALS
LOGIN FOR SUCCESS

AfraTafreeh.com

Histology

- Increased number of Neoplastic Glands with
- Architectural atypia smaller, more crowded, lack branching & papillary infolding
- Prominent Nucleoli
- Diagnosis of Ca prostate is based on <u>absence of Basal cell layer</u>

Gleason score and grading system

- Gleason score – M/C used Histological Grading system for prostate cancer

Histological patterns of prostate Cancer

Pattern 1

2

Predominant patterns:

3 → closely packed Glands invading into Normal Glands.

4 → Hypernephroid pattern (clear cells) or cribriform pattern

5 → Glands show Comedo Necrosis signet cell Pattern & arranged in sheets

Primary pattern → most commonly observed pattern

Secondary pattern → second M/C observed pattern

Gleason score: sum of the 2 patterns. Also known as Gleason sum.

i.e.: <u>Gleason score = Primary pattern + Secondary pattern</u>

Rules

1. If any pattern expression is <3% → Ignore it

2. If the entire specimen has only a pattern, then the Primary pattern is doubled.
3. If Glands show perineural Invasion → ignore it.

Gleason score 00:18:00

- Gleason score – Gleason Grade

1°	+	2°		
3	+	3	= 6	→ 1
3	+	4	= 7	→ 2
4	+	3	= 7	→ 3 → (more aggressive than 3+4)
4	+	4	= 8	→ 4
5	+	4	= 9	⎤
5	+	5	=10	⎦ → 5 → (Worst prognosis)

(So, Gleason Grade Ranges from 1 to 5
Gleason score Ranger from 6 to 10)

AfraTafreeh.com

- Gleason score is used to help evaluate the prognosis of men with prostate cancer.
- In patient with Gleason score 7,

Gleason 4+3 is more aggressive than Gleason 3+4
(Grade 3) (Grade 2)

Recent updates in prostatic carcinoma

IHC	Tumor markers
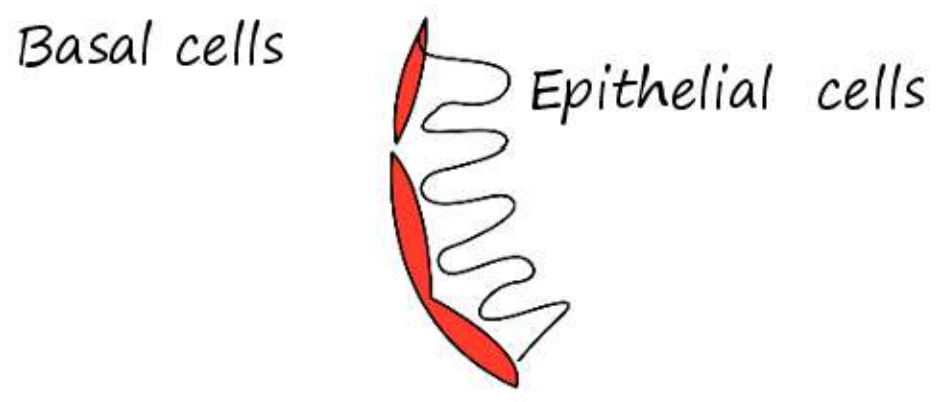	1. PSA 2. NK x 3.1

AfraTafreeh.com

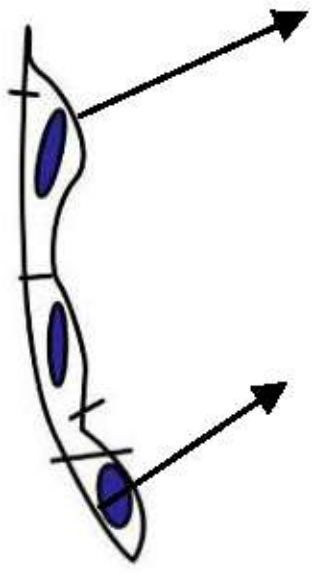

Malignant epithelial cells positive for AMCR (α- Methyl acetyl Co-A Racemase)

Loss of basal cells

Loss 1) HMW-CK

2) P63

COCKTAIL of prostate Ca

AMCR ⊕

HMV-CK ⊖

P63 ⊖z

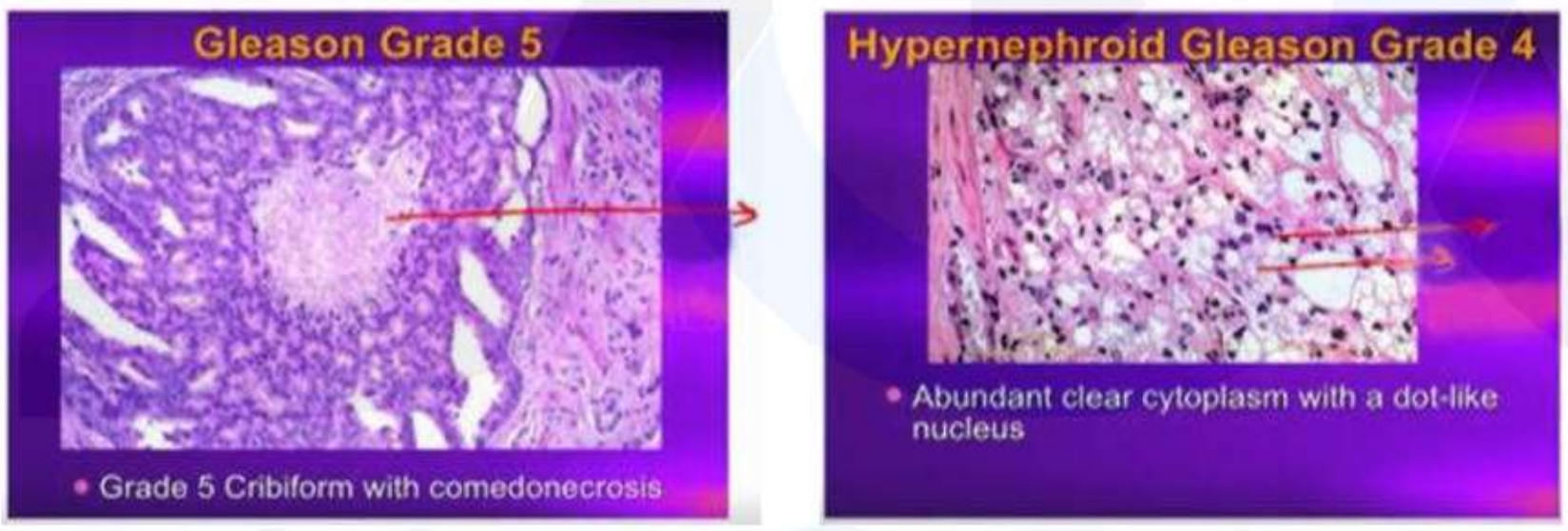

Gleason grade 5 Showing comedo Necrosis

Gleason grade 4

Fig 7

Mutations in prostate cancer

- M/C mutation (40-60%)-TMPRSS2 –ETS
- PTEN Mutation [p13k]
- BRCA2
- HOXB13 change → Hyper methylation of Glutathione Transferase (GSTP-1) gene on chromosome 11

New Biomarker of prostate cancer

PCA3 in urine

Granulomatous prostatitis

Cause =BCG injection intravesically for Bladder cancer.

AfraTafreeh.com
TUTORIALS
LOGIN FOR SUCCESS

AfraTafreeh.com

APPROACH TO JAUNDICE

Bilirubin metabolism

RBC'S break down
↓
Hb products
↓
Heme
Heme oxygenase → ↓
Biliverdin
↓ ← Biliverdin reductase
Bilirubin

- Bilirubin combines with albumin & transported to liver
- Bilirubin with the help of OATP (organic anion transport proteins) enters into space of disse from, sinusoids
- Glutathione S transferase prevents bilirubin to move out of sinusoids
- Bilirubin enters hepatocytes and undergoes glucoside conjugate

Bilirubin
↓ UDP glucuronyl transferase enzyme
Bili diglucuronide (80%)
Bili monoglyceride (320%)

- Conjugated bilirubin enters bile ductules from hepatocytes by ATP dependent MRP2 (multidrug resistant protein – 2)
- Conjugated bilirubin enters colon & beta glucoronidase bacteria breaks down and form unconjugated bilirubin
- unconjugated hydrogenation (44h) forms urobilinogen & (48h) forms stercobilinogen – 80% of this excreted in stools get 20% is resolved and enters hepatic circulation
- 2-5% of bilirubin from enterohepatic circulation enters plasma & excreted via kidney and undergoes oxidation to form urobilin which gives yellow colour to urine
- 2-5%uroblinogen excreted in urine is normal individuals

If MRP2 blocked, conjugated bilirubin can enter plasma through MRP3 occurs in obstruction

AfraTafreeh.com TUTORIALS LOGIN FOR SUCCESS

Four bilirubin fraction have been isolated from serum 00:17:45

- Unconjugated bilirubin – alpha bilirubin
- Monoconjugated bilirubin beta bilirubin
- Di conjugated bilirubin – gamma bilirubin

AfraTafreeh.com

- A fraction irreversibly bound to protein bilirubin - (delta) bilirubin – half life is more due to albumin which it is bound (albumin t ½ life of 20days)

Bile acids 00:22:00

- primary bite acids -> cholic acid and chenodeoxycholic acid

Primary bile salts

- 2/ 3rd of bile in primary bile salts
- Conjugation of bile acids with taurine / glycine
- Solubilize water insoluble lipids secreted by hepatocyte
- When these bile salts are secreted into the lumen of intestine bacteria.
- Partial dehydroxylation & removal of the glycine & taurine groups form the secondary bile acids, deoxycholic acid & lithocholic acids
- Cholic acids converted into deoxycholic acid
- Chenodeoxycholic acid converted into lithocholic acid

Composition of bile 00:25:14

- Bile salts (conjugated bile acids)
- Bilirubin

- Cholesterol
- Electrolytes
- Water

Jaundice classification 00:25:58

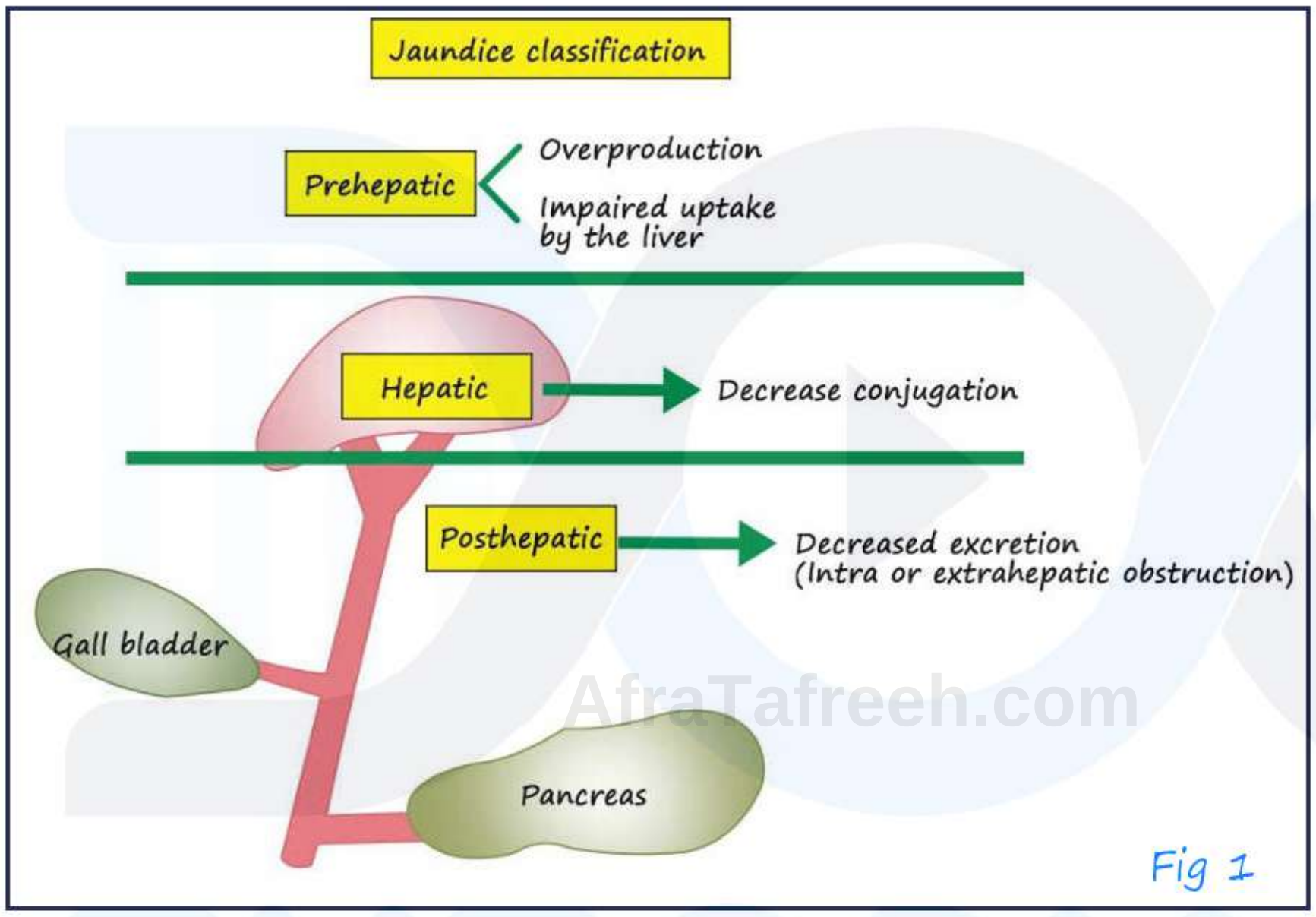

Fig 1

I. Pre hepatic jaundice
    - Over production
    - Impaired uptake by the liver

II. Hepatic
    - Decrease conjugation

III. Post hepatic
    - Decreased excretion (intra or extrahepatic obstruction)

AfraTafreeh.com

- Total Normal bilirubin level - 0.3 – 1.2 mg/dl, van der berg reaction
- Direct bilirubin (conjugated) – 20% of total bilirubin
- Indirect bilirubin - 80% of total bilirubin (Unconjugated bilirubin) – direct bilirubin
- Increased bilirubin - > 2 mg/ dl
- Unconjugated hyperbilirubinemia – unconjugated bilirubin is > 85%

  - Direct bilirubin < 15%
- Conjugated hyperbilirubinemia – direct bilirubin > 50%
- Mixed hyperbilirubinemia – direct bilirubin 20-50%
- Pre-hepatic - conjugated < 20% bilirubin (direct bilirubin)
- Hepatic – direct bilirubin 20-50%
- Post hepatic – direct bilirubin > 50%

LOGIN FOR SUCCESS

Causes of hyperbilirubinemia 00:32:05

- Hemolytic anemia
- Ineffective erythropoiesis
- Hematoma

(Hemolytic anemia, Ineffective erythropoiesis, Hematoma – RBC damage)

- Drugs

- Newborns
- Crigler najjar II | Decreased UGT (UDP – Glucuronosyltransferase
  Gilbert Syndrome
- Crigler najjar II – auto normal dominant with variable penetrance
- Crigler najjar I – absent UGT
- Breast milk - beta glucuronidase causes unconjugation

Newborn jaundice 00:39:24

i. Physiological jaundice
   - Low activity of UGT in liver jaundice occur in 3-4 days after birth

AfraTafreeh.com

ii. Breast milk jaundice
   - Due to beta glucoronidase in breast milk conjugation of bilirubin

TUTORIALS LOGIN FOR SUCCESS

iii. Pathological jaundice
   - Occurs in first 24 hrs of life

Hereditary Hyperbilirunemia				
Disorder	inheritance	defects in bilirubin metabolism	live patholo gy	clinical course
Unconjugated hyperbilirubinemia				

AfraTafreeh.com

Crigler-nijjar syndrome type I	autosomal recessive	Absent UGT1A1 activity	None	fatal in neonatal period
Crigler-nijjar syndrome type II	autosomal dominant with variable penetrance	Decreased UGT1A1 activity	None	generally mild, occasional kemicterus
Gilbert syndrome	autosomal recessive	Decreased UGT1A1 activity	None	innocuous
Conjugated hyperbilirubinemia				
Dubin johnson syndrome	autosomal recessive	impaired biliary excretion of bilirubin glucuronides due to mutation in canalicular multidrug resistance protein 2 (MRP2)	pigmented cytoplasmic globules	innocuous
Rotor syndrome	autosomal recessive	decreased hepatic uptake and storage?	None	innocuous

TUTORIALS LOGIN FOR SUCCESS

		decreased biliary excretion?		

- **Crigler – Najjar syndrome type 1** – severe UGT1A1 deficiency and is fatal around the time of birth
- **Crigler – Najjar type II and Gilbert syndrome** there is some UGT1A1 activity
- **Neonatal jaundice** – 2 weeks of age, unconjugated hyperbilirubinemia, exacerbated by breastfeeding as a result of the presence of bilirubin-deconjugating enzymes

Causes of conjugated hyperbilirubinemia

00:42:52

- Obstruction
- Dubin Johnson syndrome
- Rotor syndrome

(Dubin Johnson syndrome, Rotor syndrome) — congenital conjugated hyper bilirubin

Dubin Johnson syndrome

- Defect of MRP-2 transported leads to stagnation of conjugated bilirubin converts into epinephrine metabolites which gives black color to liver

AfraTafreeh.com

****Dubin johnson syndrome- black live jaundice

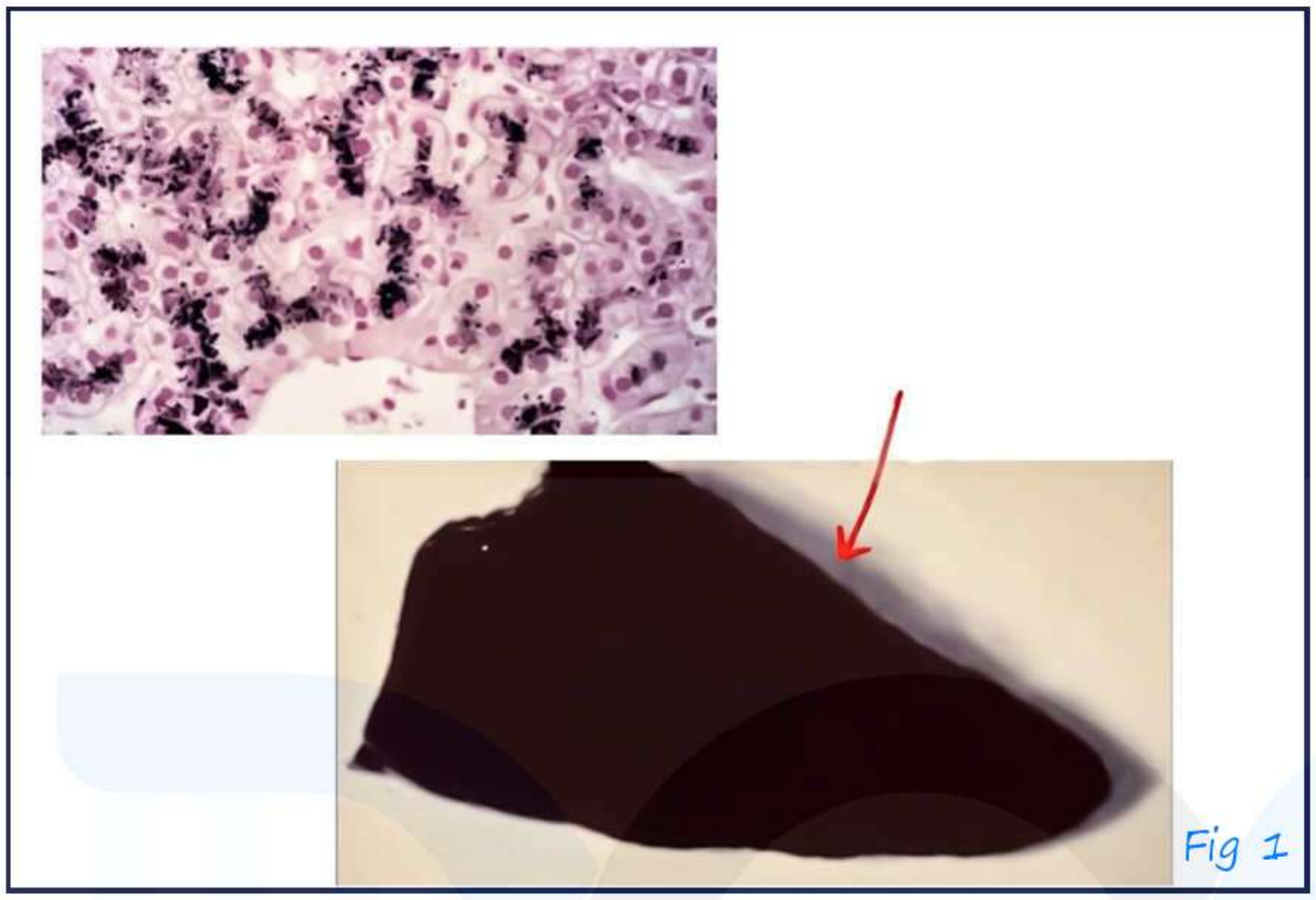

Fig 1

- Rotor syndrome -> execretion defect

TUTORIALS
LOGIN FOR SUCCESS

LIVER FUNCTION TESTS

- Group I Tests of Hepatic Excretory Function

i. Serum Bilirubin – Total, conjugated & un Conjugated

ii. Urine Bile Pigments, Bile Salts & urobilinogen.

Serum Bilirubin – Test Van den Bergh Reaction

- Urine Bile Salts – Hay's Test
- Urine Bilirubin – Fouche's Test
- Urine Urobilinogen – Ehrlich test
- Hay's Test – Sulphur powder added to sample of urine
- Principle – Normal urine, Sulphur powder floats on urine
- Urine Containing Bile Salts, surface tension of urine is decreased, Sulphur precipitates
- Causes of urine bile Salts – Obstructive Jaundice
- Urine Bilirubin – Fouchet's Reaction
- Urine Bilirubin seen in obstructive Jaundice
- Urine + BaCl2 → BaSo4 → Absolute bilirubin

↓ Filter

BaSo4 + Bilirubin filtration

↓

Add FeCl3 (Fouchet's Solution)

↓

AfraTafreeh.com
TUTORIALS
LOGIN FOR SUCCESS

AfraTafreeh.com

Bilirubin oxidized to Biliverdin

↓

Green blue Colour (PISTA GREEN COLOUR)

Urine Urobilinogen Testing 00:08:11

- Test Principle based on Ehrilich reaction
- It is seen in unconjugated hyperbilirubinemia
- Para dimethyl amino benzaldehyde - Ehrilich Reagent
- Test has to be done immediately & protect from sunlight
- Urine + Ehrlich reagent - Normal - Pink urine
- Increased - Red urobilinogen

Ehrlich's test: liver function tests based upon bile pigment metabolism

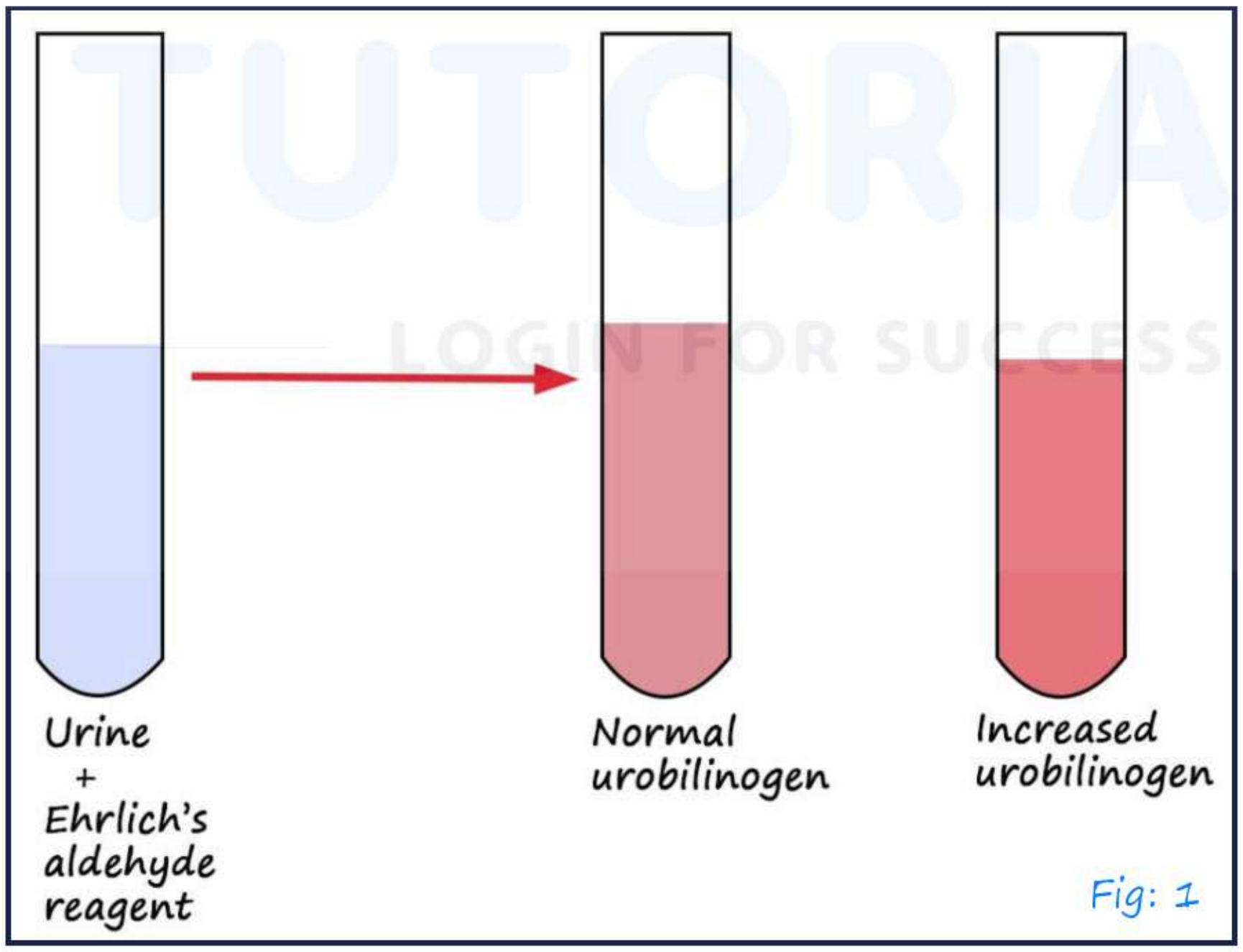

Fig: 1

Liver Function Test 00:12:44

Urine	Obstructive Jaundice	Hepatic Jaundice	Hemolytic Anemia
Urobilinogen	⊖	⊕	↑↑
Urine Bilirubin	⊕	⊕	⊖
Urine Bile Salts	⊕	⊕	⊖
Serum Bilirubin (Conjugated)	↑	↑	Normal
Serum Bilirubin (Unconjugated)	Ⓝ	↑	↑

AfraTafreeh.com
TUTORIALS
LOGIN FOR SUCCESS

Group II LET (Liver Enzyme Panel) 00:15:50

i. Alanine Amino Transferase (ALT / SGPT)
ii. Aspartate Amino Transferase (AST / SGOT)
iii. Alkaline Phosphatase (ALP)
iv. Gamma Glutamyl Transferase (GGT)

- AST & ALT – Produced by Hepatic Enzymes

AfraTafreeh.com

- AST – Also produced from muscle tissue (skeletal+ Cardiac
- ALT enzyme more specific than AST for liver damage
- Alkaline Phosphatase & Gamma Glutamyl Trans peptidase produced by canicular surface of Hepatocytes
- ALP – Also produced by Bone, intestine, placenta
  - Marker of obstructive Jaundice
  - GGT – Marker of obstructive Jaundice
  - Marker of Alcoholic Injury to liver
- Alcoholic Liver Disease AST to ALT ratio 2:1
- In all other liver injury ALT > AST

Group III. 00:22:15

- Plasma Proteins (synthetic Function)

i. Total Proteins

ii. Serum albumin, Globulins, A/G ratio

iii. Prothrombin Time

TUTORIALS LOGIN FOR SUCCESS

In Hepatic Cirrhosis 00:23:05

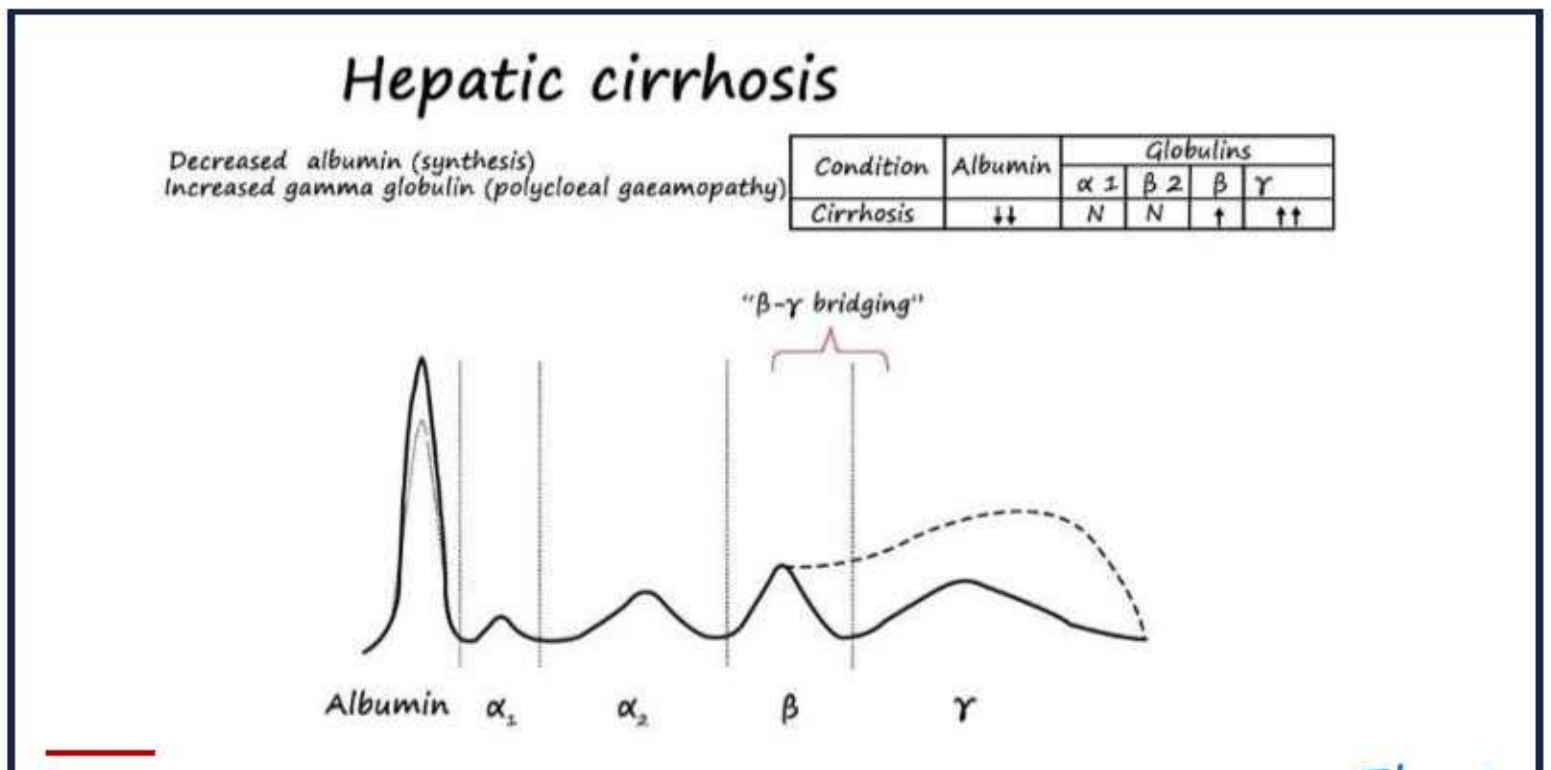

Fig: 2

- Serum electrophoresis
- Albumin – Decreased
- Beta Globulin – Increased
- Gamma Globulin – Increased
- Beta – Gamma bridging very typical of Cirrhosis

Group IV – Special Test

i. Serum ceruloplasmin

ii. Serum Ferritin

iii. Serum Alpha 1 antitrypsin

iv. Serum Alpha Fetoprotein

AfraTafreeh.com
TUTORIALS
LOGIN FOR SUCCESS

AfraTafreeh.com

NODULES OF LIVER

- High Regenerative capacity of Liver leads to Nodules Formation
- Cirrhosis of Liver - Nodules and Fibrosis
- Nodules in liver seen in

  i. Focal Nodular Hyperplasia

  ii. Nodular Regenerative Hyperplasia

  iii. Non-Cirrhotic liver

Focal Nodular Hyperplasia	Nodular Regenerative Hyperplasia
Cause: - Drugs	- Decrease blood flow to liver associated with portal hypertension
Pathogenesis	
- Fatty Change present	- This forms nodules without any fibrosis
- Never associated with Portal Hypertension	causes of NRH i. Bone Marrow Transplant ii. HIV Infection iii. Rheumatoid Arthritis iv. SLE v. Vasculitis vi. Drugs
- Nodule formation with a central scar, this central scar represents fibromuscular hyperplasia	
- From the central scar there is Radiating septa going to peripheral of nodule.	
- Ductular proliferation is present.	

Focal nodular hyperplasia showing lobulated contours & a central stellate scar
- Hypoperfused area – fibrous septa
- Hyperfused area - hyperplasia

Central gray-white depressed stellate scar from which fibrous septa radiate to the periphery.

Fig: 1

AfroTafreeh.com
TUTORIALS
LOGIN FOR SUCCESS

FNH, Gross

- Well – demarcated
- Poorly encapsulated nodule.
- Up to many centimeters in diameter
- Young to middle aged adults.
- Lighter to yellow than the surrounding liver indicating steatosis

- One should consider a diagnosis of NRH in all patients with clinical symptoms of portal hypertension (splenomegaly, oesophageal varices, ascites) but with normal transaminases and no manifestations of cirrhosis (gynecomastia, palmar erythema, spider nevi)

AfraTafreeh.com

CLASSIFICATION OF LIVER TUMORS

- Tumors
  - Child
    - Hepatoblastoma
  - Adults
    - Benign
      - Hepatic Adenoma
      - Cavernous Adenoma (Most common benign)
    - Malignant
      - Hepatocellular Carcinoma (Most common malignant)
      - Angiosarcoma
      - Cholangiocarcinoma 2nd most common

- Most Common tumor in liver where exposed to Vinyl Chloride – Angiosarcoma

Benign Adults Tumor 00:02:56

Cavernous Hemangioma

- Most common benign liver tumor cause – due to VHL mutation, tumor of blood vessel.

Characteristic Features Cavernous Hemangioma

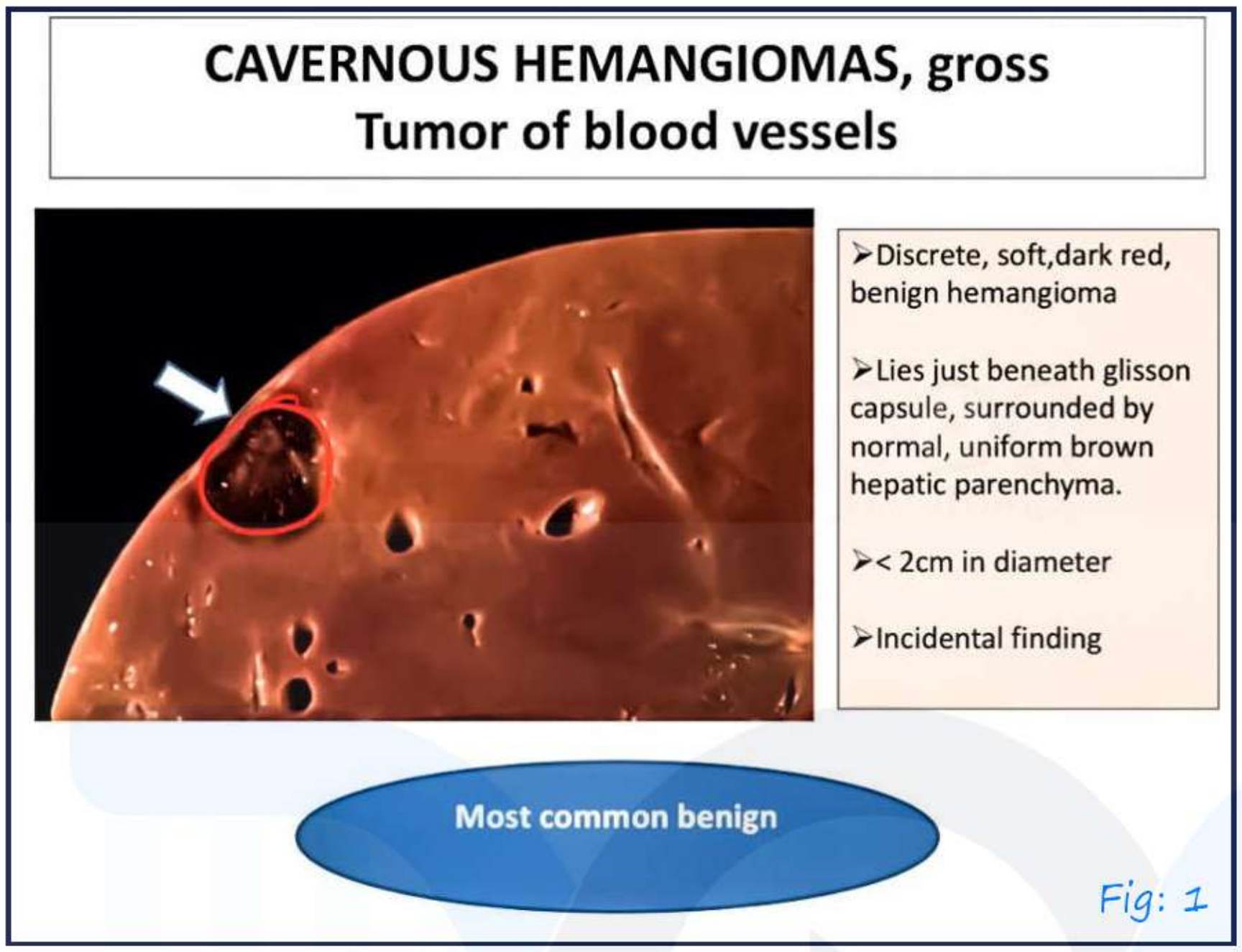

Fig: 1

- Tumor is present just below the Capsule
- Large Vascular Channels separated by **Fibrous Septa**
- Usually less than 2 cm in diameter
- Incidental Finding
- Closest Differential diagnosis of cavernous Hemangioma is Peliosis Hepatitis

Peliosis Hepatitis 00:05:56

- Abnormal Sinusoidal dilatation of Hepatic Sinuses
- Blood filled lakes seen on Microscopy
- Absence of Fibrous septae
- **Cause**: – Oral Contraceptive
  - Anabolic Steroids
  - Danazol

AfraTafreeh.com

Causes of Peliosis Hepatitis

- HIV Infection
- Bartonella infection

- Bartonella Infection causes spindle proliferation & Blood Lakes
- Bartonella Infection is seen by Warthin starry stain
- Bartonella Infection of liver - Bacillary Peliosis

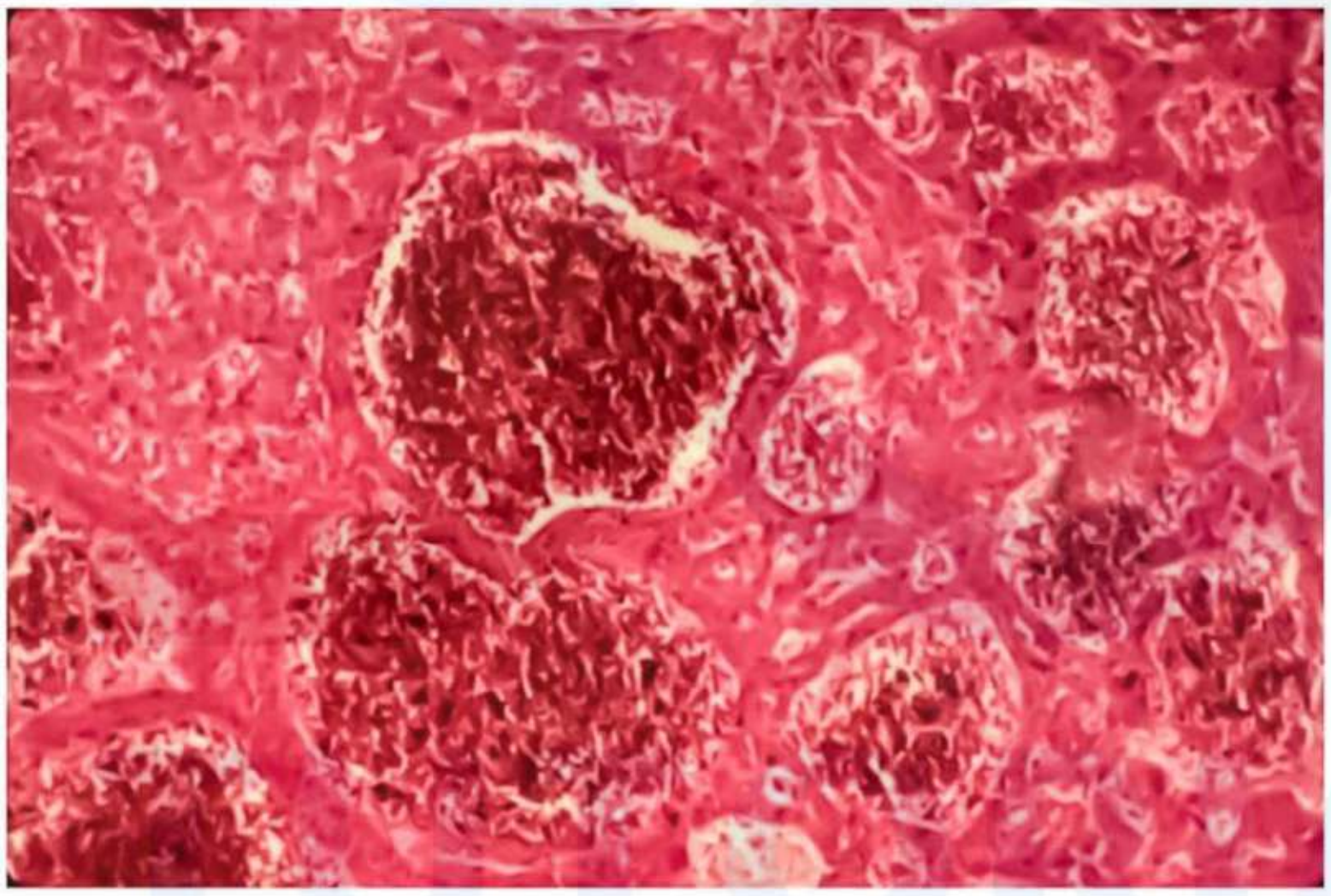

Fig: 2

LOGIN FOR SUCCESS

HEPATIC ADENOMA

- Important for AIIMS & JIPMER EXAM
- BORDEAUX Classification of Hepatic Adenoma
  i. HNF alpha inactivate Hepatic Adenoma
  ii. Beta catenin Adenoma
  iii. Inflammatory Adenomas

i. HNF 1alpha inactivated Hepatic Adenoma

00:03:28

- Occurs in Women taking oral contraceptive pills

AfraTafreeh.com

Pathogenesis

- HNF 1 alpha leads to activation of liver fatty acid binding protein found in Normal Liver
- OCP Pills block HNF 1 alpha and reduce the activation of liver fatty acid binding protein (LFABP)
- Absence of LFABP on immunohistochemistry indicated HNF 1 alpha inactivated hepatic Adenoma
- This Adenoma has less chance of turning malignant

AfraTafreeh.com

ii. Beta Catenin Associated Adenoma 00:07:06

- Beta Catenin Gene forms Glutamate Synthetase enzyme
- Glutamate Synthase enzyme present in perivenular location
- In Beta catenin Adenoma – Beta Catenin undergoes point mutation; Beta catenin mutation leads to excessive proliferative by continuously triggering transcription factor.
- This Adenoma has high chance of turning malignant
- **Immunohistochemistry**
- Normal Hepatocyte – Beta Catenin present in Cytoplasm
- Adenoma - Beta Catenin present in nucleus
- Norma Hepatocyte - Glutamate Synthase present in Perivenular Hepatocytes
- Adenoma - Glutamate Synthase present in all Hepatocytes

iii. Inflammatory Adenoma 00:19:03

- Occurs in NAFLD
- Interleukin-6 stimulate & release Acute Phase reactant in Normal individual
- In NAFLD – There is persistent inflammation, gp130 subunit of IL-6 receptor undergoes mutation which

leads to persistent activation IL-6 receptor without presence of interleukin-6

- IL-6 receptor mutation activates acute phase reaction and excess hepatic proliferation.
- Inflammatory adenoma can turn malignant

> Turns Malignant order
> - Beta Catenin Adenoma – Maximum Inflammatory Adenoma
> - HNF alpha adenoma - Least

Microscopic Features of Adenoma 00:25:35

- Increased Thickness of Hepatic Plates

ii. <u>HNF-1alpha inactivated Adenoma</u>

- Fatty change without Atypia
- Negative LFABP – IHC
- No need to be removed.

iii. <u>Beta Catenin Adenoma</u>

- Marked Atypia and should be excised
- Beta Catenin in nucleus of cells → IHC
- Glutamate Synthase present in all hepatic Cells. ↗ (IHC)

iv. <u>Inflammatory Adenoma</u>

- Ductular Reaction
- Inflammation
- Dilated Vessels
- CRP positive – IHC and should be excised.
- 10% of inflammatory Adenoma associated with Beta Catenin Adenoma

AfraTafreeh.com

AfraTafreeh.com

HEPATIC MALIGNANCY

- Most common Malignant tumor - HCC
- 2nd most common malignant tumor - Cholangiocarcinoma

I. Hepatocellular Carcinoma 00:01:26

Causes

i. Genetic - 60% cases – P^{53} gene

- 40% - Beta Catenin

ii. Acquired -

A. Viruses

a. HBV – Trans activates viral & host genes HBX

b. HCV - NS5alpha

- HBV & HCV causes mass destruction of liver which leads to marked regeneration leading to malignancy

B. Toxins

a. Alcohol - Cirrhosis

b. Aflatoxin - Mutation of codon 249 of P^{53}

C. Metabolic conditions

a. Hemochromatosis

b. Wilson's

c. Alpha 1 antitrypsin deficiency

d. tyrosinemia

e. NASH

- Precursor condition of Hepatocellular malignancy

  i. Hepatic Adenoma

    a. Beta Catenin adenoma

    b. Inflammatory Adenoma

  ii. Dysplastic Nodules-

    a. Low grade

    b. High Grade

  iii. Large cell change

  iv. Small cell change

Dysplastic Nodules

Low Grade Nodules	High Grade Nodules
• Dual Blood Supply (portal vein & hepatic artery)	• Predominant blood supply is Hepatic Artery
• Very less Dysplasia	• Nodule in Nodule appearance (seen in HCV)
• Lower risk of Malignancy	• Nuclear & Architectural dysplasia
	• High risk of Malignancy

AfraTafreeh.com
DOC TUTORIALS
LOGIN FOR SUCCESS

AfraTafreeh.com

ii. Large Cell Change 00:13:21

- Hepatocytes around portal tract become large, and show irregular nuclei
- It turns into malignancy in HBV infected individuals

iii. Small Cell Change 00:14:47

- Hepatocytes turn smaller in size with Hyperchromatic nuclei

Gross Morphology of HCC 00:16:01

i. It can be unifocal, multifocal or infiltrating
ii. It gives rise to satellite nodules

Microscopic Appearance 00:16:56

i. Thickened Hepatic Plates
ii. Prominent nuclei
iii. Tumor giant cells present
iv. Pseudo acinar pattern seen - malformed dilated bile canaliculi spread of HCC it occurs by veins

Tumor Marker of HCC

- Alpha Fetoprotein Increased – hyaline globules.
- PIVKA increased (Proteins induced by Vitamin K Absence)

Immunohistochemistry 00:20:39

- Hep – Par I – Present in all hepatic cell molecule / marker
- Glypican 3 Marker - Present in only malignant Hepatic cells

– Variant of HCC – Fibrolamellar Carcinoma

Classical HCC	Fibrolamellar Carcinoma
Right Lobes	Left lobe
Elderly	Young population
Male > Female	Female = Male
Preexisting lesions Cirrhosis	–
Spread via veins	Spread via Lymphatics
–	Microscopic – Abundant pink cytoplasm cell called Oncocytes which are separated by Fibrosis
Alpha Fetoprotein Marker	Neurotensin Marker

AfraTafreeh.com
TUTORIALS LOGIN FOR SUCCESS

AfraTafreeh.com

- Genes involved in Fibrolamellar carcinoma is DNAJB-1 and PRKACA gene
- Fibrolamellar carcinoma grossly appears cirrhosis tumor with Fibrous bands.

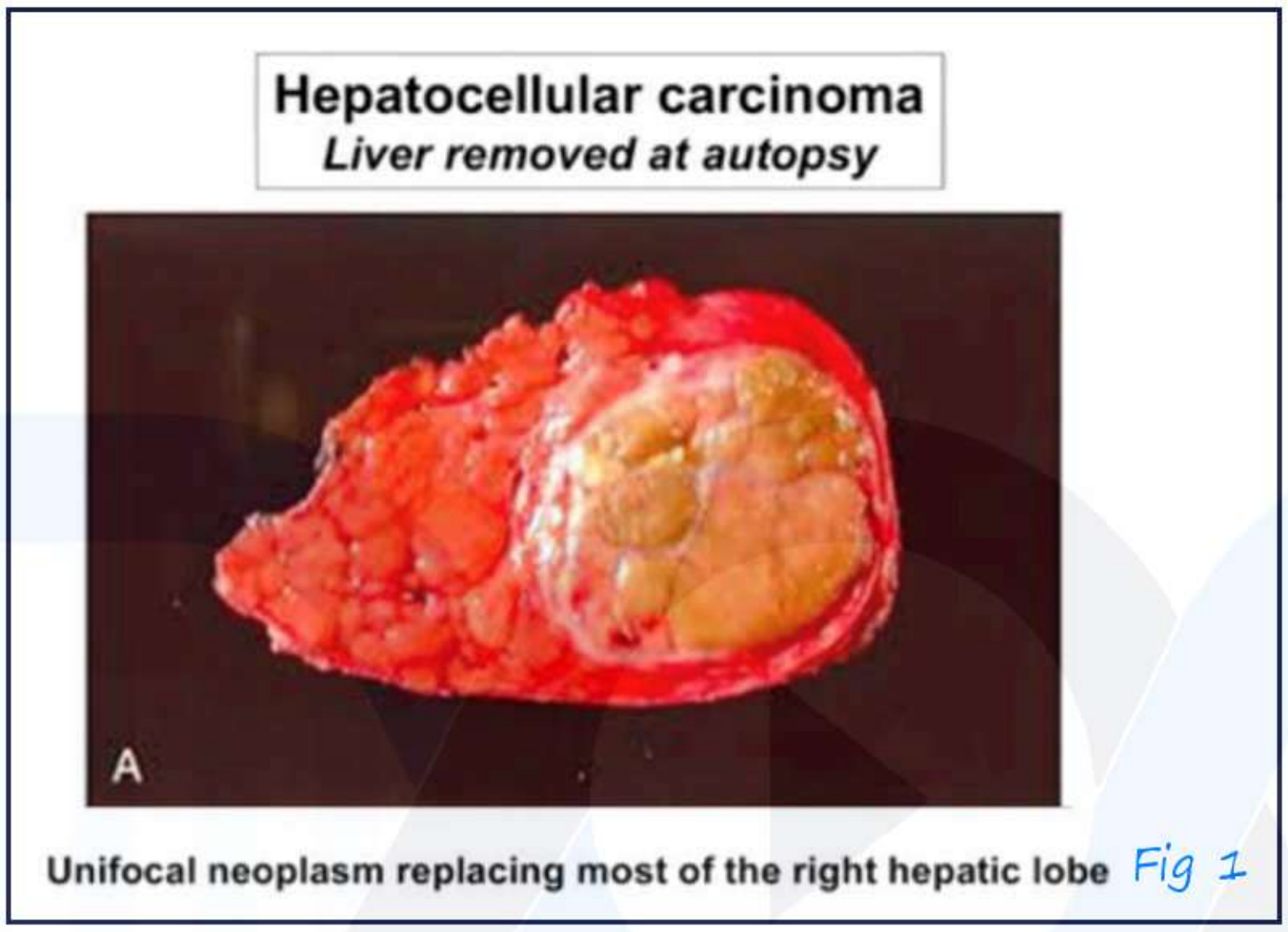

Fig 1

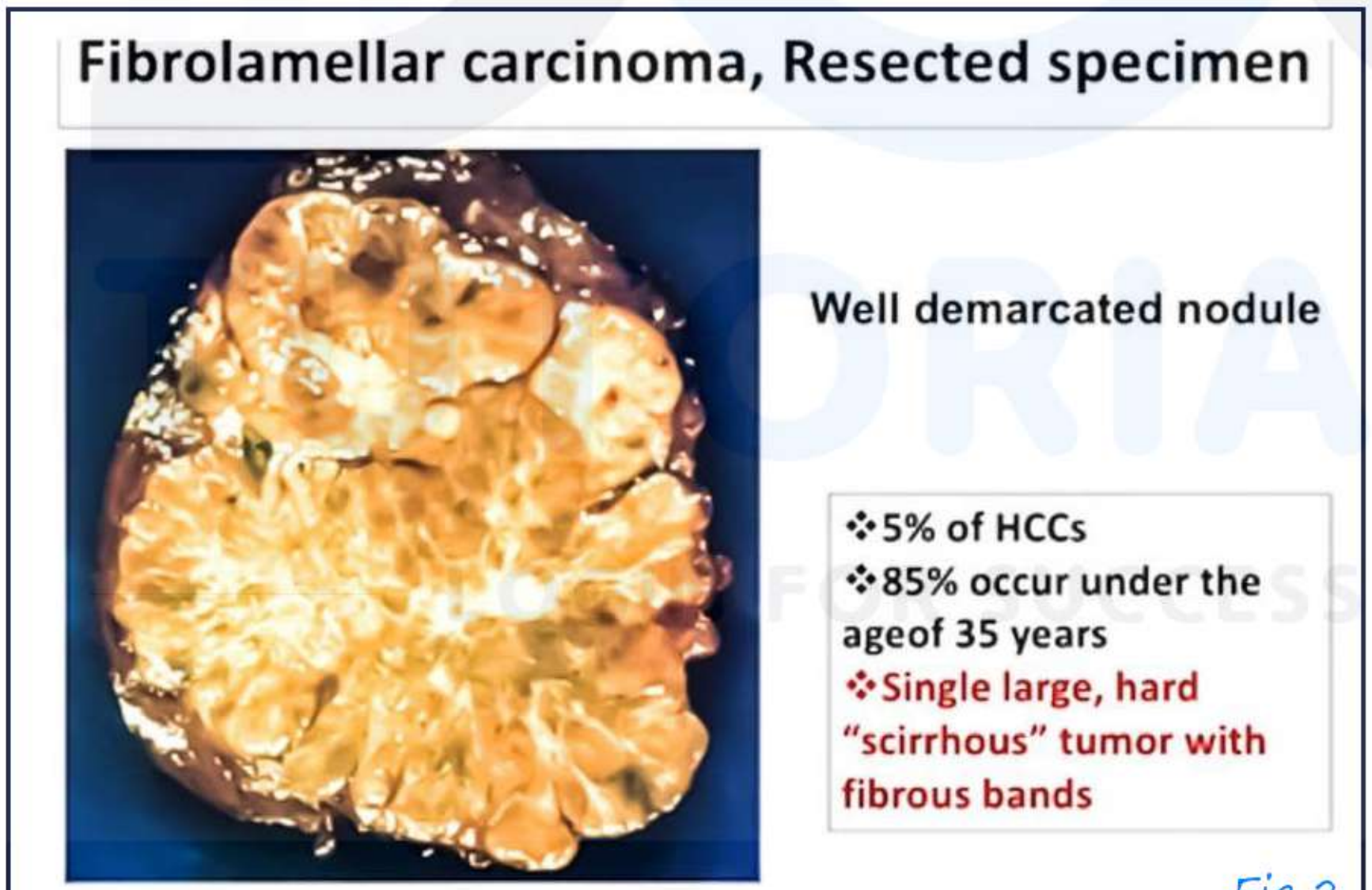

Fig 2

- Endothelial wrapping around tumour cell suggestive of primary HCC.

New Updates in HCC

- PCEA (polyclonal CEA) marker - Positive in HCC – seen in canaliculi
- Arginase - Positive in HCC

AfraTafreeh.com
TUTORIALS
LOGIN FOR SUCCESS

AfraTafreeh.com

CHOLANGIOCARCINOMA ANGIOSARCOMA, METASTASIS & HEPATOBLASTOMA

Cholangiocarcinoma 00:00:30

- 2nd most common maligned tumor of liver
  i. Genetic – KRAS gene mutation
  ii. Somatic causers
- Choledochal cyst
- Choledo cholithiasis
- Clonorchis
- HCV
- Thorotrast
- Fibropolycystic disease of liver site
- 80-90% of Cholangiocarcinoma -> extrahepatic
  Klatskin tumor – Cholangiocarcinoma at function of right & left hepatic ducts

Features of Cholangiocarcinoma 00:02:06

- Bile duct proliferation
- Extensive desmoplasia
- Perineural invasion of tumor cells
- Tumor cells are positive for CK7
- Glandular proliferation
- Lack of bile staining by the tumor nodules

Angiosarcoma 00:03:25

- Sites – skin, liver, breast
- Risk factor – thorotrast explosive
- Pathogenesis / features of angiosarcoma
- Abnormal endothelial cells
- Positive for CD34, CD31, von willi brand factor+

Metastasis to liver 00:04:42

- Most common primary tumor colon metastasis to liver features
- Multiple metastasis
- Central umblication of metastatic nodules.

AfraTafreeh.com

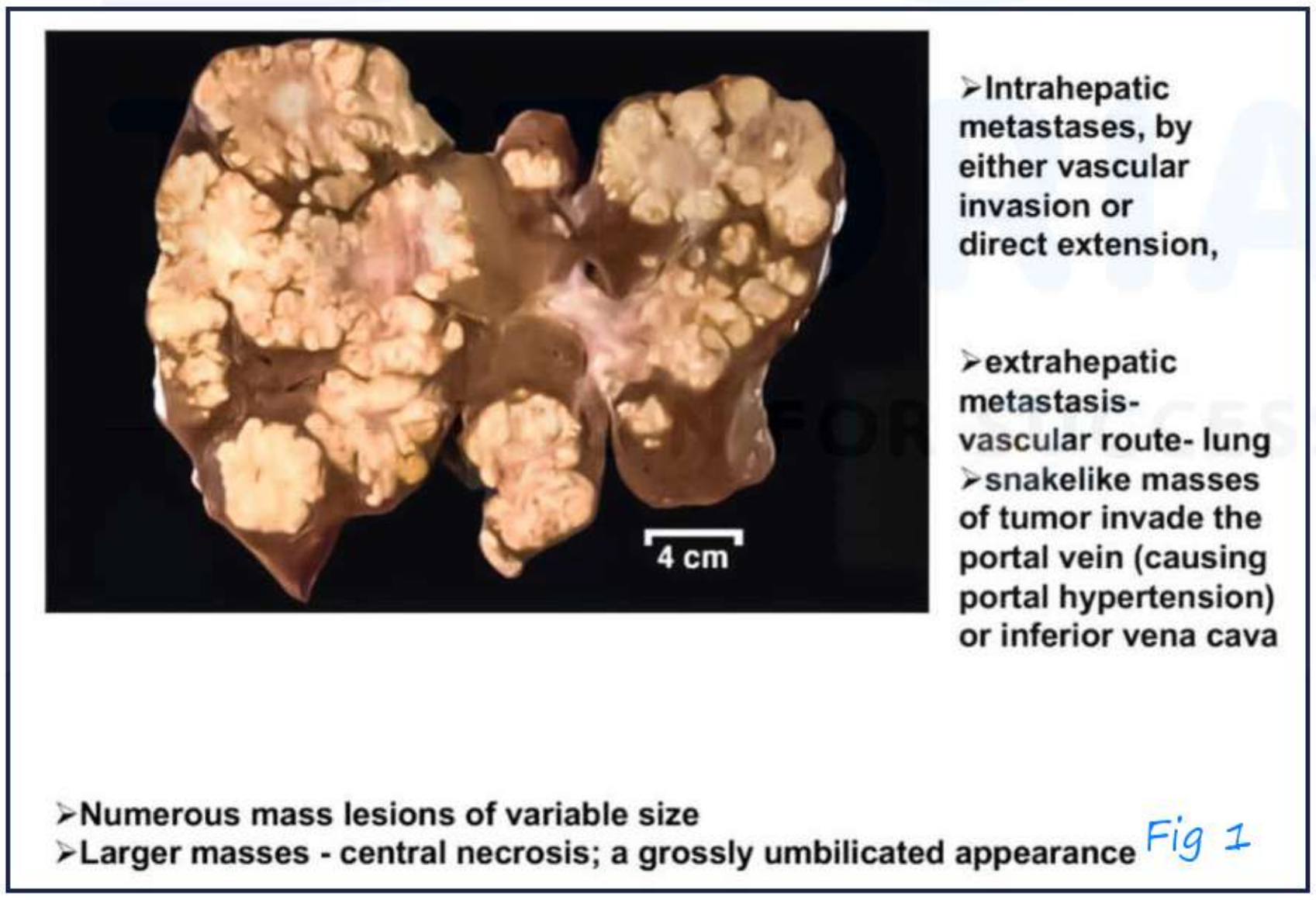

Fig 1

AfraTafreeh.com

CHOLANGIOCARCINOMA

➢White mass with a few satellite nodules
➢Lack of bile staining

Fig 2

Hepatoblastoma 00:07:39

- Tumor common in children less than 3yrs

  *** Typical mutation of hepatoblastoma tumor is FOX G1

  *** High yield box

  FOX G1 – hepatoblastoma

  FOX L2 – granulosa cell tumor of ovary

  FOX P3 – T regularly cell

Syndromes associated with hepatoblastoma

- Beckwith wilderman syndrome
- APC mutation associated with hepatoblastoma

Microscopy of hepatoblastoma 00:10:10

i. Epithelial type

- Fetal cells
- Embryonal cells

ii. Mixed

- epithelial and mesenchymal components
- Extramedullary hematopoiesis is seen in hepatoblastoma
- Tumor marker of hepatoblastoma is alpha feto protein
- Treatment of hepatoblastoma - Resection of tumor

AfraTafreeh.com
TUTORIALS
LOGIN FOR SUCCESS

AfraTafreeh.com

CSF EXAMINATION

Cerebrospinal fluid:

- Clear colourless, almost protein free filtrate (Transudale) of Blood. It is present
i. Around the Brain (in Subarachoid spaces) and inside the brain (in its ventricles)
ii. Around the spinal cord (in subarachoid space) and inside the spinal cord (in its central Canal)
- Formation: Major Source - Choroidal Plexus of all 4 ventricles mainly lateral ventricles
- Other sources - Ependymal cells of the ventricles and the brain itself via perivascular spaces.
- Total volume - 125-150 ml
- Rate of formation - 500-550 ml/day
- Replaced 3-4 times every day

Circulation of CSF

→

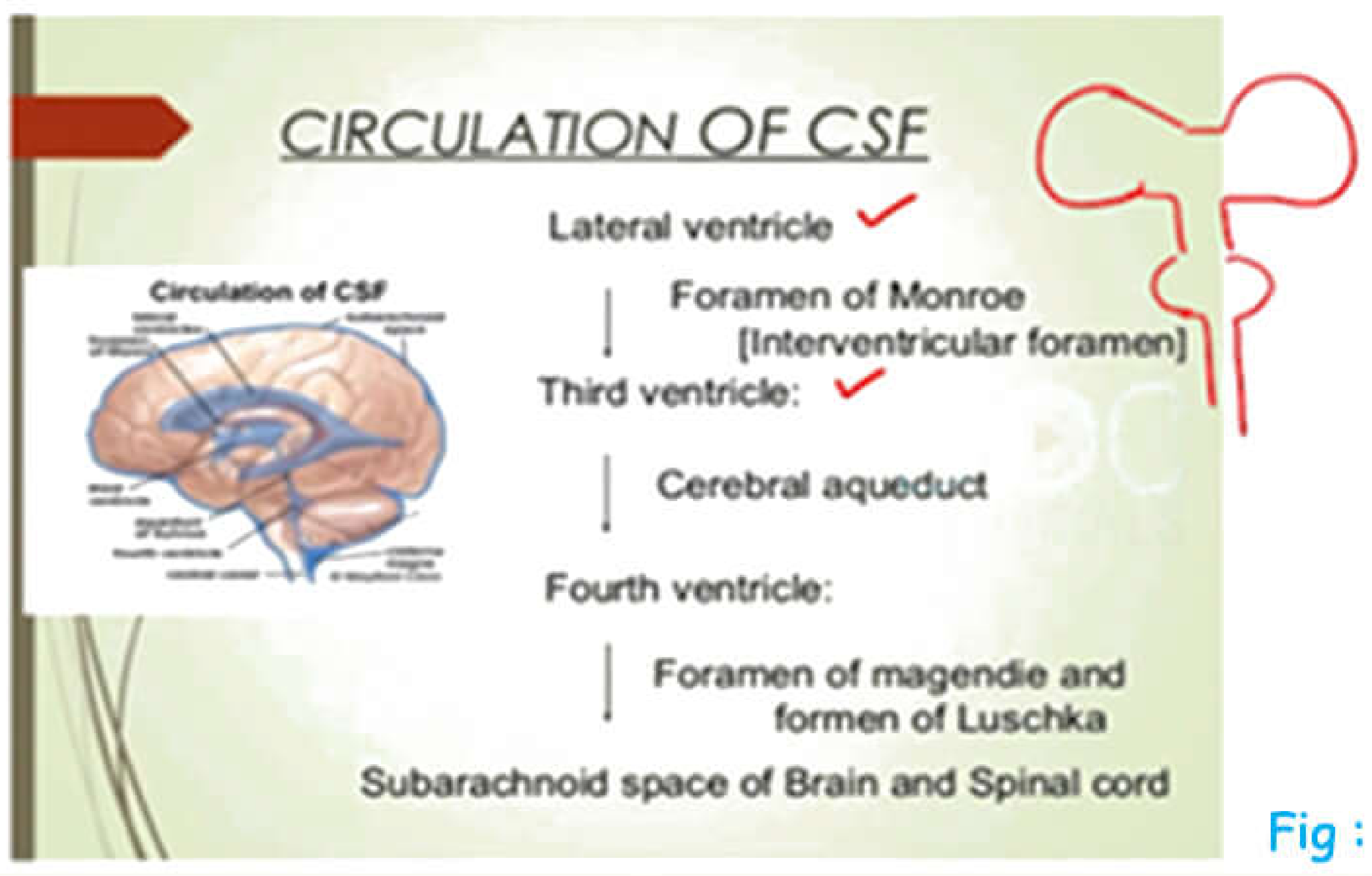

Fig : 1

Applied Pathology

- Stenosis of Cerebral Aqueduct → Enlargement of third ventricles
- Posterior Fossa,ie fourth ventrice volume decreases
- Dandy - Walker Syndrome - Cystic dilatation of 4th Ventrilen

↓

Posterior Fossa volume

↓

Atrophy of cerebellar Vermis

Characteristics of CSF

- Clear Transparent fluid
- Specific gravity - 1:004-1.007
- Reaction - Alkaline & does not coagulate
- Cells: Adults 0-5 cells / cumm (Lymphocytes predominat)
- Infants – 0-30 cells cumm (Manocytes predominant)
- ↑ in cells of CSF is called Pleocytosis These are No Neutrophils in BSF. B2 Transferrin is only found in CSF
- Hence it is a specific marker for CSF
- Pressure - 60-180 mm of H20 (adult)
  10-100 mm of 1120 (newborn)

Composition of CSF

- Proteins -15-45 mg / dl
- Glucose - 45-80 mg / dl
- CSF = Glucose = 2/3 is blood glucose
- Na^+ = 147 meg / L ↑
- Chloride = 120-130 meq / L ↑
  (ve+ & cl are higher in CSF . While Calcium is lower)
- Calcium = 2.3 meq / dl ↓q
- Bilirubin = Absent

Procedure of CSF Examination

- Lumbar Puncture sit L3-L4 interspace in adults. Never at or above L_1. Since Spinal Cord terminates at L 1
- Approximately 10-20 ml CSF collected and separated into 3 Tubes
- 1st Tube Biochemical investigation
- 2nd Tube Microbiological investigation
- 3rd Tube Cell count & for Hematological parameters
- Reason : Cell Counting by the last tube to see clear Traumatic Taps morphology of cells without any alteration by Blood as in
- 4th Tube : For Additional tests & Molecular Tests

Cell Counting of CSF Using Neubauer's Chamber

- Sample in Tube 3 in used
- No dilution of /CSF is usually required. A diluent is used only for CSF it cloudy and likely to contain increased number of leucocytes Diluent mostly used is Turks solution
  (Glacial acetic acid + Methylene Blue + Distilled water)
- Ratio of dilution in 1: 20 / ML CSF, 20 ML diluent
- Cells are counted in four WBC counting squares of neubauer's chambers
  Total count (per/mm3) ➢ no.of cells counted / no.of squares counted X 10

DOC TUTORIALS LOGIN FOR SUCCESS

- Nowadays cell counter machines are used called automated counters

GROSS EXAMINATION OF CSF

- Clear → normal or viral meningitis
- Turbid with increased miscounting ➔ pyogenic meningitis
- Colony formation ➔ tubercular meningitis
- Blood tinged ➔ traumatic puncture (clots seen)
- Xanthocrhromic ➔ seen in SAH, Jaundice (Xantho → yellowish)

yellowish red CSF → Centrifuge

- Clot of red cells → Traumatic tap
- Homogeneous → Xanthochromic CSF

Fig : 2


Xanthochromic

Fig : 3

Cobulet in TB meningitis

Microscopic examination of CSF

- Spread smears
- Cytospin smears (preferred)

Done in cytocentrifuses have special funnels which allow entry of only small amount of fluid. It concentrates the cell over a small button on the hide



Concentrated button

MICROSCOPIC FINDINGS OF CSF EXAMINATION

i. Predominantly neutropills → pyrogenic meningitis
ii. Lymphocytes → viral meningitis (inclusions in cmv meningitis) TB meningitis
iii. Cryptococcus → clear capsule - highlighted by
    i. india ink
    ii. mucicarmine

Soap bubble appearance on radiology / microbiology
↓
To be differentiated from 'glove powder'  Which appear very reflective

- M/C Presentation - diffuse meningo - encephalitis
- M/C Complication - central infarction
- Most Characteristic presentation - gelatinous basal exudates
  ↓
  Most characteristic of TB Meningitis (even on radiology)

DOC TUTORIALS LOGIN FOR SUCCESS

CSF Parameters in injections

Finding gross clear colourless	Bacterial meningitis yellowis, turbid	Viral meningitis clear colourless no clot	TB Colour coagulum (fibrian clots)	Fungal meanings Clear, colours
Pressure 60-180 mg of H_2O	↑	↑↑	↑↑↑	↑
Cells Lymphocytes 0-5/ml No neutropills	Neutropills ↑↑ (>500 pmn)	Lymphocytes ↑ (10-200)	Lymphocytes ↑↑↑↑ (200-500)	0-5 lympocytes Clusters of Cryptococcus in cryptocess meningitis
Glucose (45-80 mg %)	↓↓↓	Normal	↓	↓
Proteins (15-45 mg %)	↑↑	↑	↑↑	Normal
Chloride 120-130 mEg/L	↓ mild	Normal	↓↓↓ severe	Normal
	Pyrogenic meningitis So if proteins ↑↑↑ Glucose ↓↓↓	Viral meningitis ↑↑ Normal	TB Meningitis ↑↑↑ ↓	Fungal meningitis Normal ↓

- Remember : Normally as the cell count is CSF increases → the protein content also increases
- but, if cell count is normal & shall proteins are high. This implies albumino – cytological disassociation

  ↓

  Seen in

i. Guillian Barre syndrome
ii Intra cranial tumors
iii. late stage of polio

Causes of Meningitis :

- M/C/C of viral meningitis → enterovirus
- Causes of bacterial meningitis
- <3 month – group B streptococci ➢E. coli

  3 month – 10 years: streptococcus pneumonia ➢ H. Influenza

  10 years = 20 years → M/C/C neisseria ➢ Strepto pnuemoniae

  >20 years →Strep pneumonia ➢ listeria

AMOEBIC MENINGITIS

Naegleria Fowleri– free living amoebia	Acanthamoeba
Fresh warm waters	In immunocompromised people
Hot springs (heat loving – thermophilic amoebiae	Causes granulomatous amooebic Encephalitis (GAE)
H/O swmming	
Aka brain eating amoeba	Infection acquired by inhalation, ingestion or through Traumatised skin
Children & young adults commonly affected	Causes only encephalitis. Unlike Naegleria which causes menigo – Encephalitis
Invades nasal mucian & enters brain via affecting nerve	Acanthamoeba also causes chronic amoebia keratitis (CAM) in contact lens awareness
Causes – Necrotising meningo – encephalitis or primary amoebic meningoencephalitis	
Disease is usually fatal	

Diagnosis :

- Acanthamoeba

i. PAS Positive
ii. Calcoflour white stain – glistening white stain

  ↓

- Identifies budding of amoebia by binding to polysacharide groups of amoebia
- Also indicates the age of amoebia by the numbers of buddy

Fig : 4

Cysts of acanthamoeba



Fig : 5

PAS +VE acanthamoeba foamy cytoplasm

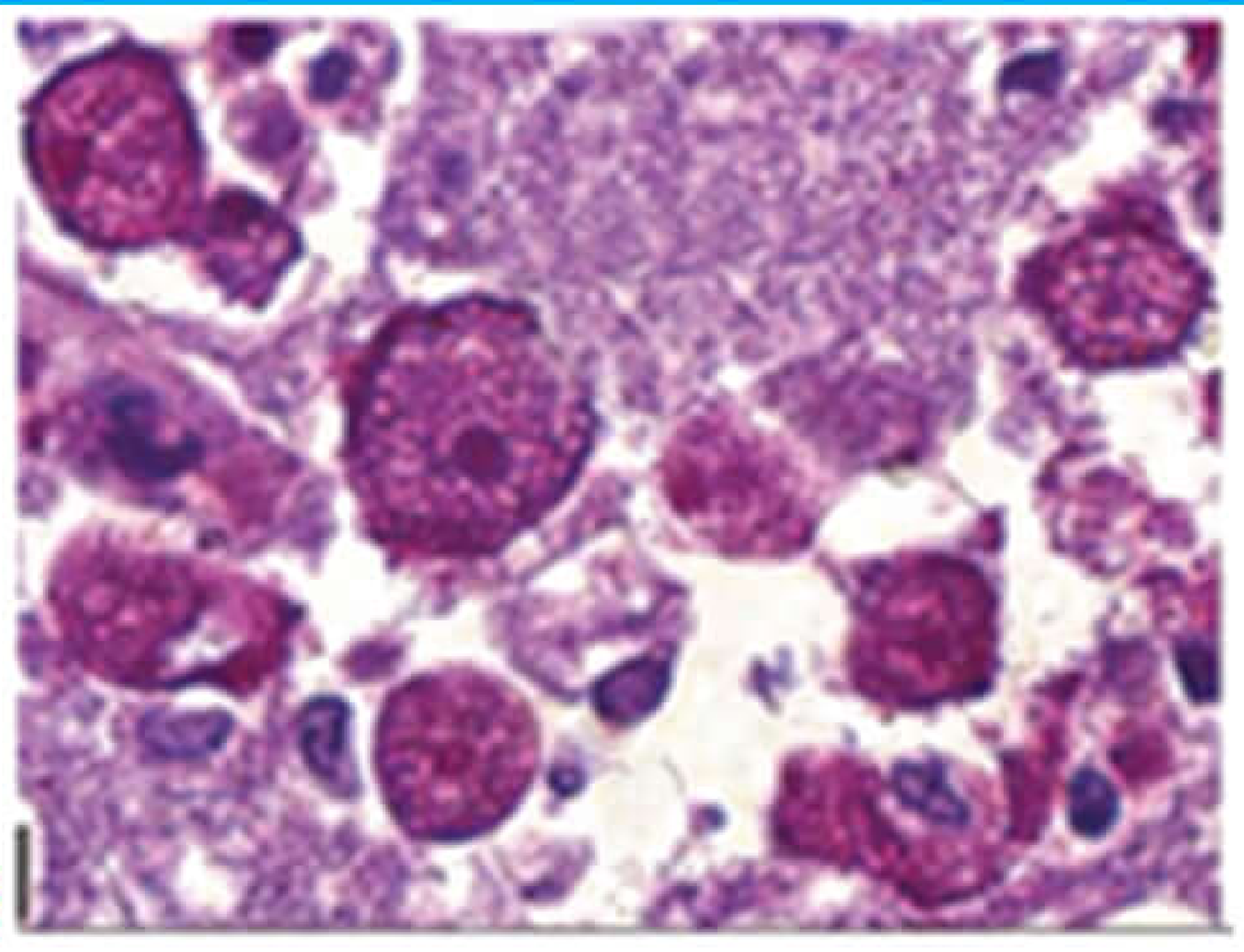

Fig : 6

E/M of acanthamoeba

Fungal Meningitis

Cryptococcus (M/C)

Gross "soap bubble"
Abscess
(gross/radio/microscope/india ink)

↓

M/C involves robin
Virchow space in brain

↓

Tiny cystic areas
(mucoid -glistening)
d/t capsules polyacaharide of fungal
stain

- Mx : -

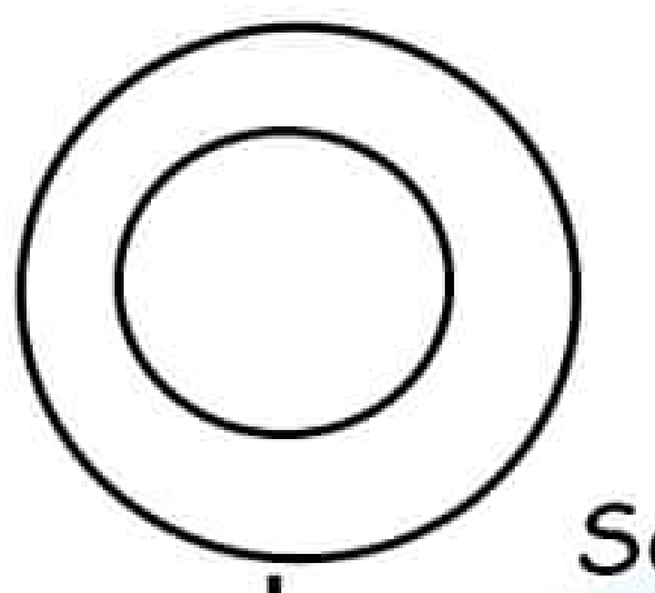

H/E

Soap bubble appearance

↓

Clear space

Mucicarmine stain



Red stain of cryptococal polysaccharide capsule

Indian ink (negative stain)

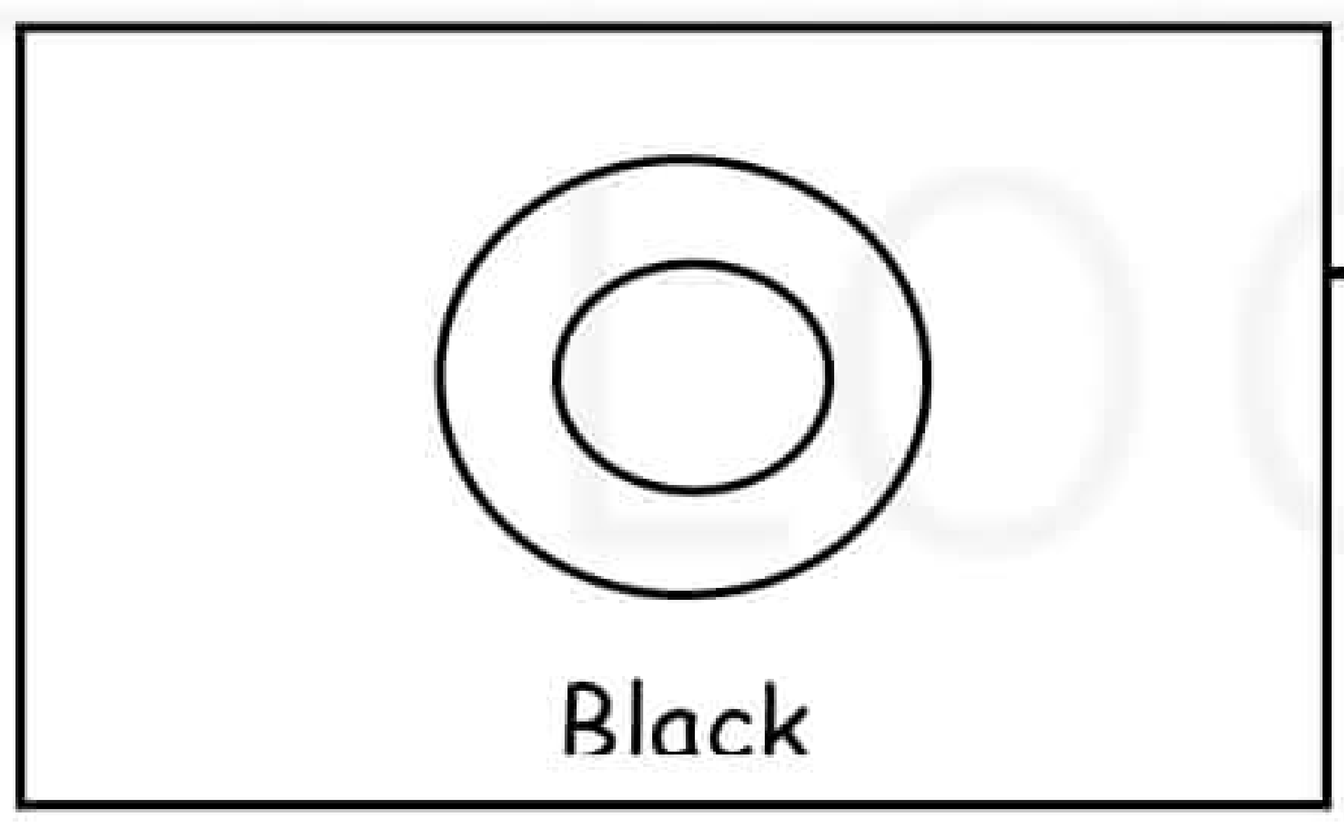

→ Organism unstained (thus called -ve staining)

- Seen in immune compromised pts
  e.g. HIV, DM

Mucicarmine stain

India ink

Aspergillus

↓

This filament septate
hyphae acute like branching

Mucor

↓

Broad aseptate
hyphae ⊥90° of branching

↓

Special stain → gomori silver methanomia

↓

Dark brown / black colour

CNS Involvement in ALL

CNS 1 – No blasts
CNS 2 – WBC $<$ 5 / μl with blasts
CNS 3 – WBC $>$ 5 / μl with blasts, or symptomatic CNS involvement
(e.g. cranial nerve palsy)

AfraTafreeh.com

BASIC INTRODUCTION WITH FOCUS ON GLIAL CELLS

Cell in central nervous system

Neurons
Neurons and ganglions

Glial cells
Supporting tissue

Astrocytes	Ependymal Cells	Microglial Cells	Oligodendrocytes
Star Shaped Cells		Macrophages of the brain (Mesodermal in origin)	Small Lymphocyte like cell with a peri-nuclear halo
Involved in Repair and formation of the blood brain barrier	Lining the ventricles (cuboidal or Low Columnar Cells with Cilia) 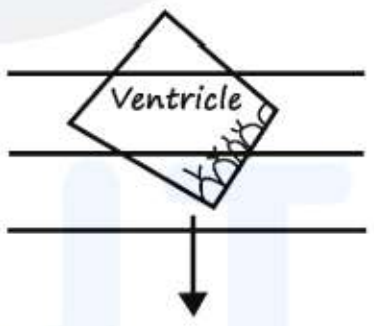		Help in Myelination 

Glial cells are positive for the intermediate filament, GFAP (Glial fibrillary acid protein)

Neuronal cells are positive for NF (Neurofilament)

Astrocytes 00:05:32

- Most predominant cells of glia

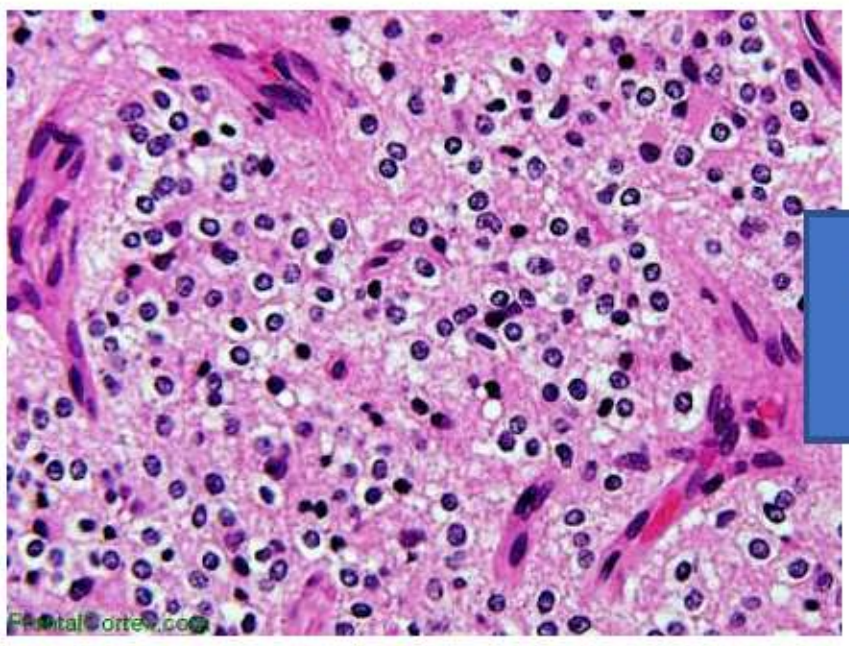

Small lymphocyte like nuclei sign of oligodendrocytes

Fig: 1

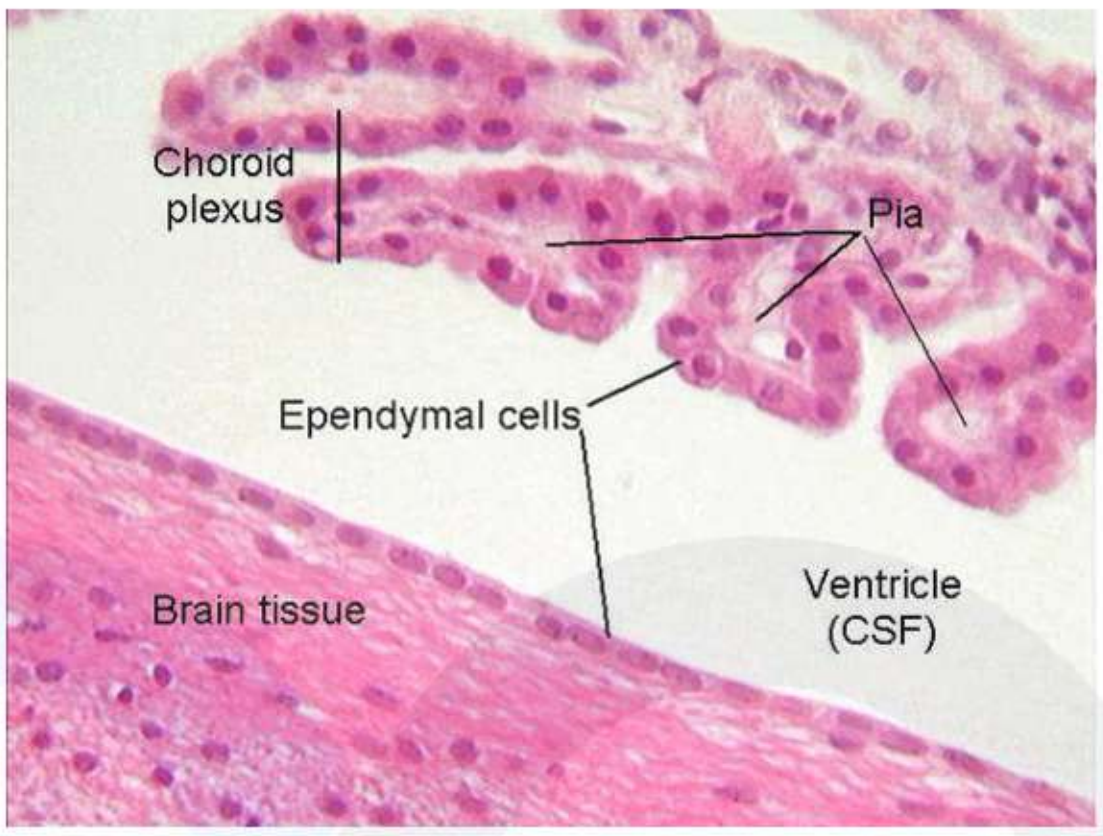

Ependymal cells

Fig: 2

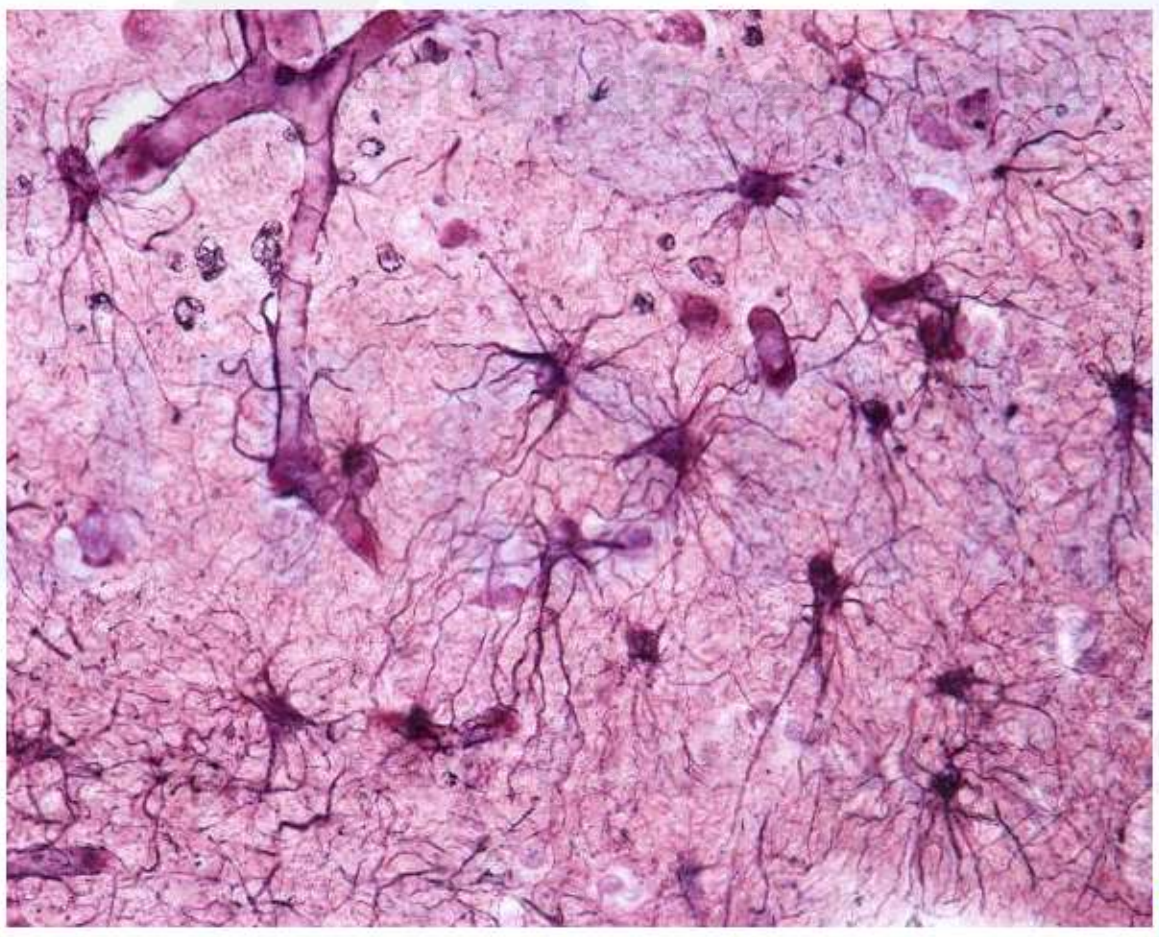

Fig: 3

Modifications Of Astrocytes

I. Rosenthal Fibres

- Present in Astrocytes
- Cork-screw like pink colored fibres

AfraTafreeh.com

- Made up of heat shock proteins bound with ubiquitin (HSP 27 + αβ crystallin)

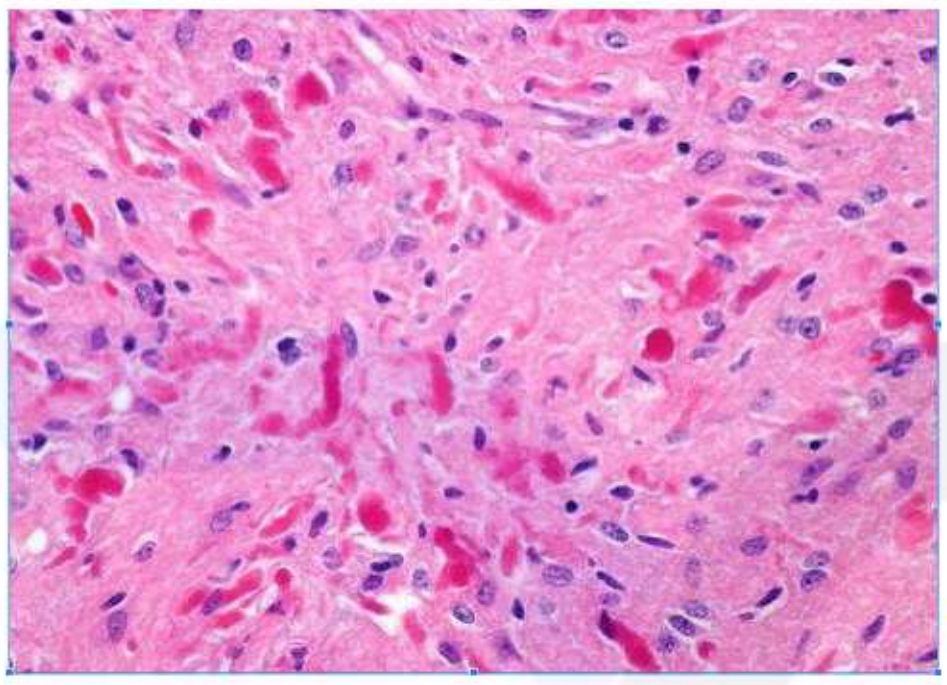

Fig: 4

- Seen in Alexander's disease and Juvenile Pilocytic astrocytoma

II. Gemistocytic Astrocytes

- Astrocytes with abundant pink cytoplasm

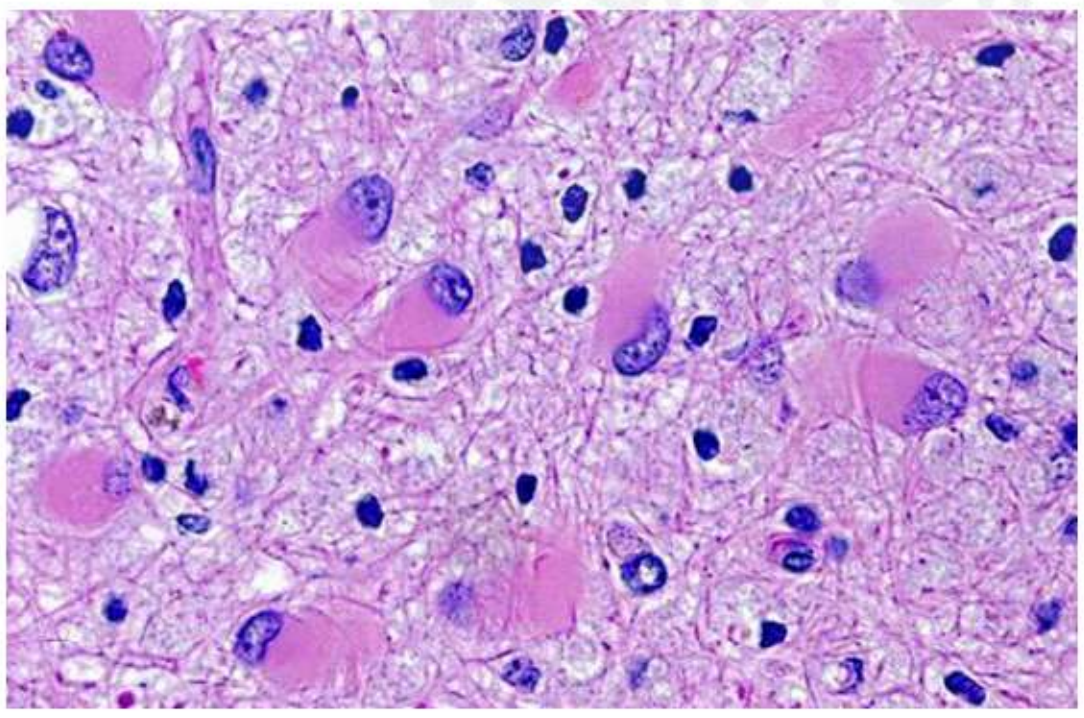

Fig: 5

- Occur either due to
  - Trauma
  - Tumor – Gemistocytic Astrocytoma

III. Alzheimer Type 2 Astrocytes

- Sometimes, Nucleus of the Astrocytes becomes vesicular due to excessive accumulation of Glycogen
- Not associated with Alzheimer diseases

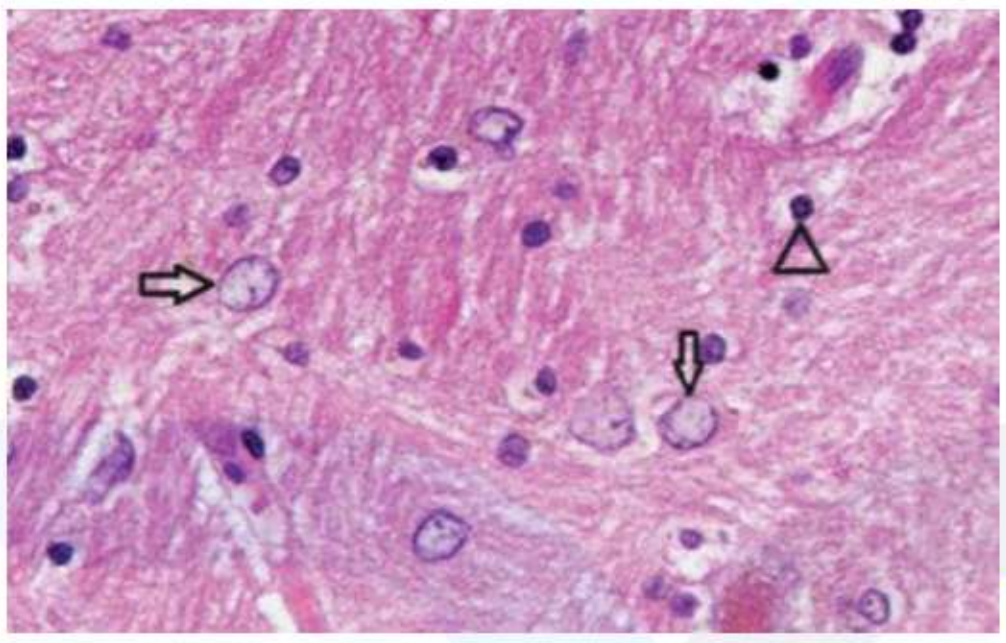

Fig: 6

- Associated with Hyperammonemia caused by Hepatic Encephalopathy, Wilson's disease
- **ALZHEIMER TYPE 1 ASTROCYTE – Multinucleated (Seen in Progressive Multifocal Leukoencephalopathy caused by JC Virus)**

IV. Corpora Amylacea

- Accumulates Polyglucan Bodies
- Ageing Phenomenon

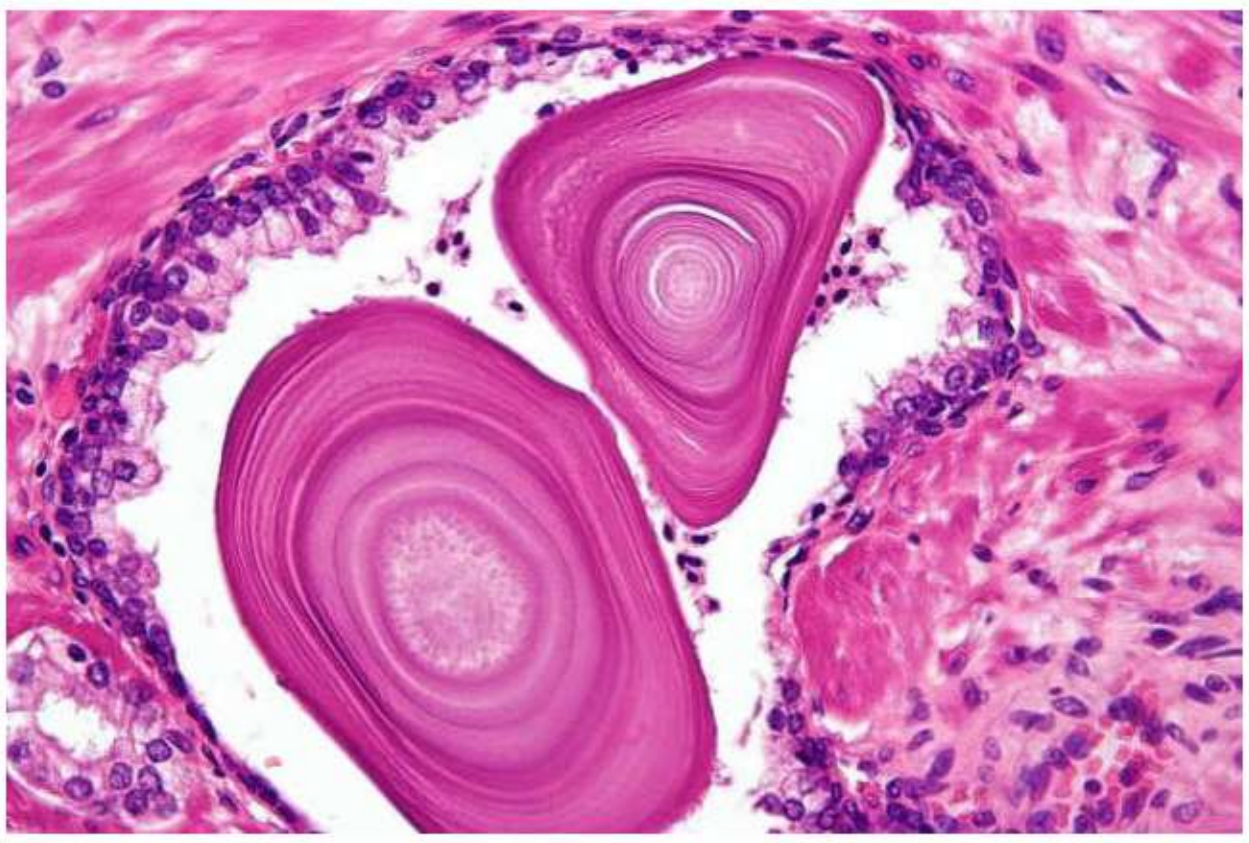

Fig: 7

AfraTafreeh.com

Ependymal Cells 00:19:28

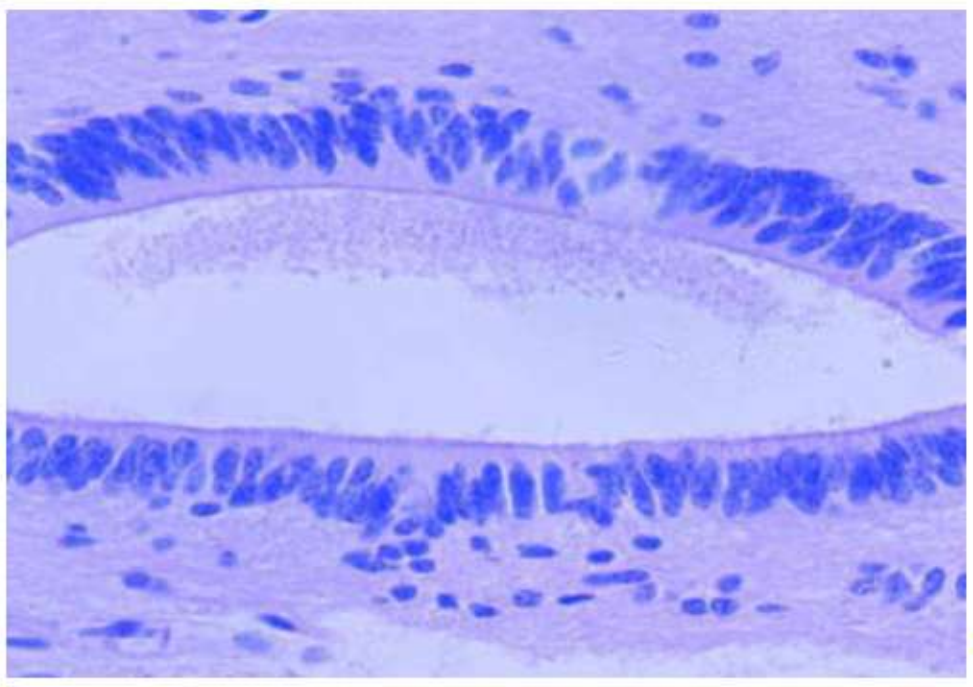

Fig: 8

- Either Low Columnar Cells/Cuboidal Cells
- No tight junctions in between cells
- Allow the exchange of material
- Lining of Ventricles
- MODIFICATIONS
  - CMV Inclusion accumulation in the brain
    - a. Neurons
    - b. Ependymal Cells
    - c. Endothelial Cells

TUTORIALS
LOGIN FOR SUCCESS

Oligodendrocytes 00:21:26

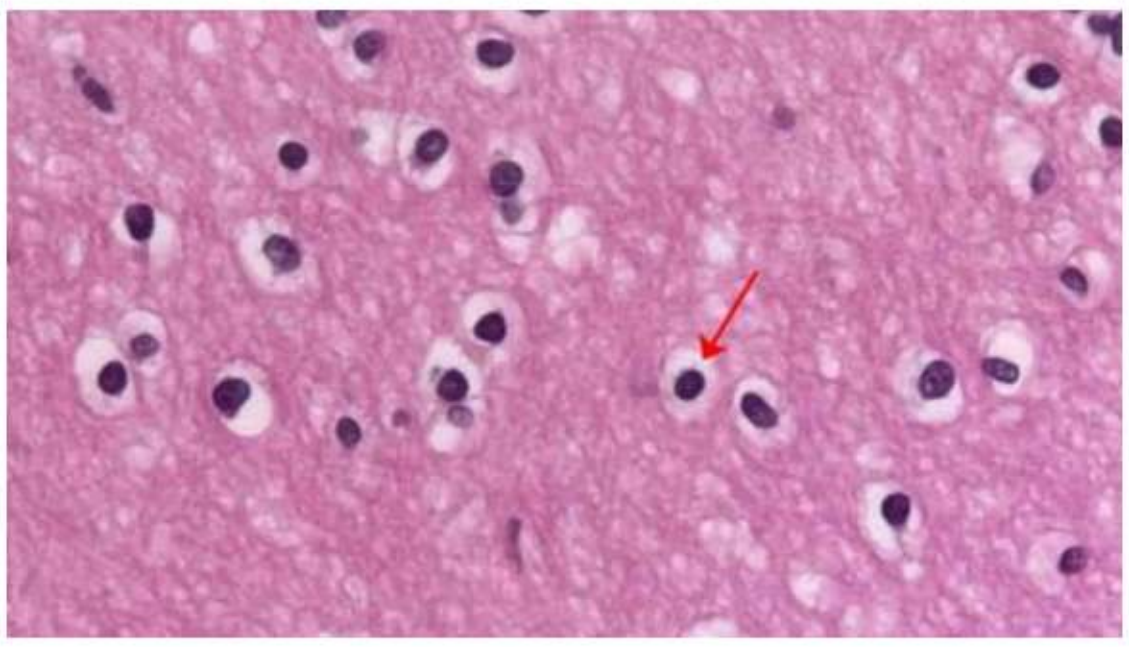

Fig: 9

- Small Lymphocyte like cell with Oligodendrocytes perinuclear halo
- Important role in Myelination

- Oligodendrocytes are damaged in demyelinating disorders
  - SSPE by measles damages Myelin synthesized by Oligodendrocytes
  - Progressive multifocal leukoencephalopathy (PML) by JC Virus which damages Oligodendrocytes – GROUND GLASS INCLUSION

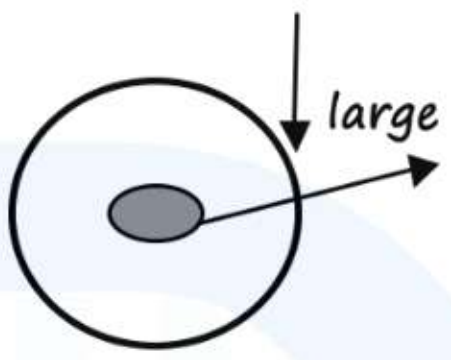

Ground glass inclusions of JC virus in oligodendrocytes

- Reactive change in astrocytes in JC virus infection is called Alzheimer Type 1 Astrocytes

AfraTafreeh.com

Microglial Cells 00:24:48

Macrophages of The Brain

I. Microglial nodules in HIV

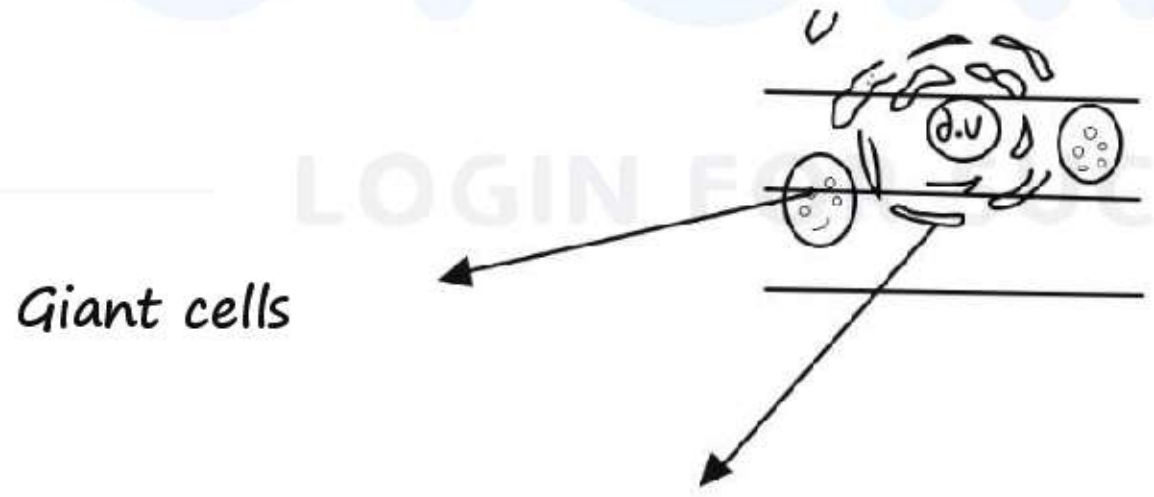

a. HIV enters into microglia and activates them
b. These activated macrophages become slipper shaped and accumulate together forming microglial nodule surrounding blood vessels
c. Damaged RBCs from the blood vessel are consumed by microglial cells which become pigment laden

AfraTafreeh.com

d. Composition of microglial Nodule

i. Activated macrophages

ii. Giant cells

iii. Pigment laden Macrophages

- Although present around blood vessels, they never show vasculitis

II. ROD Cells

- Elongated microglial cells appearing like rods
- Seen in Syphilis

III. Lipophagic Cells/Gitter Cells

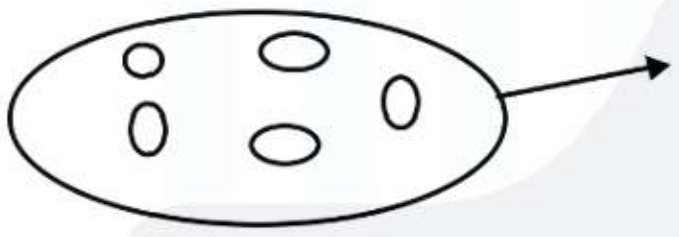

Lipid containing microglial cells - Gitter cells positively stained by Oil Red

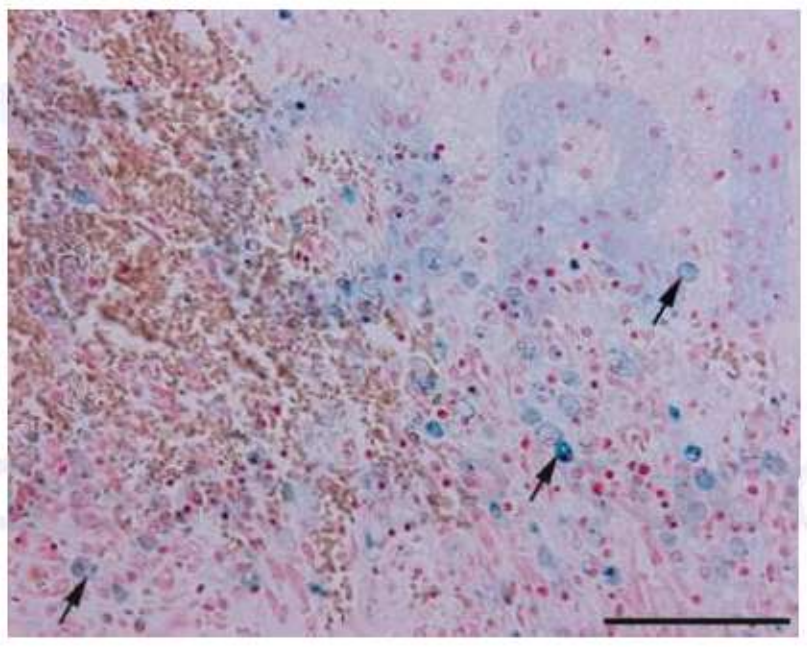

Fig: 10

IV. Neuronophagia

Dead neuron in Centre with microglial cells around, whenever there is damage to neurons

- In polio- Anterior horn calls of spinal card show Neuronophagia

FOCUS ON NEURONAL CELLS AND ITS INCLUSIONS

- Neuronal cells are identified by **Neurofilament** (NF)
- Neuronal tissue is made up of neurons and ganglions in a background of neuropil

Red Neuron 00:00:10

- Nissl granules (Import bluish color to neuron)

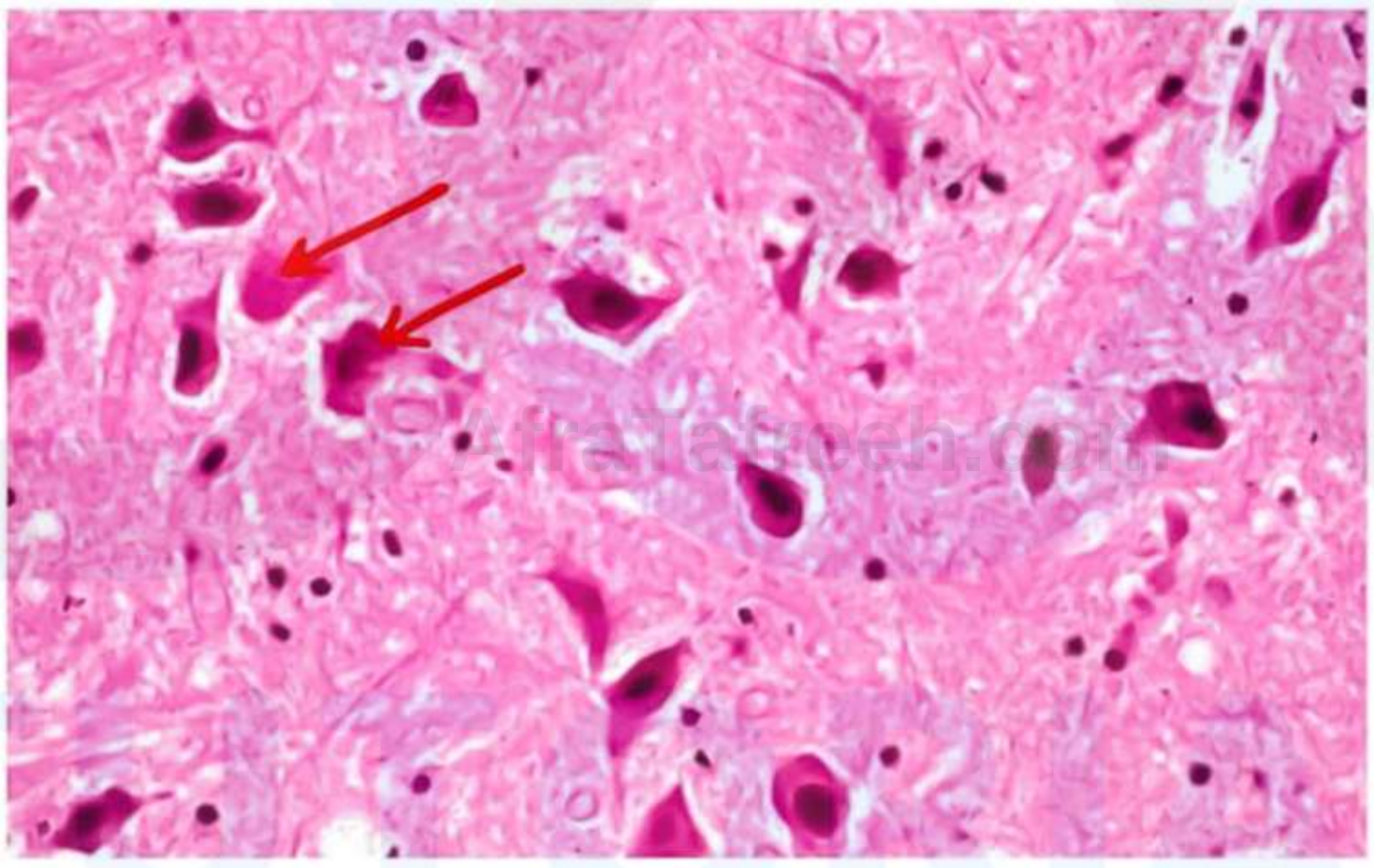

Fig: 1

In hypoxia

↓

Loss of Nissl bodies (12-24 hours after hypoxia)

↓

Neurons start appearing bright pink (**RED NEURONS**)

Inclusions In Neurons 00:03:01

Cytoplasmic inclusions

i. Lewy bodies

AfraTafreeh.com

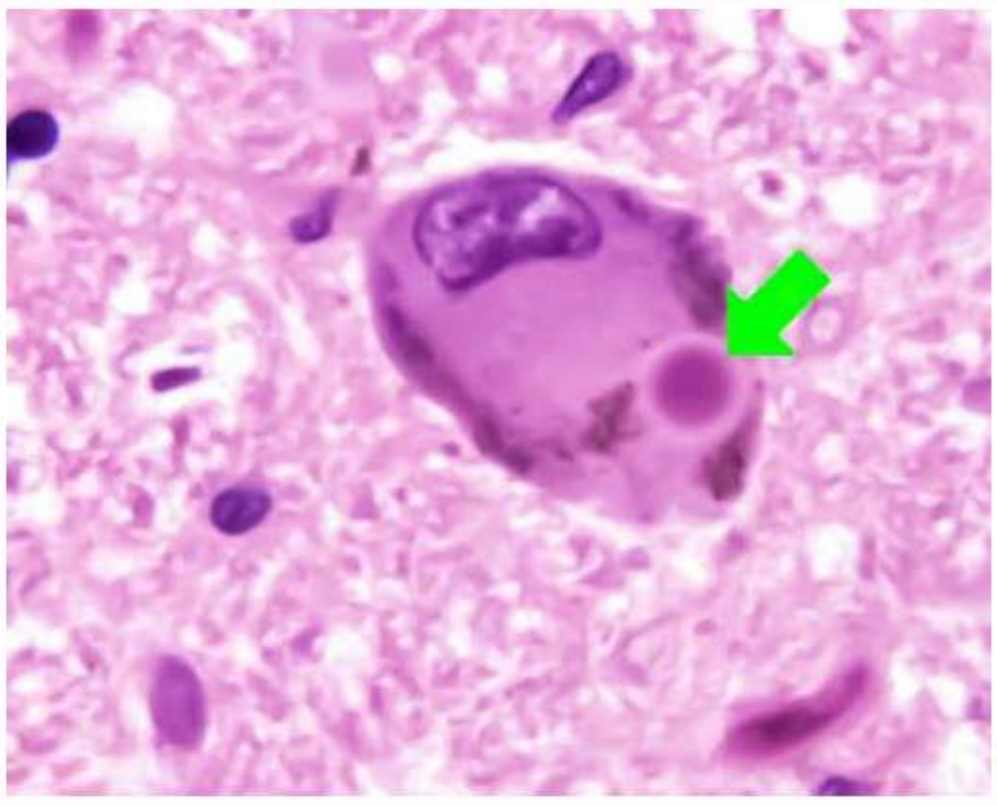

Fig: 2

- Eosinophilic cytoplasmic inclusion with surrounding halo – made of α-synuclein
- Seen in Lewy Body Dementia; Parkinson's disease which affects neurons in substantia nigra (melanin pigmented neurons)

ii. Negri bodies

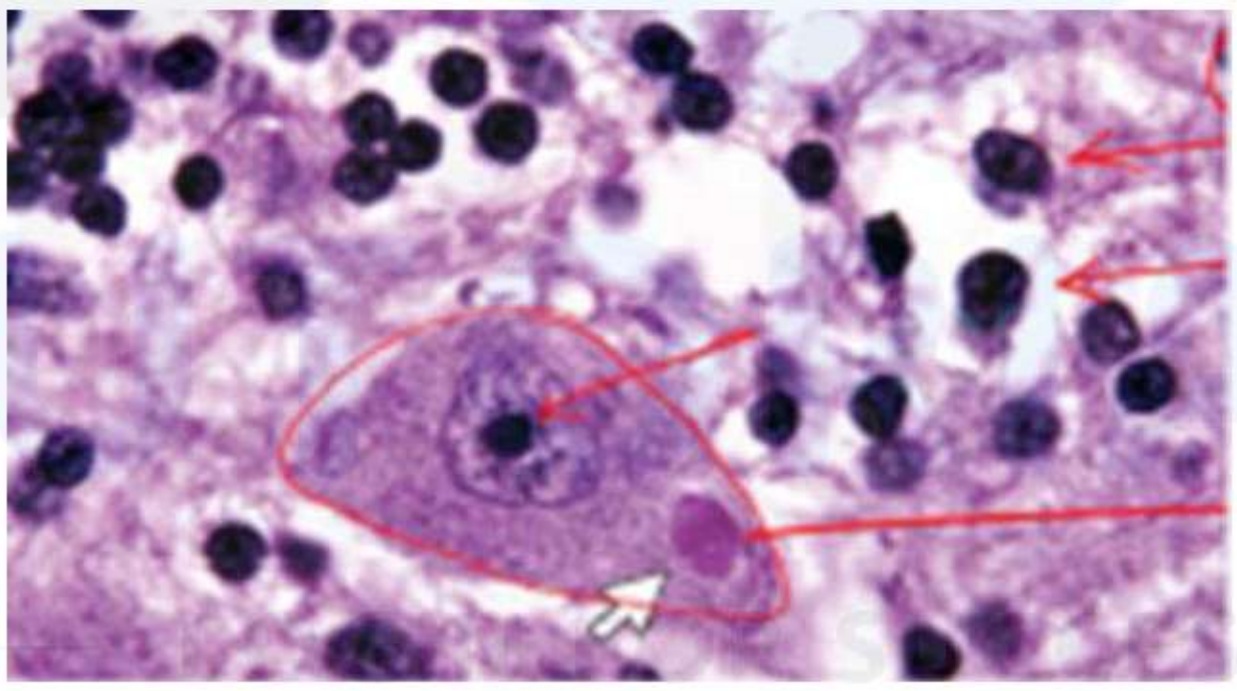

Fig: 3

- Eosinophilic cytoplasmic inclusion (made up of ribonucleoproteins)
- Seen in Rabies

Diagnostic area in brain (for Negri bodies)

- Purkinje cells of Cerebellum (Most common)
- Hippocampus
- Brain Stem

Intranuclear inclusion

i. CMV

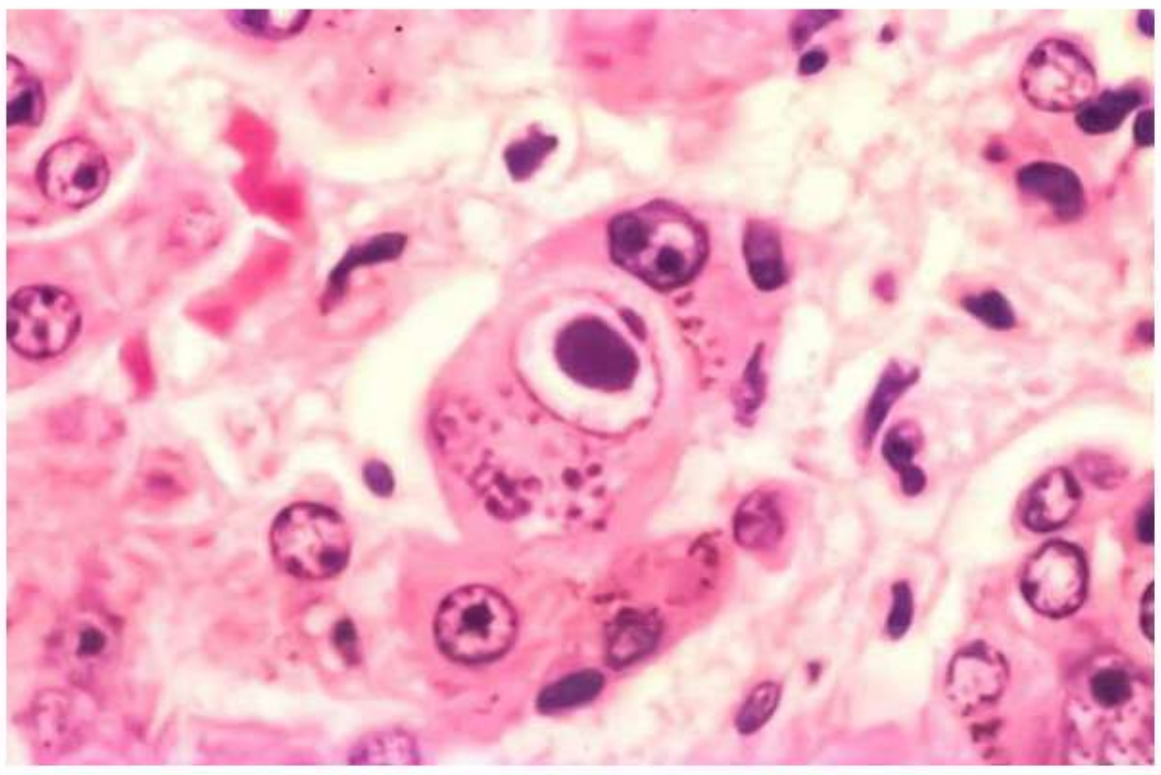

Fig: 4

- Large intra nuclear inclusion with perinuclear halo
- Cytoplasmic inclusions are also seen

ii. Huntington's disease

- Cause trinucleotide repeat disorder (CAG repeats)
- Polyglutamine aggregates seen in the nucleus of neurons

TUTORIALS
LOGIN FOR SUCCESS

Alzheimer's Disease 00:08:48

- **Neurofibrillary Tangles** – Seen in the cytoplasm of the neuron
- Seen in Alzheimer's disease & Fronto–temporal dementia
- **Aβ deposition** as diffuse plaques and neurotic plaques – Plaques are specific for Alzheimer's
- **Hirano bodies** are collections of Actin (near the proximal dendritic cells); Seen in Alzheimer's Disease

AfraTafreeh.com

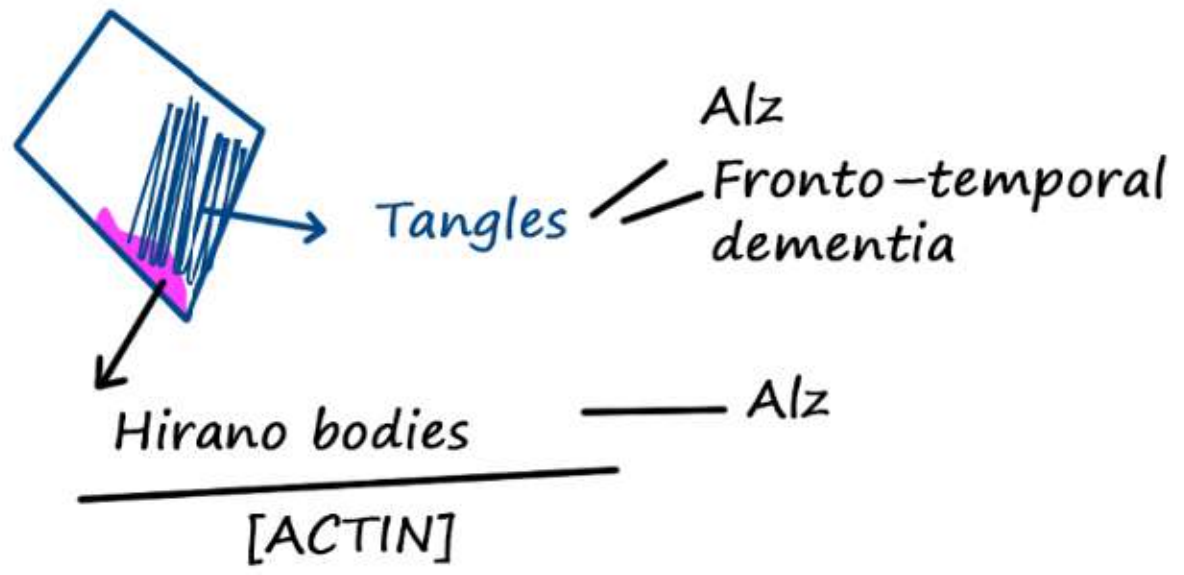

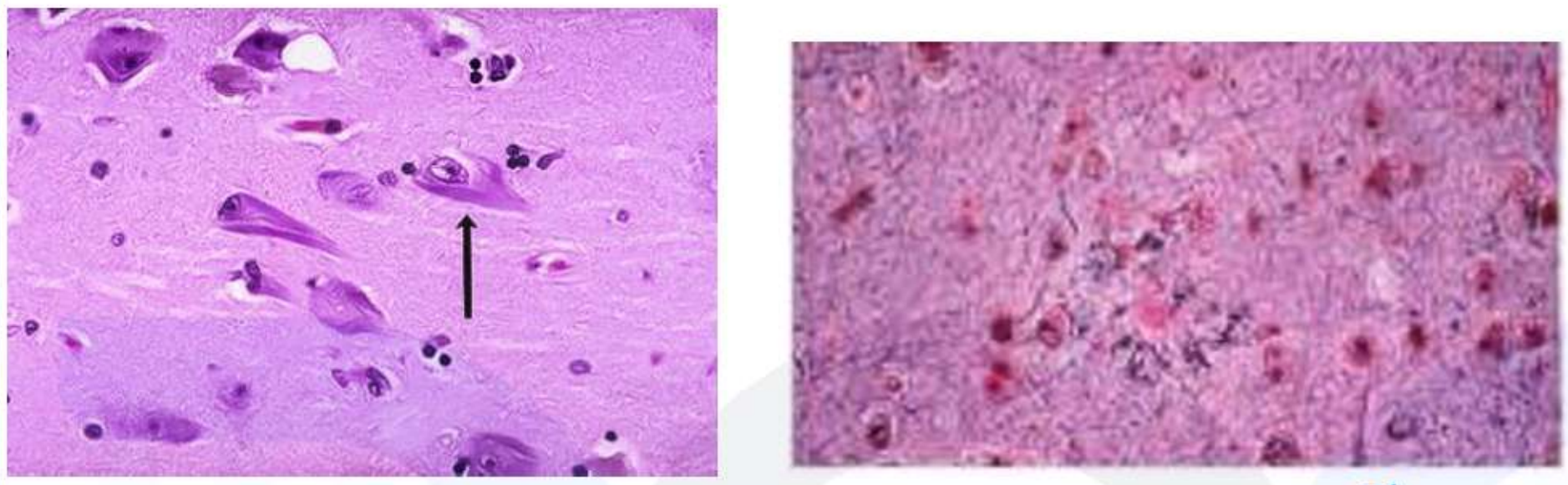

Fig: 5

- Damaged Neurites are identified by Bielschowsky Stain
- Plaques are made of Aβ Amyloid
- Plaques are specific for Alzheimer's while the neurofibrillary tangles indicate the severity of dementia.
- More the tangles – Severe the Dementia
- Diffuse plaques can also be seen in the brain of Down's syndrome. It ensures that Down's Patients >40 years develop Dementia.
- **Lewy Bodies** – α-Synuclein – Parkinson's and Lewy Body Dementia
- **Negri Bodies** - Ribonucleoprotein - Rabies

- **CMV** - Both Nuclear and Cytoplasm inclusions in neuron endothelial cells and ependymal cells
- **Huntington's Disease** – Intranuclear Polyglutamine aggregates; CAG repeats
- **Red Neurons** - Loss of Nissl granules
- **Hirano Bodies** – Actin Collections; Seen in Alzheimer's Disease
- **Tangles** – Neurofilament with Ubiquitin
- **Plaques (Extracellular)** - made of Aβ amyloid

AfraTafreeh.com
TUTORIALS
LOGIN FOR SUCCESS

AfraTafreeh.com

APPROACH TO CNS TUMORS

Cells in CNS

- **Neurons**
- **Glial cells**
  - **Astrocytes**
  - **Ependymal cells**
  - **Oligodendrocytes**
  - **Microglia**

Tumors arising from neurons

- Marker – NF
- Neuronal tumors
  - **Ganglio-glioma** – Most Common
  - **Gangliocytomas, Neurocytomas**
  - **Dysembryoplastic Neuroectodermal tumors (DNET)**

Tumors arising from glial cells

- Termed Gliomas
- Most Common Primary tumors
- Express GFAP
  - From Astrocytes – **Astrocytoma** – Most Common
  - From Ependymal Cells – **Ependymoma**
  - From Oligodendrocytes – **Oligodendroglioma**
  - From Microglial Cells – **TUMORS DON'T ARISE FROM MICROGLIAL CELLS**

Poorly differentiated tumors

- Neither from neurons nor from glia
  - Medulloblastoma
  - Atypical Teratoid/Rhabdoid tumor (AT/RT)
- Both occur in children
- Both have poor prognosis

CNS Lymphomas

- Most common type is Diffuse Large B-cell lymphoma (DLBCL)

Brain Tumor 00:08:17

- Most common tumors of the brain are metastatic tumors to the brain
- Most common site of primary to send metastases to the brain

1. **Lungs** - Intraparencymal metastasis especially small cell carcinoma
2. Breast cancer – Metastases to the Dura (Dural Nodule/Dural Metastases)
3. Skin - Melanoma – Metastases of individual tumor cells
4. GIT - Colon cancer
5. Renal Cell Carcinoma
6. Choriocarcinoma

AfraTafreeh.com

Remember – Prostate cancer can never send metastases to brain

Most common primary tumor of brain → Meningioma (35%) ≥ Glial Tumors (30%)

TUMOR INCIDENCE IN BRAIN – **Metastasis ≥ Meningioma ≥ Glioma**

- Most Common tumor of the brain – **Metastases**
- Most Common primary tumor – **Meningioma**
- Most Common Malignant Primary Tumor – **Glioma**
  1. Adults – **Astrocytoma (Glioblastoma)**
  2. Children – **Juvenile Pilocytic Astrocytoma**
- Most Common 1° Neuronal tumor of Brain – **Ganglio-glioma**

Approach To CNS Tumors

History is the key 00:13:55

- **GENETIC** – Syndromic Association
  a. Li-Fraumeni Syndrome
     i. Heterozygous for p53
     ii. Secondary Glioblastoma
  b. Gorlin Syndrome
     i. PATCHED Gene Mutation
     ii. Medulloblastoma
  c. Cowden Syndrome
     i. PTEN Mutation
     ii. Dysplastic Gangliocytoma

iii. Breast, Endometrial and Thyroid Cancers
iv. Hyperkeratosis of Hand and Foot

d. Von-Hippel-Lindau Syndrome
i. In conditions of **Hypoxia**, HIF1α is induced – Causes Angiogenesis by inducing VEGF
ii. **Normo-Oxic** State – Body will produce VHL which breaks HIF1α.
iii. Angiogenesis is unhindered in VHL Deletion
iv. Hemangioblastoma in Cerebellum – Extensive Vascularity

e. Tuberous Sclerosis
i. Sub-Ependymal Giant Cell Astrocytoma **(SEGA)** in Brain

f. Gardner Syndrome – APC Mutation - Medulloblastoma

g. Turcot Syndrome – APC Mutation – Medulloblastoma

AfraTafreeh.com
TUTORIALS
LOGIN FOR SUCCESS

- **ACQUIRED**

a. Exposure to Radiation (LEUKEMIA **(m/c)** > PAPILLARY CARCINOMA THYROID > BRAIN TUMOR)

AfraTafreeh.com

Age affects the incidence of tumors 00:22:45

i. **Pediatric CNS Tumors**

  a. Most common tumor - Pilocytic astrocytoma
  b. Most Aggressive Malignant tumor - Medulloblastoma
  c. Others - Atypical tumor/Rhabdoid Tumor (AT/RT), Midline Pontine Gliomas

ii. **Adult CNS Tumors**

  a. **<20 years** – Ependymoma (Sporadic)
  b. **>20 years** – Ependymoma (with NF2 Mutation in Spinal Cord)
  c. **30-40 years** – Oligodendroglioma, Glioblastoma

Radiological Interpretation in CNS Tumors

00:25:50

i. **Cystic tumor with mural nodule**

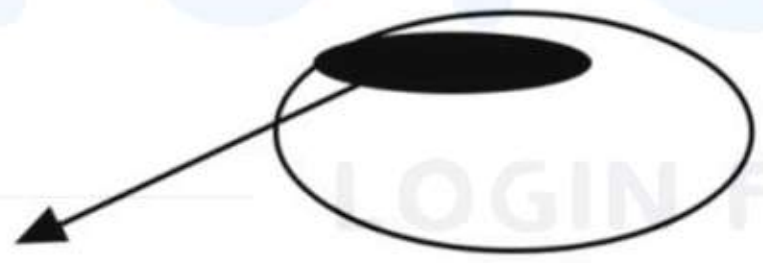

  a. MURAL NODULE
  b. **Differential Diagnosis** - Pilocytic astrocytoma, Hemangioblastoma, Pleomorphic Xantho-astrocytoma (PXA)

ii. **CNS tumors showing calcification**

  a. Oligodendroglioma
  b. Meningiomas (Psammoma bodies)
  c. Craniopharyngiomas (Suprasellar calcifications)

ASTROCYTOMA WITH SPECIAL MENTION OF PILOCYTIC ASTROCYTOMA AND GLIOBLASTOMA

WHO Classification of Glial Tumors 00:00:15

WHO classification of glial tumors

- **Grade I** → Pilocytic Astrocytoma (Grade I)
- **Grade II** → Diffuse astrocytoma (Grade II)
- **Grade III** → Anaplastic Astrocytoma (Grade III)
- **Grade IV** → Glioblastoma (Grade IV)

Non-infiltrating Astrocytomas (Grade I)

Infiltrating Astrocytomas (Grades II–IV)

AfraTafreen.com
TUTORIALS
LOGIN FOR SUCCESS

Pilocytic Astrocytoma (WHO GRADE 1) 00:01:54

i. Most common pediatric brain tumor

ii. Most common site – Cerebellum (posterior fossa)

a. Can be picked up early due to the apparent symptoms presented by the child

iii. Most common gene involved – **BRAF gene mutation**

- **Point mutation (being evaluated)**
- **BRAF V600E mutation**

AfraTafreeh.com

iv. Sometimes, it can also involve optic nerve forming optic nerve glioma. It is associated with a mutation of NF-1

a. Presenting with headache/sudden blindness

v. Gross – large cystic tumor with small mural nodule

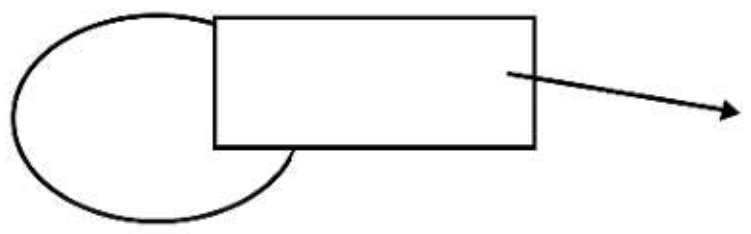

On histological examination

- Piloid cells
- Hypercellular & hypocellular areas
- Rosenthal fibres

- Rosenthal fibres are made up of HSP 27 & αβ crystallin
- Excision is curative (no infiltration of surrounding brain)

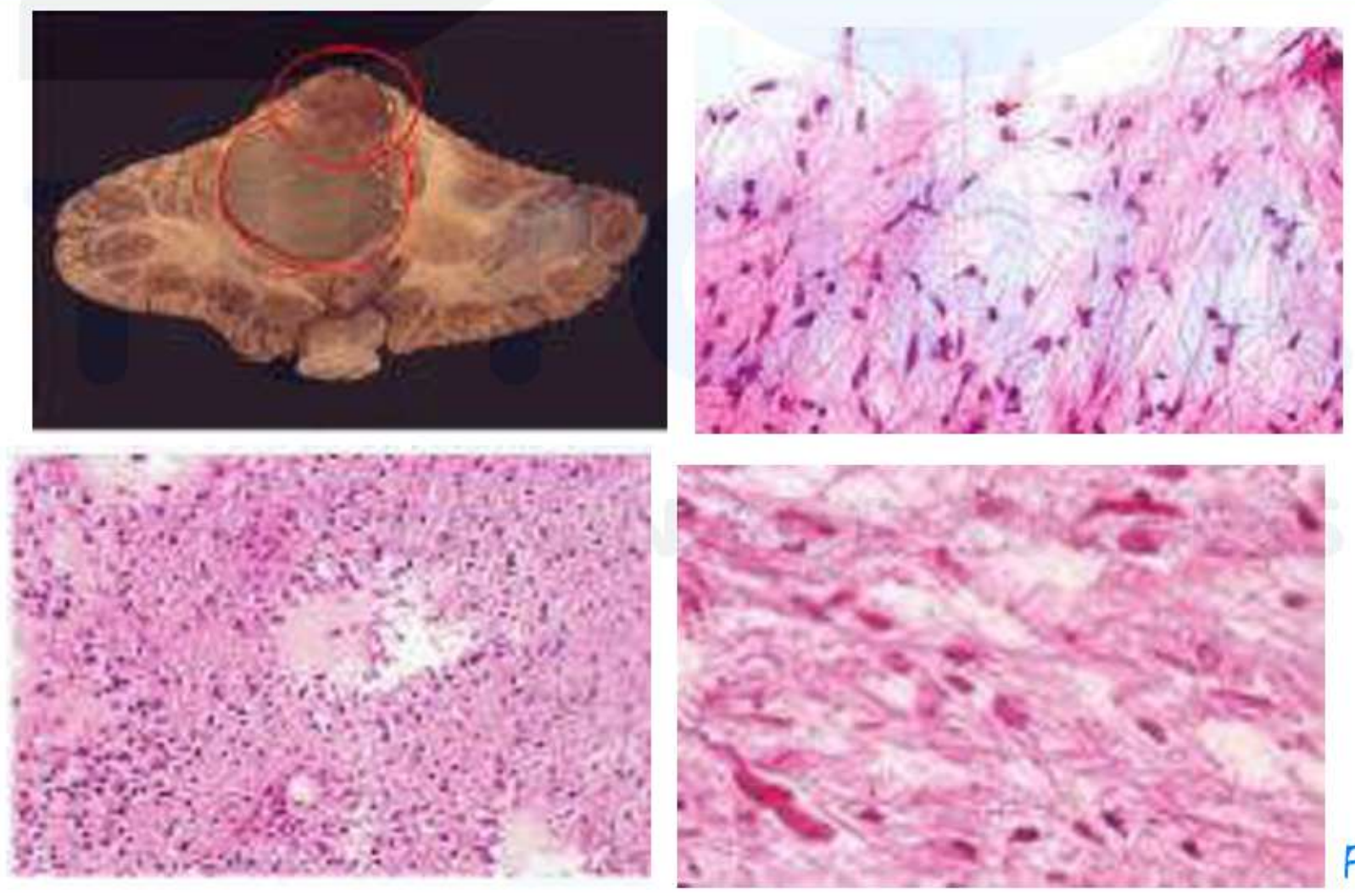

Fig: 1

Gross Appearance – Cystic Areas are Hypocellular and adjacent hypocellular areas – Corkscrew shaped fibres (Rosenthal Fibres)

WHO grade II

- Variant → Gemistocytic Astrocytoma
- Occurs in the lobes of brain – Intraparencymal tumor
- Gemistocytes have eccentrically placed nucleus and abundant pink cytoplasm

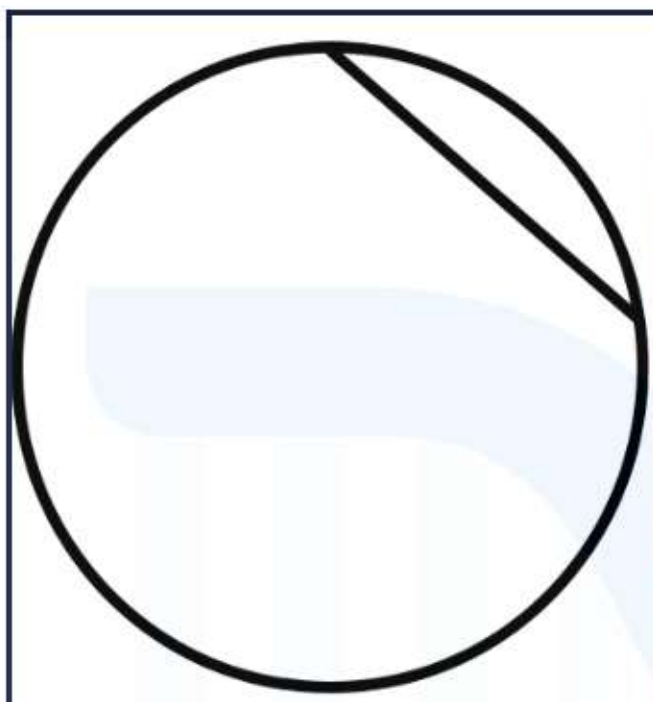

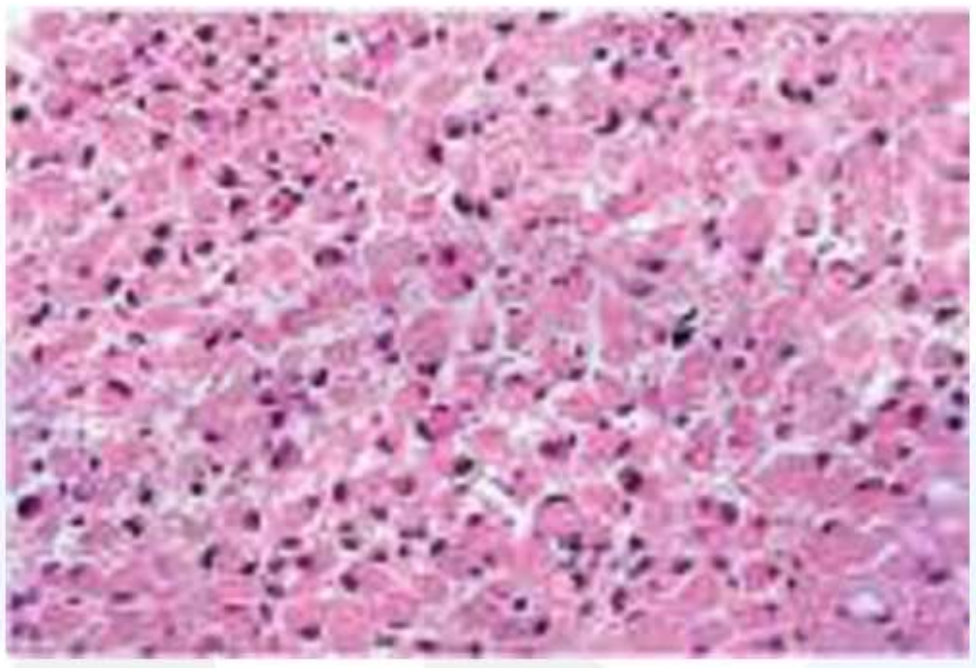

Fig: 2

- Very rapidly progressing tumor (abundant mitotic activity – AGGRESSIVE TUMOR) and can progress to Grade IV tumor Glioblastoma
(i.e., low grade astrocytoma into high grade astrocytoma)

AfraTafreeh.com
TUTORIALS
LOGIN FOR SUCCESS

Sub-Ependymal Giant Cell Astrocytoma (SEGA)

00:11:18

- It is the closest differential diagnosis of gemistocytic astrocytoma
- Seen in patients of Tuberous Sclerosis

AfraTafreeh.com

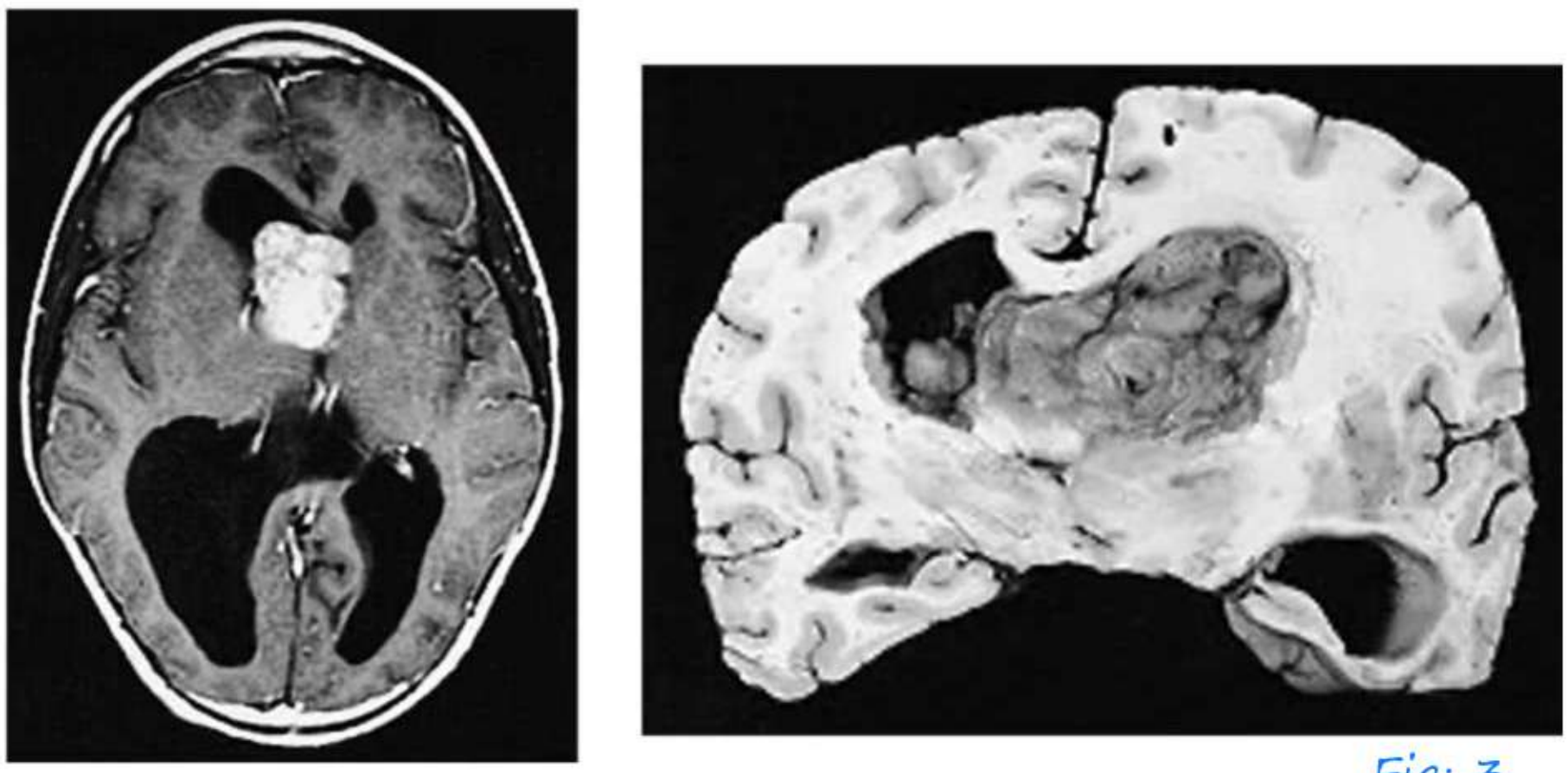

Fig: 3

- Categorized under WHO GRADE I
- On Histology – It shows Gemistocytes + Spindle shaped cells
- Intraventricular tubers (arises in the ventricles of brain)

SEGA	Gemistocytic astrocytoma
• GRADE I • Intraventricular • Strong history of tuberous sclerosis • Markers of both glial cells and neurons • Abundant Fibrous tissue intermingling Gemistocytes 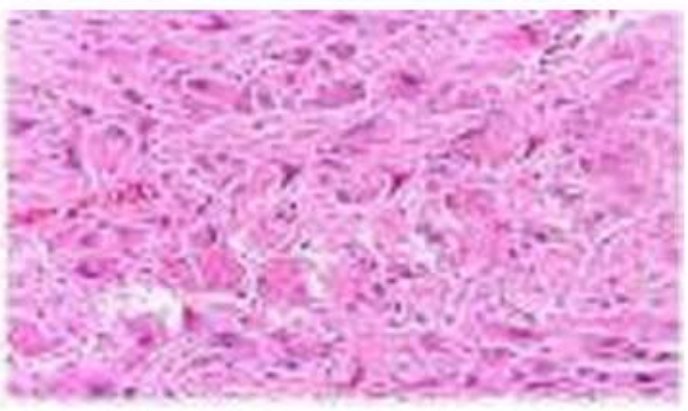	• GRADE II • Intraparencymal 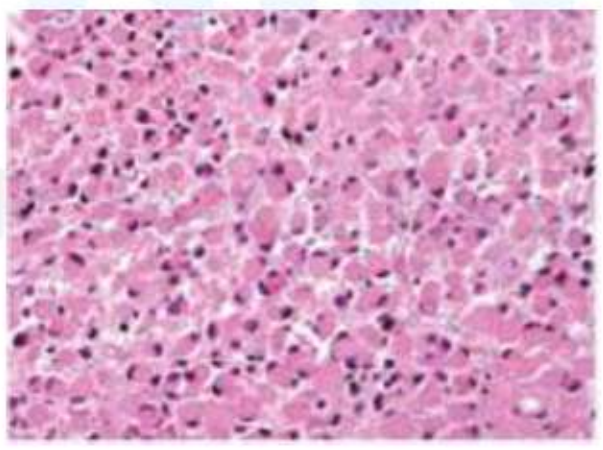 • Fibrous tissue – Minimal

Grade IV Astrocytomas 00:14:23

- Glioblastoma (previously Glioblastoma Multiforme)
- Grade IV Tumors
- Occurs in adults (in the Parenchyma)
- In supratentorial region
- Most common site of glioblastomas – Frontal lobe of brain - Highly vascular ↑↑↑
- De-novo/progressed from lower grades of tumors
- **ETIOLOGY**: IDH Mutation

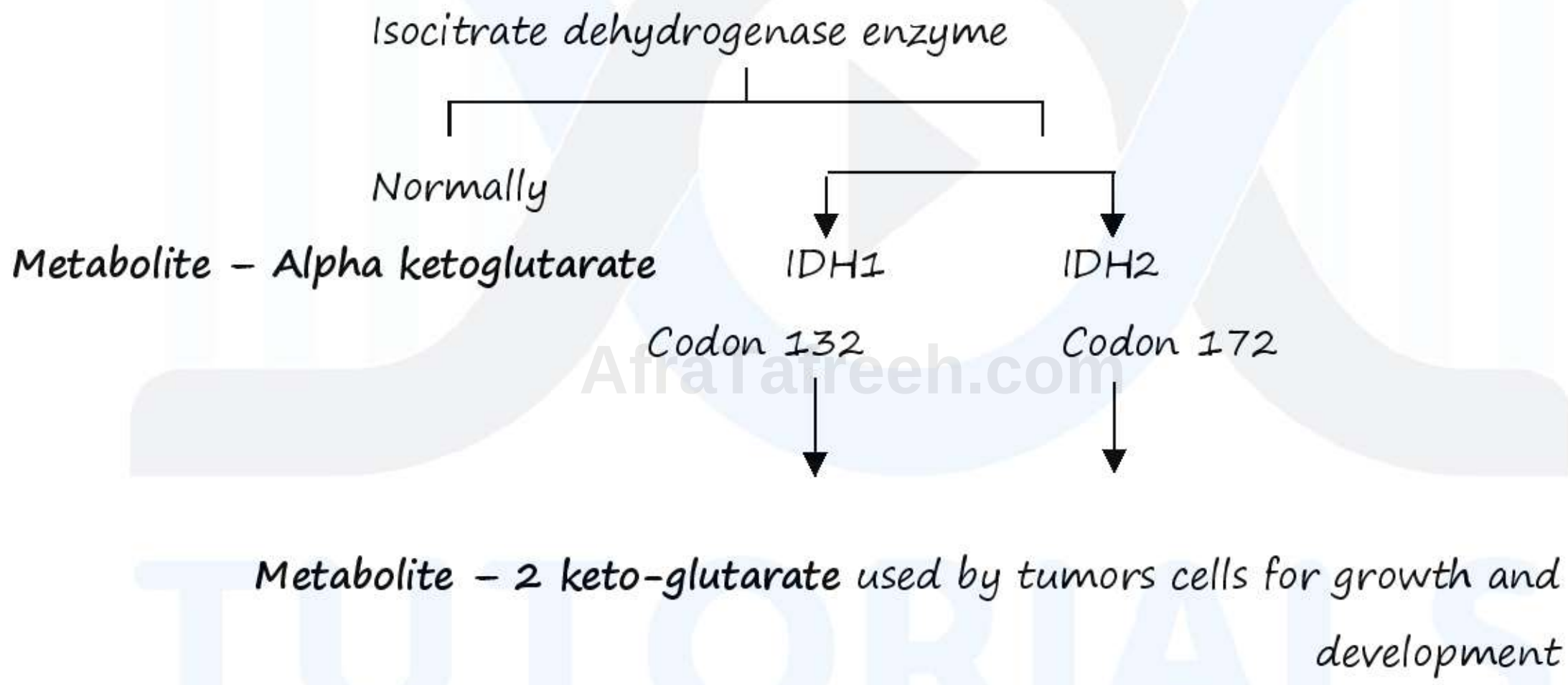

- **Oncometabolic Therapy (Targeted – doesn't target normal cells)**

AfraTafreeh.com

Types of glioblastomata based on IDH mutation

IDH (wild type glioblastoma)	IDH (mutated type glioblastoma)

• Called as primary glioblastoma
• Typically occur in Elderly Population
• Poor prognosis
• Mutation
  – TERT (Telomerase Elongation gene) (most common)
  – EGFR
  – P-TEN
• 90% of glioblastoma are of wild type
	• Called as secondary glioblastoma
	• Occurs in Younger population
	• Good prognosis
	• Therapy against mutated IDH
	• Mutation
	  – IDH 1 and IDH 2
	  – p53
	  – ATRX (At-alpha thalassemia, R- mental retardation, X-X linked)
	• Only 10% of glioblastoma are mutated type

- IDHI & IDH2 mutation are also seen in 95% of Oligodendroglioma. Therefore, Secondary glioblastoma and oligodendrogliomas are now classified together as IDH mutated types (Pro-neural type of Glioblastomas).

- **GROSS APPEARANCE**: Tumor spreads from one cerebral hemisphere to another hemisphere rapidly, through Corpus Callosum (BUTTERFLY APPEARANCE – Butterfly tumor

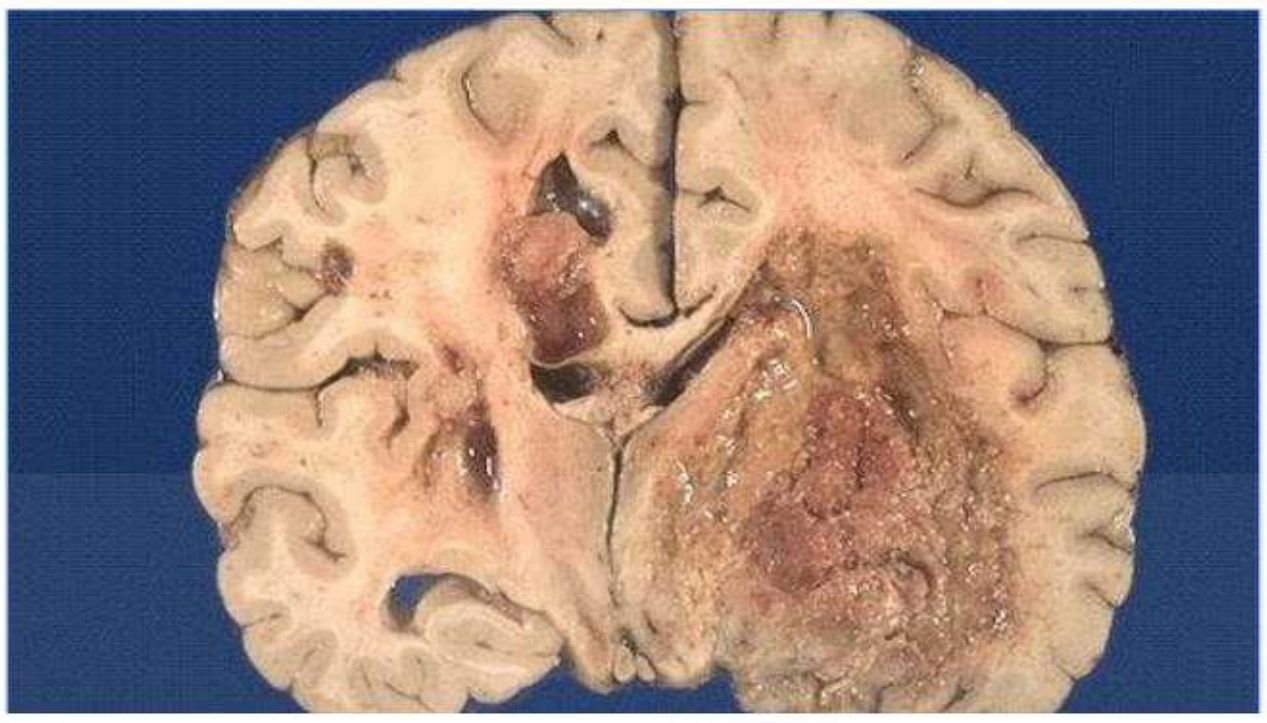

Fig: 4

- **Central part quickly undergoes necrosis** – due to the endothelial proliferation and angiogenesis in the peripheral part (NOT STATIC – **SERPENTINE NECROSIS**)

AfraTafreeh.com

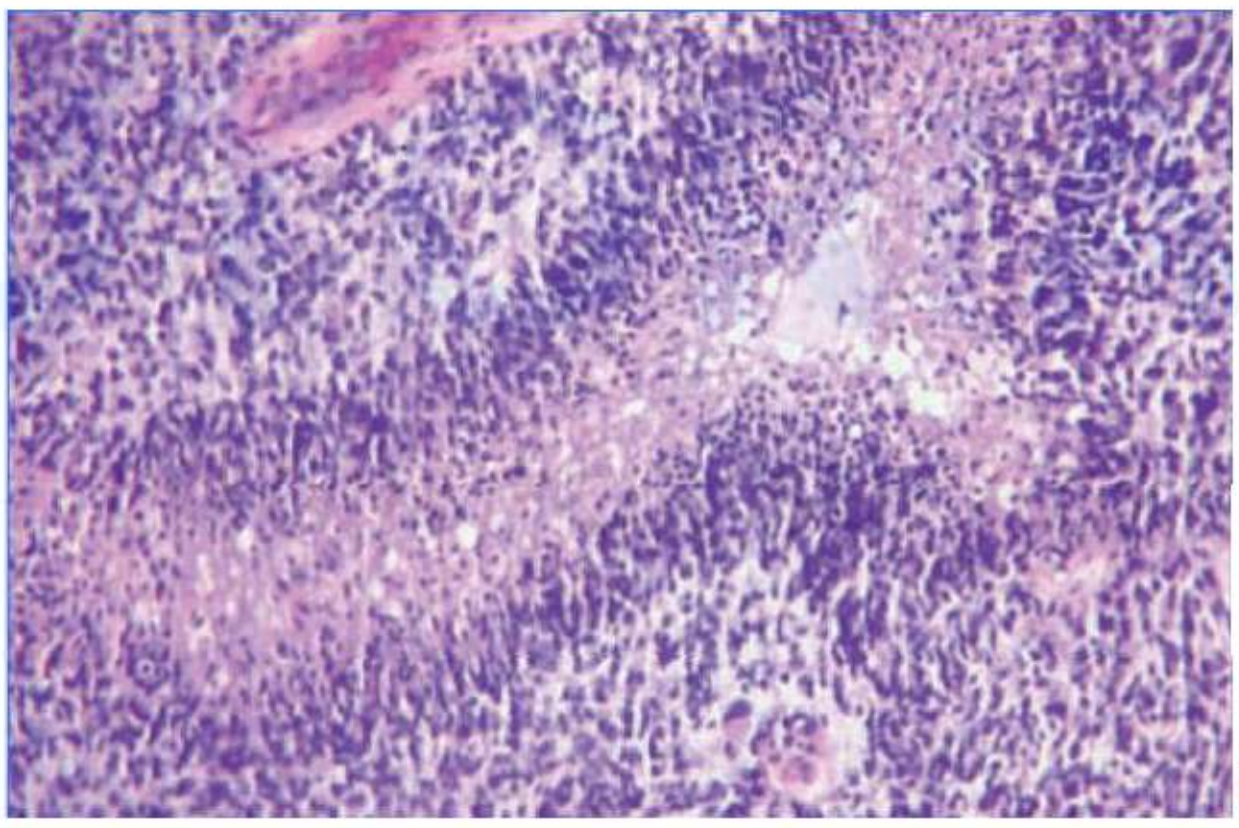

Fig: 5

- Collection of Endothelial cells **(GLOMERULOID BODIES)** forming leaky vessels similar to Capillaries of Glomerulus

AfraTafreeh.com

- Tumor cells between Necrosis and Blood Vessels – Forced to be in a line **(PSEUDO-PALISADING APPEARANCE)**

Remember:

i. Leipidic patient – Butterfly on fence appearance seen in Broncho-alveolar carcinoma

ii. Butterfly tumor → Glioblastoma

iii. Tumors showing true palisading appearance

a. Schwannoma

b. BCC

TUTORIALS
LOGIN FOR SUCCESS

OLIGODENDROGLIOMA

- > 90% of oligodendrogliomas show IDH1 (132 Codon) and IDH2 (172 Codon) mutation (Argentine replaced by histidine (**R132H**) at 132 codon)
  i. **Byproduct metabolite of the enzyme activity - 2 keto-glutarate (used by tumor cells)**
  ii. Causes loss of methylation of genes (activation of silenced genes)
  iii. Activation of oncogenes
  iv. Cancer
- Mutation of p53 and ATRX gene can also be seen similar to secondary glioblastoma
- > 80% of oligodendroglia shows loss of heterozygosity on 1p and 19q (Earlier considered as the most common mutation)
- Age group effected → 40-50 years
- Predilection for the cortex and white mater of cerebral hemispheres (Frontal lobe in 50-65%)
- Clinical feature: Frequently presents with seizures
- **Microscopy**
  - Peri-neuronal Satellitosis

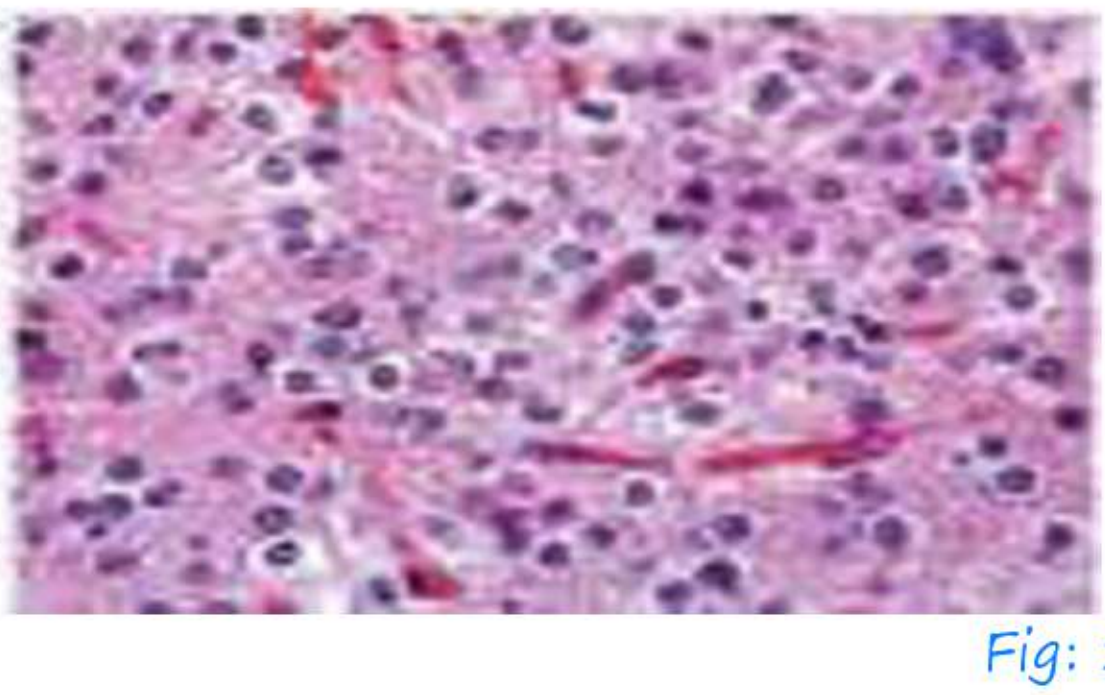

Fig: 1

AfraTafreeh.com

- "Fried egg cytoplasm"
  PERINUCLEAR HALO AND CHICKEN WIRE VESSELS
- "Chicken wire vasculatures"
  - Chicken Wire fibrosis seen in alcoholic hepatitis
  - Chicken Wire Calcification seen in Chondroblastoma
- Calcifications

TUTORIALS
LOGIN FOR SUCCESS

Updates

Midline pontine glioma

- Brain stem glioma of children
- Epigenetic mutation in histone 3.3 or histone 3.1 - point mutation at codon 27 on histone 3 → H3K27M

Pleomorphic Xanthoastrocytoma

- WHO grade 2 tumors
- Xantho → lots of lipidized cells
- Present as a large cystic lesion with a mural nodule

EPENDYMOMA AND CHORDOMA

Ependymoma 00:00:07

- It occurs in <20 years of age
- If seen in >20 years of life – it is associated with NF2 mutation and occurs in spinal cord
- Arises from ependymal lining of ventricles, especially in the 4th ventricle

AfraTafreeh.com

Microscopy

- Ependymoma shows both true (cells resting on the basement membrane) and pseudo-rosettes (cells resting on blood vessel – perivascular pseudo-rosettes)
- EMA stain (Epithelial membranous antigen) shows dot like positivity in Ependymoma
- Dissemination through CSF

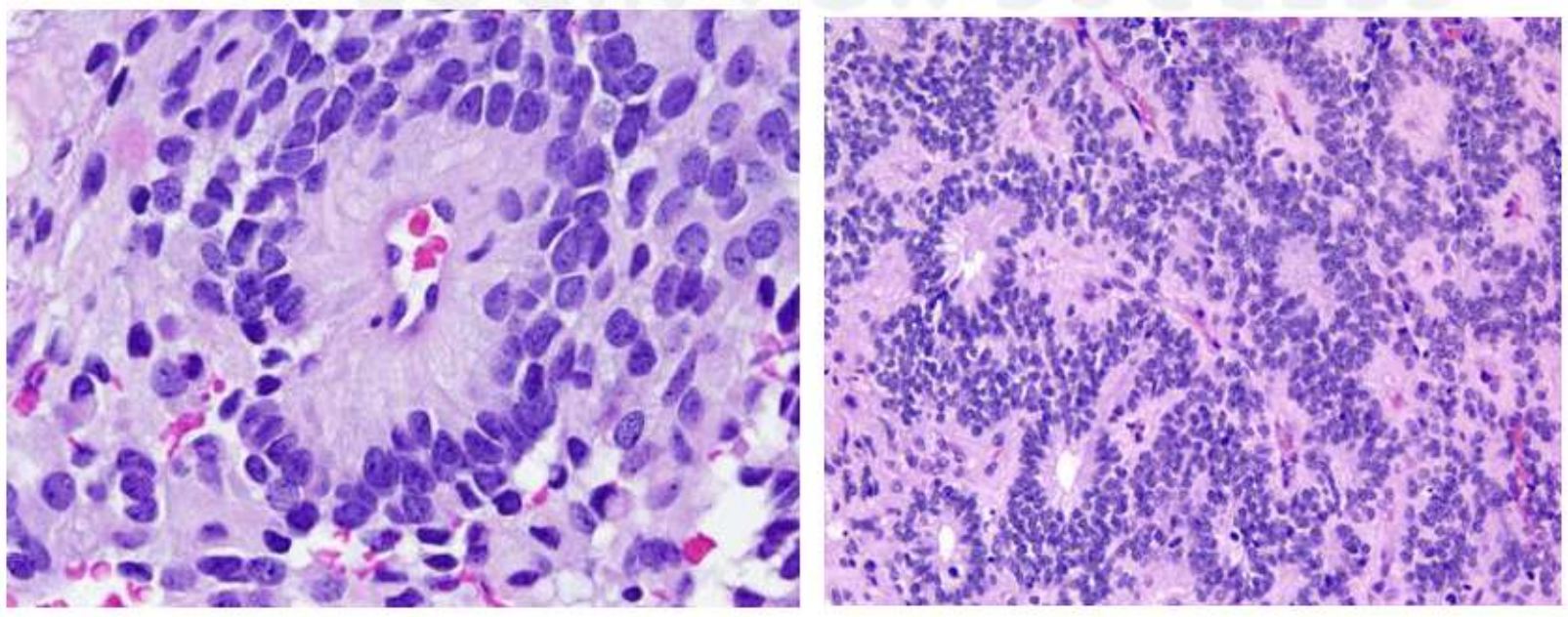

Fig: 1

Histology

i. Myxoid matrix – contains both Neutral and acidic mucopolysaccharides

AfraTafreeh.com

ii. Papillae and Tumor cells surrounding the papilla

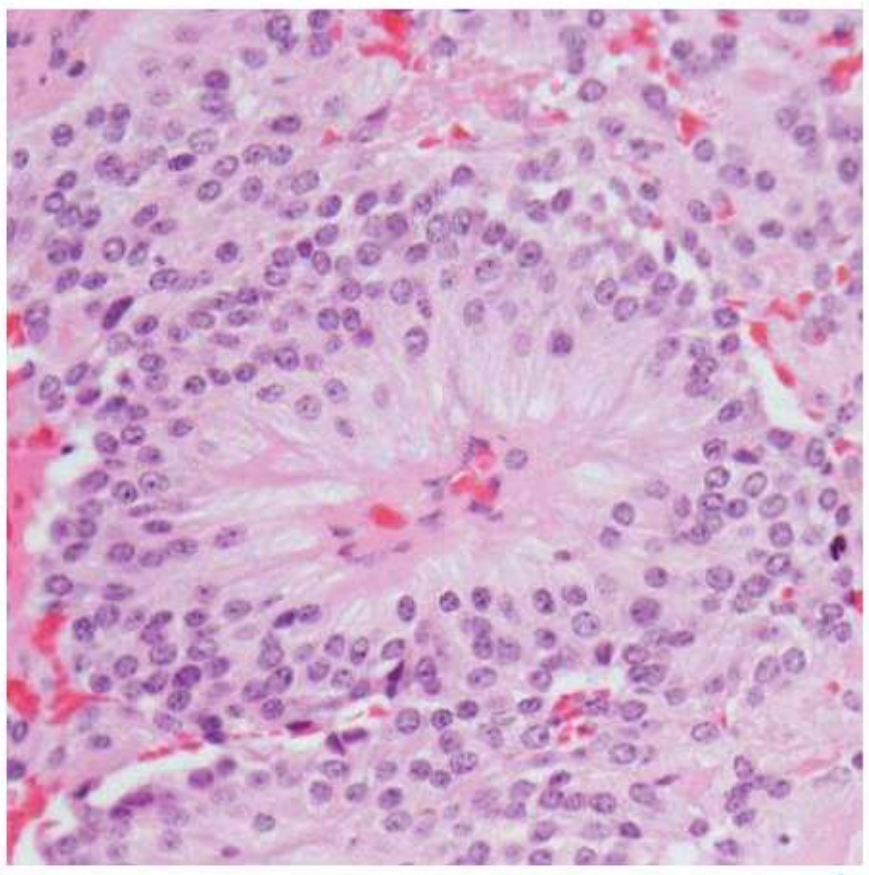

Fig: 2

Variant of ependymal occurring in the spinal cord →

MYXOPAPILLARY EPENDYMOMA

- WHO grade I tumors?
- In Children
- Occurs in filum terminale of the spinal cord
- Papilla with tumor cells and lot of myxoid matrix
- Lots of acidic mucopolysaccharides – stained by Alcian Blue Stain

New updates in ependymoma:

i. YAP_1 gene positivity signifies good prognosis

ii. Variant of ependymoma → RELA mutated ependymoma which occurs in supratentorium and have a poor prognosis

a. **Diagnosis of choice:** FISH (diagnosis of choice) to identify RELA mutation or a surrogate IHC marker – L_1 CAM

Chordoma 00:11:07

- A Differential for Myxopapillay Ependymoma
- Rare type of cancerous tumor that can occur anywhere along the spine, from the base of skull to sacrum
- Approximately may occur at the base of the spine (Sacro-coccygeal region)
- On Histology – special cells called physaliferous cells seen (bubbly cyst)
- Immunohistochemistry Marker- BRACHURY

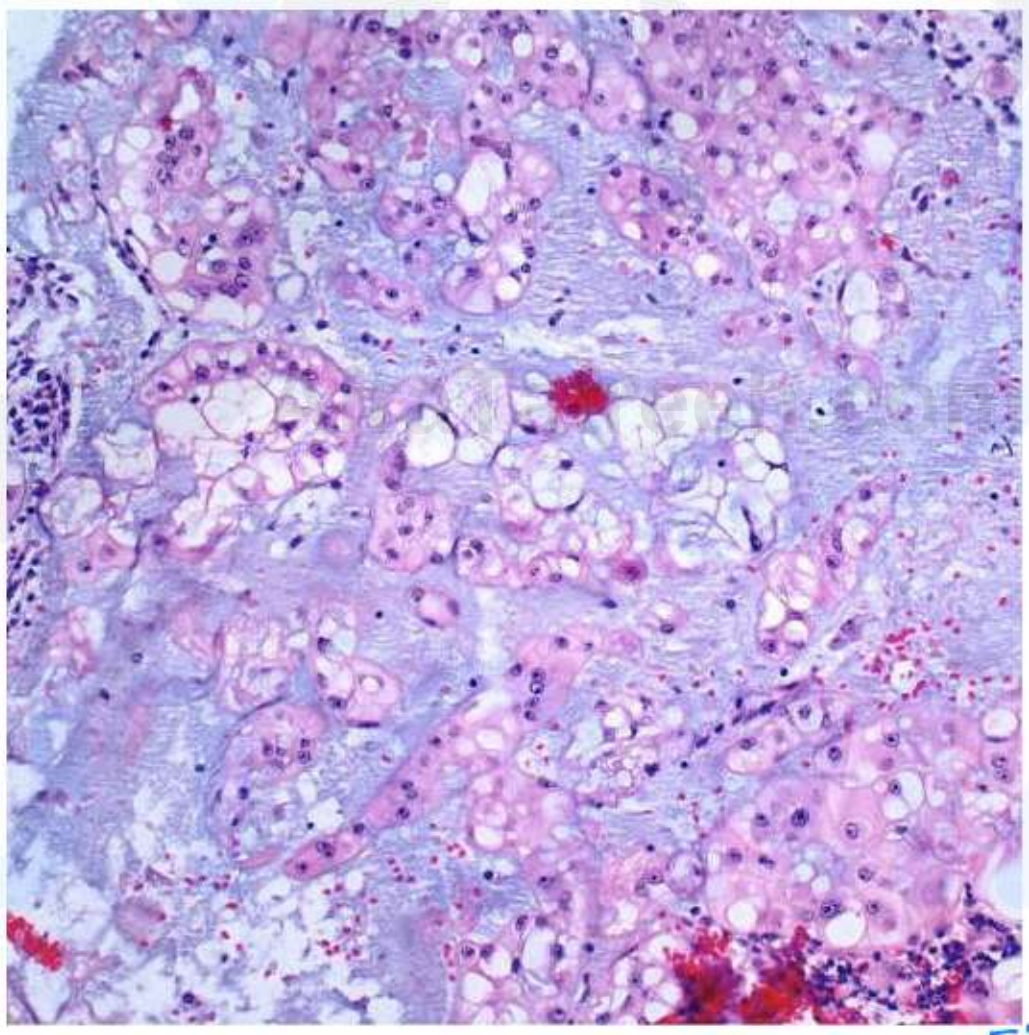

Fig: 3

Colloid Cyst of the Ventricles 00:15:12

- Occurs in temporal lobe
- Typical history of positional headache

AfraTafreeh.com

NEURONAL AND EMBRYONAL TUMORS

a. Gangliogliomas

b. Neurocytomas

c. Gangliocytomas

d. Dysembryoplastic Neuro-ectodermal tumors

Gangliogliomas 00:0050

- Most common type of Neuronal Tumor
- Usually occurs in **Temporal lobes of children & young adults**
- Typical Presentation - **Temporal Lobe epilepsy**
- Gross - Large cyst with Mural Nodule (40-50%) or a Solid Tumor
- Microscopy - **Ganglion Cell + Primitive Astrocytic cell**
- Positively for both Neuronal (NF) and Glial (GFAP) markers

TUTORIALS
LOGIN FOR SUCCESS

Neurocytoma 00:02:46

- Has Neurolytic Rosettes - Large & irregular surrounded by the cells with neurofibrillary substance in the centre

Gangliocytomas 00:03:36

- A variant of Gangliocytoma - Dysplastic Gangliocytoma – It's a rare, slowly growing tumor of cerebellum
- It is associated with PTEN Mutation
- Also called as PTEN Hamartoma Syndrome/Cowden Syndrome/LHERMITTE DUCLOS DISEASE

Dysembryoplastic Neuroectodermal Tumor 00:05:28

- WHO grade I tumor
- Usually occurs in children
- On Histology – shows floating Neurons in a Myxoid Matrix
- Excision is curative

Poorly Differentiated Tumors/Embryonal Tumors

- Medulloblastoma
- Atypical Teratoid/Rhabdoid Tumor

Medulloblastoma 00:08:24

- Most common malignant Brain tumor of Childhood
- Turcot Syndrome (A variant of FAP) is associated with increased incidence of medulloblastoma
- Highly Malignant tumor found in Cerebellum and infratentorial location

AfraTafreeh.com
TUTORIALS
LOGIN FOR SUCCESS

AfraTafreeh.com

- Most Aggressive Brain Tumor of Children
- Predominantly in children (3-4 years)
- Most Radiosensitive Brain Tumor
- Most common Site – Vermis m/c Site in Adult – Lateral cerebellar hemisphere
- Clinical features
  - Child with increased ICT
  - Adults present with ataxia and unilateral dysmetria
  - Dissemination through CSF leading to Drop Metastasis

WHO Classified of Medulloblastoma?

Type I (WNT-Activated Medulloblastoma)

- WNT
  ↓ ⊕
  B-Catenin
  ↓ ⊕
  Transcription factor
  ↓
  Proliferation
- On immunohistochemistry, nuclear positivity of β-catenin can be observed
- Occurs in older children
- Associated with monosomy of Chromosome 6
- Better Prognosis compared to the other types
- It has the morphology of a Classical Medulloblastoma

DOC TUTORIALS LOGIN FOR SUCCESS

Type-II

- **SONIC HEDGEHOG PATHWAY** associated Medulloblastoma
- Occurs in infants & young adults
- SHH Pathway is a very important pathway for morphogenesis of Brain
- PATCHED gene controls activity of SHH Pathway
- If PATCHED gene gets deleted, SHH Pathway becomes over-activated – Gorlin Syndrome
- In Infancy - P53 mutated or P53 wild type – Intermediate Prognosis
- Has N-MYC Amplification
- **Histology**: Nodular Desmoplastic type (because of reticulin)

AfraTafreeh.com

Pale island areas (Rich in reticulin (immature collagen)) between tumor cells

TUTORIALS
LOGIN FOR SUCCESS

Type-III

- Isochromosome 17q w**ith N-MYC activation**
- Worst prognosis
- **Histology**: Clear Cell/Large Cell type

Type IV

- Isochromosome 17q w**ithout N-MYC Activation**
- Intermediate prognosis
- **Histology**: Clear Cell/Large Cell type

AfraTafreeh.com

Morphology of Classical Medulloblastoma

- Blue tumor (SRCT - Small round blue tumor)
- Very Rapidly Proliferative Cells (positive for GFAP)
- Pseudo rosettes (Pink neuronal in centre – has Neuropil) – Homer Wright Rosettes

Neuropil → Negative for Neurofilaments
Blue Tumor cell → negative for GFAP
Metastasis → Drop Metastasis

] Therefore, classified as poorly differentiated tumor also called as Embryonic Tumors

Atypical Teratoid/Rhabdoid Tumors 00:23:45

- Occurs in infant <3 years
- **INI-1 mutation in Chromosome 22**
- **Poorly differentiated**
- Poor prognosis
- On Histology, Rhabdoid cell/Neuronal cell/Glial cell/Mesenchymal cells i.e., named as Teratoid/Rhabdoid Tumor

TUTORIALS LOGIN FOR SUCCESS

Primary CNS Lymphomas (PCNSL) 00:25:40

- Occurs in immunocompromised/Transplant recipient
- Most common site of extra nodal NHL in HIV/ Immunocompromised patient is the Brain (Most common site of extra nodal NHL – Stomach)

- Show a characteristic phenomenon called as **HOOPING** i.e., Tumor cells are arranged around vessels and are separated by a reticulin meshwork.
- Diagnosis by Immunohistochemistry
  - Positive for CD20
- Treat with Rituximab (Anti CD-20 Monoclonal Antibody)
- Poor prognosis

Question hour:

1. **Butterfly tumor - glioblastoma**
2. **Pseudopalisading - glioblastoma**
3. **Perineuronal satellitosis - oligodendroglioma**
4. **Hooping – primary cns lymphoma**
5. **Small round cell tumor of brain - medulloblastoma**
6. H3k27 MUTATION – MIDLINE PONTINE GLIOMA
7. IDH R123H MUTATION – OLIGODENDROGLIOMA and SECONDARY GLIOBLASTOMA

Spotters

1. 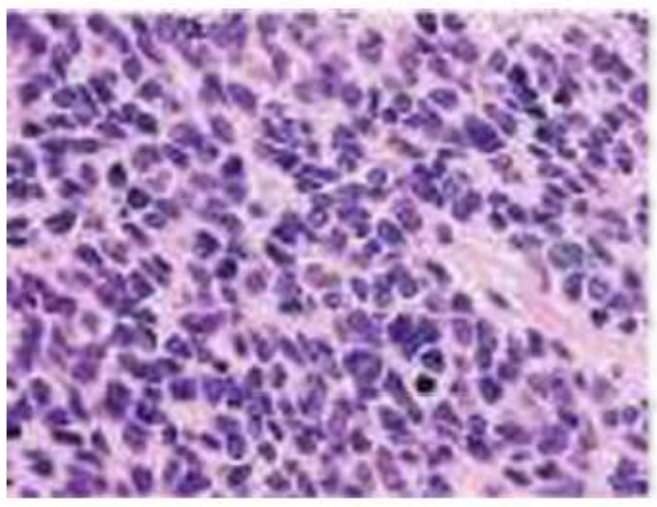 - All tumor cells are small and round - SRCT

AfraTafreeh.com

2. 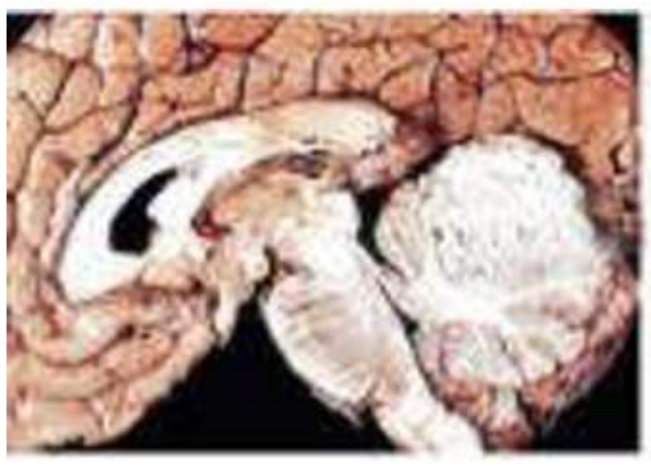 – Posterior Fossa and Solid tumor – Medulloblastoma

3. 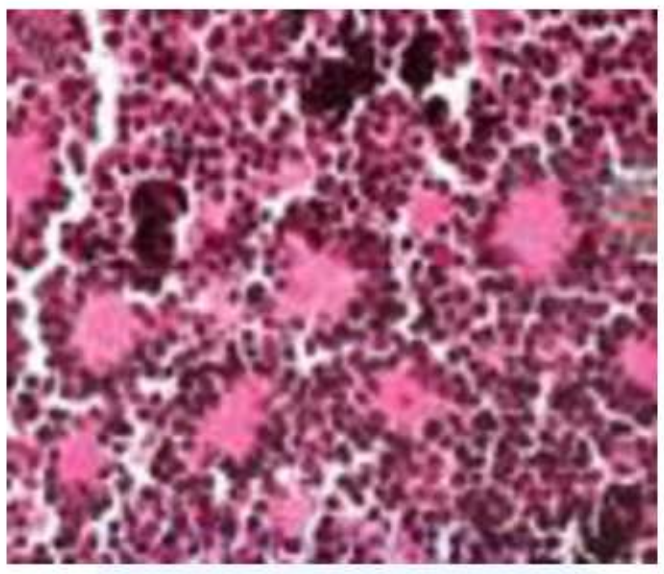 – Rounded and packed, very mitotically active – arranged as rosettes with central pink neurofibrillary substance – Homer-Wright Rosettes

4. 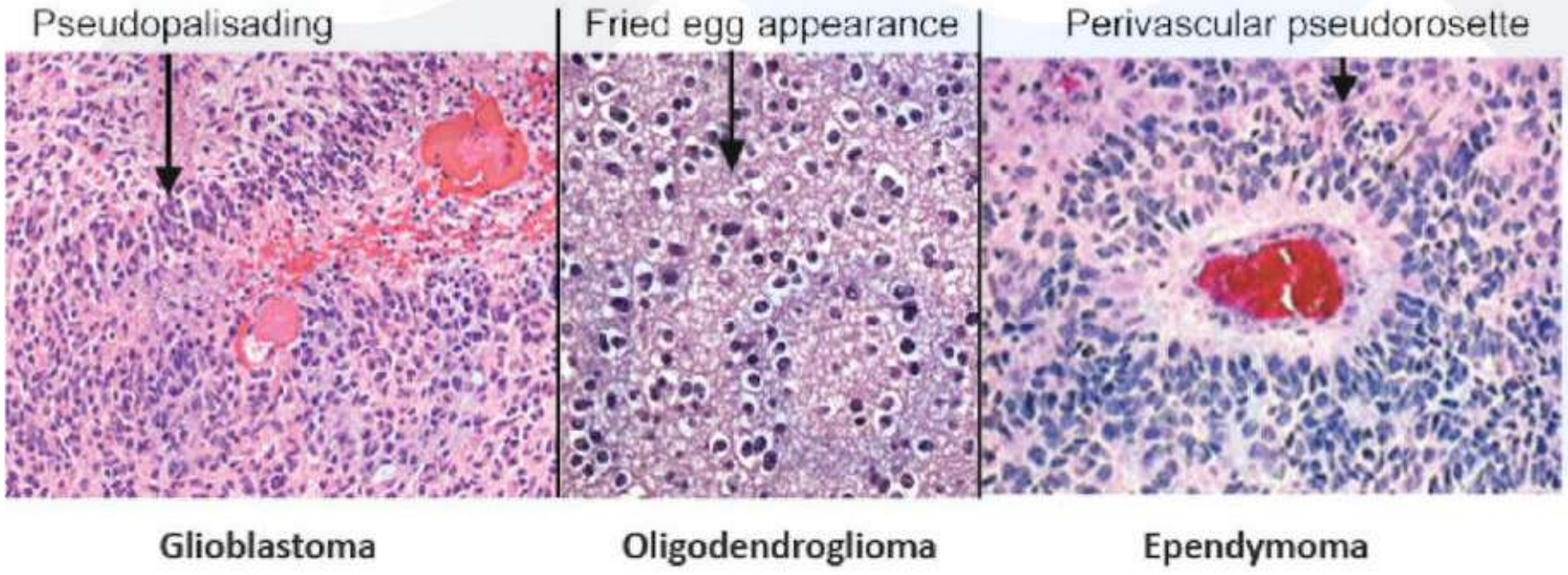

GLIOBLASTOMA; OLIGODENDROGLIOMA; EPENDYMOMA respectively

5. 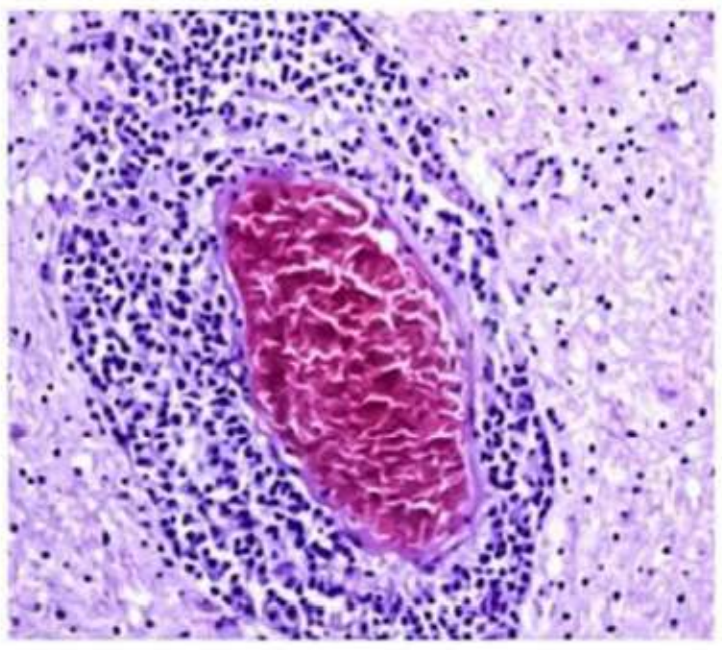

6. 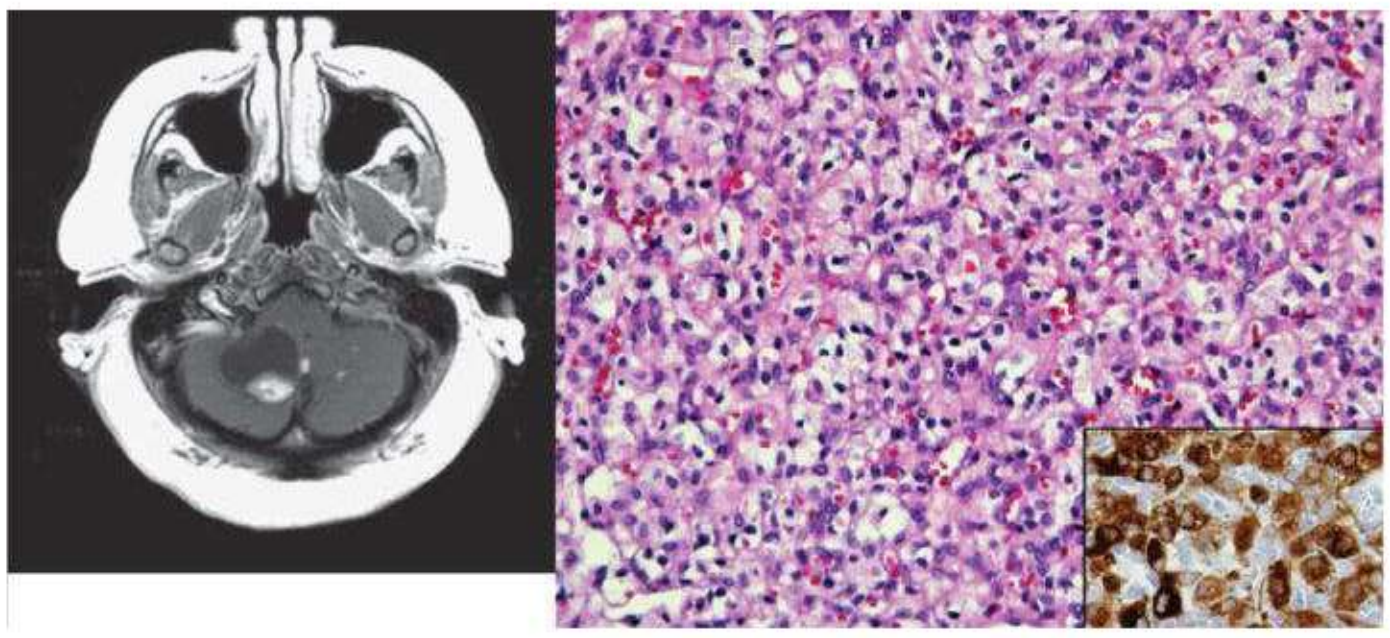

1.cystic tumor with mural nodule – pilocytic asrocytoma, pleomorphic xanthoastrocytoma, hemangioblastoma, ganglioglioma

2.vascularity high – this is a hemangioblastoma

3.confirmation with ihc by inhibin a (yolk-sac tumors of ovary and testis); in patients with bhl mutation

Rosettes In CNS

Rosette type	Definition	Associated tumors
Homer wright rosettes	• Ball like arrangement of cells that enclose meshwork of fibres • Fibres represent primitive neuronal processes	• Neuroblastoma • Medulloblastoma • PNET • Pineoblastoma
Flexner-winterseiner rosette	• Tumor cells circumscribe a central lumen	• Retinoblastoma • Pineoblastoma • Medulloepithelioma

AfraTafreeh.com

	• Lumen contains small cytoplasmic extensions of encircling cells	
True ependymal rosette	• Rosettes with an empty appearing lumen	• Ependymoma
Perivascular pseudorosette	• Spoke-wheel arrangement of cells • Tapered cellular processes radiated around a wall of a centrally placed vessel	• Ependymoma • Medulloblastoma • PNET • Central Neurocytoma • Glioblastoma • Monomorphous Pilomyxoid Astrocytoma
Pineocytomatous and neurocytic rosettes	• Neuropil-rich rosettes similar to homer wright rosettes • Larger and more irregular in contour	• Pineocytoma • Central Neurocytoma

Retinoblastoma: Flexner-Wintersteiner Rosettes

- True Rosette
- Cytoplasmic projections from tumors forms the lumen
- Seen in retinoblastoma.

AfraTafreeh.com
TUTORIALS
LOGIN FOR SUCCESS

AfraTafreeh.com

METASTASIS AND MENINGIOMA

Metastasis in CNS 00:00:07

- Most common tumors of the brain are metastatic tumors to the brain
- Most common site of primary to send metastases to the brain

  1. **Lungs** - Intraparenchymal metastasis especially small cell carcinoma
  2. Breast cancer – Metastases to the Dura (Dural Nodule/Dural Metastases)
  3. Skin - Melanoma – Metastases of individual tumor cells
  4. GIT - Colon cancer
  5. Renal Cell Carcinoma
  6. Choriocarcinoma

  Remember – Prostate cancer can never send metastases to brain
- Metastases to the brain are multiple in >70% of cases
- Location – cerebral hemispheres (80%), mainly the frontal lobes
- Lesion are in the grey matter and white matter junction; well circumscribed and edematous
- If the nodules are very big, central necrosis can be seen in the specimen. (Esp., lesions from GIT)

Fig: 1

Meningioma 00:02:27

- Most common primary brain tumor – meningioma (35%) > glial tumors (30%)
- Benign tumor of brain, usually arises from the arachnoid villi and strongly attached to the dura mater, compresses the underlying cerebrum
- It is a benign tumor of adults and is more common in women
- Meningiomas are the most common intracranial, extra-axial dural based tumor
- Mostly occur along the superior sagittal sinus

AfraTafreeh.com
TUTORIALS
LOGIN FOR SUCCESS

Etiology

- Sporadic meningioma – Radiation Exposure is the most common reason for brain tumors
- Inherited
  - NF2 mutation on chromosome 22
  - Remember: NF2 mutation seen in 3 tumors (Schwannoma, Ependymoma, Meningioma)

AfraTafreeh.com

- Characteristic finding: Increased expression of progesterone receptor, thus this **tumor grows with pregnancy**

WHO Grading of Meningioma 00:06:16

I	II	III
Majority of meningioma are benign and fall under grade I called classical meningioma. Classical meningioma phenotypes included are 1.Meningothelial 2.Fibromatous 3.Psammomatous	Atypical meningioma with a mitotic activity of >4 per 10 high power field Phenotypes are 1.Clear cell 2.Chordoid type	Anaplastic meningioma • Mitotic Activity > 20/HPF • Can even show invasion into the brain • High grade • Rare type with worst prognosis

Gross features of meningioma 00:09:07

- Round encapsulated mass showing characteristic en-masse pattern of growth – plaque like spread → Overlying bone shows localized bony **hyperostosis**
- Attached to the dura mater

Microscopic features of meningioma 00:10:16

- The characteristic feature of meningioma is the presence of desmosomes. The tumor cells grow together appearing like a syncytium and form meningothelial whorls
- As the tumor grows, it's growing away from the vascularity – Psamomma Bodies (Dystrophic calcification around blood vessels).

Diagnosis 00:11:53

- Immunohistochemistry – Positive for EMA (Epithelial membranous antigen)
- Psamomma bodies (Dystrophic calcification around blood vessels)

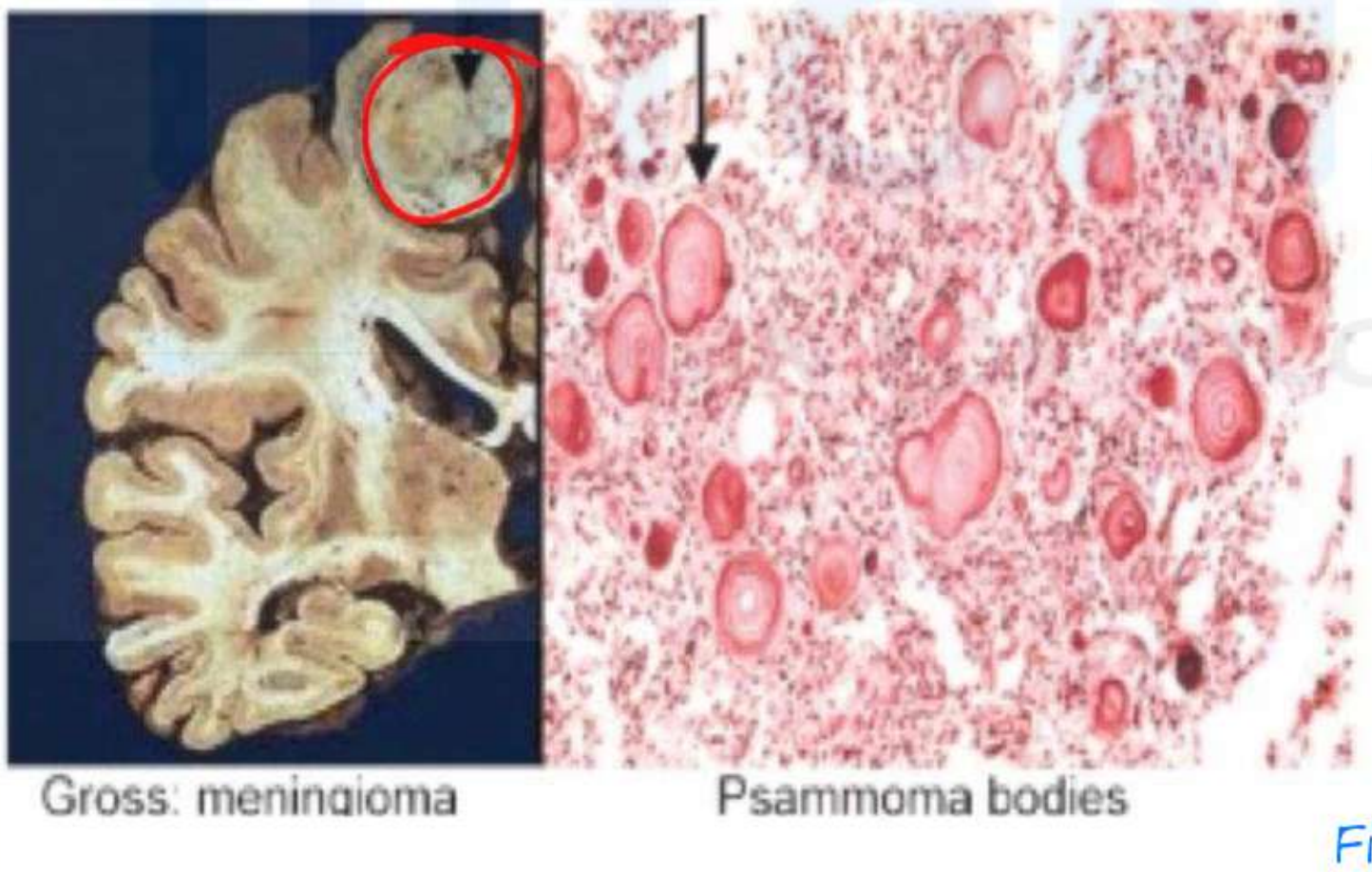

Fig: 2

- Meningothelial whorls with EMA positivity on Immunohistochemistry

AfraTafreeh.com

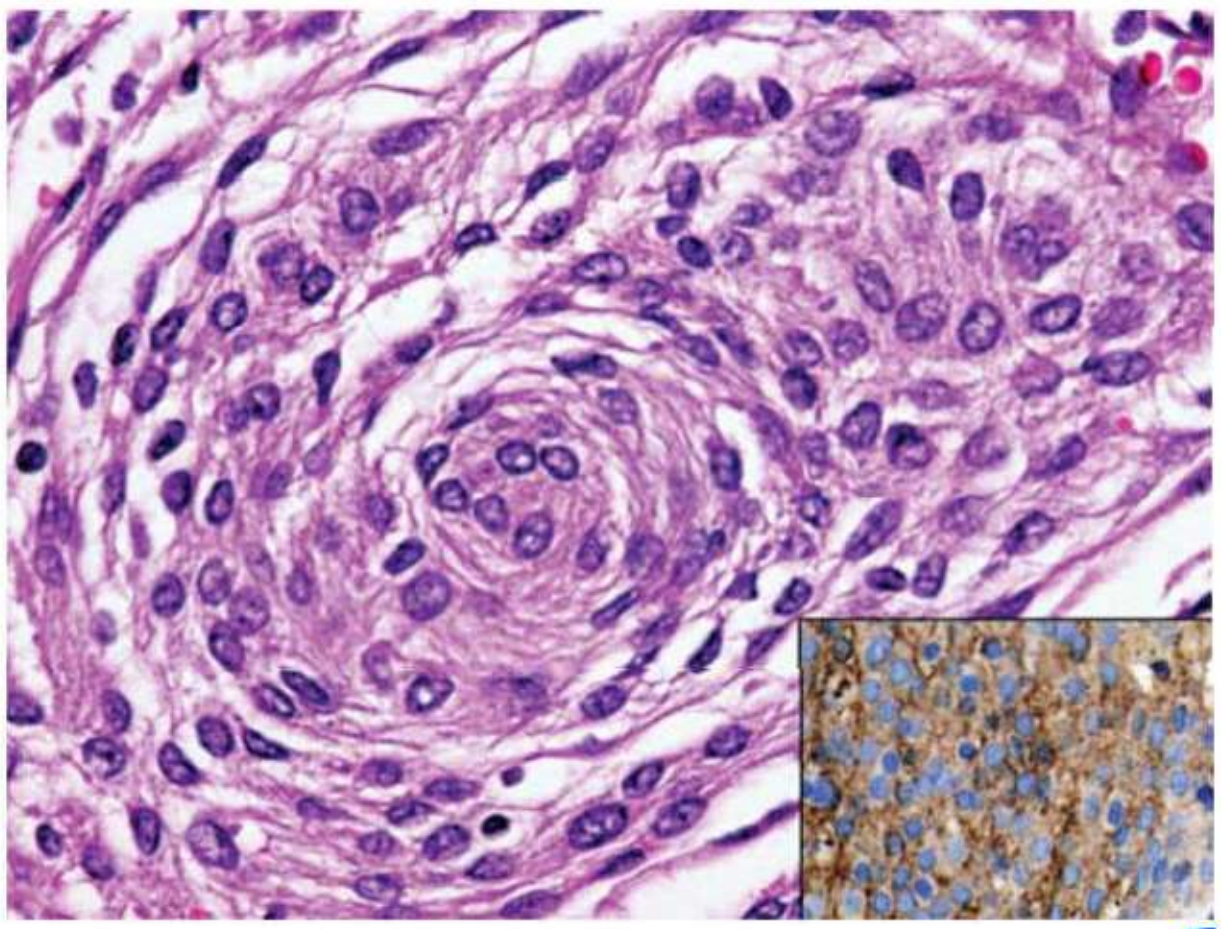

Fig: 3

- Electron microscopy showing desmosomes

Fig: 4

Treatment of Meningioma

- Surgical resection is the treatment of choices

TUTORIALS
LOGIN FOR SUCCESS

NERVE TUMORS

Nerve Tumors

Neurofibroma	Schwannoma
Cause: NF_1 gene mutation • Tumor mingles between nerve fibres (can't be separated from the nerve) • Non-capsulated tumor • Product of NF_1 is Neurofibroma	Cause: NF_2 gene mutation • Tumor is separate from the nerve's fibres • Capsulated tumor • Product of NF_2 is Merlin

AfraTafreeh.com

Histopathology 00:00:07

Neurofibroma

- Contains spindle shaped wavy cells
- Contains lots of collagen fragments between spindle shaped wavy cells giving a **shredded carrot appearance**

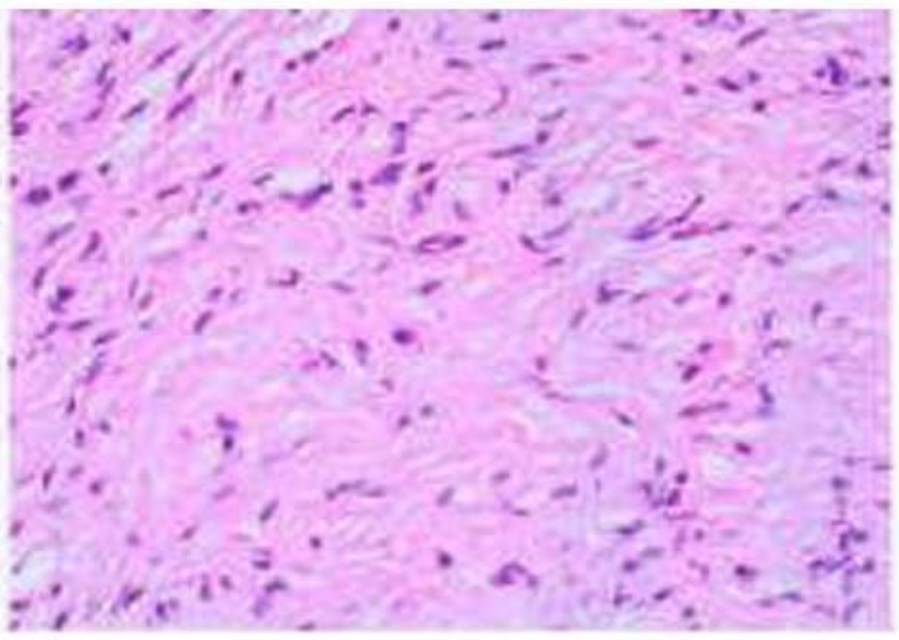

Fig: 1

TUTORIALS LOGIN FOR SUCCESS

AfraTafreeh.com

Schwannoma

Has 2 areas

- Antoni A – Hyper-cellular area
- Antoni B – Hypo-cellular area

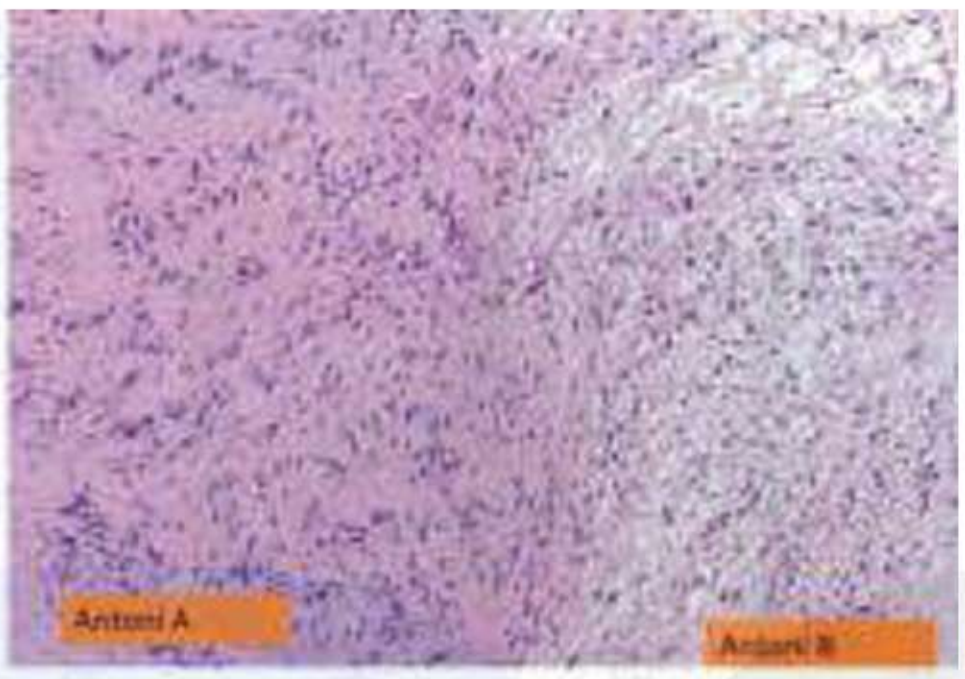

Fig: 2

Hyper cellular areas/Antoni A

- Contains Verocay bodies
- Verocay bodies contains palisaded nuclei – tumor cells
- Pink matrix between palisaded nuclei

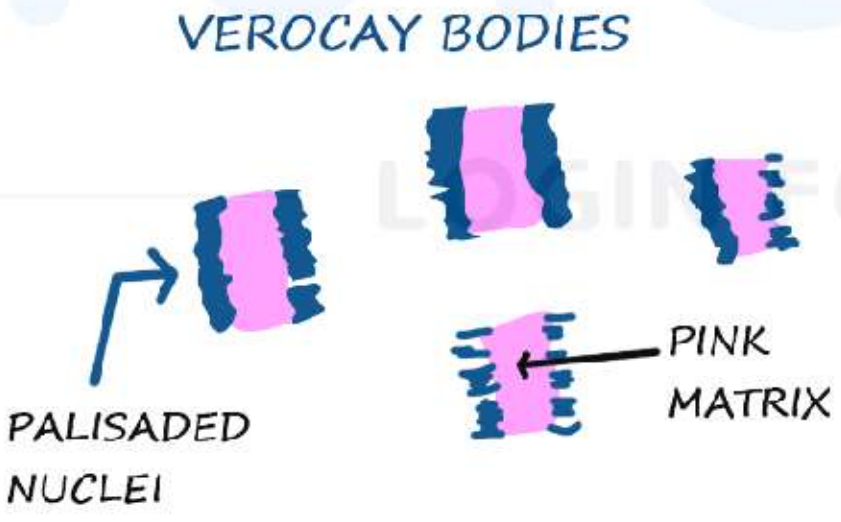

Gross – Schwannoma are glistening white tumors

Markers

- S100
- SOX10

- Markers for neural tissue
- Positive for both neurofibroma and schwannoma and hence, cannot differentiate both the tumors

Stains for differentiation

i. Bielschowsky stain – For the neurofilaments
   a. If the stain appears intermingled, then it is Neurofibroma
   b. If the stain appears compressed in the periphery, it is a Schwannoma

ii. Calretinin
   a. It is moderate positive in schwannoma
   b. It is --/very dim in neurofibroma
   c. Also, a marker of mesothelioma

Variants

Plexiform Neurofibroma 00:12:31

AfraTafreeh.com

- Thickening of nerve takes place
- Perineurium is intact even after formation of tumor cells
- Proliferation of collagen, nerve cells, myxoid matrix in perineurium – causing a thickened, nerve fiber
- Individual nerve bundles appear thickened
- Not capsulated as perineurium is involved instead of the nerve fibre. Due to thickened nerve fiber, the distortion of specimen takes place
- Gross Appearance

DOC TUTORIALS LOGIN FOR SUCCESS

AfraTafreeh.com

In microscopy

Fig: 3

- Individual thickened muscle fiber is seen
- Appears like "bag of worms"
- Mutation of NF_1 gene in neurofibroma or in plexiform neurofibroma has high chances of transformation into malignancy or a tumor called MPNST (Malignancy peripheral nerve sheath tumor)

MPNST (Malignant Peripheral Nerve Sheath Tumor) 00:16:40

- Mutation of NF_1 gene
- History of preexisting nerve sheath tumor

(Woodruff's criteria)

Malignant Triton Tumor 00:18:35

- Presence of skeletal muscle differentiation
- MPNST + Rhabdomyoblasts

Neurothekoma 00:20:04

- Tumor with a lot of myxoid matrix and hence it is also known as nerve sheath myxoma

Summary

- Carrot shredded Appearance – Neurofibroma
- Antoni A, Antoni B, Verocay bodies - Schwannoma
- Bag of worms – Plexiform NF
- NF_1 gene mutation – MPNST
- Triton – MPNST + Skeletal muscle differentiation/Rhabdomyoblasts
- Neurothekoma – Nerve Sheath Myxoma

AfraTafreeh.com
TUTORIALS
LOGIN FOR SUCCESS

AfraTafreeh.com

CRANIOPHARYNGIOMA

Introduction 00:00:07

SEEN IN PAEDIATRIC AGE GROUP

- Benign Cystic Lesions
- Second peak of incidence around 50 years of age
- Derived from Rathke's pouch and arise near the pituitary stalk extending into Suprasellar cistern
- Occurs in Sellar/Suprasellar Locations
  - Presents with Visual Disturbances/Headaches (due to raised ICT)
- WHO Grade I Tumor
- Associated with Calcifications
- Mutation of β-Catenin Gene
- Diagnosis of Choice – FNAC
  - Machinery Oil Aspirate (Presence of Cholesterol Granules)

Microscopy of Craniopharyngioma 00:01:55

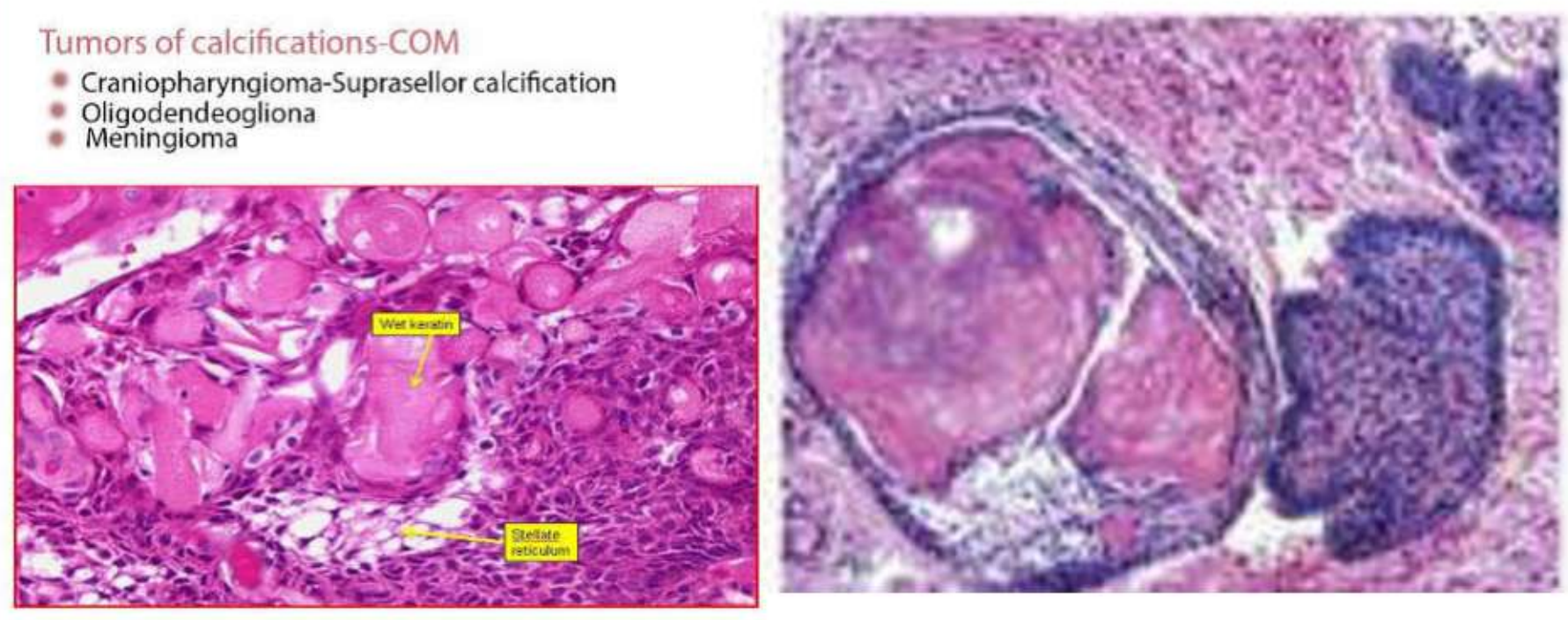

Fig: 1

1.Palisading of the Epithelium and Reversed Polarity

2.Net/Stellate Reticulum seen just below the Epithelium

3.Enucleate Squamous Cells/Ghost Cells (wet keratin) seen below the Reticulum.

Tumors showing ghost cells

i. Craniopharyngioma

ii. Pilomatrixoma in skin

AfraTafreeh.com
TUTORIALS
LOGIN FOR SUCCESS

AfraTafreeh.com

CNS HEMORRHAGES

- The Brain is covered by Meninges – Pia Mater, Arachnoid Mater, Dura Mater (Inside to Outside)

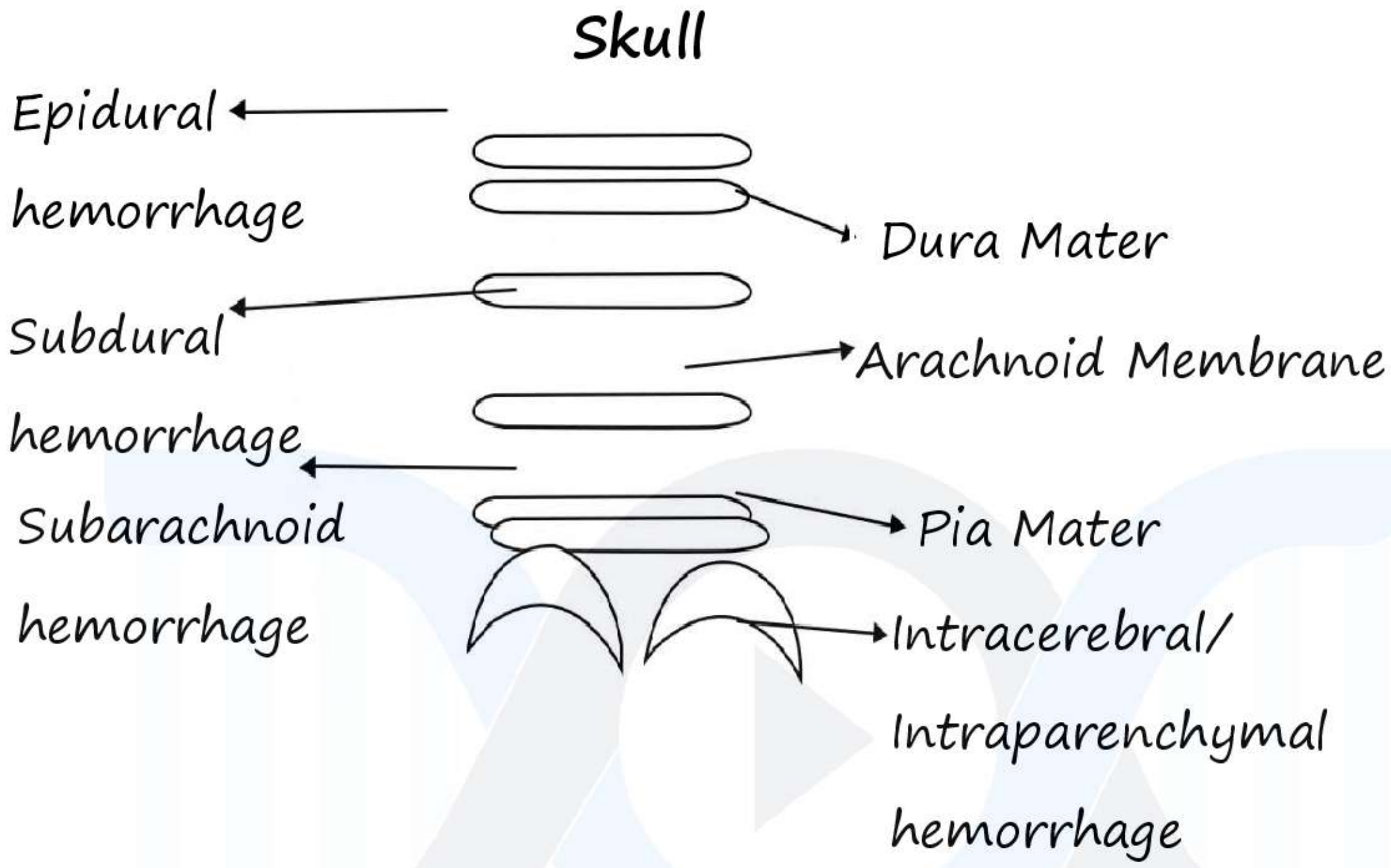

Epidural Hemorrhage Fig: 1

Subdural Hemorrhage Fig: 2

Epidural Hemorrhage	Subdural Hemorrhage
Haematoma accumulates between bone & dura	Haematoma accumulates between Dura and arachnoid
Rupture of middle meningeal artery (MMA) (Arterial bleed)	Rupture of cortical bridging veins (venous bleed)
Nearly always associated with a skull fracture	Nearly always associated with significant primary brain injury
More common in young male patients - More characteristic - lucid interval (period of consciousness between 2 unconscious period)	
M/C site - temporal - pterion thinnest part of skull overlying M.MA	
CT Findings – Lentiform (Lens shaped - biconvex hyperdense lesion)	**CT Findings** - Concavo-Convex hyperdense lesion
NEUROSURGICAL EMERGENCY – REQUIRES IMMEDIATE SURGERY	

AfraTafreeh.com
TUTORIALS
LOGIN FOR SUCCESS

AfraTafreeh.com

Subarachnoid Haemorrhage 00:06:13

- Below Arachnoid Mater
- Most Common Causes of Spontaneous SAH
  - Rupture of berry aneurysm (80%)
  - A.V. Malformations (10%)

Berry Aneurysm (SACCULAR ANEURYSMs)

- Congenital aneurysm; Can also be associated with atherosclerosis
- Basic defect is in the Tunica Media and the internal elastic lamina (between Tunica Intima and Tunica Media) of the blood vesse

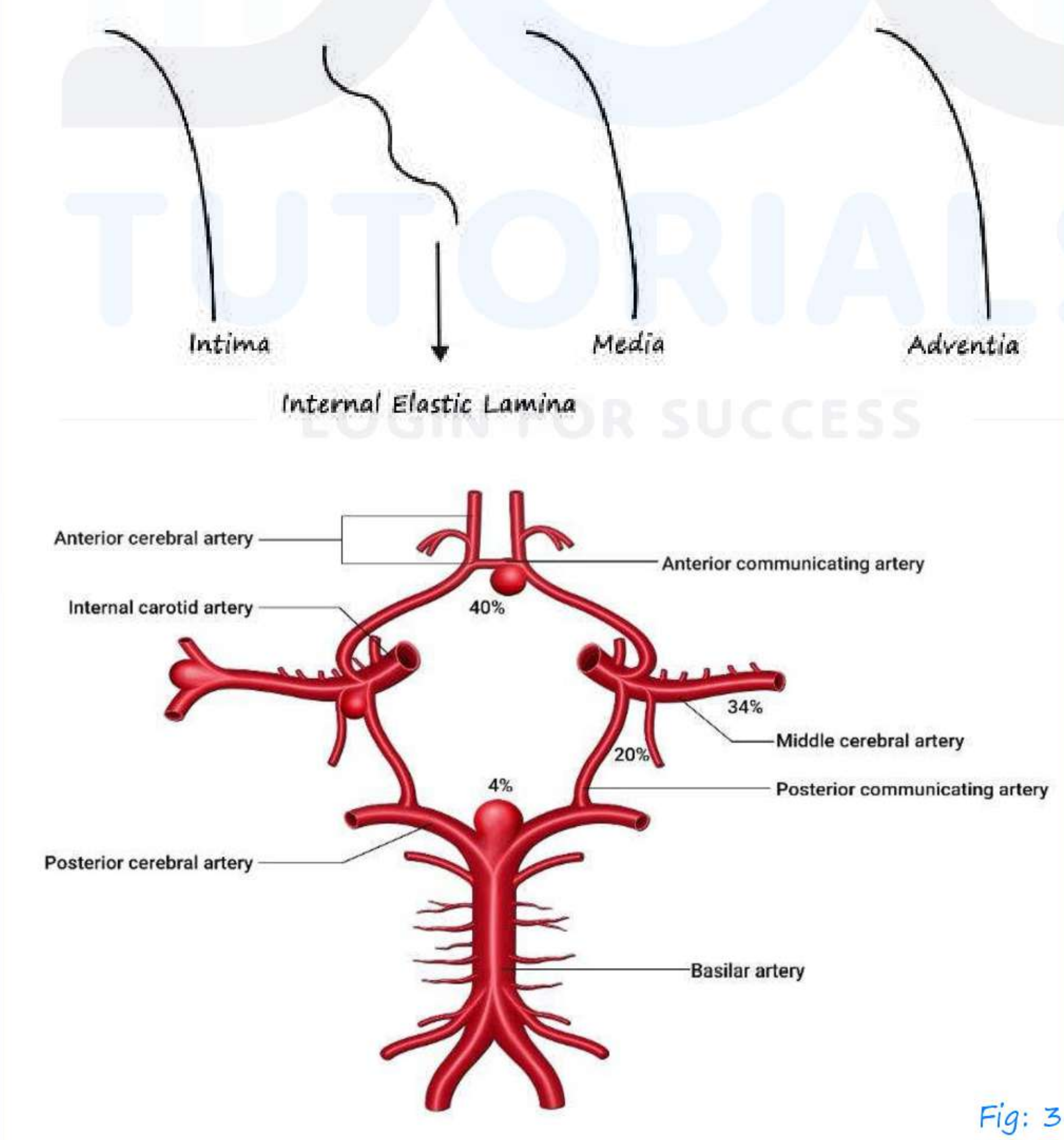

Fig: 3

- Most common site of berry aneurysm – Junction of anterior cerebral artery and anterior communicating artery in the Circle of Willis

  ↓

  Tunica media is very fragile at this junction and flow of blood is rapid
- Least common site → vertebral artery

Foix Alajouanine disease

- AV malformation of the spinal card
- Lower thoracic and/or lumbosacral levels
- Masses of enlarged, tortuous and thick-walled subarachnoid veins are observed overlying the surface of the cord (primarily on the posterior aspect)

AfraTafreeh.com
TUTORIALS
LOGIN FOR SUCCESS

Intra Cerebral Hemorrhage 00:10:53

Causes of Intracerebral Hemorrhage

- Hypertension (Most common cause)
- Central amyloidosis deposition of amyloid around vessels of brain
  - Alzheimer's
  - Elderly
- CADASIL

AfraTafreeh.com

Hypertension causes

1. Hyaline arteriosclerosis or lipohyalinosis 2. Charcot–bouchard aneurysm usually occurring in lenticulo-striate branch of middle cerebral artery ↓ Rupture → haemorrhage most common site – basal ganglia (putamen)	Repeated episodes of Hypertensive bleed and Thrombosis causes hypertensive encephalopathy ↓ Progressing to dementia called Binswanger dementia

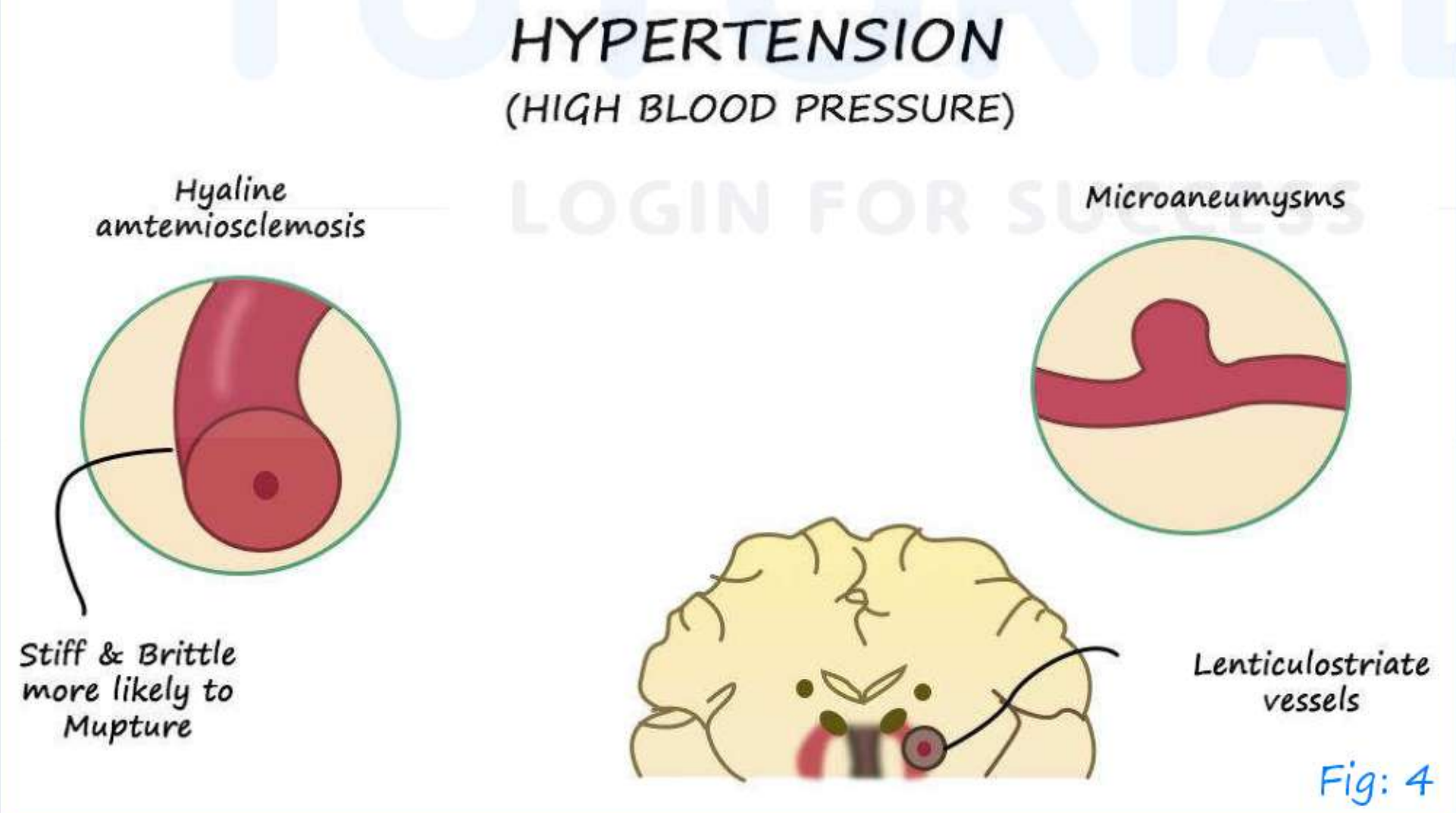

Fig: 4

i. Cerebral amyloid angiopathy (CAA)

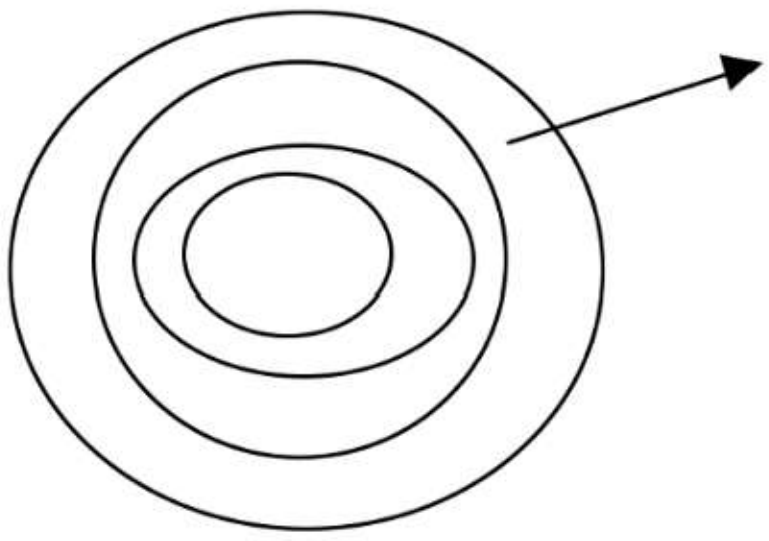

Deposition of amyloid Aβ40 in tunica media and adventitia of small vessels of brain

↓

Tunica Media becomes weakened and becomes prone to rupture and haemorrhage

- Staining with CONGO RED → Salmon red color
- Causes Lobar ICH
- Has Temporal and Occipital Affinity
- Seen in Elderly Patients

AfraTafreeh.com

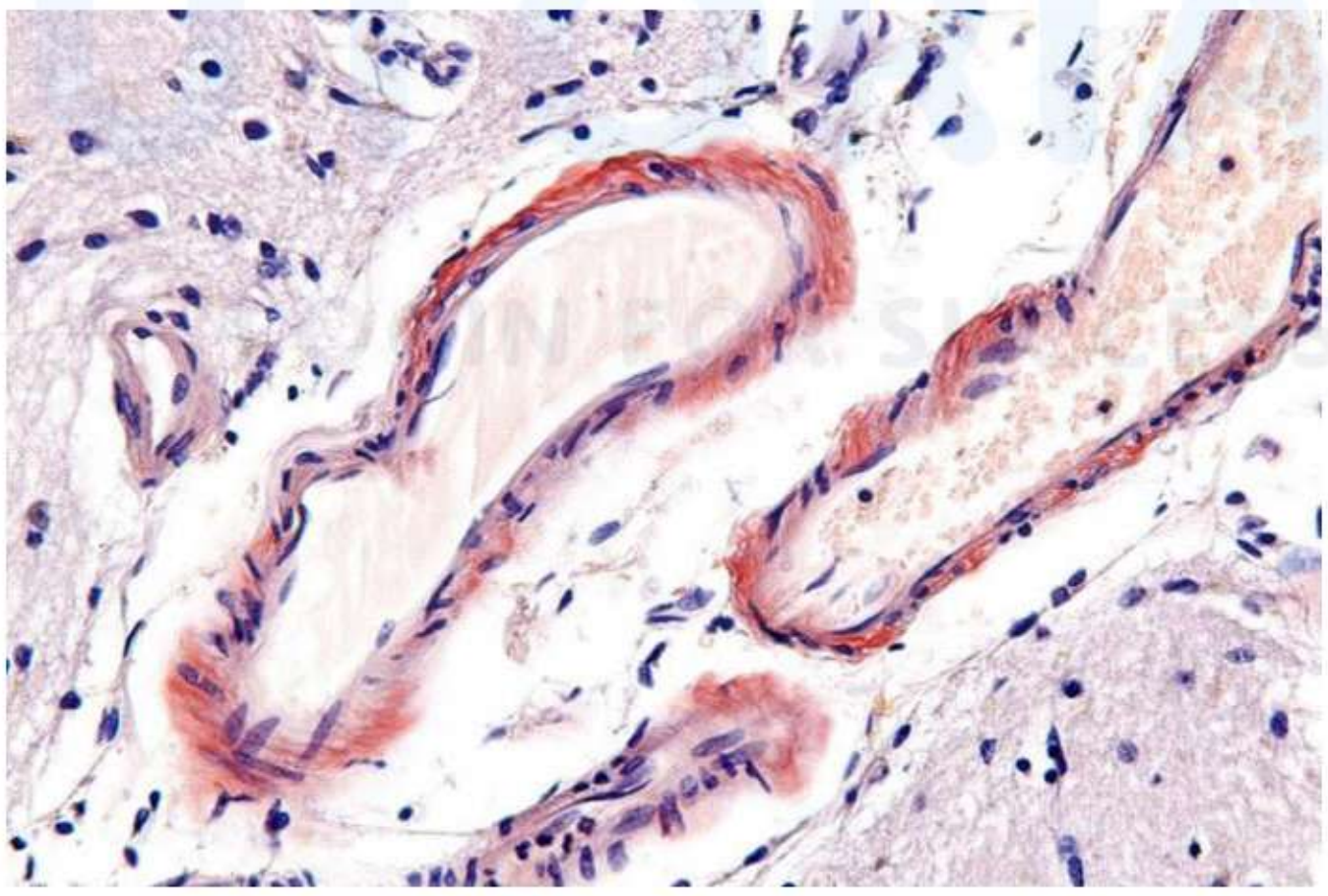

ICH Fig: 5

AfraTafreeh.com

ii. CADASIL

CADA - Cerebral autosomal dominant arteriopathy with **SIL** - Subcortical infarcts and leukoencephalopathy

- Occurs due to mutation of notch3 receptor [notch receptors are very important for proper development of blood vessels]
- Apoptosis of smooth muscle of vessels (tunica media)
- Deposition of blue granular material in vessel wall electron microscopy image

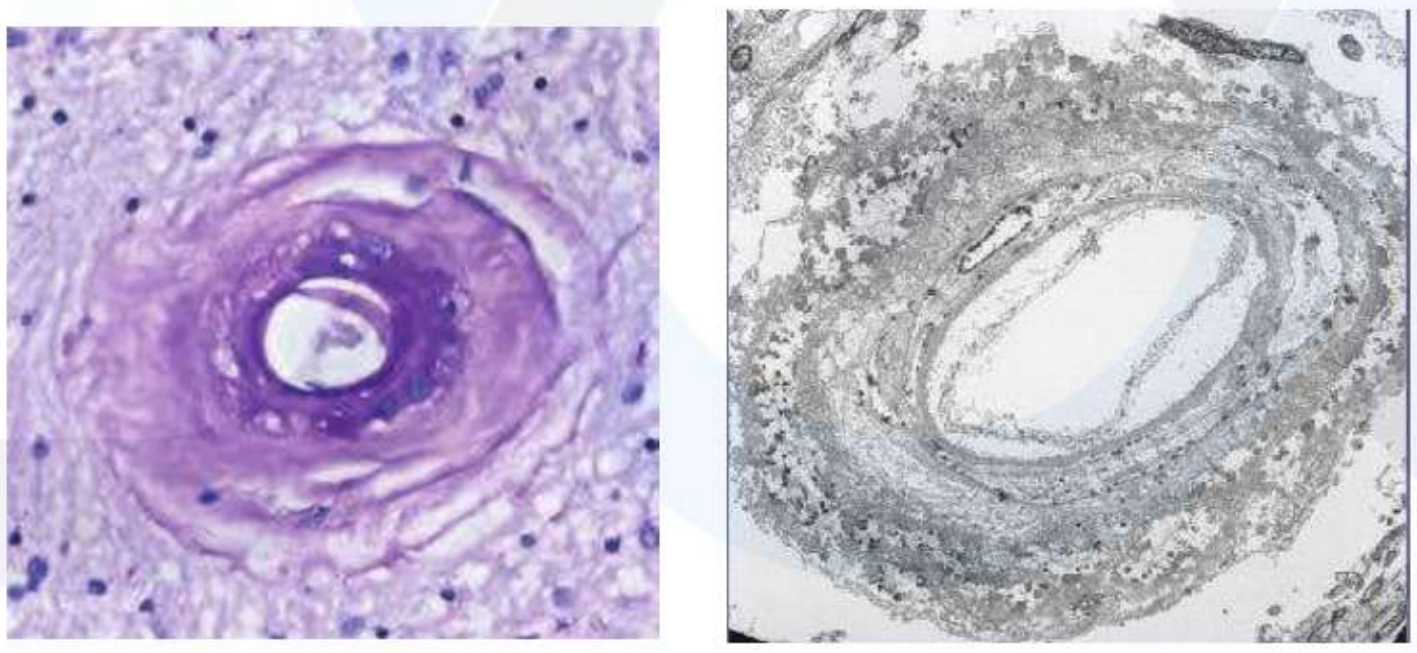

Fig: 6

Type of Hemorrhage	Seen in
EDH	Rupture of Meningeal Artery
SDH	Rupture of Bridging Veins
SAH	Traumatic Rupture of Berry Aneurysm or AV Malformations (Foix Alajouanine Disease)
ICH	HTN (Charcot-Bouchard aneurysm) Cerebral Amyloid Angiopathy ($A\beta40$ Deposition) CASADIL (mutation of notch 3)

Petechial Hemorrhage	Fat Embolism
Duret Hemorrhage	Sudden Herniation (Pons/Midbrain)

Petechial Hemorrhages 00:23:17

- P inpoint Hemorrhages seen in fat embolism

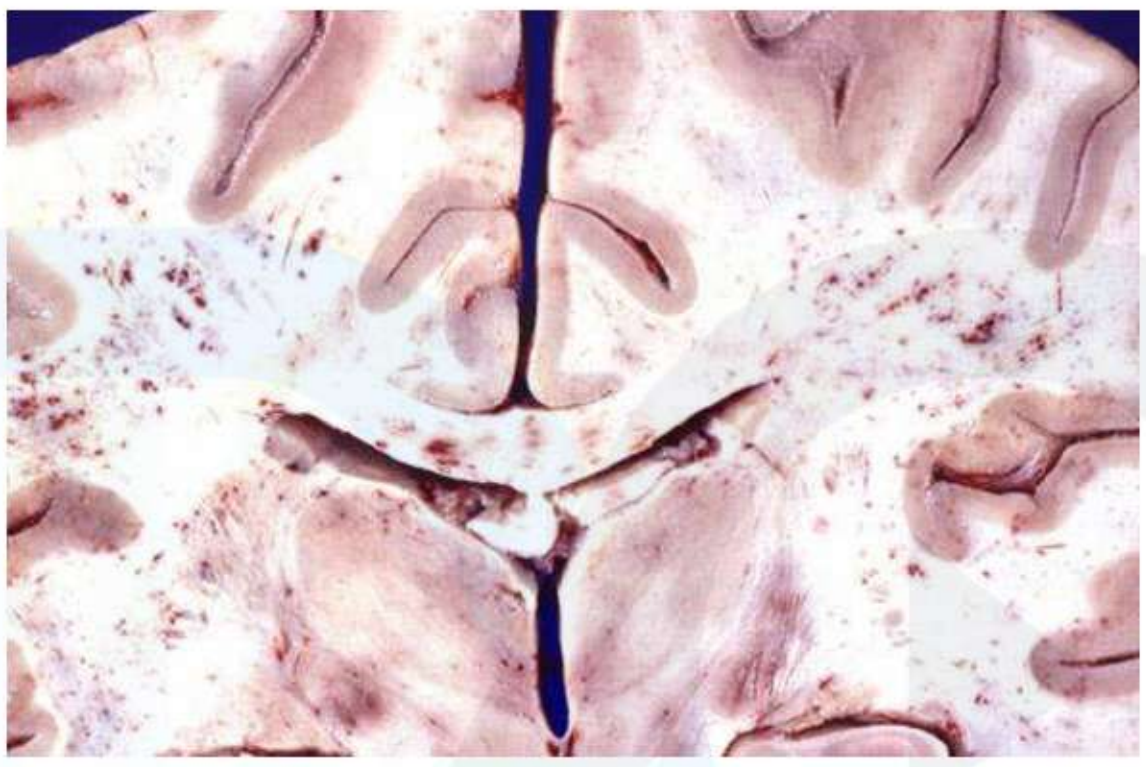

Fig: 7

AfraTafreeh.com

Duret Hemorrhages 00:23:57

- A Type of linear hemorrhages occurring in pons and midbrain as a result of sudden herniation of the brain
- Named after Duret, who identified it

TUTORIALS LOGIC FOR SUCCESS

Duret Hemorrhages Fig: 8

AfraTafreeh.com

ALZHEIMER'S DISEASE

Alzheimer's Disease 00:00:30

Most common cause of Senile dementia

- Degenerative Neuropathy
- More common in 60+ years and the Male gender
- Alzheimer's disease is now classified under proteins Misfolding defects

Etiology of Alzheimer's Disease 00:00:07

Sporadic (Late Onset)	Hereditary/Familial (Early onset)
• >65 years of age • Multifactorial Disorder • ApoE4 Gene Mutation on Chromosome 19 (Strongest Risk)	• <65 years of age • Mutation of Presenilin 1 (PS-1) on Chromosome 14 (most common) • Presenilin 2 (PS-2) Chromosome 1 • APP (Amyloid Precursor Protein) gene on chromosome 21

- Many SNPs (Single Nucleotide Polymorphisms) are being studied with GWAS (genome wide association

studies) to find association with Alzheimer's Disease (Late Onset)

- **Early Onset Alzheimer's**: PS1 ≥ APP ≥ PS2

Pathogenesis of Alzheimer's Disease 00:07:55

- Amyloid plaques formation → main pathogenesis event in Alzheimer's
- APP (Amyloid Precursor protein is normally present in the brain
- Three Types of Secretases are present in Brain (Alpha, Beta and Gamma)

APP

α
↓
Acted upon by γ Secretase
↓
No amyloid

β
↓
Acted upon by Gamma Secretase
↓
Aβ amyloid

Aβ40
↓
Associated with Cerebral Amyloid angiopathy
↓
Cerebral hemorrhage

Aβ42
Key initiator of plaque formation (Neurodegeneration)

AfraTafreen.com
TUTORIALS
LOGIN FOR SUCCESS

- Alpha – α-secretase breaks APP in Centre
- Beta – β-secretase breaks APP in Periphery

AfraTafreeh.com

- Aβ pathway is the amyloid pathway. Newer Therapies targeting β secretase & ϒ secretase are under study to prevent amyloid production in the brain
- Aβ40 typically deposits around blood vessels (Cerebral Amyloid Angiopathy) – Prone to Cerebral Hemorrhage

Histopathology of Alzheimer's Disease 00:20:07

- Amyloid plaques deposited outside neurons activates kinesis which phosphorylates TAU proteins

Hyper-phosphorylated TAU proteins

TAU TAU

TAU

- Microtubules (important for motility) are normally stabilized by TAU Proteins
- Aggregation of TAU proteins causes **disorganization of microtubules** into **Neurofibrillary Tangles (Hyper-phosphorylated TAU)**

NFT (intracellular)

↓

Interrupted Transmission of Action Potentials in the neuron

↓

Apoptosis of the Neuron

↓

NFT (Extracellular) due to Neural damage

↓

Neurodegeneration

Classical Presentation: Dementia due to loss of neurons

A. Neurofibrillary Tangles are not specific for Alzheimer's. They are also seen in Fronto-temporal Dementia

a. Neurofibrillary Tangles correlate with the severity of dementia (can also be highlighted by Bielschowsky stain)

B. When microtubules are defective, other proteins can also become defective. Actin can polymerize and form crystalline inclusions in the brain – Hirano Bodies (Eosinophilic cytoplasmic crystals of actin)

C. Vacuolization can also occur in neurons – Granulo-vacuolar Degeneration (Normal in ageing but excessive in Alzheimer's)

Arshafreeh.com

All The Changes Seen in Alzheimer's Disease

00:26:50

DOC TUTORIALS LOGIN FOR SUCCESS

PLAQUES (MOST IMPORTANT)

A. **Diffuse Plaques**

a. Aβ deposition

b. Seen in Alzheimer's Disease and also in the brain of Down's Syndrome (Trisomy 21)

AfraTafreeh.com

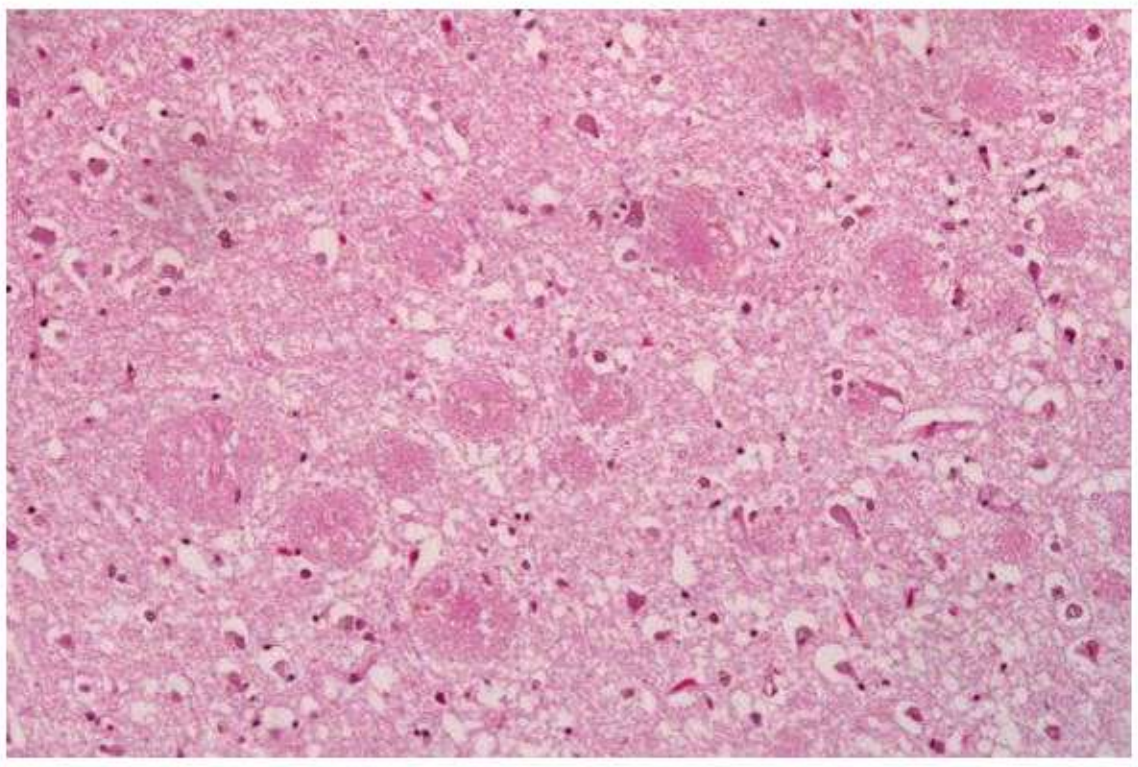

Fig: 1

B.Neuritic Plaques

a. Deposition of Aβ and lots of neurites responding to the deposits

b. Seen in Alzheimer's Disease

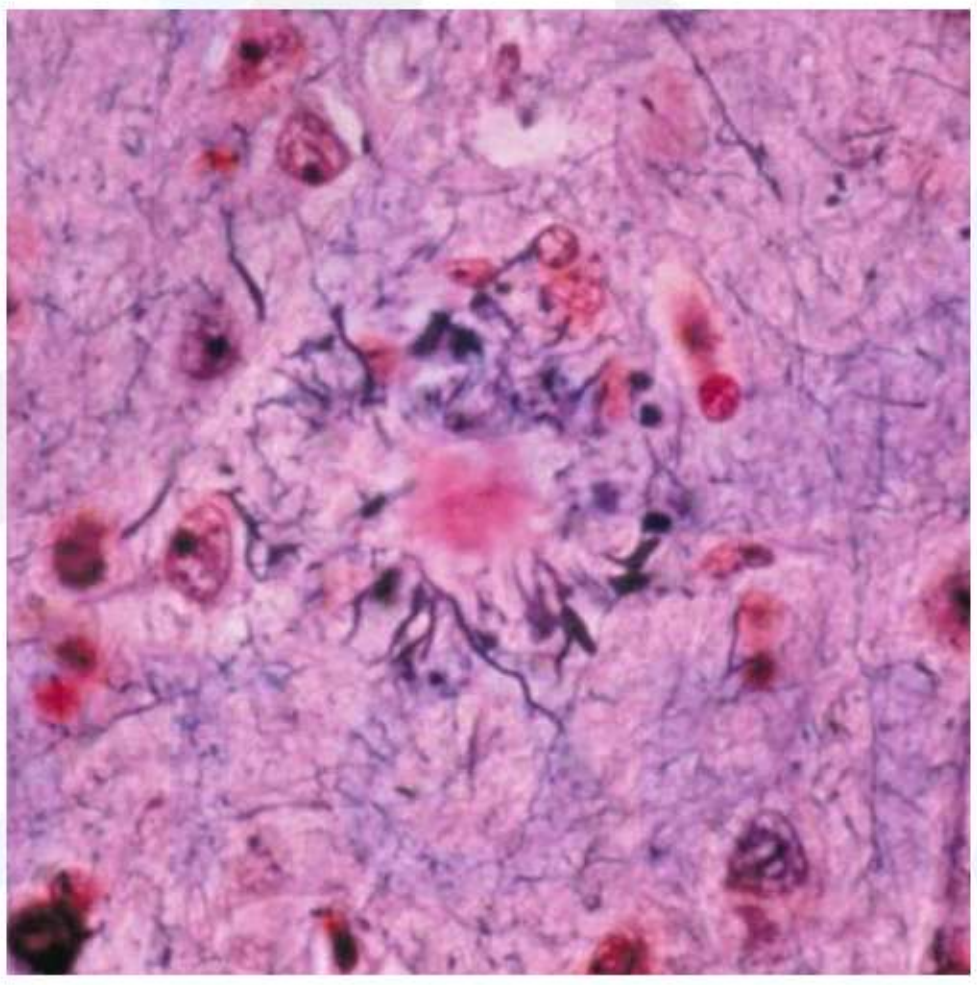

Fig: 2

LOGIN FOR SUCCESS

c. Stain for Amyloid – Congo red

d. To differentiate between Diffuse and Neuritic Plaques – Bielschowsky Stain is given – Gives a typical black colour to the neurites

C.NEUROFIBRILLARY TANGLES

D. CEREBRAL AMYLOID ANGIOPATHY

E.HIRANO BODIES

F. GRANULO-VACULAR DEGENERATION

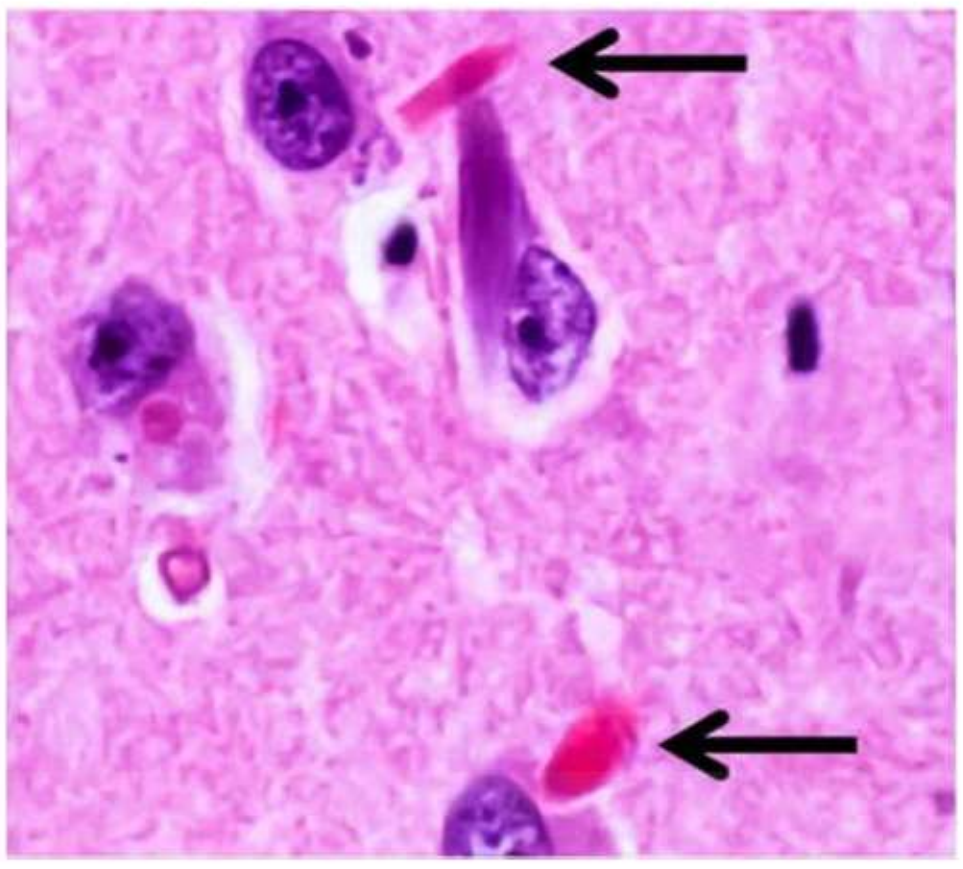

Fig: 3

(NEUROFIBRILLARY TANGLES AND CRYSTALLINE HIRANO BODIES)

Morphological Changes in Alzheimer's Disease

00:32:13

AfraTafreeh.com

1. Flattening of Gyri
2. Widening of Sulci
3. Dilated Ventricles – Hydrocephalus (Ex Vacuole)
4. Earliest site of cortical atrophy → Entero-rhinal area of medial temporal lobe

TUTORIALS LOGIN FOR SUCCESS

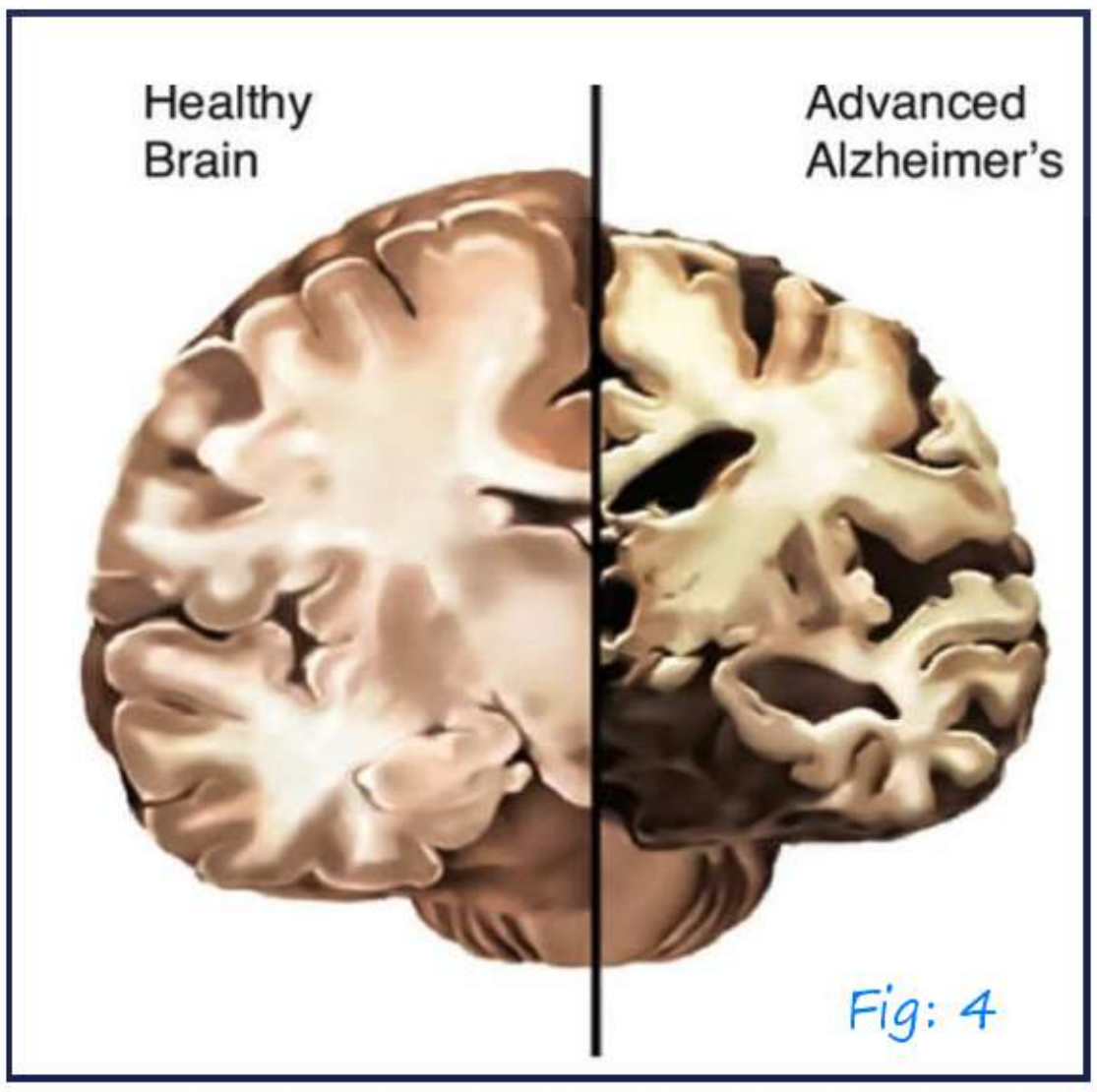

Fig: 4

AfraTafreeh.com

Clinical Features of Alzheimer's 00:34:35

Short term memory loss	Motor skills affected	Long term – Memory loss and Mental retardation	Infections ↓ Most common cause of death in Alzheimer's is aspiration pneumonia

PROGRESSION OF ALZHEIMER's DISEASE
→→→→→

Key points

- Gene PS1 > APP > PS2
- Sporadic more common – SNP/ApoE4
- Therapies against Beta and Gamma secretases
- PS1 and PS2 mutations have altered gamma secretases which facilitates Aβ deposition
- Brain Biopsy is diagnostic of Alzheimer's Disease
- Down's syndrome
  - Pre-existing third copy of APP in Down's Syndrome (APP is on Chromosome 21, Down's in Trisomy 21) ensures that patients with Down's develop Alzheimer's after 40 years of age
  - Higher presence of APP – Higher Activity of Secretase – Higher formation of Amyloid – Higher chance for Amyloid Deposition

Binswanger disease (Sub-cortical leuko-encephalopathy) 00:40:05

- Sub-cortical arteriosclerotic encephalopathy
- Associated with hypertension
- Generally, affects patients > 55 years of age
- Slowly protrusive vascular dementia
- Involves white matter (Which distinguishes it from multi-infarct dementia and lacunar infarcts)
- Diagnosis – Peri-ventricular hyper intense lesions on MRI/Hypo intense lesions on CT

AfraTafreeh.com
TUTORIALS
LOGIN FOR SUCCESS

AfraTafreeh.com

PRION DISEASES

Prion disease 00:00:05

a. Due to infectious proteins (altered proteins)

b. Very long Incubation Period - ranging from months to years

c. Invariable fatal termination

Etiology Of Prion Disease

Etiology

- Genetic predisposition
- altered immune response
- contamination

Mechanism: Mutation of PRNP gene on chromosome 20

- Mutation is single nucleotide polymorphism at codon 129 → replacement by methionine or valine (homozygous for methionine/valine or heterozygous for methionine and valine) → Predisposes to the formation of one β pleated sheet
- Prion disease is also transmissible. Infection either by iatrogenic/traumatic routes can cause induction of normal α helical proteins into infective β pleated sheets
- Most common prion disease in Humans is sporadic form of CJD

Pathogenesis of Prion Disease 00:00:26

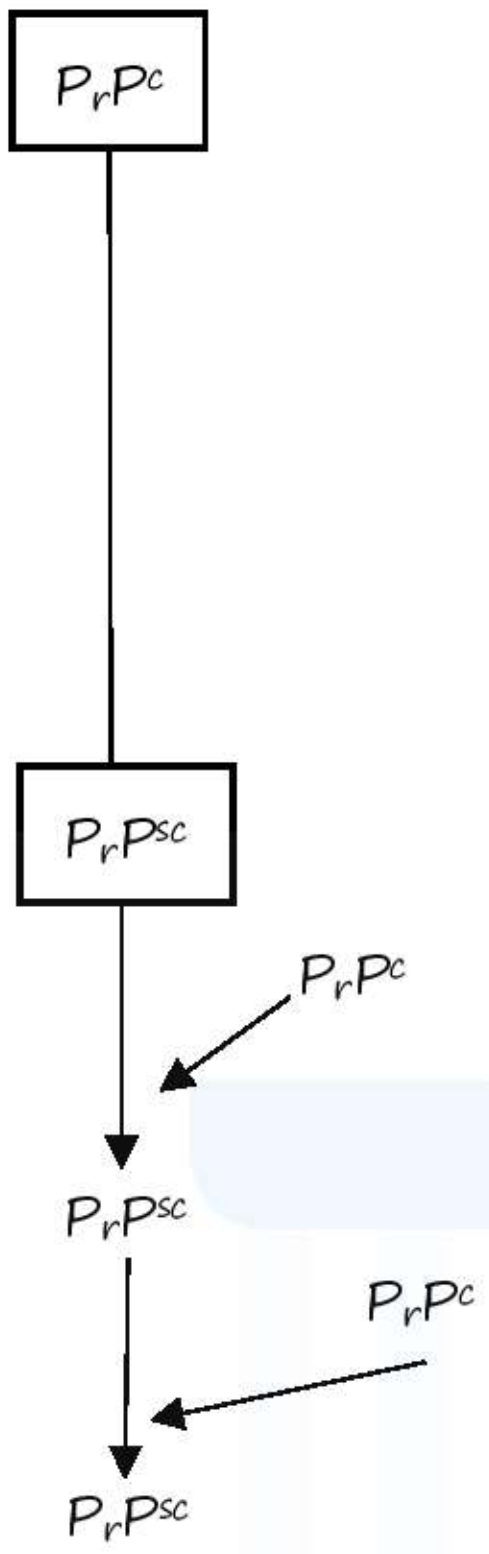

a. Normal prion protein (PrP^c)

b. α helical protein

c. Sensitive to hydrolysis by physiological proteases

i. Mutation or

ii. Contamination

- Intragenic example: Neurosurgery with contaminated instruments
- Corneal transplantation
- Cannibalism

Abnormal prion protein (Sc-stands for scrapie)

i. α helical protein mutated to β pleated sheets

ii. Resistant to the action of Proteases

AfraTafreeh.com

Histological Features of Prion Disease

Cluster of grape like vacuolation

↓

Spongiosis – Intercellular Edema (Hallmark of prion disease)

↓

Hence, the name of prion disease is Transmissible Spongiform Encephalopathy

- Intercellular Edema and Vacuoles formation in the neurons and neuropil. Resembles a fatty change in the brain (which is not physiological)
- ALL PRION DISEASES EXCEPT FATAL FAMILIAL INSOMNIA SHOW SPONGIOSIS

TUTORIALS LOGIN FOR SUCCESS

AfraTafreeh.com

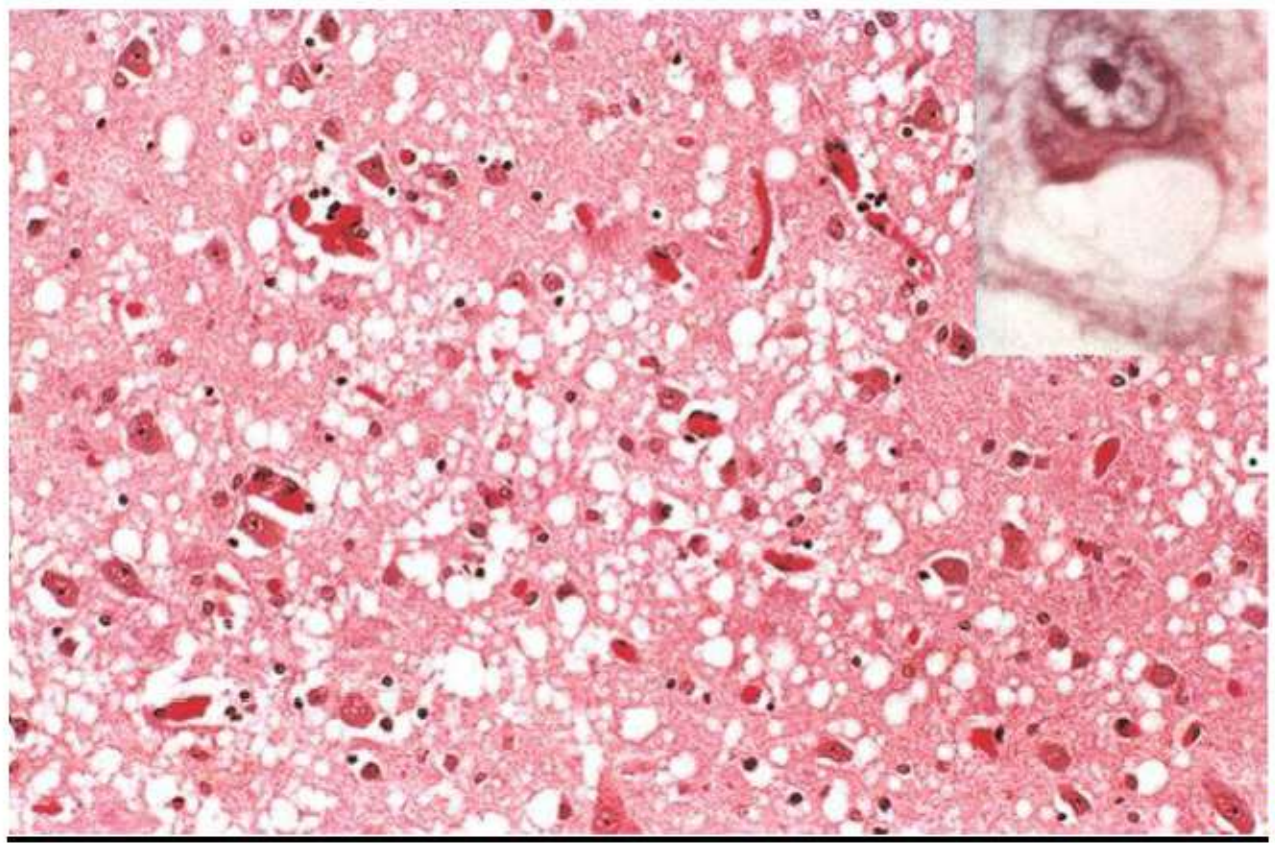

Fig: 1

Other histological features

- Amyloid deposition seen in biopsy of brain with surrounding vacuolation

↓

Seen in brain biopsy of Kuru & Variant Creutzfelt-Jakob Disease

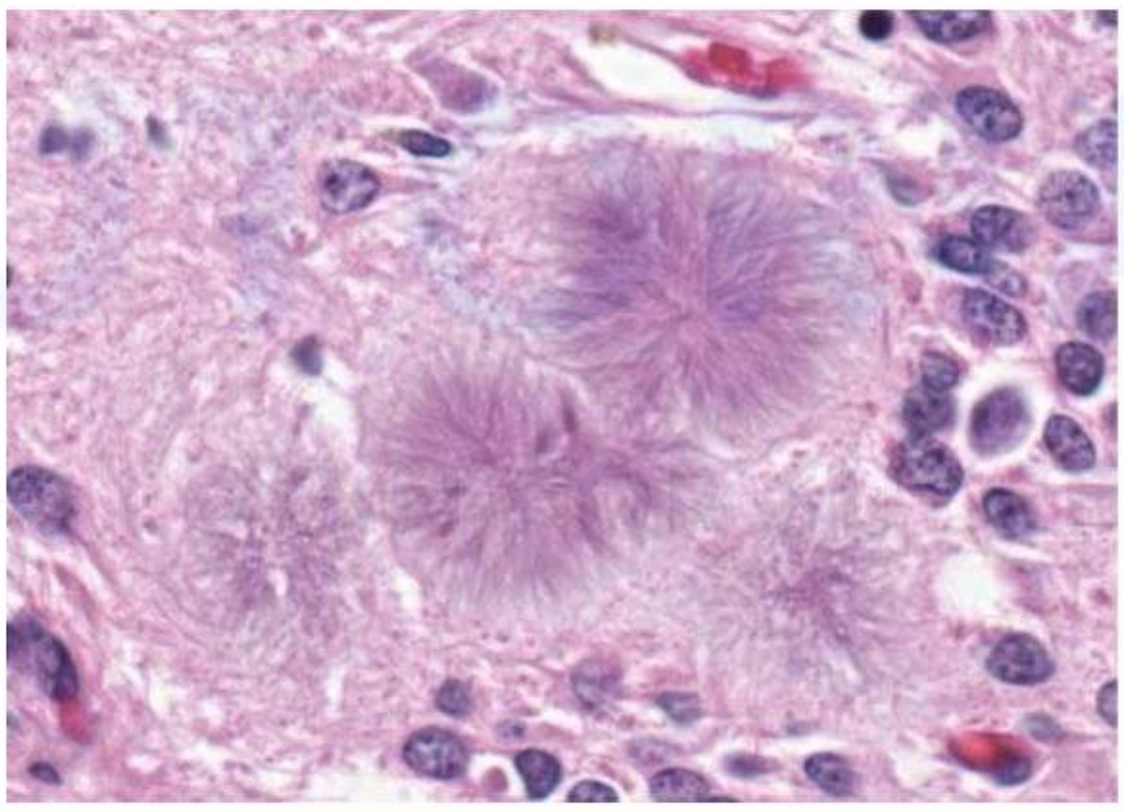

Fig: 2

↓

Vacuole formation is seen around the amyloid plaque (SPONGIFORM CHANGE - HALLMARK FEATURE OF PRION DISEASE)

DEPOSITION OF THE AMYLOID PLAQUES IS RESPONSIBLE FOR THE NEURONAL DAMAGE AND PROGRESSIVE DEMENTIA IN THESE PATIENTS

Classification Of Prion Disease 00:07:23

Prion Diseases of Animals

i. Scrapie Disease in Sheep
ii. Bovine spongiform encephalopathy (BSE)
iii. Mink Transmissible encephalopathy
iv. Chronic Wasting Disease (Disease of Deer and Elk)

Prion Diseases of Humans

i. Creutzfeldt-Jakob Disease
ii. Gerstmann-Straussler-Scheinker Syndrome (GSSS)
iii. Fatal Familial Insomnia
iv. Kuru
v. Variant CJD (in victims who eat BSE infected animals)
vi. Iatrogenic CJD
vii. Familial CJD

AllaTafreen.com
TUTORIALS
LOGIN FOR SUCCESS

Clinical Features of Prion Disease 00:18:10

Creutzfeldt Jakob disease (CJD)

- Sporadic form of prion disease
- Seventh decade of life
- Nervousness, anxiety

AfraTafreeh.com

- >90% patient exhibit startle myoclonus which persists during sleep unlike other involuntary movements
- Ataxia, Visual symptoms, Rapidly progressive dementia
- ECG shows generalized periodic (one per second) triphasic waves

Bovine Spongiform Encephalopathy (VCJD)

- From consumption of infected cows/cattle
- Affects younger patients > 26 years
- Clinical feature: Psychiatric manifestations (Aggression, Depression), Painful Sensory Stimuli
- On Biopsy – Spongiosis + Kuru plaques

Iatrogenic CJD (ICJD)

- Corneal Transplants, prion contaminated human growth hormone, Dura mater graft, Infected implantable electrodes
- PrP^{Sc} is now being found in lymphoid tissues (Spleen, tonsils etc.)
- Also being transmitted by Blood Transfusions
- Cerebellar manifestations (Ataxia) are predominant
- Formation of Amyloid plaques

DOC TUTORIALS LOGIN FOR SUCCESS

Fatal Familial Insomnia 00:29:50

- Mutation in PRNP Gene at Codon 178 (Single Nucleotide Polymorphism) (Asparagine instead of the normal Aspartate) accompanied by methionine at 129
- Doesn't show spongiosis, it shows Gliosis

Diagnosis of Prion Disease 00:24:40

Diagnosis of choice - Western blot documenting proteinase resistant proteins
(Use fluorescently tagged proteases)

Newer diagnostic techniques - CSF examination

- Increased neuron specific enolase (NSA)
- Increased protein 14-3-3

AfraTafreeh.com
TUTORIALS
LOGIN FOR SUCCESS

Key points:

- Gene PRNP-SNP @ codon 129 (Methionine/valine)
- Also called as transmissible spongiform encephalopathy
- Every Prion Disease shows spongiosis except fatal familial insomnia (Gliosis is the feature of Fatal Familial Insomnia)
- Diagnosis of choice – Western Blot plaque
- Kuru plaques test positive for Congo Red and PAS stain

AfraTafreeh.com

BASICS OF BLOOD VESSELS

Blood Vessels 00:00:06

1. Basics Of Blood Vessels

Blood Vessels
↓
3 Types

Arteries ↓
- High Pressure Vessels

Capillaries ↓
- Present between arteries and veins (connects them)
- Pressure between arteries is decreased by capillaries
- Usually present inside the organs or near end organs

Veins ↓
- Low Pressure Vessels

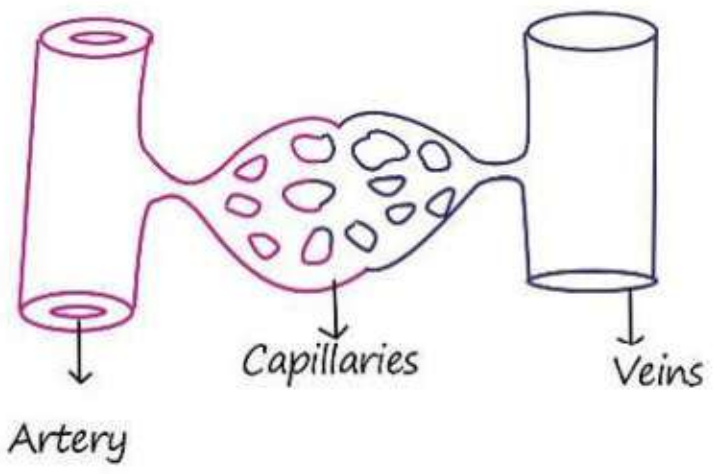

TUTORIALS
LOGIN FOR SUCCESS

Arteries & Veins

↓

3 layers in their wall

(Concentrically arranged called TUNICS or COATS)

↓

Inner layer – Intima

Middle layer – Media

Outer layer – Adventitia

Arteries	Veins
- Media very well-developed arteries have sustain a lot of pressure (Blood pressure) i.e Thick Media	- Media not very well developed; adventitia Abundant.
- No valves	- Valves are present V → Veins V → Valves

AfraTafreeh.com
TUTORIALS
LOGIN FOR SUCCESS

Vasa Vasorum

- Blood vessels which supply blood to other blood vessels.
- These are present in adventitia of both arteries & veins, apply blood to outer part of vessel (inner part gets blood supply by diffusion)

AfraTafreeh.com

Capillaries

- Do not have 3 layers like arteries and veins
- Only Intima (endothelial cell layer)
- Intima rests on basal lamina (Basement Membrane)
- Supporting cells on the outside of basal lamina, called PERICYTES.

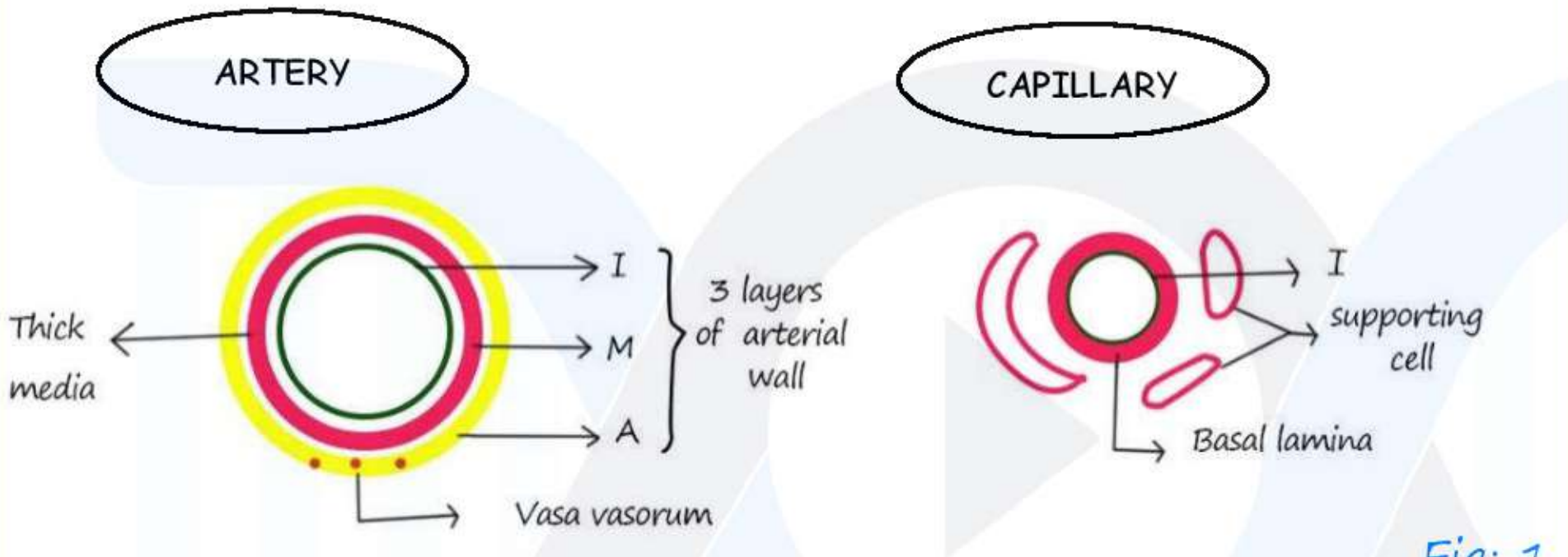

Fig: 1

- A direct connection between artery and vein, without interversing capillaries –called A-V Fistula
  - i. Iatrogenic A-V Fislula [created by doctors]—
    Eg: Hemodialysis [Fistula over forearm, we can hear the regurgitation sound]
  - ii. Internal elastic lamina (IEL): Membrane present between Intima and media
    - Rich in elastic fibre – stain VON GIESON /VERHOFF VON GIESON STAIN.
  - iii. VON GIESON/ VVG stain is used to stain elastic fibres (Black)

iv. External elastic lamina (eel): Membrane present between media and adventitia usually not so well developed. Also such in elastic fibres and stained with VVG stain.

- Significance – Internal elastic lamina gets duplicated in Benign Hypertension due to high Blood Pressure.

Classification of Arteries 00:09:07

Classification of Arteries

↓

3 Types

AfraTafreeh.com

Elastic

↓

- Predominantly contain elastic fibers these fibers parallel arranged
- Large arteries which deal with lots of Blood e.g. Aorta & it branches – Contain lots of elastic fibers in media (apart from muscle fibers). As a result

Muscular

↓

- Media in rich in muscle fibre
- Therefore, IEL and EEL can be seen distinctly
- Thicker adventitia well–spacedout

Arterioles

↓

- Small vessels media is seen predominantly

TUTORIALS
LOGIN FOR SUCCESS

AfraTafreeh.com

internal and external elastic lamina are not distinctly seen (Media containing elastic fired & both IEL and EEL stain dark with VVG stain) - Less adventitia present	vasa vasorum present

v. Marfans Syndrome:

- Elastic fiber of elastic arteries get fragmented due to cystic medial Necrosis
- Defect in elastic (Fibrillin & defect)
- Fibrillin is essential to maintain structure of elastin.
- Wall of elastic arteries gets weakened due to defective elastin –> patient develops Aneurysm, (dilatation) of vessel wall (as wall Thickness is less).

Capillaries

↓

3 Types

Continuous capillaries

- Basal lamina with continuous layer of endothelial cells (Continuous intima)

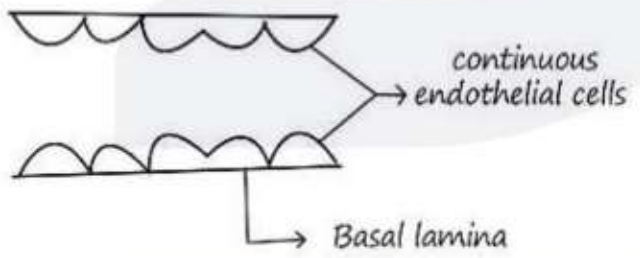

Fenestrated capillaries

- Present in kidney
- Basal lamina is continuous but Interendothelial gaps present in intima

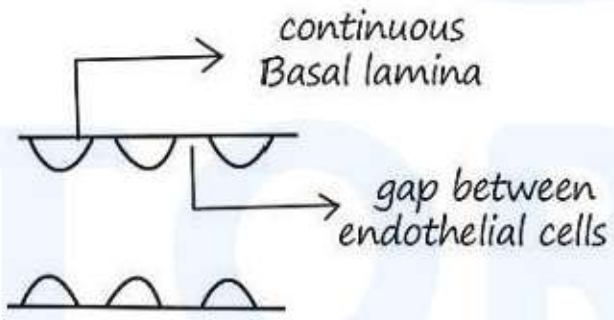

Sinusoidal capillaries

- Spleen, liver, bone, marrow
- Discontinuous Basal lamina with Interendothelial gaps

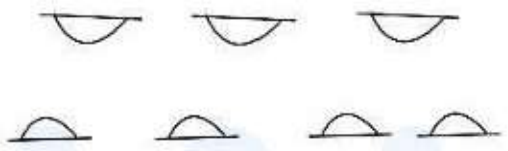

Gaps in Basal membrane as well

AfraTafreeh.com
DOCT TUTORIALS
LOGIN FOR SUCCESS

AfraTafreeh.com

SCLEROSIS WITH HIGHLIGHT ON ATHEROSULEROSIS

Sclerosis (narrowing of lumen)

- **Atherosclerosis** (when sclerosis occurs in larger vessels)
- **Arteriosclerosis** (occurs in smaller vessels)
  - 2 types
    - Hyaline
    - Hyperplastic
- **Monckeberg sclerosis**
  Misnomer not sclerosis, it's calcification of media of blood vessel

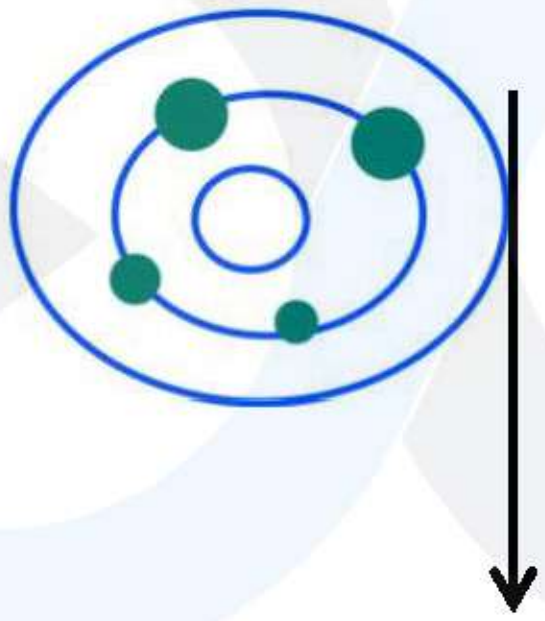

calcification of vessel media called – "MEDIAL CALCIFICATION"

Its dystrophic calcification due to aging

Asymptomatic seen in elderly

It's a post mortem finding

Does not lead to narrowing of lumen

ARTERIOSCLEROSIS: - (Narrowing of lumen present) 00:02:54

Hyaline

due to Benign hypertension

↓

Vessels become leaky

↓

Plasma proteins leak

↓

Lining of vessel by hyaline material

Duplication of internal elastic lamina (IEL) to counts the high BP called FIBROELASIC HYPERPLASIA

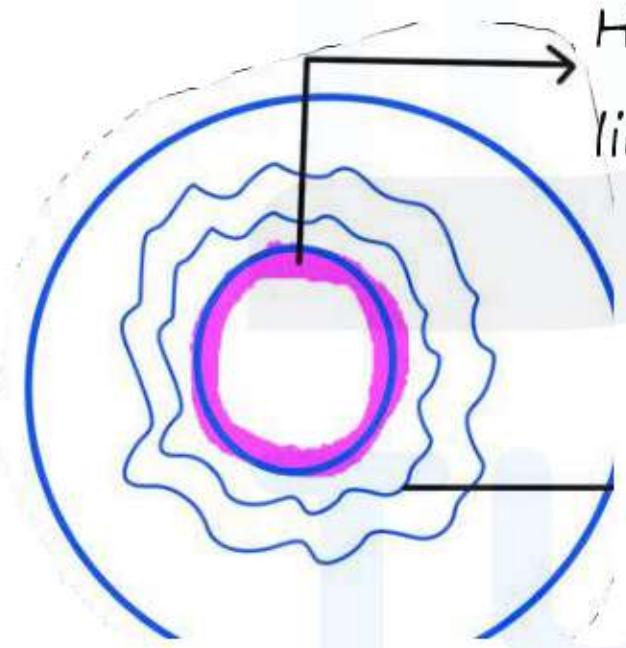

In no of muscle cells

Hyperplastic

Due to malignant hypertension

↓

Damage to endothelium (endothelial injury)

↓

Coagulation proteins come out and line the vessel wall + infiltration by inflammatory cells to catch up dead endothelial cells (in intima coat)

Causes of damage: -

Malignant hypertension

Immune complex mediated injury eg- polyarthritis Nodosa, Asch off nodule, Libman scales endocarditis (SLE)

Leads to deposition of dirty pink material in vessel wall called FIBRINOID NECROSIS

↓

BP is very high -> leads to concentric hyperplasia of vessel media called as "ONION SKINNING OF MEDIA"

↓

Thickening of vessel media -> insufficient blood supply via vasa vasorum -> necrosis of some area's media called "NECROTISING ARTERIALITIS" (fibrinous necrosis).

Features of Malignant Hypertension

↓

1. Intimal Fibrinous Necrosis
2. Onion skinning A Media
3. Necrotizing Arterioles

AfraTafreeh.com

AfraTafreeh.com

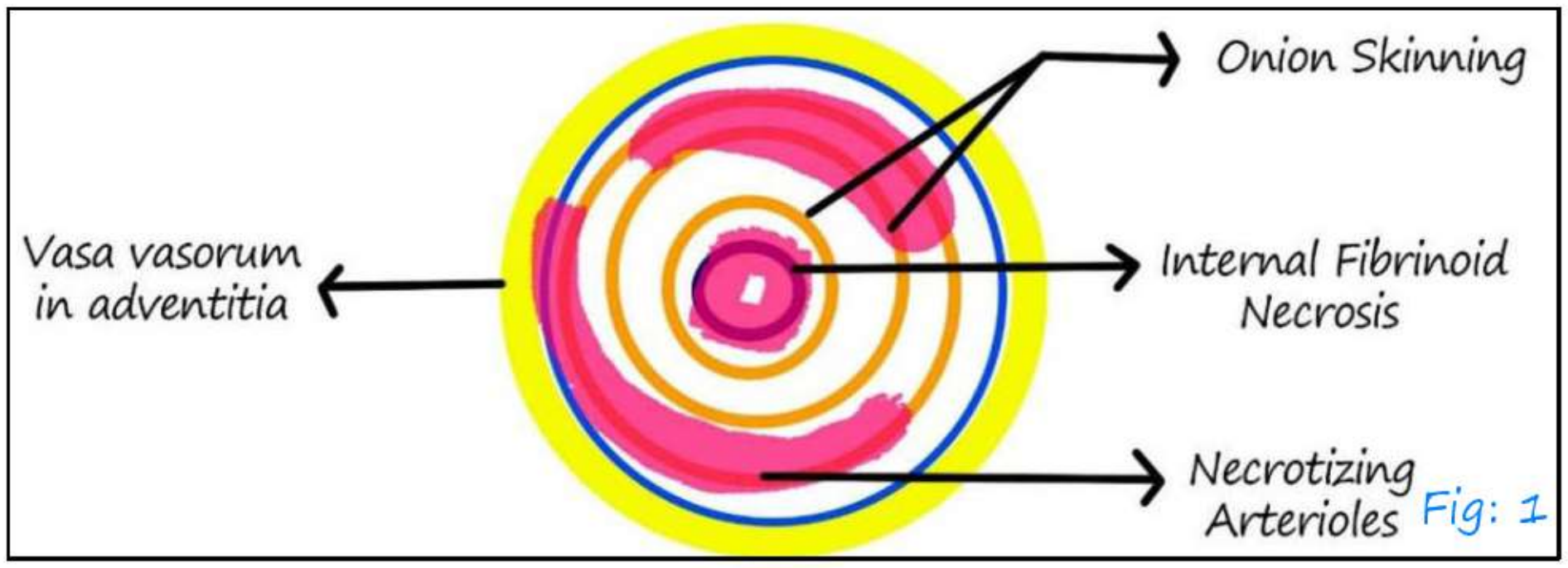

Fig: 1

Hyaline Arteriosclerosis image

- Vessel wall lined by pink smooth homogenous hyaline material made up leaked plasma proteins

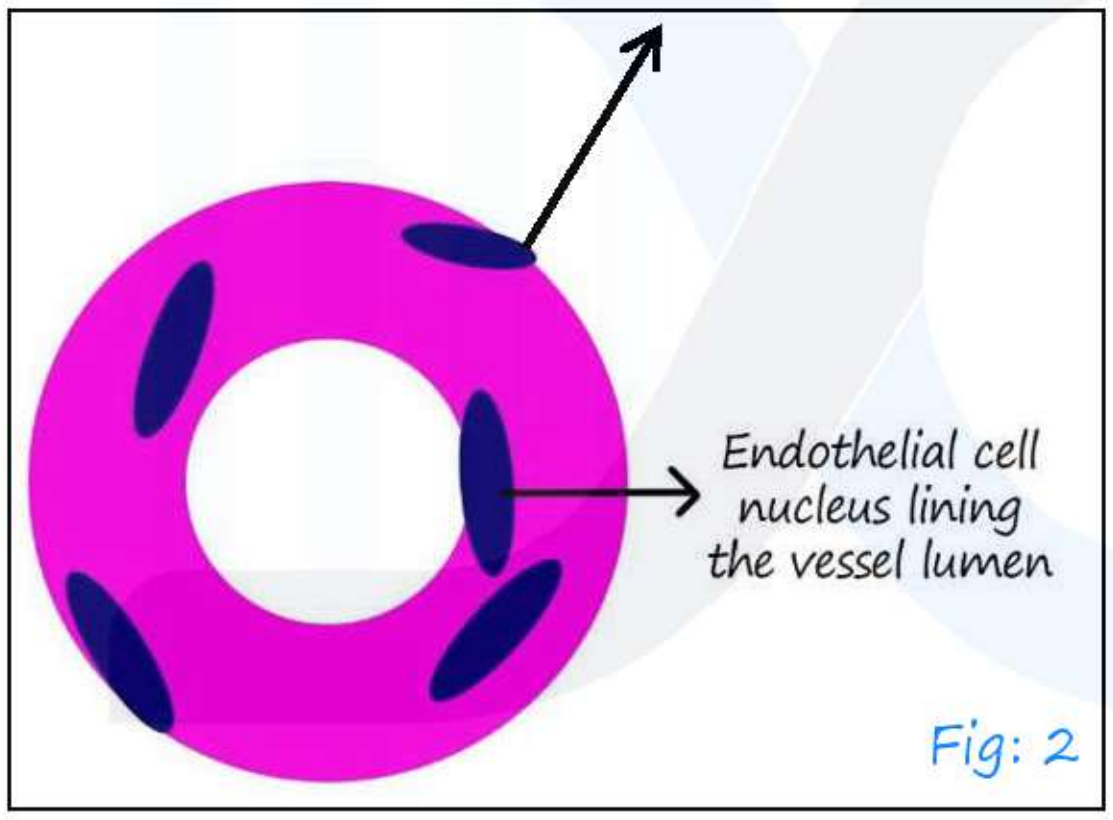

Fig: 2

Hyperplastic Arteriosclerosis image

TUTORIALS
LOGIN FOR SUCCESS

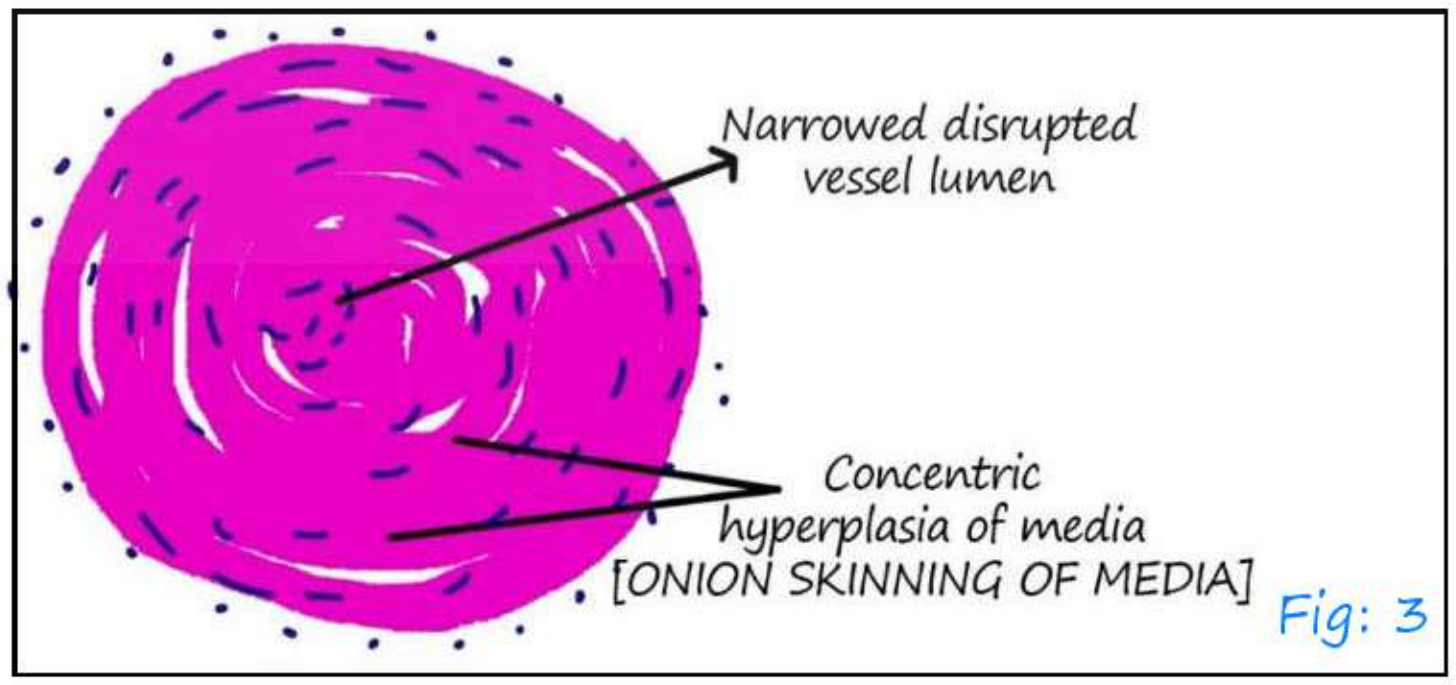

Fig: 3

- When hyperplastic arteriosclerosis (due to malignant HTN) occurs in kidney the gross appearance of

kidneys is called "FLEA BITTEN KIDNEY". It is due to occurrence of pin point hemorrhages in kidney to narrowed vessel lumens

- Onion skinning examples

1.Bile duct: Onion skinning of Bile duct Primary Sclerosing cholangitis

2.Nerves: Onion skinning of nerve bults [seen in chronic inflammatory demyelinating polyneuropathy – CIDP]

3.Lymph Node: Onion shining - Castleman disease

4.Blood vessels: malignant hypertension

5.Fibroid necrosis of intinca is co -existent with hyperplastic arteriosclerosis

AliaTafreeh.com

Moncheberg Medial sclerosis image-

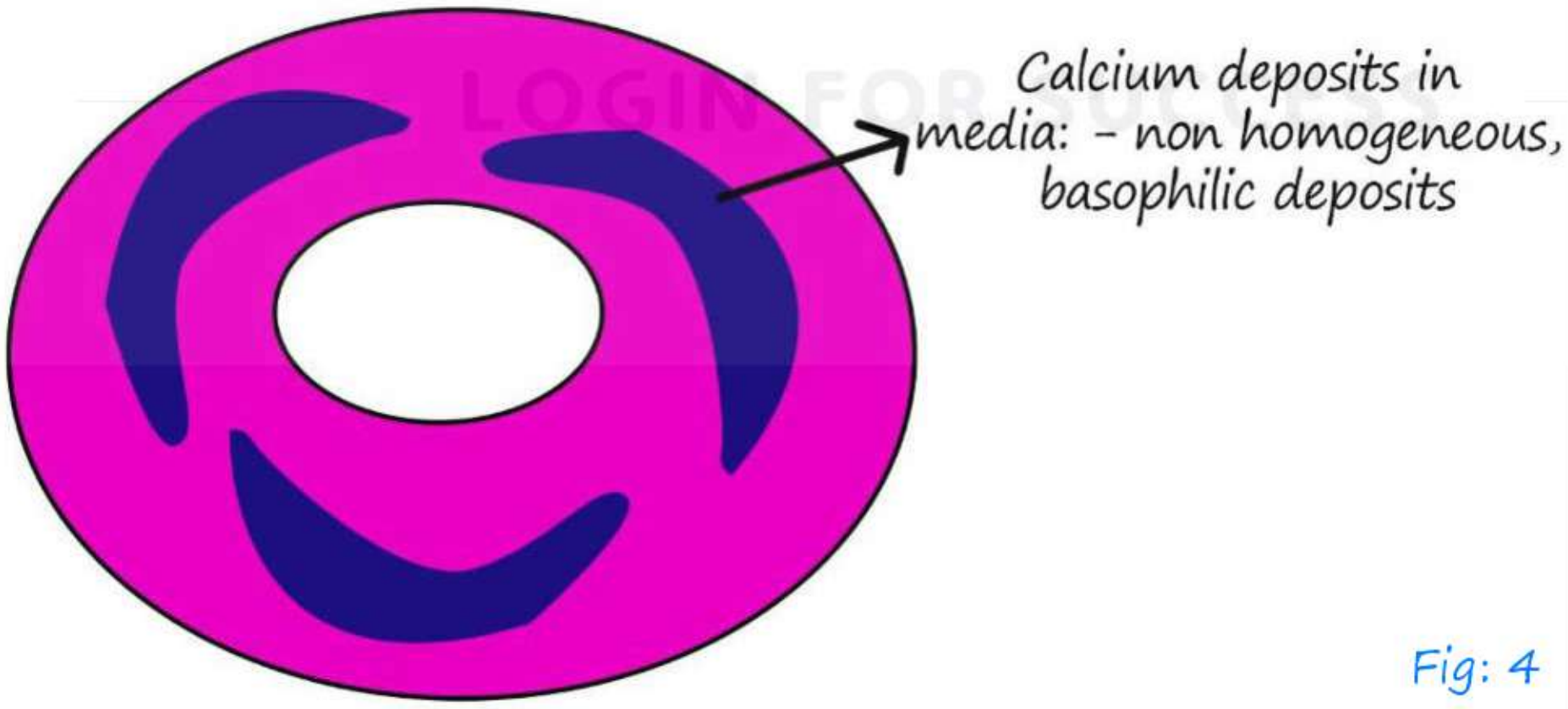

Fig: 4

AfraTafreeh.com

Atherosclerosis (large vessels involved) 00:16:10

- Most common vessel involved => Abdominal Aorta.
- Most common Peripheral vessel involved => Popliteal Artery
- Most common coronary Artery involved => left anterior Descending artery
- Most common site of involvement of abdominal aorta -> just before the bifurcation of aorta into common iliac arteries (just after aorta gives renal arteries).

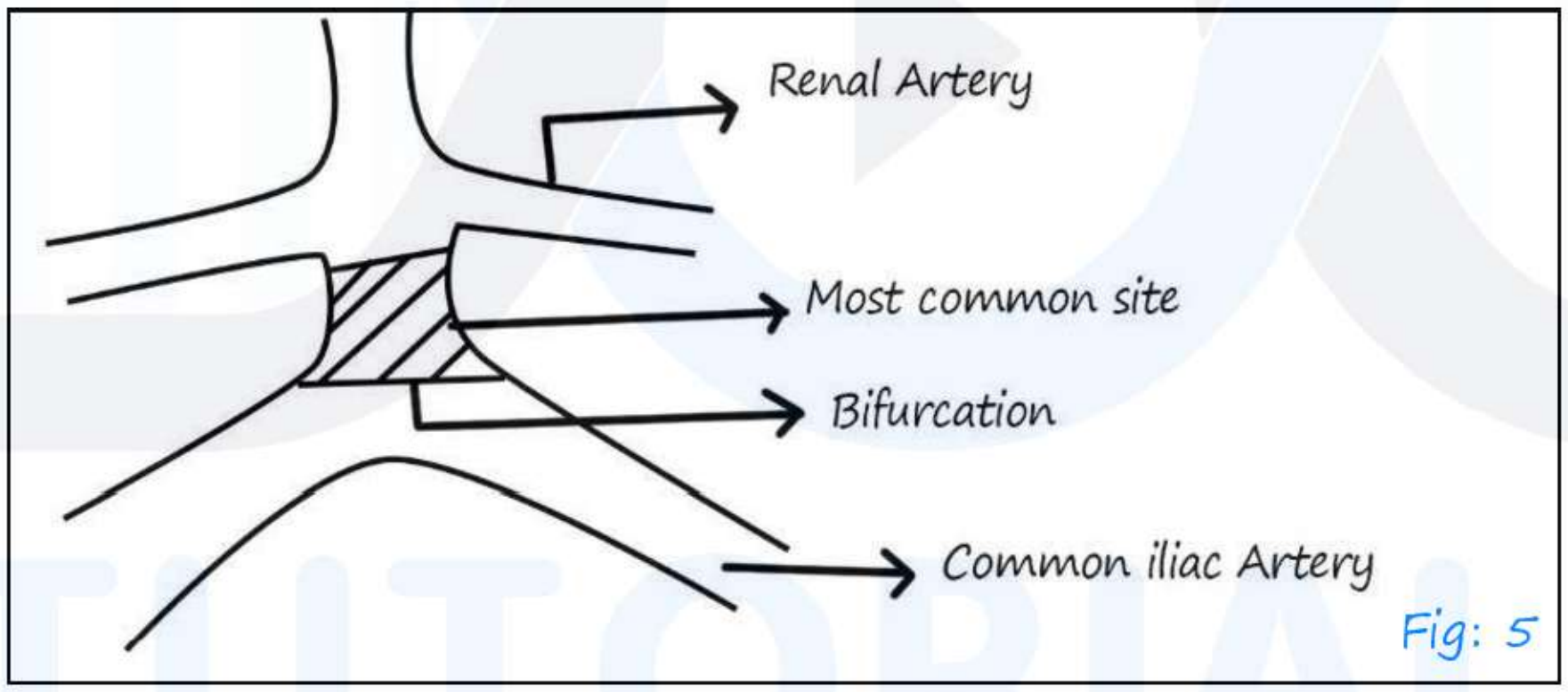

Fig: 5

HALLMARK Of Atherosclerosis - Endothelial dysfunction

- Normal endothelium does not allow anything to stick to it. Dysfunctional endothelium allows oxidized LDL to attach to it as a result, macrophages come and eat these oxidized LDL molecules and get converted

  Into FOAM CELLS

  ↓

Intima is lined by foam cells

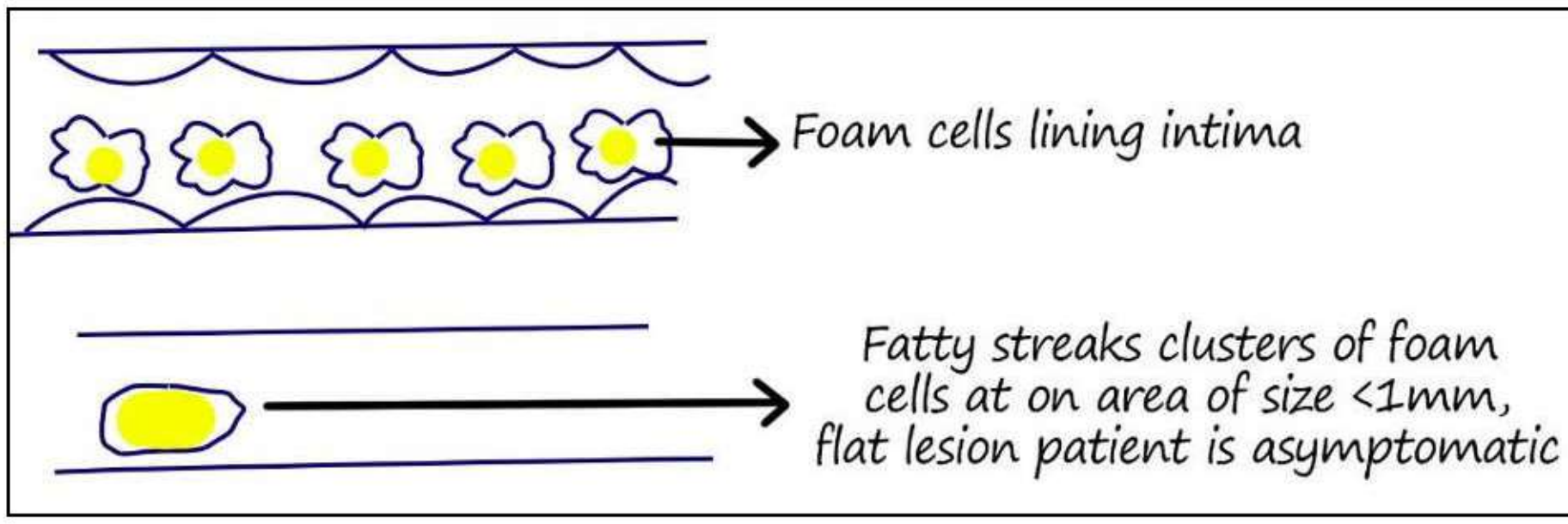

Fig: 6

- Fatty streaks start in infancy (1yr of age)
- Over years more endothelial dysfunction and consumption of fat results in more LDL deposits
- Macrophages are not sufficient to eat these many LDL deposits
- Smooth muscle cells from media migrate to intima to eat the oxidized LDL deposits and convert into FOAM CELLS

AfraTafreeh.com

FOAM CELLS → Macrophages
FOAM CELLS → Smooth muscle

TUTORIALS
LOGIN FOR SUCCESS

- Due to high blood flow in large arteries, endothelial injury occurs in an already dysfunctional endothelium.
- Platelets come and seal the sites of endothelial injury and also release cytokines

↓

Action

AfraTafreeh.com

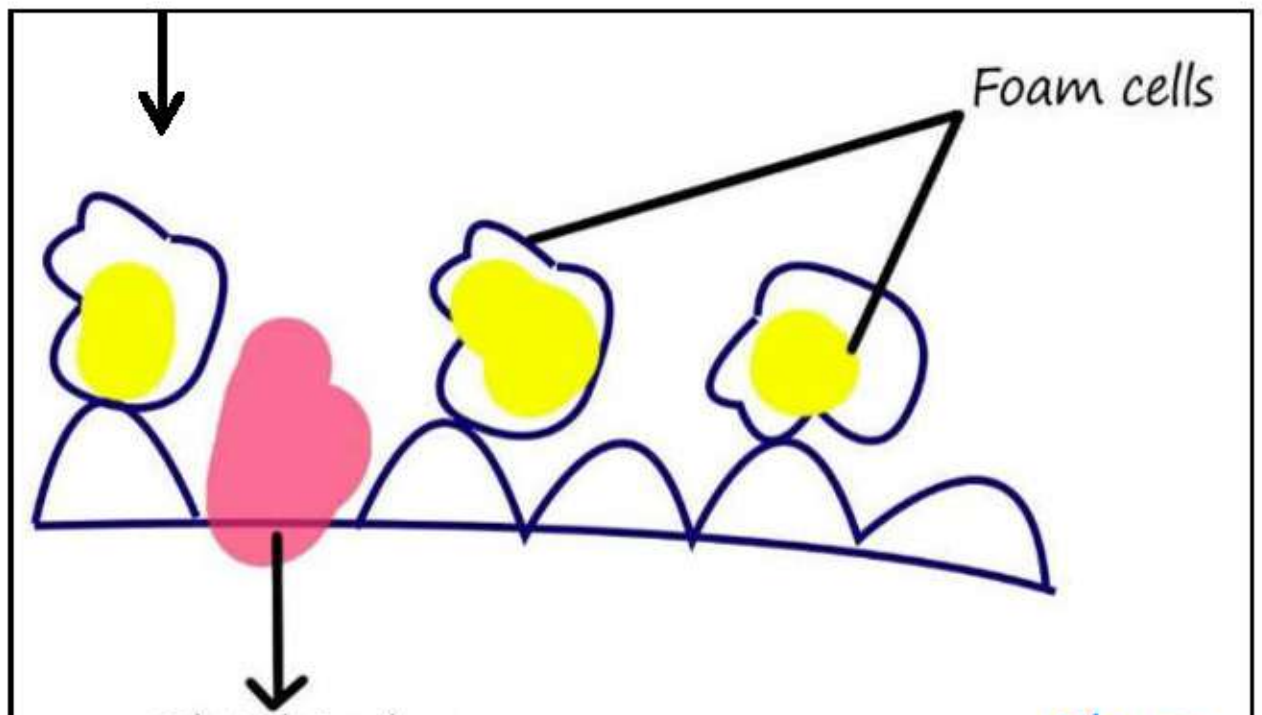

Fig: 7

1.Promote migration of smooth muscle cells from media to intima (foam cell formation)

2.Activate T-cells

↓

These changes are called as "RESPONSE TO ENDOTHELIAL INJURY HYPOTHESIS".

↓

Atherosclerosis

- With advancing endothelial injury, fatly streaks become bigger plaques

Components of plaque: -

1.Central necrotic core containing oxidized lipids

Lipids present in 2 forms-

- Intracellular lipid → Foam cells (Macrophages or smooth muscle cells)
- Extracellular lipid → Free lipid not within foam cells

2.Cap, constituting of smooth muscle cells and collagen covers the lipid core

3.Shoulder – contains smooth muscle cells and collagen and lets of T cells

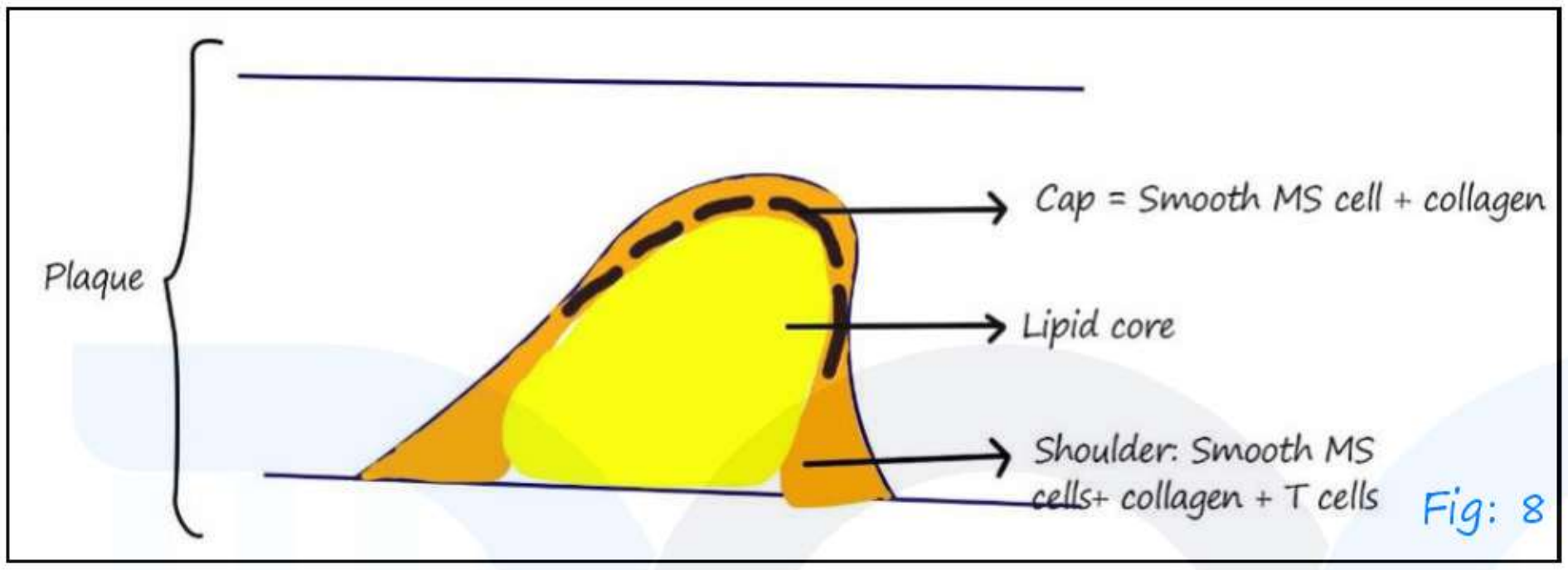

Fig: 8

Histopathology - key points

i. plaques => 2 types

AfraTafreeh.com

Stable	Vulnerable
1.CAPS Have thick caps. Do not usually rupture (i.e. usually no acute plaque change) 2.CORE: Small Core 3.SHOULDER: Shoulder is zone of inflammation less the inflammation lesser the movement in plaque,	1.CAP Have thinned out caps. Are vulnerable to rupture / acute plaque change 2.CORE : large core 3.SHOULDER: more the size of shoulder more inflammation and movement Higher risk of Rupture

AfraTafreeh.com

lesser chances of rupture	Vulnerable
Stable	Thin cap
Thick Cap	Big core
Small core	Big shoulder zone
Small shoulder zone	More inflammation
Less inflammation	

- Masson Trichrome: used to determine thickness of cap

↓

Blue staining – collagen

↓

Red Staining – muscle

ii. Tissue processing

↓

Tissue is put in formalin

Intracellular fat in plaque does not dissolve

Extracellular fat dissolves

↓

Formation of needle shaped clefts seen called "cholesterol Clefts"

TUTORIALS
LOGIN FOR SUCCESS

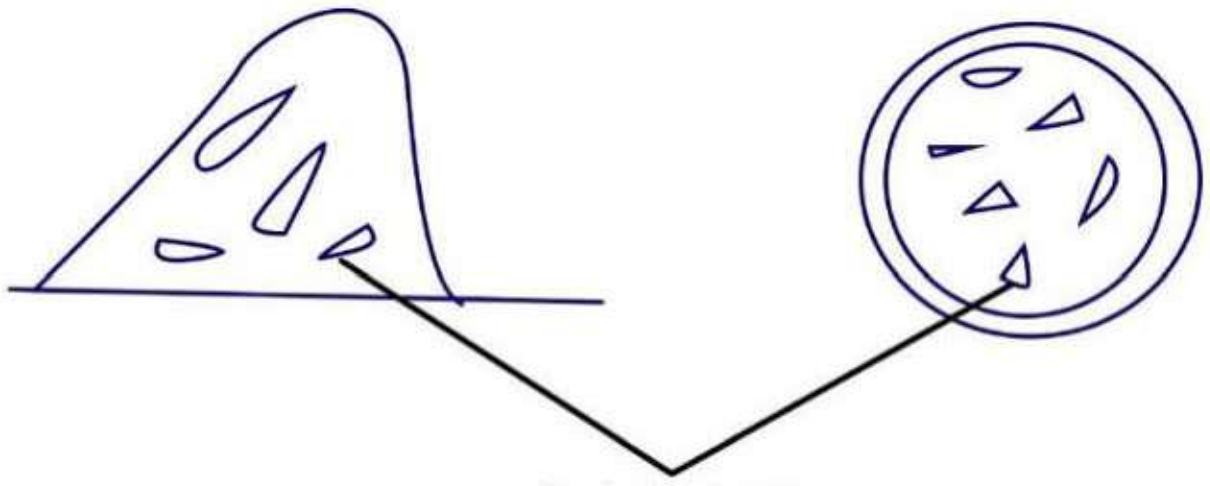

↓

Cholesterol clefts

More clefts in section indicate

presence of more extracellular fat

Response to injury Hypothesis image:-

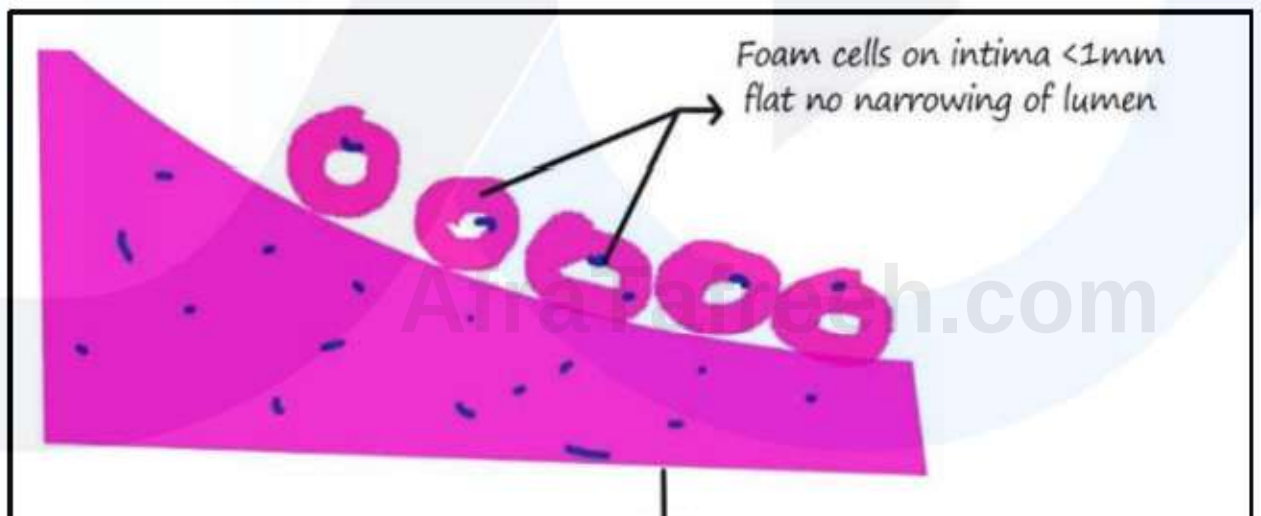

Fig: 9

- Cap of plaque is concave towards the side of lumen que to pressure existed by word column.

Q A thin cap appears concave

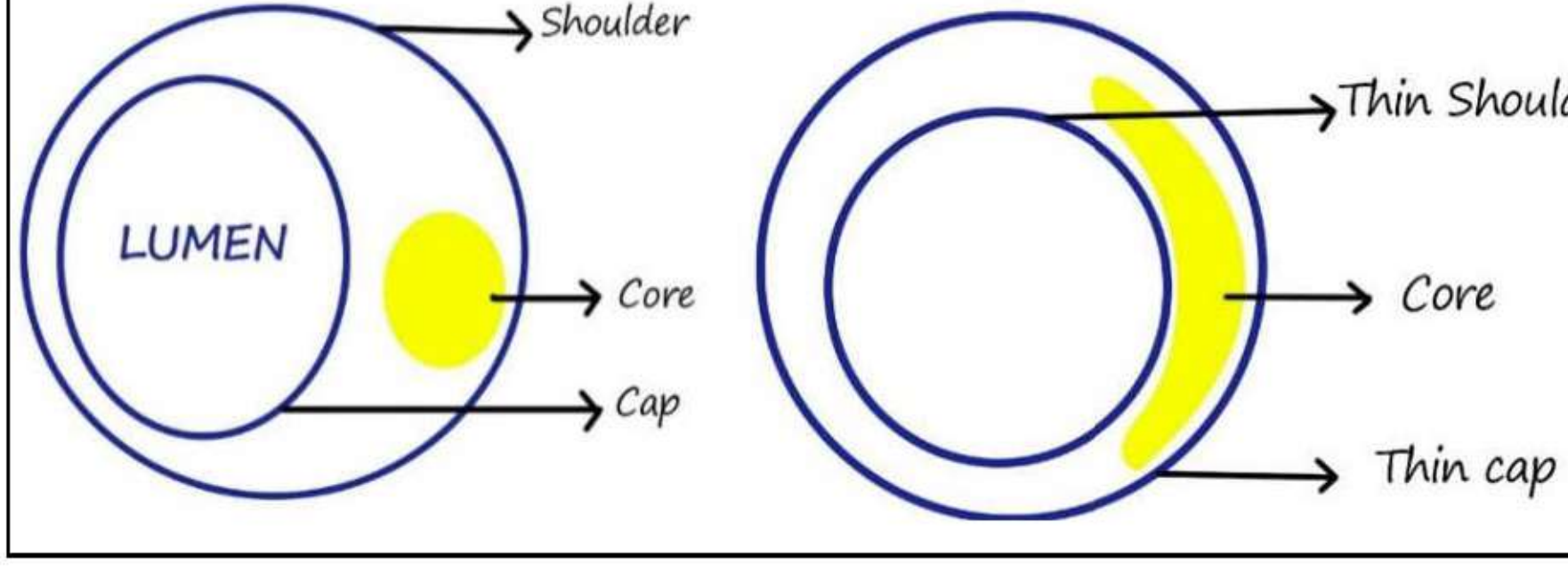

Fig: 10

AfraTafreeh.com

- Features seen in histopathology of atherosclerotic thrombus-

1. Foam cells
2. Giant cells
3. Cholesterol clefts

Plague stained with Masson's Trichrome stain:-

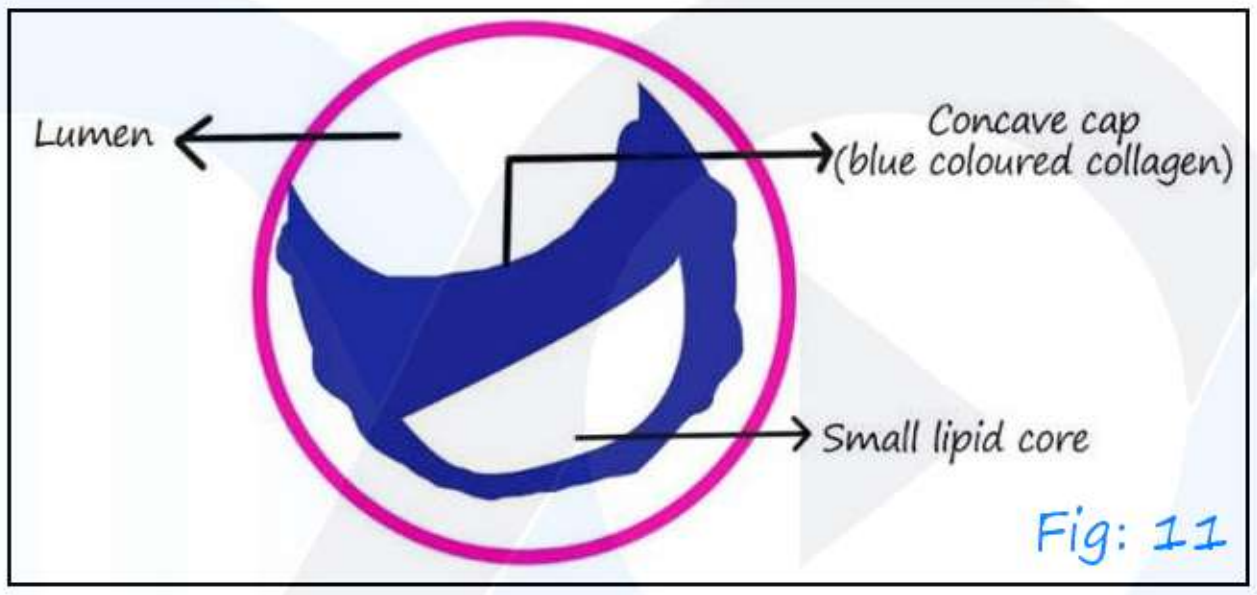

Fig: 11

Risk Factors: Atherosclerosis

I) Modifiable Risk Factors	II) Non-Modifiable
i) Increasing age (LDL)	i) Hyperlipidemia
ii) Gender (Male > Females) (Females protected by Estrogen)	ii) Hypertension
iii) Genetic factors	iii) Cigarette smoking
	iv) Diabetes Mellitus

iii. Additional risk factor –

1. Inflammation
2. Hyperhomocysteinemia
3. Metabolic syndrome

4.Abnormal proteins –Lipoprotein (a)*

5.Factors affecting hemostasis (Factor V Laiden)

6.Lack of exercise

7.Stressful lifestyle

8.Obesity

9.Infections – CMV, chlamydia, herpes

Recent update in Atherosclerosis

Complications of Atherosclerosis

- i. Acute plaque change
  - i. Hemorrhage
  - ii. Rupture
  - iii. Erosion
- ii. Embolization

AfraTafreeh.com

ii. Rupture

- d/t rupture of cap
- content of plaque released into blood
- feature of MI in elderly (STEMI) [ST segment elevation myocardial infarction]

Complications of atherosclerosis

1.hemorrhage

2.erosion/ulceration

3.ruputue/fissure

iii. Erosion

- endothelial injury (erosion)
- platelets stick to the injured site

i. platelet rich thrombus formed

↓

ii. Neutrophil extra cellar traps (NETs) formed

[NET is rich in histone rich proteins]

iii. Erosion usually occurs in an area rich in mucopolysaccharides (glycosaminoglycan's)

- Erosion is considered to be an important cause of myocardial infarction in young premenopausal females

AfraTafreeh.com

ANEURYSM

- Occurs due to weakening of vessel media

2 types

True Aneurysm

↓

No defeat in media that results in bulging of the wall



2 subtypes based on shape

Saccular

↓

A saccule form in a small area

Fusiform

↓

Whole part of vessel becomes fusiform

Pseudo aneurysm

↓

- No defeat in media, these is a hematoma which communicates with the lumen and is lined by extracellular malison on the outside

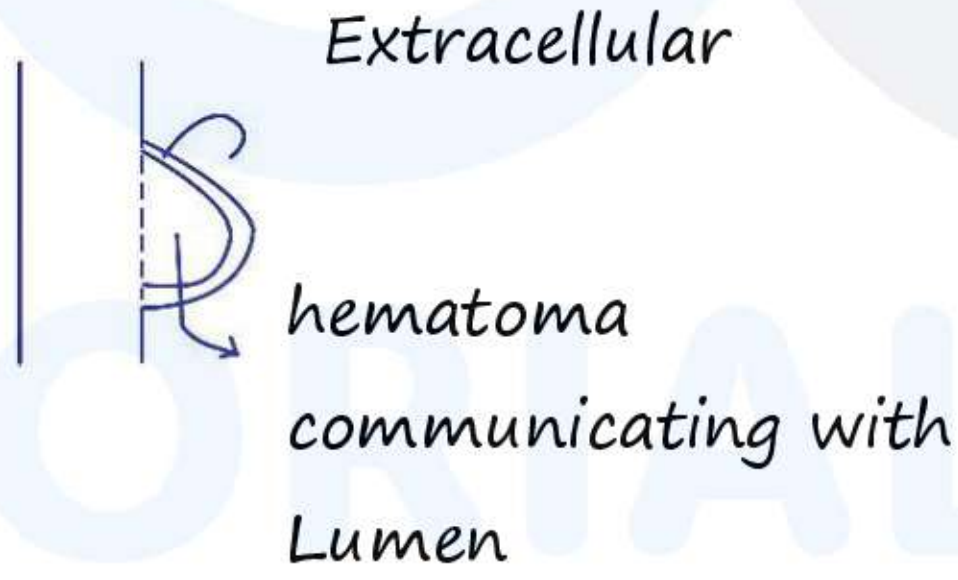

- very common post myocardial infarction

Causes of Aneurysm 00:02:01

I. weakness of wall

i. weakening of vessel wall due to atherosclerosis

↓

Most common cause

most common site – Abdominal aorta

– (on atherosclerosis, the migration of smooth muscle cells from media to intima causes thinking and weakening of media)

ii. weakening of vessel walls due to mutations of elastic fibers and collagen –

i. Marfans syndrome

– Mutation in the TGF β

– Defective Fibrillin

ii. Loeys Dietz syndrome: –

– Mutation in TGF β receptors leading to defective synthesis of elastin, collagen I and III

iii. Ehlers Danlos syndrome (vascular forms)

iv. Vitamin c deficiency

II. Defect in Muscle

↓

– High Blood pressure in hypertension

↓

IraTafreeh.com

AfraTafreeh.com

- Cystic medial degeneration (seen in Marfan's syndrome also)

↓

- There is fragmentation of elastic fibres in media leading accumulation of muco polysaccharides of ECM in cystic spaces

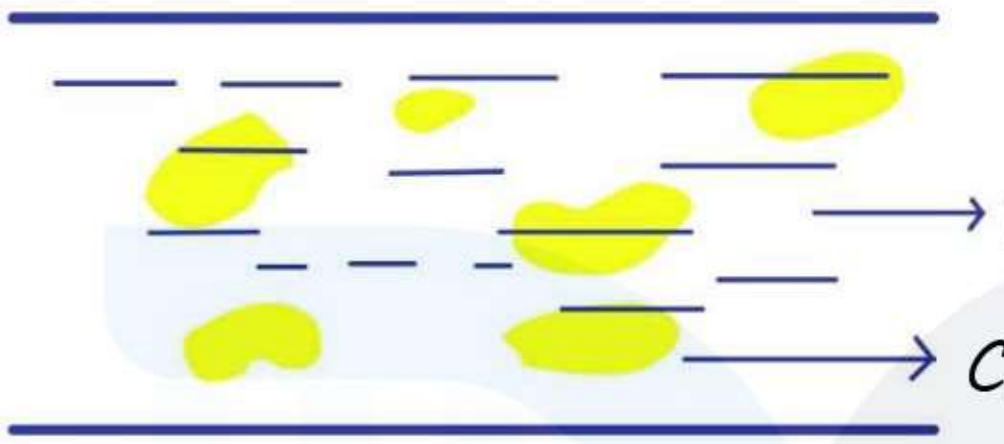

III. Matrix metalloproteinase theory: -

- Blood vessels undergo remodeling continuously There is formation of new Collagen and excess collagen is broken down by collagenases a form of matrix metalloproteinase (MMP).
- MMPs are kept under control by TIMPs. (Tissue inhibitors of matrix metalloproteinase)
- If there is deletion of TIMP

↓

- MMPs are over activated

↓

- Excess collagen breakdown

↓

- Aneurysm

Summary: Causes

i. Atherosclerosis (Descending Aorta)
ii. Hypertension (Ascending Aorta)
iii. Collagen + Elastic defects (Marfa's etc)
iv. Syphilis (Asc. Aorta)
v. MMP-TIMP Balance.

Syphilis:

i. Arteritis of vasa vasorum

↓

- Decreased blood supply to media, degeneration of media and aneurysm.

ii. Decreased perfusion of intima

Fibrosis of intima

AfraTafreeh.com

↓

Called TREE BARK APPEARANCE

- Most common cause of Ascending aortic aneurysm - Hypertension > Syphilis.

TUTORIALS
LOGIN FOR SUCCESS

MYCOTIC ANEURYSM. 00:13:08

↓

Media weakened by bacterial infection

Most common site: Femoral arteries, Causative Organism – staphylococcus, streptococcus

- A true aneurysm is lined by vessel wall, whereas a pseudo- aneurysm is not lined by vessel wall instead is lined by ECM.

AfraTafreeh.com

- Vascular Malformations – BERRY ANEURYSM

  ↓

  Due to, inherited defect in media as well as internal elastic lamina (IEL) of vessel wall.

  ↓

  Saccular aneurysm.

  More common in anterior circulation of circle of Willis.

- Risk Of Ruiture Of Aneurysms Q:

Diameters	Risk (%)
<= 4 cm	No risk
4-5 cm	1% per year (1)
5-6 cm	11% per year (11)
>6 cm	25% of year (22)

- Aneurysms expand at rate of 0.2 to 0.3 cm/year.

LOGIN FOR SUCCESS

Updates in Aneurysm 00:17:52

- Mycotic Aneurysm – Another important causative agent is salmonella

  ↓

  Most common cause of Mycotic abdominal aortic aneurysm is gastroenteritis

- Inflammatory aneurysm –
  - Seen in young individuals

- Increases CRP
- local immune complex deposits weaken the vessel wall
- Abundant lymphoplasmacytic infiltrate seen in wall.

↓

- A subtype of Inflammatory aneurysm is said to be a <u>IgG4 related diseases</u>

↓

- IgG4 related diseases cause of a lot of Storiform fibrosis. Fibrosis of aorta is seen (Aortitis) along with lot of plasma cell infiltration in the vessel wall

↓

Usually occurs around Vasa vasorum.

↓

This inflammation weakens the vessel wall leading to aneurysm & rupture.

- Patients also have a history of pancreatitis & obliterative phlebitis,
- IgG4 related diseases usually occur in elderly.

AfraTafreeh.com
DOCT TUTORIALS LOGIN FOR SUCCESS

AfraTafreeh.com

DISSECTION

- Dissection means there is a tear in vessel intima and it allows blood to enter the vessel wall commonly the blood enter between the vessel media and adventitia (i.e. outer layer)
- Most common cause of dissection is hypertension
- In hypertension, the vasa vasorum undergo medial hyperplasia and their lumen narrow. As a result, blood supply to the vessel media is reduced and cystic medial necrosis occurs in vessel media.
- So, when an intimal tear leads to dissection, blood easily enters the cystic spaces in the degenerated vessel media and accumulate between media and adventitia.
- Double barrel aorta:-
- When these is a second tear in the intima, through which blood from the dissection reenter the aorta is called double barrel aortic dissection
- In chronic double barrel dissection endothelization of dissected vessel wall will occur.

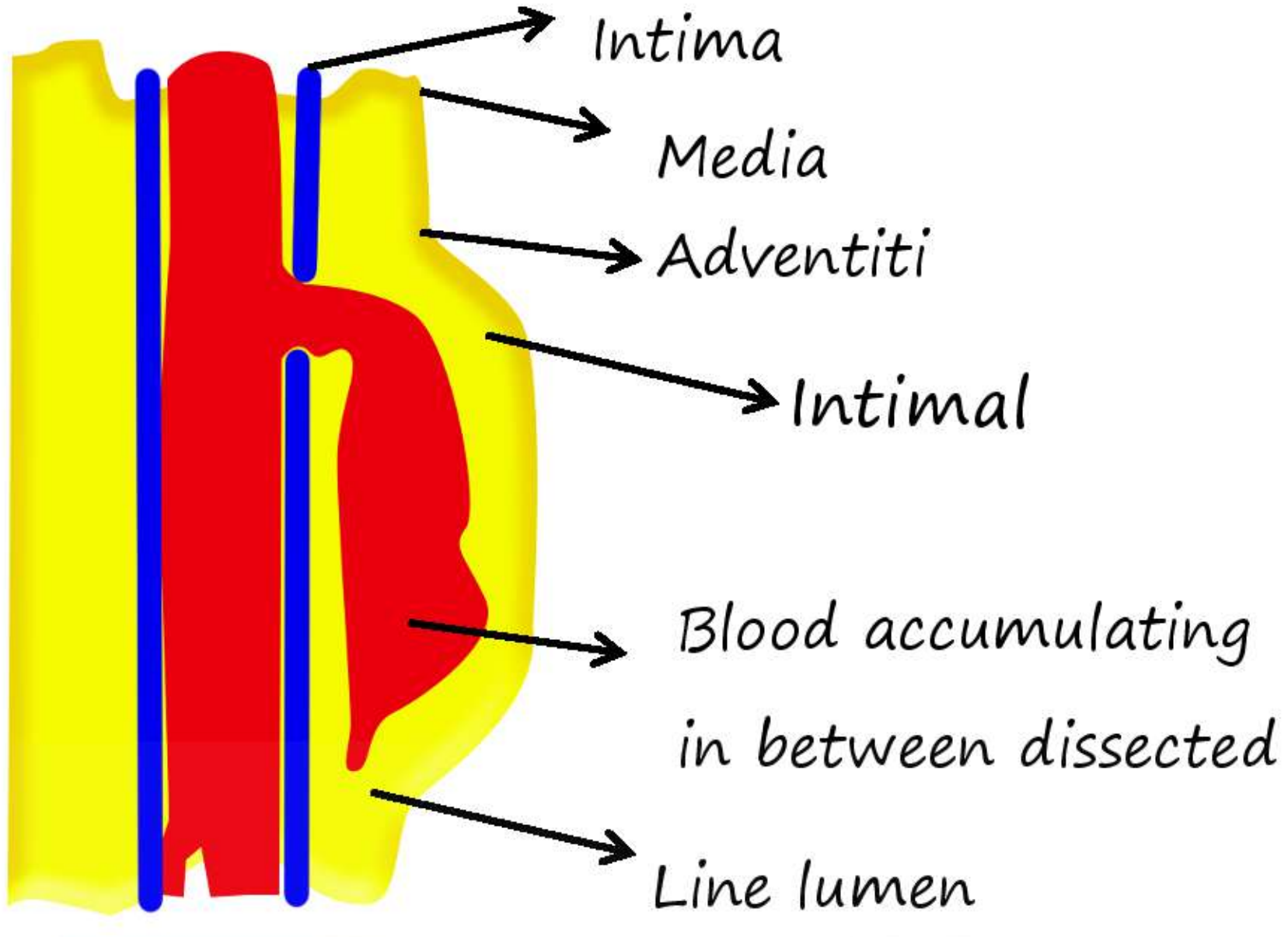

Fig: Dissection

Fig: 1

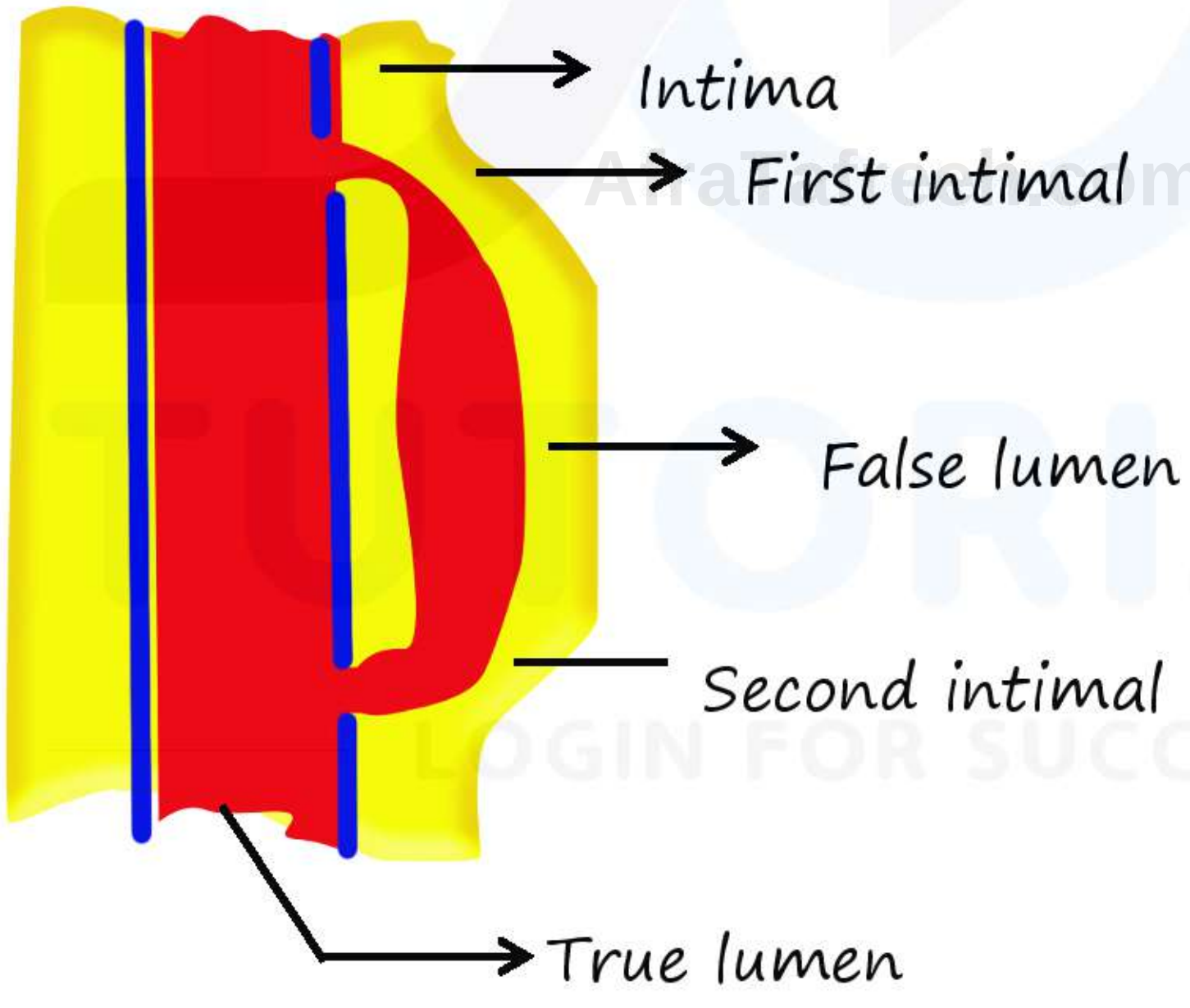

Fiq: Double Basel

Fig: 2

AfraTafreeh.com

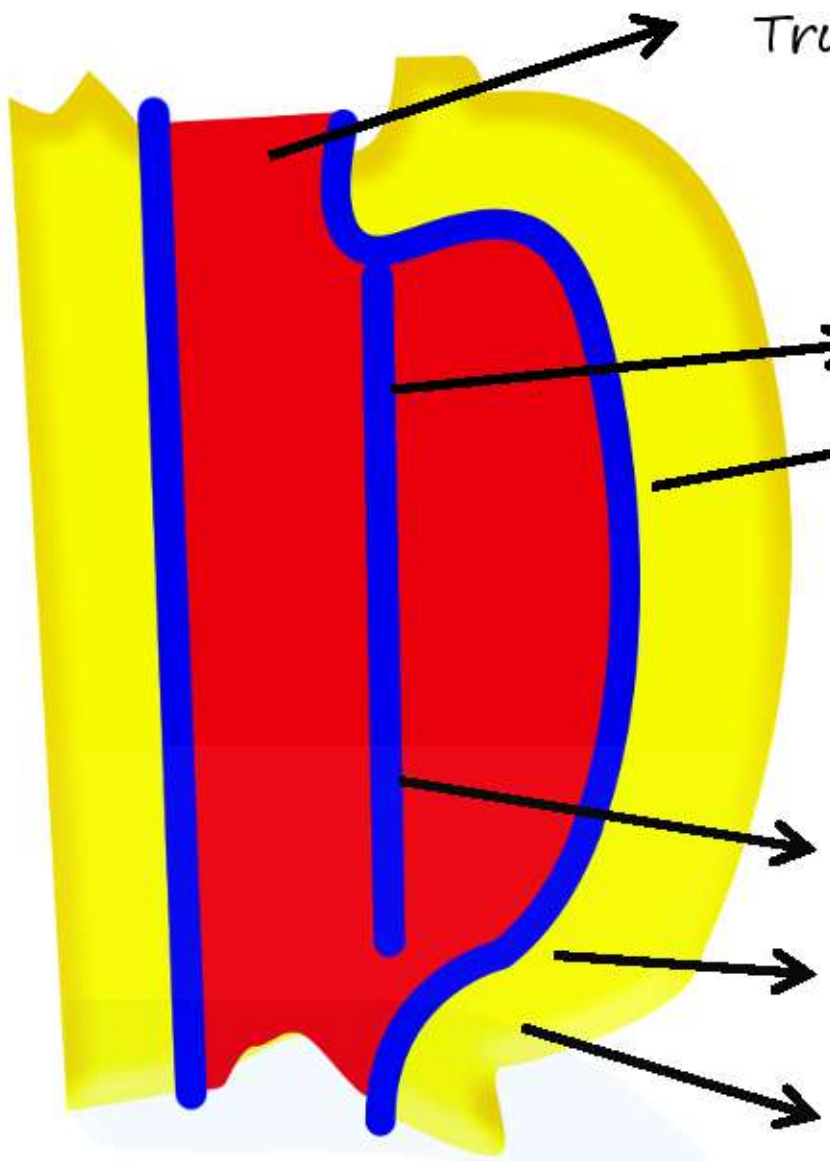

Fig: 3

- Marfan's syndrome
- Ehler Danlos syndrome

] Dissection is also seen in these conditions

Classification of Dissection 00:07:08

I) DeBakey Classification – <u>Stanford classification</u>

i. B Beth Ascending & Descending Aorta involved 3
ii. A Ascending aorta involvement only

] Stanford A (DeBakey I & II)

iii. D Descending aorta involvement only → Stanford B

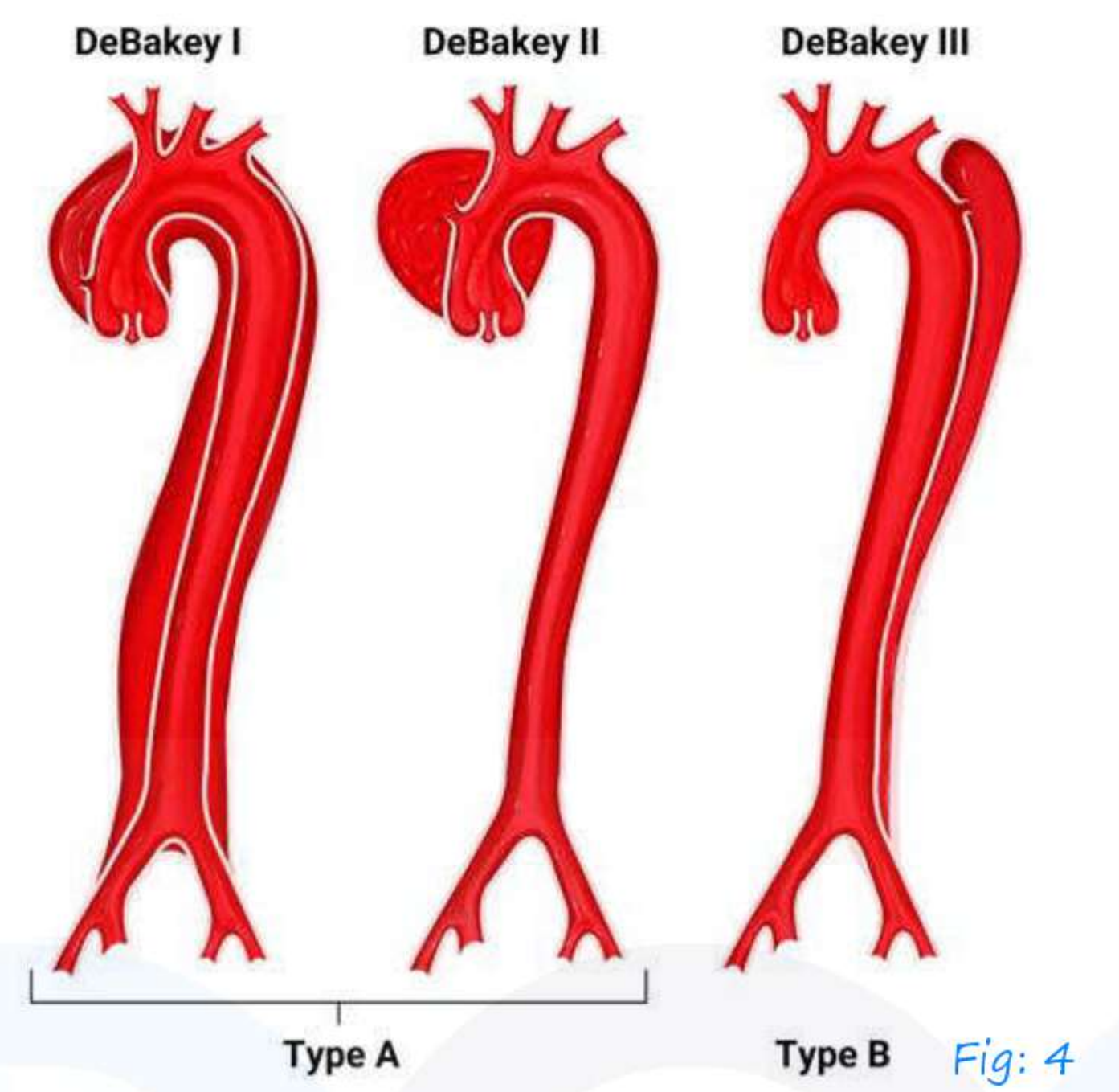

Fig: 4

- Stanford B: Management is conservative by giving antihypertensive
- Stanford A: Management requires surgical intervention as well as medical treatment antihypertensive
- Clinical feature of dissection: severe pain in chest that radiates to the back.
- Complications of dissection –
  i. Rupture and hematoma
  ii. Can extend proximally up to aortic root and cause aortic valve insufficiency.

AfraTafreeh.com

AfraTafreeh.com

VASCULITIS BASICS, LARGE VESSEL VASCULITIS, MEDIUM VESSEL VASCULITIS

Vasculitis basics: 00:00:38

- Chappel hill classification of vasculitis – based on size of vessels involved

Large Vessel (Aorta and elastic arteries)
↓
i. Takayasu arteries
ii. Temporal arteries
both the above are granulomatous vasculitis (i.e. inflammation is due to granulomas)

Medium Vessel (Muscular arteries)
↓
i. Polyarteritis Nodosa
ii. Kawasaki disease

Small Vessel (Arterioles capillaries, Venules, post capillary venules)

- Immune complex mediated
  ↓
  1. Henoch schonlein purphra (HSP)
- Non-Immune mediated
  ↓
  ANCA mediated
  ↓
  1. Microscopic polyangitis
  2. Churg strauss disease
  3. Granulomatosis with polyangitis

Takayasu Arteritis <50 yrs of age	Temporal Arteritis >50 yrs of age
- Most commonly involved artery is subclavian artery - Called as pulseless disease as upper limb pules cannot be felt due to vasculitis - Least common artery to be involved coronary Arteritis (since they are not elastic arteries)	-Most commonly involved artery is temporal artery -Ophthalmic artery and its branches may also be involved and severe disease may lead to blindness -Patient has headache and scalp tenderness

AfraTafreeh.com

PAN	Kawasaki disease
- Immune complex mediated vasculitis Antigen associated is HBsAg (in 30% cases) - Ag –Ab complex damages endothelium of vessel causing FIBRINOID NECROSIS - Most commonly involved Renal artery - Can involve any vessel in the body except pulmonary artery	- Due to anti – endothelial cell antibody which damages the blood vs - Most commonly affects coronary artery (since it affects muscular arteries) - Usually seen in children - Coronary artery involvement results in aneurysms and myocardial infarctions

AfraTafreeh.com

- Most common cause of MI in children is Kawasaki Disease.
- Most common vasculitis in children - HSP
- 2nd most common vasculitis in children-Kawasaki Disease
- Ag is not known in HSP, however IgA combing with the unknown Ag to form immune complex which damage the vessel wall

↓

Neutrophil infiltrate to phagocytose the debris.

Degenerated Neutrophils are seen in fragmented vessel wall

↓

Called as leucocytoclastic vasculitis.

(leuco -> neutrophils

Cytoclastic -> cell degeneration).

↓

Palpable purpura seen.

TUTORIALS
LOGIN FOR SUCCESS

ANCA mediated pauci immune vasculitis 00:09:16

2 types of ANCA (Anti Neutrophil cytoplasmic antibodies)

P ANCA
↓
Ab against neutrophil MPO (Myeloperoxidase)
↓
(Mnemonic PM => PANCA MPO)
↓
2 diseases
↓
i. Microscopic polyangitis
ii. Churg Strauss disease

C ANCA
↓
Ab against proteinase 3
↓
Wegener's Granulomatosis [New name – Granulomatosis with Polyangitis (PGA)]

AfraTafreeh.com

Microscopic polyangitis –

- Affects pulmonary capillaries
- leukocytoclastic vasculitis – microscopic polyangitis
- Churg strauss disease and granulomatous with polyangitis (Wegener's) are both granulomatous vasculitis
- Churg Strauss Disease =
- Granulomas everywhere + Granulomatous
- Vasculitis + Asthma + Eosinophilia
- Granulomatosis with Polyangitis =

AfraTafreeh.com

- Granulomas everywhere + Granulomatous
- Vasculitis
- (No eosinophilia).

Thrombo Arteritis Obliterans (TAO) / Burge's disease 00:19:54

- Affects small and medium sized arteries, nerves and veins
- very painful due to entrapment of nerves
- Granulomatous vasculitis
- Most common artery involved = Tibial artery

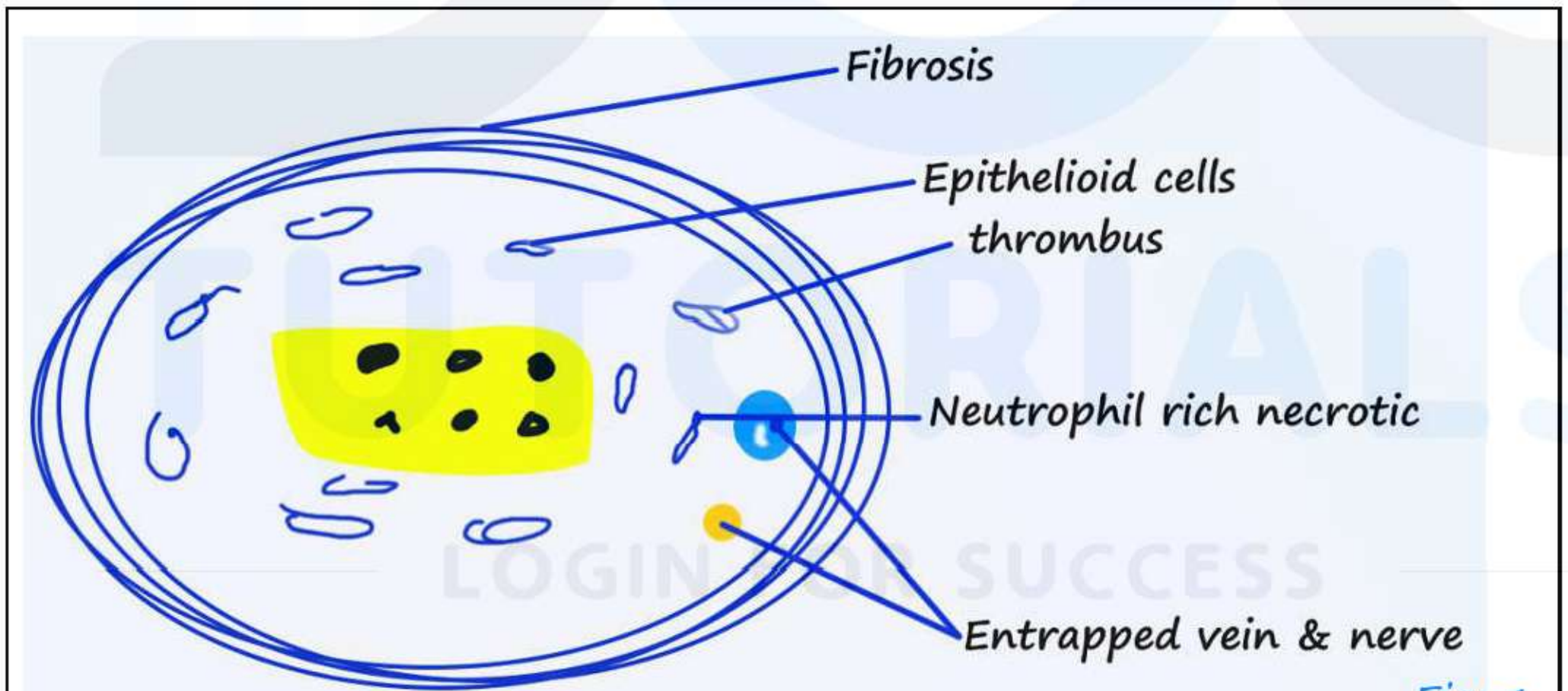

Fig: 1

Granuloma in TAO

↓

Acute as well chronic vasculitis

LARGE VESSEL VASCULITIS

Temporal Arteritis	Takayasu Arteritis
- >50 yrs. - Most common: Temporal Artery either – ophthalmic artery & its branches involvement - Most common symptom: headaches - Most specific symptom: Jaw claudication - Can present with sudden blindness	- <50 yrs. - Aortic arch & its branches involved most common: subclavian Artery involvement - Pulseless disease - Renal artery involvement and renal hypertension - Fibro muscular dysplasia - Least commonly involved - coronary artery

AfraTafreeh.com

Temporal Arteritis 00:04:36

TUTORIALS LOGIN FOR SUCCESS

- Pathogenesis
  - Unknown antigen (Ag) present on vessel wall

    ↓

    Recognized by Antigen presenting cells (APCS)

    ↓

    T cells

    ↓

    Release cytokines

AfraTafreeh.com

TNF → Main cytokine involved

- Suspected Ag is either present on endothelial cell or on smooth muscle cells.
- (Ex. Of large vessel vasculitis with anti-endothelial cells antibodies = Temporal arteritis) –update
- Presence of Anti endothelial antibodies or anti SMA Ab is seen in 2/3rds of Cases.

T cells

↓

TH1

↓

IFNgamma->
- Granuloma formation
- Conversion of macrophages into epithelioid cells

TUTORIALS
LOGIN FOR SUCCESS

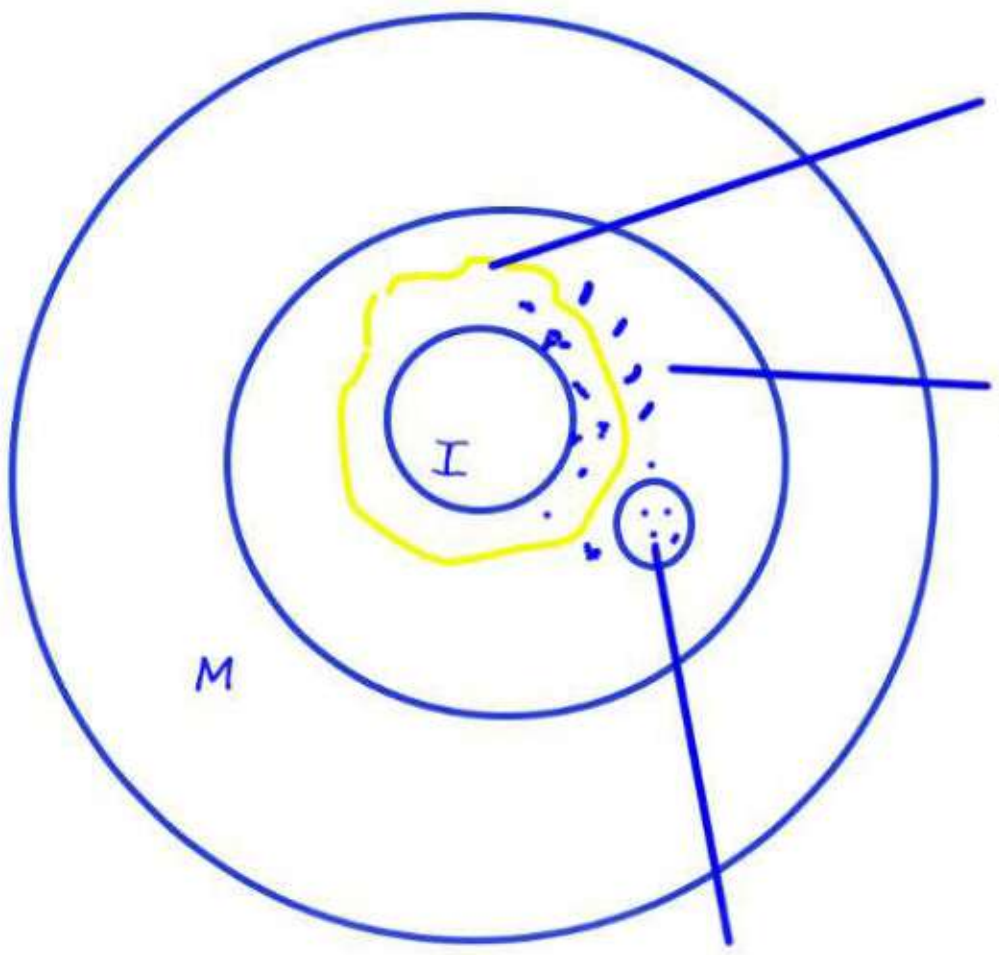

IEL

↓

Granuloma causes widening of intima

↓

Fragmentation of internal elastic lamina [seen on

Giant cell

↓

Granuloma has lets of giant cell

↓

Therefore also called a <u>Giant cell Arteritis</u>

AfraTafreeh.com

- CD4 cells > CD8 cells in granuloma
- Patchy granulomatous changes in Vessel wall with intervening normal vessel tissue mandates procurement of large section of vessel in biopsy (1cm biopsy taken).

Treatment:

Advantage:

- Biopsy
- Raised ESR (first do ESR, if it raised do a biopsy)
- Treatment Anti TNF therapy.

AfraTafreeh.com

Takayasu Disease. 00:17:47

- <50 yrs. of age
- Present with renovascular hypertension, pulseless disease
- Mutation in MHC -II due to which body starts recognizing self-antigens.
- TNF not involved

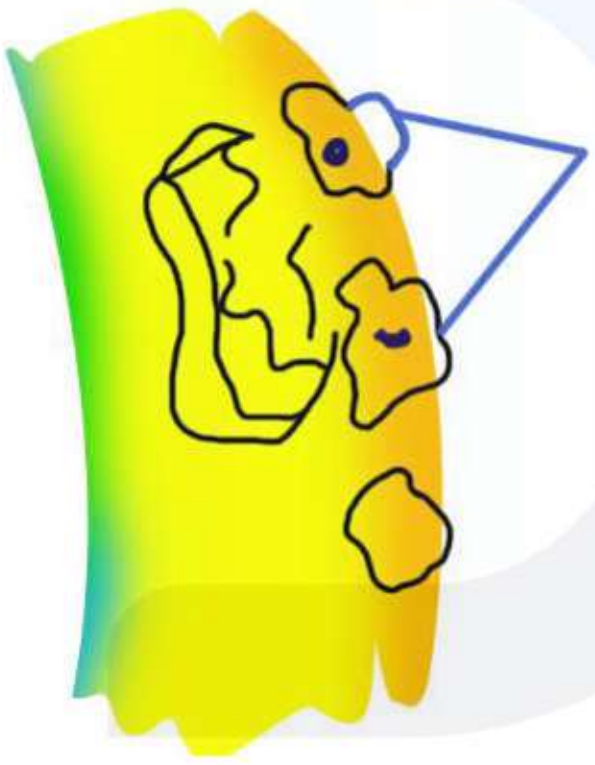

Granulomatous inflammation of vasa vasorum extending into the media (Outer layer to inner layers)

IMA

TUTORIALS
LOGIN FOR SUCCESS

MEDIUM VESSEL VASCULITIS

- PAN (Polyarteritis Nodosa)
- Ag-Ab complex damages endothelium
- Ag- HBsAg (in 30% cases)
- Fibrinoid necrosis

↓

Healing and fibrosis around vessels

- In biopsy of PAN, all stages of disease activity are seen -some Vessels showing necrosis
- Some showing fibrosis (healing)
- Some vessels seeing both necrosis & fibrosis
- Any vessel except pulmonary vessels can be involved
- Most commonly involved artery in PAN is Renal Artery, however glomerulonephritis is never seen.

AfraTafreeh.com

Kawasaki Disease 00:05:44

- Discovered in Japan
- Usually, children below 4 years affected
- Most common vessel involved are coronaries
- Anti-endothelial antibodies are formed against vessels such as coronary arteries

↓

Weakening of vessel wall

↓

Aneurysm

TUTORIALS LOGIN FOR SUCCESS

AfraTafreeh.com

Stasis of blood & thrombosis → Myocardial Infarction →

Rupture

Giant Coronary aneurysm > 7-8 mm.

- Most common cause of Myocardial infarction in children is - Kawasaki Disease.

Criteria for diagnosing:

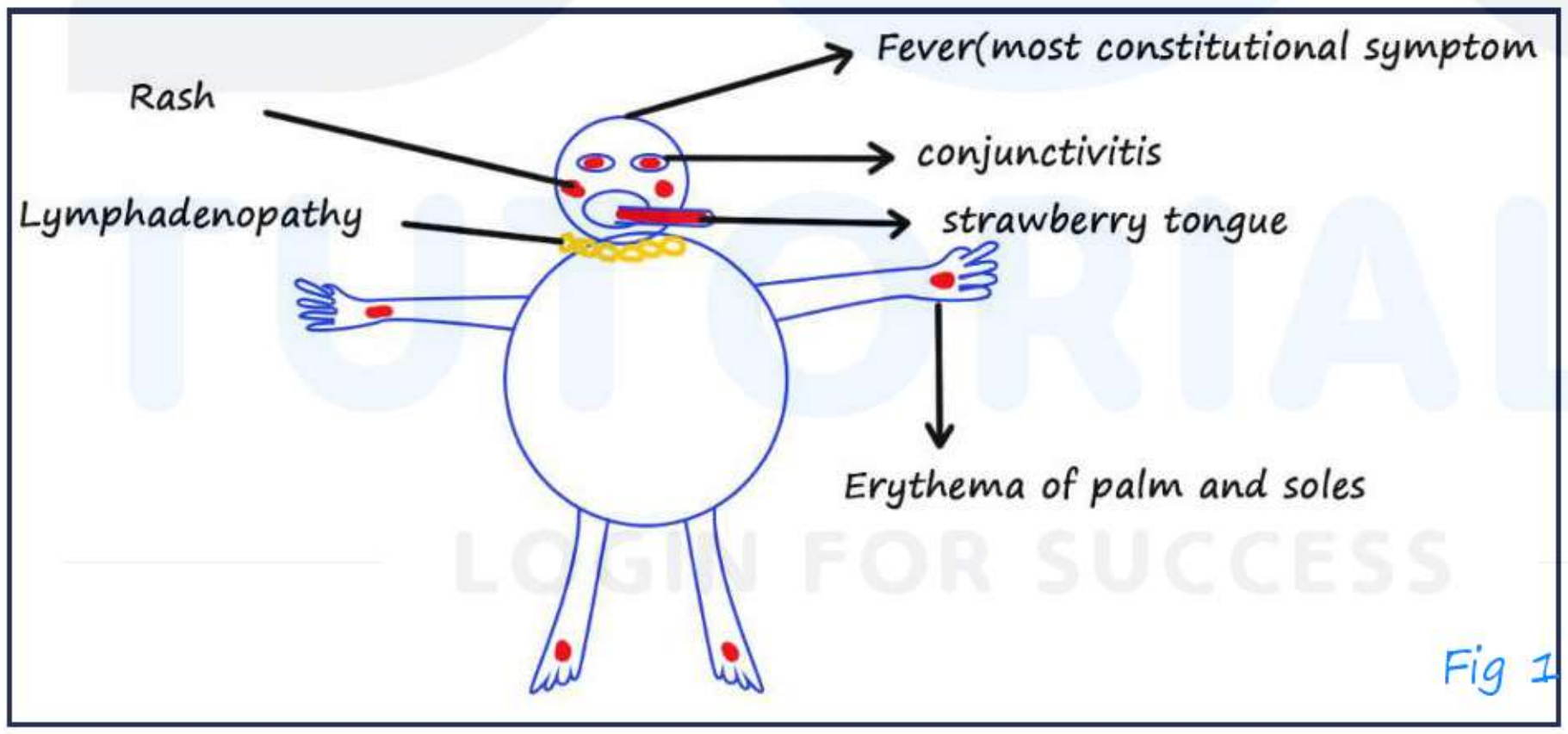

Fig 1

- Kawasaki's Disease is also called as Mucocutaneous lymphadenopathy syndrome
- Fever + CARES = Kawasaki if 4 out of 5 of CARES + Fever should be present

  C = conjunctivitis

  A = Adenopathy (lymphadenopathy)

R = Rash

E = Erythema of palm and soles

S = strawberry tongue

Biopsy shows –

- Trans mural fibrinoid necrosis but extent is les than – PAN

Strawberry lesions in pathology

- Strawberry tongue – KAWASAKI DISEASE
- Strawberry gums – WEGENER'S GRANULOMATOSIS
- Strawberry angioma – Capillary hemangioma
- Strawberry skull – EDWARDS Syndrome
- Strawberry gallbladder – cholestrolosis
- Strawberry cervix – Trichomonas's

AfraTafreeh.com
TUTORIALS
LOGIN FOR SUCCESS

AfraTafreeh.com

SMALL VESSEL VASCULITIS

Small Vessel Vasculitis

- Immune complex mediated
  - Henoch schnolein purpura
  - SLE
- Pauci immune
  - C ANCA
    Targets (CP) Proteinase -3 of Wegener's (polyangitis granulomatosis) PGA
  - P ANCA
    Targets MPO (PM)
    - Microscopic polyangitis
    - Churg strauss syndrome
      Allergic PG

Pauci – immune 00:04:05

- C ANCA
- Wegener's granulomatosis (PGA)

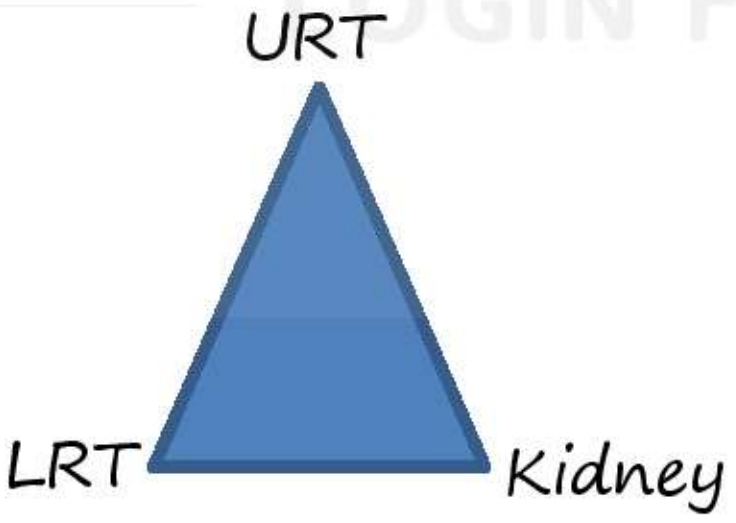

- Granulomas present all over the body except kidney
- Granulomatous vasculitis
- Kidney shows glomerulonephritis

Necrotizing GN | RPGN/ Crescentric GN

Morphology of granuloma

Necrotizing Granuloma

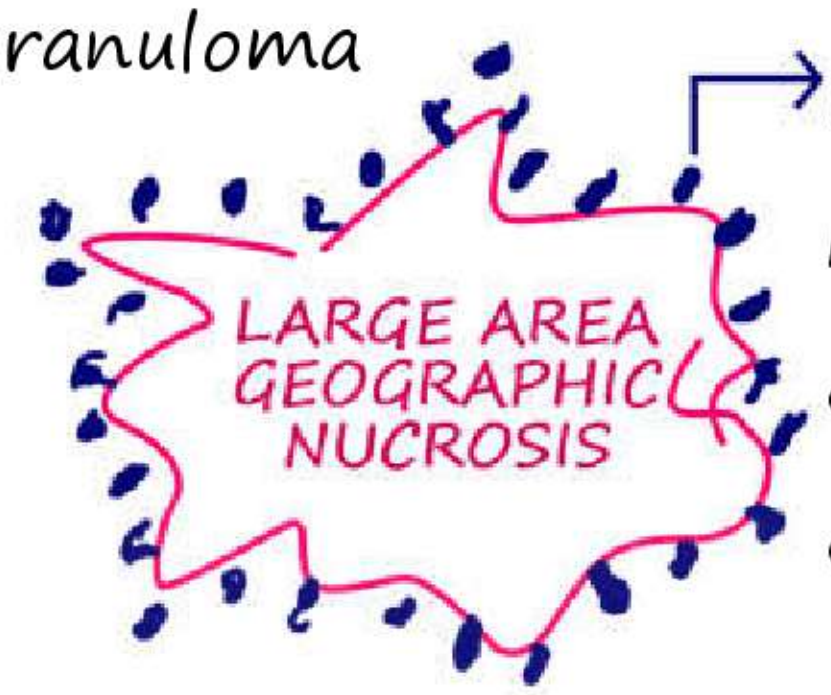

→ Palisading histiocytes Seen in

- RA
- Wegeners

- Naked granuloma (no lymphocytes)– Sarcoidosis
- Limited wegeners Only respiratory tract (URT + LRT) involved, kidney not involved

AfraTafreeh.com
TUTORIALS
LOGIN FOR SUCCESS

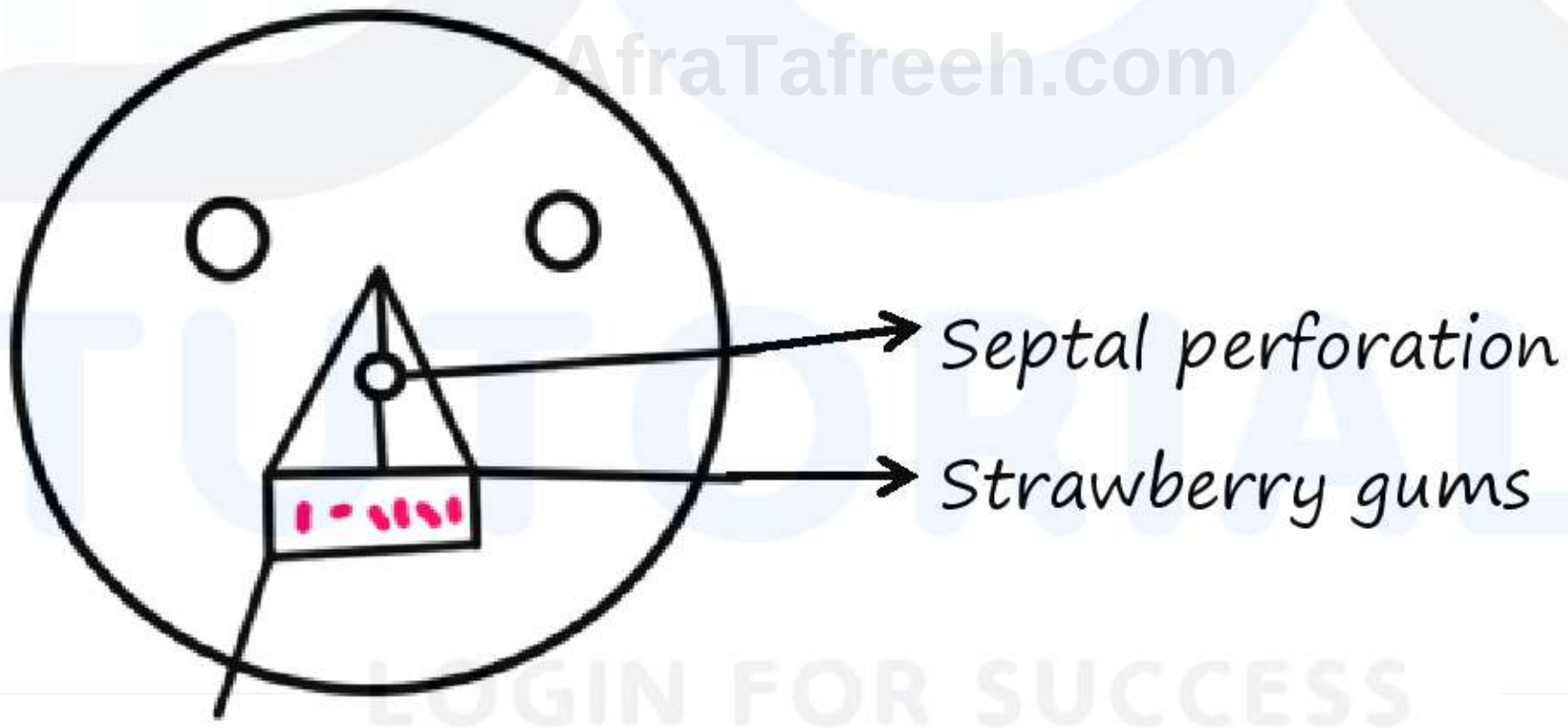

Q 40 year old O č septal perforation

- Leprosy
- Wegeners → granulomas + granulomatous Vasculitis
- NK/T cell lymphoma or lethal midline granuloma CD16/CD56 (+)

AfraTafreeh.com



- Confirm diagnosis by CANCA
- Treatment – immediate Cyclophosphamide anti TNF therapy

ANCA

C ANCA	P ANCA
Proteinase 3	MPO

- Dye used for immunofluorescence – FITC Flouro iso-thiocyomase used green Flourescence
  Rhodamine – Red Flourescence

Panca

Microscopic Polyancitis Hypersensitivity vasculitis (MPA)

- PANCA Abs (more common than churgg strauss)

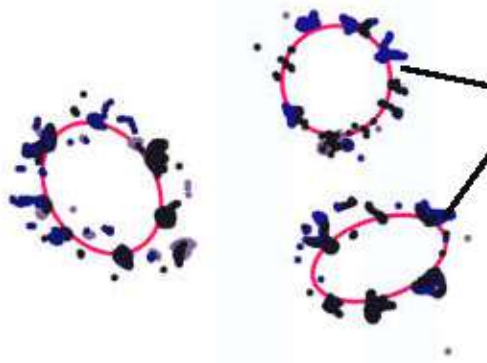

Neutrophil debris

- Leukocyte fragment >c/a leukocytoclastic vasculitis

Churgg Strauss syndrome Allergic Granulomatous with polyangitis

- Granulomatous vasculitis
- Asthma + eosinophilia's
- Incresed IgE
- H/O atopy

Mc COD = Restrictive (CMP) cardiomyopathy

PANCA(+) – in Few cases

AfraTafreeh.com

Microscopic polyangitis

Some unknown Ag –Ab complex

Deposited in vessel wall

↓

Attract neutrophils

↓

Neutrophils can't enter small vessels

AfraTafreeh.com



- Get fragmented
  - Inflammation of vessel well -> Palpable purpura
  - Biopsy:- one stage of activity of neutrophils (vs PAN – all stages of activity)

Microscope polyangiitis (C/a micro PAN)	PAN
- Small vessel vasculitis - One stage - Mc involves – pulmonary capillaries - Associated with GN progress to RPGN - Can progress to cresentric GN	• Medium sized vessel affected • All stages of activity • All vessels except pulmonary vessels • No GN

Henoch schonlein purpura (HSP). 00:40:35

- Small vessel vacuities
- M/c vasculitis in child

Immune complex mediated
↓
Ag = infective
↓
Body makes IgA
↓
Neutrophils infiltrate the vessel wall but cannot enter small vessels

Biopsy

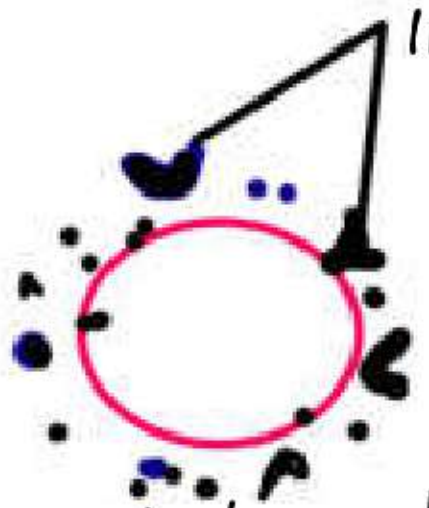

- If = IgA Ab
- Ag- Ab complex in skin – palpable purpura on extensor surface of arms & lugs
- Arthralgia
- Abdominal pain – ischema
- Runal – mesangio proliferative GN
- Platelet levels (N)

AfraTafreeh.com
TUTORIALS
LOGIN FOR SUCCESS

AfraTafreeh.com

SPECIAL TYPES OF VASCULITIS

Behcet's disease 00:00:06

- Small + medium size vessels affected
- Silk route disease - travellers along silk route would get affected
- Triad of
  - Relapsing uveitis
  - Recurring genital ulcers
  - Recurring oral → Hallmark
- Ulcers - painful with red rim + necrotic center
- HLA – B51 (+) polymorphism seen in silk route travellers

  ↓
- Present to T cells → Change to TH17

  ↓

  Activate neutrophils

  ↓

  Infiltrate blood vessels.
- Pathergy test: 0.1 ml isotonic saline injected, in volar aspect of forearm

  ↓

  Read after 24-48 hrs of prick

  ↓
- Positive test – If papule/Pustule > 2mm & depth of > 5mm

SLE vasculitis / APLA vasculitis. 00:05:41

- Ag – Ab disease
- Dx: Immune fluorescence – IgG
  - C1
  - C3
- Usually in Juvenile patients
- Vasculitis – a criteria of severity in SLE

Thromboangitis obliterans (TAO) or Burger's Disease 00:08:10

- Young 20 – 35 years
- Hypersensitive to tobacco

AlfaTafreeh.com

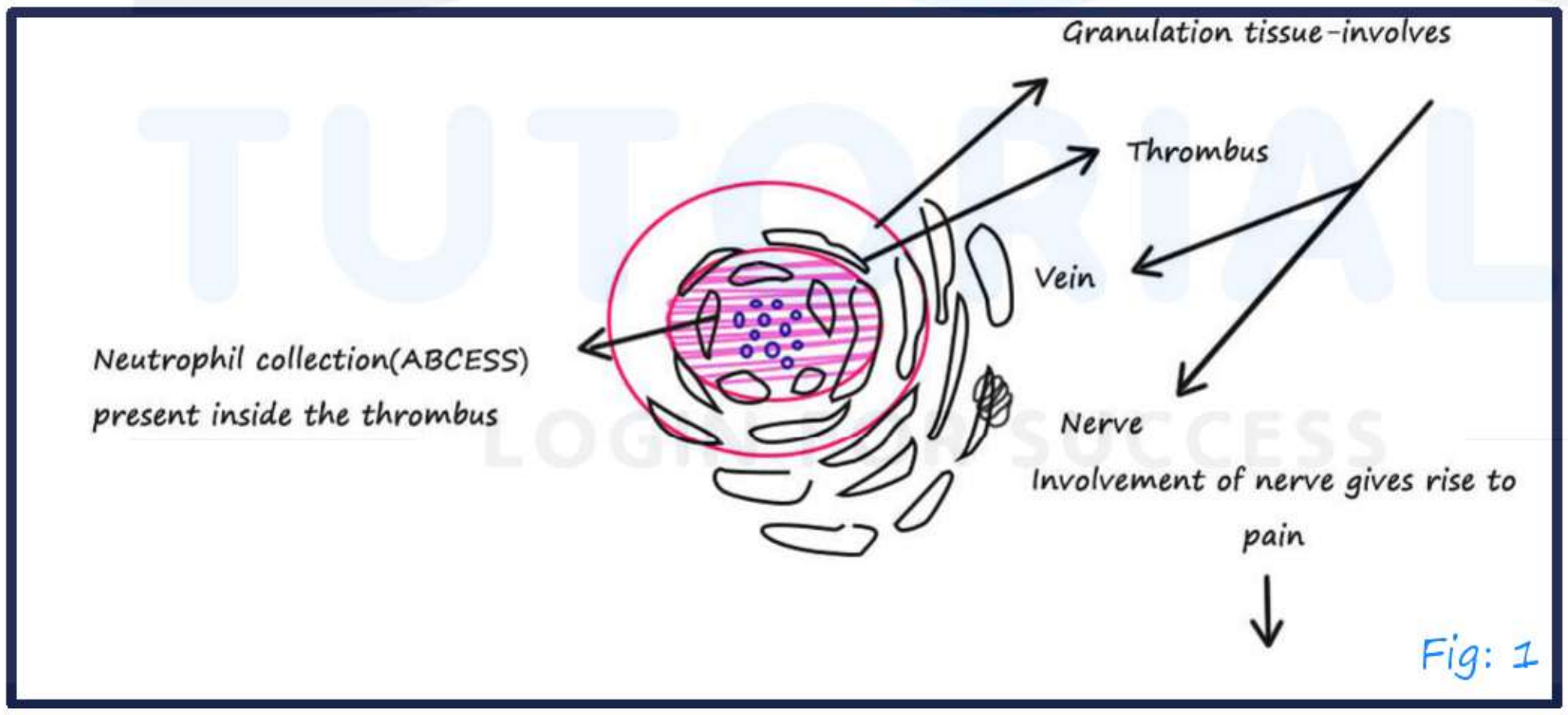

Fig: 1

- Typically involve – **Tibial** / radial arteries
  ↓
  In step claudication
- Unique : both acute + chronic inflammation
  ↓ Abscess ↓ Granuloma
- medium + small vessel vasculitis

AfraTafreeh.com

- Thrombo – angitis obliterans
  Thrombus d/t abscess obliterating the lumen
- eventually process to **Gangrene -→ Amputation**
- Treatment – Quit smoking

Summary Of Vasculitis 00:19:02

- Causes granulomatous vasculitis
  i. Temporal
  ii. Takayas
  iii. Churg Strauss
  iv. Wegners
  v. TAO - Acute to chronic, involves nerve Medium +small vessel 18 vein
- Leukocytoclastic vasculitis (LCV)
  I. Microscopic polyangitis
  II. Henoch schnohlein Purpura - IF - IgA antibodies
- Neutrophilic vasculitis - Behcet's disease (HLA B51 polymorphism)
- Fibrinoid necrosis
  - PAN
  - Kawasaki's disease – aneurysm / Anti-endothelial Abs

Bartonella

Henselae	Quintana
• Causes excess proliferation of vessel • Peliosis hepatis (i.e liver)	• Used to cause a disease called Trench fever during WWI

AfraTafreeh.com
TUTORIALS
LOGIN FOR SUCCESS

AfraTafreeh.com

TUMORS OF BLOOD VESSELS

Tumors of Blood vessels 00:00:30

Benign	Intermediate	Malignant
• Tendency to form vascular lumen • Known as hemangioma • Lymphangioma if happens in lymphatic vessels • Glomus tumor	• Kaposi sarcoma • Hemangio endothelioma	• Lumens are not formed properly • Has irregular proliferation of cells • Called as Angiosarcoma • Hemangioma pericytoma

Vascular abnormalities

Vascular Ectasia	Being Vascular Proliferation
• Nevus flammens (port wine stain) • Spider angioma • HHT (Hereditary Hemorrhagic Telangiectasia)	• Bacillary angiomatosis • Abnormal proliferation of vessels in response to organism called bartonella

TUTORIALS LOGIN FOR SUCCESS

BENIGN TUMORS OF BLOOD VESSELS

Hemangioma's 00:00:10

- Proliferation of thin sized capillaries separated by connective tissue

  i. CAPILLARY HAEMANGIOMA

    - Most common type of hemangioma
    - occurs in – skin
      - mucous membrane

- Juvenile hemangioma /Strawberry hemangioma a type of capillary hemangioma in newborn
- Regress maximally by 7 years

AfraTafreeh.com

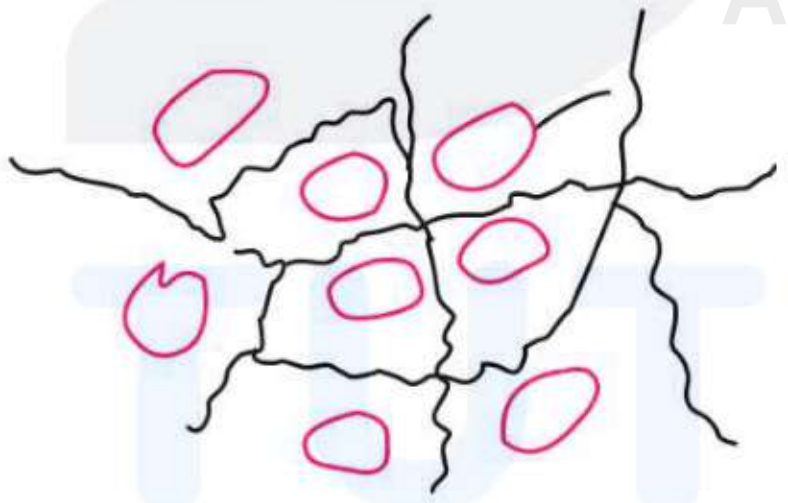

Thin blood vessels

Connective tissue septa

DOCTUTORIALS LOGIN FOR SUCCESS

- This is an un encapsulated tumor

  ii. CAVERNOUS HAEMANGIOMA

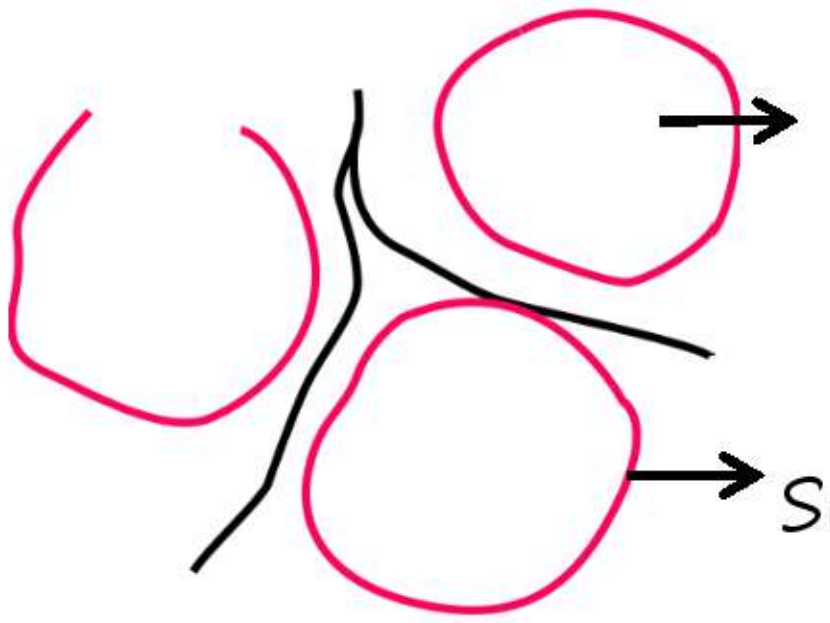

large cavernous thin-walled vascular spaces

Separated by fibrous septae

AfraTafreeh.com

- Un encapsulated
- Common sites – skin

↘ Liver

(D/d: Peliosis)

- Associated with VHL – Von Hippel Lindau syndrome (chromosome 3p)

↓

- Have multiple cavernous hemangiomas in
  - Liver
  - Pancreas
  - Cerebellum
- Thrombosis & dystrophic calcification is commonly seen
- Locally destructive, don't regress spontaneously

iii. Pyogenic granuloma or Lobular capillary Hemangioma (LCH)

- Name is a misnomer
- Usually occur in gum –c/a GUM TUMOUR
- Protruding tumor
- Earlier Thought to be a granulation tissue arising due to some infection

TUTORIALS LOGIN FOR SUCCESS

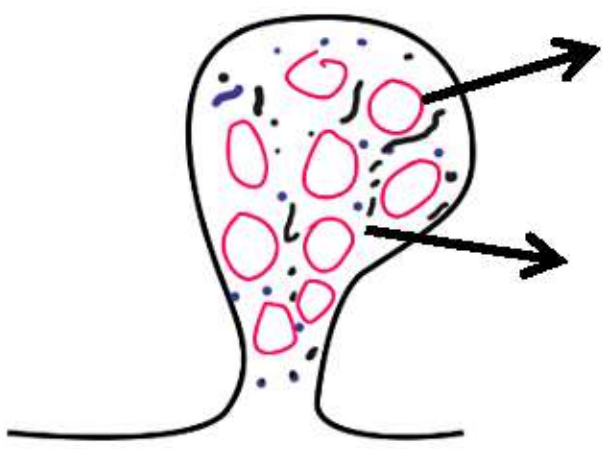

vascularity in pregnancy

Grows in pregnancy -

↑ ↓

Hence c/a pyogenic gravidarum

↓

Regresses after pregnancy spontaneous

Lymphangiomas 00:06:52

Lymphangiomas

- Simple lymphangioma or capillary
- Cavernous/ CYSTIC HYGROMAS
  - Associated with turner's syndrome (45 XO)
  - Commonly seen in neck & axilla

AfraTafreeh.com
TUTORIALS
LOGIN FOR SUCCESS

Glomus tumor/ Glomangioma

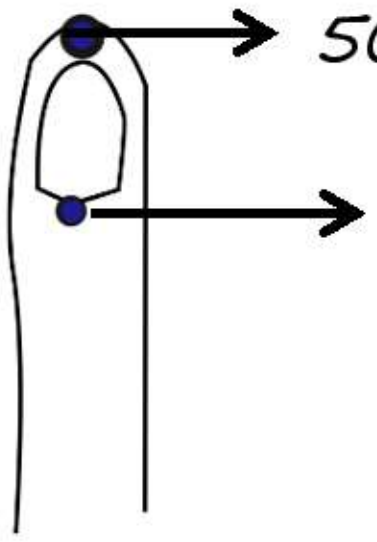

50% Nail lip -> Typical site

50% Nail bed

- Benign painful tumor
- Glomus cells- involved in thermoregulation

AfraTafreeh.com

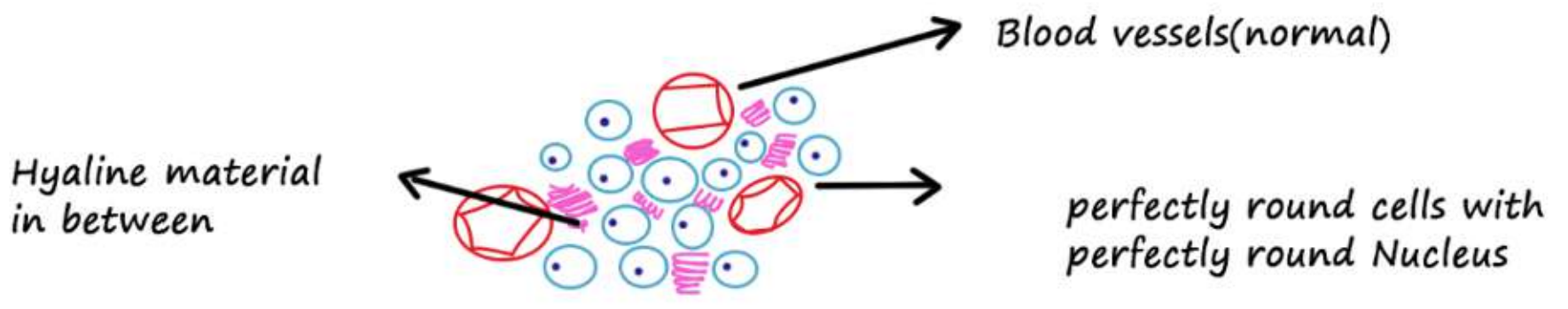

PUNCHED OUT Nucleus
GLOMUS TUMOR HISTOPATHOLOGY

- Most common site = distal phalanges

TUTORIALS
LOGIN FOR SUCCESS

KAPOSI SARCOMA

- Intermediate category limor
- Caused by KSHV/HHV8
- 2nd most common tumor in HIV (+) patients (most common is NHL [DLBCL])
- Most common site (OVERALL) = Skin of feet of lower limbs
- MC site – (Extracutaneous) = lymph node
- MC site – GIT = Duodenum

Types of Kaposi sarcoma

Sporadic	Endemic / African / Lymphadenopathy	Transplant associated	HIV associated KAPOSI Sarcoma
	Caused by HHV8		Caused by HIV virus
• Only seen in skin (very rarely involve viscera) • Not associated with HIV	• Lymph node • Aggressive tumor	• Lymph node mucosa viscera • Occurs in background of chronic immune-	• Lymph node viscera

AfraTafreeh.com
DOT TUTORIALS
LOGIN FOR SUCCESS

AfraTafreeh.com

• Seen in elderly males	suppression

Stages of Kaposi Sarcoma 00:04:16

i. Patch stage

ii. Plaque stage

iii. Nodule stage – most characteristic findings

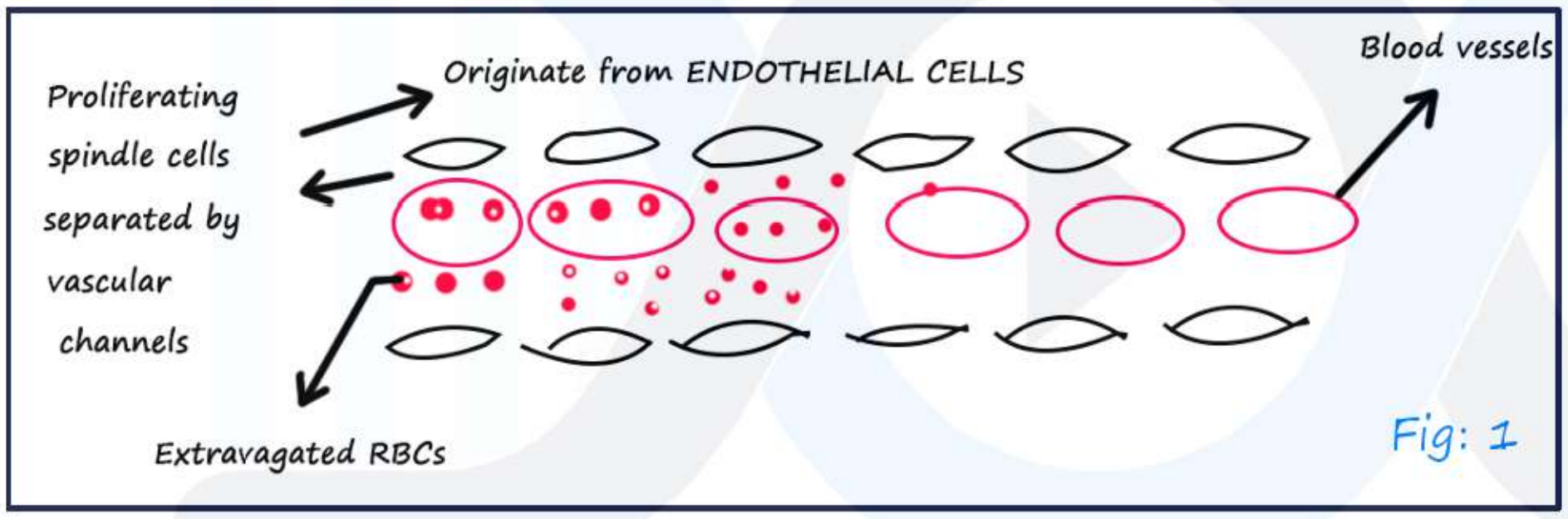

Fig: 1

Extra Edge info:

HHV8/KSHV related diseases

i. PEL/Primary effusion lymphoma
ii. DLBCL
iii. HHV8 + Multi centric Castle man disease
iv. Kaposi sarcoma

} May be co-associated with HIV

v. Germinotrophic lymphoproliferative disorder
vi. Plasmablastic lymphoma

} Associated with KSML only

MALIGNANT VASCULAR TUMORS

Hemangioendothelioma – Intermediate grade tumor

Malignant Tumors

Angiosarcoma	Hemangiopericytoma
- Cell of origin = Endothelial cells Become dysplastic Ido not from proper lumen ↓ Proliferate irregularly Aggressive tumor – early meta-stasis - Typical sites - Skin - Liver - Breast Factors VIII immunoreactive Most imp risk factors for liver angiosarcomas – thorotrast, arsinic, vinyl chloride MARKERS - CD34 - CD31 - VWF	-Originates – abnormal pericytes ↓ Cells which cover the vessels Eg: capillaries are made of -Endothelial cells -Basement membranes -Pericytes •Pericytes proliferate ↓ Turn into abnormal spaces 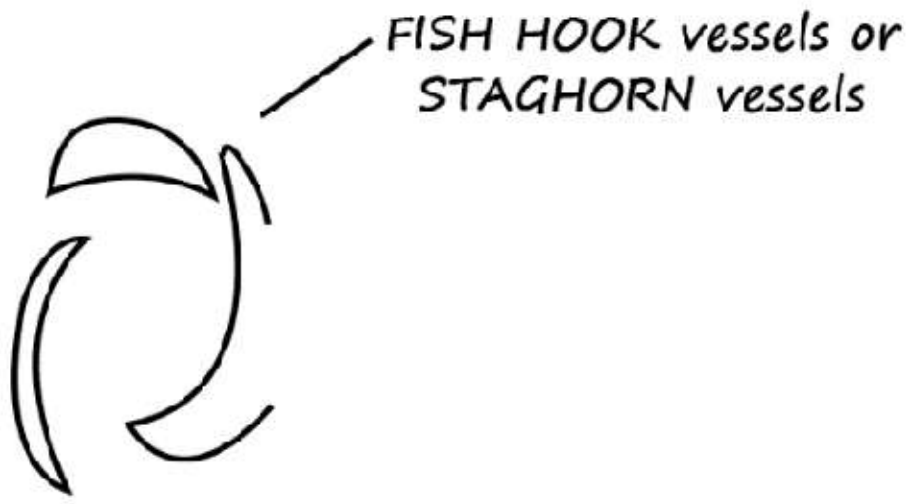

AfraTafreeh.com

AfraTafreeh.com

↓ Only way to confirm angiosarcoma is CD markers 	

Revision

- Thorotrast is a R/F of Angiosarcoma
- Pyogenic granuloma / granuloma gravidarum
- Pregnancy gum tumor
- Type of hemangioma
- Lymphangiosarcoma of Breast – seen in post mastectomy patients.

LOGIN FOR SUCCESS

Lymph after mastectomy

↓

Stagnates in arm lymphatics

↓

- Chronic irritation
- Chronic lymphedema
- C/a Stewart Treves Syndrome

] Chronic lymphedema sarcoma

- Endothelial markers =
  - CD34
  - CD31
  - VWF

Kaposi sarcoma = associated with

- HHV8
  - Sporadic
  - Endemic
  - Transplant associated
- HIV
  - Type IV
  - Immuno compromised

AfraTafreeh.com
TUTORIALS
LOGIN FOR SUCCESS

AfraTafreeh.com

VULVA

Vulva

Cysts

I. Bartholin cyst

- Location – Posterolateral Aspect of vaginal orifice
- lined by Transactional/ Squamous epithelium

Leukoplakia

Inflammation

psoriasis

Malignant

- Paget's disease
- Vulval intra epithelial neoplasia

Lichen simplex chronicus

Lichen Sclerosis

<table>
<tr><th>Lichen simplex chronicus</th><th>Lichen Sclerosis</th></tr>
<tr><td>
<u>Presentation:</u> – White patches (Leucoplakia) with trick leathery vulva skin
<u>Pathogenesis: –</u> Benign Hyperplasia of Vulvar epithelium secondary to itching due to pruritus
<u>Histology: –</u>
i. Type of squamous hyperplasia
ii. Epithelium appears thickened
iii. Lymphocytic infiltration of upper dermis
–Hallmark at histology– acanthosis
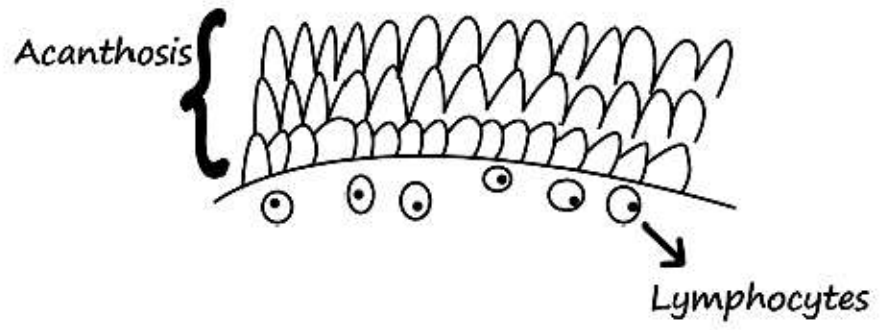

</td><td>
<u>Presentation</u>:
– White patch (Leucoplakia) which coal ease leading to a paper – thin – like stiff labia with a constricted skin, vaginal orifice
– more common in elderly women
pathogenesis: LS as an autoimmune disease with preference for a T_h1 immune response against a genetic background is summarized. As the exact pathogenesis of LS remains unknown.
<u>Histology: –</u>
i. Benign thin, flat squamous epidermal cells with band of fibrosis in upper dermis.
ii. Hallmark at histology dense collagen band.
iii. Lymphocytic infiltration of upper Dermis
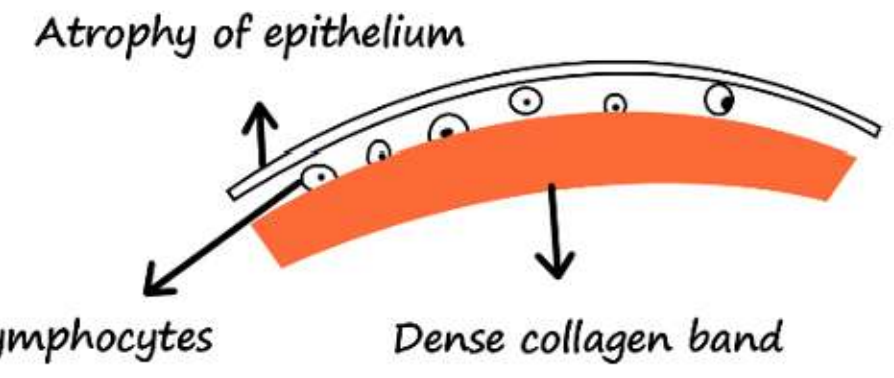

</td></tr>
</table>

- Both lichen simplex chronicus and lichen Sclerosis can progress to Vulval Intraepithelial Neoplasia VIN (Differentiated Type)

Vulval Intra – epithelial Neoplasia (VIN)

- Pre-malignant proliferation of Vulval Squamous epithelium
- Basal epithelial cells now dysplasia
- Can progress to squamous cell carcinoma of vulva

Malignant Lesions of Vulva

- Paget's disease
- Squalors cell ca
- Glandular Lesions
  - Papillary Hidradenoma Similar to Ductal papilloma of Breast
  - Extra mammary Paget's Risk of Adenocarcinoma

AfraTafreeh.com

Extra Mammary Paget's: -

(Risk of Adenocarcinoma)

Presentation: - Erythematous, Prolific, ulcerated crusted valval skin

- Paget's disease of breast is amounted with underlying malignancy in 100%

AfraTafreeh.com

- Cases.
- While Paget's disease of vulva has underlying malignancy only in 12% of the cases.
- Ex Postulated that mammary glands like structure are present in vulva which can modify into → Apocrine or sweat glands.

Histology: –Glandular Tissue visible with normal squamous cells. No Invasion Paget's cells with clear cytoplasm – full of Monopoly saccharides → Stained positively by PAS/Alcian blue / Mucicarmine.

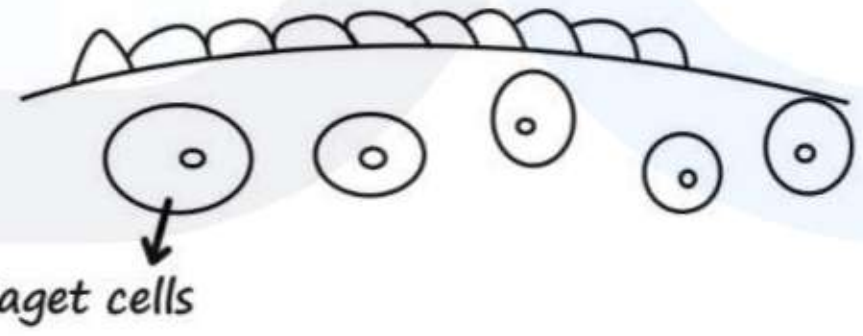

- IHC- CK 7 ⊕

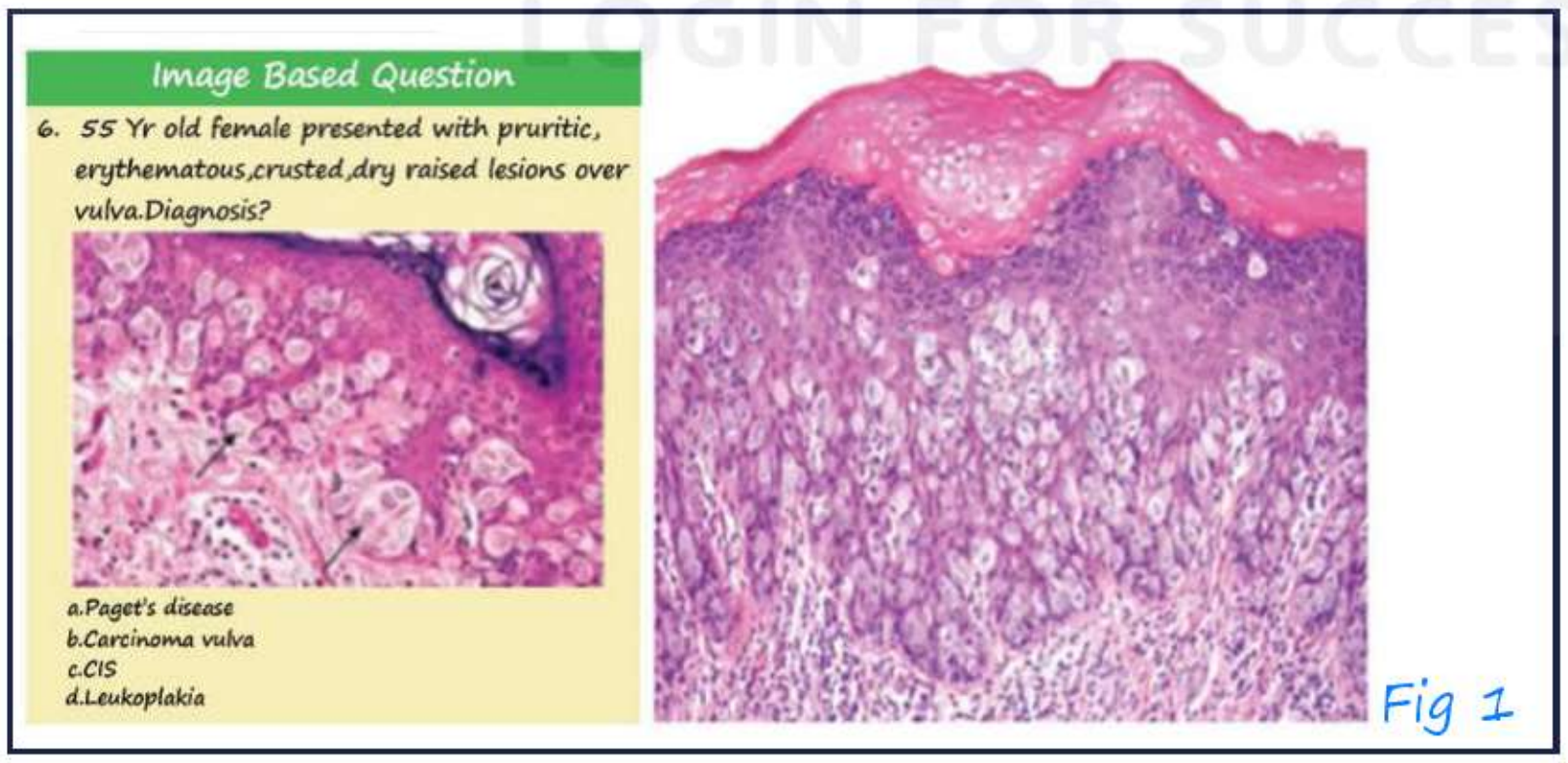

Fig 1

TUTORIALS LOGIN FOR SUCCESS

Squamous Cell Carcinoma of Vulva

- M/C Type of Vulval Carcinoma

Arise from Vulval Intra – epithelial Neoplasia

Clinical VIN

- HPV Injection Related
  - warty
  - basaloid
- Induced by HPV-16
- Carcinoma in Situ – aka Bowen's disease
- Younger age group

Differentiated VIN

- Not associated with HPV infection Secondary to Lichen Sclerosis or Lichen Simplex Chronicus
- Basal cells show Dysplasia
- Warty Basaloid Progresses to Keratin sing SCC in 70% Cases.
- Elderly females

Basaloid or warty SCC

- Multifocal
- In younger
- Related to HPV infection
- Clinical VIN

Keratinizing SCC

- Unifocal
- In older
- Not related to HPV infection
- Differentiated VIN
- On histology – keratin pearls

AlfaTafreeh.com

Vulval Cancers metastasize to Inguinal Lymph Nodes

Identified by Sentinel Lymph Node Biopsy

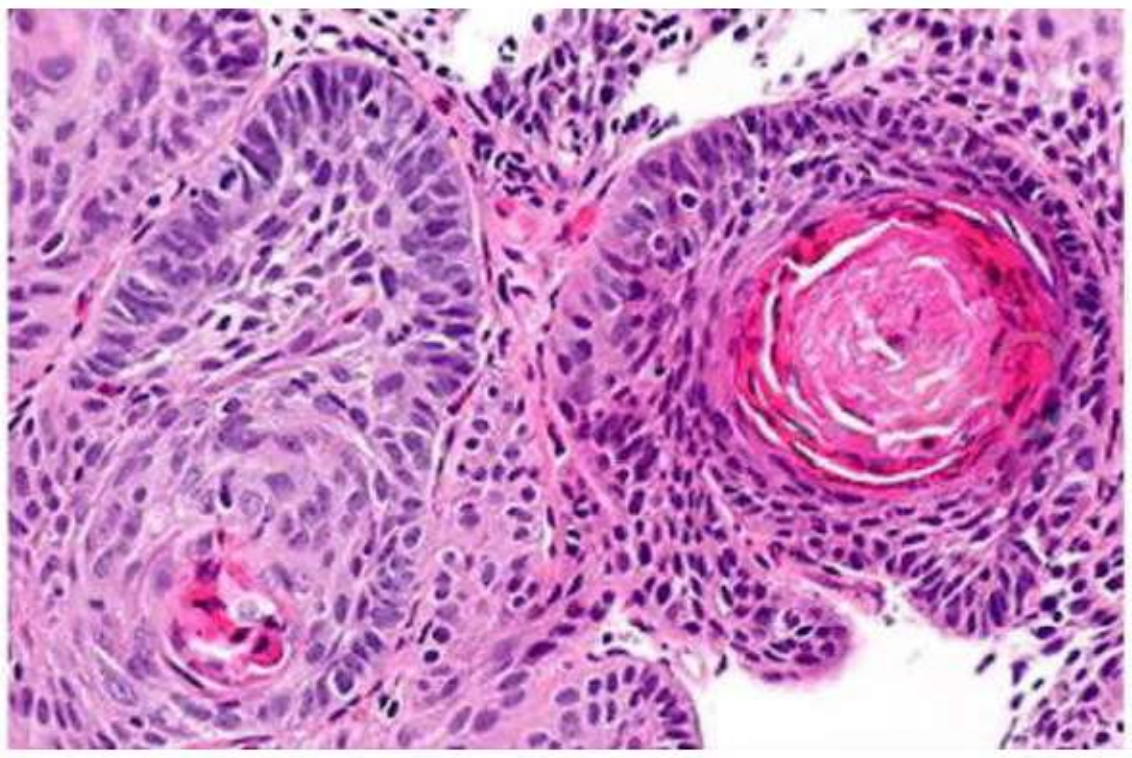

Fig 2

AfraTafreeh.com

Condyloma: - 00:23:32

Benign xerophytic lesions

- Condylar Acuminata
- Condylar Latum

- Papillary lesion seen with Low grade HPV-6, 11 infections

Histology: -

i. Koilocytosis Raisinoid nucleus with Perinuclear Halo

ii. Papillary fronds

iii. Thickened Squamous epithelium → Acanthosi

iv. No Dysplasia

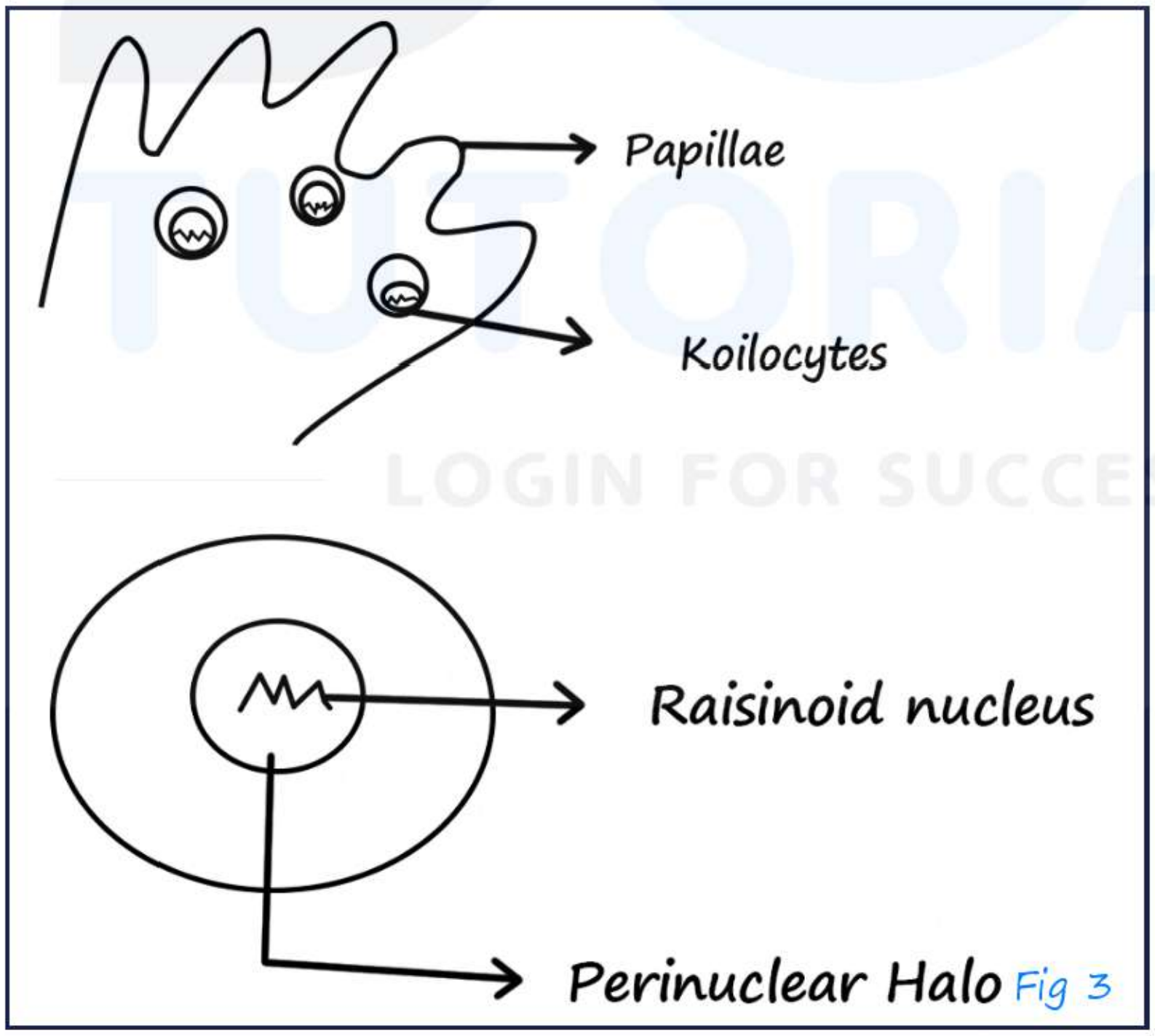

Fig 3

VAGINAL TUMORS

Vaginal tumors 00:00:14

Vaginal Tumors

SCC	Adenocarcinoma	Embryonal Rhabdomyosarcoma
• M/C malignancy of vagina • HPV associated • Usually, an extension from the cervix • Occurs in the posterior 1/3rd especially at the Junction of ectocervix • Well differentiated SCC will show keratin pearls	• Due to exposure to diethylstilbestrol (DES) in utero • Risk vaginal adenosis and clear cell carcinoma • occurs in upper 1/3rd of anterior wall	

AfraTafreeh.com
TUTORIALS
LOGIN FOR SUCCESS

Embryonal RhabdoMyosarcoma (ERMS)

00:03:24

- Children – 5 yrs.
- Presentation – grape –like clusters (botyroid) protruding from vagina
- Also called as botyroid variant ERMS

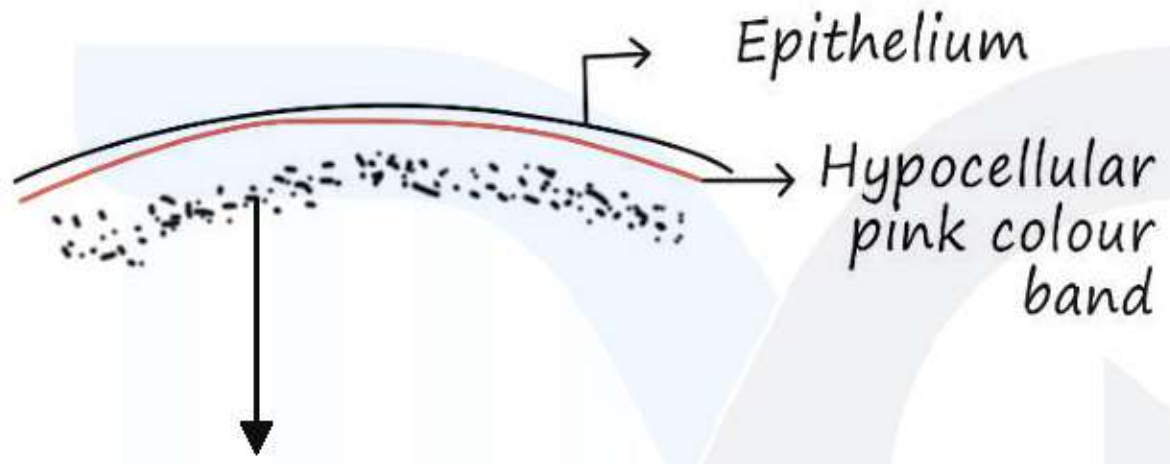

Cambium layer: Cluster of Hyper cellular Tumor cells



- Small round tennis rocket shaped tumor cells
- On IHC → Strongly positive for Desmin
  Myogenic
  Myo D1
- SPECIAL STAIN – PTAH stain (phosphor tungstic acid hematoxylin stain)

↓

Shows striations in skeletal muscle tumors

- Prognosis of embryonal Rhabdosarcoma is good.

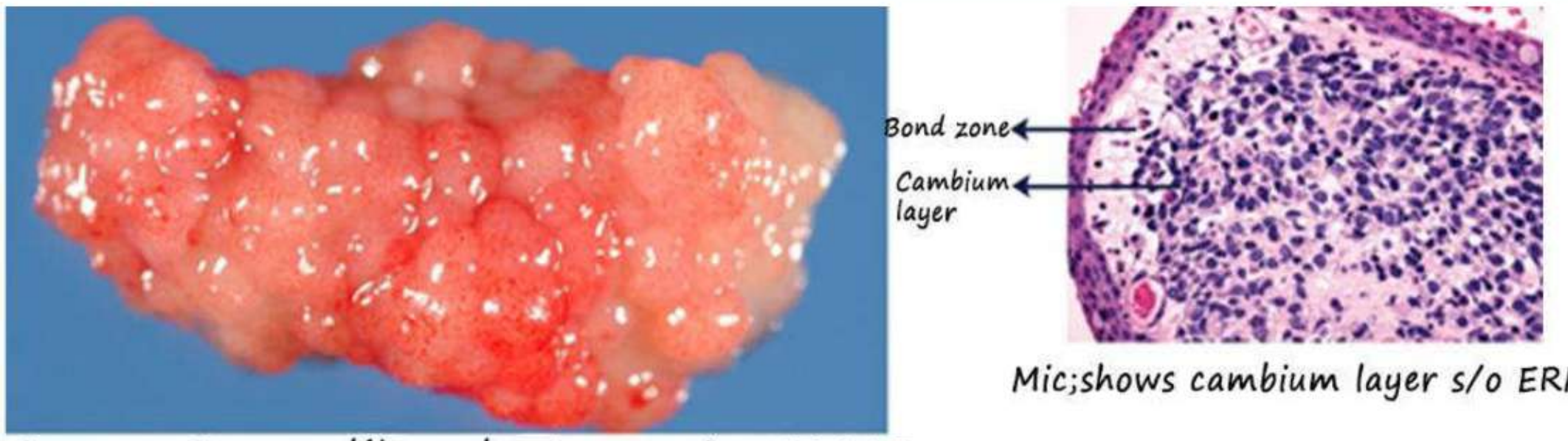

Gross: Grape like clusters s/o ERMS

Mic;shows cambium layer s/o ERMS

Fig 1

AfraTafreeh.com
TUTORIALS
LOGIN FOR SUCCESS

AfraTafreeh.com

ENDOMETRIUM

Endometrium 00:00:10

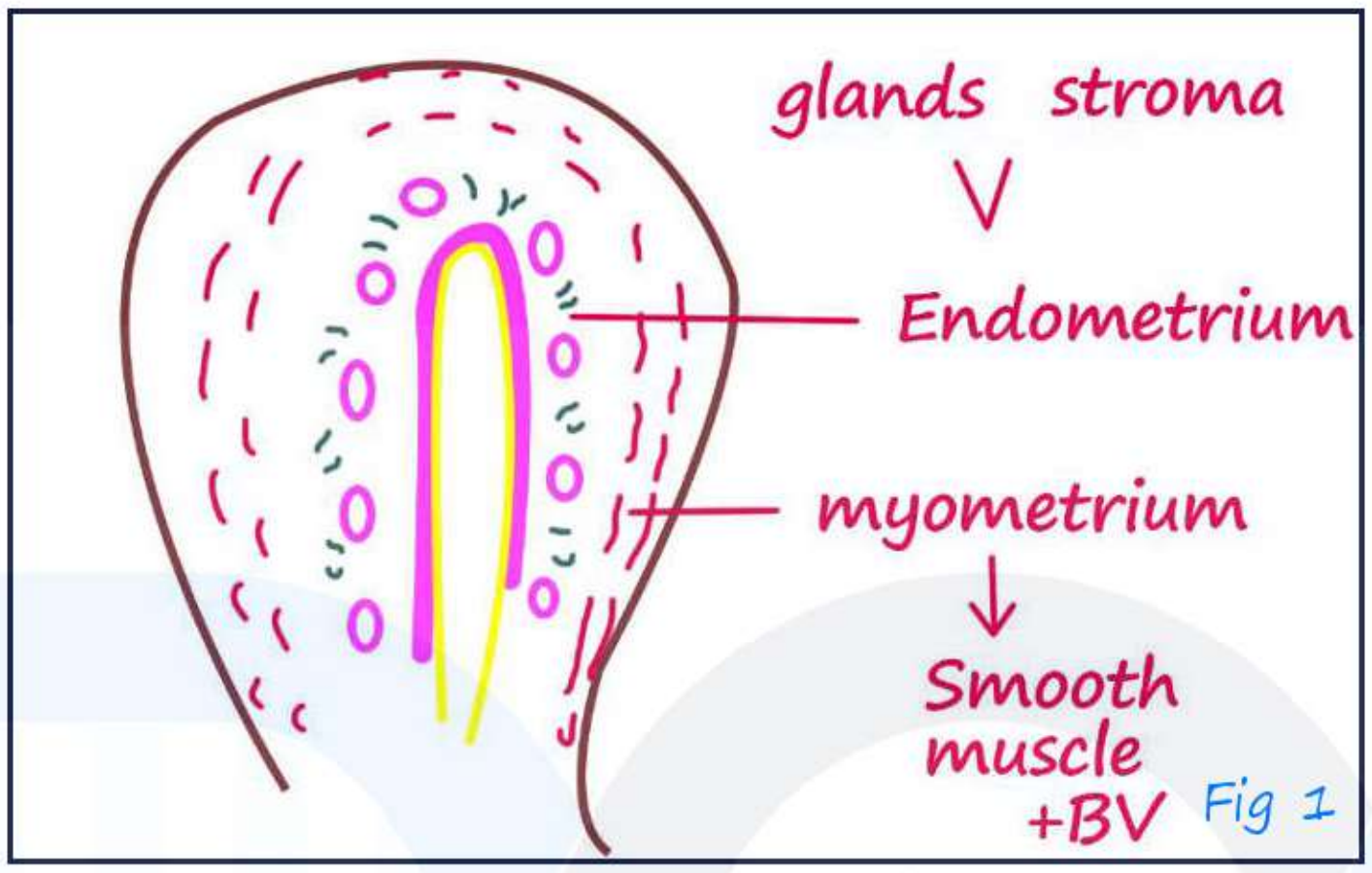

Fig 1

Endometrial Cycle:

- Under estrogen → Proliferative phase
  ↓
  Glands of Endometrium –Round & compact with compact stroma

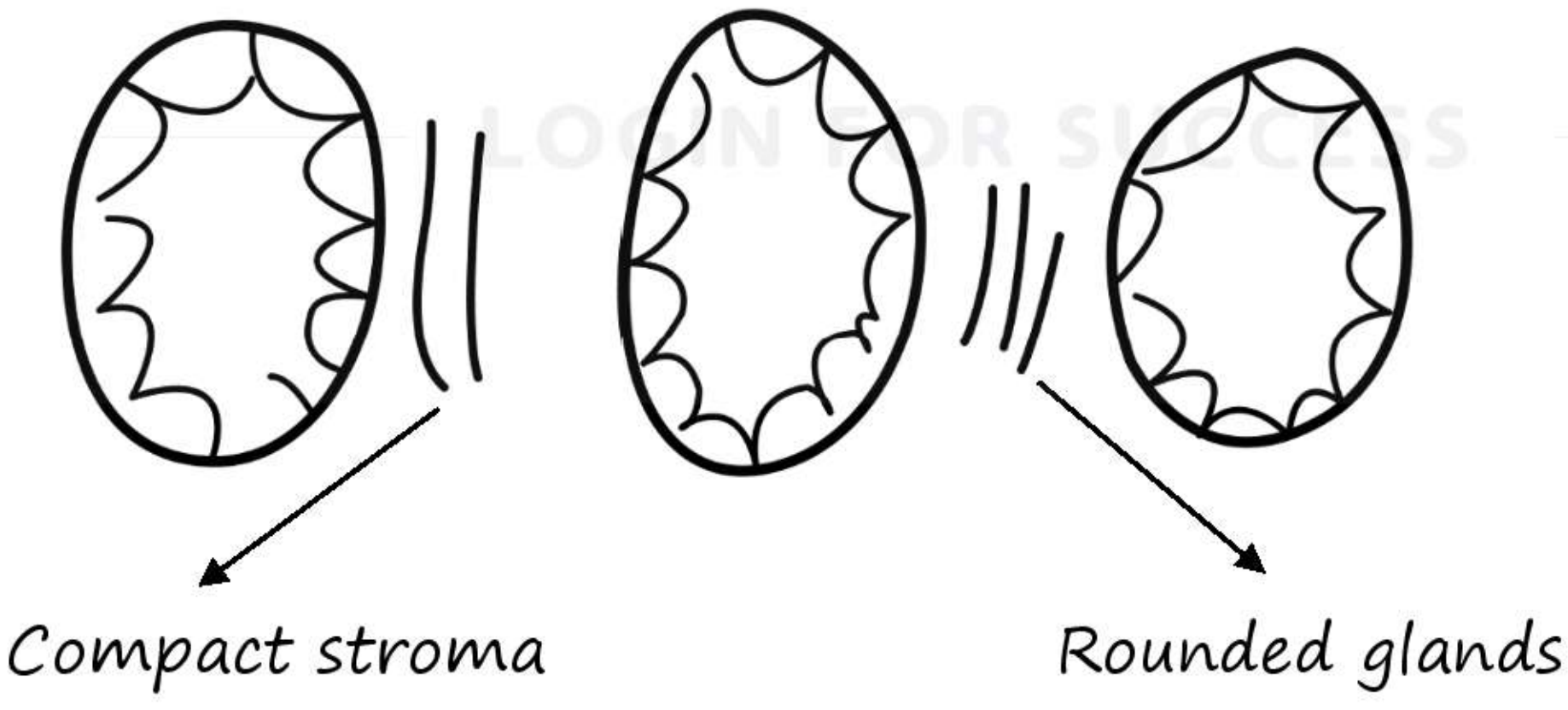

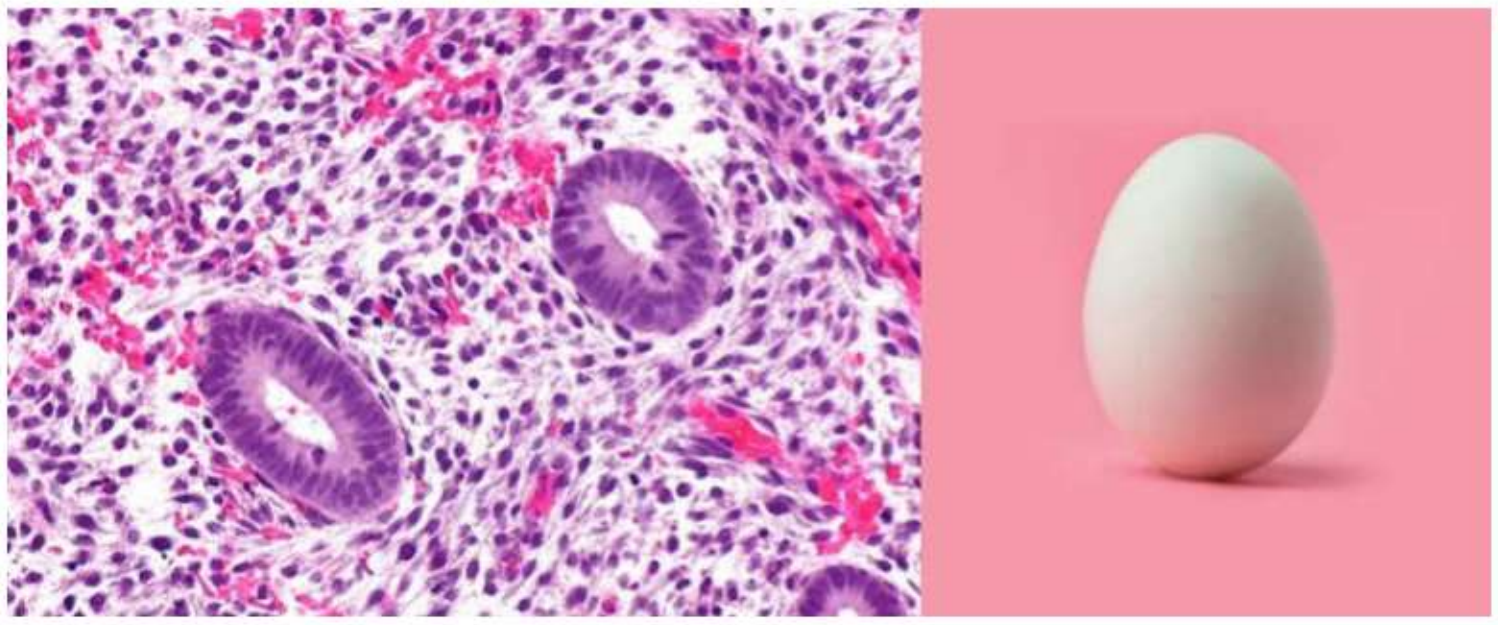

Proliferative endometrial glands Fig 2

Early Secretary phase:

- Sub nuclear vacuoles see
- Piano appearance of glands

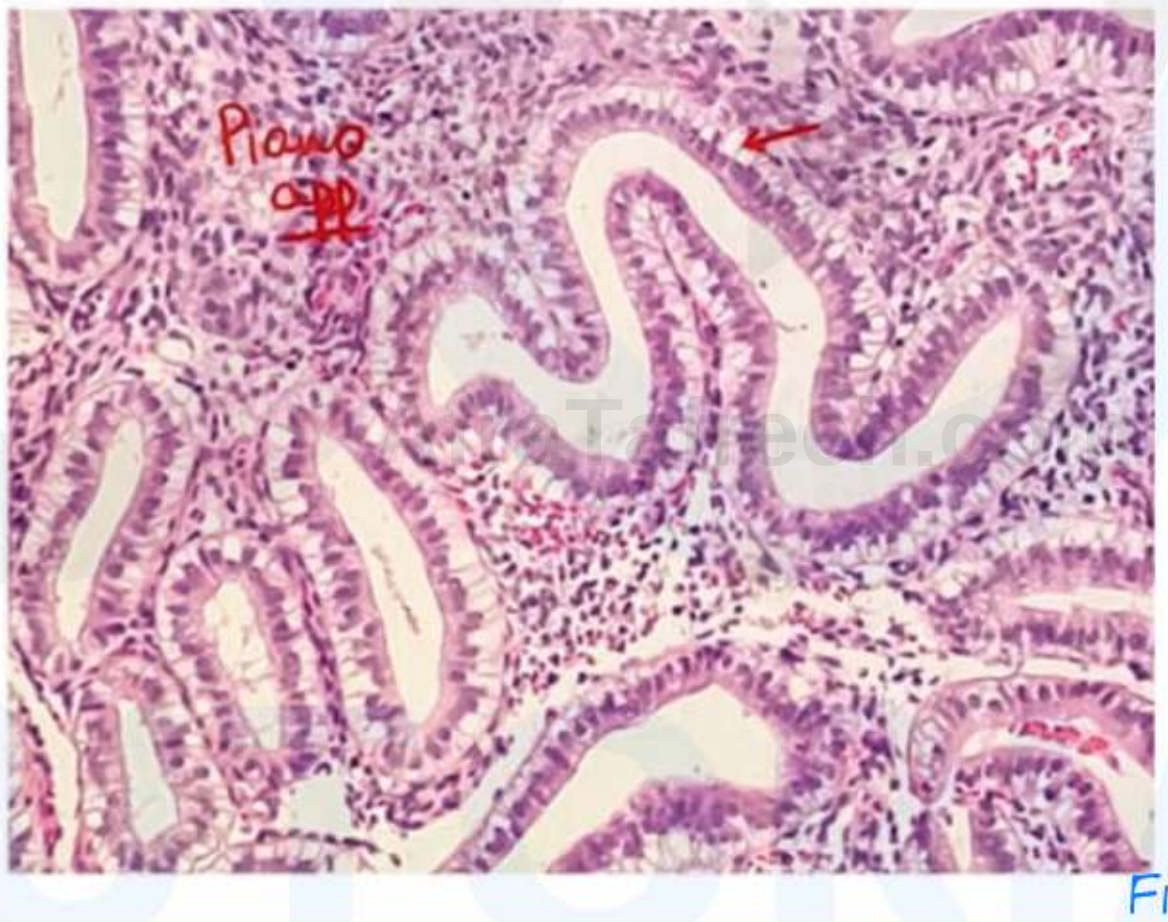

Fig 3

- Late secretary phase

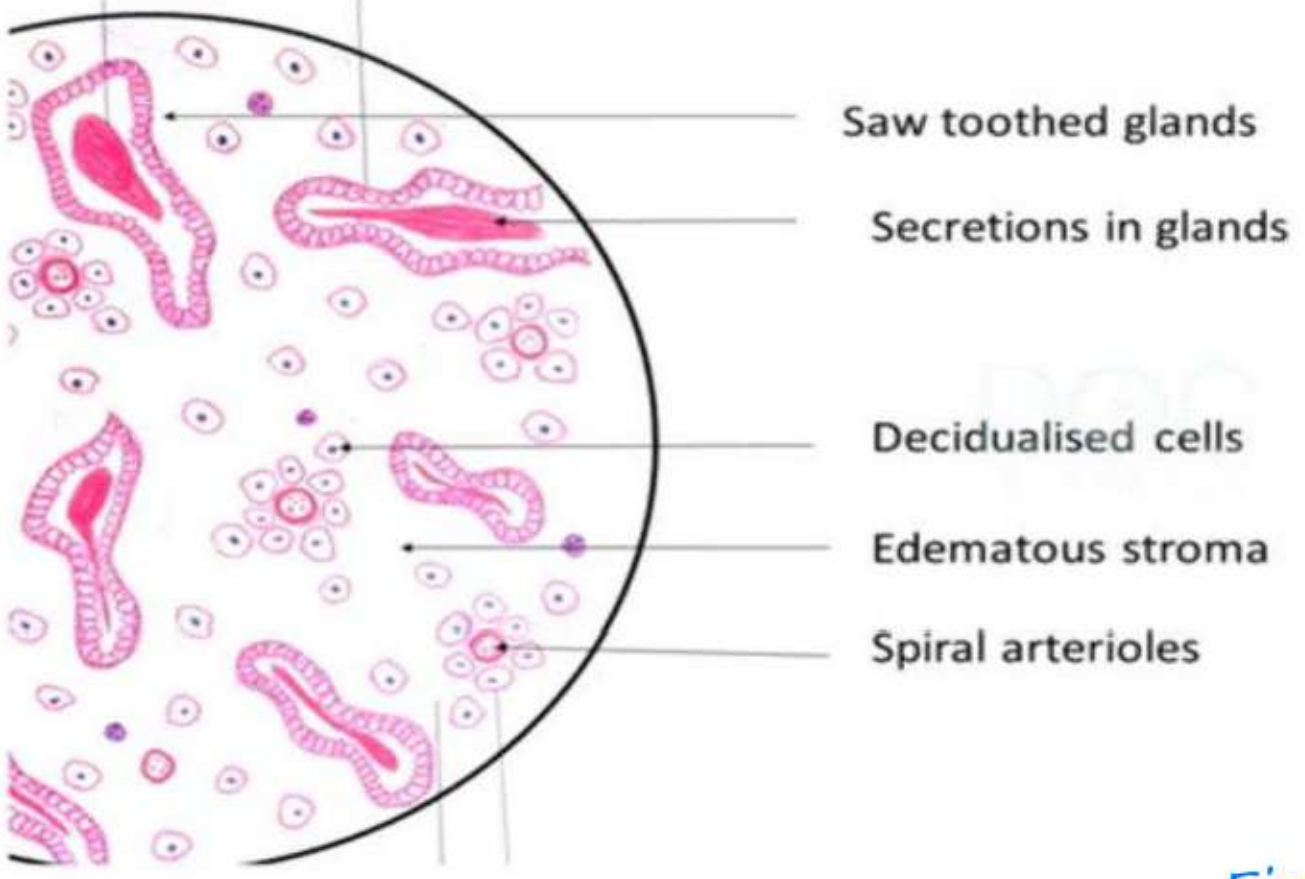

Fig 4

AfraTafreeh.com

- Menstrual phase → shedding of Endometrium

Endometritis 00:07:10

- Inflammation or irritation of endometrium
- **Acute Endometritis** – Characterized by injection, due to abortion, medical instrumentation and retention of products of conception.
- **Histology** –Neutrophilic infiltration of endometrium

Chronic Endometritis – More common

- Chronic nonspecific Endometritis
  - On Histology plasma cells infiltrating endometrial glands
- Chronic Tubercular Endometritis
  - Caseating epithelioid cell Granuloma with Langerhans giant cells

TUTORIALS
LOGIN FOR SUCCESS

Hyperplasia

- Simple
  - Cystically dilated glands
    - W/ atypia
    - W/o atypia
- **Complex**
  - Glands show branching and are arranged back-to-back
  - Stroma increased markedly

Simple → W/o atypia → Cystically dilated glands without atypia

→ W/ atypia

Fig 5

- 8% chances of developing into cancer

- Cystically dilated glands without atypia

  a. prominent nucleoli

  b. Anisonucleosis

  c. Haphazardly arranged Nucleus

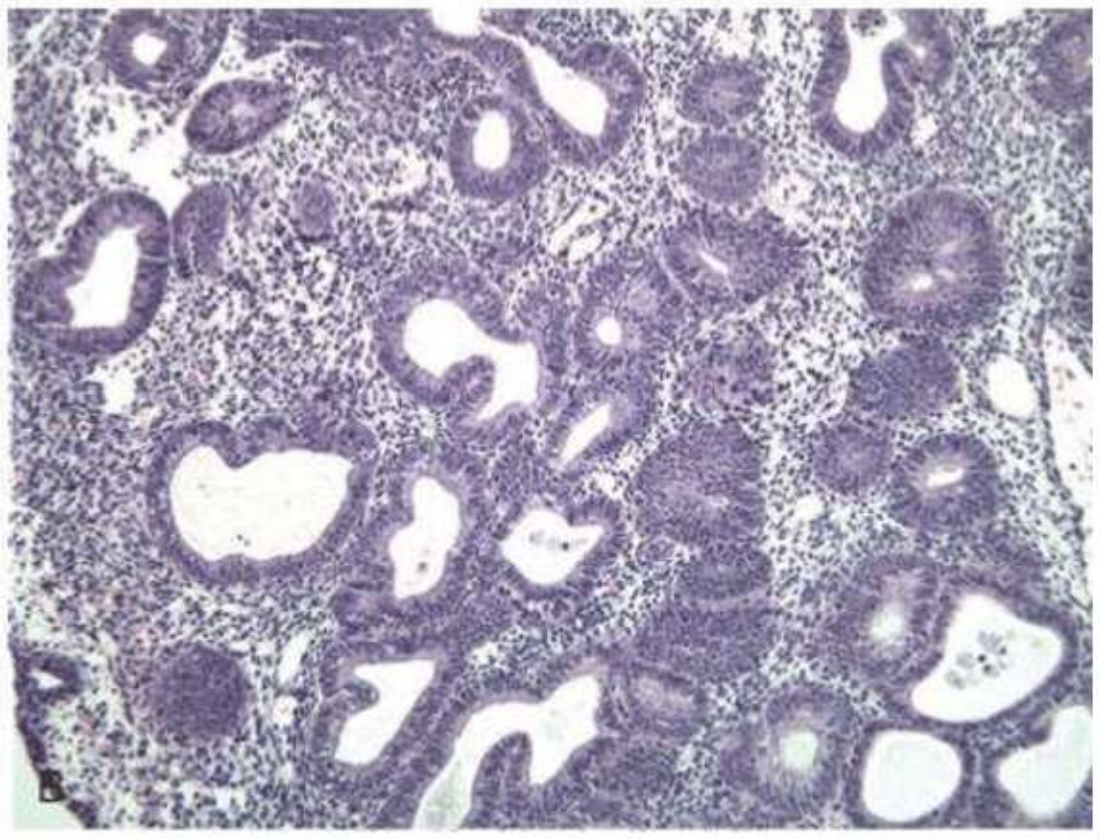

Fig 6

AfraTafreeh.com

Complex → w/o Atypia

Branched glands stroma

↓ (N)

Epithelium

Complex arrangement of glands with atypia of nucleus

→ W/o Atypia

- 25-48% show progression into cancer, at the time of presentation

Causes of endometrial hyperplasia:

- Conditions with excessive estrogen levels
  - PCOD
  - Granuloma cell Tumor of ovary
  - Diabetic
  - Hypertensive
  - Obesity
- Hyperpl~~asia progr~~ession type I Endometrial cancer or endometrial carcinoma

Genetic Basis

↓

Estrogen excess

↓

Proliferating endometrium

↓PTEN mutation

Non atypical hyperplasia

↓KRAS mutation, MSI

Atypical hyperplasia

↓ AR1D1A, B-catenin [CTNNB-1] mutation

↓PI3 kinase mutation

Type-I Endometrial cancer: 00:18:48

Features of endometrial cancer Type-I:

- Premenopausal females [55-65 years]
- Prespring factors –Diabetes, Hypertension, obesity, estrogen excess
- On Histology–Endometrial type
- Good prognosis
- Mutations – PTEN, KRAS, AR1D1A
  MSI β-catenin
  PI3K

AllaTalreen.com
TUTORIALS
LOGIN FOR SUCCESS

ATROPHY: 00:21:19

- In post-menopausal females 65-75 years

AfraTafreeh.com

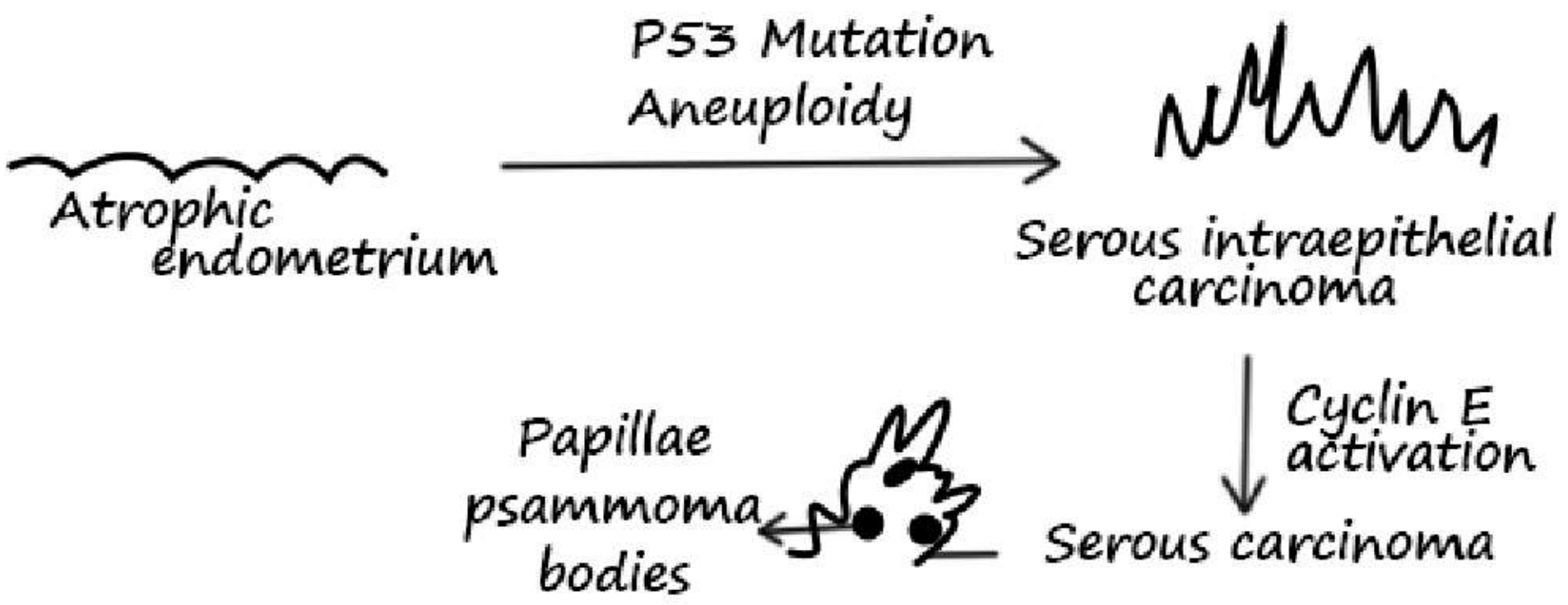

- Serous carcinoma
  - High grade tumor
  - FIGO grade -3
  - Very poor prognosis
  - So Endometrial Atrophy progression to Type II Endometrial Carcinoma

Features of Type II Endometrial Carcinoma:

00:24:02

- Elderly females 65-75 years
- Thin females, atrophic endometrium
- High Grade Cancer
- Types
  - serous
  - Clear cell
  - Malignant mixed Mullerian tumor (MMMT)
- Worse prognosis
- Mutation
  - P53 Aneuploidy
  - Aneuploidy
  - Cyclin E activation

Malignant mixed Mullerian tumor:

- Also called as carcino-sarcoma
- Shows both malignant epithelial & mesenchymal component
- Mesenchymal –Malignant spindle cells
- Other tissues –cartilage, bones etc.
- High grade-poor prognosis
- Endometrial Tumors

Endometrial Tumors

- Tumor of glands
  - ↓ Endometrial carcinoma
    - Type I
    - Type II
- Tumor arising from stroma
  - ↓ Endometrial stromal sarcoma
    - + (7,17)
    - Invades into lymphatics
    - Grows-Yellowish Ropy extensions
    - Marker of choice for identification CD 10 positivity

FIGO grading

1.< 5% solid areas

2.5-50% solid area

3.> 50 % Solid areas

AfraTafreeh.com
DOC TUTORIALS
LOGIN FOR SUCCESS

AfraTafreeh.com

Endometriosis:

- Ectopic endometrium at any site except utures
- M/C location –ovary [chocolate cysts]
- Postulated theories:
  a. Retrograde spread of endometrial tissue into ovary
  b. Metaplastic theory –endometrial metaplasia in ovary
  c. Stem cell theory –stem cells in ovary transform into Endometrial tissues

Diagnosis based on presence of any 2 of the following:

1. Endometrial glands
2. Endometrial stroma
3. Hemosiderin laden macro phases

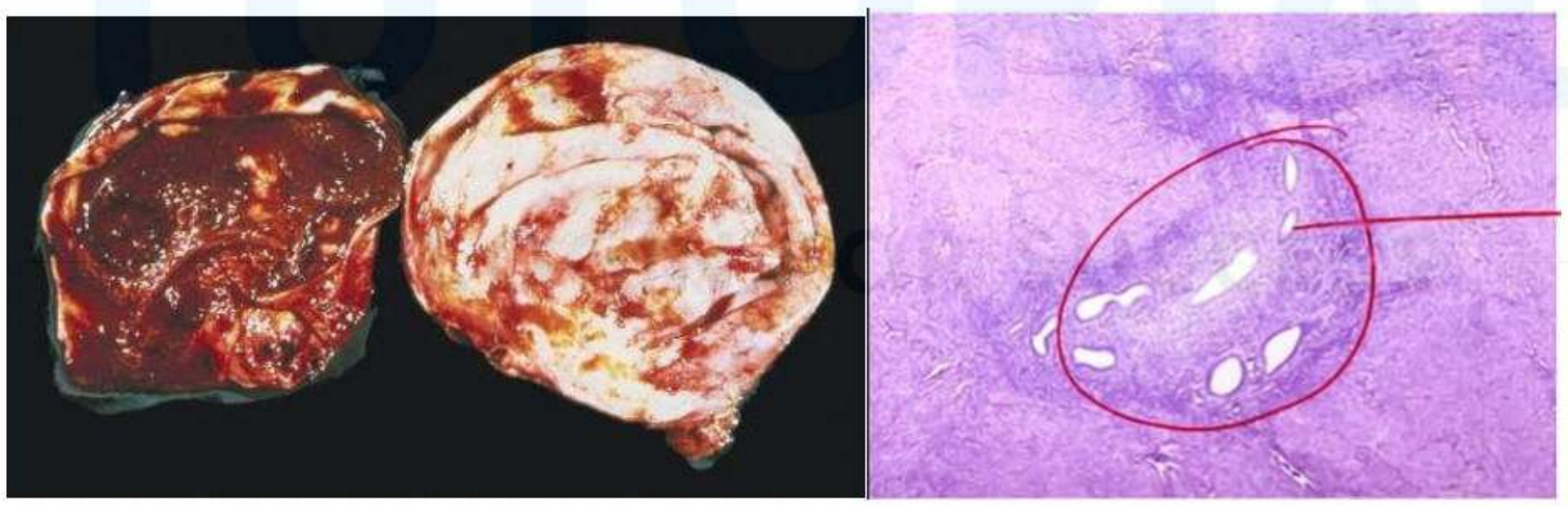

Fig 7

Adenomyosis:

Fig 8

- 2-3 mm from basa layer
- Ectopic presence of endometrial glands deep (2-3mm) into myometrium
- Enlarged uterus with hemorrhagic spots in myometrium

Fig 9

- Microscopy

AfraTafreeh.com

Fig 10

- Endometrial glands in myometrium

Sites of Endometrium:

- Ovary > pouch of Douglas > Posterior leaf of broad of ligament

Appearance of Endometriosis: 00:32:25

- Red flame lesions → new lesions
- Powder burn appearance of older lesions

Fig 11

- Peritoneal defect due to chronic endometriosis is known as Allenmasters syndrome.

MYOMETRIUM

Myometrium 00:00:18

Monckeberg sclerosis

- Calcification of media of myometrial blood vessels
- dystrophic calcification

Tumors

- Leiomyoma or fibroid uterus – most common benign tumor of uterus
- Leiomycosarcoma

LEOMYOMA- Histology

- Proliferation of smooth Muscle Cells
- Arranged in a whorled Pattern s
- Cigar shaped Nucleus.



Fig 1

Fig 2

AfraTafreeh.com

- Mutation –MED12
- Degenerations in Leiomyoma / Fibroid
    a. Hyaline degeneration – M/C Type of degeneration
    b. Red degeneration
- Complications of pregnancy
- Rupture of small vessels → Blood oozes into leiomyoma → Reddish Raw meat Appearance
- C/F – Severe abdominal pain, fever
- Rx –symptomatic Management NSAID

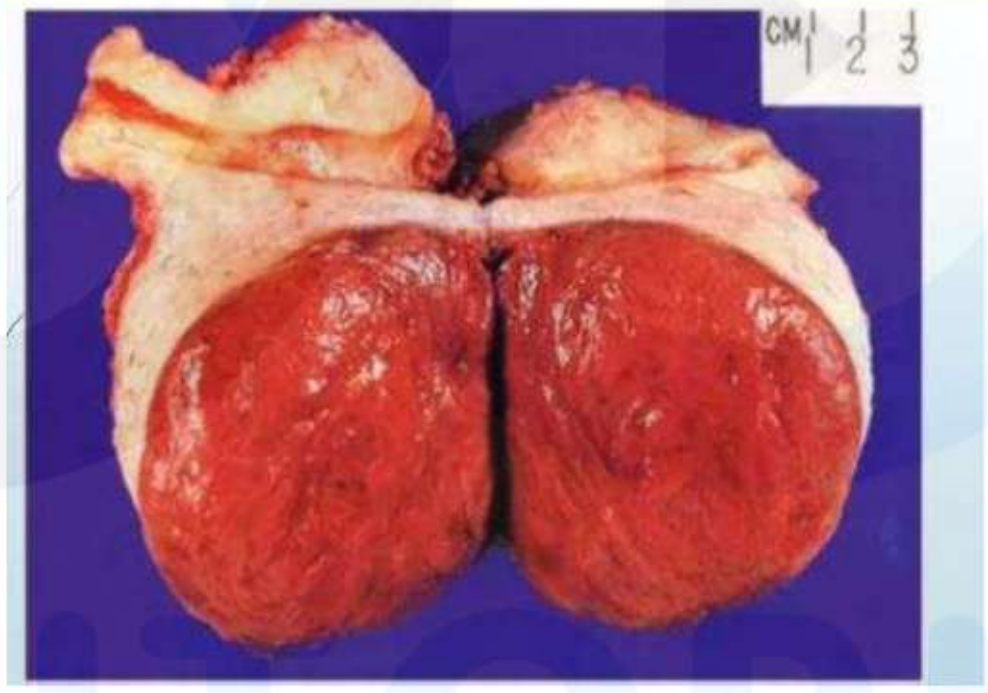

Red Degeneration of fibroid Fig 3

Other types of Leiomyoma

i. Symplastic Leiomyoma associated with Atypia

ii. Cellular Type
↓
Cellularity

iii. Metastasizing Type

Both do not show Increased Mitotic activity

- Invades veins and can occur at other location
- No Atypia, Typically Benign

iv. Disseminated Peritoneal Leiomyoma benign

- Differential Diagnosis of GIS

IHC Markers

- Any smooth muscle tumor is positive for
  i. Smooth muscle Action (SMA)
  ii. Clemson

Sarcoma – Positive for Vimentin

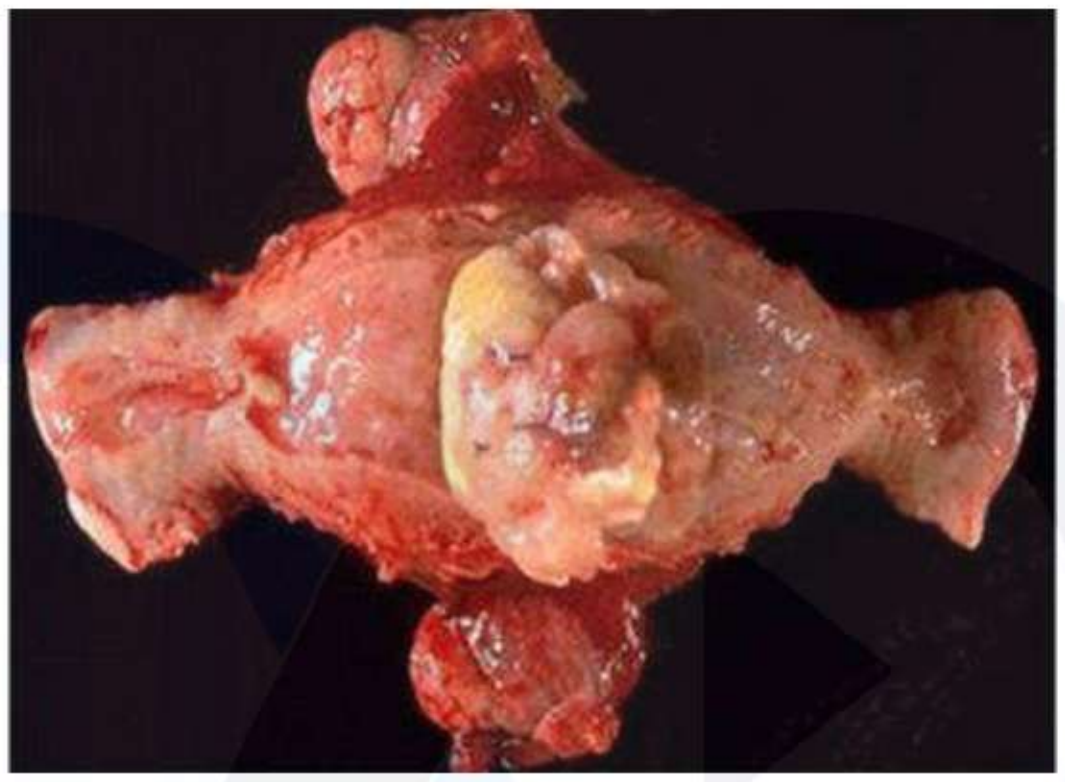
Fig 4

AfraTafreeh.com

- Gross = Leiomvosarcoma → smooth muscle sarcoma
- Histology
  - Cellularity –spindle stopped cells
  - Nuclear >Atypia
  - Increased Mitotic activity > 10/10HPF

TUTORIALS LOGIN FOR SUCCESS

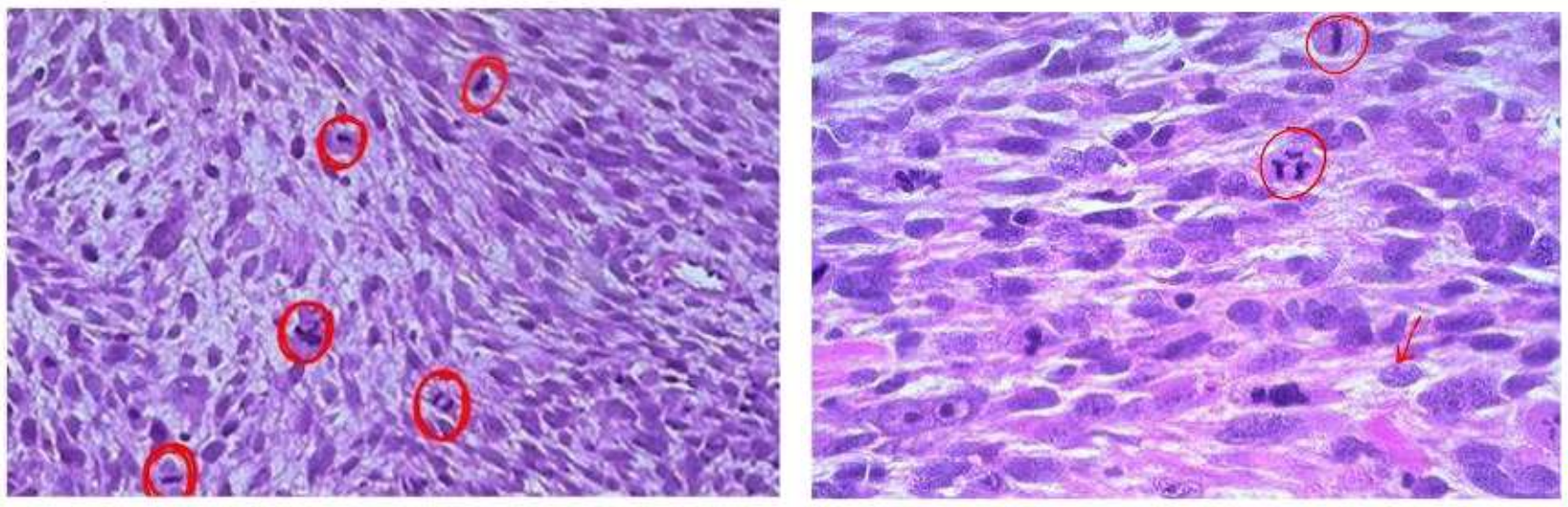
Fig 5

- Necrosis

  ↓

- Metopic actability

AfraTafreeh.com

Epithelioid lei sarcoma

- Histology
  - Epithelioid cells
  - MA >5/10HPE
  - Necrosis, Nuclear Atypia

Stump

- Smooth muscle Tumors of Undetermined Malignant potential
- Histology
  - cellularity
  - MA 4/10 HPE
  - Nuclear Atypia
  - Necrosis

Spectrum

- Leiomyoma → STUMP → Leiomyosarcoma.

TUTORIALS
LOGIN FOR SUCCESS

WHO CLASSIFICATION OF OVARIAN MALIGNANCIES

WHO Classification of Ovarian Malignancies 00:00:10

- Surface ovarian tumours
  - Serous
  - Mucinous
  - Endometroid
  - Brenner
  - Clear all
- Germ cell tumours
  - Dysgerminoma
  - Choriocarcinoma
  - Embryonal carcinoma
  - Teratoma
  - Yolk sac tumours
- Sex cord tumour (dicer mutation)
  - Sertoli cell tumours
  - Lending cell tumours
  - Granuloma cell tumors
  - Theca cell tumours
- Metastasis
  ↓
  krukenberg tumours metastasis to B/L ovarian from gastric ca appendicular ca

AfraTafreeh.com

Surface Ovarian Tumours:

i. Serous ovarian ca- resemble epithelium of fallopian tube

ii. Mucinous ovarian ca- mucinous epithelium like git/ endocervix

iii. Endometrioid - resemble the lining like bladder

iv. Brenner –Transitional epithelium like Bladder

Nuclear away from

v. Clear cell ca- has hobnail cells 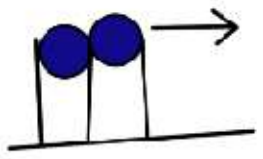

AfraTafreeh.com

Tumour markers: 00:10:48

i. CA– 125 → Marker of surface ovarian tumours

ii. PLAP → Dysgerminoma

iii. Hcg → Choriocarcinoma

iv. AFP →Yolk sac tumours

v. LDG → Marker of innerved tumours see in dysgerminoma

vi. Hormones Increase in Estrogen → Granuloma cell tumours present with endometrial Hyperplasia

TUTORIALS
LOGIN FOR SUCCESS

CLASSIFICATION OF OVARIAN CANCERS IN DETAIL

I. Surface Epithelial Tumours 00:00:31

A. **Serous Epithelial Tumours** – M/C Ovarian Tumour (45 – 47%)

- Resembles epithelium of fallopian tube
- M/C surface epithelial tumour of ovary
- Usually, bilateral
- Uniloculate filled with serous fluid
- 3 spectrums

Benign	Borderline	Malignant
– No proliferation – No invasion into stroma	– Proliferation – No invasion into stroma	– Invasion into stroma – More common

- Serous ovarian tumours also BRCA 1, 2 mutations

Low grade serous tumour	Higher grade serous tumour
– BRAF mutation – KRAS	– P53 mutation – BRCA mutation 1,2

AiraTafreeh.com

AfraTafreeh.com

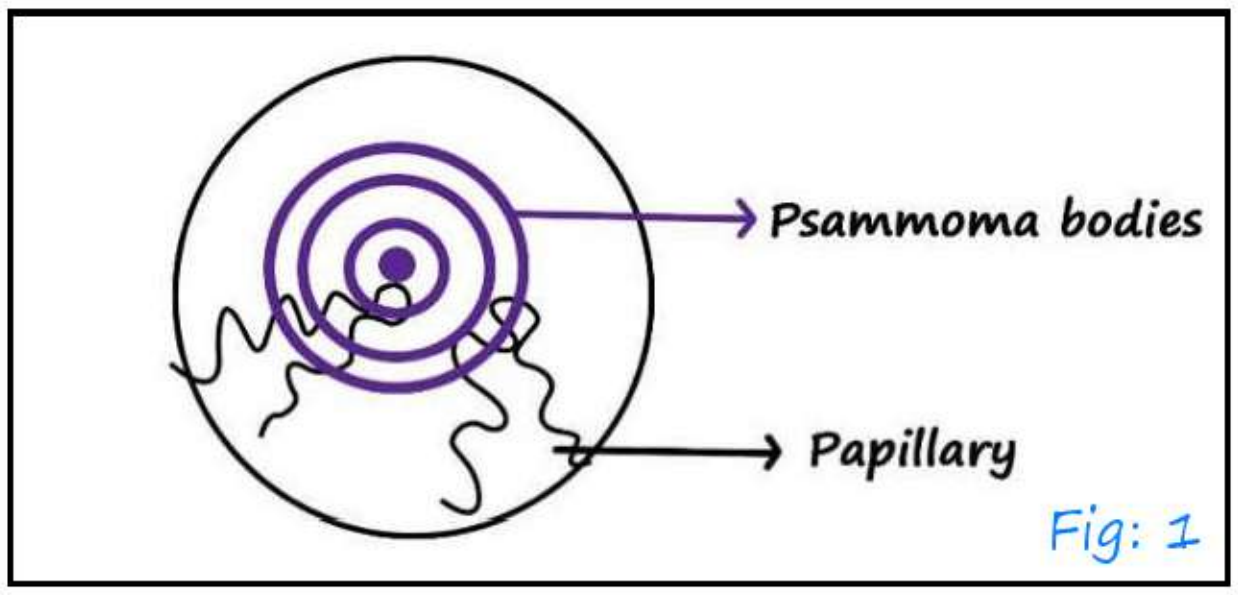

Fig: 1

Gross

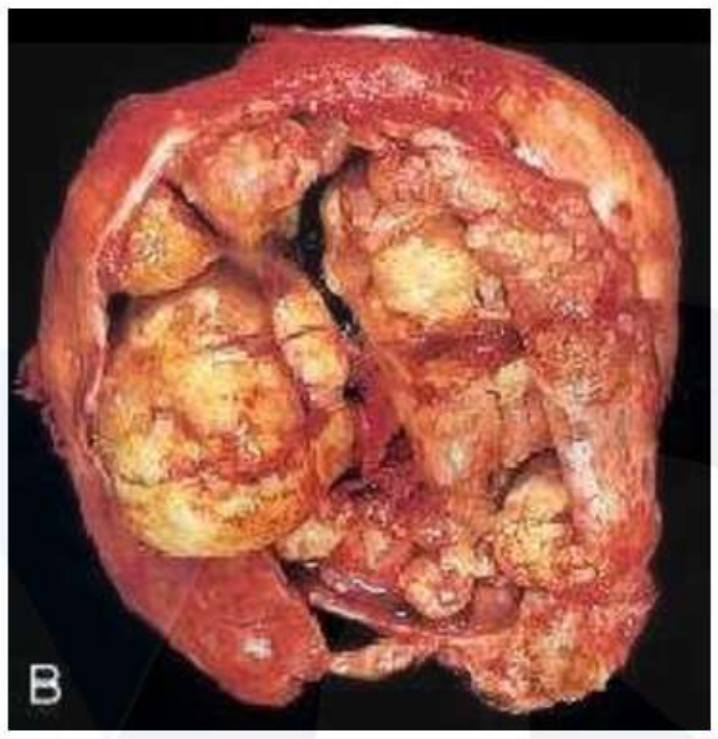
Fig: 2

Microscopy

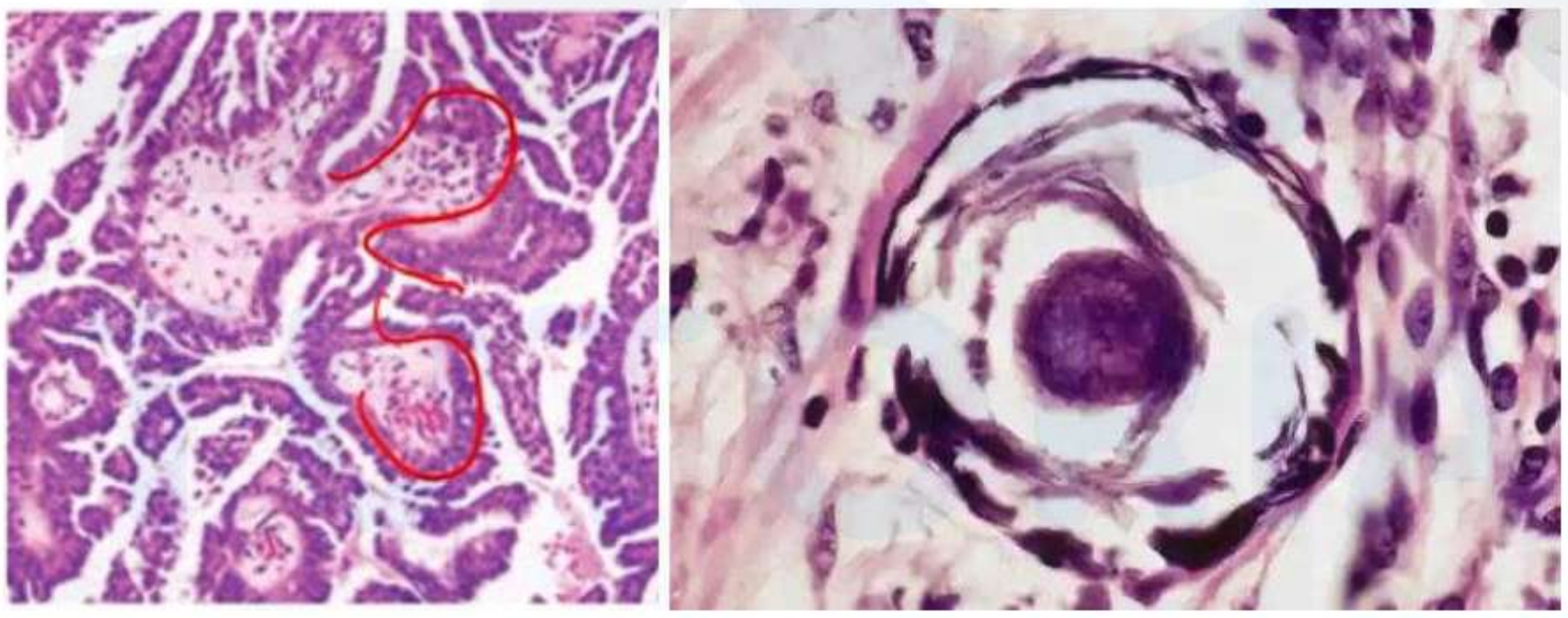
Fig: 3

B. Mucinous Ovarian Tumour

- Multiloculated filled with mucin

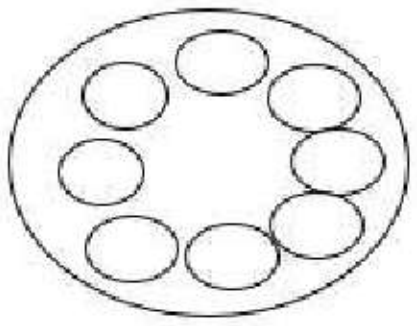

Gross – appearance like cob – web 00:06:49

- Usually unilateral
- KRAS mutation consistently present
- Microscopically resemble — gastric epithelium OR Intestinal epithelium
- Can spill into peritoneum resulting in Pseudomyxoma peritonei
- Patients with mucinous ovarian tumour can have hypercoagulable state

Fig: 4

- Spectrum → Benign, Borderline, Malignant

C. Endometroid Ovarian Tumour

- Usually have coexistent endometriosis

Mutations

- PTEN mutations [PI3K pathway mutation]
- DNA repair defects
- B catenin mutation

AfraTafreeh.com

D. Brenners Ovarian Tumour

- Remembers bladder epithelium
- On microscopy
  - i. Islands of transitional epithelium separated by fibrotic stroma
  - ii. There transitional cells can occasionally show grooves, coffee bean like nucleus (But not clerical of Brenner)
- Solid tumour of ovary

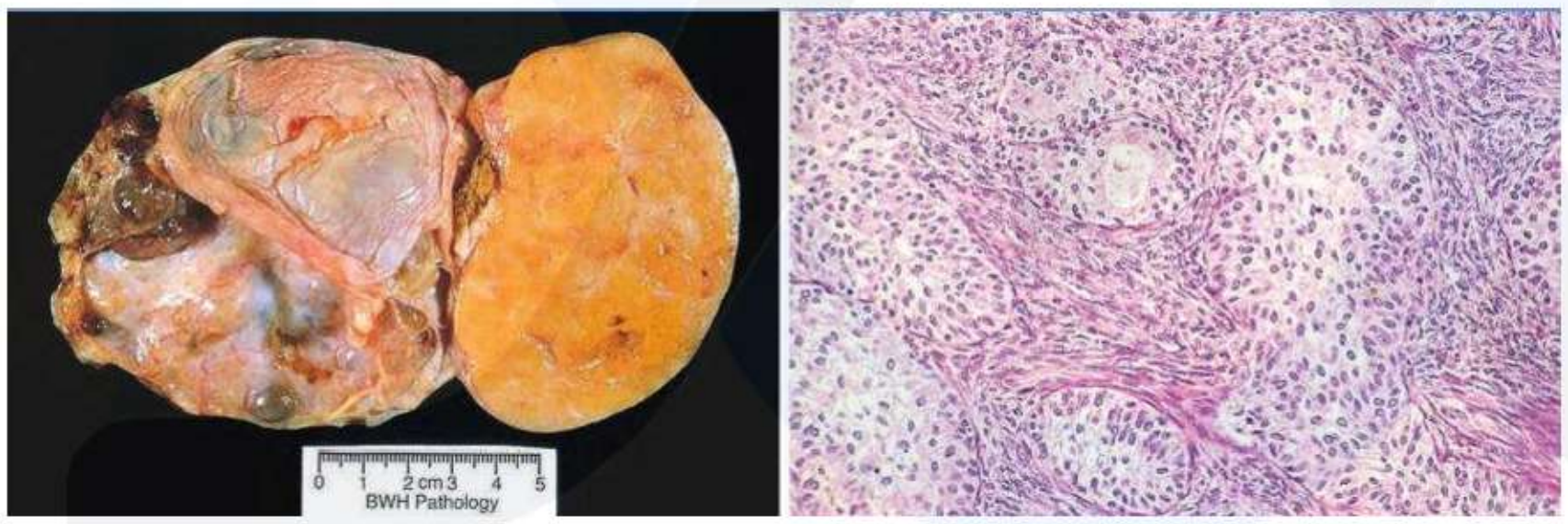

Fig: 5

E. CLEAR CELL CARCINOMA OVARY

- Typical cells with nucleus bulging away from basement membrane called Hobnail cells
  - Mutations- P13 K, ARID1A

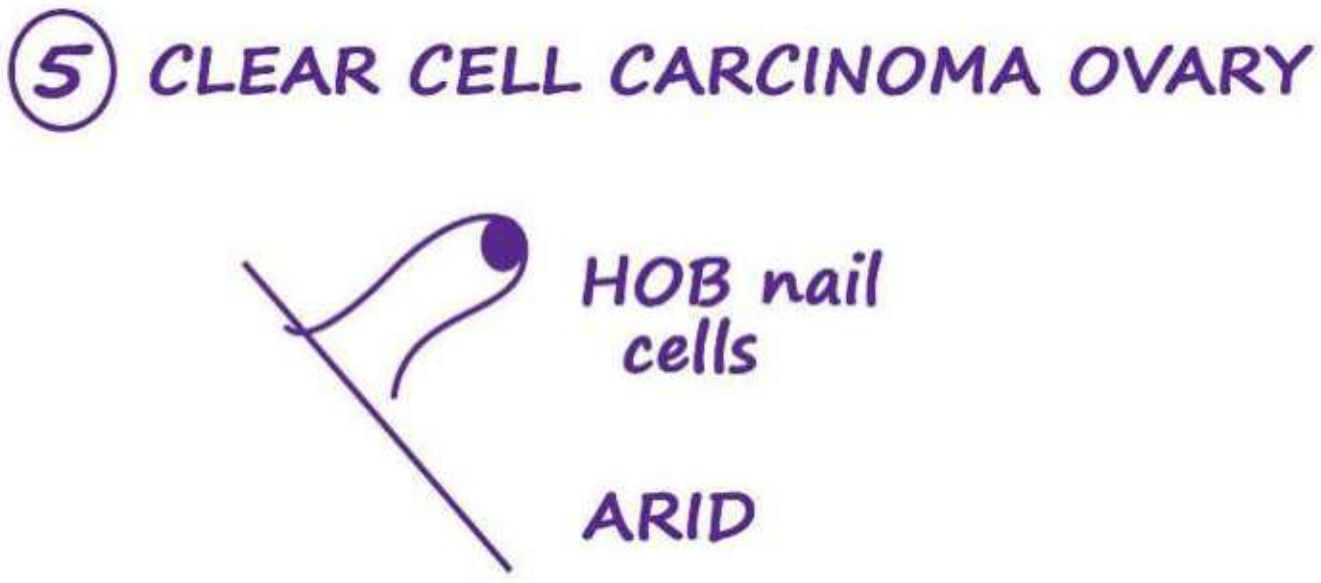

- 5 years survival rate - 90%

Germ Cell Tumour

i. Dysgerminoma

- Resembles seminoma in males
- Mutations – Oct 3/4 nanog
- Tumour Markers – PLAP, LD4

ii. Choriocarcinoma ovary

- Non-gestational origin
- large ares of necrosis and haemorrhage with syncitiotrophoblast and cytotrophoblast
- Worst prognosis
- Tumour Markers – hCG

iii. Embryonal carcinoma

- CD 30 positivity

AfraTafreeh.com

iv. Teratoma

<u>Mature Teratoma</u>	<u>Immature Teratoma</u>	<u>Monodermal</u>
↓ • Mature components • Mature cystic Teratoma are called dermoid cyst 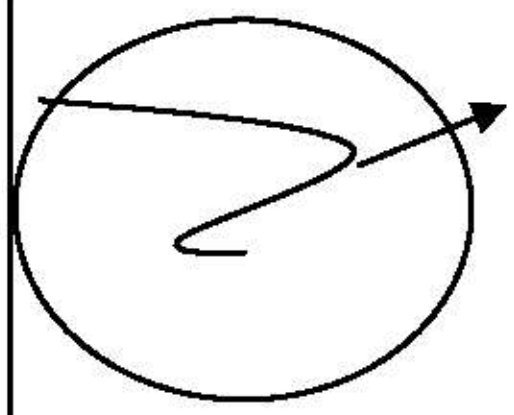 Rokintansky protuberance – Site of origin of secondary malignancies like SCC – Always to be examined while doing biopsy		

AfraTafreeh.com

Immature Teratoma

- Comprises of immature components like immature neuroepithelium or immature cartilage
- 3 grades depending on immature components seen
- Grade I: immature epithelium seen in < 1 field
- Grade II: > 1 but < 3 fields
- Grade III: > 3 fields show immature epithelium

Monodermal:

2 Monodermal component

- Struma thyroid
- Struma carcinoid

v. Yolk Sac Tumour

- Shows Schiller duval bodies
- Hyaline globules
- Tumour marker – AFP
- Yolk sac tumours in males have excellent prognosis whereas yolk sac tumours in females have poor prognosis

SEX CORD TUMORS

- Sertoli- Leydig Cell tumour
- Thecoma
- Fibrom
- Granulosa cell Tumour

Granuloma cell tumour

Juvenile	Adult
	- More common
	- Post menopausal
Presentation	female
	- Estrogen secreting tumour producing endometrial hyperplasia

- Metrophathia hemorrhagica
- Metastasis 1st to opposite ovary
- FOX L_2 mutation
- Microscopy - cells with coffee bean nuclear arranged in follicles – can be seen on PAP smear

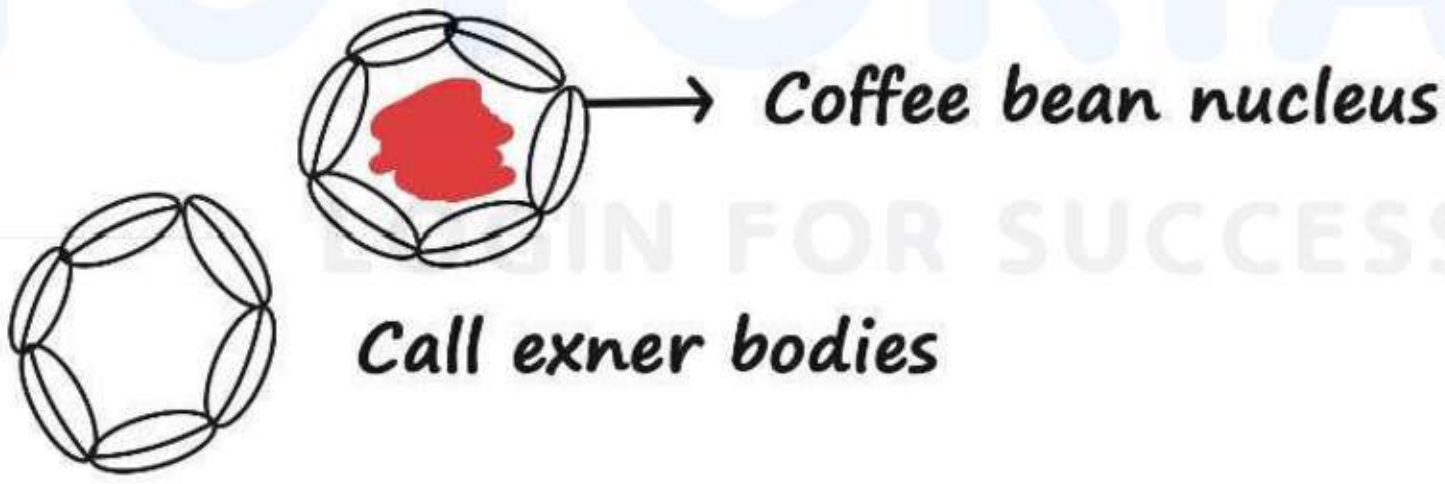

Fig: 6

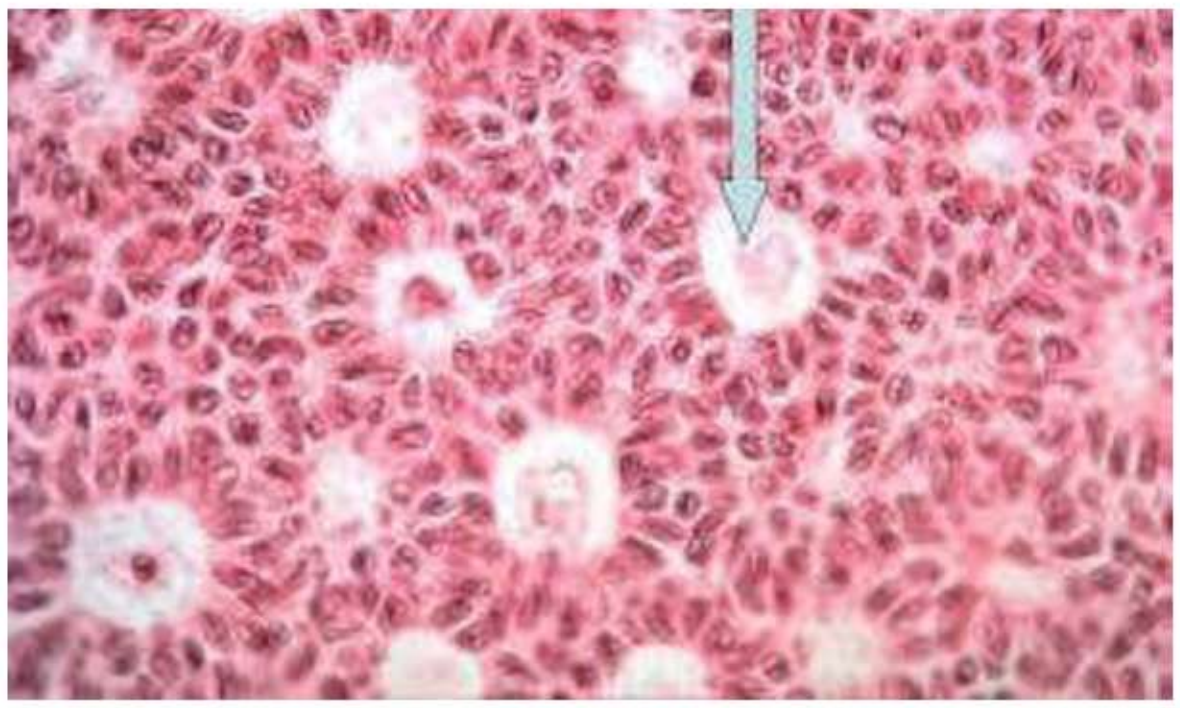

Fig: 7

AfraTafreeh.com

- Typical IHC – Inhibin

THECA CELL TUMOR	FIBROMA
 ↓ Fatty Cytoplasimic vacuoles ↓ Positively stained by oil – red O	 ↓ - Spindle snapped cells - Part of Meigs syndrome Theca – Fibroma • Ascites • Right sided pleural effusion

Sertoli – leading tumour

- Show DICER mutation
- H/O Peutz-Jegher's syndrome
- On microscopy –

Fig: 8

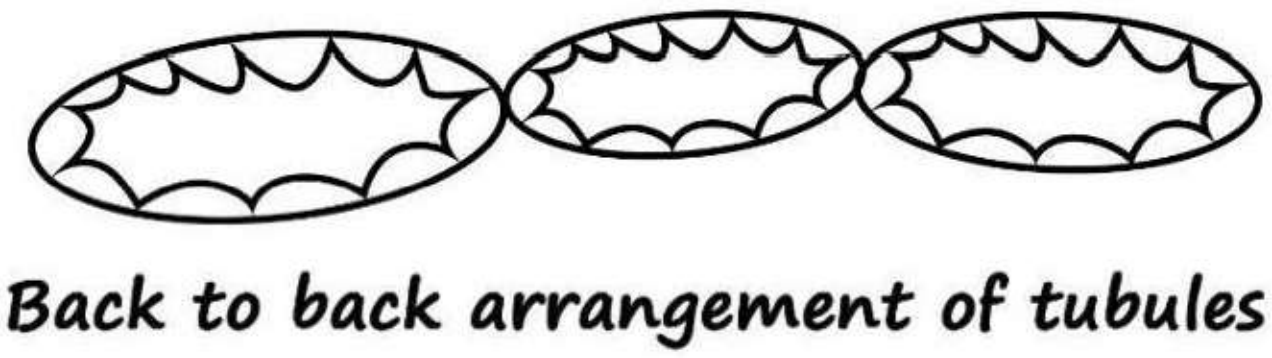

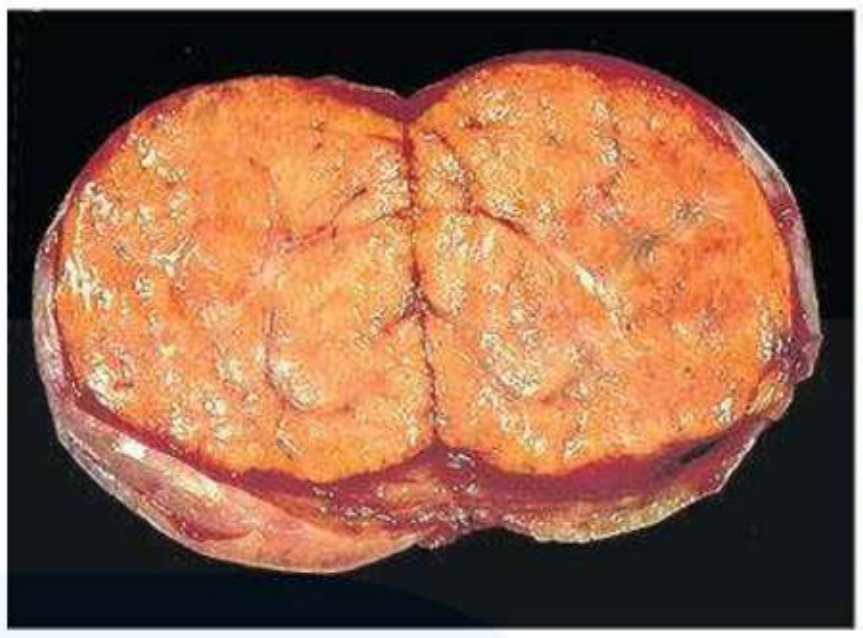

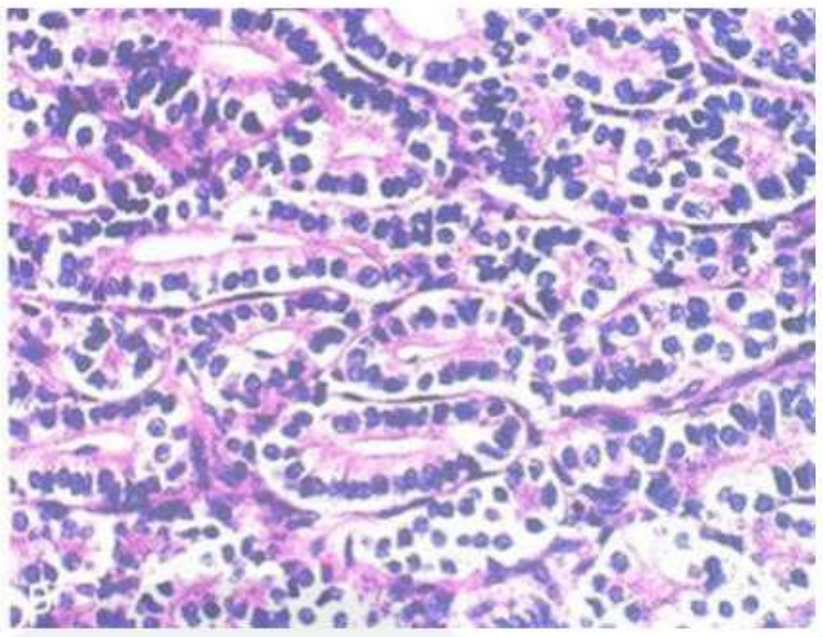

AfraTafreeh.com
TUTORIALS
LOGIN FOR SUCCESS

Leydig Cell Tumour

- Also known as Hilus tumour in ovary
- On microscopy - Shows Reinke crystals

Gonadoblastoma

- Combination of germ cells and sex cord stromal
- Occurs in patients with ambiguous genitalia
- TSPY mutation

Metastasis to ovary

Krukenberg tumour

- Metastasis to bilateral ovaries from gastric cancer / lobular carcinoma of breast
- Both ovaries are enlarged
- Microscopy shows signet ring cells

AfraTafreeh.com

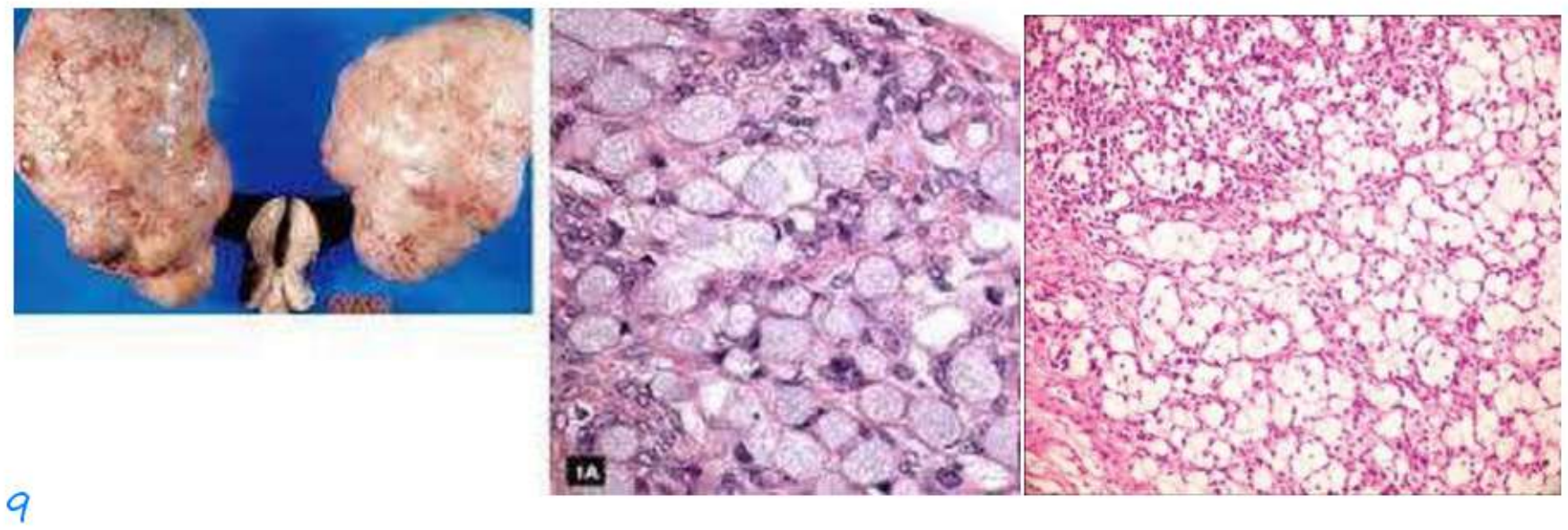

Fig: 9

Summary of Mutations in Ovarian Carcinoma

- Serious – Low grade – KRAS High grade – P 53
- Mucinous – KRAS (consistent)
- Endometrioid – PTEN / PI3K, mismatch DNA repair genes and CTNNB1 (B – Catenin)
- Granuloma cell tumours – FOX L2 gene

Update on pathological approach to diagnosis of ovarian tumour

PAX – 8 Positivity

↓

Marker of Ovarian Tumour

- Look for WT1 mutation
  - **Present**
    ↓
    Serous tumour
    ↓
    Look for P 53 mutation
    - ⊕ High grade serous tumour
    - ⊖ Low grade serous
  - Absent
    ↓
    EP/PR/Vimentin positivity
    - ⊕ ↓ Endometroid ca
    - ⊖ ↓ Mucinous ca
- HNF 1 alpha⊕
  Napsin ⊕
  Clear cell ca [ARID 1A Mutation
  Look for Hobnailing

PAP SMEAR

Site of pap smear & fixation 00:00:12

- Specimen should be taken form (Site) – Squamocolumnar June
- Ayre's spatula is used to take both ecto & endo cervix cells
- Fixation: 95% ethanal
- Stain: Papanicolon

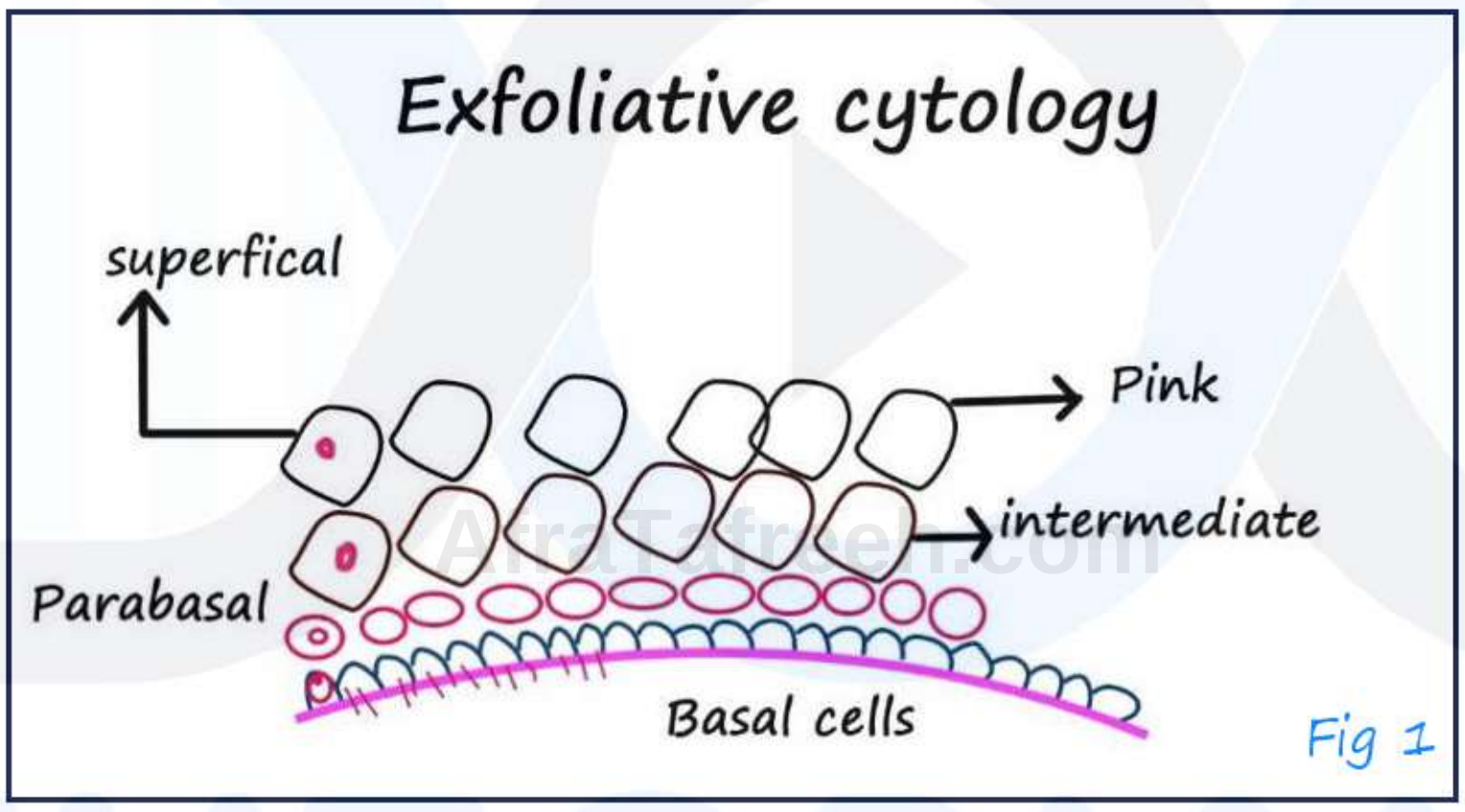

Fig 1

Exfoliated EP. Cells 00:03:40

- In ecto cervix there are 4layers of cells basal cells
- As you from basal cells nucleus becomes pyknotic
- Superficial cells
- Intermediate cells

(Superficial cells, Intermediate cells – Polygonal parabasal – round)

- Pap smear is exfoliative cytology → Collect shed cells
- Superficial cells – Pink in color on pap stain max responsive to estrogen
- Intermediate cells – Bule, max response to progesterone

AfraTafreeh.com

- Para based cells – Deep blue – No response to any hormone
- Basal cells – do not exfoliate into pap smear
- If female is in: Estrogenic phase: More squamous shaped pink cells with pyknotic nuclei
  Progesterone phase (Pregnancy) – Blue green cells polygonal shape

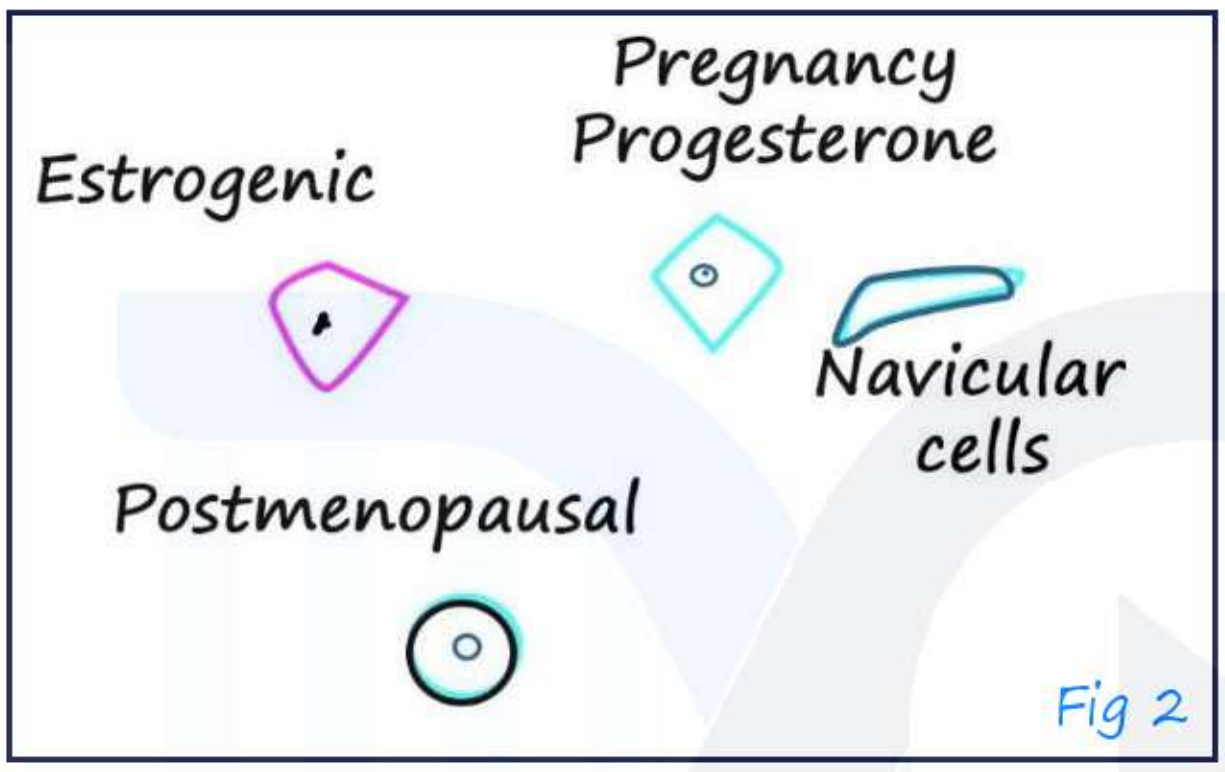

Fig 2

Post-menopausal

- Pasa basal cells

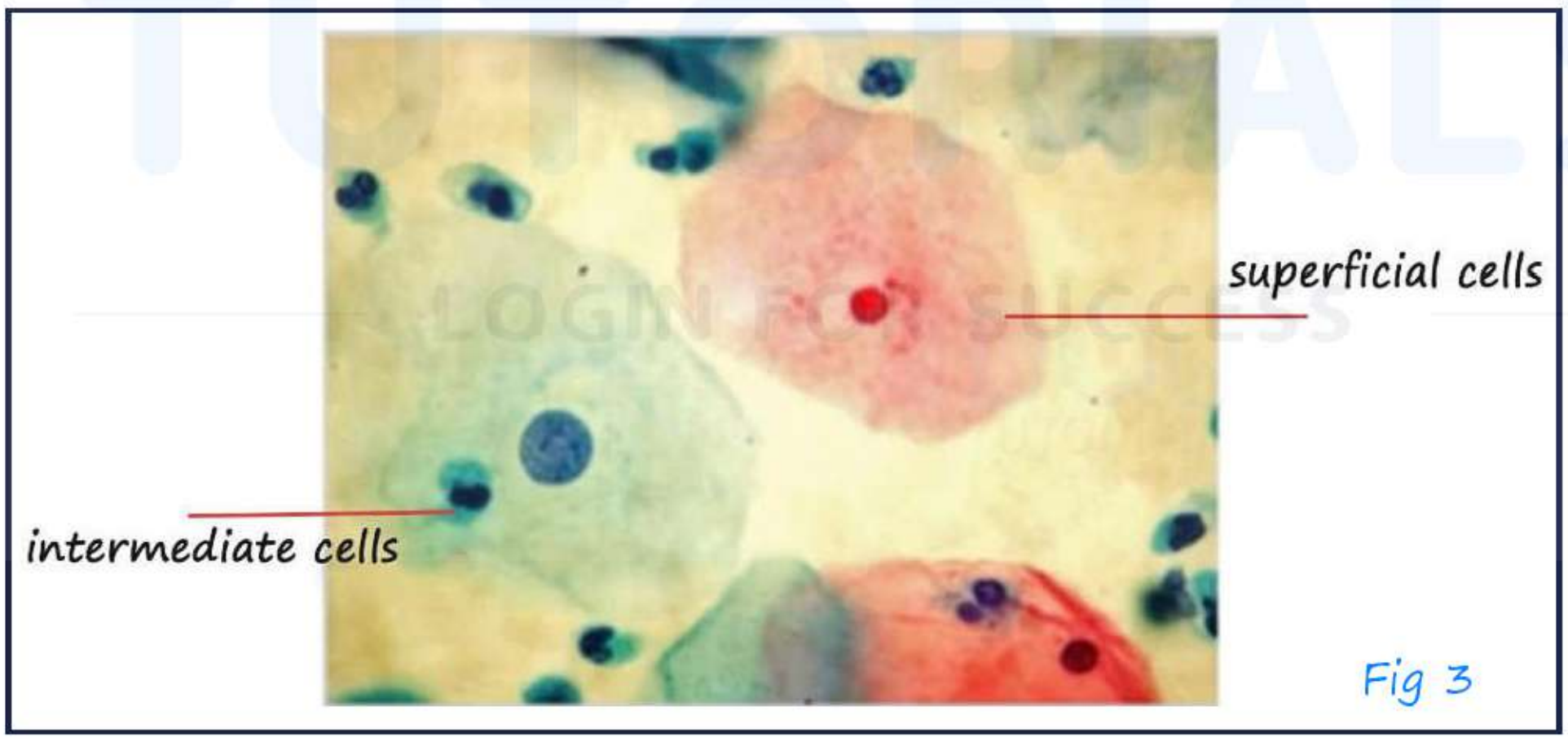

Fig 3

Columnar cells

- Nucleus towards base
- Exfoliate together present in cluster – Picket fence arrangement

- At least 10 endocervical cells should be seen

Fig 4

Pap smear adequacy

Squamous	Endo
Low	10 or
LBC	metaplastic cells

Background of pap smear 00:12:51

- Lactobacilli causing cytolysis helps in maintaining PH = 5

AfraTafreen.com

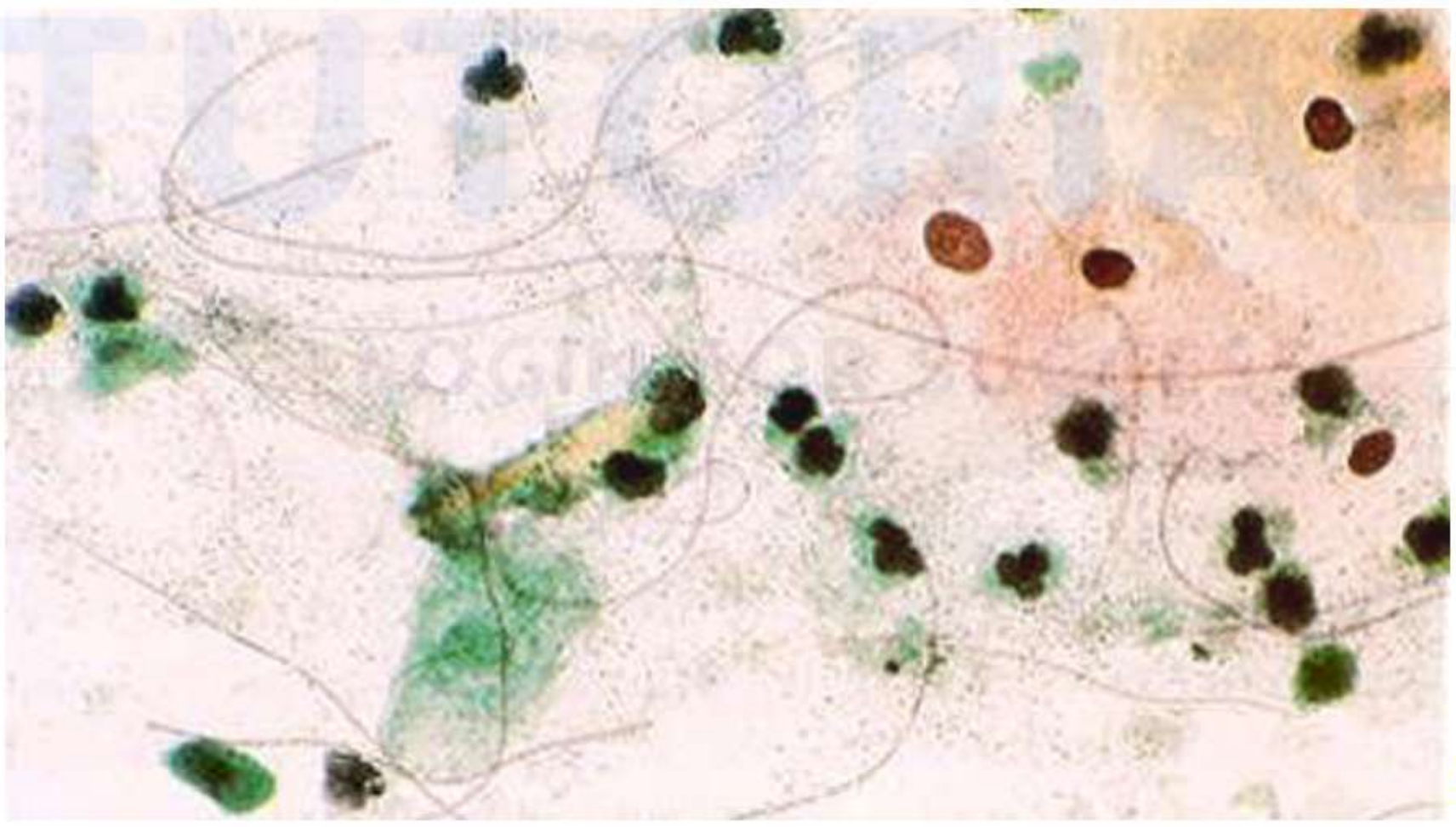
Fig 5

Pathological condos

- Long thread like structure – Leptothix, Indicative of trichomonas infection

AfraTafreeh.com

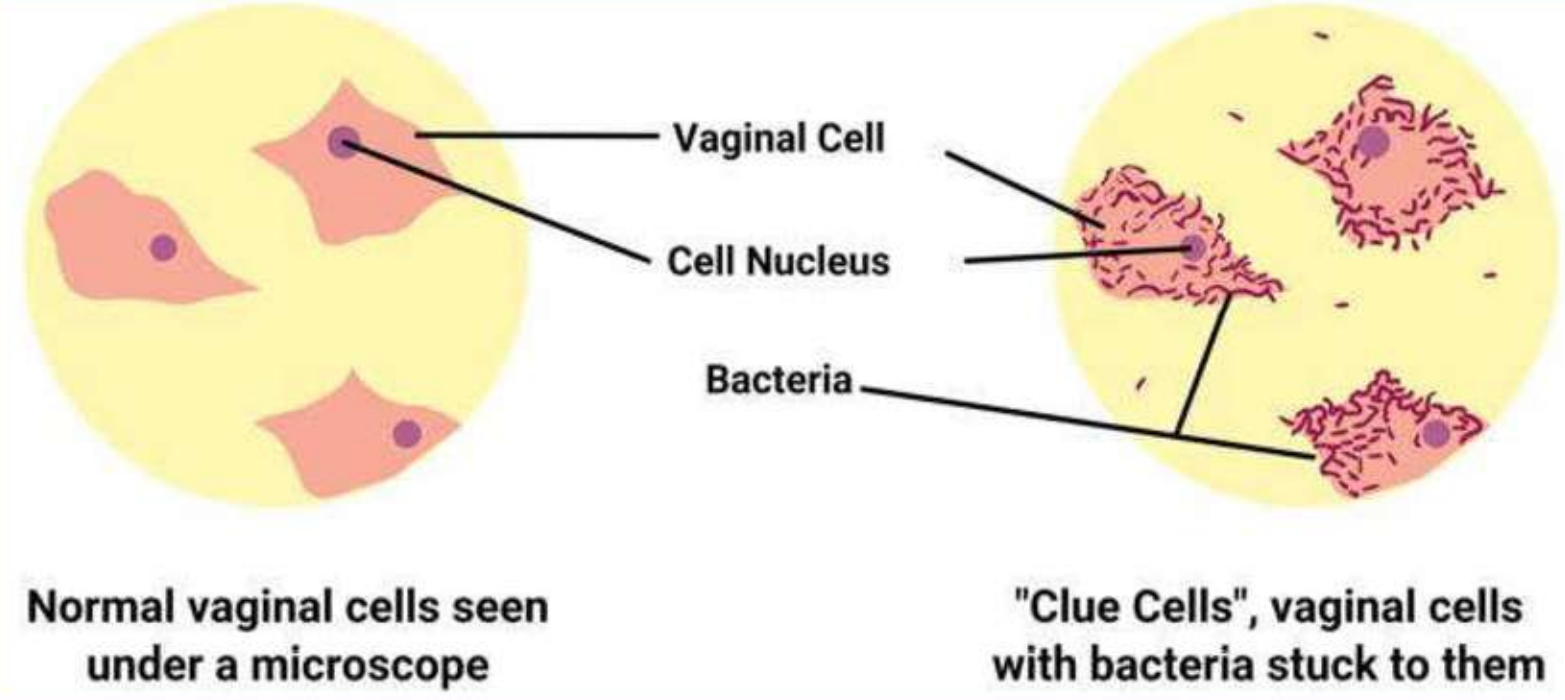

Fig 6

- Bacterial sticking to squamous cells: Due cells → Bacterial vaginosis

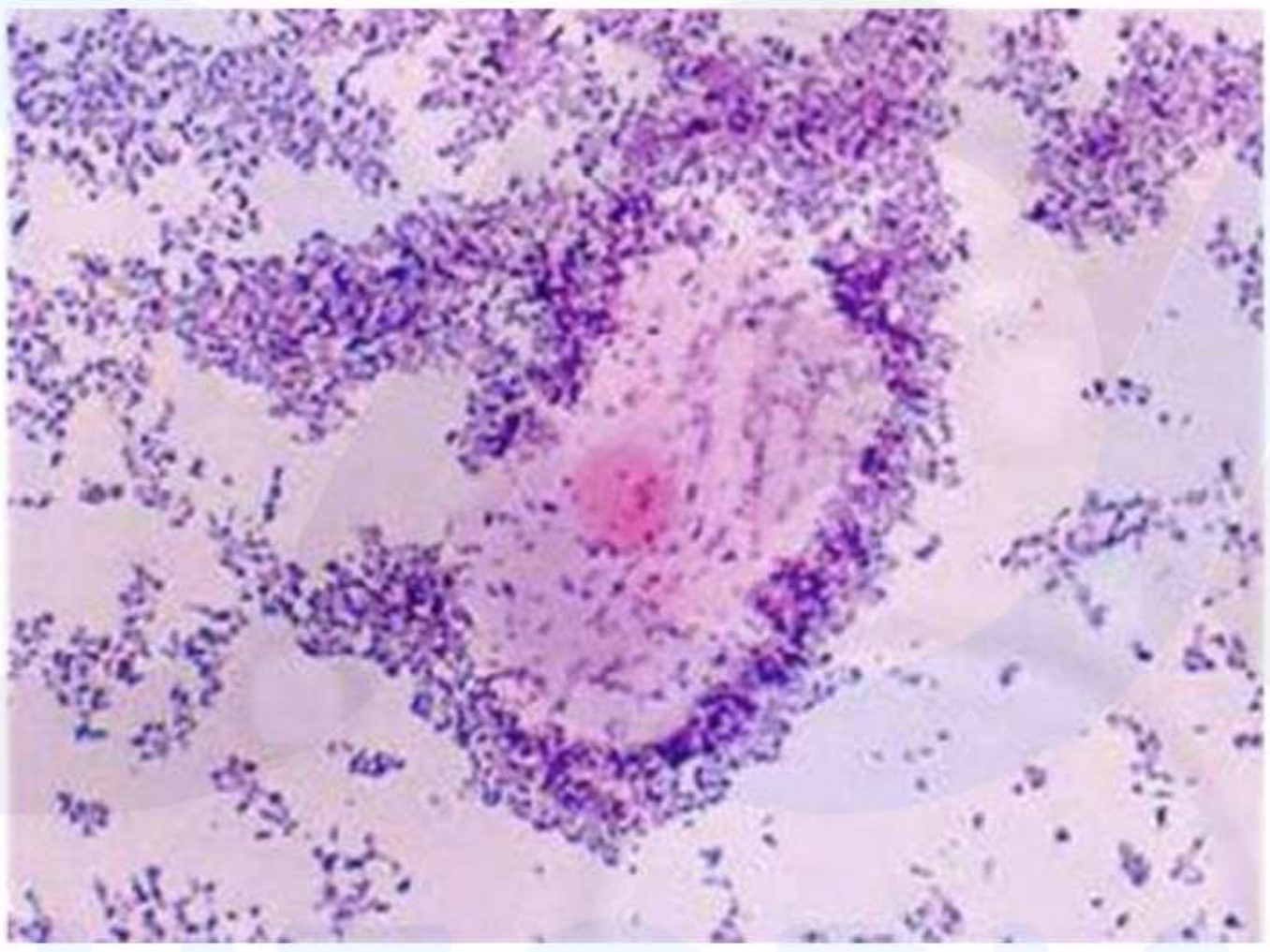
Fig 7

Organisms in pap smear 00:16:30

Fig 8

- Trichomonas → Strawberry cervix

- Giardia



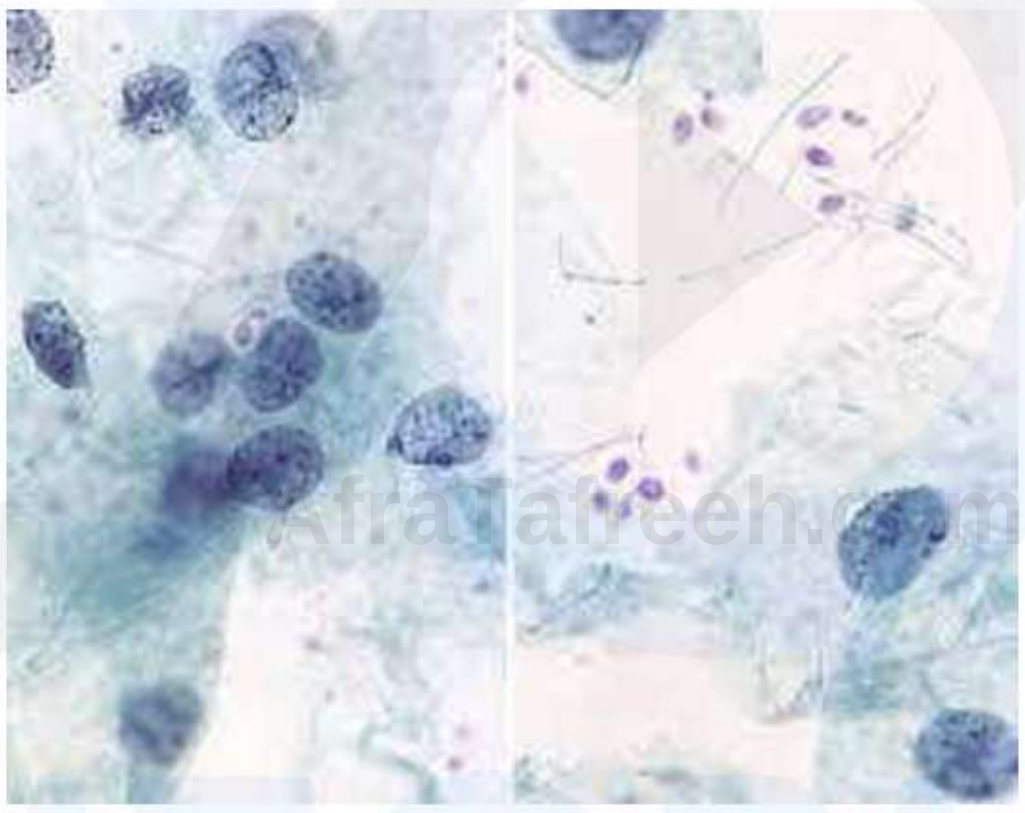

Fig 8

TUTORIALS
LOGIN FOR SUCCESS

- Candida → White frothy discharge pseudo hyphae
- Candidiasis is common in pregnancy due is charge in PH

Liquid based cytology (LBC) 00:19:24

Fig 9

AfraTafreeh.com

- Has a brush instead of spatula

Fig 10

LBC

Sure path
↓
- Read of brush broken & patin container
- Thinner area to screen
- Better cellularity
- Monolayer

Thin prep
↓
Gradient method
- Lead is not broken
- Method fixator
- Vacuum processor used

Candida of LBC

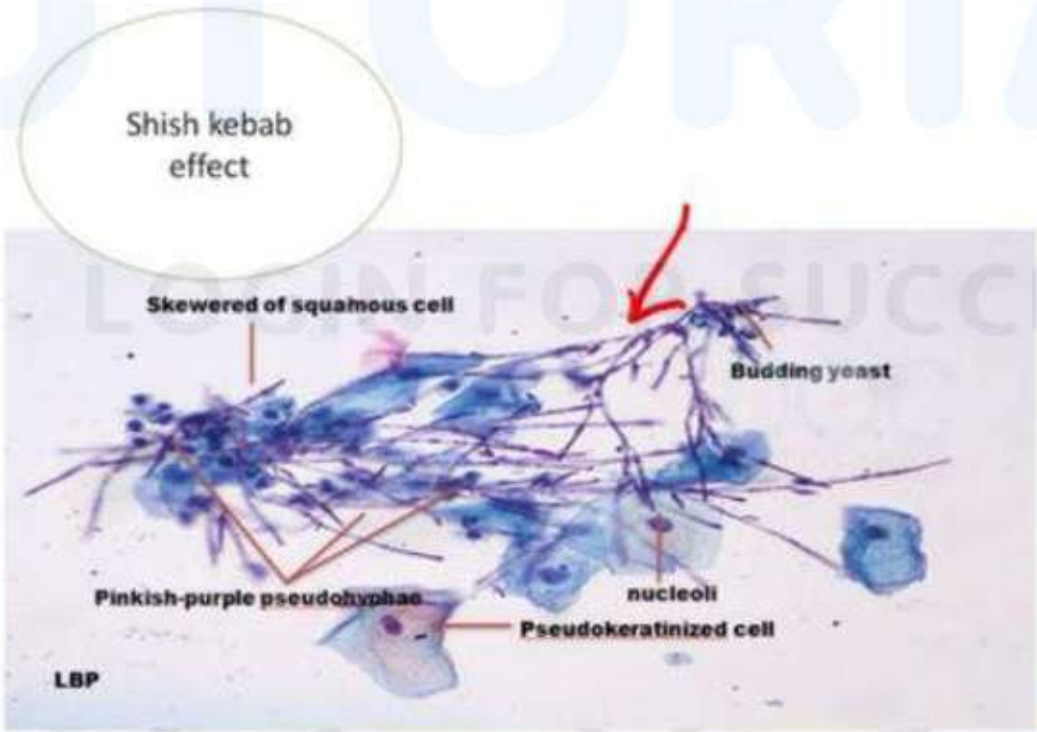

Fig 11

- Shish kebab effect
- Actinomyces → Complication of IUCD

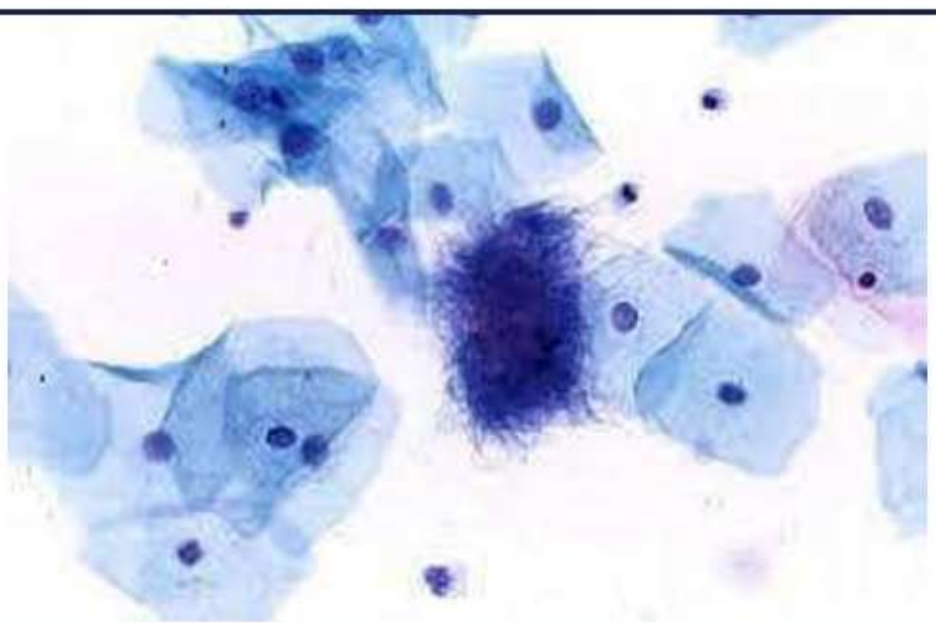

Fig 12

- Cotton ball cluster appearance of actinomyces infection

Pap smear in HSV, HPV & SCC 00:27:44

- HSV
  - Multinucleation
  - Molding
  - Margination of normal chromatin
- Nuclear inclusions – Cowdry inclusion

AfraTafreeh.com

- HPV
  - Koilocytic charge in squamous cells
  - If nuclear abnormalities also present = LSIL

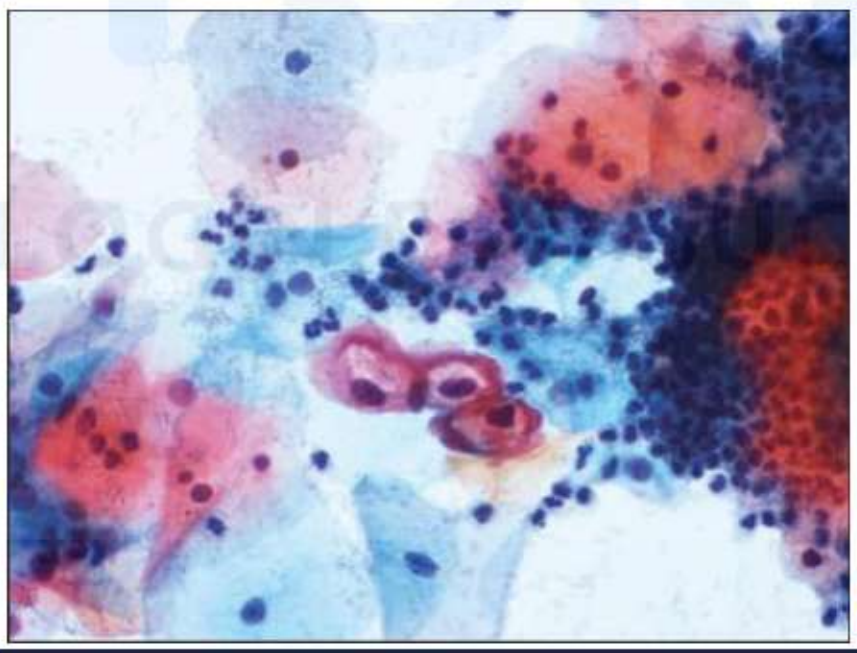

Fig 13

- SCC
  - tadpole shaped orange squamous cell
  - Large nucleus

AfraTafreeh.com

Fig 14

Karyopyknotic index 00:34:29

- KPI = $\frac{\text{Mature sq. cells}}{\text{Intermediate + parabasal cells}}$ Peaks on equation day

- Maturation index
- Parabasal/int/sq

Update

Bethendsa classification

	SQ.	ECC
Conv.	8000/10HPF	10/M
LBC	5000/HPF	

If >75percent observed by inflammation

↓↓

INADEQUATE

GESTATIONAL TROPHOBLASTIC DISEASES

- Mole
  - Complete
  - incomplete
  - Invasive
- Choriocarcinoma
- PSTT
  Placental site Trophoblastic tumor

Complete Mole	Incomplete Mole or Partial Mole
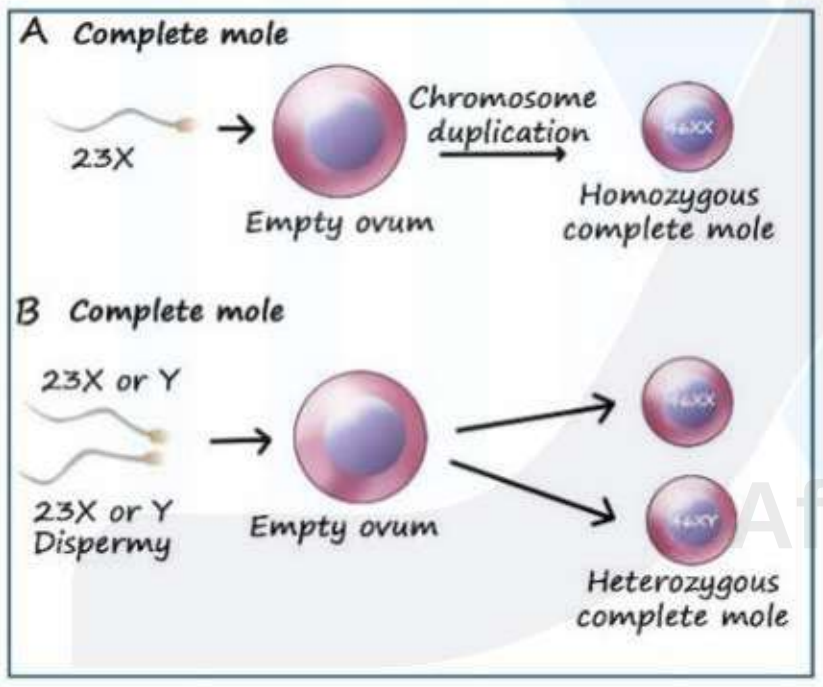 46XX <u>46XX</u> <u>Androgenic diploid</u> No fetal parts Grape like structures filling uterine cavity 	<u>69XXX</u> <u>69XXY</u> Fetal parts present 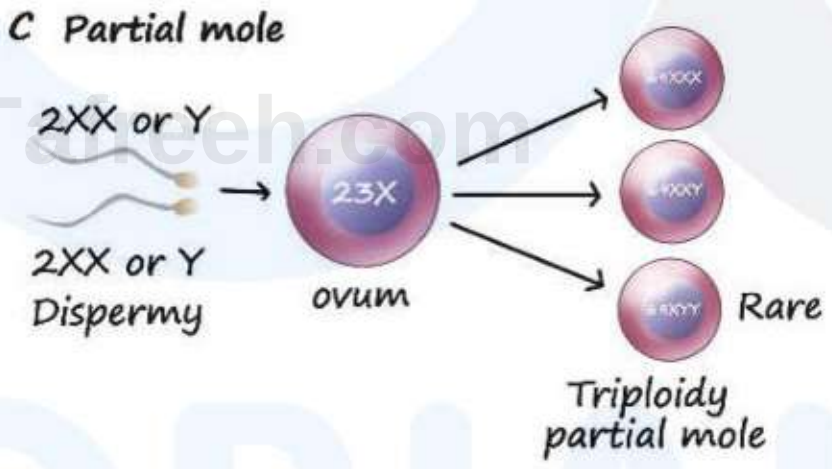

DOC TUTORIALS LOGIN FOR SUCCESS

AfraTafreeh.com

Microscopy	Microscopy
Cystically enlarged villi with hydropic change Trophoblastic proliferation around villi 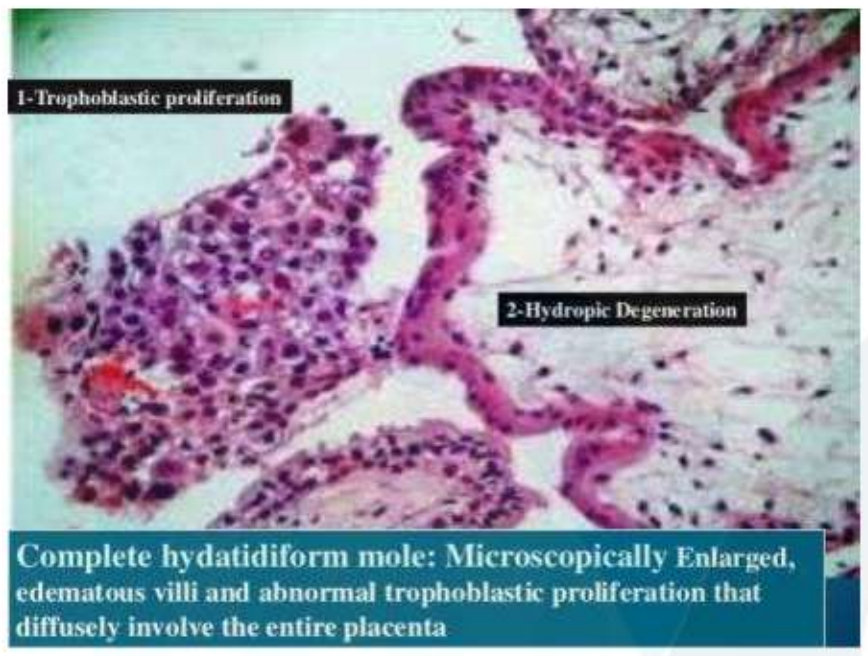 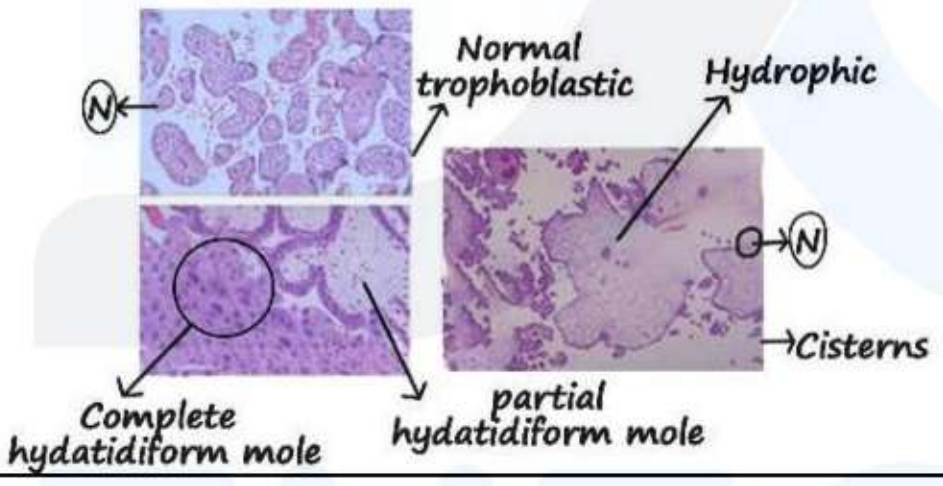	Hydropically enlarged villi with normal villi focal trophoblastic proliferation 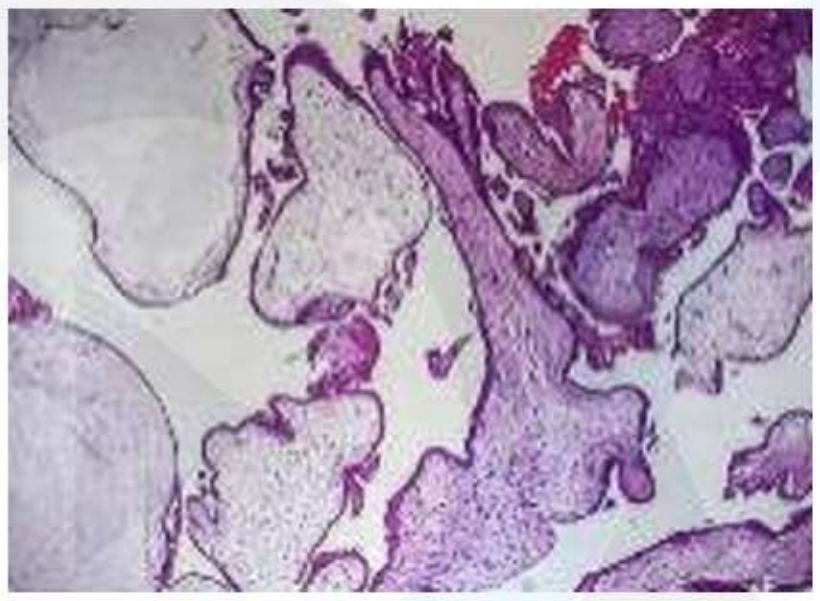

Immunohistochemistry

- Normally p57 gene is imprinted on internal chromosome only maternal gene is expressed

Complete mole

- Only paternal chromosomes

(-)

- Greater risk of Transforming Into choriocarcinoma

Partial mole

- p 57 is imprinted in paternal genes
- So p57 is silent

Invasive mole. 00:15:37

- Villi infiltrating into myometrium

Choriocarcinoma. 00:16:43

- Sites – Placental site > Ovary [Non gestational Choriocarcinoma]
- rapidly proliferating tumors
- As they overgrow their blood supply, they show large areas of necrosis and hemorrhage

Microscopy

1. Necrosis and Hemorrhage
2. Prolongation of **cytotrophoblast** & Syncytiotrophoblast infiltrating into myometrium
   - **cytotrophoblast**
   - Syncytiotrophoblast Multinucleated

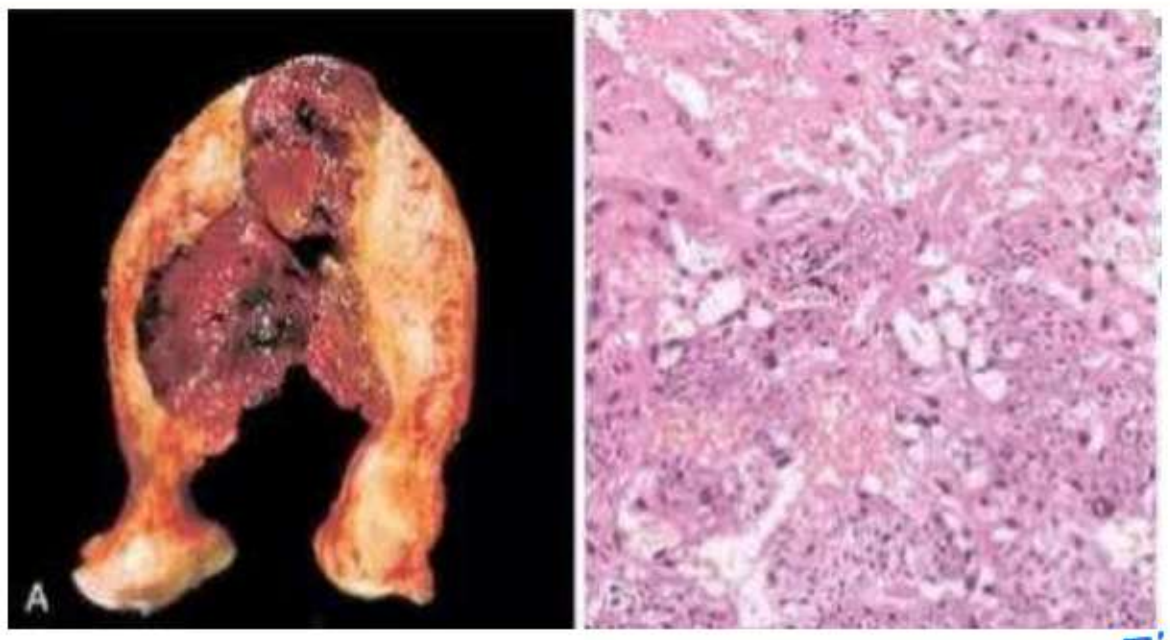

Fig: 1

1. Metastasis to lungs>Brain

AfraTafreeh.com

2.Tumor marker - Hcg

3.Poor prognosis

PSTI-placental Site Trophoblastic Tumor.

00:20:28

- Proliferation of intermediate trophoblast
- Hcg levels not increased
- Algorithmic Approach to Diagnosis of
- Hydatid form moles

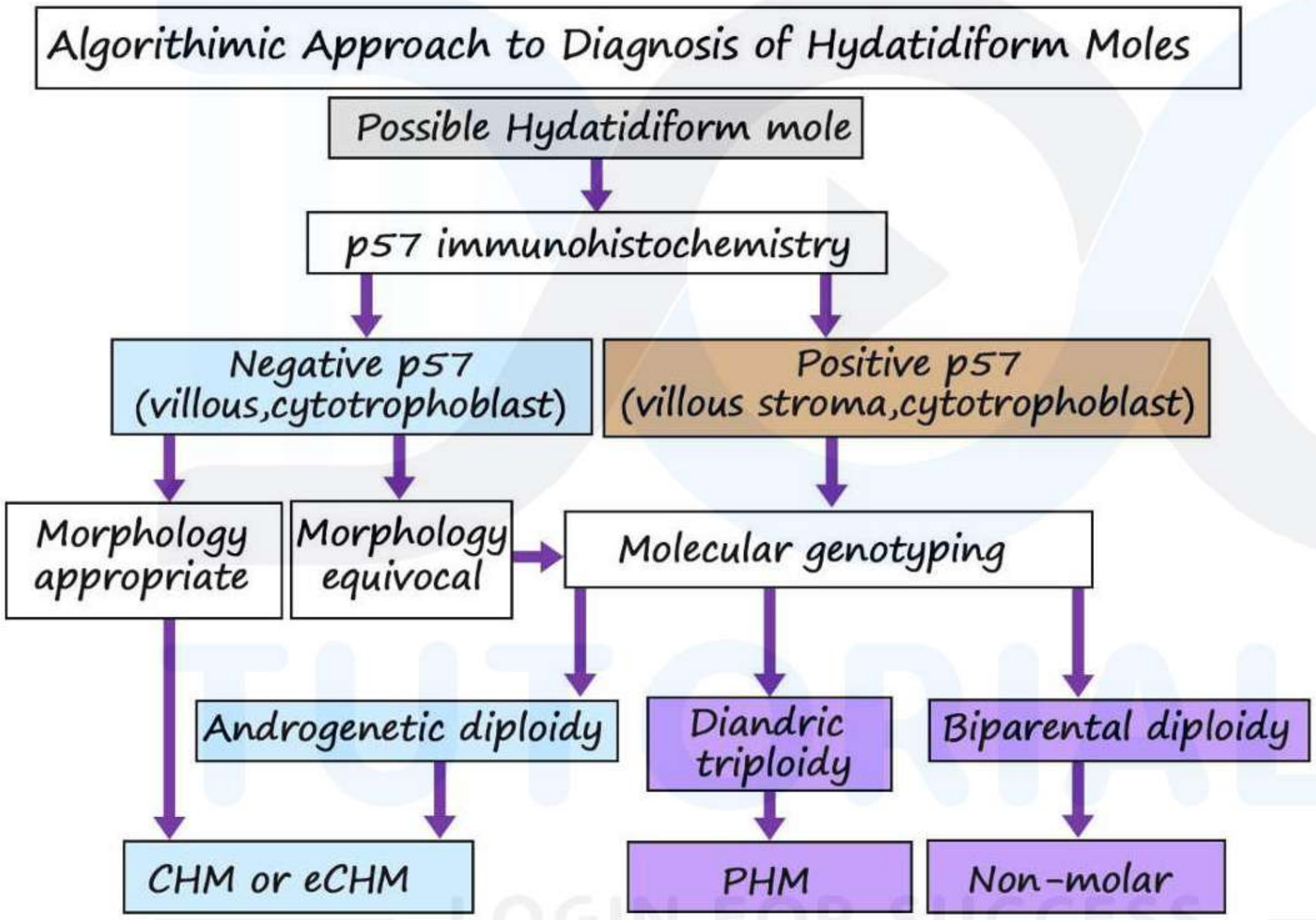

BASICS OF BREAST

Breast – A modified sweat gland 00:00:05

Structure

Large Ducts	Basal cells:
Have Elastic Tissue 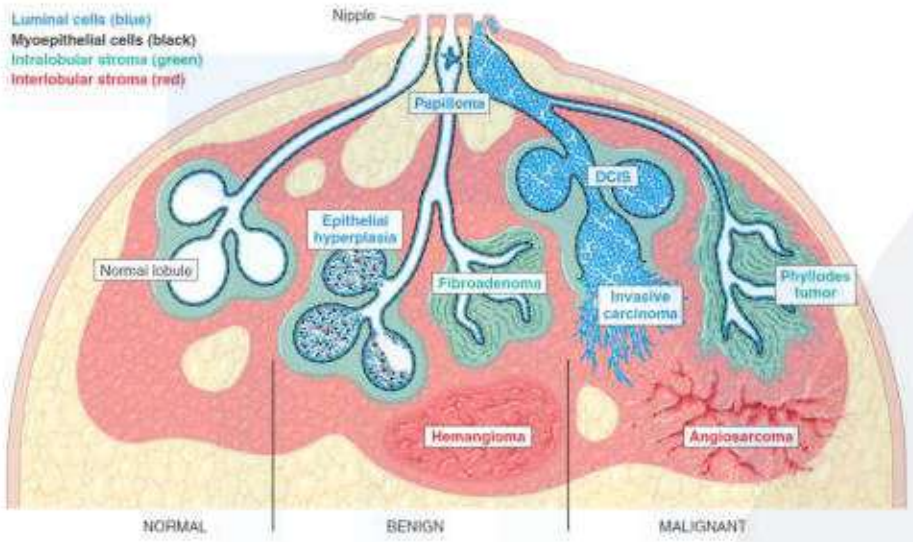 **Luminal Cells** • CK7 • EMA • Columnar/cuboidal Cells	i. Cells of origin of luminal and myoepithelial cells ii. Positive for ck5 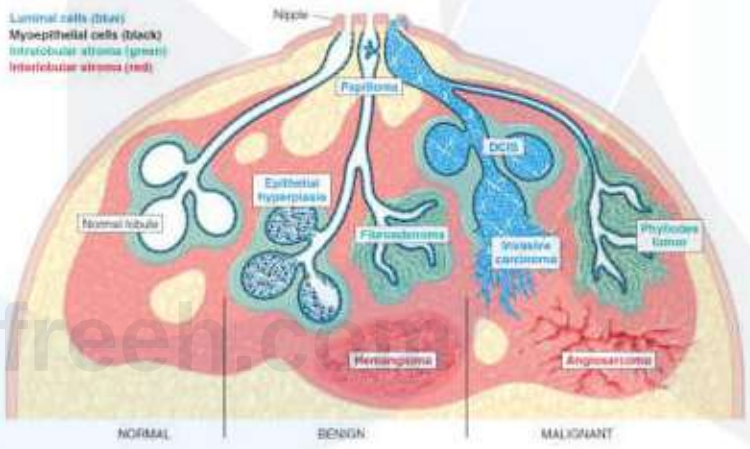 **Myoepithelial Cells** CK 5/6 SMA • Flattened small cells • Especially important to detect invasion

AfraTafreen.com
TUTORIALS
LOGIN FOR SUCCESS

- Basal Cells:

  i. Cells of origin of luminal & myoepithelial cells

  ii. Positive for CK5

AfraTafreeh.com

I. Epithelial Hyperplasia

example: during pregnancy

- There is proliferation of both luminal and myoepithelial cells.

II. Fibroadenoma: most common fibroepithelial tumor of breast

- Interlobular stroma proliferation
- It compresses the acini-appearing like slits

III. DCLS-Proliferation of ductal/luminal cells

- Myoepithelial cells intact

IV. Invasive carcinoma Myoepithelial cells breached

Malignant ductal cells infiltrate into stroma

V. Phyllodes Tumor:

- Proliferation of Intralobular trauma which either pushes interlobular stroma Benign phyllodes
- infiltrates interlobular stroma → Malignant phyllodes

VI. Paget's Disease:

- Retrograde progression of malignant ductal cells involving skin of nipple.
- Majority of Paget's disease of breast have underlying DCIS or invasive carcinoma in 100% cases whereas in extra mammary Paget's - underlying malignancy is present in only 12% cases.

DOC TUTORIALS LOGIN FOR SUCCESS

Structure of Nipple 00:17:57

- Stratified squamous epithelium
- Rich in sebaceous glands
- Basal cells of epithelium are rich in Melanin and few clear cells called TOKER cells

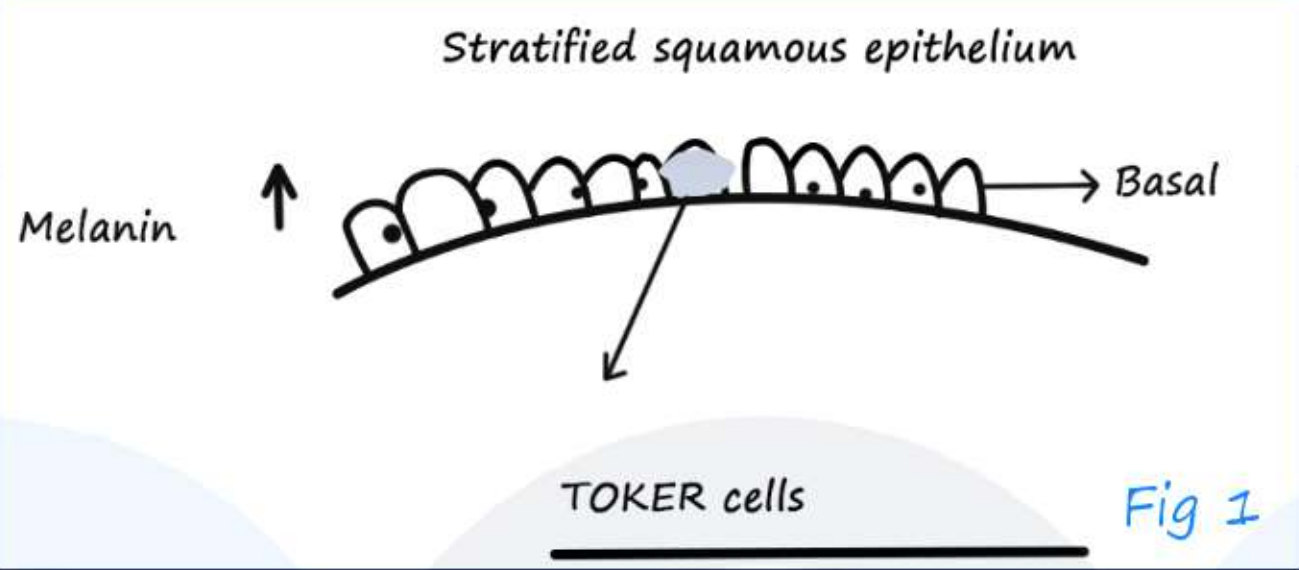

Fig 1

Features of male breast:

- No lobular unit, only ducts
- BRCA 2 Mutation predispose to carcinoma of male breast
- Breast pathologies and their site of origin:

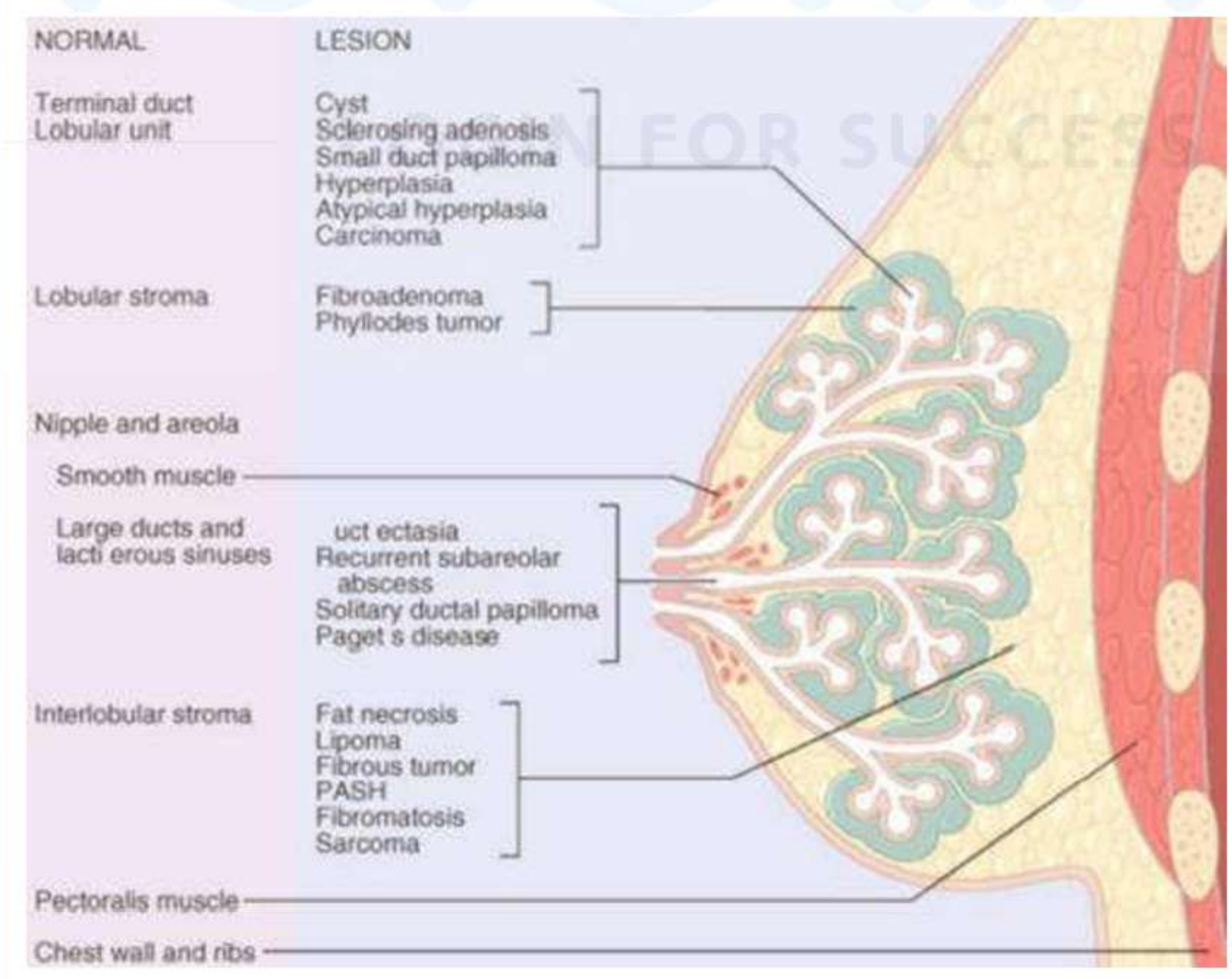

Fig 2

AfraTafreeh.com

Normal breast glands and stroma

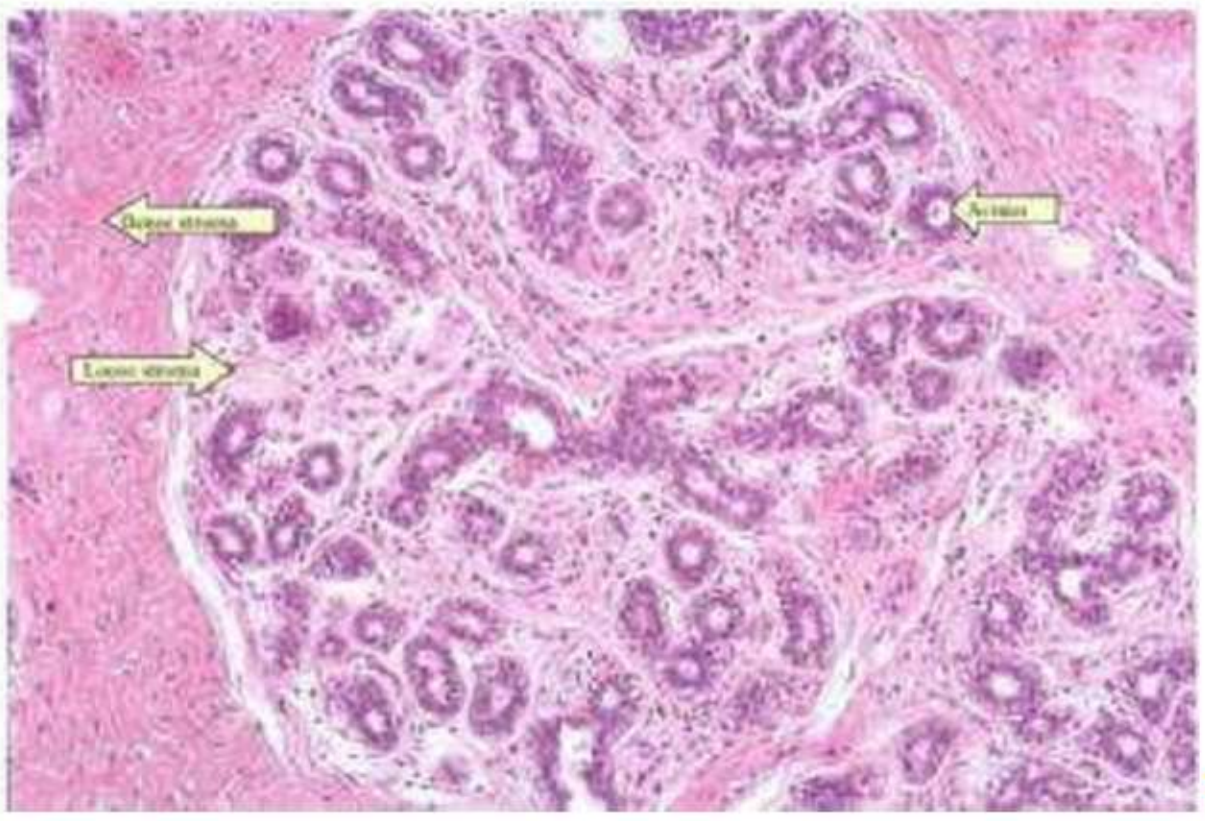

Fig 3

CLASSIFICATION OF BREAST LESIONS

Benign lesions 00:00:30

- Non – Proliferative lesion
  - Origin – Duct
    - Duct Ectasia
  - Origin TDLU
    - Adenosis ↓
      - Mild hyperplasia
      - Cyst formation
      - Apocrine metaplasia
      - fibroadenoma

- Relative risk of progression into cancer – 1%
- Absolute risk – 3%

- Proliferative Lesion
  - W/O Atypia
    - Duct papilloma
    - IDLU to severe hyperplasia
      - Relative Risk – 2%
      - Absolute Risk – 6%
      - Moderate-sever hyperplasia
      - Sclerosing adenosis
      - Radial scar
      - Complex fibroadenoma

AR-2%
AR-6%

  - W/O Atypia →
    - Atypical ductal hyperplasia
    - Atypical lobular hyperplasia

RR-4%
AR-14%

AfraTafreeh.com

TUTORIALS LOGIN FOR SUCCESS

- In situ lesion
  - i. DCIS
  - ii. LCIS

  } Relative risk -8%, Absolute risk -28%

	RR	AR
Non-Proliferative lesions	1%	3%
Proliferative w/o Atypia	2%	6%
Proliferative w/Atypia	4%	14%
In Situ lesion	8%	28%

AfraTafreeh.com

INFLAMMATORY - LESION

Inflammatory lesion of breast 00:00:08

- Acute mastitis
- Duct ectasia
- Lymphocytic Mastitis
- Granulomatous mastitis
- Squamous metaplasia of lactiferous duct
- Fat necrosis

I. Acute Mastitis 00:01:24

- Occurs within 1 month of breast feeding
- Inadequate feeding and crocks in nipple predispose to injection with **staphylococcus** aureus causing mastitis Painful inflammatory condition

II. Duct Ectasias 00:02:05

- Abnormal dilatation of ducts
- 50–60-year-old females

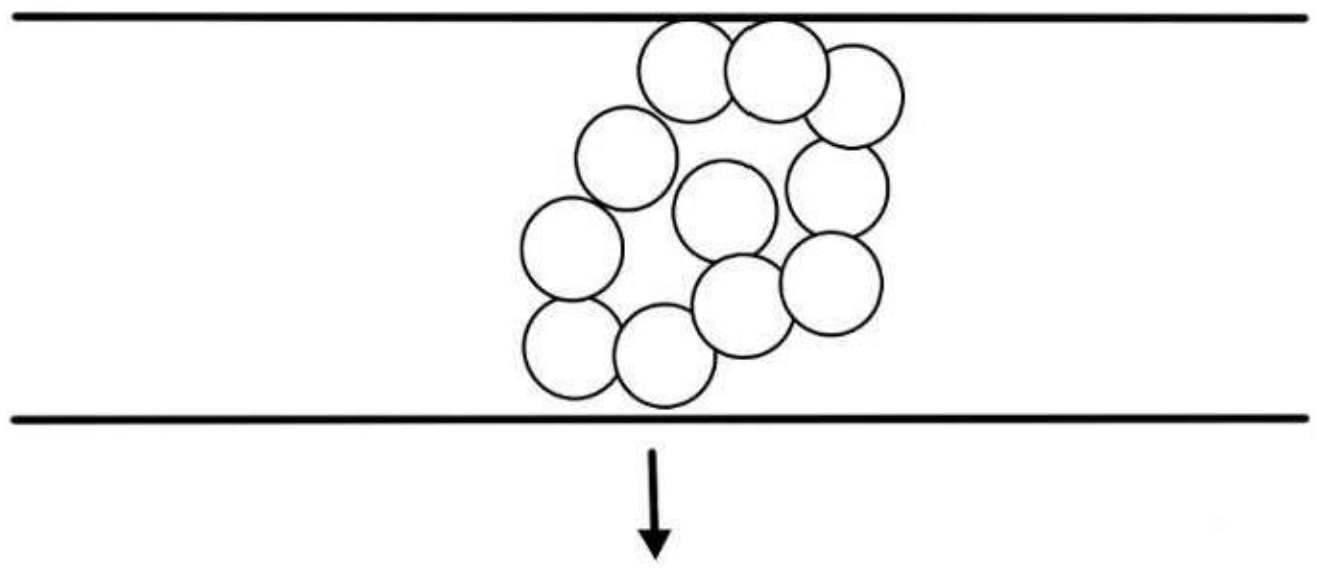

Foamy macrophages blocking the ducts

Presentation i. Thick white paste like discharge from nipples

ii. Nipple retraction

↓

Infiltration of plasma cells also called **plasma cell mastitis**

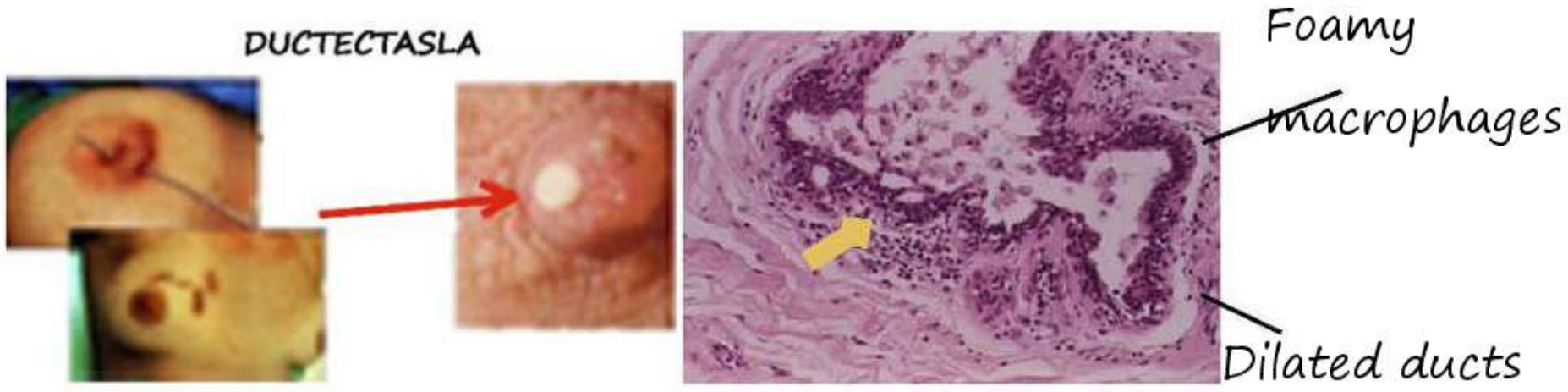

Lymphocytic mastitis 00:06:24

- Etiology-Autoimmune phenomena against antigen expressed during lactation
- Common in patients of diabetes DM1> DM2

Infiltration of B lymphocytes

↓

Causes atrophy of lobular and acini

↓

Thickened basement membrane

Granulomatous Mastitis 00:09:06

i. Tubercular Infection (rare)

ii. Silicon / Implants / nipple piercing

iii. Sarcoidosis (rare)

i. Lobular granulomatous Mastitis

Autoimmune against idiopathic antigen

i. Cystic neutrophilic

ii. Granulomatous mastitis

- cause- **Corynebacterium**

AfraTafreeh.com

1.Squamous Metaplasia of lactiferous ducts

- Aka Zusha's Disease
- Occurs in females who smoke
- Lining of lactiferous ducts undergoes squamous Metaplasia

Fat Necrosis 00:13:32

– Cause – Trauma

- Seen in interlobular stroma
- Gross – chalky white deposits.

TUTORIALS
LOGIN FOR SUCCESS

FYBROCYSTIC DISEASE

(Non-proliferative breast lesion)

i. Also known as fibrocyst adenosis, cyclical mastalgia with nodularity
ii. Presentation – In menstruation age group as a bilateral painful swelling better felt with palpating fingers
iii. Pain and tenderness are more just prior to menstruation (Cyclical mastalgia)

Microscopic changes:

a. Adenosis (increase number of acini)
b. Stromal fibrosis
c. Cyst formation
   - An estrogen dependant condition
   - Lining of ducts are flattered
   - Filled with secretions
   - One of the cysts may get enlarged to become clinically palpable well localized swelling with thin bluish capsule called **Blue Dome Cyst**
d. Mild hyperplasia of ducts and acini
e. Apocrine metaplasia – abundant pink cytoplasm with apical snouting

AfraTafreeh.com
TUTORIALS
LOGIN FOR SUCCESS

AfraTafreeh.com

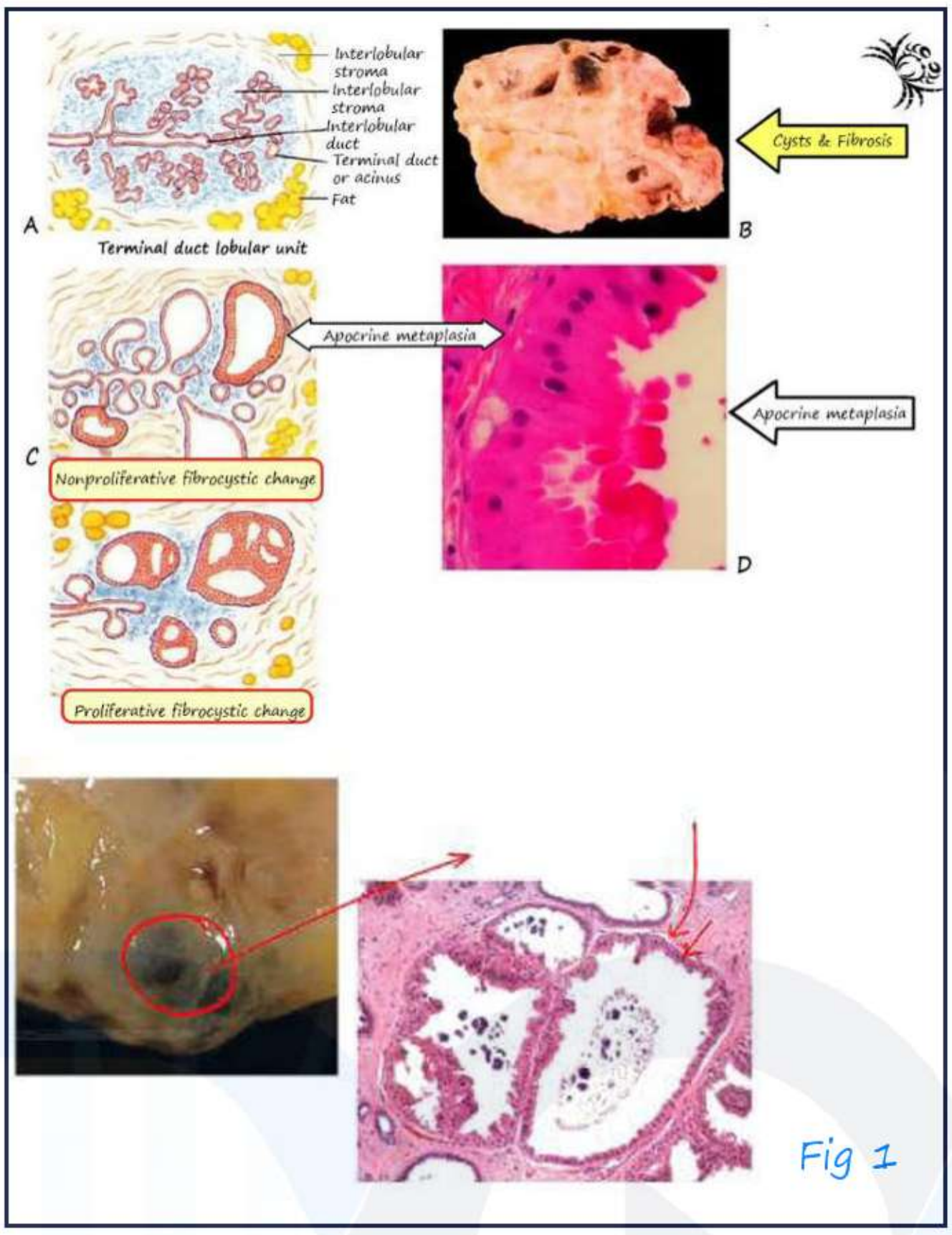

FIBROEPITHELIAL LESIONS WITH EMPHASIS ON FIBROADENOMA AND PHYLLODES TUMOR

Fibroepithelial lesions

Fibroadenoma | Phyllodes Tumor

- Relative risk of malignant transformation – 1%

  Absolute risk – 3%

← Both arise in intralobular stroma →

Fibro Adenoma: 00:01:23

i. Most common benign tumor of female breast occurring in young female's – **25-40 years**

ii. A hormone dependent condition

iii. Gross – Rubbery well circumscribed palpable mass with slit spaces moving freely within breast (**Mouse in the breast**)

FNAC –

- Slit shaped spaces seen

Fig 1

AfraTafreeh.com

- Stromal Proliferation
- Staghorn Appearance (Antler horn)
- Spindle shaped cells seen

Microscopy – proliferation of both intralobular stroma and epithelium

2 patterns

Intracanalicular	**Pericanalicular**
• Slit like compression acini and ducts by proliferating stoma	• Normal duct surrounded by proliferating stroma
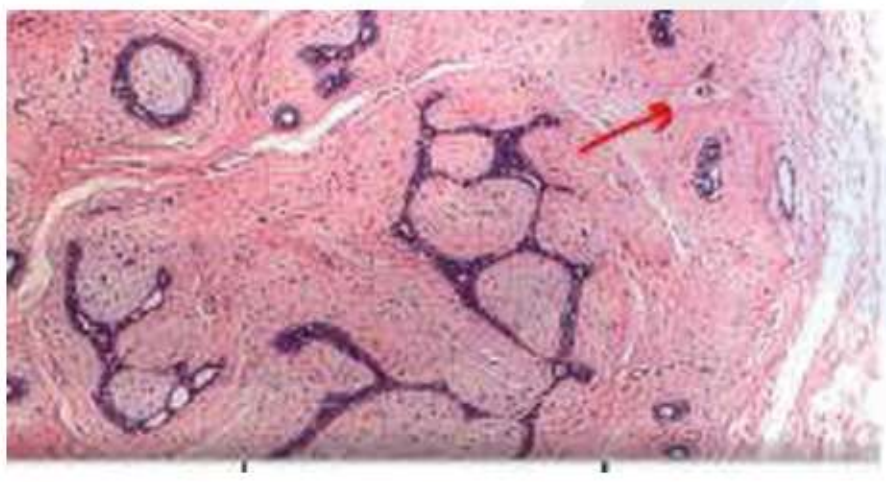	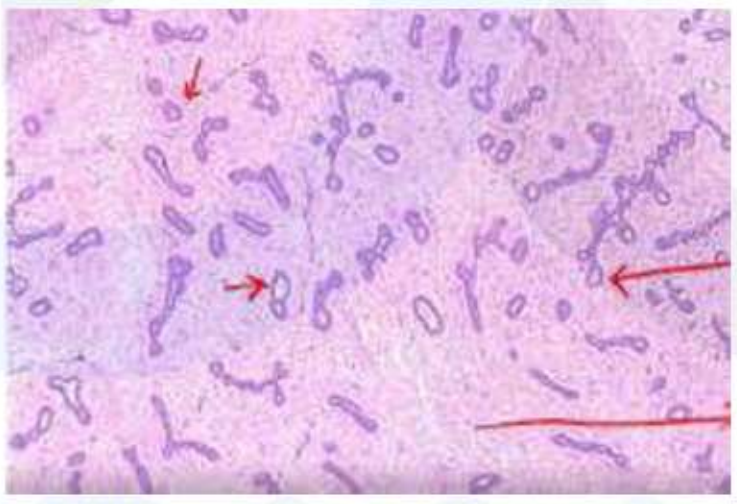

Complex fibroadenoma:

Typical fibroadenoma with fibrocystic changes like

- Sclerosing adenosis
- Papillary apocrine metaplasia
- Cyst formation > 3 mm
- Epithelial calcification
- Occur in the older age groups
- Increased risk of cancer

Phyllodes tumor: 00:13:14

- Phyllodes meaning leaf like
- Also known as cystosarcoma phyllodes
- Most commonly after 60 years
- Spectrum

Benign	Malignant
proliferating intralobular stroma pushes into interlobular stroma	intralobular stroma proliferates and infiltrates into interlobular

Gross – large capsulated area with cystic spaces cut surface – soft brownish, cystic areas

AfraTafreeh.com
DOC TUTORIALS LOGIN FOR SUCCESS

Microscopy:

	Benign	Border Line	Malignant
i. Border	Pushing		Infiltrating
ii. a. Stromal Over Growth	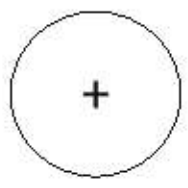	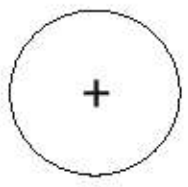	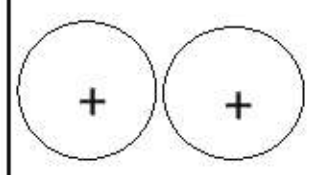
b. Stromal Cellularity	Mild	Moderate	Severe
c. Stromal Atypia	Mild	Moderate	Severe
iii. Mitotic Activity	< 5/10 HPF	5-9 / 10 HPF	>10/10 HPF

AfraTafreeh.com

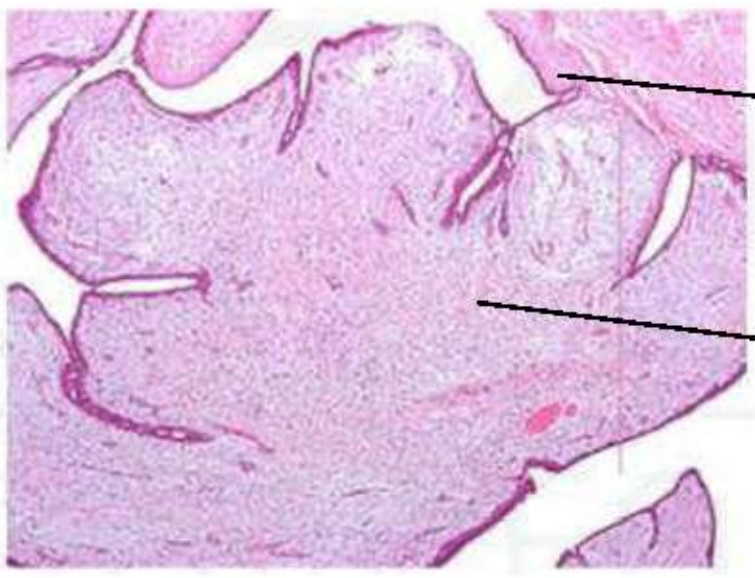

Fig 2

Note:

Fibroadenoma: If showing extensive myxoid change look for features of **CARNEY complex**

Phyllodes tumor: showing extensive **mesenchymal metaplasia** signifies malignant transformation.

Complex fa: sclerosing adenosis 00:22:35

- Epithelial calcifications
- Papillary apocrine metaplasia
- Cysto greater than 3 mm

TUTORIALS LOGIN FOR SUCCESS

PROLIFERATIVE BREAST DISEASE

- Papilloma
- Sclerosing adenosis
- Radial Scar
- Moderate to florid hyperplasia

Papilloma 00:00:55

- Usually single, from a single lactiferous duct Vascular stalk
- It blocks the duct causing ductal dilatation
- Epithelium lined true polyps of breast lactiferous ducts
- Vascular stalk is present usually
- Multiple papillomas in many ducts can be premalignant

AfraTafreeh.com

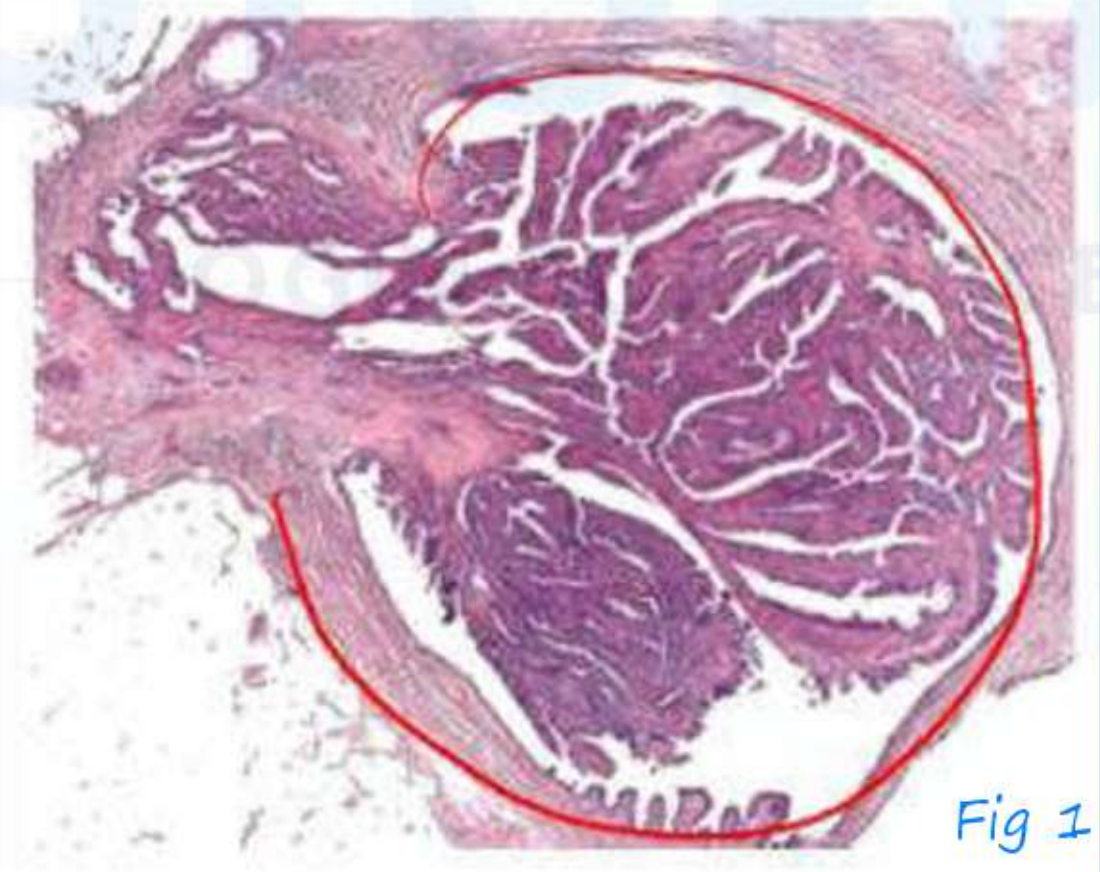

Fig 1

- Presentation Serous/Woody discharge from nipple

AfraTafreeh.com

Sclerosting Adenosis 00:03:13

- Benign proliferative condition of terminal duct lobular unit (TDLU) with increased number of Acini lobulocentric disease
- 30-50-year age group

Microscopy

- Proliferative terminal ductless and acini with proliferation of stroma
- There is lobular enlargement
- Fibrous stromal proliferation and distortion of ducts
- Cellularity Higher in center
- Intact luminal & myoepithelial cells differentiate it from carcinoma

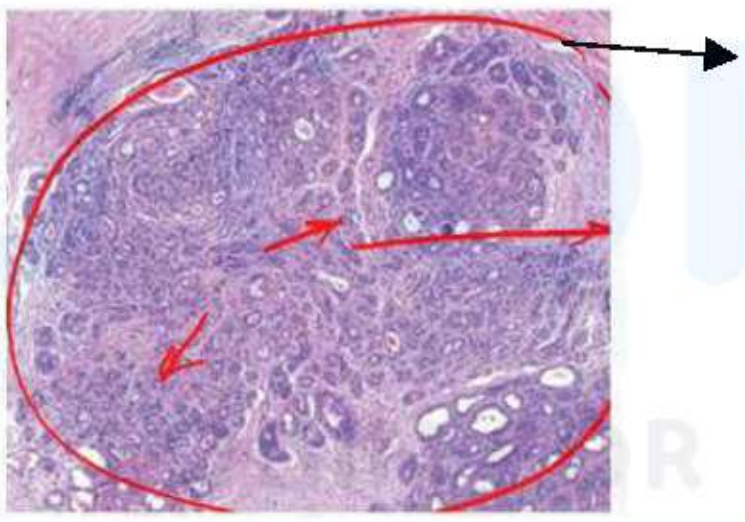

Fig 2

Complex sclerosing lesion

- Complex sclerosing lesion is with papilloma, and epithelial hyperplasia often with fibroadenoma radial scar is a variant of this
- Radial scar-rosette like proliferative breast lesion with **increased elastic fibres.** Stained by VGE stain

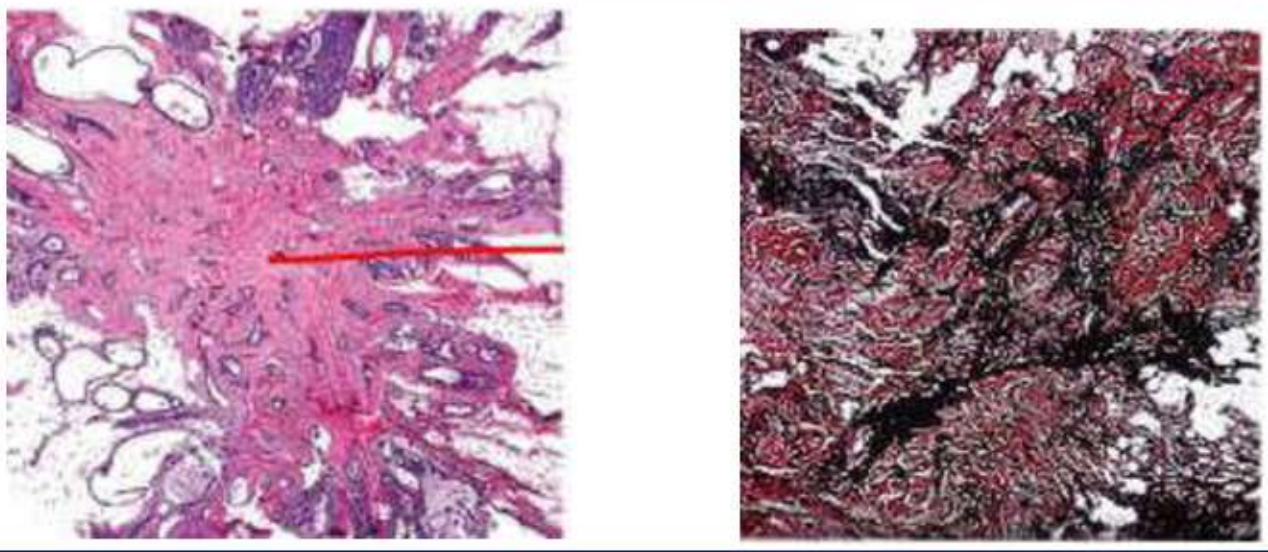

VGE stain

Fig 3

- On HPE, it shows a central fibrous cora with radial extension of tubular structures appearing like a flower head

Epithelial Hyperplasia 00:10:39

- Increase in number of luminal & myoepithelial cells

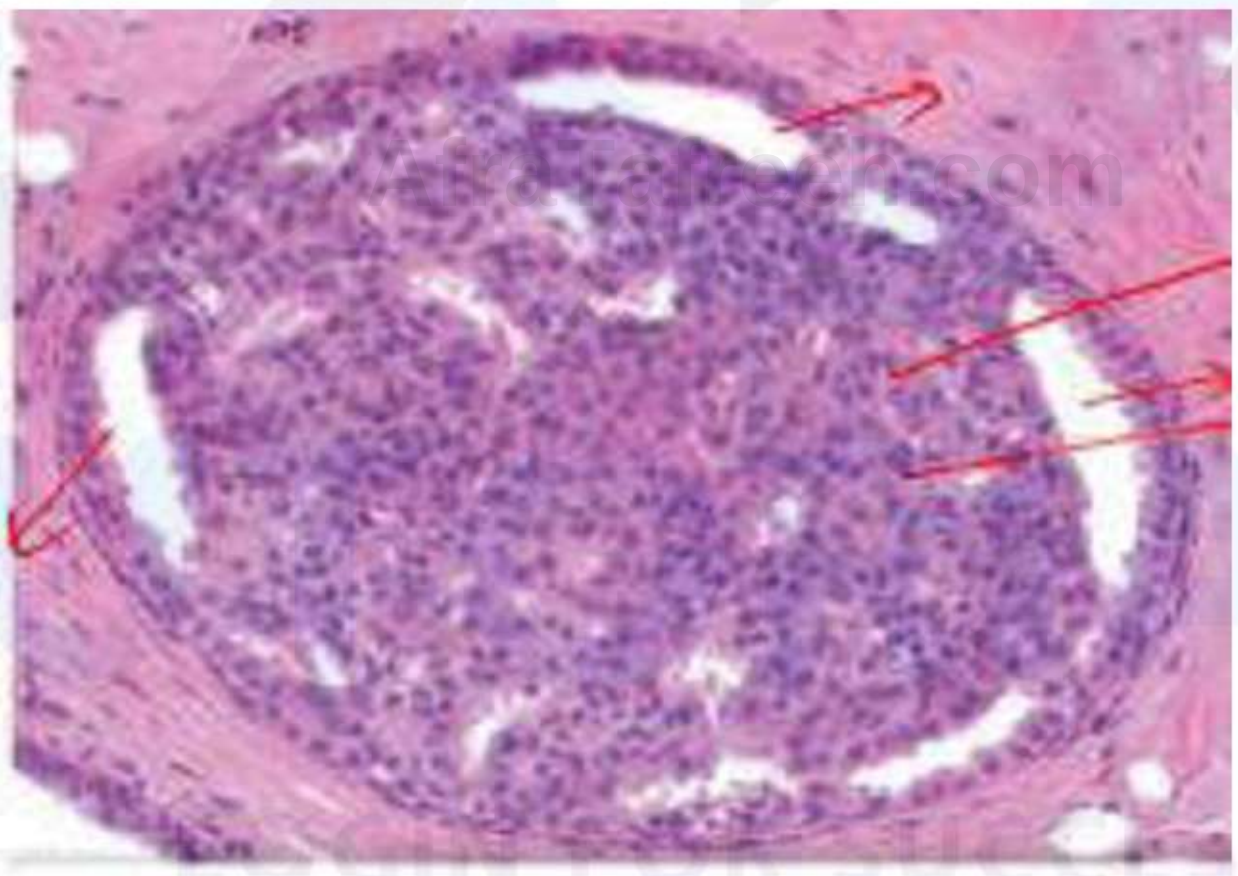

Fig 4

- Flore hyperplasia

AfraTafreeh.com

Proliferative Breast Disease with Atypia 00:12:33

- Clonal lesion-proliferation of one type of cells
- Mutations loss of 16q or gain of 17p

2 Lesions

- Atypical ductal hyperplasia
- Atypical lobular hyperplasia

  - when lesion is ≤ 2mm

    or involvement of 1 2 ductal spaces
  - Monomorphic cells
  - Do not fill the duct lumen completely
  - 3 common patterns

    i. Solid

    ii. Cribriform

    iii. Micropapillary
- Cribriform → Polarization of nucleus towards spaces
- Micro papillary → club shaped

Fig 5

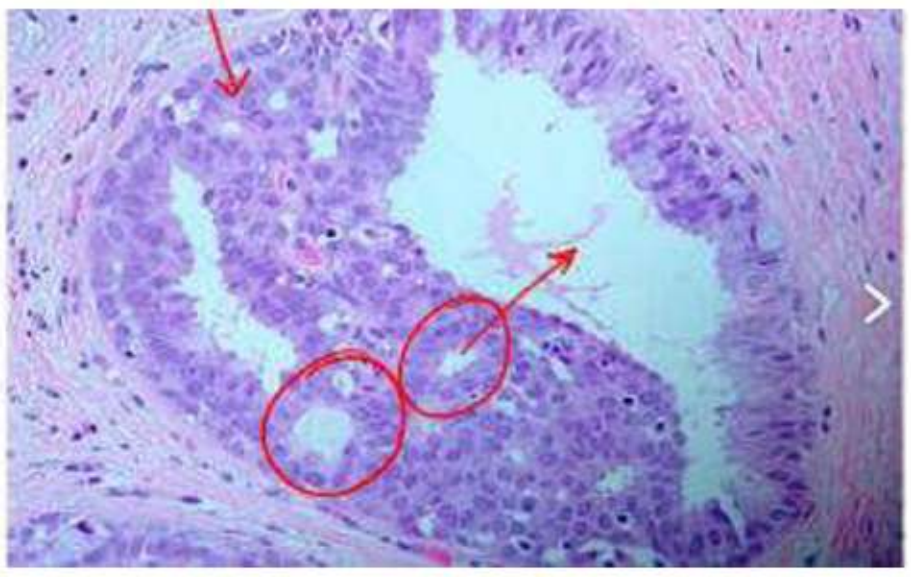

ADH with solid and cribriform architecture. Fig 6

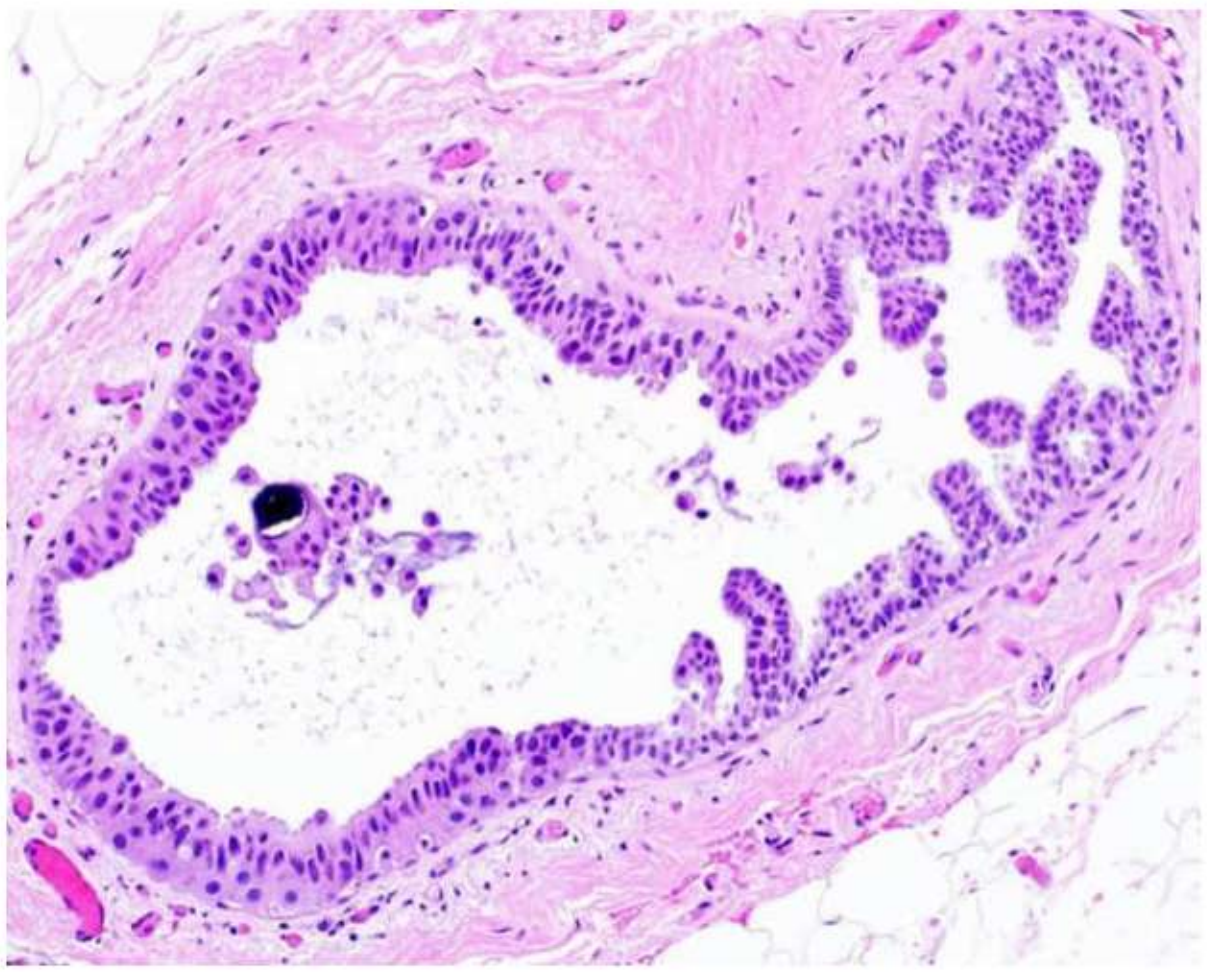

Fig 7

- Microscopically ADH can also show pattern of uniform sized bridges

Atypical lobular hyperplasia

- Cells do not fill or distend more than 50% of the acini within a lobule

AfraTafreeh.com

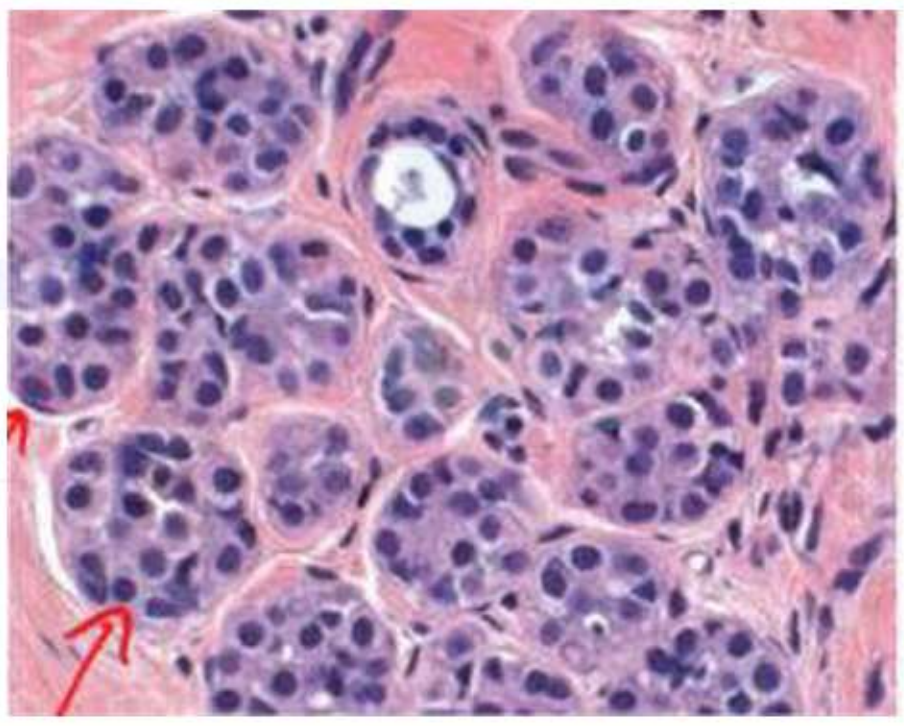

Fig 8

- When > 50% involved – it is called as **lobular carcinoma in situ**
- Both ALH and LCIS show **loss of E-cadherin.**

AfraTafreeh.com

IN-SITU LESIONS – DCIS, – LCIS

In-Situ Lesions

DCIS

- Proliferation of malignant ductal epithelial cells without any invasion into basement membrane (myoepithelial cells preserved)
- It can be
  1. Comedo DCIS
     - -With central necrosis
     - -High grade
     - -Lined by single layer of luminal cells
  2. Non- Comedo DCIS
     - -Cribriform (Cookie cutter pattern) — low grade
     - -Micropapillary — low grade
     - -Solid → High grade

LCIS

- > 50% of acini in a lobule are involved
- Show loss of E-cadherin

- Comedo DCIS

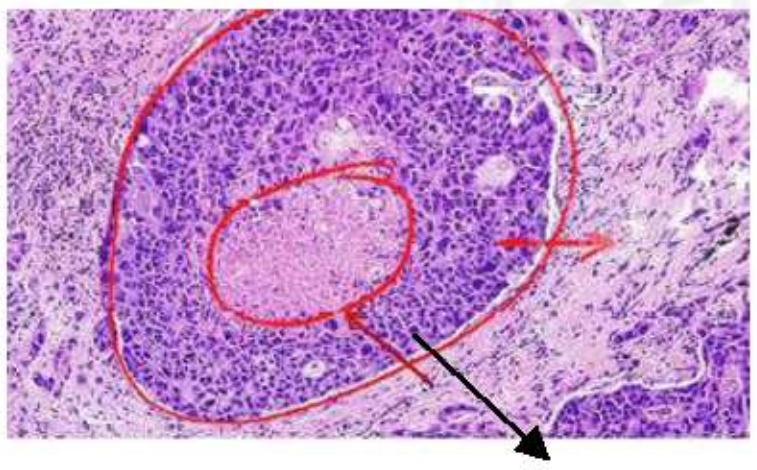

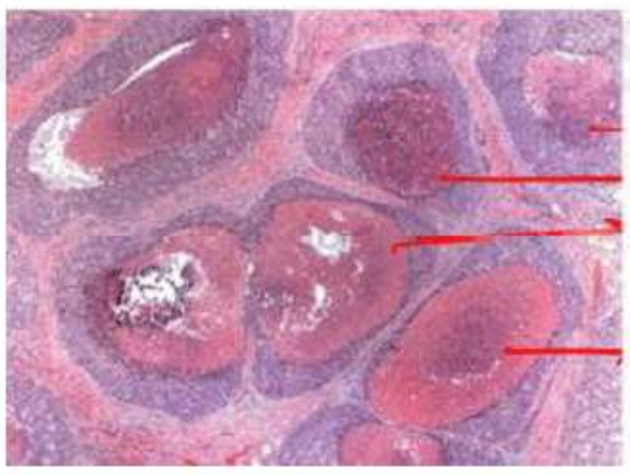

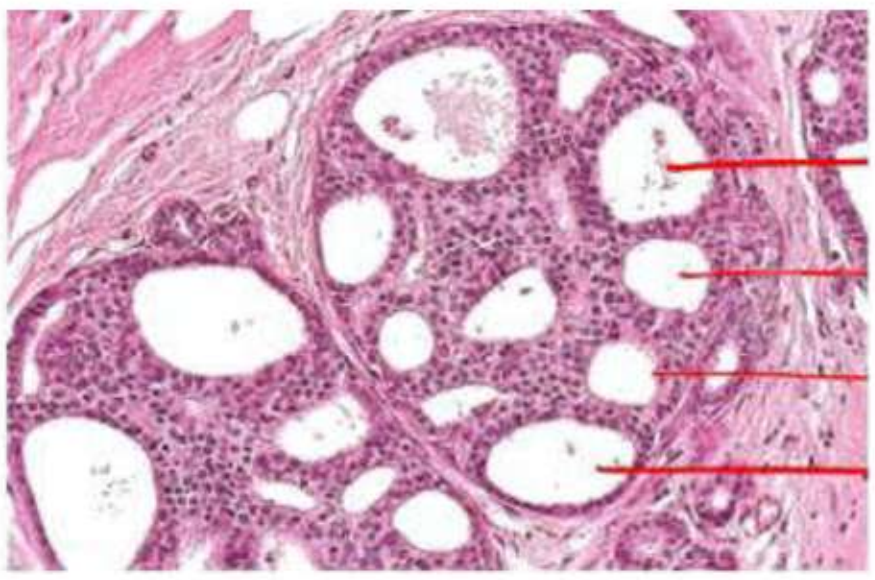

Cookie cutter pattern

Fig 1

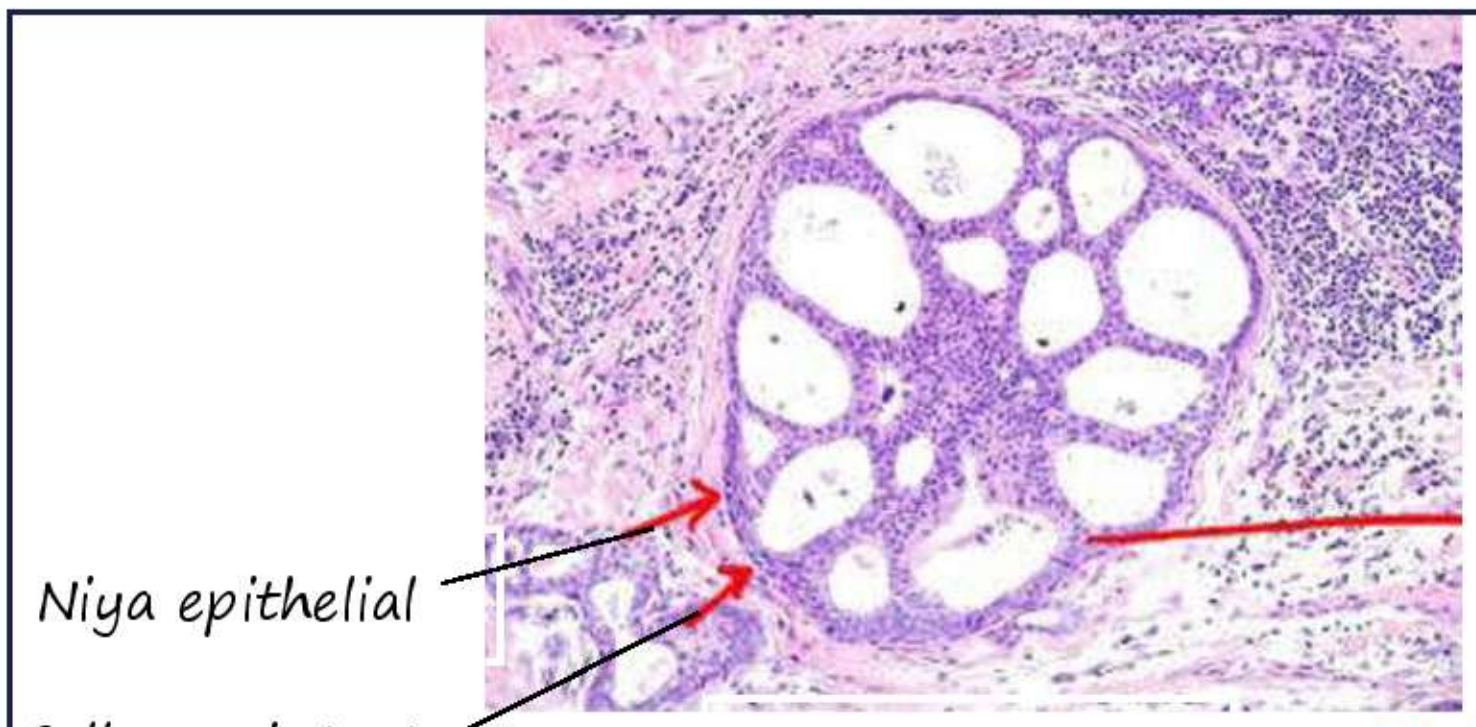

Cribriform DCIS Fig 2

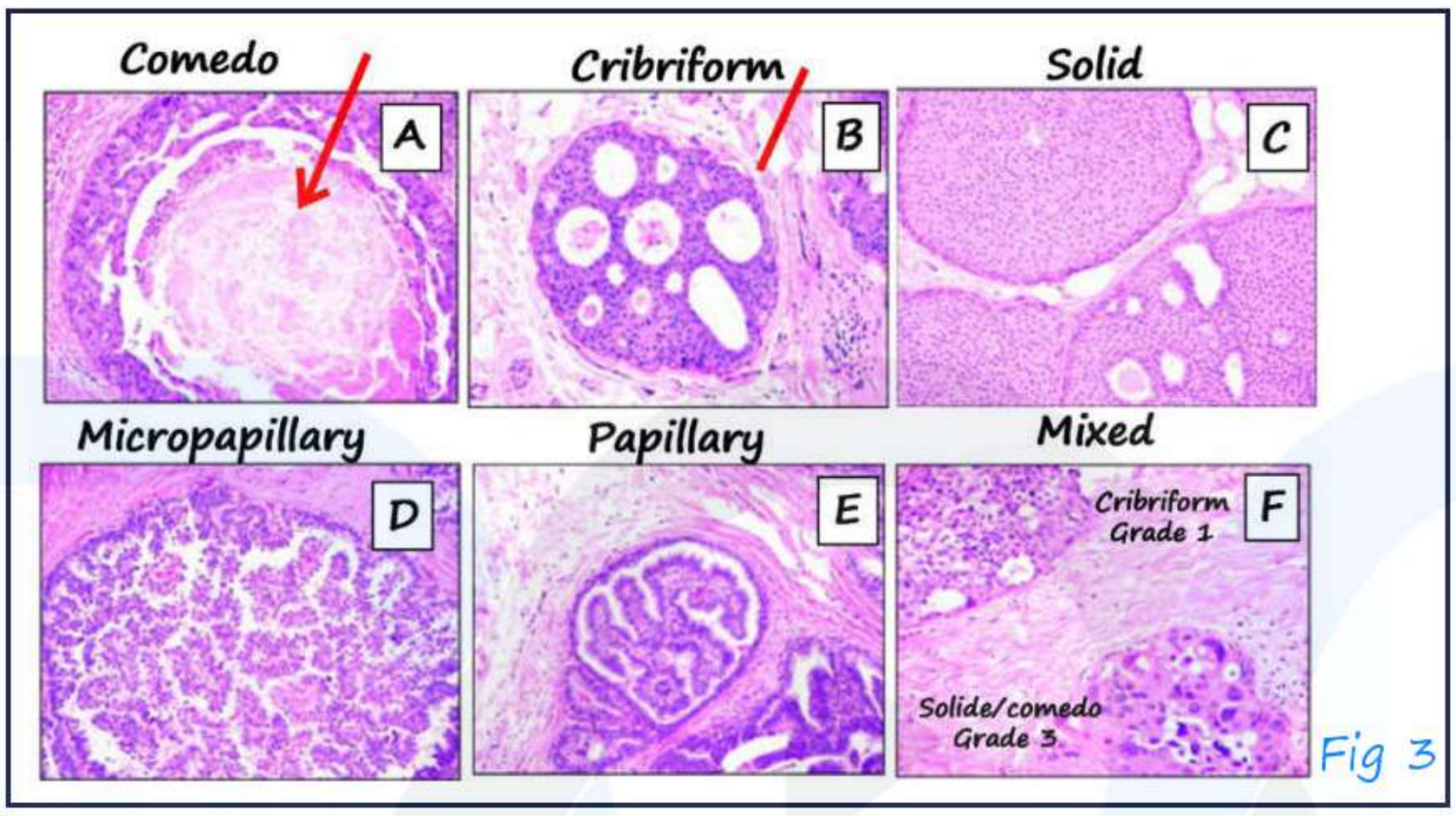

Fig 3

LCIS 00:05:26

AfraTafreeh.com

- Originates in terminal duct lobular unit only of female breast it duties
- Involvement of > 50% acini by small round with cells
- Loss of **E-cadherin**
- Loss of contact inhibition

TUTORIALS
LOGIN FOR SUCCESS

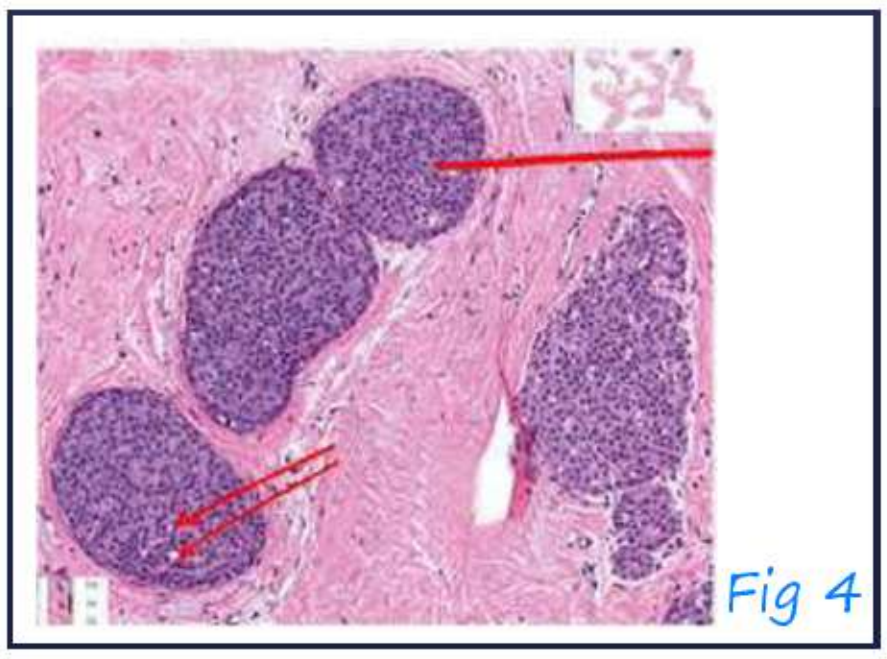

Fig 4

AfraTafreeh.com

- LCIS, classic type 10x-H and E : TDLU filled and distended by solid proliferation of small and uniform population of cells; cells are loosely cohesive, vacuolated cytoplasm, many with distinct intracytoplasmic vacuoles

TDLU

- Filled and distended by solid proliferation of small, loosely, adhesive cells with vacuolated cytoplasm.

BREAST TUMORS

Based On Genetic Etiology

Sporadic
↓
Most Common gene - p53

familial
– BRCA – 1 > BRCA –2

Radiation induced
↓
CHEK–2

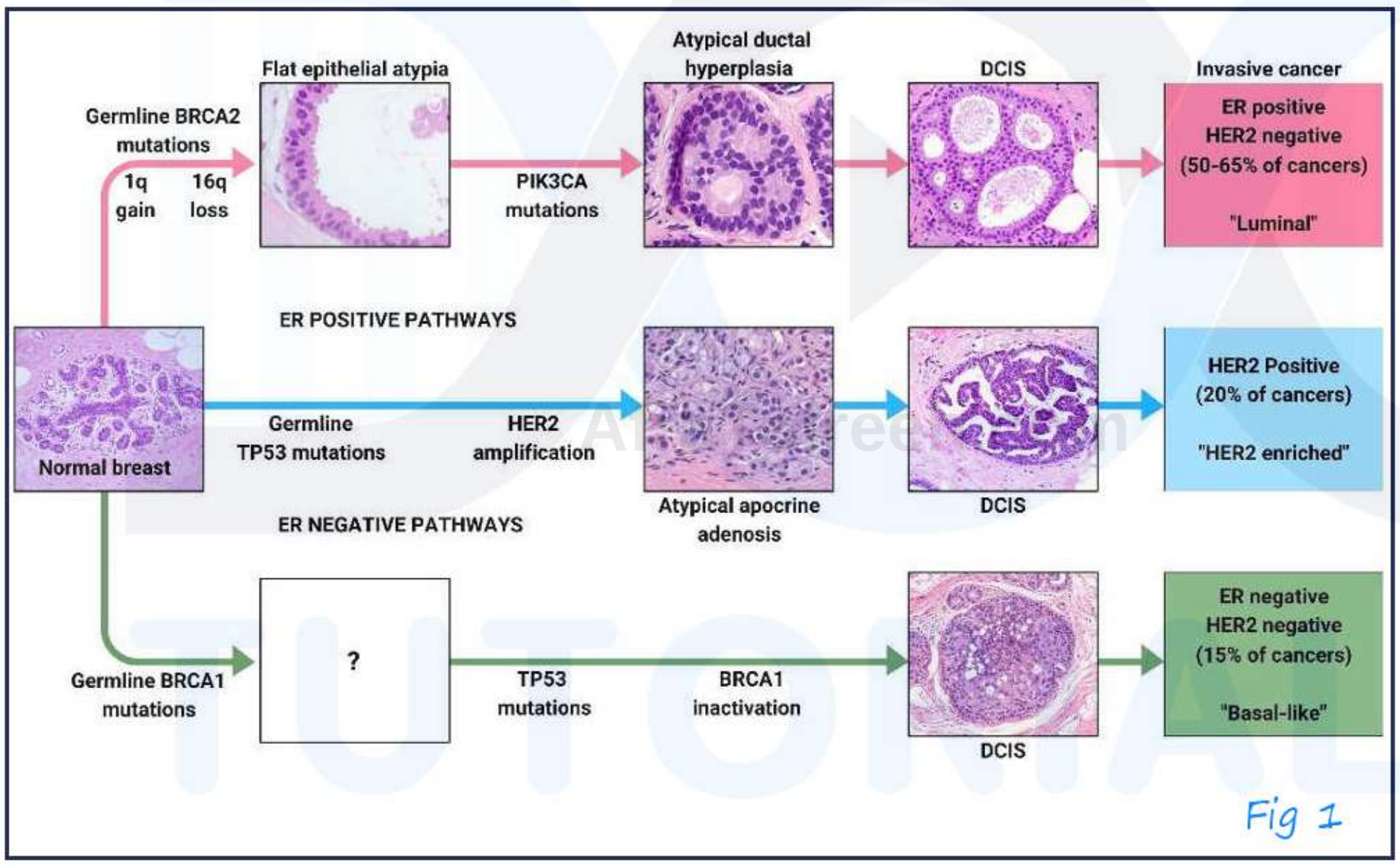

Fig 1

LOGIN FOR SUCCESS

Molecular Classification of Breast Cancer:00:09:33

1.Luminal Type (most common molecular type of breast cancer)

AfraTafreeh.com

ER/PR -VE

Luminal-A Ki67	**Luminal-B Ki67**
(Low Proliferation) • Most common Type in 40-50% O • Older • Low risk of Relapse <u>Histology</u> • Lobular • Tubular • Mucinous	(High Proliferation) Associated with BRCA-2 Mutation <u>Histology</u> • Atypical Lobular

Treatment – Tamoxifen

2.Her-2neu rich

Amplified Her-2neu

- P53 Mutation
- Apocrine change seen

2 types

ER positive 15% | ER negative

- Young females
- Rx-Transtuzumab (Herceptin)

TUTORIALS
LOGIN FOR SUCCESS

3.Triple-VE

- ER-VE
- PR-VE
- Her-2-neu-ve
- Always **BRCA-1 Mutation**
- Very poor prognoses
- Histology -
  - Medullar Ca
  - Secretory Ca
  - Adenocytic ca

Triple negative

Basel Type	Non-Basel Type
CK5/6 positive	CK5/6 negative
EGF-R positive	EGF-R negative

AfraTafreen.com
DOC TUTORIALS
LOGIN FOR SUCCESS

4.Claudin type

- Recently described type
- Associated with expression of myoepithelial Transition marker.
- No targeted therapy
- Worst prognosis

Methods of Molecular Classification of Breast cancer

- Genotyping-standard method
- Immunohistochemistry for ER/PR/HER-2-neu

AfraTafreeh.com

Her-2-neu Positivity 00:25:16

3 grades

• Scant membrane positivity • 1+ • Graded as Her 2-neu negative • Implies no DNA amplification	• Membrane positivity but not complete • 2+ • DNA amplification checked by FISH 50% negative for 50% negative amplification ↓ Her-2-neu positive ↓ RX-Herceptin	• Complete membrane positivity • 3+ • Implies Her-2-neu positivity Le DNA amplification present

Morphological Patterns of Breast Cancer

Breast cancer is mostly adenocarcinoma subdivided into

Special type	No Special Type (NST) – modified bloom Richardson criteria
• Lobular • Tubular • Mucinous • Medullary • Inflammatory	• Invasive ductal carcinoma not otherwise specified [IDC-NOS] • M/C TYPE • On Histology • Shows intense Desmoplasia • Well-formed Glands infiltrating into stroma • Lymphoplasmacytic infiltrate

TUTORIALS LOGIN FOR SUCCESS

Graded According to Bloom Richardson Criteria

00:33:12

based on

i. Tubule Formation

ii. Mitotic Activity

iii. Nuclear Pleomorphism

Classified into Grade 1, 2 & 3.

i. Lobular Carcinoma 00:34:32

- Bilateral, Multifocal
- Not seen in Males
- There is loss of E-Cadherin
- On Microscopy Targetoid

AfraTafreeh.com

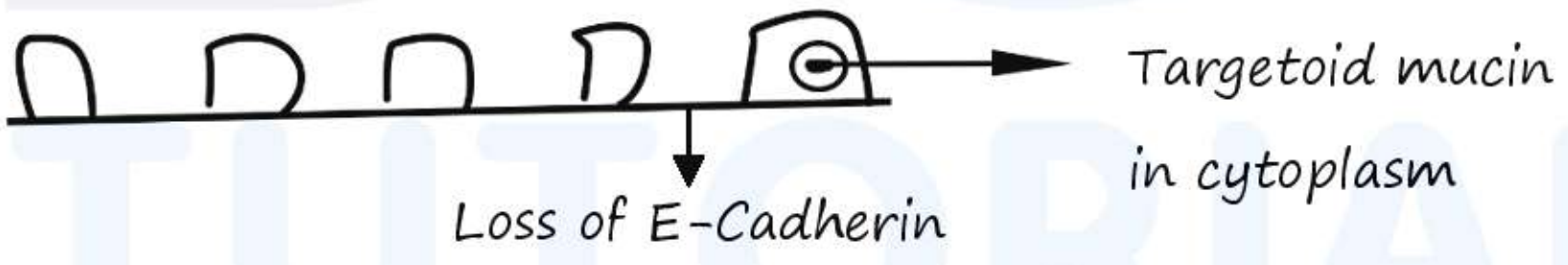

- ER/VR+VE, Her-2-neu-ve
- Good prognosis

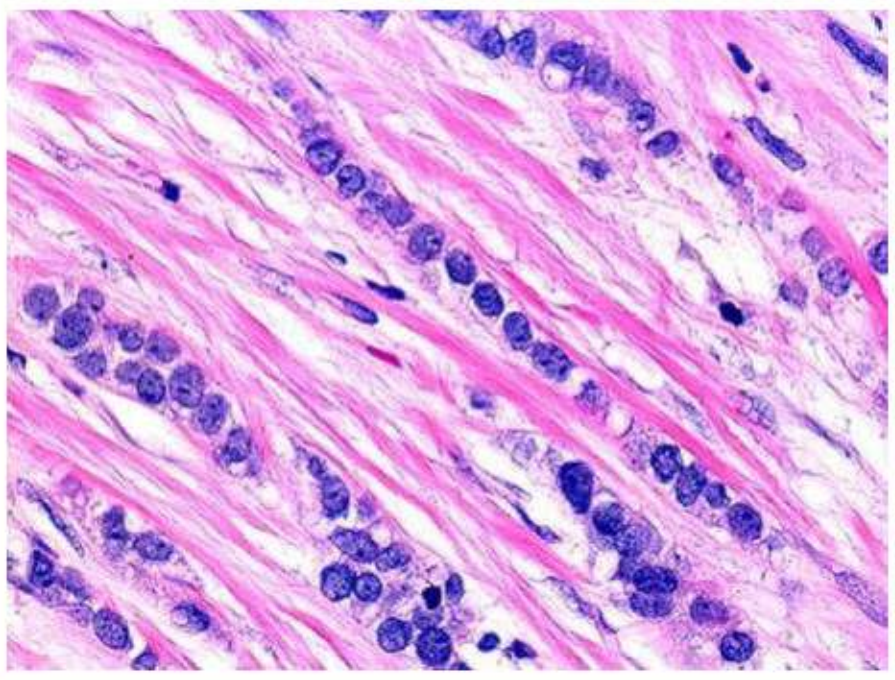

Fig: 2

AfraTafreeh.com

ii.Mucinous carcinoma 00:37:37

- Occurs in post-Menopausal females
- Soft lump in Breast
- On Gross Gelatinous Tumor
- Microscopy-Tumor Cell in pool of Mucin – investigations – FNAC/trucut biopsy
- ER/PR positive
- Her-2-neu negative
- Good Prognosis

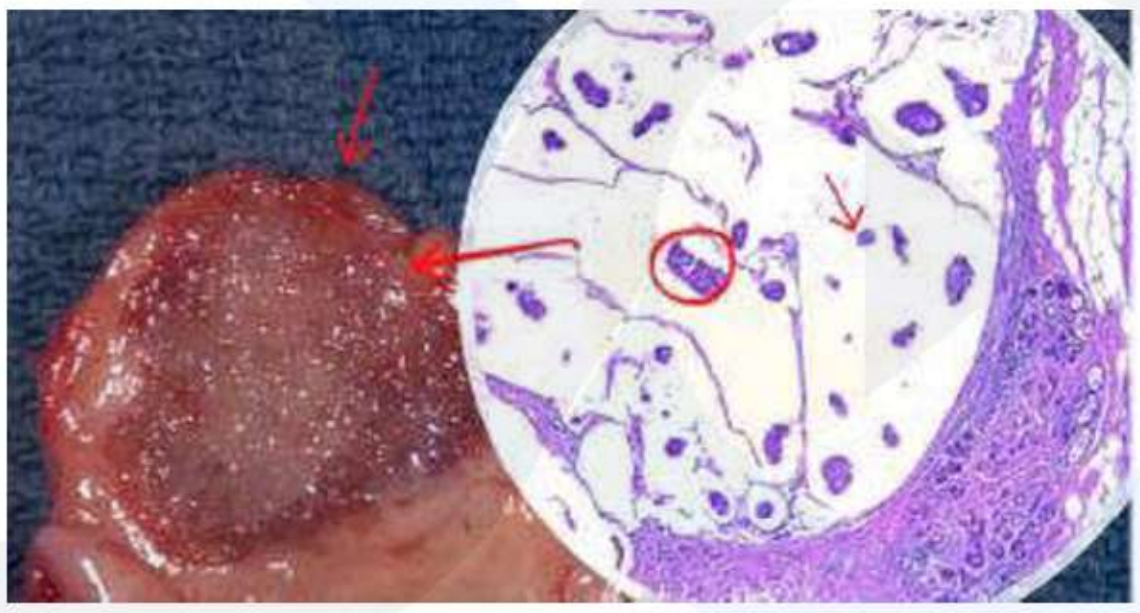

Gross **Microscopy** Fig 3

TUTORIALS LOGIN FOR SUCCESS

iii. Tubular carcinoma 00:40:13

- ER/PRVE
- Her 2-neu-ve
- <u>On Microscopy</u> -

  Angulated Tubular infiltrating stroma

  String of beads arrangement of Tumor cells around lumen
- Excellent Prognosis

iv. Medullary carcinoma 00:42:14

- Carcinoma with medullary facture
- Age group 45-50 years females – No desmoplasia
- Soft well circumscribed lesion in breast resembling fibre adenoma
- On Microscopy
- 75% Tumor cells show Syncytium formation
- Dense Lymphoplasmacytic (CD8) infiltrate
- Prominent nuclei seen
  - Syncytium like growth
  - Large pleomorphic nuclei

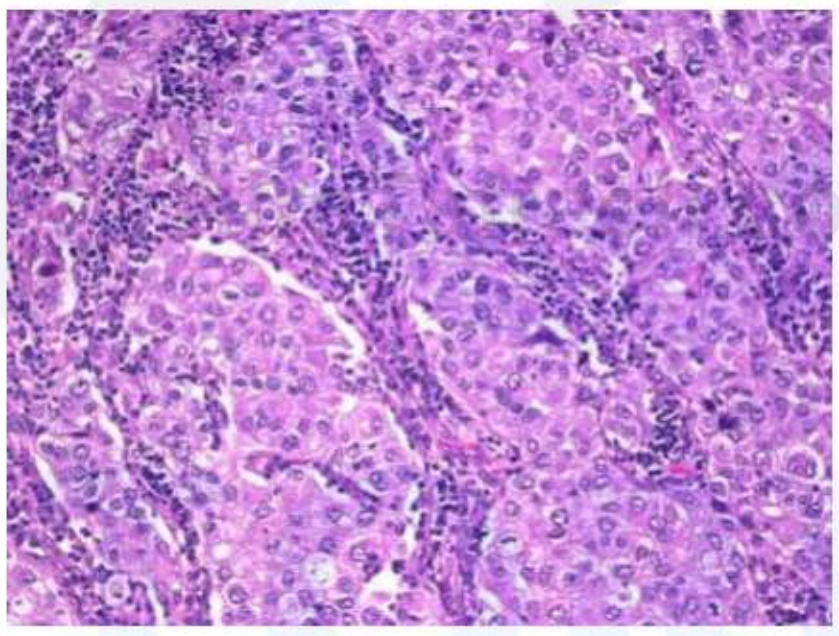

Fig 4

- Seen in females with **BRCA-1 mutation**
- Better prognosis than NST Tumors
- Triple Negative

v. Papillary carcinoma 00:49:40

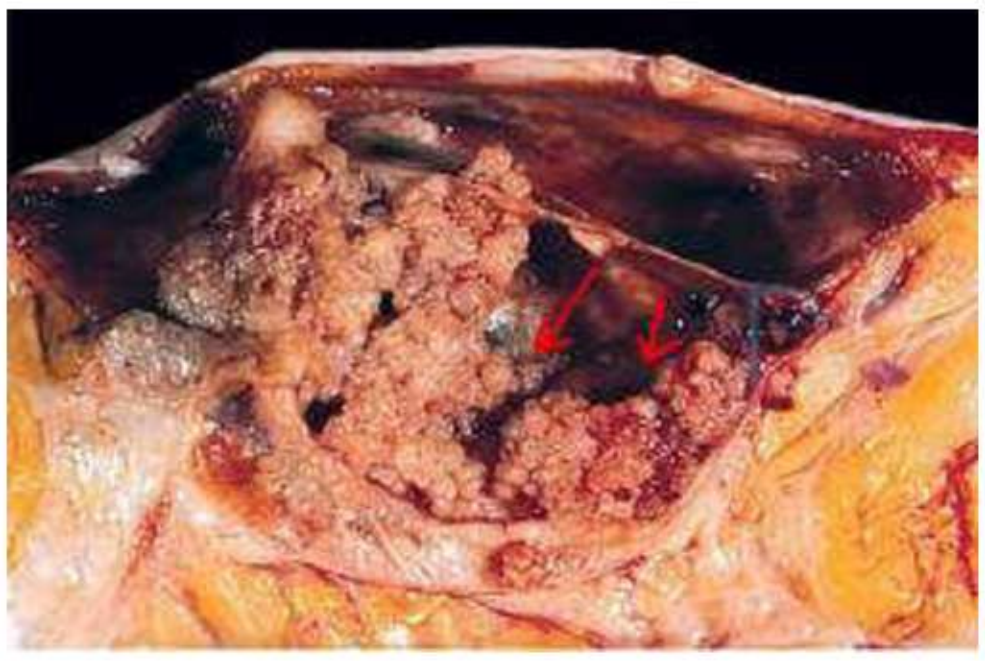

Fig 5

AfraTafreeh.com

vi. Inflammatory carcinoma 00:50:17

- Most aggressive type of Carcinoma Breast
- Common in locating women or Pregnancy
- Mimics acute Mastitis
- Clinically Peau 'd' orange appearance of Breast due to tumor emboli within dermal lymphatics
- Worst prognosis

No special type → IDC-NOS

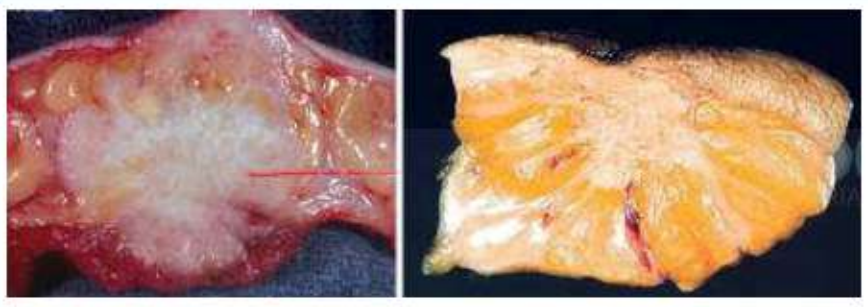

Fig 6

Gross and microscopy

- Hard Tumor with extensive desmoplasia
- Well form glands infiltrating into stroma

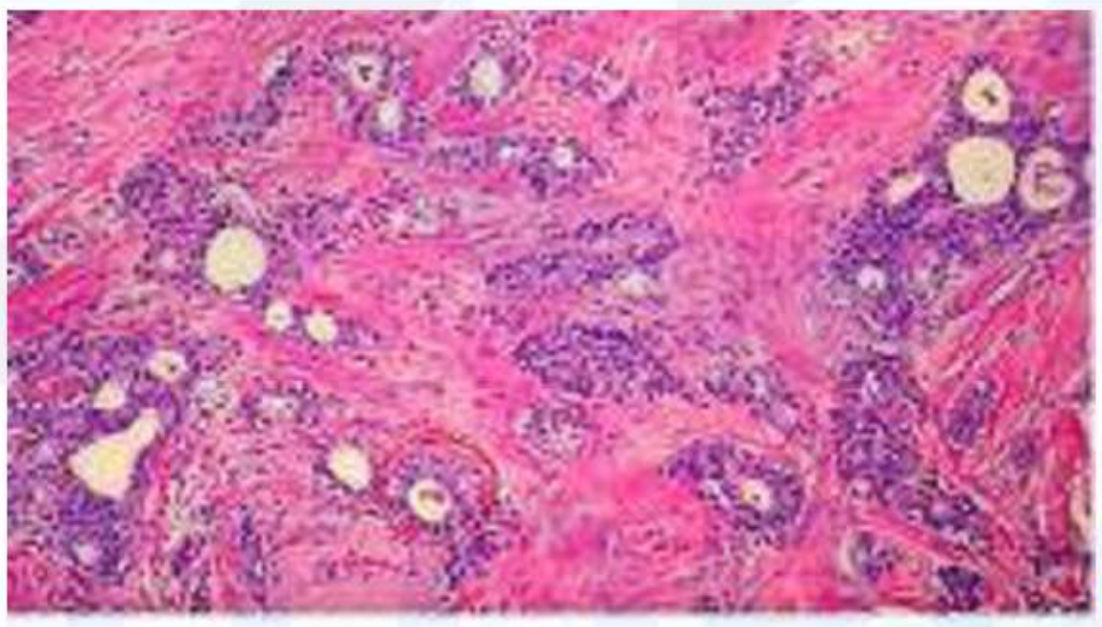

Fig 7

Prognostic & Predictive Factors 00:54:37

- Prognostic factors → Factors deciding outcome
- Predictive factors → Deciding course & therapy
- 3 Prognostic Categories
  - Grade-I: Well researched responses to therapy studied
  - Grade-II: Research done but response to therapy not studied.
  - Grade-III: Under Research

Category I	1.Tumor size 2.Lymph node status 3.Micro metastasis 4.Histological grade 5.Mitotic count 6.Hormonal receptor status
Category II	1.HER-2/neu expression 2.P53 mutation 3.Lymphovascular invasion 4.DNA ploidy
Category III	1.Tumor angiogenesis 2.EGFR 3.Transforming growth factor

AfraTafreeh.com

Nottingham prognostic criteria/bloom Richardson criteria

i. Tubular formation

ii. Nuclear pleomorphism

iii. Mitotic activity

TUTORIALS
LOGIN FOR SUCCESS

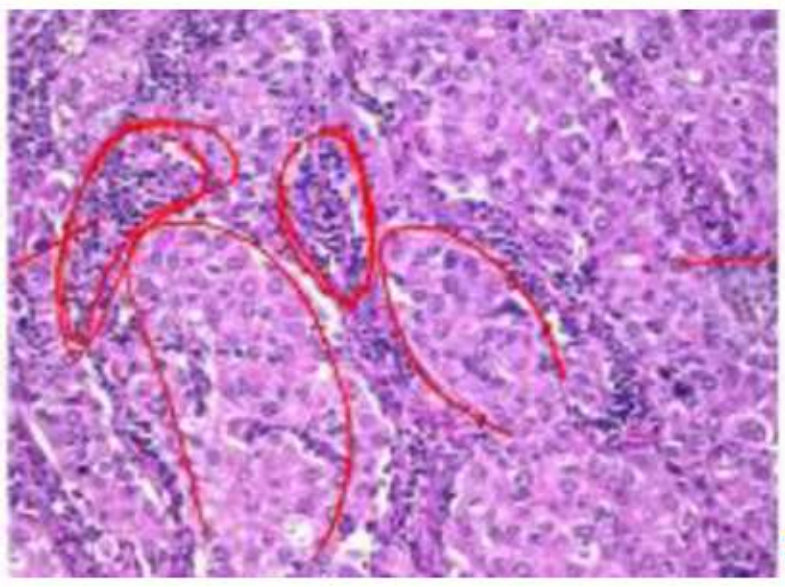

Fig 8

AfraTafreeh.com

Inflammatory carcinoma

MammaPrint (FDA Approved)	oncotype DX (not FDA approved)
• Analysis of 70 genes • Based on DNA – Micro – array technologies • Eligibility – stage I and II invasive < 5cm ER positive	• 21 gene assays – 16 cancer related genes – 5 housekeeping genes

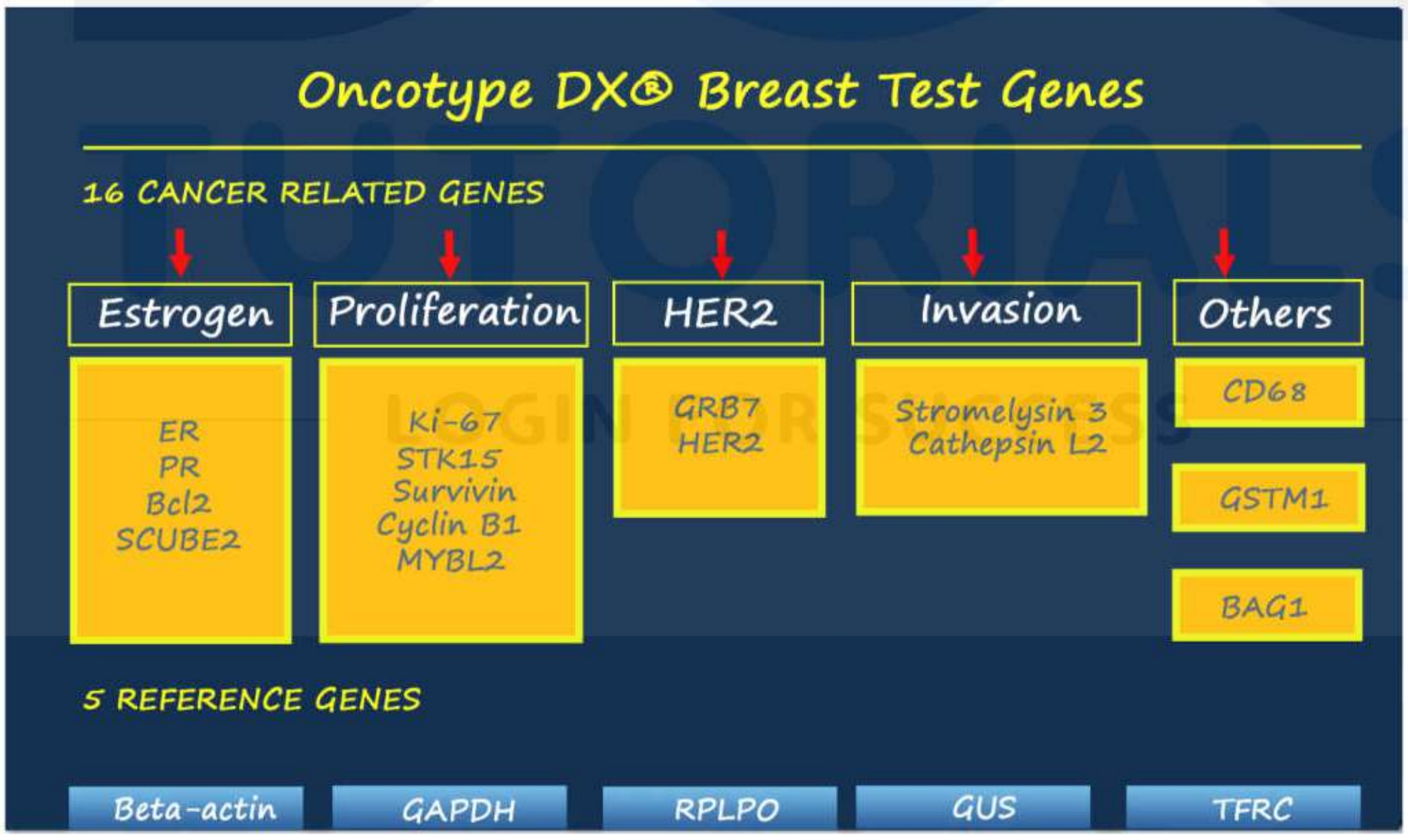

- **The Oncotype DX assay** is based on reverse transcriptase polymerase chain reaction assays.
  - To quantify expression of selected genes in paraffin embedded tissues.
  - A panel of 16 cancer-related genes and five reference genes were employed to compute a recurrence score (0 to 100).

RISK	SCORE
Low risk	<18
Intermediate risk	18-30
High risk	31-100

13) GENETIC PROFILING (MAMMA PRINT & ONCOTYPE DX)

DNA-microarray

70 genes

- Based on DNA-microarray technologies.
- Mamma Print is a 70 gene signature developed in Netheland, approved by FDA in 2007.
- It analyses 70 genes from an early stage breast cancer tissue sample to figure out if the cancer has LOW RISK or HIGH RISK of coming back in 10 years.
- ELIGIBILITY:
- Stage I and II
- Invasive
- <5cm
- ER+

AfraTafreeh.com
TUTORIALS
LOGIN FOR SUCCESS

AfraTafreeh.com

RHEUMATIC HEART DISEASE

Rheumatic Fever 00:00:17

- Type II Hypersensitivity reaction occurring as a delayed sequel to Pharyngeal injection with group A β-hemolytic streptococci

Pathogenesis

i. Antigenic cross reactivity

↓

β-Hemolytic streptococci → Sore Threat

AB → β-Hemolytic streptococci

AB → M proteins in heart

ii. Ag- APC → T cells

↓

CD4

↓

TH_1 Cells

↓

IFN gamma

↓

Macrophages → Activated Macrophages

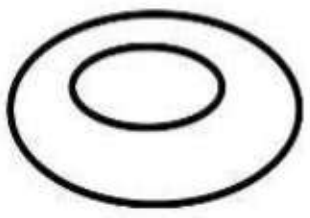

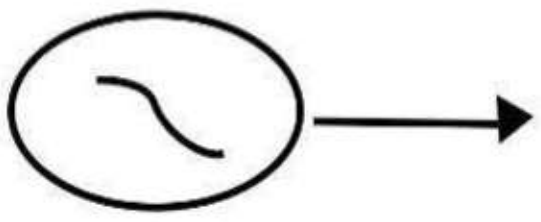

Anitschkow cells → Caterpillar like chromatin

↓

ASHOFF BODY/NODULE

- Hallmark of Rheumatic heart diseases
- Asch off Body /Nodule around blood vessels

DOC TUTORIALS LOGIN FOR SUCCESS

Diagnosis: 00:10:27

Modified JONES Criteria a 2015

High risk population	Low risk population
- Areas of poor economic conditions overcrowding and housing	< 2 cases /1 lakh children /year - Age group most susceptible is 5-15 years

AfraTafreeh.com

Major Manifestation

TUTORIALS

J	O	N	E	S
Joint Involvement M/c Major	Carditis	Nodules	Erythema Marginatum	Sydenham's chorea

LOGIN FOR SUCCESS

Minor Manifestation (Pneumonic -FEAP)

- Fever
- Raised ESR
- Arthralgia
- Prolonged PR interval

AfraTafreeh.com

For Diagnosis

- 2 major

  Or

- 1 major +2 minor with features of pre-existent streptococcal infection

Fig 1

- Migratory polyarthritis of large joints
- M/C involved are large joints of the extremities
- Migratory involvement or flitting nature is characteristic

Subcutaneous Nodules

- Small, pea sized, painless nodules over bony prominences
- Common sites -Extensor tendons of hands & feet, elbows
- Skin over them is not inflamed

Fig 2

Erythema Marginatum

- Erythematous rashes with a clear center and round or serpiginous margins
- Transient, Migratory, non-pruritic, and blanch on pressure
- Most commonly seen on the trunk and proximal parts of extremities, but never on face

AfraTafreeh.com

Fig 3

TUTORIALS LOGIN FOR SUCCESS

AfraTafreeh.com

sydenham's chorea

- movement disorder
- described as rapid,irregular,aimless and involuntary
- affect the muscles in the limbs,face and trunk
- girls > boys
- 25% – develop chronic rheumatic valve disease

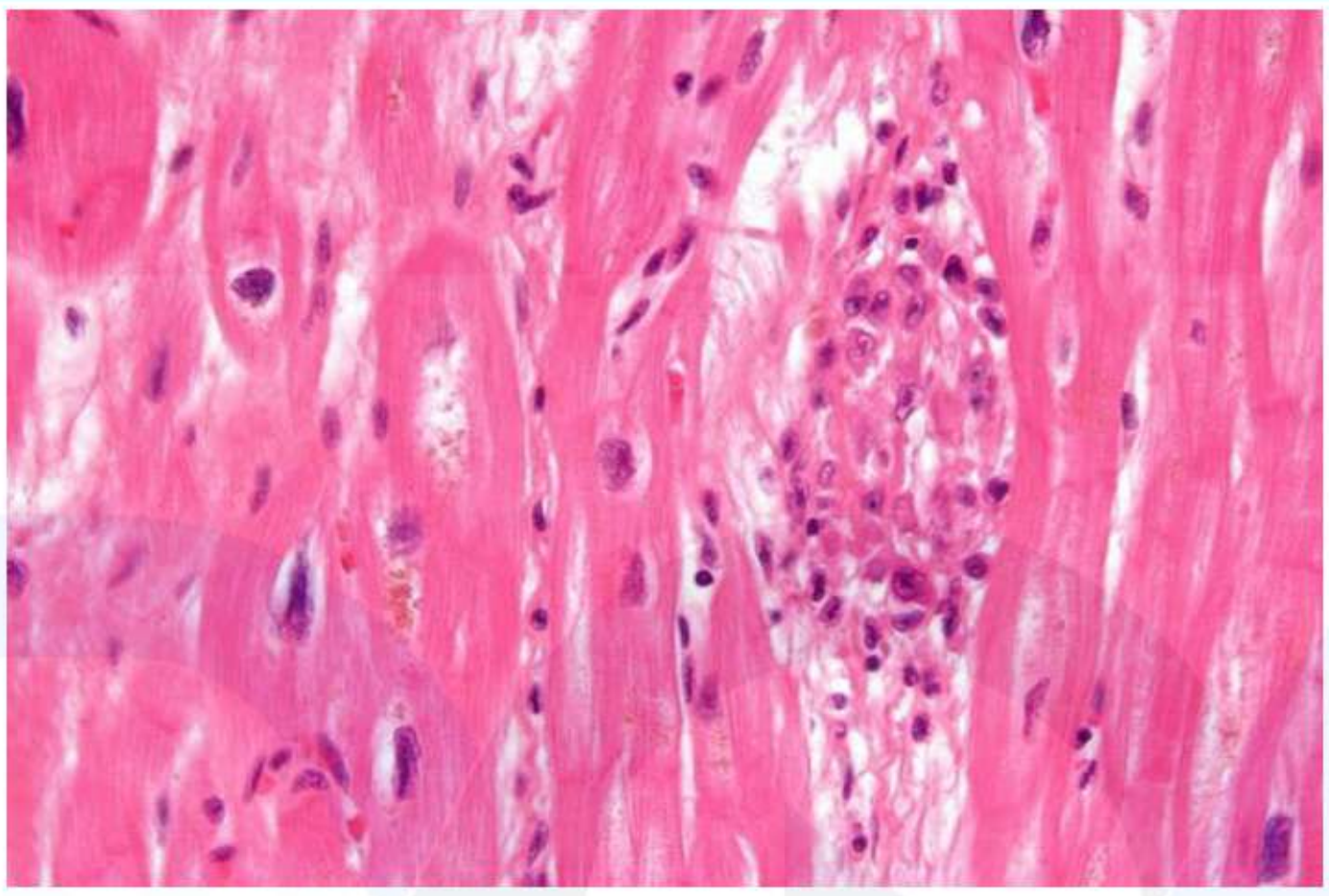

Aschoff Body

Fig 4

Hallmark of RHD

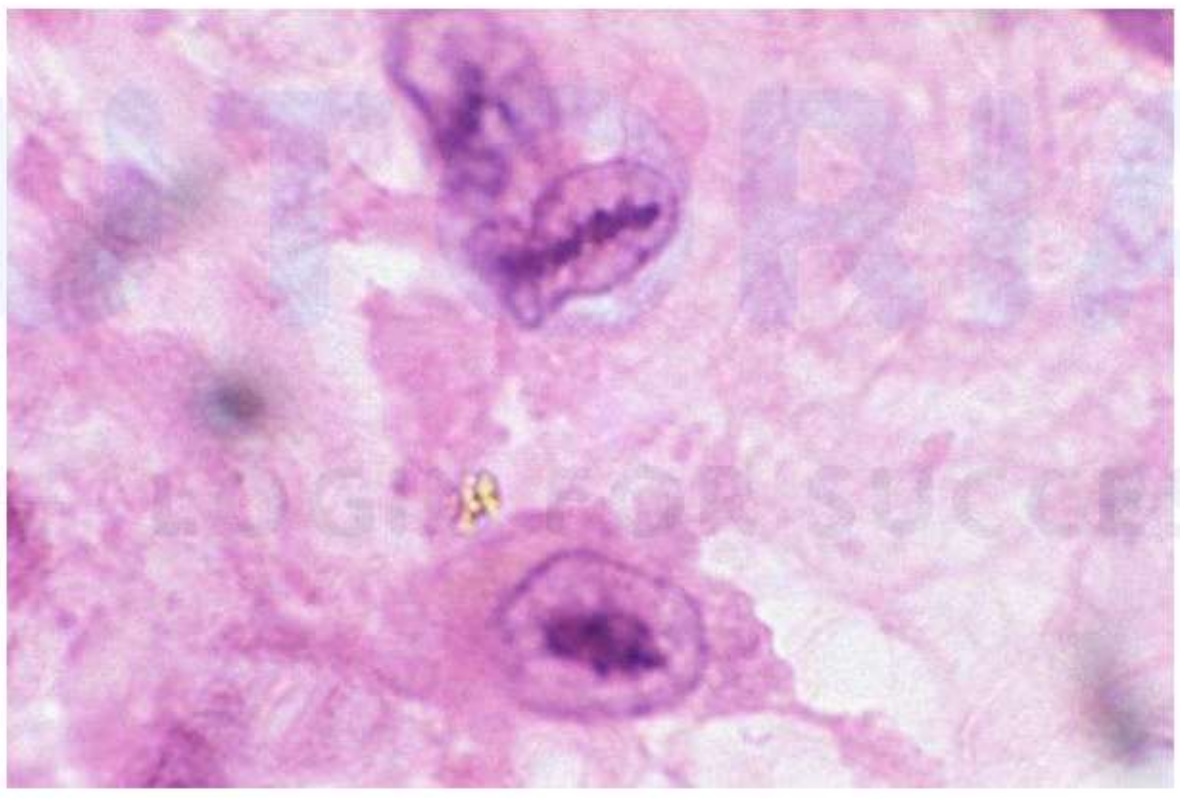

Fig 5

Hallmark of RHD

- Anitschkow cells showing caterpillar chromatin
- On Transverse section –OWL eye Appearance of nucleus

- Remember -OWL eye inclusion – CMV infection

OWL eye Nuclei:

i. Hodgkin's Lymphoma

ii. Transvers section of anitschkow cell

Manifestations of Rheumatic Heart disease

00:24:53

PANCARDITIS

Endocardium	Myocardium	Pericardium
i. Asch off Nodules +	Asch off Nodules + +	Asch off Nodules+
	(M/C seen in Myocardium Near The blood vessels)	

ii. Verrucae pathogenesis → Activation of platelets & fibrin

- Damage to endocardium Platelets +fibrin deposition

iii. Degeneration of collagen / swollen collagen

↓

Formation of warty vegetation

AnaTafreeh.com

AfraTafreeh.com

- Warty vegetation along the lines of closure of valves

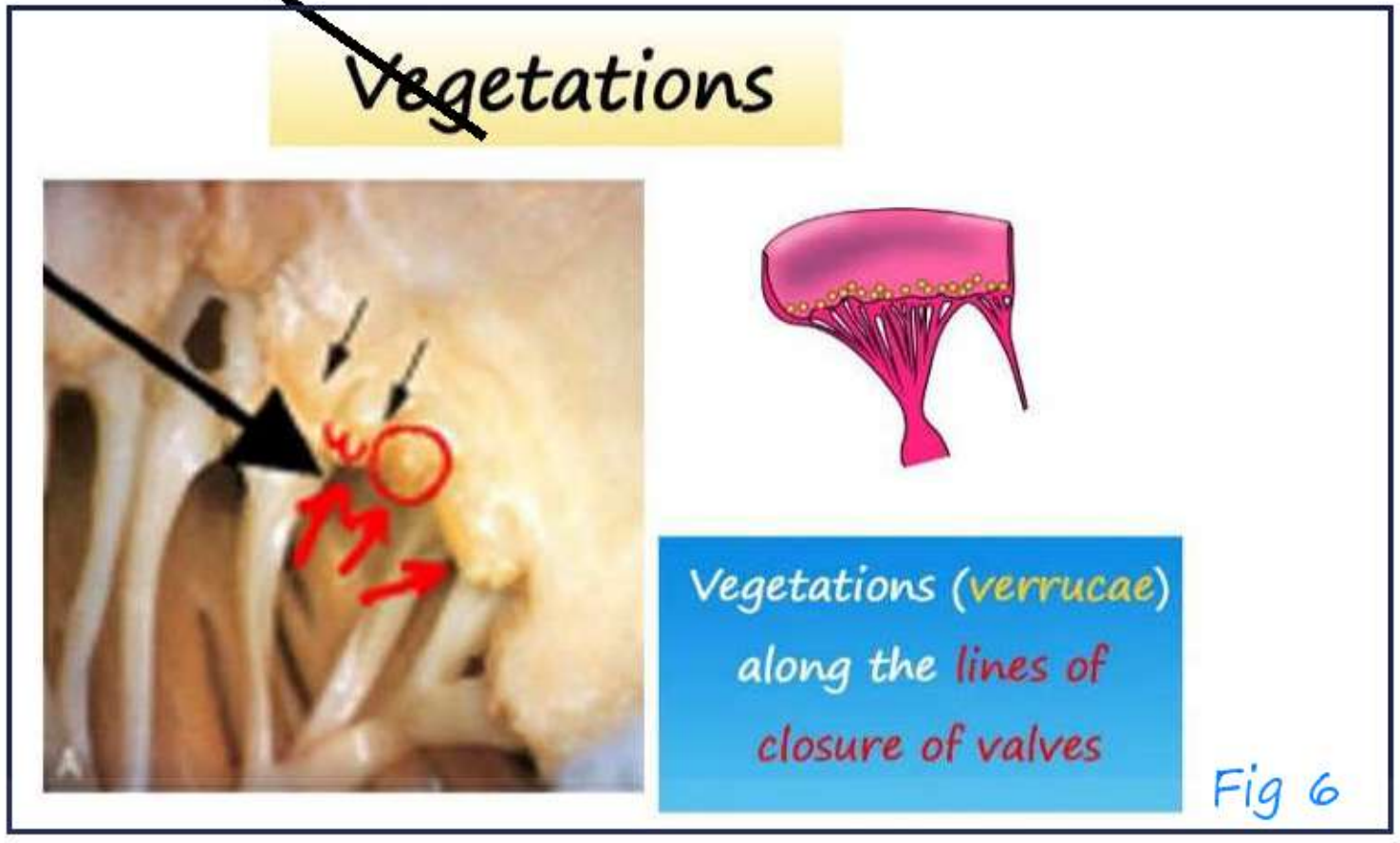

Fig 6

Myocarditis

- Asch off Nodules near BV

↓

Myocarditis

↓

Cardiac Failure

(Causes of Death)

Pericarditis

- Fibrinous pericarditis

Fibrin depiction between 2 layers of pericardium called as bread & butter pericarditis

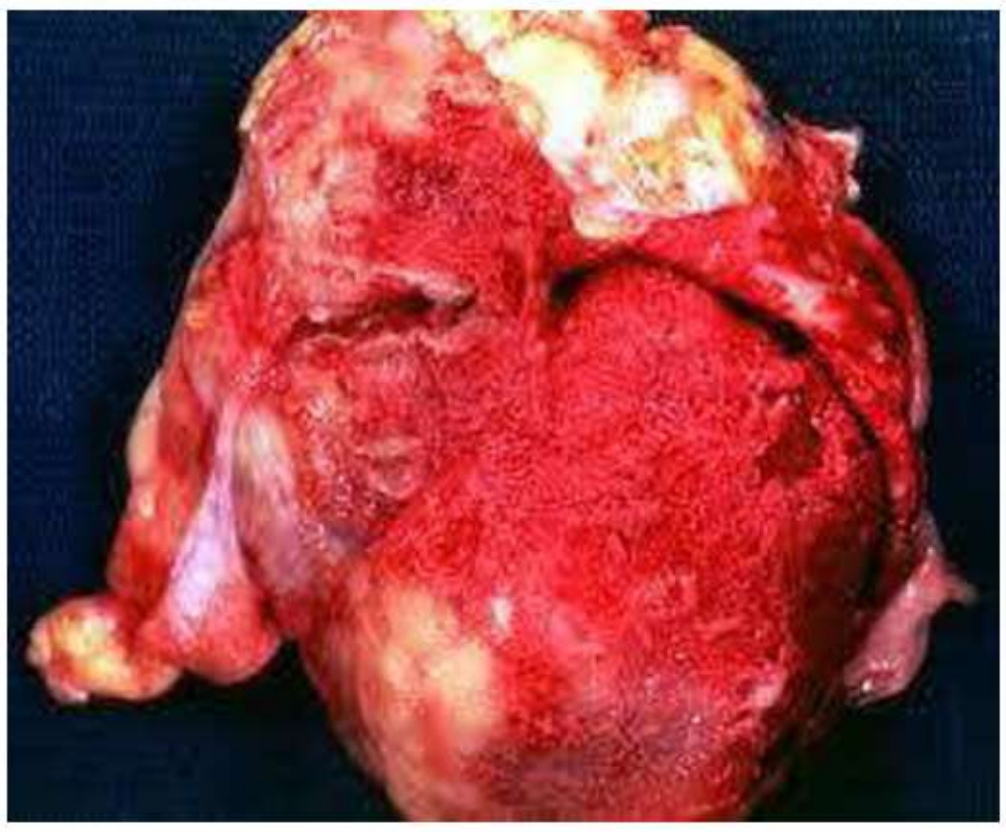
Bread & Butter Pericarditis Fig 7

Manifestation of Chronic RHD 00:30:19

Characterized by fibrosis

Fibrosis of valves

i. Leaflet Thickening
ii. Fusion of commissures
iii. Shortening chordae tendinea

↓

Fish Mouth Deformitve of Valve

Mac Callum patch

- Mitral regurgitation causes a roughened patch on the wall of left atria posterior called Mac- Callum Patch
- A Frequent site of Mural Thrombus

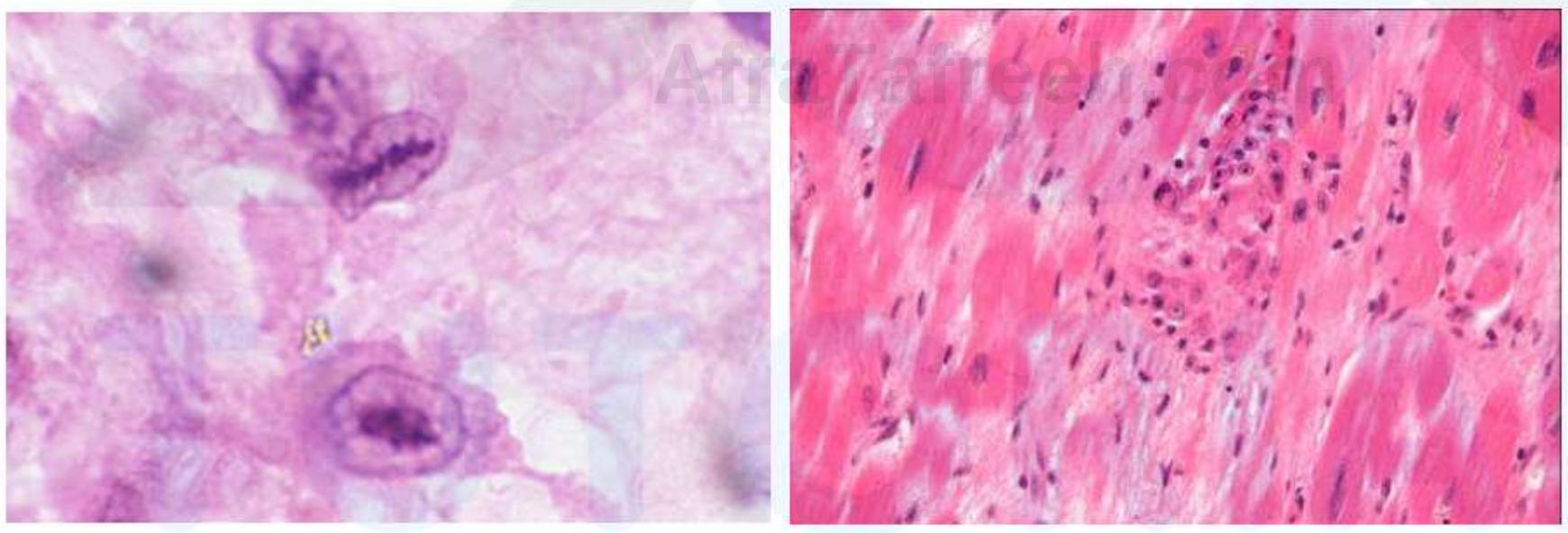

Fig 8

- Mac Callum patch
- Thinned chordae tendinea

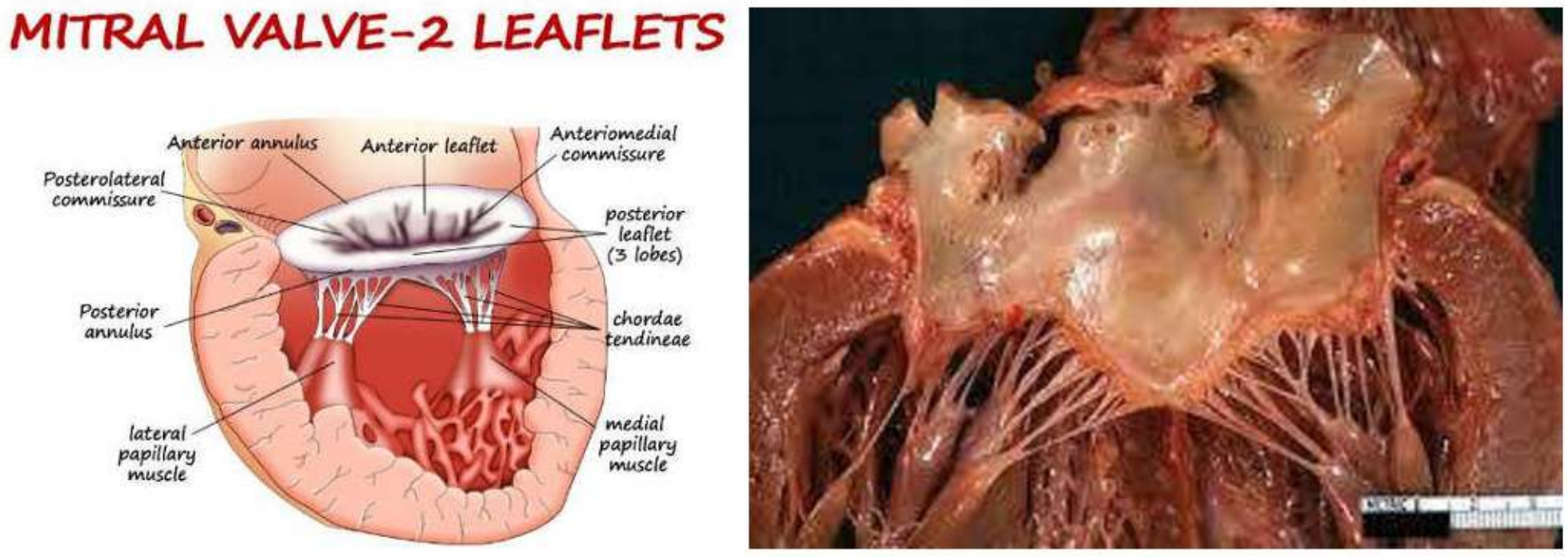

Fig 9

AfraTafreeh.com

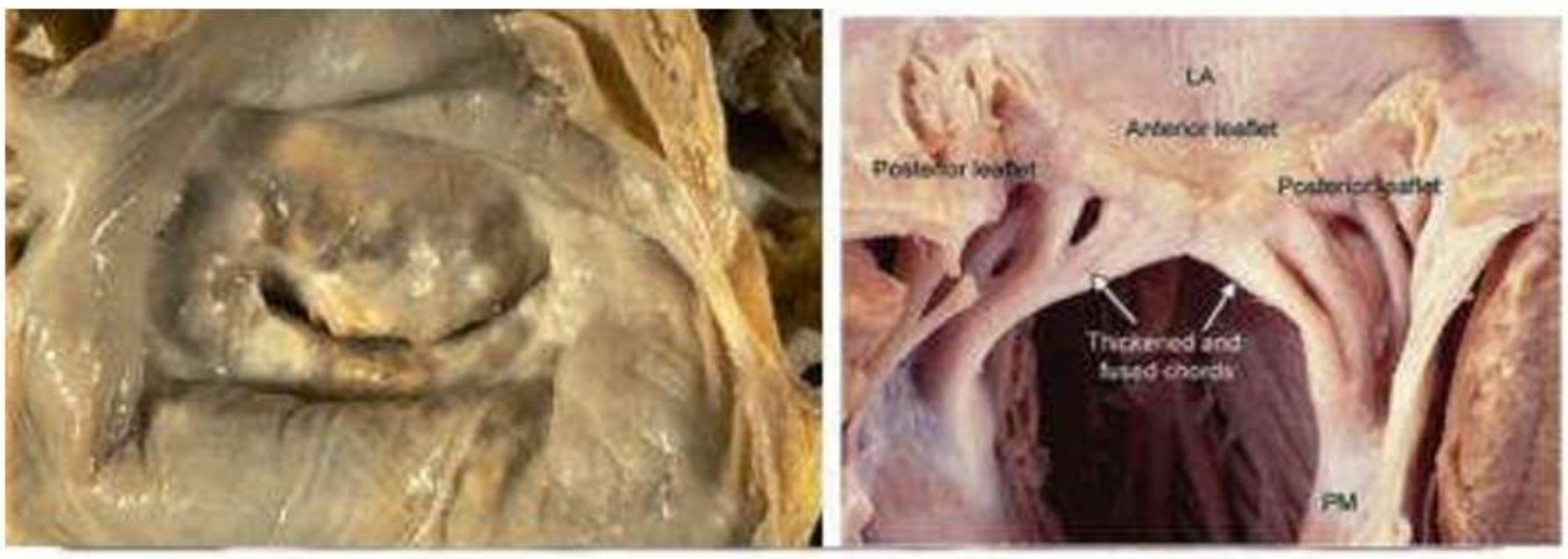

MITRAL STENOSIS WITH DIFFUSE THICKENING AND DISTORTION OF VALVES

THICKENED CHORDAE TENDINAE

Fig 10

TUTORIALS
LOGIN FOR SUCCESS

MYOCARDIAL INFARCTION

Myocardial Infarction

Transmural infarction
- When > 75% of coronary Arteries blocked especially LAD
- Apex – commonly Affected
- ST Elevation

Subendocardial
- occurs due to
- Occurs due to Plaque Disruption
- NSTEMI

Multifocal Infarction
- Infarction at multiple areas

↓

- progresses into Takatsubo cardio-myopathy

- Subendocardial
  - Most Prone to Ischemia
  - Infarction follows plaque disruption

AfraTafreeh.com
TUTORIALS

Diagnosis of MI LOGIN FOR SUCCESS 00:03:43

Diagnosis of MI

Cardiac makers
- Earliest to Rise – Myoglobin

Biopsy /Autopsy
- Reversible injury Seen on E/M till ≤ 30 min

CK-MB

AfraTafreeh.com

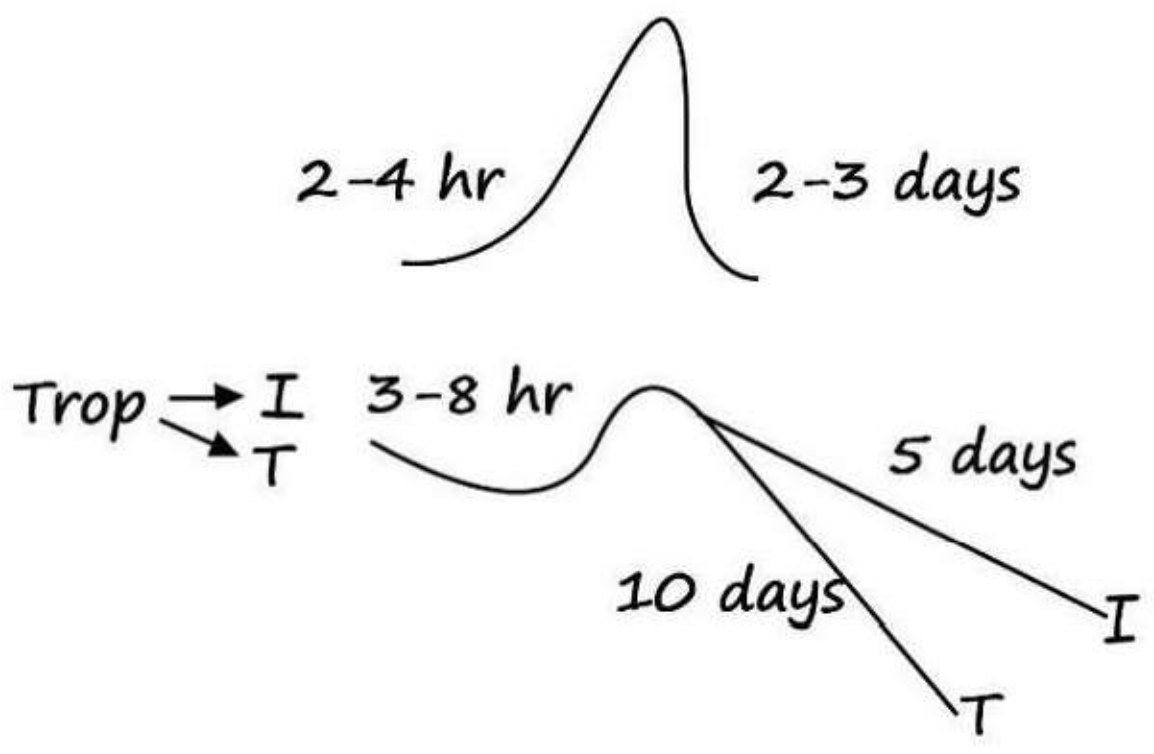

Waviness of
Myocardial fibers
Myocytolysis
↓
Hydropic change
around myocardia
fiber's

Flipping of LDH

- Normally ≥ LDH 2 LDH1
  In MI LDH1 ≥ LDH2
- SGOT elevated

Biopsy/Autopsy findings 00:06:42

< 30mins-Reverisble change

> 30mins-Irreverisble change

30mins- 4hours: Waviness of myocardial cells

4-12 hrs	- Coagulative Necrosis - On gross-dark mottling
12-24 hrs	- Neutrophils Infiltrate - Myocyte Hyper eosinophilia
1 to 3 days	- Contraction band Necrosis - Maximum Neutrophil (Abscess)

3 to 7 days	- Gross-Yellow Tan infarct center - Macrophages appear
7 to 10 days	- Gross – Hyperemic border - Granulation Tissue appears
10 to 14 days	- Gross – Hyperemic border - Max Granulation Tissue appears
2wk	- Scarring Starts
2m	- Completion of scarring

AfraTafreeh.com

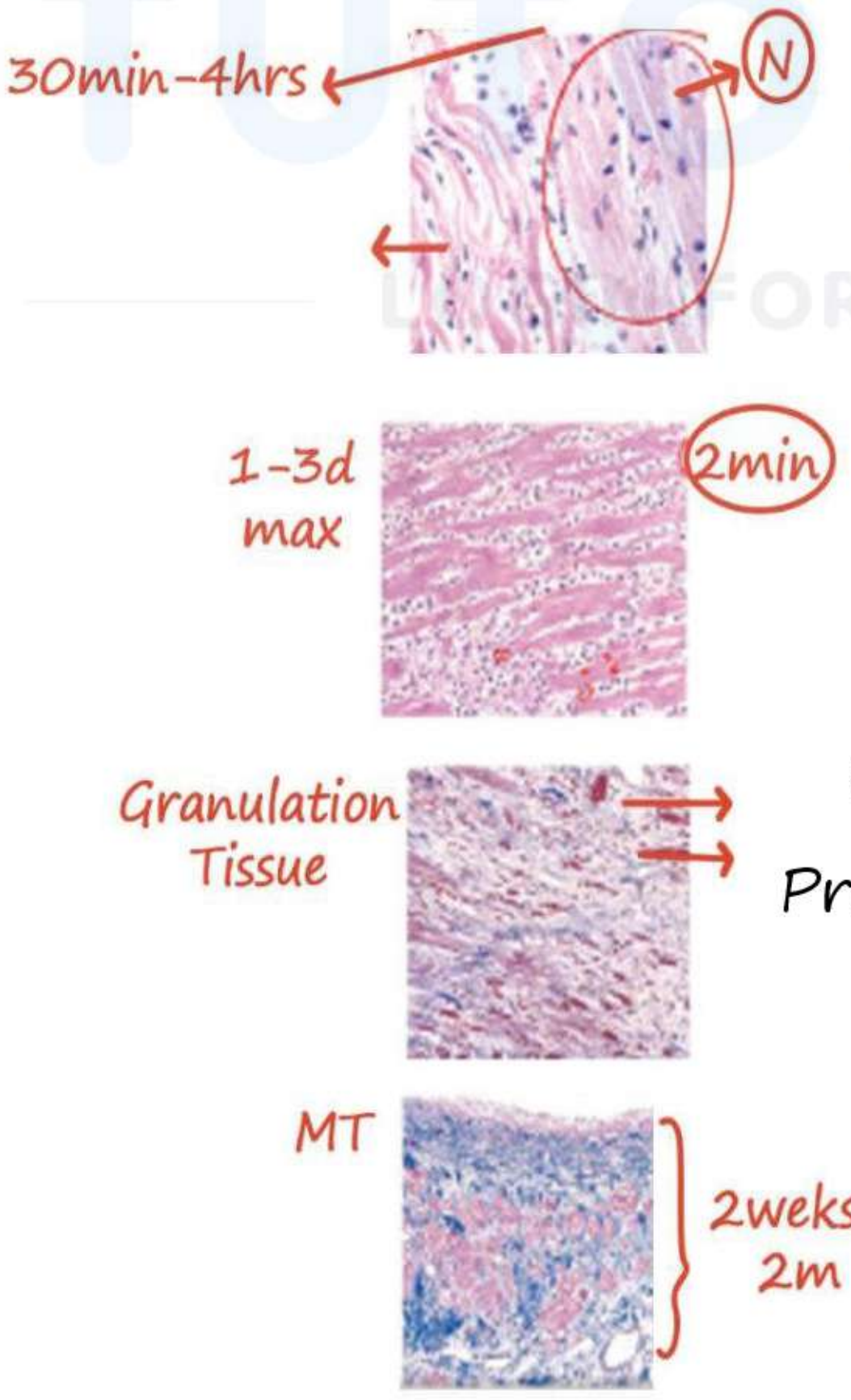

Earliest finding – Waviness

30mins-4hours

Neutrophilic infiltration

Granulation Tissue – Proliferating blood vessels

Masson's Trachoma depicting collagen in scar

Fig: 1

AfraTafreeh.com

Evolution of Morphological changes in MI

Time	Gross	Light Microscopy	Electron Microscopy
Reversible injury 0-30 min.	None	None	• Relaxation of myofibrils • Glycogen loss • Mitochondrial swelling
Irreversible injury			
30 min – 4 hr	None	Waviness of fibers at border (earliest microscopic change	• Sarcolemmal disruption • Mitochondrial amorphous densities
4 – 12 hr	Dark mottling appears	Beginning of coagulative necrosis	
12 – 24 hr	Dark mottling	• Neutrophilic infiltration • Myocyte hypereosin-ophilia • Marginal contraction	

		band necrosis	
1 – 3 days	Yellow tan infarct center	Brisk interstitial infiltrate of neutrophilis	
3-7 days	Hyperemic borders, central yellow tan softening	Marcophages at infarct border	
7 – 10 days	Maximum yellow tan	Early formation of fibrovascular granulation tissue at margins	
10 – 14 days	Red gray infarct border	Well established granulation tissue collagen deposition	
2 – 8 weeks	Gray white scar	Collagen deposition	

Afraidofsoul.com
TUTORIALS
LOGIN FOR SUCCESS

AfraTafreeh.com

> 2 months	Scorring complete	Dense collagenous scar	

TTC Triphenyl – Tetrazolium chloride stain

- TTC Stain binds to LDH giving → Manage colour / → Brick Red colour

Reversible injury	Irreversible injury
LDH LDH LDH LDH	Eg MI •LDH •LDH
- LDH within the cell - Stain Positivity with TTC	Membrane Disruption - Loss of LDH ↓ - No Staining by TTC - Pale heart ↓ - Infracted Heart - Old infarcts appear glistening white - New infarcts appear Pale

	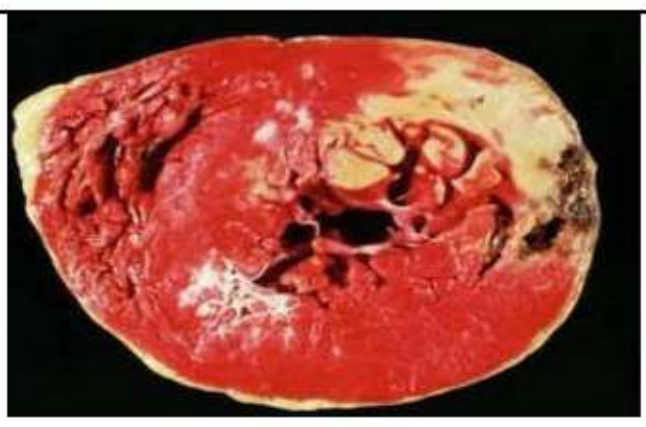

TTC Results start appearing by 4 hours of Infarction

REPEREVSION

Free Radicals ↓ Cause stunned myocardium ↓ (Transient ischemia)	Calcium ↓ Causes Hypercontraction of heart ↓ Formation of contraction bands

AfraTafreeh.com

Triphenyltetrazolium chloride, an enzyme substrate that colors viable myocardium magenta failure to stain is due to enzyme loss after cell death

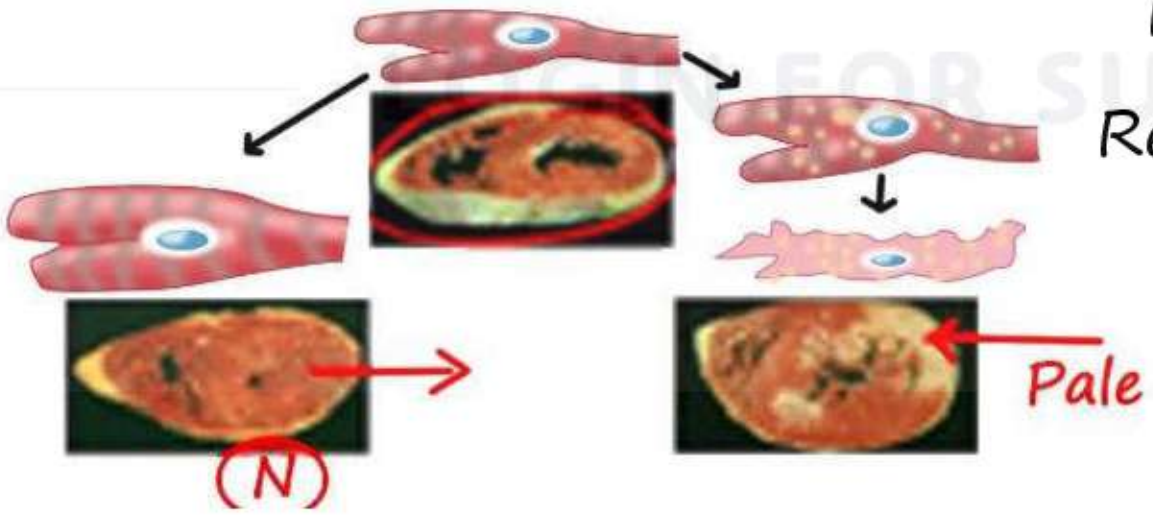

Red infarct in Reperfused heart

Fig: 2

Reperfused

Contraction Bands- Sign of Increased Calcium in Myocardial fibrosis

Fig: 3

AfraTafreeh.com

Stunned Myocardium	Hibernating Myocardium
- Occurs if coronary Blood flow was impaired for a brief period of 5-15 minutes	- Exposure to Chronic, sublethal ischemia
- State of Prolonged Cardiac Failure induced by transient ischemia	- Myocardium enters into a state of lowered metabolism and function called Hibernation
- Recovers after several days	- Reversible with Revascularization
- May follow Reperfusion injury	

TUTORIALS
LOGIN FOR SUCCESS

Complication of MI 00:29:27

Mnemonic: **ACT RAPID**

i. Arrythmia

< 1hr → > 1hr (SVT)

1.Vascular Tachycardia

2.Contractile Dysfunction – causes Cardiogenic Shock

3.Thrombus (Mural)

4.Rupture – Of Free wall (3rd to 7th day after MI)

- Usually, Anterolateral wall of left ventricle especially at mid-ventricular level

5. Aneurysm – Pseudoaneurysm
6. Pericarditis
   - Post MI Pericarditis called as Dressler Syndrome Autoimmune
   - Either at 1-3 day of Mi or 1-3 week of MI
7. Infarct Expansion
8. Dysfunction – papillary muscle Dysfunction

AfraTafreeh.com
TUTORIALS
LOGIN FOR SUCCESS

AfraTafreeh.com

ANTI COAGULANTS AND VACUTAINERS

Vacutainers 00:00:05

- Vaccine's containers prefilled with anticoagulant

EDTA containers: purple color vial

- Used for routine blood tests
- Dipotassium salt – 1.5-2.2 mg/ml
- Chelates calcium molecules

CBC – Hb, TLC
PS
ESR determination by wintrobes methods
Reticulocyte counts

Fig: 1

Sodium fluoride (N_aF) container: grey vial

- Used for blood sugar estimation
- Inhibits enolase enzyme in glycolysis
- Specimens are pressured at 25° c for 24 hrs & 4° C for 48 hrs

Fig: 2

Heparin container: green vial

- 0.2 mg /ml of blood
- Anticoagulant of choice for – osmotic fragility test
  - Flow cytometry
  - Blood gas analysis
- Sample in heparin is viable for 48 hrs
- Peripheral smear with blood from heparin container will give a blue discoloration to the slide

Fig: 3

Trisodium citrate: blue vial

- 3.2 – 3.8 g/dl
- Conc. 1.9 – coagulation tests
- Conc. 1.4 – ESR by westergren method

Fig: 4

Serum vial: red vial

- Used for biochemical assays
- Clot activation get can be used for quick testing

TUTORIALS
LOGIN FOR SUCCESS

AfraTafreeh.com

Fig: 5

Dipotassium EDTA: pink vial

- Only for blood bank, to easily differentiate from hematology specimens



Fig: 6

Order of collection 00:10:15

- Samples for culture
- Trisodium citrate for coagulation
- Serum vial
- Heparin tube
- CNC- EDTA tube
- Glycolytic inhibitor- blood sugar testing

Fig: 7

Anticoagulants used in blood bank 00:12:00

- Acid-citrate -dextrose sol (ACD) – 21 days
- Citrate – phosphate-dextrose sol (CPD) – 28 days
- Citrate- phosphate-dextrose – dextrose sol – 21 days

- Citrate- phosphate – dextrose- adenine sol (CPDA) – 35 days
- SAGM – blood bag additive – 42 days
  ↓
  Mannitol

Action of ingredients of anticoagulant solution

00:14:00

- Dextrose- supports ATP generation by glycolytic pathway
- Citrate – chelates calcium
- Sodium diphosphate – prevents fall in pH
- Adenine- synthesizes ATP, increase shelf life of red cells

AfraTafreeh.com
TUTORIALS
LOGIN FOR SUCCESS

Black vial:

Fig: 8

- Only for ESR by westergren
- Na citrate 1:4
- 3.8 % of sodium citrate

→All coagulation tests must be completed within 2 hrs of starting of blood collection

AfraTafreeh.com

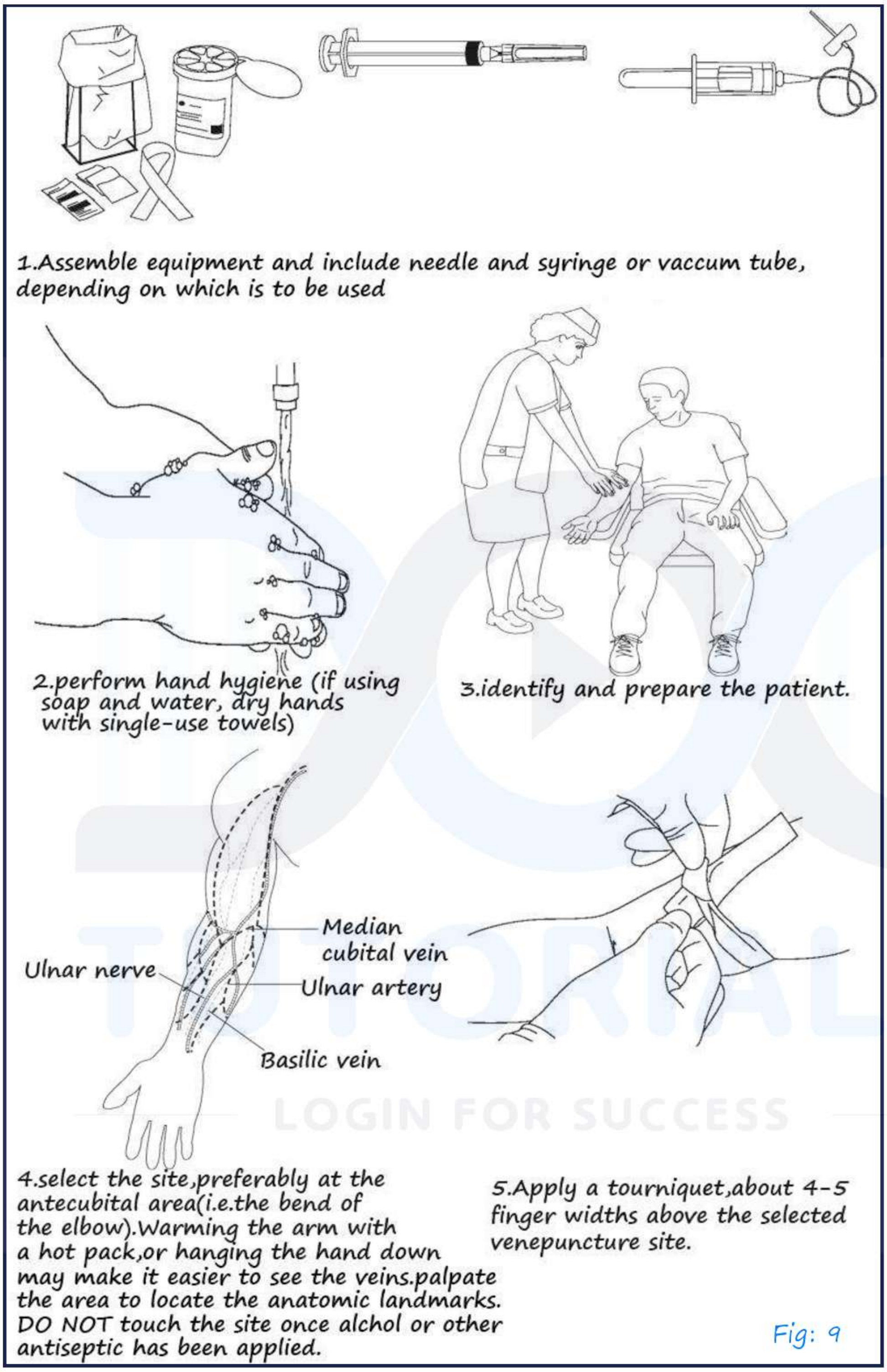

Fig: 9

Steps:

- Assemble equipment
- Perform hand
- Identity and prepare patient

- Select site
- Apply tourniquet
- Ask patient to form a first
- Put on well-fitting nonsterile gloves
- Disinfect site using 70% isopropyl alcohol allow it to dry
- Anchor the vein
- Euter the vein swiftly at a 30° angle
- Released the tourniquets
- Withdraw the needle
- Discard the needle in puncture proof containers
- Check label's & forms for accuracy
- Discard shapes and glass
- Remove gloves place them in general enousite

TUTORIALS
LOGIN FOR SUCCESS

AfraTafreeh.com

INTRODUCTION OF WBC

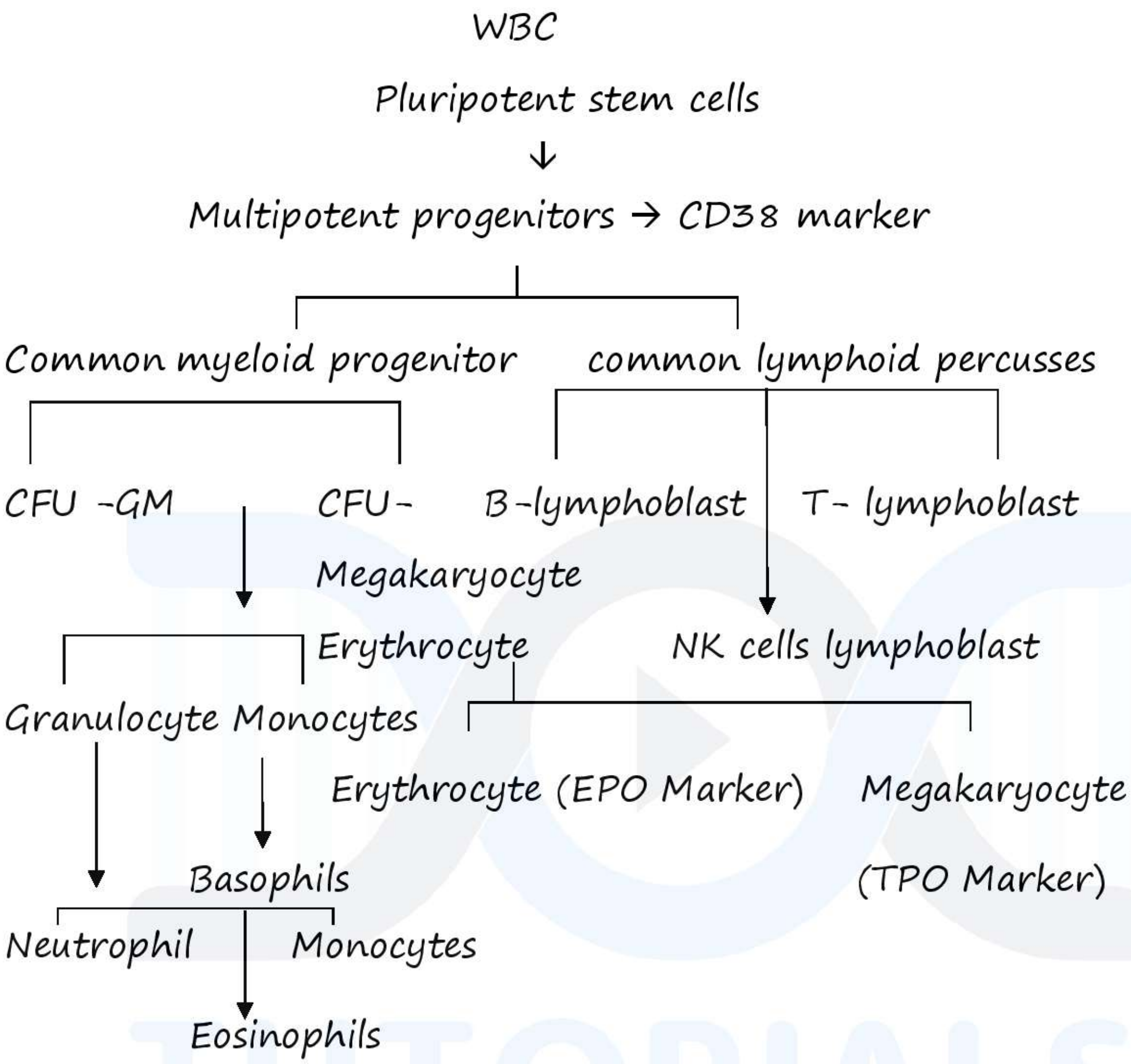

Stem cells of 3 types

- Totipotent stem cells -give rise to entire body
  Eg: Blastocyst
- Pluripotent -gives night to different lineage
  Eg: Hematopoietic
- Multipotent – give nine to one lineage.
- Pluripotent stem cells marker
- C 34
- CD 133
- AIDH

Collection stem cells

- Liver site of Hematopoiesis
  i. peripheral stem collection done by administering granulocyte - colony stimulating factor [G-CSF]
  ii. Umbilical cord Blood
- Embryogenesis of Hematopoiesis

1st to 3 months

i. Embryo - Hematopoiesis occur in yolk sac(temporary)
ii. Definitive Hematopoiesis in embryo occur is Aorta, Gonadal, mesonephros

After 3 months

- Liver site of Hematopoiesis

AfroTafreeh.com
TUTORIALS
LOGIN FOR SUCCESS

4th month

i. It shifts from lover to bone marrow
ii. Some haemopoietic stem cells via placenta got to umbilical
Cord

4th month to puberty

- All bone narrow is activity

After puberty

- Only bone marrow of axial skeleton is active
Hematopoiesis in embryo begins at 3 weeks

AfraTafreeh.com

Recent update

- CD !50
- It is used in stem cell transplant
- It check whether the yield of stem cells is good, and proliferating

  After transplant T lymphocyte development is dependent on NOTCH

  Pathway /IL-7

  B- Lymphocyte development is dependent on PAX pathway

  IL-15 is very important for NK cells

Myeloid lineage markers

Granulocyte	Monocytic	Erythroid	Megakaryocyte
MPO	CD 11c	CD 71	CD 41
CD 13	CD 14	Transferrin	CD
42		receptor	CD 61

- MPO most specific marker of Granulocyte lineage

Lymphoid lineage Markers

T cell	B cell	NK cell
CD 3	CD-19	CD16
[pan T cell	[Pan B cell	
marker]	marker]	
CD1	CD 79a	
CD2	CD 20	

CD3 CD 21

CD4 CD 22

CD5

CD6

CD7

CD8

CD 28

- Lymphoblasts marker is Td T [terminal deoxynucleotidyl transferase]
- Myeloblast & Monoblast positive is HLADR
- PAX S is as marker o B lymphocyte lineage, it is marker of immunity.

AfraTafreeh.com
TUTORIALS
LOGIN FOR SUCCESS

AfraTafreeh.com

IMAGES OF MATURE WHITE BLOOD CELLS

Neutrophils 00:00:05

- Cells have characteristic deme nuclear consisting of 3 - 5 lobes &
- Pale cytoplasm – containing fine pink- blue (azurophilic) granules
- Hyper segmented Neutrophils → 3 5 of neutrophils have more than 5 lobes or 1 neutrophil having more than 6 lobes
- Hyper segmented neutrophils seen in
  a. Vit B12 deficiency
  b. Myelodysplastic syndrome
  c. Post chemotherapy, post radiotherapy
- Bilobed neutrophils? Deceased nuclear segmentation neutrophils → pelger – Huet anomaly

Pelger Huet Anomaly
- Time
- Pseudo
  Acquired seen in chronic myeloid leukemia myelodysplastic syndrome

Dohle Bodies 00:04:15

- Seen in neutrophils
- Periphery of cytoplasm
- There are dilated endoplasm reticulum

- It is seen in infections

-May hegglin anomaly
-MyH9 Mutation
Three characteristic features
a)Dohle Bodies like inclusion
b)Giant platelets
c)Thrombocytopenia

- Prominent azurophilic granules in neutrophils → Toxic granules it is seen in sepsis. Alder – Reilly Anomaly
- Presence of longer than normal azurophil & basophil granules
  (Alder Reilly it is seen in mucopolysaccharidosis Bodies)

AfraTafreeh.com

Many small Granules	In Neutrophil Moderate	Large granules
↓	↓	↓
Toxic granules	Alder Reilly Bodies	chedi AK hiaashi syndrome

TUTORIALS
LOGIN FOR SUCCESS

Vacuoles in WBC

i. Jordan Anomaly
   - Familia vacuolization of leucocytes
   - Presence of vacuoles in the

ii. Severe infection

iii. Heavy chain disease

AfraTafreeh.com

Eosinophils 00:13:10

- Normal – 5- 500 cells /mms
- Cells are similar to neutrophil, except that the cytoplasmic granules are more deeply red staining & having two nuclear lobes mostly

Causes of eosinophilia

i. Allergic diseases
ii. Parasitic diseases
iii. Langerhans cells histiocytosis
iv. Hodgkin's lymphoma
v. Chronic eosinophilic lymphoma
vi. Healing Appendicitis – Eosinophils are the predominant cells

Basophils 00:14:44

- Normal – 10-100 cell s/mm2
- Cells have dark cytoplasmic of granules which overline the nucleus & Heparin & histamine

Basophils causes

i. Hypothyroidism
ii. Chronic Myeloid leukemia
iii. Polycythemia vera
iv. Myelofibrosis

TUTORIALS LOGIN FOR SUCCESS

Images of Mature White Blood Cells

Monocytes 00:16:16

- Normal 200-1000 cells /mm3
- Largest leucocyte in peripheral bold & possess basophilic cytoplasm
- Causes of Mon cytosis
- Chronic myelomonocytic leukemia
- Surveille Myelomonocytic leukemia

> Epstein Barr virus causes infectious mononucleosis.
> CD8 T cells
> In IM are called Downey cell which resemble monocytes Downey cells
> Are called ballerina cells

AfraTafreeh.com
TUTORIALS
LOGIN FOR SUCCESS

Lymphocytes 00:18:00

- Normal count 1500 – 3000 cells /mm3
- Small cells with nucleus having condensed chromatin & a small

A small amount of pole basophilic cytoplasm acid phosphates

Stain –It's called polar stain

–It stain 'T' lymphocytes

Plasma cells 00:19:42

- Eccentrically placed nucleus having a perinuclear Hoff
- On High power– Chromatin visualized it has a CART WHEEl /CLOCK FACE CHROMATIN

AfraTafreeh.com

Increased plasma cells causes

i. Chronic infection & inflammation – HIV, rheumatoid arthritis

ii. Multiple myeloma

PUNCHED OUT LESION IN THE SKULL
- → ↑ increase plasma cell → multiple
- → ↑ Langerhans cells [Groove cells] → Langerhans cells

Mast cells 00:23:35

- Basophils infiltrate tissue 7 turn into mast cells
- Mostly found in blood vessel

Increased mast cells

- In skin – Urticaria Pigmentosa
- Increased in choric infection& inflammation
- Special stain of mast cell s – TOLUDINE BLUE
- Marker of MAST CELLS –Cd 203c

BASICS UNDERSTANDING OF LEUKEMIA & LYMPHOMA & PATHOGENESIS OF ACUTE LEUKEMIA

Basic understanding of leukemia & lymphoma

i. Leukemia – Proliferation of Atypical Blood cells in Bone Marrow
and released in periphery

ii. Lymphoma – proliferation of Atypical Blood cells in solid organs

Types of leukemia
- Myeloid leukemia
- Lymphoid leukemia

AfraTafreeh.com
TUTORIALS
LOGIN FOR SUCCESS

Types of lymphoma
- Hodgkin's
- Non-Hodgkin's

Acute Leukemia	Chronic Leukemia
- Blast >20% - Mutation -Block in differentiation saturation of cells	- Blasts < 5% - Mutation → increased proliferation of cells

AfraTafreeh.com

Acute leukemia

AML	ALL
Acute Myeloid Leukemia	Acute Lymphoblastic leukemia

i. ALL [Acute lymphoblastic leukemia]

- Molecular pathogenesis T Number of chromosome
  - a. Hyper diploid -Most common cryptogenic change
    - good prognosis
  - b. Hypodiploidy - P53 Mutation
    - poor prognosis
  - c. Trisomy 4,7,10 -good prognosis

ii. Translocations

i. T (12,21) – ETV6 – RVNXI– very important gene for Maturation

Of myeloid & Lymphoid

-associated with good prognosis

ii. t (9, 22) - BCR – ABL Protein

-190 KDA size

- poor prognosis

iii. (v, !!) - variant 11

- MLL! (Histone methyl transformation
- It causes condensation of chromate &

Blocks Maturation

- Very poor prognosis

Provisional Classification of All 00:21:56

i. IAMP21

- Typical associated with chronotherapies (shattering of chromosome)

ii. BCR- ABL like ALL

- Acute Myeloid Leukemia molecular Pathogenesis

i. Recurrent genetic translocation

- T (8,21)- gene present RUNXI -RUNXI TI
- Inv 16 – code Binding Factor B Myelin bund [CBFB-MyH11]
- T915,17) → PML – RAR a- activate
  → Mutation occurs at level of promyelocytes

AfraTafreeh.com

Acute promyelocytic leukemia Mutuums
- T (15, !7) – most common (90%)
- T (11,17) – Zinc Finger [PMZF-RAR a]
- T 915,17) → NPM -RAR a

- If there three Mutation is T (8,21), inv(16),t(15,17) if anyone Present → diagnosis of AML without Requirement of 20% Blasts

AfraTafreeh.com

ii. Other Mutations of AML

- MLL1
  - Poor prognosis
  - Infantile Leukemia's
- NPM
  - Nucleon phosphoric mutation
  - Good prognosis
- Balletic CEBP

Provisional classification of AML 00:38:55

- T (BCR-ABL)
- AML with RUNX1

New categories of AML According to WHO

- AML with germline prescription GATA Mutation
- Cohesion complex Mutation

TUTORIALS LOGIN FOR SUCCESS

CLASSIFICATION & CLINICAL FEATURES OF ACUTE LYMPHOBLSTIC LEUKEMIA

Classification of Acute leukemia's 00:00:05

i. FAB classification
   - Based upon morphology
ii. Who classification
   - Based upon prognosis

Classification of Acute leukemia's

- In ALL, Blasts wont more than 25% blasts morphology
  (Lymphoblast)
- Size -2-3 times bigger than lymphocytes increased N/C ratio
- Slant Agra nuclear cytoplasm
- Hard mirror cells Lymphoblast with slightly leaked cytoplast

AfraTafreeh.com
TUTORIALS
LOGIN FOR SUCCESS

FAB classification of ALL 00:02:39

a. L1
b. L2
c. L3

i. L1 Type of Blasts
   - Homogenous Blasts Good prognosis
ii. L2 Type of Blasts

AfraTafreeh.com

- Heterogeneous Blasts

iii. L3 Type of Blasts

- cytoplasm shows vacuolization, vacuoles positive For oil red stain
- L3 Type of Blasts now classified under Burkitt's lymphoma

2018 WHO classification ALL

Hypodiploidy	t (12,21)
4,7,10 Trisomy	t (9,22)
Hypodiploidy	t (v,11)

- Good prognosis — Hypodiploidy's
  4,7,10 Trisomy
  T (12,21)
- Bad prognosis — Hypodiploidy's
  t (9,22)
  t (v,11)
- Best pragmatic factor — Response to Therapy

Special stain for Lymphoblast 00:17:18

i. PAS stain –it appears as DOT & BLOT positivity

TUTORIALS
LOGIN FOR SUCCESS

Clinical features of ALL 00:19:26

- Child 2-5 years

i. Fatigue due to anemia

ii. In felonies caused by neutropenic

iii. Bleeding form ums due thrombose osteopenia

iv. Bone pain and Tendinosis due to bone marrow Expansion by infiltration

v. CNS involvement due to meningeal spread

- Due to early CNS involvement CSF sampling in mandatory& intrathecal chemotherapy is given

vi. Testes involvement is common, home mala have poor prognosis

vii. Generalized, Lymphadenopathy, splenomegaly's, hepatomegaly due to neoplastic infiltration

AfraTafreeh.com

T- ALL

- It occurs in adducent (13-17)
- It presents with mediastinal mass

B- ALL

- Most common Type Younger age group (2-5 years) Presents as Lymphadenopathy
- Diagnosis of choice of ALL – Flow cytometry

AfraTafreeh.com

Prognosis Factors

Comtesse	Good	Bad
Age	2-10 years	< 2 years,>10
Gender	female	years
Race	white	Male
CNS involvement	absent	Black
Testicular		present
involvement		
Cytogenetic'	Hypodiploidy's	
WBL want	Trisomy	Hypodiploidy
immunophenotype	4,7,10	t (8:!4)
gen	t (9,12)	t (9:22)
	t(12,220<	>1,00.,000
	1,00,000	Pre B- ALL
	Early pre B-	T-ALL
	ALL	Mature
		B-ALL

Update

- B-ALL → Loss of function mutation of PAX-3
- T-ALL → Gain of function mutation of NOTCH gene

ACUTE MYELOID LEUKEMIA

FAB classification 00:00:05

Embryology

Common myeloid percussion

- Eruthroid
  - Proerythroblast ↓ Normoblast ↓ Reticulocyte ↓ RBC
  - Megakaryoblast ↓ megakaryocyte ↓ platelets
- Granulocyte Precursor ↓ Myeloblast ↓ Promyelocyte ↓ Myelocyte ↓ Metamyelocyte ↓ Stable band cells ↓ Neutrophils, eosinophils, basophils
- Megakaryoblast ↓ Megakaryocyte
- Monocyte Presession ↓ Promyelocyte ↓ Monocyte

AfraTafreeh.com
TUTORIALS
LOGIN FOR SUCCESS

AML types

- AML -7 -> megakaryoblast arrest
- AML – 6-> proerythroblast arrest
- AML- 5 -> myeloblast arrest
- AML- 4 -> myeloblast & monoblast arrest
- AML - 3 -> pnomyelocyte arrest

AfraTafreeh.com

- AML – 2 -> 20% blasts are myeloblast AML with maturation
- AML – 1 -> 90% blasts are myeloblast AML without maturation

FAB classification of AML

Ma [AML without differentiation

- M1 – AML without maturation
- M2 – AML with maturation
- M4 – acute myelo monocytic leukemia
- M5 – acute monoblast leukemia
- M6 – acute erythroid leukemia
- M7 – acute -megakaryocyte leukemia

Myeloblast	Lymphoblast
size 3-5 times size of small	Size 2-3 times the size of small lymphocyte
cytoplasm more compared to nucleus	Nucleus more compared to cytoplasm
Auer rods present in cytoplasm	No Auer rods

AML1

- M1 – 90% cells are teloblast
- M2 – 20% cells are myeloblast
- <3 – 20% cells are myeloblast

M3

- Abnormal promyelocyte
- Nucleus is indented
- Cytoplasm has excessive granules
- Auer rods bundles present
- Faggot cells (bundles of auer rods)
- Abnormal promyelocyte also called buttock cells
- Abnormal promyelocyte also called as blast equivalent

AfraTafreeh.com
TUTORIALS
LOGIN FOR SUCCESS

Predominant cells

- M1 -90% myeloblast
- M2 – 29% myeloblast
- M3 – abnormal promyeloblast (blast equivalents)
- M4 – monobalst, myeloblast
- M5 – monoblast
- M6 – erythroblast
- M7 – megakaryoblast

AML-M7

- Most common leukemia present in down's syndrome

AfraTafreeh.com

Most common hematologic manifestation of down's syndrome – transient Abnormal myelopoiesis

- Most common leukemia is down's syndrome less than 4 years ->

AML – M7

More than 4 years ->ALL AML- M6

- Features common with megaloblastic anemia & myelodysplastic
  Syndrome
  AML M4 & AML M5
- It shows gum infiltration & skin infiltration (leukemia cutis)
  AML: -
- Azurophilic granules containing MP which on rupture leads to DIC
- Mutation of t (PML, RAR a)

- Treatment
  - All trans Retinoic Acid
  - Arsenic O_3

  All trans Retinoic Acid Removes the block in the maturation of promyelocyte

- CHLOROMA
  - Seen is AML, M1, M2, M4
  - Mostly seen in Head, Neck Extramedullary

  Proliferation of Blast is called chloroma this growth appears greenish
  - Most common with AML -M2

TUTORIALS LOGIN FOR SUCCESS

Special stains for AML 00:35:00

i. PASS stain

Diffuse PAS positivity → AML M6

→ AML M7

ii. MPO stain

MPO positivity – M1, M2. M3, M4

- Maximum positivity of MPO – M3
- Sudan Black & chloroacetate also used to defect AML M1, M2, M3, M4 [myeloid series]

iii. Non- specific esterase

NSE positive → M4, M5 [Monoblast]

Specific esterase → M4, M1, M2, M3

Dual Esterase → M4

AfraTafreeh.com

CYTOCHMISTRY Stains: Positivity

- M1, M2, M3 –MP Cholinesterase Sudan Black
- M4, M5 _ NSE
- ALL – Dot & Blot PAS

PAS [diffuse]

TUTORIALS LOGIN FOR SUCCESS

WHO 2018

i. AML with recurrent genetic translocation

t (8,21)
t (15,17) } < 20% Blast → Acute leukemia
inv 16

AfraTafreeh.com

ii. AML with Myelodysplasia

Criteria a. > 20% Blast

b. > 50 % of cells in lineage show dysplasia

iii. AML with Therapy

a. AML with Alkylating Agent therapy

- Latest period → 5-19 years
- Unbalanced Translocation

b. AML with Topoisomerase inhibitor

- Latent period → 1-5 years
- Balanced Translocation

iv. AML with Downs

- < 4 years of age most common leukemia – AML M7
- > 4 years of age ALL most common

Downs associated with GATA mutation

v. AML NOS

Subtyping for AML

TUTORIALS
LOGIN FOR SUCCESS

Diagnosis

All MLS's: Except AML – M3 diagnosis by flow cytometry

- AML M3 diagnosed by FISH
- Best marker of prognosis of leukemia → Respond to Therapy.

FLOW CYTOMETRY

Flow cytometry 00:00:05

- Definition – Measurement of cells, which are flowing.
- In flow cytometry we do immune phenotyping
  - Machine use – Flow cytometer
  - Procedure
- Laser light falls on flowing cells in the tunnels, the tunnel has sheath fluid
- Laser light falls on cells, due to the characteristics of the cell – the lights scatter
- The light can scatter in two directions
  i. Forward scatter
  ii. Reverse scatter
  iii. Side scatter
  - Forward scatter is proportional to size
  - Side scatter is proportional to granularity
  - CD 45 in present on all mature Hematolymphoid cell
  - To detect any blood cell antibody is attached to CD 45
  - Antibody can have florescent dye tagged to it

AfraTafreeh.com

- Green fluorescent dye
  - → FITC – Fluorescein iso thio cyanate
  - Most common
- Red Florescent dye
  - → Phycoerythrin
  - CD 45 side scatter Plot

AfraTafreeh.com

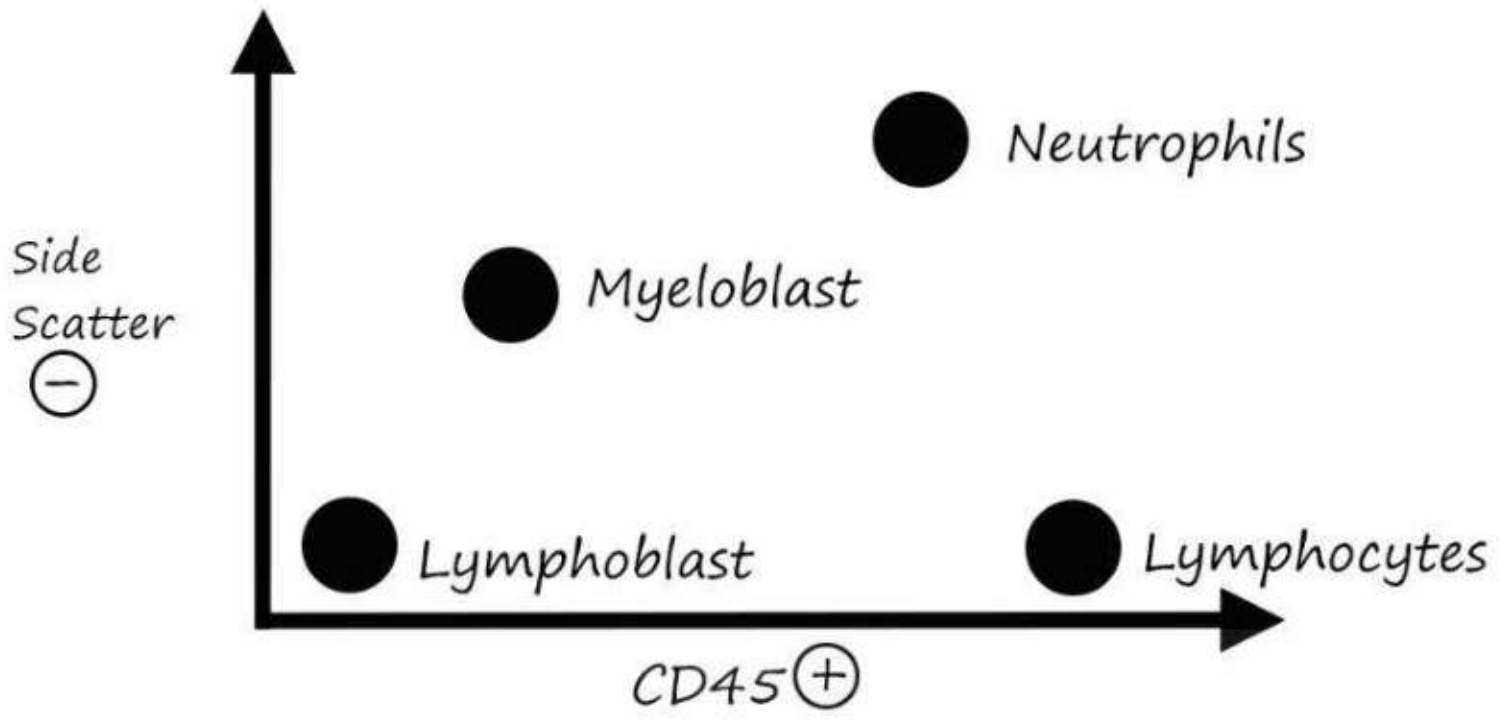

Protocol of flow cytometry 00:14:18

- Step I
  - i. Identity cell
  - ii. Identity lineage of the cell by markers

Protocol of AML 00:19:57

Lymphoblast + [Weak/Dim CD45 marker]

B cell	T cell
CD19	CD 3
pan B cell marker	pan T cell marker
weak CD19	weak CD1 CD 5
CD 10	CD2 CD6
CD 79	CD3 CD6
CD 22	CD4 CD8

Protocol of AML

- HLA DR marker foe AML – It is immature marker
- Granulo cystic lineage marker x MPO, CD33, CD 13
- Monocytic lineage marker – CD11c.CD 15
- Megakaryocytic lineage – CD41, CD42, CD61

B- ALL

Marker

Pro B- ALL → CDb19, CD 34, TaT

↓

Common B – ALL → CD 10 +, good [calla] prognosis

↓ Common ALL antigen

Pre-B ALL → cytoplasmic 4

↓

Late pre-B ALL → surface lg M positivity (Mature ALL)

- Surface IgM positivity present in Burkitt's lymphoma.

AfraTafreeh.com

TUTORIALS

LOGIN FOR SUCCESS

AfraTafreeh.com

BASICS OF CHRONIC LEUKEMIA & LYMPHOMA

Molecular genetics of chronic leukemias

- Mutation of signal Transduction
- Pathway of Hematolymphoid cells.

Types of chronic leukemia proliferative

i. Chronic Myeloid leukemia

ii. Chronic lymphocytic leukemia

CMPL

- It shows panmyelosis in except essential thrombocytosis

Types of CMPL

i. Chronic myeloid leukemia
   - Excess of granulocyte lineage

ii. Polycythemia vera
   - Erythroid cells are the main proliferating cells

iii. Essential thrombocytosis
   - Megakaryocytes are the only proliferating cells

iv. Primary Myelofibrosis
   - Megasociety's cause fusions of bone marine

Pathogenesis of CMPL 00:15:40

i. Chronic myeloid leukemia Mutation is translocation of t (9,22)

- Which leads to function of BCR – ABL

i.e., BCR _ABL is 210 KDa in size which activates tyrosine kinase enzyme is

- Tyrosine kinase is an signal transduction molecule which causes proliferation of cells
- Philadelphia chromosome is found when these is translocation of ABL gene from the chromosome aq to BCR gene on chromosome 22q

ii. Polycythemia Vera

- 95% cases due to SAK 2 V617F mutation
- It is a point mutation at protein 617 where valine is replaced by phenylalanine

iii. Essential thrombocytosis

- Mutations present JAK2, CALR or MPL mutation

iv. Primary Myelofibrosis

- 50-60% cases have mutation of JAK2 and MPL mutation in 1-5 % cases. Chronic myeloid Leukemia
  - Peripheral smear
- Neutrophilic cells & precaution are of variation sizes & unpigmented describes as cocktail or garden party appearance.
  - Bone marrow
    - CML bone marrow is hypercellular -finding is sea-blue histocytes

AfraTafreen.com

AfraTafreeh.com

In lymph Nodes

In lymph Nodes
- There is germinal center which lack BCL
- Zone outside of germinal center month zone
- Marginal zone is present outside lymphoid

- In general Centre – cells are under group maturation & somatic hypermutation occurs due to merman of AID

Germinal Centre lymphoma

i. Follicular lymphoma
   - Mutation t (14,18)
   - Tumor cells express BCL2
   - Normally Geminal Centre BCL2 negative

Two Types of cells present

i. Centrocytes – small cell with leaved nuclear & scant cytoplasm [Buttock cells]

ii. Central ducts are large cells with open nuclear chromatin; several nuclear & modest amount of uptopskim

   - Bone marrow Biopsy shows characteristic Para trabecular lymphoid aggregates

Burkitt's lymphoma 00:27:50

- Mature B cells lymphoma i.e. cd 34– & Ig+
- Very aggressive type of tumor
- It is most common cause of tumor lysis syndrome
   - Cytogenetion

i. It is associated with c- MyC gene [chromsome8] translocation

- T (8,14)
- T (2,8)
- T (8,22)

- Mitotic activity of Burkitt's → 100%
- Starry sky appreance

3 categories of Burkitt's lymphoma

i. African (endemic) Bl
   - Most commonly affects mandible
   - All cases latently infected c→ EBV

ii. Sporadic (non endemic) BL
   - Presents as ileocecal or peritoneal ma
   - 15-20% patients infected by EBV

iii. HIV associated aggressive lymphomas 25% patients infected by EBV

LOGIN FOR SUCCESS

Lymph Node Biopsy

- Characteristic starry sky appearance due to apoptotic tumor cell laden foamy cytoplasm of macrophage.
- Bone marrow aspirate show tumor cells with clumped nuclear chromatin with prominent nuclear & nogal bule lipid Immunophenotype
- BCL 6 positive & BCL 2 absent

AfraTafreeh.com

Define large B cell Lymphoma

- Most common type of non-Hodgkin lymphoma inworld & India
- Most aggressive, winze progressive immunophenotype
- BCL6 mutation
- Tumor cells are CD20+ve → Rituximab used for treatment Cytogenic t (14,18)
- Most common extra nodal type
- Sites involved → central Nervous system → Testes
- Most common primary tumor in CNS
- Define large B cells lymphoma

Marginal Zone lymphoma (maltoma) 00:35:30

- Most common site for Mucosa associated lymphoid tissue is claim
- Most common site for mudra associated lymphoid tumor is stomach
- Chronic inflammatory conduction Eg: H. pylori infection, S.jogren disease, Hashemites thyroiditis
- It remains localized for long period
- Tumor can regress if the inciting stimulus is removed

Cytogenetics

- T (11,18) → this translocation resistant to chemotherapy
- T (11,18)
- T (1,14)

Harry cell leukemia

- It is a B – cell non-Hodgkin lymphoma
- Middle age Male commonly official
- Most common presentation is massive splenomegaly
- Pancytopenia occurs due to marrow infiltration & splenic sequestration
- High incident of atypical Mycobacterial infections
- Che sensitives & overall program is good
- Cytogenetics BRAF mutation

TUTORIALS
LOGIN FOR SUCCESS

Peripheral smear

- Hairy cells are B cell with reniform nuclear & hair like cytoplasmic projections which is vest seen by phase contrast microscopy

– Mantle zone	– Mantle cell lymphoma
– Germinal Centre Lymphoma	– Hodgkin lymphoma Burkitt's Follicular lymphoma
– Memory B cells	– Define large B cell Marginal zone Hairy cell leukemia chronic lymphocytic leukemia
– Plasma cell	– Multiple Myeloma

AfraTafreeh.com

CHRONIC LYMPHOCYTIC LEUKEMIA

- CLL is defined as absolute lymphocyte count more than 5000/mm3

Pathogenesis 00:00:05

- Most common type of CLL→ Native B cell chronic leukemia
  a. Predominant pathway of excess proliferation of cells due to decreased apoptosis (main mechanism)
  b. Other is excess proliferation

Cytogenetic

- Deletion 13 q – Most common — Decreased apoptosis
- Good prognosis

Trisomy 12

Deletion 17p

Bruton Tyrosine kinase — Excess proliferation

Mutation

This over activity leads to production of abnormal Antibodies that can lead to autoimmune hemolytic Anemia & idiopathic thrombocytopenia

Characteristics Features of CLL

1. Asymptomatic individual, only present as fatigue
2. Most common chronic leukemia of west
3. This leukemia never occurs with radiation
4. mRNA 15, mRNA 16 — They are sign of good prognosis

Clinical Features 00:11:44

a. Asymptomatic individual
b. More common in males, age 60 years
c. Commonly present with generalized lymphadenopathy & hepatosplenomegaly

Peripheral smears 00:13:50

i. Absolute lymphocyte count> 5000/4l
ii. Fragile, fragmented tumor cells known as smudge cell /parachuted cells /GHOST CELLS/SHADOW cells of gum Precht
iii. Cytoskeleton theory – loss of vimentin in tumor cells, hence are very fragile – disrupted during formation of peripheral smear

AfraTafreeh.com

Bone marrow Aspiration

- Proliferation centers visualized Investigation of choice
  a. Flow cytometry
  b. CD5 and CD 23 positive
  c. Monoclonal cells

CD5+

CD 23 + → CLL

CD 23 – → Mantle cell lymphoma

AfraTafreeh.com

Lymph node biopsy

- Lymph nodes shows diffuse proliferation of small, round lymphoid cells
- Scattered nodules (pseudo follicles) growth centers or proliferative centers is observed

  Staging done for CLL
  Rai & Binet staging Fate of CLL

a. Treatment of patient begins when patient presents with anemia & Thrombocytopenia
b. CLL can turn into diffuse large B cell lymphoma – this is called Richter syndrome

Poor prognosis of CLL

a. Deletion of 11q or 17p & trisomy 12
b. Expressions of XZAP 10 protein

Update in CLL

a. mRNA 15-1, mRNA16 signify good prognosis
b. CD 200 important marker or CLL
c. These lymphomas not associated with radiation
d. Patient with BRCA 2 mutation have high chances of CLL
   - CLL → Lymphocytes of same size & configuration → convert girl appearance

CHRONIC MYELOPROLIFERATIVE NEOPLASMS – CHRONIC MYELOID LEUKEMIA

Pathogenesis 00:00:05

- BCR –ABL fusion leads to proliferation of cells in bone marrow
- DWARF megakaryocyte is formed due to excess proliferation of cell in bone marrow

Clinical features

- Sternal Tend mess
- Splenomegaly is a common feature die to in extravascular hemolysis
- Mostly affects adults with peak incidence from 50-60 years of age
- No peripheral lymph mode enlargement is seen usually
- Sudden, painful enlargement of lymph mode is a known case of CML is suggestive of blast crisis

Peripheral smears 00:07:47

- Peripheral blood shows leukocytosis (more than 1,00,000 cells)
- It consists of neutrophils, eosinophils & basophils
- Tumor cells enter into peripheral blood known as leukostasis
- Blast count are less than 10% of circulating cell

AfraTafreeh.com

- All precursor cells enter peripheral smear– garden party appearance

Leukemoid Reaction	chronic myeloid leukemia
NAP/LAP score increased (Nuclear alkaline phosphatase, Leukocyte alkaline phosphatase) - Basophilia absent - Eosinophilia absent - Thrombocytosis absent	NAP/ALP score is decreased in CML except blast crisis - Basophilia - Eosinophilia - Thrombocytosis

Bone marrow aspirate in CML

a. CML marrow is hypercellular
b. Characteristics finding is present of se blue histiocytes or pseudo Gaucher cells which is a macrophage
c. Panmyelosis is seen
d. Dwarf megakaryocytes observed
e. Pseudo Pegler huet cells

Index to assess prognosis of CML

1. Sokol index
    a. Platelet count
    b. Age
    c. Spleen size
    d. Circulating blast
    e. Cytogenetic changes

2. Hansford system

   a. Age
   b. Basophils & eosinophils
   c. Circulating blasts
   d. Platelet count
   e. Spleen size

Diagnosis 00:29:20

- Investigation of choice – FISH

Stages of CML

i. Chromic phase

   a. Bone marrow or peripheral blood < 10% of blast cells
   b. BCR – ABL fusion gene present
   c. Thrombocytosis

ii. Accelerated phase

   a. Blasts cells 10-19%
   b. Basophilia > 20%
   c. Thrombocytosis non responsive to treatment thrombocytopenia without any treatment
   d. Leukocytosis or splenomegaly non responsive to treatment
   e. Cytogenetic changes Trisomy 8, isochromosome 17 q, Philadelphia chromosome
   f. Not responsive to Tyrosine kinase therapy

AfraTafreeh.com
TUTORIALS
LOGIN FOR SUCCESS

AfraTafreeh.com

iii. Blast crisis

a. Blast count > 20%

b. Extra medullary blast cell on bone marrow biopsy

Drug of choice

- Imatinib – Tyrosine kinase inhibitor this is phenomenon of oncogene addition

TUTORIALS
LOGIN FOR SUCCESS

CHRONIC MYELOPROLIFERATIVE NEOPLASM

POLYCYTHEMIA VERA

Polycythemia Vera 00:00:05

- It is characterized increased marrow production erythrocytes, granulocytes & platelets (pan myelosis)

Cytogenetics

- Point mutation in tyrosine kinase JAK2
- Most of the clinical symptoms due to absolute increase in red blood cells mass
- RBC mass in more than 25% of preexisting mass

AfraTafreeh.com
TUTORIALS
LOGIN FOR SUCCESS

Diagnostic criteria (WHO)

Diagnostic requires

a. 3 major criteria on
b. First 2 major criteria and the minor criteria

Major criteria

- Hb > 16.5 g/dl in men > or HCT > 49% in men, > 48% n women or increased red cell mass > 25% above normal predicated value
- Bone marrow biopsy showing hypercellularity for age with trilineage growth (pan myelosis) including prominent erythroid granulocytic & megakaryocytic

AfraTafreeh.com

proliferation with pleomorphic, mature, megakaryocyte

- Presence of JAK2 V617F or Jak-2 exon 12 mutation

Minor criteria

Subnormal serum erythropoietin level

Morphology

- Hyper cellular marrow involving all three lineages
- Basophilia & abnormally large platelets are seen in peripheral blood
- Extramedullary hematopoiesis in spleen & liver lead to massive organomegaly
- 2% of patient transform to AML

  - Chemical features of PV

- Erythropoietin due to increased red cell mass
- Hyperviscocity -headache, dizziness & blurring of vision

Types of polycythemias

Absolute | Relative

i. Absolute polycythemia

Classification

- High erythropoietin → secondary polycythemia
- Low erythropoietin → Primary polycythemia → polycythemia Vera

Causes

- Hypoxia
- Chuvash polycythemia
- Paraneoplastic syndrome
  - a. Hemangioblastoma
  - b. Renal cell carcinoma

AfraTafreeh.com
TUTORIALS
LOGIN FOR SUCCESS

ii. Relative polycythemia

- Apparent increased red cell count

Causes

a. Dehydration

b. Gas bock syndrome

Complication of polycythemia vera thrombosis

- Arterial thrombosis
- Venous thrombosis > hepatic venous thrombosis (Budd Chiari syndrome)

AfraTafreeh.com

Essential thrombocytosis 00:21:10

- It is characterized by increased proliferation & production of megakaryocytic elements
- Cytogenetics – JAK2 Mutation
  CALR Mutation
  MPL mutation
- Bone marrow -hype lobulated megakaryocytic called staghorn megakaryocytes

Clinical features

- Erythromelalgia
- Thrombosis _ Budd Chiari
- Bleeding – gastrointestinal /mucosal bleeding

Criteria WHO

Major criteria

- Platelet count -> 4.5 lakh
- Bone marrow aspirate – staghorn megakaryocytes
- Presence of KAK2, CALR or MPL or MPL mutation
- Not meeting WHO criteria for (ML, PV, PMF, MDS)

Minor criteria

- Absence of evidence for reactive thrombocytosis diagnosis

All 4 major of first 3 major + minor criteria

Thrombocytosis seen in for condition

- CML – chronic myeloid leukemia
- PV-polycythemia Vera
- ET- essential thrombocytosis

Primary myelofibrosis 00:30:50

- Hall mark of primary myelofibrosis of obliterative marrow fibrosis

Cytogenetics

- JAK2
- MPL

AfraTafreeh.com
TUTORIALS
LOGIN FOR SUCCESS

WHO diagnosis criteria

i. **Major criteria**

- Proliferation of megakaryocytes + fibrosis
- Not meeting WHO criteria for (ET, PV, CML, MDS)
- Presence of JAK2, CALR OR MPL mass

ii. Minor

- Anemia
- Leukocytosis 11laksh
- Palpable splenomegaly
- LDH increased
- Leucoerythroblastic

AfraTafreeh.com

Peripheral smear

- Tea drop RBC – Dacrocytes
- Abnormally large palettes
- Pancytopenia → WBC < 4000, HB < 10/dl, Plt/ 1 lakh
- Leucoerythroblastic -> release of nucleated erythroid progenitors & early granulocyte progenitors

Bone marrow biopsy – investigation of chronic

- Shows clusters of atypical megakaryocytes with unusual nuclear shapes (describes as cloud like) dilated marrow

Sinusoids

- Special stain- reticulin stain- shows fibrosis

Massive splenomegaly seen in

- CML -> + leukocytosis
- Primary myelo fibrosis _> pancytopenia
- Hairy cell leukemia-> pancytopenia

Types of megakaryocytic 00:46:28

- DWARF -> CML
- Staghorn -> essential thrombocytosis
- Cloud like -> primary myelo fibrosis
- Pawn like -> myelodysplastic syndrome
- Smooth -> idiopathic thrombocytopenia

APPROACH TO B CELL – LYMPHOMA PART - I

B – lymphoma

- Geminal centre
  - Burkitts
  - Follicular
  - DLBCL
- Month
- Post Centre
  - Marginal Zone
  - Hairy cell leukemia
  - Chronic Lymphocytic Leukemias

Mantle cell lymphoma. 00:03:30

AfraTafreeh.com

- Caine cell lymphoma t(11,14)

  ↓

  Activation cyclin D, Ig4

  ↓

  Increase cell cycle polyreaction
- Peculiarity – Lymphomatosis polyposis.
- Microscopy – Centrocyte's → Buttock cells.
- Immunohistochemistry – Cyclin D_1

  CD 5 ⊕

  CD 23 ⊖
- New update – New monkeys SDX11
- Markers of Germinal center are

  BCL 6

  CD 10

AfraTafreeh.com

Follicular Lymphoma 00:07:40

- Follicular lymphoma cause: t (14,18) mutation.

↓

BCL ⊕, Ig4

↓

Increase germinal center

Peculiarity

- Most common indolent NHL
- Most common site stomach
- Most common site for extra Modal NHL → stomach
- Bone Marrow Involvement (Para Trabecular Infiltration)

Microscopy

- Centrocytes & Centro blasts are seen.

  1HC: BCL 6⊕

  Markers BCL 2 ⊕

  CD 10 ⊕
- New update – 95% cases of follicular lymphomas shows MLL2 mutation.
- MLL_1 mutation seen acute leukemia.

DOC TUTORIALS LOGIN FOR SUCCESS

Burkitt lymphoma 00:14:02

- Causes – mutation t(8, 14) Cmyc, Ig4

t (2,8) cmyc, K

t (8, 22) cmyc's, λ

↓

Activates transcription

↓

Massive proliferation

Peculiarity

i. Endemic type

- Africa origin, lesion is
- In mandible, 100% EBC infection

ii. Sporadic type.

- Ileocecal mass presentation
- 20-30% EBV positive case.

iii. Immunodeficient

- Ant site
- 30-50% EBC positive case
- Viscera involvement.

Microscopy

- Large nuclear with cytoplasmic vacuoles
- The vacuoles contain FAT.
- Oil red O stain protocol.
- Starry sky appearance.

AfraTafreeh.com
TUTORIALS
... FOR SUCCESS

AfraTafreeh.com

IHC markers

- Positive for surface IgM. BCL 6⊕
- K, 67 sure is 100%

Diffuse large B cell Lymphoma (DLBCL) 00:22:20

- Causes – BCL6 mutation

Peculiarity

- Most common Non Hodgkin lymphoma.
- Most aggressive.
- Most common extra modal sites – CNS, Testis.

Microscopy

- Large cells which are immunoblasts.

I4C marker

- BCL 6+
- CD20+
- Hence Rituximab used for treatment

Update

- Two categories of DLBCL
  i. Immunodeficiency associated DLBCL.
  ii. Primary effusion lymphoma

Immunodeficiency Associated	Primary effusion lymphoma
• DLBCL • Cause EBV • Severe Ig (T cells) deficient.	• HHV 8 virus • HIV virus • IHC markers – CD 30⊕ – CD 38⊕

CD 30+ positive lymphoma

- Hodgkin lymphoma
- Anaplastic large cell lymphoma
- Primary effusion lymphoma.
- Marginal zone lymphoma also called MALToma (macula associated lymphoma) cause → t (11,18)
- Peculiarity →
  i. Chronic inflammation
    - 4 pylon
    - Sjogren's syndrome
    - Hashimoto thyroiditis

  ii. Localized

  iii. Tumor regresses on treatment.
- IHC markers – CD 43⊕

DOC TUTORIALS LOGIN FOR SUCCESS

AfraTafreeh.com

APPROACH TO B CELL LYMPHOMA PART – II WITH FOCUS ON HAIRY CELL LEUKEMIA AND CASTLEMAN DISEASE

Approach to B – cell lymphoma

- Marker for post Germinal center – Mum-1 Hairy cell leukemia
- Cause – BRAF Mutation

cancer due to BRAF
Hairy cell leukemia
colon cancer
melanoma
papillary cancer of thyroid

Pathogenesis

BRAF mutation

↓

Leads to Hairy cell prosecutes

Of tumor cells & mobility

↓

Tumor cells infiltrate Bone marrow present Lymph node

↓

In bone marrow, hairy cells leader to flimsies -> this called

secondary Myeloid fusions

Peculiarity

a. Tear Drop RBC

b. Pancytopenia

(Monocytopenia is characteristic)

- Monocytopenia Prodi viruses to Atypical myclobutanil infection
- Extra medullary Hematopoiesis occurs which leads to Less Erythroblastosis & massive splenomegaly
- Extra medullary Hematopoiesis occurs which leads to Less Erythroblastosis & massive splenomegaly
- Peripheral Smear
  - Tear Drop RBC
  - leucoerythroblastic
  - Pancytopenia
  - Monocytopenia

AllFreeTech.com

- Hairy cells
- Special stain for hairy cells) – 1) TRAP (Tarrasa's Resistant Acid phosphates)
  2) Annexin SA!
  3) BDA 44

TUTORIALS LOGIN FOR SUCCESS

- IHC marker → CD 11c
  → CD 103
  → CD25
- Other investigation – phase contrast Microscopy → hairy cells are seen
- Peculiarity
  - Monocytopenia
  - Involved Red pulp spleen

AfraTafreeh.com

Investigation

- Bone marrow Biopsy – Hairy cells are seen
- Fried egg appearance
- Reticular stain – identifier fluorosis
- Spleen Biopsy → pseudo sinus formation
- Election Microscopy → Ribosome Lamellar completion seen
- Diagnosis of choice of hairy cell leukemia
- BRAF mutation V600E → valine replaced by glutamine at peritenon 600 which is present is 100% hairy cell leukemia

Hugh Yield Box

- Paint mutation
- BRAF * V600E
- Valine → Glutamine

]— 100% of hairy cell leucine

- SAK2 V617
- Valine → phenylalanine

]— 95% of polyethylene vera & 30 – 50 % of ET, PMF

Morphology Castleman disease

- Condensed Germinal center
- Onion skinning of mantle zone lymphocyte
- HHV 8 virus infection

HODGKIN'S LYMPHOMA

- It arises from germinal center – B cells
- Epstein Barr virus infect germinal center or post germinal center B cells and give rise to read Sternberg cells
- Reed Sternberg cell alone are not diagnostic of Hodgkin; lymphoma since they are seen in
  a. Infection mononucleosis
  b. Non-Hodgkin lymphoma
  c. Carcinoma
  d. Sarcoma
- Redd Stenberg cell's features
  a. Binucleated
  b. Eosinophilic cytoplasm
- Reed Sternberg cell undergo a REL mutation& turns oncogenic & release
  a. R IL 5 → activate
  b. IL 4 → increase Lymphocytes
  c. IL10 } surprise immunity
  d. Galectin }
- Histological diagnosis of Hodgkin's lymphoma is established by presence of Reed Stenberg cells along with background of mixed inflammation consisting of neutrophil, lymphocytes, plasma cells, eosinophils & histocytes

AfraTafreeh.com
TUTORIALS
LOGIN FOR SUCCESS

AfraTafreeh.com

Read Stenberg cell morphology

a. Classic RS cells express PAX5 and CD15 and CD 30
b. Lymph histiocytic variants of RS cells are negative for CG15 and Cd 30
c. Classic RS cells are large (45cm diameter) with either a multilobed Nucleus or multiple nuclei large nucleoli → owl eye appearance

Classification of Hodgkin's lymphoma 00:03:00

i. Classical
ii. Non classical

i. Classical Hodgkin's lymphoma
   a. Lymphocyte rich
   b. Mixed cellularity
   c. Nodular sclerosis
   d. Lymphocyte rich

ii. Non classical Hodgkin's lymphoma
   a. Lymphocyte predominant

i. Classical Hodgkin's lymphoma
   a. Nodular sclerosis
   - Most common form of HL (world)
   - Female= male, equal
   - Most patients are young

- Mediastinal involvement is common
- Characteristics by presence of lacunar variant RS cells collagen bands which forms nodules
- Lacunar cells will have cytoplasmic retraction
- It is uncommonly associated with EBV
- Lacunar RS cells → FOMRALIN FIXATIOJN ARTEFACT

b. Mixed cellularity
- Males are commonly affected
- Most common type in developing countries
- Biphasic incidence
- It is more commonly associated with B symptoms (fever & weight loss)

c. Lymphocytic Rich
- Older males commonly affected
- Mononuclear RS cells / Hodgkin's cells

AfraTafreeh.com
TUTORIALS
LOGIN FOR SUCCESS

d. Lymphocyte depleted
- Lest common form of HL. immunodeficient individual
- This subtype has worst prognosis
- RSD cells also known as pleomorphic RS cells and Mummified RS cells
- Hodgkin's cells (atypical histiocytes) are seen this variant
- Maximum association with HIV

ii. Non classical Hodgkin's lymphoma

a. Lymphocyte predominant

AfraTafreeh.com

- No EBV association (Max PAX% positively)
- Popcorns Rs cells, B -lymphocytes predominant
- They are also known as lymphocytic variants of RS cells
- Best prognosis

Classical HL	Non classical HL
• EBV associated expect nodular sclerosis • CD15, CD 30 positive • Prognosis good to bad	No EBV associate • EMA positivity • CD 20, CD 45 positive • Best prognosis • Oct/Bob1 positively

Clinical features

- Most common presentation is painless cervical lymphadenopathy
- They have fever, which cyclically increase for one to two weeks & then decrease → Pe; Epstein fever
- Two important paraneoplastic syndromes
  a. Secondary amyloidosis
  b. Alcohol induced pain in lymph nodes

Adverse prognostic features

- Age > 45 years
- Male gender
- Hemoglobin < 10.5 blob
- Leukocyte count > 15000/mm3

- Lymphocytopenia

- Absolute lymphocyte count < 600/ul: lymphocytes < 8% leukocytes serum albumin level < 4g/dl

Ann Arbor staging 00:22:55

stages	Distribution of Disease
I	single group of LN or single extra Lymphatic organ/site Two or more groups of Ln same side of diaphragm
II	Or
III	Localizes extra lymphatics Organ site involvement
IV	group of lymph nodes on both sides of diaphragms with or without localized involvement of extra lymphatic organ/site Diffuse involvement site with or without lymphatic involvement
B symptoms	→ Night sweat → Unexplained fever → Unexplained weight loss

AfraTafreeh.com

PLATELETS & COAGULATION

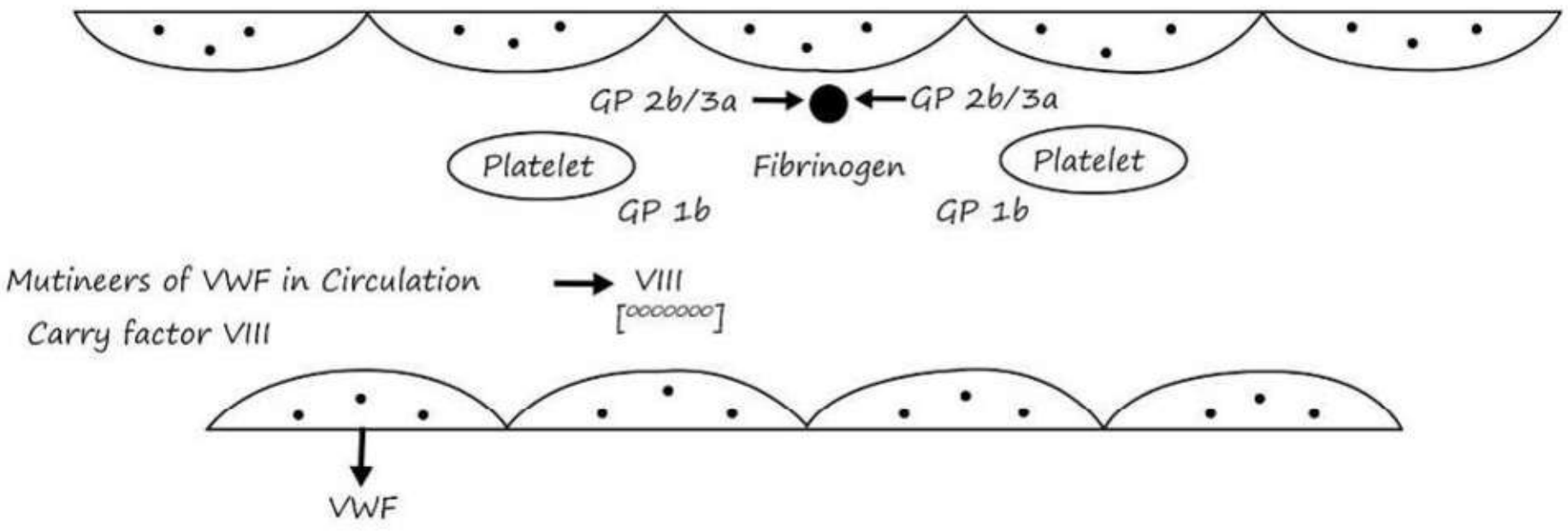

i. Weibel polade bodies endothelium

Store – VMF

-p-selection

ii. circulatory farm of VVG = multimer of VWF

ii. VW carriers factor VIII + factors VIII W/VWF =12 hours

\+ factor VIII w/o VWF= 2.5 hours

T1/2 of factor VIII w/o VWF 2.5 hours this is called Pseudohemophilia

- Antigen on platelets

Antigen on platelet

GPIb → Affinity for VWF

GP2b/3a → Affinity for Fibrinogen

vi. format of primary Hemostatic plug

Endothelial injury

1st step adhesion of platelets to vessel wall

00:10:25

VWF

+

GIPb

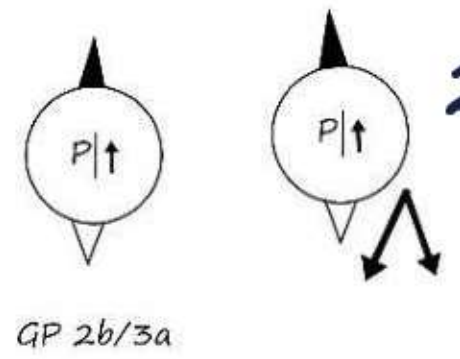

2nd step secretion

Dense granules → Adp

ATP

Serotonin

Epinephrine

Calcium

a Granules

↓

P F T

P- selection PDGF, PF -4

factors 5, 8 fibrinogens

TGF β thrombospondin β

thrombospondin

↓

Release of Granules of platelets

Attract more platelets to the

Site of endothelial injury

TUTORIALS

AfraTafreeh.com

3rd step platelet aggregation

↓

Primary hemostatic plug

So step of primary hemostatic plug formation

Adhension — APIB, VWF

Secretion — a Granules, Derse Granules

Aggregation — GP2b/3a, Fibrinogen

Patients with defect of 1st Hemostatic plug formation

with potentialGum bleeds

vii. formation of secondary Hemostatic plug



1st plug

↓

Platelets

↓

Flipping gives negative charge to 1° plug

↓ Negative charge

↓ Activates

Intrinsic pathway → XII: XII o ↓

Tenase → factor IX.VIII ↓

Prothrombinase → factor X.V

x → xa

12
11
9
8

IX

VIII production → thrombin

X → xa

Extrinsic pathway

Endothelia injury → Release of tissue factor

↓

VII → VIIa

Factor 7 x → xa

Common pathway

Intrinsic pathway Extrinsic pathway

AfraTafreeh.com

x→ xa

↓ V

common pathway follow law of Halves

10	prothrombin → thrombin
5	(factor 2)
2	Fibrinogen to fibrin(clot)
1	(factor 1) Linear unstable

2° hemostatic plug

↓

Factor XIII

Cross linked

Solid stable

AfraTafreeh.com

Applied pathway

SCOTT syndrome 00:28:55

- Absence of flipping of phosphatidyl serine
- No activation of i. Intrinsic pathway

  ii.Tenase &prothrombinase

Factor 13 00:30:00

- factor 13 is also called Laki lorand factor or Fibrin stabilizing factor
  - longest +1 /2 of 14 days
- Deficiency → patient presents with

  i. cephalhematoma

  ii.prolonged umbilical cord stump

  iii. Bleeding

Test to detect deficiency of factor13 → urea clot Solubility test

Urea clot solubility test 00:33:10

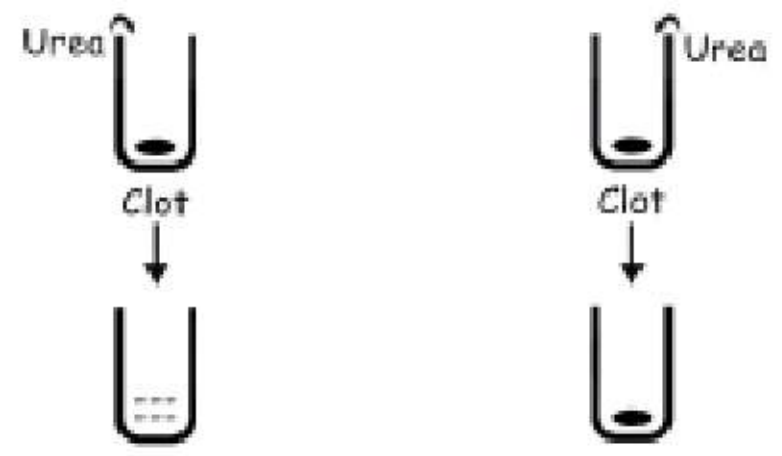

Clot solubilizes | clot does not solubilize

On addition of urea | Normal Factor 13

↓

Factor 13 deficiency present

T -CELL LYMPHOMA

Classification 00:00:07

i. Lymphoid t-Tissues

ii. Skin- mycosis fungoides – Sezary syndrome

i. Lymphoid Tissues

a. Adult T cells Lymphoma

b. Peripheral T cell lymphoma

c. Hepatosplenic T cells lymphoma

d. Anaplastic t cells Lymphoma

e. Angio immunoblastic T cells Lymphoma

AfraTafreeh.com

ii. Skin/cutaneous T cells lymphoma

a. Mycosis fungoides

- Most common cutaneous T cells lymphoma
- It is a CD4 t cells lymphoma
- Epiderma tropism (cutaneous localization of tumor cells) is seen due to present
  - i. Cutaneous leukocyte antigens
  - ii. Chemokine receptor CCr4 & CCRIO
- Myosis Fungoid is also called AKIBER BAZIN SYNDROME
- Due to epidermotropism there is partiers micro-Abscess

AfraTafreeh.com

- Sezary cells /Lutzner cells > Neoplastic T cells with cereloriform nuclei due to marked infoldings of the nuclear memlarane
- Sezary cells more than 20% or more than 1000/mm3 and erythrodermas of skin it is now called Sezary syndrome

i. Lymphoid tissue

a. Adult t lymphoma due to infection by HTLV /-1 virus
   - HLTV1 infects lymphocytes -> clover Leaf / flower cells

b. Anaplastic large cell lymphoma
   - It is a T – cells lymphoma

Three types of ALCL

i. ALK + ve [Anaplastic lymphoma kinase]
   - Most common ALCL
   - Children, younger age group
   - Good prognosis

ii. ALK-ve
   - It occurs in old age
   - Poor prognosis
   - Tumor cells are large anaplastic cells with uniform Lena myoid/horse shoe nuclei called

iii. Hallmark cells
   - Hallmark cells are diagnostic of ALCL

TUTORIALS LOGIN FOR SUCCESS

- Hall mark cells are positive for: _

    a. CD30 +ve

    b. EMA +ve

iv. Breast implant associated ALCL

- It occurs in the capsule of breast implant
- It occurs after 9-10 years of implant in the body
- Breast Implant associated ALCL is also called seroma

Lennert lymphoma

- It is a type if T-lymphoma in which histolytic cells accumulate

Hepato splenic T- Lymphoma

- It has massive splenomegaly

Angioimmunoblastic T cell Lymphoma

- The Tumor has angiogenesis with large number of eosinophils

Enteropathy Associated T cells lymphoma

- It is occur in celiac disease.

AfraTafreeh.com

DISORDERS OF PRIMARY HEMOSTATIC PLUG FORMATION

Disorders of Primary Hemostatic Plug Formation

Defect in platelet count	Defect in platelet count
↓ Platelet count less than 1.5 lakh is labeled as thrombocytopenia (Drugs are major cause of thrombocytopenia) Normal platelet count – 1.5 to 4.5 lakh/mm3	

Procedure 00:01:30

- Gum bleed
- Petechiae < 3mm
- Purpura > 3mm but <1cm
- Prolonged Bleeding time

  Bleeding Time

  Normal 2-7 min

Measurement of Function and count of platelet

2 methods

Duke method

Via ear lobe

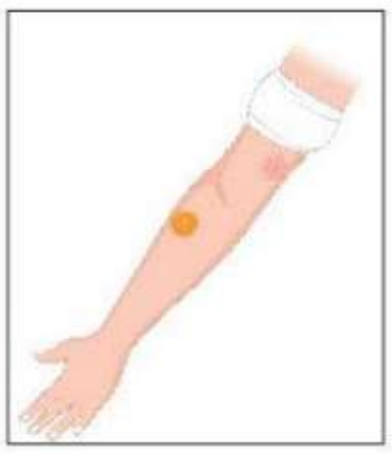

Ivy method

- On fore arm

BP cut of 40 hg 2 cuts 5m deep at 5 cm distance

↓

Keep Blotting them with a Blotting paper every 30 sec to draw off the Blood

AfraTafreeh.com

The time from when the incision made until all bleeding has stopped is measured and is called the Bleeding so

Patient with petechial purpura gum bleeds

↓

Check for Bleeding time, If increased

↓

Investigate the platelet count (N) 1.5-4.5 lakh /mm3

Methods

- Manually by Neubaeur chamber
- Counter machine

Estimate by Peripheral Smear at power of 100x (oil power) count the number of platelets

If 10-15 platelets seen on P.S the count is normal

↓

If platelet count is Normal Rule out Platelet Function defects

AfraTafreeh.com

Classification of platelet function defects 00:09:30

Classification of Platelet Function defects

- Adhesion defect
  - Bernard Saulier syndrome
  - Von Willebrand disease
- Secretion defect
  - A granule secretion defect → Gray platelet syndrome
  - Dense granules secretion defect → hermansky pudlak
- Platelet aggregation defect
  - Glanzmann thrombasthenia
  - afibrinogenemia

Platelet Adhesion Defects

- Defect in gplb IX → Bernald soulier syndrome
- Defect in Von Willebrand factor (VW) → Von Willebrand disease

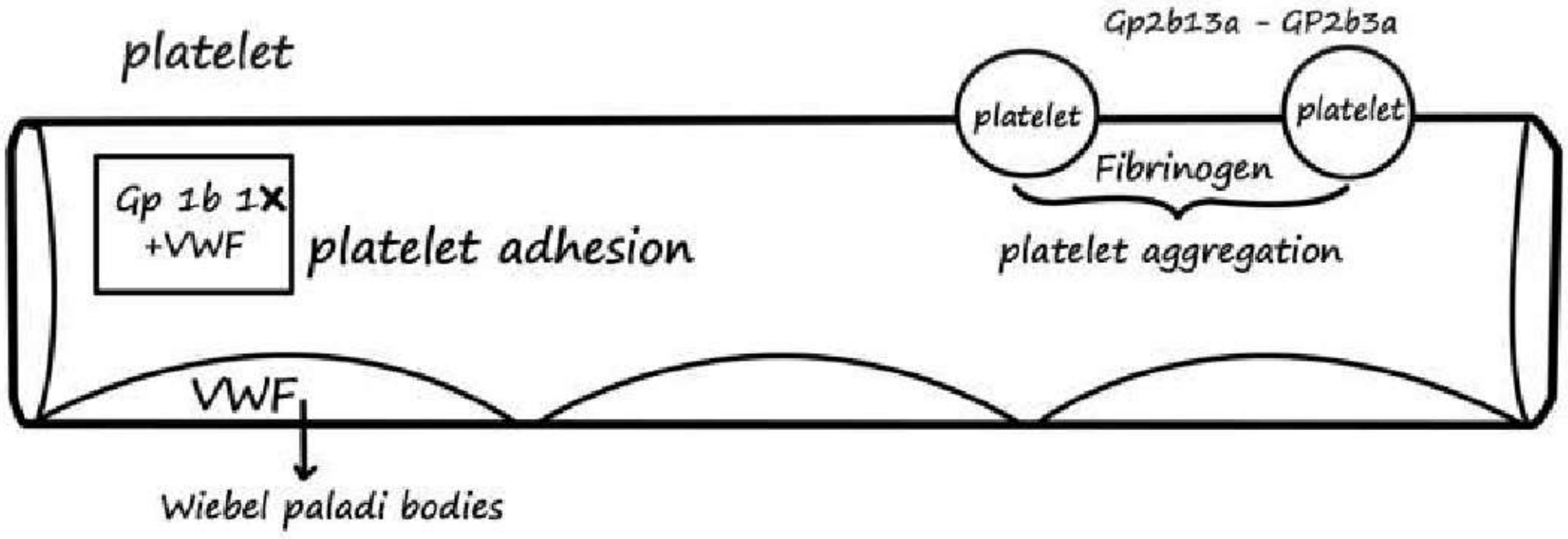

Weibel Palade Bodies store Von Willebrand Factor (VW) VW is synthesized by

i. Endothelium (most abundant source)

ii. Megakaryocytes (minor amount

➔ Adhesin of patient to endothelium involves Von Willebrand factor and Gp/1b receptor of platelet each other requires Gp2b/3a receptor of platelets and Fibrinogen which connects Gp2b/3a

Platelet size defects 00:13:30

	platelet RBC	condition
1.Giant platelets	size of platelet equal to size of RBC	Bernard soulur syndrome may haggling anomaly ➢ MyH9 gene defect ➢ Dohle body like induction in WBC ➢ Giant platelets
2.Large platelets	Large platelets but smaller than size of RBC	➢ Immune – Thrombocytopenic purpura (ITP)
3.Small platelets	Smaller than Normal	Wiscott Aldrich syndrome

AfraTafreeh.com

AfraTafreeh.com

Von Willebrand disease 00:02:01

- The gene for VWF is located at chromosome 12
- VWF is responsible for platelet adhesion (Bridge between extracellular collagen matrix and platelet surface receptors
- GP 1b-1x is major receptor for VWF
- VWF acts as a carrier for factor VII and is important for its stability and pl=prolongs its half life
- Von Willebrand disease is the most common inherited disorders o Human but asymptomatic

Type of VVD

Type I	Type 2	Type 3
- Autosomal dominant - Due to missense mutation - Most common type (85%) - Mild to moderate bleeding - Quantitative defects of VVF where in level of VVF are low	- Qualitative defect of VWF - Missettise mutation - Mild to moderate bleeding - Type A.B.M.N - 2nd M/C type	- Autosomal recessive - Dilations or frame shift mutation - Extremely low levels of VWF - Severe clinical manifestations - Least common type

Type 2 VWD

2A	2B	2M	2N
- Autosomal dominant - Decreased binding VWF to Gp1lbIX - Multimers decreased	- Increased of affinity of VWF & GP1bIX - Ultra large multimers formed and removed form circulation - Presents with Thrombocytopenia - Low dose Ristocetin test - Quick platelets aggregation seen - Ristocetin induced platelet aggregation (RIPA) is markedly increased	- Affinity decreaded - Multimers normal	- Discovered in Normally (France) - VWF does bot bind to Factor VIII - T of factor VIII becomes very short & levels of Factors VIII decrease markedly - Patient presents with hemophilia - Sometimes termed as autosomal hemophilia

Most common symptomatic Bleeding disorder is Hemophilia

AfraTafreeh.com

Differentiation between Bernard saulier & VWD

Bernard Soulier syndrome	VWD
- Autosomal recevive - Giant platelets - Gp Ib is defective - Gp IIb/IIIa is normal - Platelets adhesion disorder - Lab investigation - BT - Pt - aPTT - TT - RAT is +ve i.e. (Abnormal) Ristocentin adhesin test) - Platelet's aggregation test (PAT) is normal - BSS	- Autosomal dominant - Normal sized platelets - VWF deficiency - VWF functions Binding GPIb / stabilization with Of factor VIII (More important) - So VWF =>factor VIII + of factor VIII in presence of VWF is 12 hr. ↓ pseudo hemophilia - Lab investigation BT increased PT (N) aPTT increased RAT _ve PAT #(N)

o. for amusement of plt functional disorder

i. Platelet aggregation test: watch video for concept.

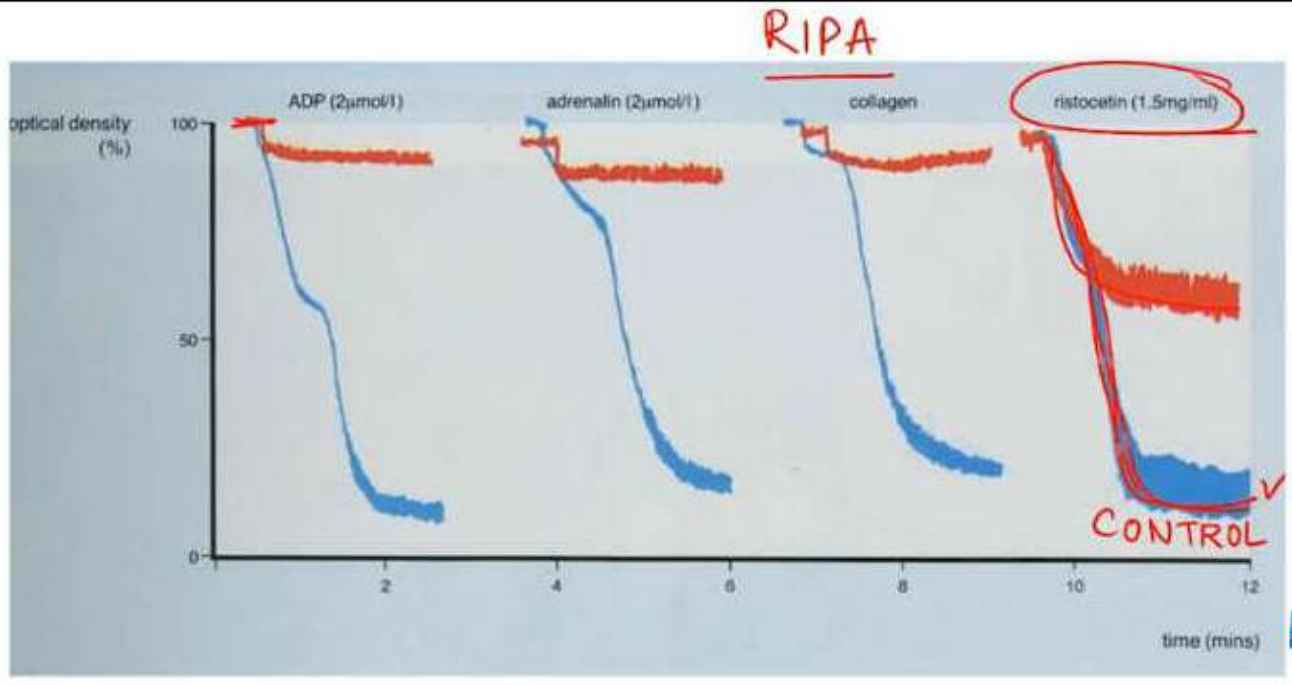

Fig: 1

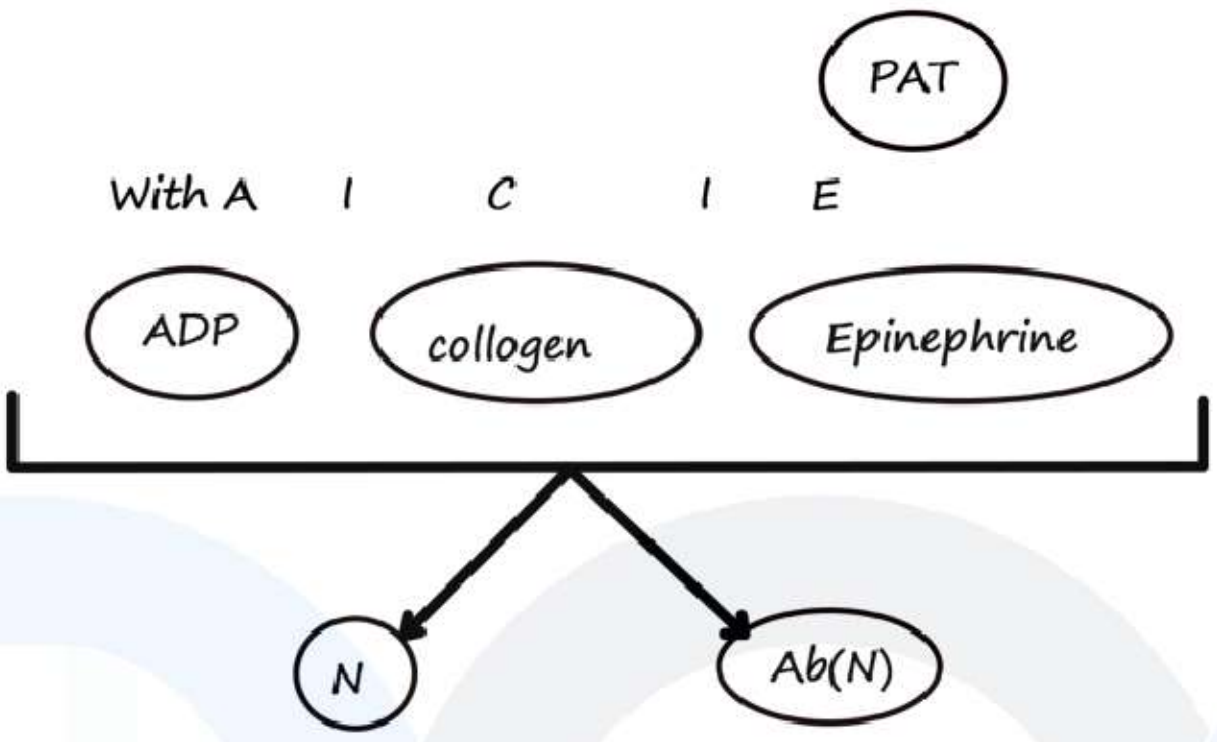

ii. Ristocetin adhesion test.

Ristacetin drug banned now (but use in lab)

Because it Gp Ib & VWF human blood

↓

Thus, induces platelet adhesion

So Ristocetin adhesion test +ve => Gp Ib (N)

RAT (+) VWF (N)

So positive => (N) i.e. present

If any of Gp Ib / VWF – Absent / ab(N) ⇨ RAT (+ve)

TUTORIALS
LOGIN FOR SUCCESS

AfraTafreeh.com

Secretion defects 00:02:01

Secretion defects:

1.Alpha granules defect

Grey platelet syndrome

Hypogranular platelets

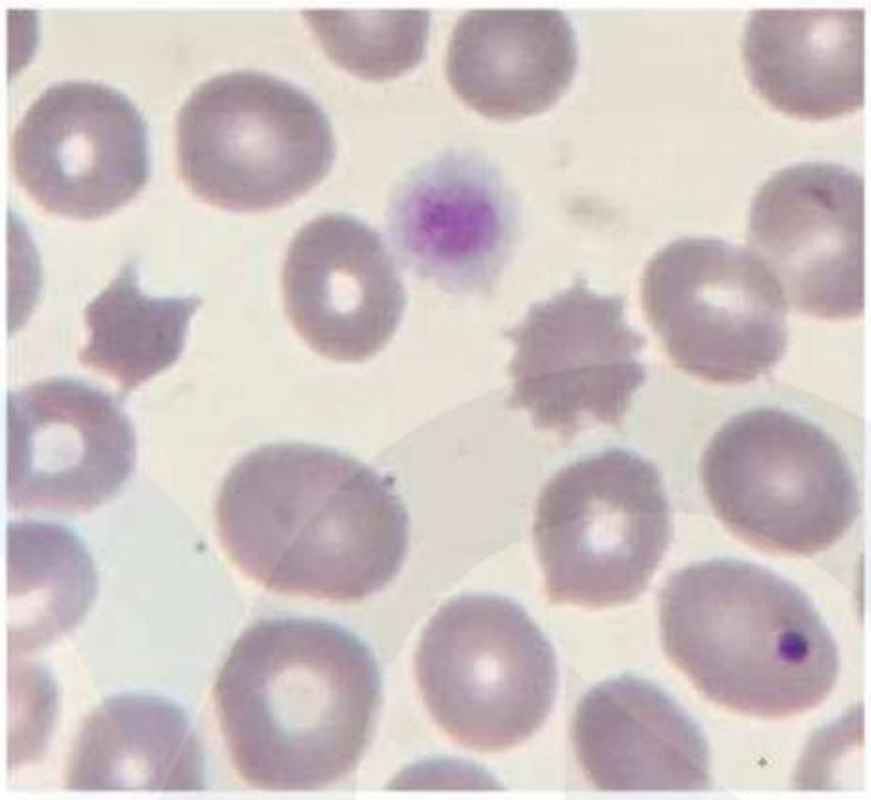

Fig: 2

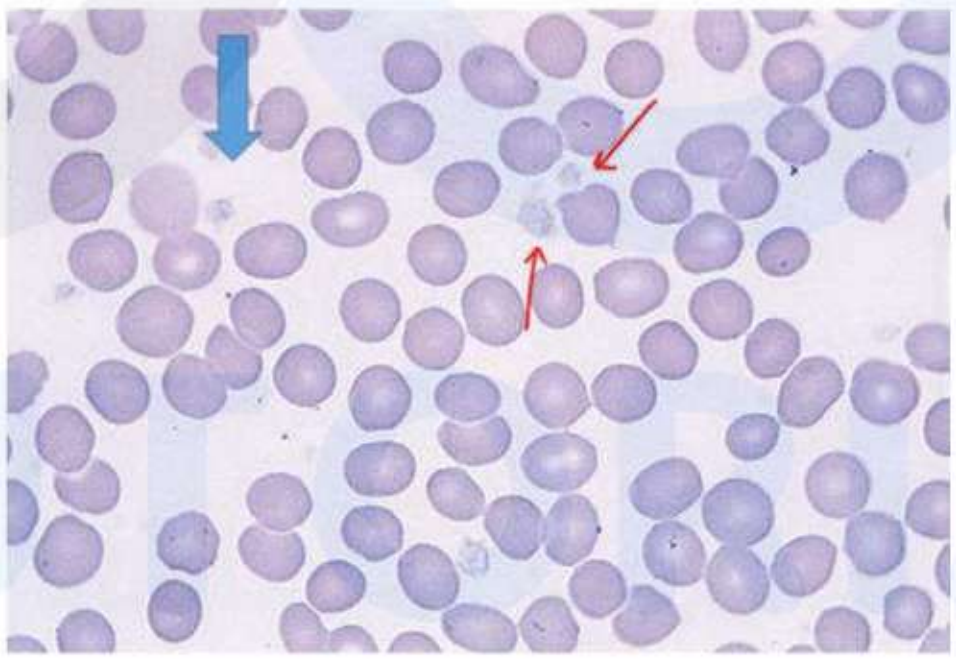

Fig: 2

LOGIN FOR SUCCESS

2.Denese granules defect

Hermansky pudlak syndrome

Oculocutaneous albinism

Platelets aggregation defects 00:44:20

Glanzmann thrombasthenia	Afibrinogenemia
- Autosomal recessive - Defective platelet aggregation - Deficiency or dysfunction of Glycoprotein IIb/ IIIa integrin that participates in bridge formation between platelet by binding fibrinogen - Lab investigation - BT increased - PT. aPTT (N) - RAT is +ve RAT – Abnormal presents with excessive bleeding from umbilical cord	- Absence of Fibrinogen - Defective platelet aggregation GP IIb/3a-GP 2b /3a 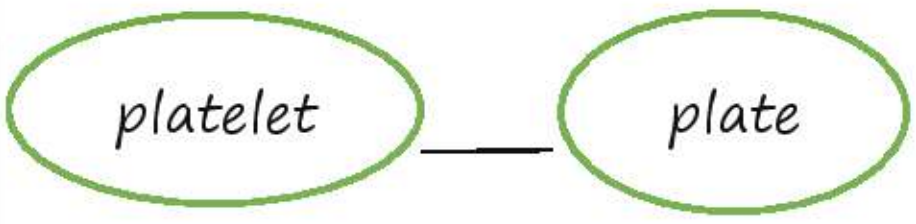 Fibrinogen - lab investigation - PT increased aP TT increased TT increased PAT -Ab (N) RAT +ve

AfraTafreeh.com
TUTORIALS
LOGIN FOR SUCCESS

AfraTafreeh.com

Differential of umbilical cord bleeding 00:47:00

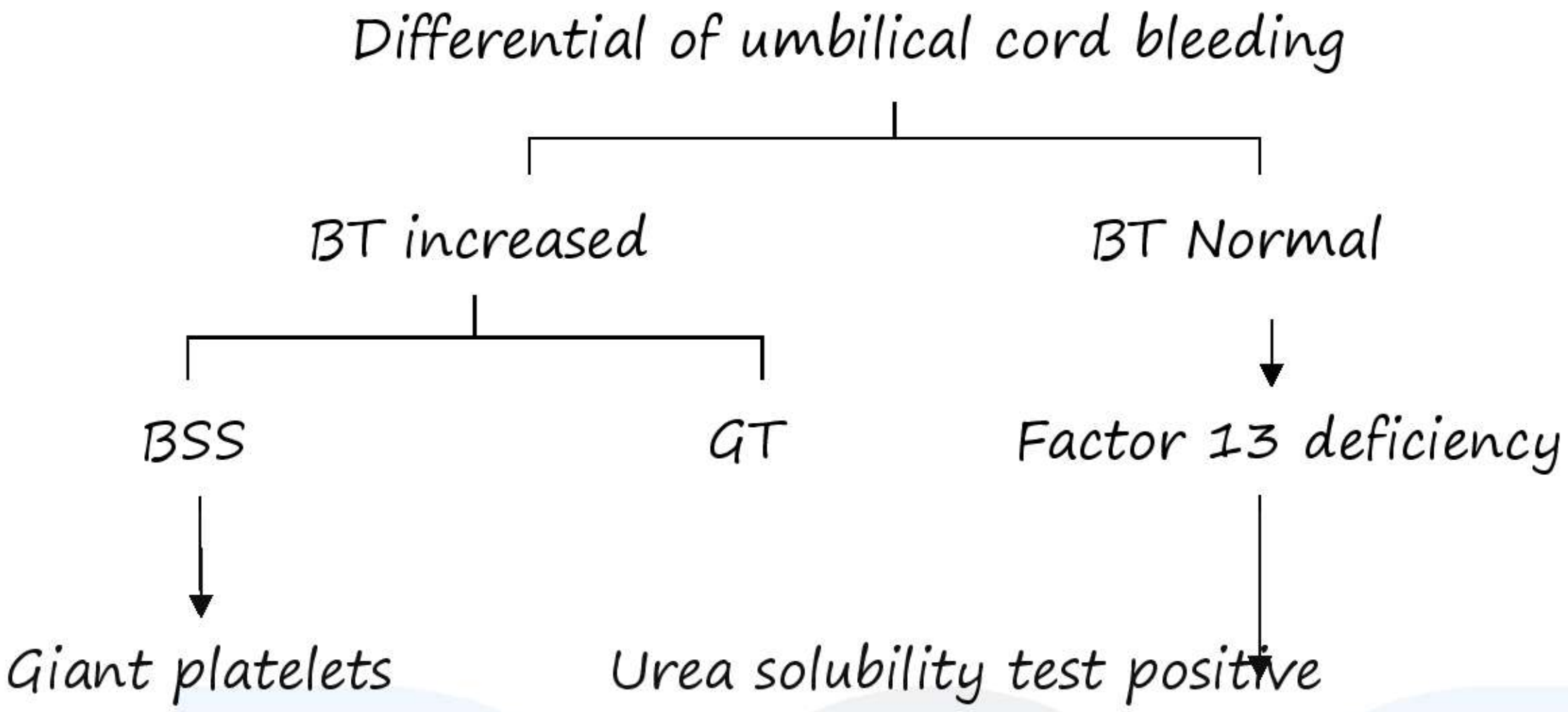

TUTORIALS
LOGIN FOR SUCCESS

MONOCLONAL GAMMOPATHY – MYELOMA & WALDENSTROM MACROGLOBULINEMIA

Classification 00:00:06

i. Myeloma

- Frank multiple myeloma
- Smoldering myeloma
- Monoclonal gammopathy of undetermined significant (MGUS)
- Solitary plasmacytoma
- Plasma cell leukemia

ii. Walden Strom macroglobulinemia

AfraTafreeh.com

- B cells neoplasm
- Affect 60 -70
- Characteristically sentence IgM to caused hyper viscosity syndrome known as Walden Strom macroglobulinemia
- Proliferation of lymphocytes, plasma cells, most cell known as lymphoplasmacytic cell
- All causes of lymphoplasmacytic lymphoma are insulated with acquired mutation MYD 88
- Kidney involvement is rare
- Heavy & light chain synthesis is balanced
- No bone destruction
- IgM results in hyper viscosity syndrome

AfraTafreeh.com

- Marrow infiltration causes anemia due to w/d angulation IgM

*** most common cytogenetic abnormality is deletion of chromosome 6q

- Hyper viscosity -causes acrocyanosis, Raynaud phenomenon, neurologic problem, bleeding cryoglobulinemia

i. Myeloma 00:07:38

- Post germinal center - released B cell - which mature into plasm cell in peripheral blood

Cytogenetics

- t (11,14) → cyclin D1, IgH --- good prognosis
- t (6,14)→ cyclin D3
- deletion 13 (most common mutation) --- poor progression
- increased proliferation of plasma cells more than 10% of bone marrow cells

plasma cells – produce excess immune globulin

-most commonly IgG heavy chains

Multiple myeloma – light chains ^ -> ^3 & ^6 lead to K & ^ light chains excreted in mine called Bence jones proteins

Kidneys _ proximal convoluted tubules almost light chain of immunoglobulin -called light chain deposition diseased known as myeloma kidney

Calcium – hyperparathyroidism occur in multiple myeloma leads to increased calcium in plasma

Infection – high chances to infection

-Most common causes of death in multiple myeloma

Pathogenesis of multiple myeloma

- Proliferation & survival of tumor cell are dependent on cytokine Il-6
- High serum IL-6 level is a sign of poor prognosis
- Myeloma tumor cells release MIPIK (macrophage inflammatory protein 1k) for two functions
  1) H increases expression of receptor activator of NF -KB ligand (RANKL) by bone marrow stromal cells to activate osteoclasts & causing bone resorption & hypercalcemia
- Activate modulation of the WNT pathway which inhibit osteoblast (that is why serum alkaline phosphatase level is normal in multiple myeloma

  *** 2nd most common cause of kidney damage in multiple myeloma is hyperkalemia
- Anemia occurs due to absence of erythroid precursors

AlfaTahrir.com
TUTORIALS
LOGIN FOR SUCCESS

AfraTafreeh.com

- Multiple myeloma – plasma cells > 10% +monoclonal protein > IgG > 3g/dl + hypercalcemia + renal diseases+ anemia + bone lysis

Criteria 00:23:12

- Asymptomatic myeloma -> plasma cell > 10% + monoclonal protein > 3g/dl smoldering myeloma (no symptoms)
- Monoclonal gammopathy of undetermined significance (MGUS) -> plasma cell + 10% monoclonal protein < 3g/dl

1 %

MUGS ⟶ multiple myeloma

Convert to

Solitary plasmacytoma two types 00:27:03

i. Bony

ii. Extramedullary

SLIM criteria – Also used to diagnosis myeloma

- Plasma cell> 60%
- No M protein, no hyperkalemia, nor renal disease, no anemia, no bone lesion
- Light chain uninvolved

⟶ >100

Light chain uninvolved

- MRI > mm lesion

Plasma cell leukemia criteria

- Plasma cell > 20%
- Plasma cell > $2x10^9$/L

i. Peripheral smear of multiple myeloma

- Rouleaux formation – characteristic due to red cell sticking by M proteins
- Background bule due to excess immunoglobulin

ii. Bone marrow aspirate

- 10% plasma cells
- Russell bodies – accumulated immunoglobulins in nucleus
- Mott cells, monocular cells – plasma cells with multiple grape like bluish cytoplasmic droplets
- Flame cells -seen in IgA myeloma there are plasma cells with fiery red cytoplasm

iii. Protein electrophoresis

- Monoclonal peak is observed due to Y gammopathy
- Quantification also identity type of light & heavy chain.

AnaTareem.com
TUTORIALS
LOGIN FOR SUCCESS

AfraTafreeh.com

LANGERHANS CELL HISTIOCYTOSIS

Molecular genetics

- BRAF mutation -most common
- It is a spectrum of proliferation of a special types of immature dendritic cell knowns as Langerhans cell

Types of Langerhans cell Histiocytosis

a. Eosinophilic granuloma
b. Hand- Schuller – Christian diseases
c. Multifocal multisystem disease Letterer sieve syndrome

a. Eosinophilic granuloma

i. Pulmonary Langerhans histiocytosis leads to interstitial lung disease
ii. Unifocal lesion most common presentation is calva rial defect

TUTORIALS LOGIN FOR SUCCESS

b. Hand Schuller Christian diseases

Traid bone lesion (calvaria bone defects

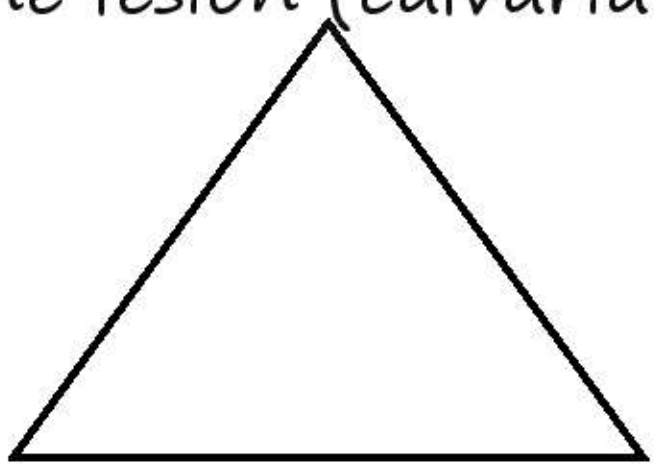

Diabetes insipidus exophthalmos

(Due to involvement of pituitary)

Letterer sieve syndrome

- Poor prognosis occurs in < 2 years of age
- Seborrheic lesion, hepatosplenomegaly, rash, bone destruction

Microscopic feature of Langerhans cell histiocytosis

00:05:59

a. Eosinophils
b. Langerhans cells → have abundant, often vacuolated cytoplasm & vascular nuclei containing linear grooves or folds
c. Bir beck granules → present in cytoplasm of Langerhans cells which are Penta laminar tubules with a dilated terminal end producing a tennis racket like appearance on electron microscopy
d. Tumor cells express CD1a, HLA-DR, S-100
e. Bir beck granules contain langerin [CD 20170].

AfraTafreeh.com
DX TUTORIALS
LOGIN FOR SUCCESS

AfraTafreeh.com

SECONDARY HEMOSTATIC PLUG AND ITS DISORDERS

Extrinsic pathway & intrinsic pathway

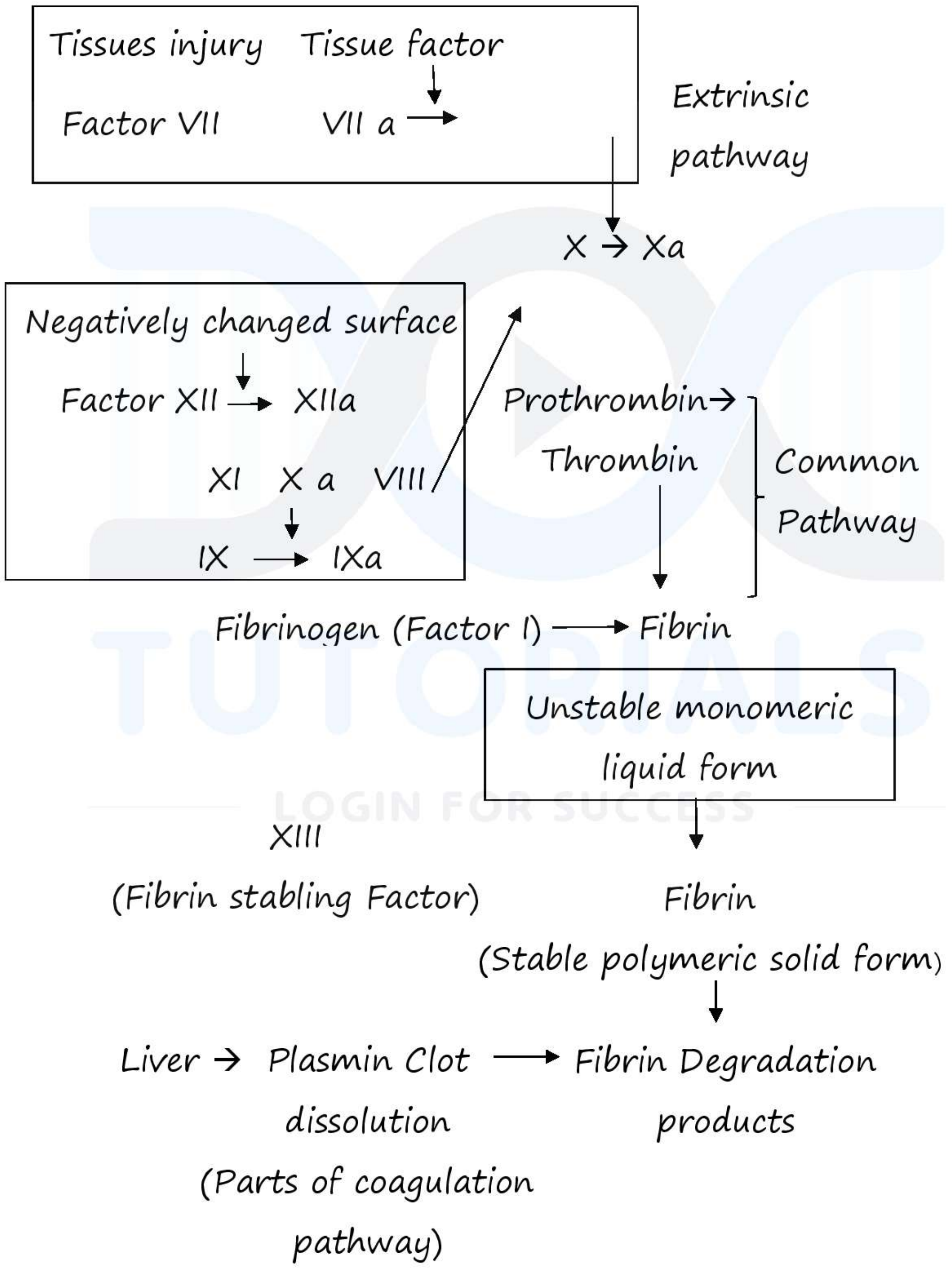

- Coagulation factors involved in Intrinsic pathway

- Factors 12.11.9.8

In common pathway – 10

5

2

1

(Pneumonic – Rule of half -10/5/2/1)

Prothrombin time 00:03:06

Assay involved the extrinsic pathway and common pathway of coagulation

Addition of Thromboplastin to a test tube

↓

Extrinsic pathway

↓

Common pathway

↓

(Prothrombin → Thrombin)

- Bleeding stops spontaneously because reflex was construction due to endothelin released from damaged endothelium

Major cut

↓

Sub endothelial collagen exposed

↓

Platelet adhesion

↓

Platelet aggregation [Plt -plt] →

↓

[Plt –(a granules) \y] — V. VIII. fiber → Ca^+

↓ ⊕

DX TUTORIALS LOGIN FOR SUCCESS AfraTafreeh.com

AfraTafreeh.com

Coag pathway

↓

Fibrin (glue/cement)

↓

Plt + ply – fibrin 9 w hemistich plug)

Coagulation pathway

Coagulation pathway

Intrinsic	Extrinsic
Intrinsic	M/C – (In vive)
M/C in vitro	PT = 11-16 sec
oPTT +30-40 sec	Tissue injury
negatively charged surface	Tissue
(Glow, Silica, Koolin	thromboplastic
XII (Hagman factor	VII
contact factor)	
	VIIa

TUTORIALS
LOGIN FOR SUCCESS

Thromboplastin

- Type of extrinsic tissue factor
  - Source -Rat Brain /Rabbit Brain/Human Brain
  - Thromboplastin vials have ISI No. (International standardized (index)based on the source of thromboplastin
  - Standardized ISI closest to I are of better quality
- Prothrombin time of test is compressed with PT of control Normal PT= 12-16 sec

- Abnormal or prolonged PY is PTC * 2 sec= PTT

  i.e., if PT of test more than w sec of PT of control

  Nowadays PY is reported as Pt-INR

  Where INR _ International Normalized Ratio

$$INR = \frac{PTT}{PTC} \quad [S]$$

PTr = PT of Test

PT c = PT of control

Activated intrinsic pathway & common time (aPTT) 00:09:54

- Assay of Intrinsic pathway & common pathway
- Normal Range = 30-4- sec
- Prolonged aPTT if aPPT = aPPTC + 6 SEC

  i.e. is aPPT of test is more than 6 sec of aPTT of control

Thrombin time 00:13:03

- Assay of common pathway
- Time taken for clot formation addition of thrombin

$$\text{Fibrinogen} \xrightarrow{\text{Thrombin}} \text{Fibrin}$$

- TT assays only Fibrinogen I.e factor Normal Thrombin time 12-14 sec

AfraTafreeh.com

Scenarios

i. Patient ⎤ Factor 7 deficiency (extremely Rare)
aPTT N ⎦

- vitamin K dependent factor – Factor 2,7,9,10
  protein c & Protein s
- warfarin – antagonist of vitamin K- causes of depletion of vit k dependent factors
- Earliest to fall is Factor VII because of its shortest t ½ 6 hours

↓

Next to drop is factor IX levels
(t ½ = 24 hours)

So warfarin monitoring is done by PT _ INR to detect factor 7 deficiency at the earliest

ii. PT N ⎤ Factor 12/11/9/b deficiency
aPTT ⎦

Factor XII deficiency

- Manifests as thrombosis
- Never produces Bleeding
- This was discovered by a scientist named Hageman hence Factor XIII is called Hageman factor.

Factor VIII, IX and XI deficiency manifests as Hemophilia

Hemophilia types

- A → Deficiency of Factor VIII
- B → IX
- C → XI

A & B are X linked Recessive (XLR)

Hemophilia type c is Autosomal Recessive (AR)

To differential hemophilia type A, B and C

Do factor assay at 2-4 c

- VIII — Type A
- IX — Type B
- IX — Type C

iii. PT increased
aPPT increased] Common pathway defect factor 10/5/2/1

- Factor v deficiency results in para hemophilia
- Factor X is deficient in hematological manifestations of Amyloidosis

Factor I deficiency causes prolonged thrombin Time

Protocols of coagulation studies 00:24:00

- Anticoagulation of choice for coagulation studies 3.2% Trisodium Citrate

AfraTafreeh.com

AfraTafreeh.com

- Don't use Glass tubes for coagulation studies (Use plastic Tubes)
- Sample must be processed withing 2 hours because in VWD, t ½
  Of factor 8 reduce to 2-5 hours. So, coagulation tests should be performed
  Within 2 hours of sample collection
- Keep the Blood sample at Room temperature (20-25 $_{o}$ c) because cold will activate platelets and some coagulation factors

↓ Exceptions

For ALPA and Factor assays, sample to be kept at 2-4 $_{o}$ c

- Sample for coagulation studies – platelet poor plasma (Because alpha granules of platelet contain Factor 5 & Factor 8)

TUTORIALS
LOGIN FOR SUCCESS

Platelet poor plasma

- Obtained by centrifuging Blood till Platelet counts decrease to less than 10,00 Remember -Rule of two in Hematology
- 2 Autosomal Dominant condition
  - Von Wille brand Disease
  - Hereditary Spherocytosis

ANTICOAGULANT MOLECULES

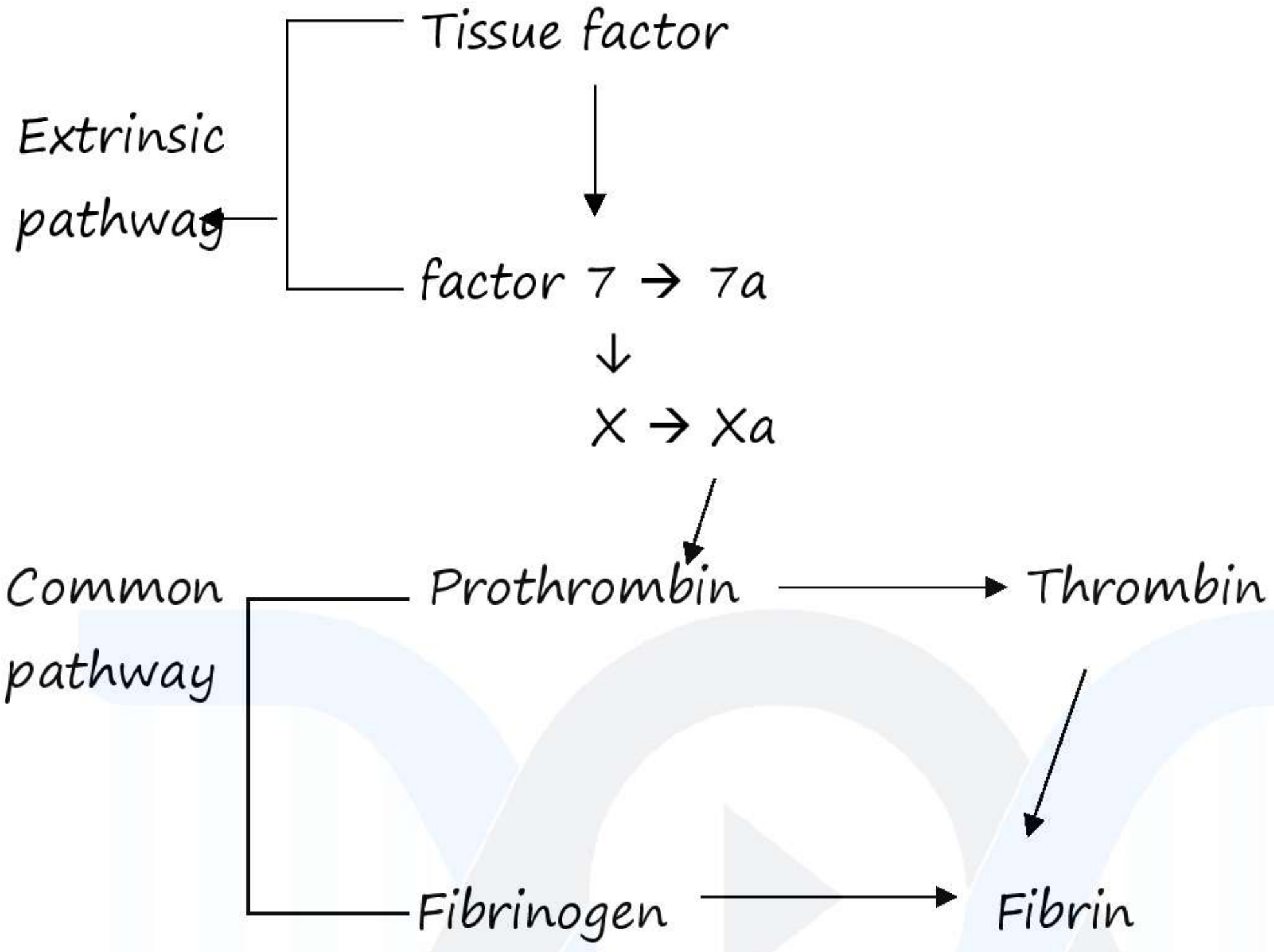

Controllers of Coagulation Pathway

AfraTafreen.com

i. Tissue factor Pathway Inhibitor (TFPI)

Binds of Tissues factor

Factor 7a

Factor Xa

↓

And Blocks Coagulation pathway

↓

i.e. Extrinsic & Common pathway Blocked

- TFPI is the First Controller of Coagulation pathway

ii. Second Controller – AT III _ Anti Thrombin III

AT III

- Thrombin involved in

TUTORIALS
LOGIN FOR SUCCESS

AfraTafreeh.com

a. Coagulation Pathway – conversion of Fibrinogen to Fibrin
b. Activates TAFI (thrombin activatable fibrinolysis inhibitor)
c. Role in Kallikrein pathway
d. Activates PPAR (Peroxisome proliferate activated receptor)

Causing inflammation

- Therefore, thrombin is the master regulator of coagulation system

Heparin Combines with AT III

↓

Heparin + AT III

↓ (–)

Thrombin (Factor 2) Factor X

Monitoring of Heparin

- Factor Xa and Thrombin -part of common pathway
- Implies both PT and aPTT are Raised But aP TT I is more sensitive in picking up deficiency of Factor Common pathway
- So Heparin monitoring is done by measuring aPTT
- Remember – Warfarin is monitored by PT-INR

Intrinsic pathway:

-ve Charge
↘
XII → XII a
↓
IX → XI a
↓ VIII

Common pathway:

Factor X → X a
↓ V
Prothrombin → Thrombin
↓
Fibrinogen → Fibrin

Controller

i. Thrombomodulin – As the name suggests

Thrombomodulin modulates Thrombin

Thrombin – Pro coagulant

But Thrombomodulin + Thrombin

↓ (+)

Protein C

↓ Protein S (cofactor of protein C)

Breaks Factor V and VIII

- Thrombomodulin is present in endothelium of all Blood vessels except Brain are higher So risk of Thrombosis (Stroke) is higher in CNS than Periphery
- There is Inactivation of Factor V (common pathway) & Factor VII (Intrinsic pathway)

AfraTafreeh.com

AfraTafreeh.com

GIST of the Topic

Anti coagulant molecule

a. TE.PI
b. Thrombomodulin
c. Antithrombin III

Anti fibrinolytic Molecular

a. TAFI
b. PAI-1
c. Anti-plasmin

Remember: - Endothelium can act both as anti-coagulant & Pro coagulant

Applied pathology 00:14:34

i. Factor v Leiden

Thrombomodulin + Thrombin

↓ (+)

Protein C

↓ (−)

Factor 5,8

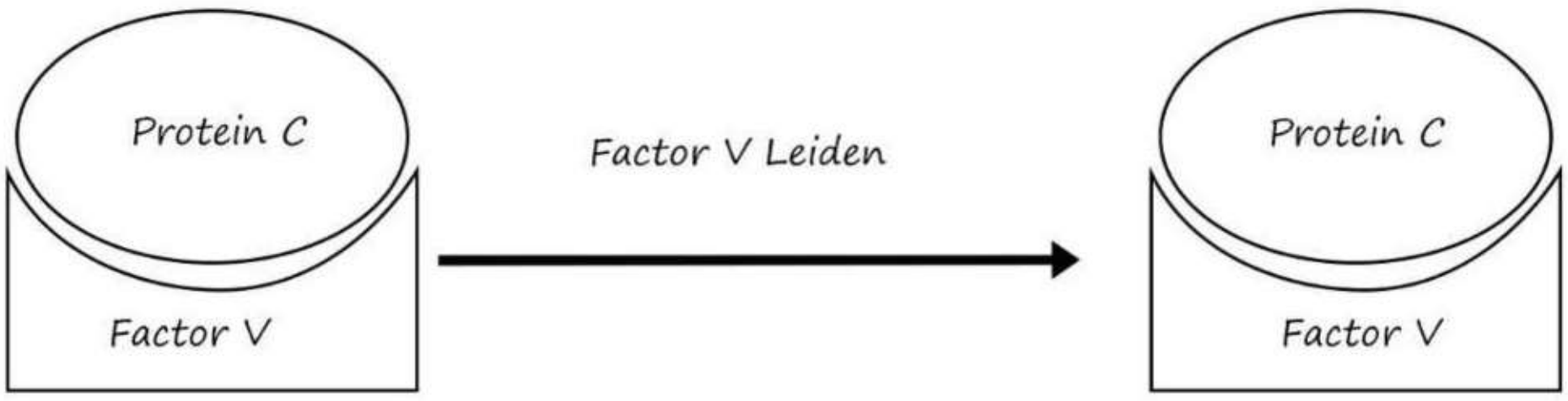

Activated Protein C (APC) binds to Factor V and inactivates it

APC cannot bind to Factor V

↓

No inactivation of Factor V

↓

Activated Protein C Resistant

- Mutation is a Single Nucleotide Polymorphism replacing Arginine with Glutamine at position 506

Arginine ⟶ Glutamine

Position 506

- It is the most common inherited cause of hypercoagulability

ii. Complication of Warfarin Therapy

- Warfarin-vit K antagonist Causes depletion of Vitamin K dependent factor
- Protein C & S are natural anticoagulant synthesized by liver
- Depletion of Protein C&S is responsible for the thrombotic side effect of Warfarin

AfraTafreeh.com
TUTORIALS
LOGIN FOR SUCCESS

AfraTafreeh.com

Warfarin

↓

Protein C,S

↓

No breaks on Factor V

↓

Thrombosis of dermal vessel

↓

Dermal necrosis (Dreaded complication of Warfarin use)

Common sites – Breast, things

- Levels of Protein c should be checked before Warfarin initiation patents with depleted protein C should not be administered warfarin

iii. Purpura Fulminans – Congenital deficiency of Protein C

iv. HIT and HITT

HIT- Heparin induced Thrombocytopenia

HITT – Heparin induced Thrombocytopenia with Thrombosis

a granules of Platelets release platelet factor 4 (PF4)

↓

Heparin strongly binds to PF4

↓

Heparin – PF4 complex formed

↓

IgG Antibody formed against this complex destroy platelets causing Thrombocytopenia (after approx..5 days of Heparin therapy)

- These IgG Ab -> may cause Activation of platelets

↓

Release of Micro particles

↓

Thrombin → Thrombosis

- HIT and HITT are more common with unfractionated
- heparin
- Warfarin and LMVJ Heparin are contraindicated in this syndrome
- Lepirudin and bivalirudin (direct Thrombin inhibitor) are anticoagulant of choice

AfraTafreeh.com
TUTORIALS
LOGIN FOR SUCCESS

AfraTafreeh.com

APPROACH TO FIBRINOLYTIC SYSTEM

Plasminogen

↓ +PA – tissue Plasminogen activator (released from Endothelium)

Plasmin

↓

Fibrin → Fibrin Degradation Products (FDP)

Factor XIII ↓

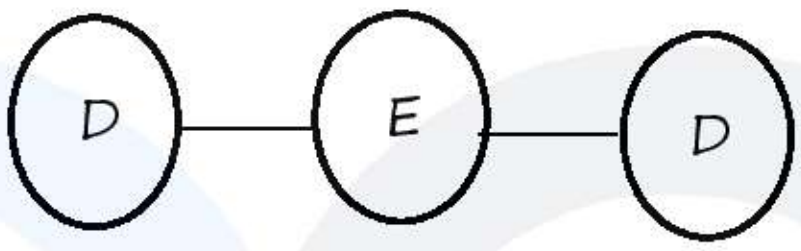

Linear molecule

Cross linked Fibrin → D -dimer

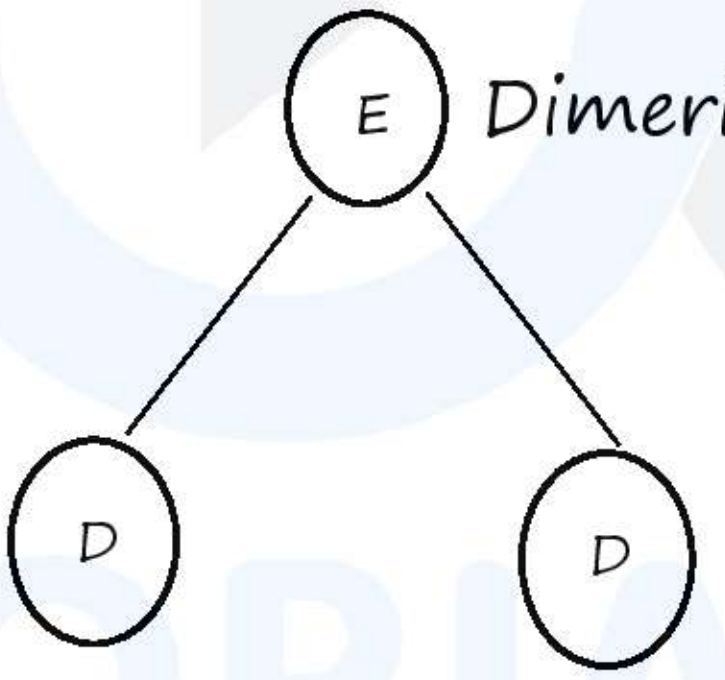

Dimeric structure

Anti fibrinolytic molecules 00:03:08

i. Plasminogen Activator Inhibitor (PAI-1)

↓

Control activity +PA

Plasminogen

↓ +PA ← (–)

Plasmin

↓

Fibrinolysis

ii. α 2 Anti – Plasmin

↓

Blocks plasmin → No Fibrinolysis

iii. Thrombin Activable Fibrinolysis Inhibitor (TAFI)

↓ Fibrin degradation products (FDP)

↓ Fibrin Resistant to plasmin

↓

Plasmin not able to lyse Fibrin

↓

No Fibrinolysis

Fibrinolytic molecules	Antifibrinolytic molecules
i. tPA	i. PAI-1
ii. Plasmin	ii. X2 Anti – Plasmin
	iii. TAFI

D- Dimer 00:09:11

- From breakdown of Cross-linked Fibrin
- Normal level should be [less than Age (year) X 10] ng/ml
- Normal D- Dimer is out of 500 ng/ml or less (or) 0.5 mg.ml or less or as FEV (Fibrinogen Equal

AfraTafreeh.com
DOC TUTORIALS LOGIN FOR SUCCESS

AfraTafreeh.com

- D – Dimer levels are tested by latex Agglutination test

  Raised level of D -Dimer seen in

  a. DVT

  b. Acute Pulmonary Thromboembolism

  c. DIC

- Negative Predictive value of D – dimer test approved for exclusion of acute Pulmonary Embolism
- Well's Score is used to predict the risk of Pulmonary embolism
- Most Sensitive test for DIC → FDP levels

  Most specific test for DIC → D – Dimer levels

- In Factor of XIII Deficiency cross linking of Fibrin does not occur so there is no break down to D – Dimer
- Condition with reduced level of D – Dimer
- Factor XIII deficiency

TUTORIALS
LOGIN FOR SUCCESS

IDIOPATHIC /IMMUNE THROMBOCYTOPENIC PUPURA

Idiopathic/immune thrombocytopenic purpura

00:01:43

- Antibodies are formed against platelets membrane Glycoprotein Gp1b or Gp1b/3a
- IgG antibody most common

Platele →

↓

Removed by spleen or killed by NK cells

↓

- Resulting Thrombocytopenia
- Megakaryocytic Hyperplasia in Bone Narrow

AfraTafreeh.com

Smooth forms of Megakaryocyte formed

[Endoduplication does not occur]

↓

Release of large platelets

- Bleeding Time prolonged
- PT and a PT are Normal

If Thrombocytopenia → 1st Rule out Drugs as the cause

AfraTafreeh.com

Diagnosis 00:06:26

Peripheral smear → Large platelets
↓
BM aspirate → Megakaryocytic Hyperplasia
↓
BM aspirate → Megakaryocytic Hyperplasia
↓
No other cause of Decreased platelets
No splenomegaly
↓

- Do ELISA to find Antibody against platelet
- Dictum – If splenomegaly is present – ITP is ruled out
- Recent update – H.Pylori's is implicated with ITP

Acute ITP	Chronic ITP
- Disease of childhood - Affects both sexes equally - Onset is abrupt - Many cases are preceded by viral illness - Viral interval between the Injection and onset of Purpura is 2 weeks	- More common form - Most common in adult women< 40 years (F:M ratio 3:1) - Can be associated with connective tissue disease, lymph proliferative disease, medication and injection (Hepatitis c Virus and HIV)

- Self – limited spontaneous Resolution in six months - 20% children (Those without Viral prodrome) have present Low platelet counts after 6 months	- Presentation – petechiae, ecchymosis easy bruising, bleeding from nose and gums, menorrhagia - Wet purpura (Blood blisters in mouth)

Treatment 00:08:23

- Majority of Acute ITP resolve spontaneously
- Initial treatment for patients without signification bleeding
- First line: - single dose I.V immunoglobulin (causes rapid rise in platelet counts) or short course steroids
- Newer Therapy – Intravenous anti – D therapy – only for Rh positive patients

Basis :-RBC's have D antigen

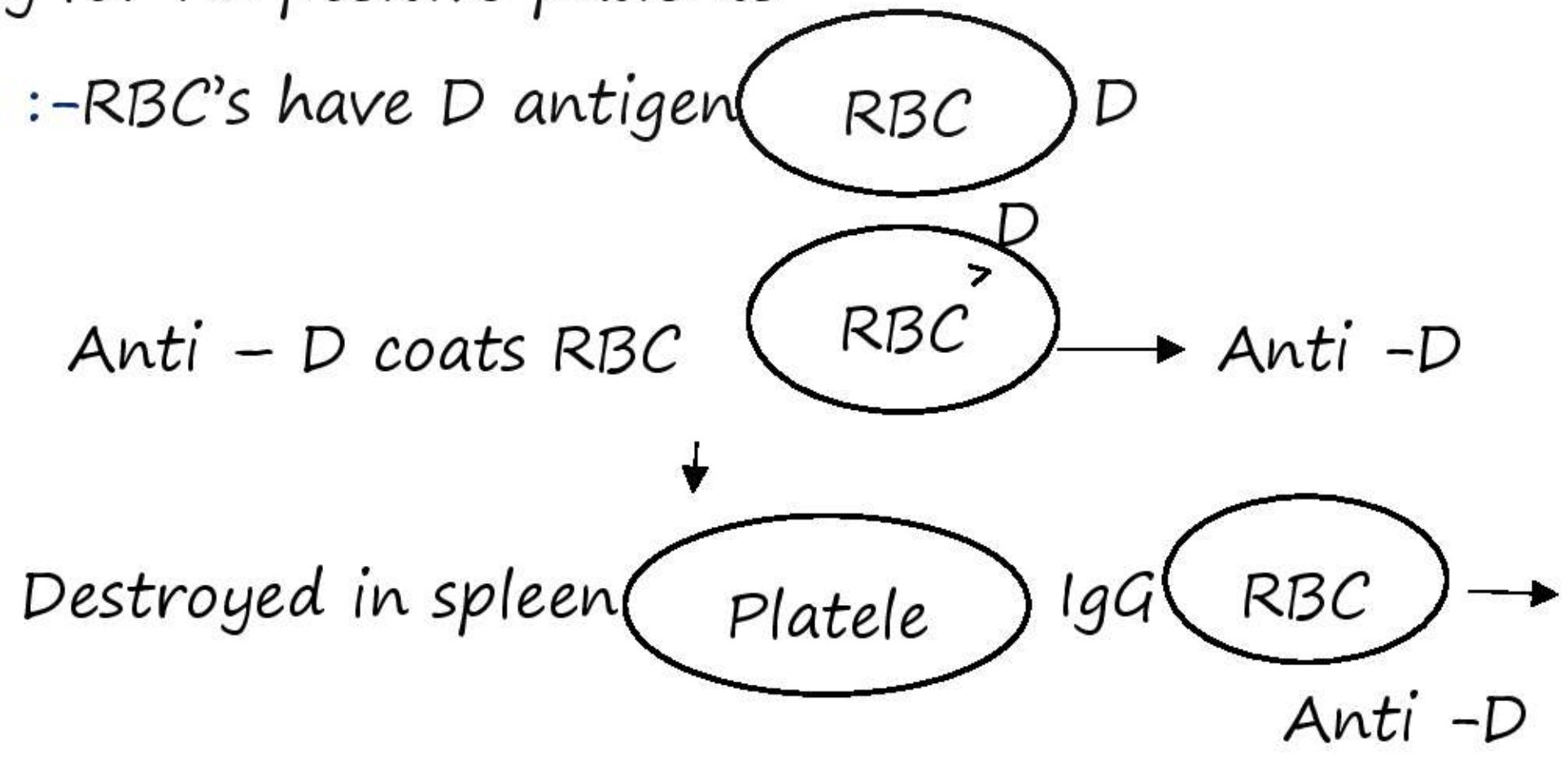

AfraTafreeh.com

Since RBC count is Higher RBCs are destroyed in spleen sharing Antibody coated platelets Patients with severe ITP and /or symptoms of bleeding. Hospital admission and combined therapy

- High – dose Glucocorticoids
- I.V Igg or anti Rho (D) therapy

Relapse - Splenectomy

Refractory Cases: - Thrombopoietin receptor agonists (Romiplostim and eltrombopag)

Remember

- Evans syndrome: - Autoimmune hemolytic anemia + ITP Drugs causing Thrombocytopenia –Quinine, Quinidine, Vancomycin.

TUTORIALS
LOGIN FOR SUCCESS

APLA AND FACTOR 8 INHIBITORS

- Antiphospholipid antibodies (APLA)

Causes of isolated a PTT prolongation

- Hemophilia A, B, C
- Acquired factor VIII inhibitors
  ↓
  - Autoimmune disorder
  - F>M
  - Present with Bleeding And prolonged aPTT
- APLA Anti phospholipid
  ↓
  Antibody against phospholipids of cell

AfraTafreeh.com

Anti phospholipids Antibody syndrome

00:01:24

Antibody are targeted against Phospholipid

↓

Phospholipoid damage (vily charged)

↓

Intrinsic pathway activated

↓

Consumption of coagulation factor & Thrombosis

↓

↑ aPTT

TUTORIALS
LOGIN FOR SUCCESS

AfraTafreeh.com

The three known APLA are

- Anti-cardiolipin Antibodies IgG or IgM → Inhibit protein C → Thrombosis
- Lupin anticoagulant → Converts prothrombin → Thrombin → Thrombosis
- anti β-2 Glycoprotein 1 antibodies → Cause endothelial damage → Thrombosis

Clinical features of APLA

Vascular Thrombosis

Recurrent arterial or Venus Thrombosis

- Venous Thrombosis (More common)
  - DNT is the M/C manifestations
  - Pulmonary embolism
  - Pulmonary hypertension
  - livedo reticularis
- Arterial Thrombosis (less common)

Pregnancy complications

- Repeated pregnancy loss
- >3 loses of fetus < loss of gestation
- Last fetal loss(>10wks)
- Premature Birth < 34 weeks

Isolated Prolongation of aPTT

Antibody against Coagulation factors	Deficiency of Coagulation factor

Mixing Test

- Mixing of patient's plasma with Fresh Frozen Plasma 1:1 ratio
- (FFP contains all the coagulation factors

Deficiency of factors

↓

↑ aPTT

↓

Mixing test



↓

aPTT becomes Normal

↓

Hemophilia

Antibodies factors 8

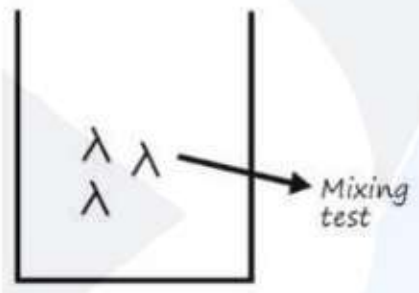

↓

↑ aPTT

↓ Mixing test

Initially aPTT becomes (N)

Because of addition of coagulation factors form FFP

↓

After sometime Antibodies destroy

Normal plasma factor VIII also

↓

↑ aPTT

↓

Factor VIII inhibitor present

AfraTafreeh.com
TUTORIALS
LOGIN FOR SUCCESS

AfraTafreeh.com

In APLA

↑ aPTT

↓ Mixing test

Present Prolongation aPTT become-antibodies
Are present against phospholipids which is not
Corrected by addition of Normal Plasma

↓

So Persistent Prolongation of aPTT implies
ALPA

Difference between apla and
factor8 antibody

factors 8 inhibitors	APLA
-presents as Bleeding - antibodies are time dependent they have been measured at 2 hourly interval ↓ special test to measured factor 8inhibitor antibodies ↓ Nijmegen Bethesda assay	- presents as Thrombosis -most important APLA is β2glycoprotein I ↓ Anti β2 gp I cause endothelial injury ↓ platelet plug ↓ coagulation pathway - so, they have Thrombocytosis - special test for APLA - dilute Russell viper venom test (DRVVT)

	This test is very sensitive for phospholipids

Venoms used in Hematology

- Dilute Russell viper test
- Replicate time (from Bothrops snoke)

Reptilase Time

- Reptolase behaves like thrombin but is not affected by AT III

Heparin

+

AT III

↓

Thrombin

- Reptilase time is used to differentiate causes of prolonged Thrombin time (TT)

Caused of prolonged TT

- A fibrinogenemia
- HITT

- Reptilase is not affected by Heparin so if Heparin is the cause of prolonged TT. It corrects with addition of Reptilase

AfraTafreeh.com
TUTORIALS
LOGIN FOR SUCCESS

AfraTafreeh.com

TT ↑

↓

Check of fibrinogen levels

↓

Reptilase time

- If prolonged
  ↓
  Fibrinogen deficiency
- Normal
  ↓
  Cause was Heparin

TUTORIALS

LOGIN FOR SUCCESS

THROMBOTIC MICROANGIOPATHIES

- RBC – Thrombus (Schistocytes or Helmet cells due to Macroangiopathy)

Thrombus

1° Hemostatic plug plt + plt + plt
↓
Consumption of platelet
so
Platelets count Increases
Seen in
HUS | TTP

2° Hemostatic plug plt+–plt+plt
↓
consumption of platelets & coagulation factor
↓
Plt ↓, PTT ↑, PTT ↑
↓
DIC

← All show Schistocytes →

AfraTafreeh.com
TUTORIALS
LOGIN FOR SUCCESS

AfraTafreeh.com

Hemolytic Uremic Syndrome 00:03:36

Hemolytic Uremic syndrome

HUS

- Pediatric (2.5 yrs.)
- GIT manifestation – Diarrhea a/k/a D+ve
- M/c/c – E.coli [O157-H7]

↓

Toxin – Shiga Toxin/Vero toxin

↓

Causes endothelial injury

↓

1° Hemostatic platelet plug formed

Atypical HUS

- Adults
- No GIT Manifestation
- No Diarrhea Causes -> Deficiency of Factor H (M/C) Factor I And CD46

↓

Complement pathway not controlled

↓

Excess compliments causes Endothelial injury (→ 1° Hemostatic platelet plug formed)

- Atypical HUS is now called as Compliment pathway

TUTORIALS
LOGIN FOR SUCCESS

1° Hemostatic Platelet plug formed

Plt	Schistocytes	Hb
Thrombocytopenia	(Intra vascular Hemolysis) ↓ Macroangiopathic Hemolytic Anemia	↓ Hemosiderin ↓ Hemosiderin laden cells in urine ↓ Renal Dysfunction

Triad of RAT in all Thrombotic Microangiopathies

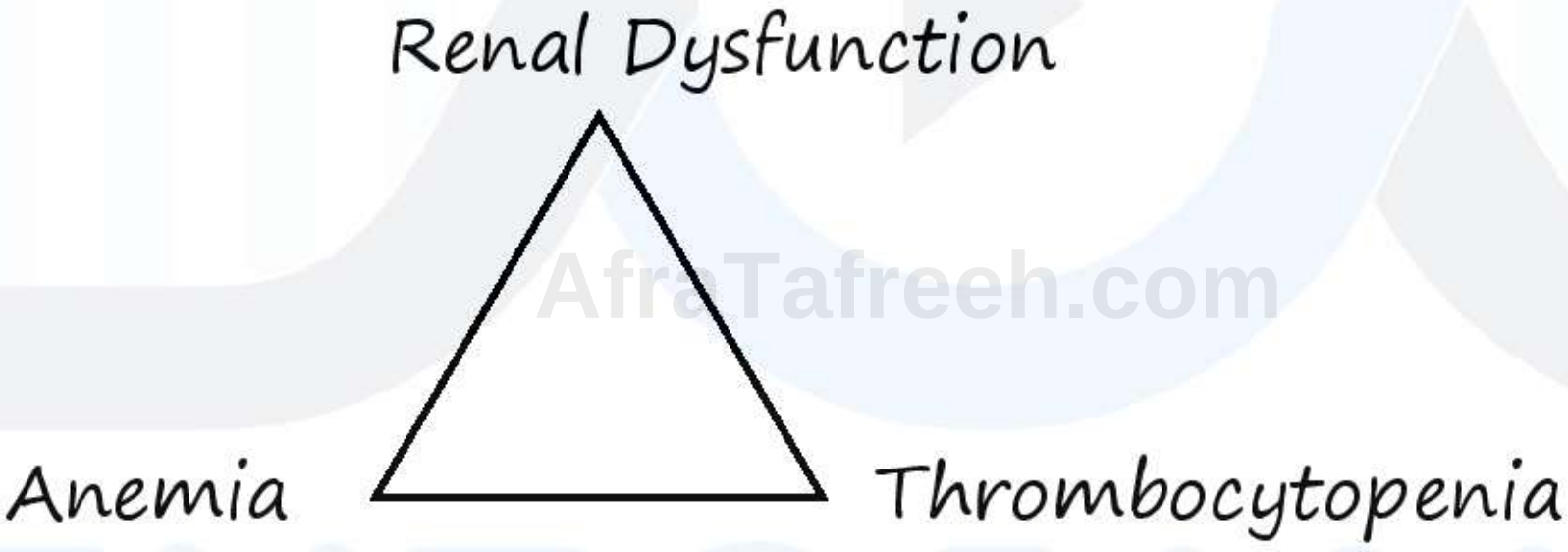

AfraTafreeh.com
TUTORIALS
LOGIN FOR SUCCESS

<u>C/F of typical HUS</u>	<u>C/F of Atypical HUS</u>
– Triad of RAT – CNS involvement, fever } less common TTP	– Some as Pentad of TTP

AfraTafreeh.com

Thrombotic thrombocytopenic purpura 00:08:27

- Cause- Deficiency of ADMATS

↓

Ultra long Multimers of VWF

Platelets stick to Multimeric of VWF

i.Renal dysfunction	ii. Macro angiopathic memocytic anaemia	iii.↓ platelet count (thrombocytopenia)	iv.Fever v. Neurological involvement

So, pentad of TTP

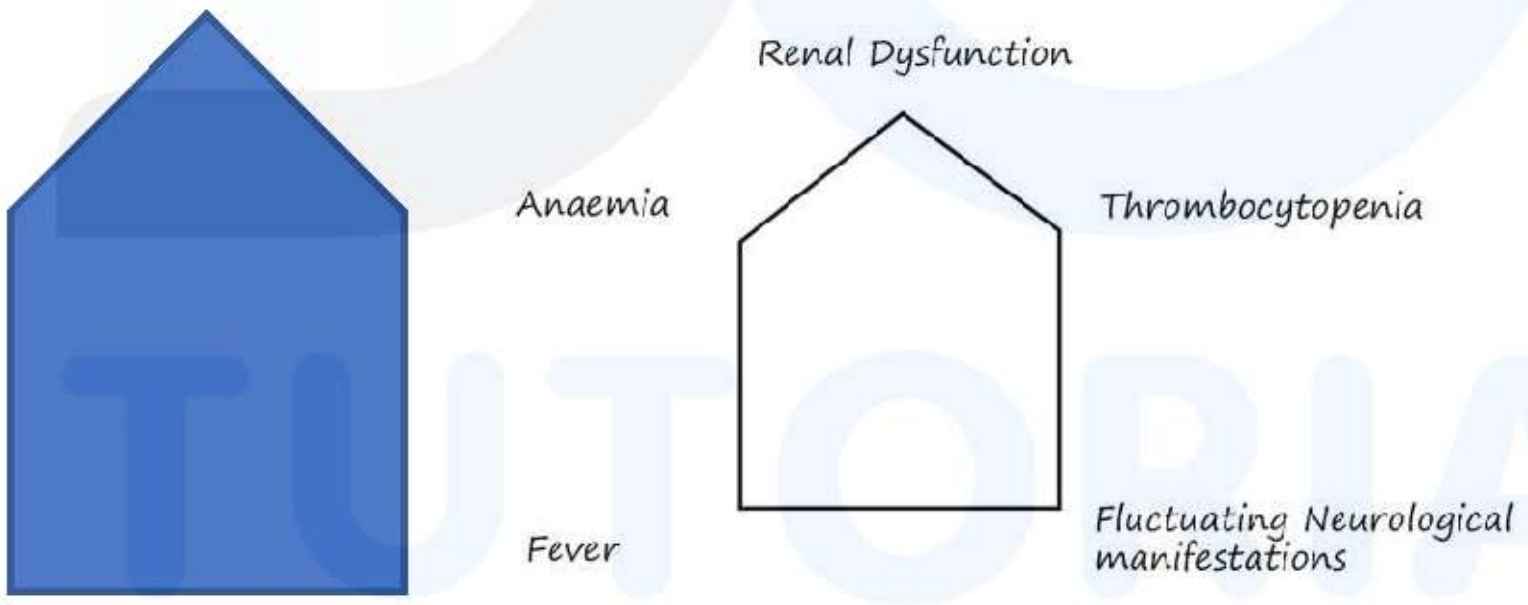

- Note: _ PT and aPTT are characteristically Normal in TTP or HUS Inherited TTP -> i.e., Inherited deficiency of ADAMTS is seen un Upshow-Schulman Syndrome
- To differentiated between TTP an Atypical HUS with same clinical

Features

↓

look for ADAMTS on Flow Cytometers

In TTP　　　　(N)in Atypical HUS

Approach to Macroangiopathic Hemolytic Anemia (MAHA) 00:12:55

i. Peripheral smear showing schistocytes

ii. Platelet count, PT and a PTT

- Plt decrease PT, a PTT (N)
  - HUS
    Infection Exertive
    complement activation
  - TTP
- plt increases PT, aPTT
  ↓
  DIC

AfraTafreeh.com
TUTORIALS
LOGIN FOR SUCCESS

Updated in TTP

- TTP decreases ADAMT -> persistence of Ultra large multimers od vWF Si If patients of TTP required Blood Transfusion
- They should be transfused with cryopoor plasma to present thrombus Formation since cryoprecipitates contains vWF

AfraTafreeh.com

HEAVY CHAIN DISEASE

Types of heavy chain disease 00:00:05

a. Alpha (α)
b. Mu (μ) heavy chain disease
c. Gamma (γ) heavy chain disease

i. α heavy chain disease 00:01:15

a. Seligman disease another name
b. Due to excess IgA

Clinical feature

a. Yong age
b. Immune proliferative small intestinal disease presentation
c. H pylori, C, jejune infection are common

ii. μ Heavy chain disease 00:02:21

- Due to excess IgM

Clinical feature

- Elderly associated with chronic lymphoid leukemia positive for Bence jones in urine cytoplasmic vacuolation positive is μ heavy chain disease
- Cytoplasmic vacuolation of lymphocytes or plasma cells

iii. γ Heavy chain disease 00:03:58

- Another term – Franklin

Clinical feature

a. Palatal edema
b. Waldeyer ring
c. Elderly people

AfraTafreeh.com
TUTORIALS
LOGIN FOR SUCCESS

AfraTafreeh.com

MDS

Pathogenesis 00:00:30

- Dysplasia in myeloid lineage

Characteristics of MDS

i. Cytopenia -Hb < 10 gm

Absolute Neutrophil count → < 180 dm

Platelet count < 1 lakh

ii. Dysplasia
- dyserthropoiesis
- dysmyelopoiesis
- dysmegakaryopoiesis

(can lead to AML)

iii. Ineffective erythropoiesis

iv. Obsess in elderly

WHO 2016 Classification 00:03:40

i. MDS with single unease dysplasia

- Dysplasia in unease
- Peripheral Blood Blast < 1 %
- Bone MARROW Blast < 5 %

ii. MDS with multiline ages dysplasia

- More than 1 induced
- Peripheral Blast < 1 %
- Bone Marrow Blast < 5 %

TUTORIALS LOGIN FOR SUCCESS

iii.MDS with Excess Blast

i. MDS with Excess Blast → Peripheral Blast → 1-5 % Blast

1

→ Bone Marrow Blast → 5-9 % Blast

ii. NDS with Excess Blast → peripheral Blast → 5-10 %

2

Bone Marrow Blast 10-19 %

iv. MDS with Ringed Sidioblasts

i. MDS with Ringed Sideoblast

- Ringed Sideoblasts > 15 %

ii. MDS with Splice Rome mutation

- SF3 B1 Mutation
- Ringed Sideoblast 5 %

AfraTafreeh.com
TUTORIALS
LOGIN FOR SUCCESS

V. MDS with unclassifiable

- Peripheral Blast → 1%
- Bone Marrow Blast < 5 %

VI. MDS with Isolated 5 q dilation

- 5 q dilation is associated

VII. Refractory cytopenia childhood

AfraTafreeh.com

APPROACH TO ANEMIA AND UNDERSTANDING HEMATOCRIT, ESR AND MCV (RED CELL PARAMETERS PART – I)

Classification of Anemia on Etiology 00:00:05

Nutritional Anemia

i. Iron deficiency

ii. B12 & Folic acid deficiency

Hemolytic Anemia

i. Extravascular Hemolysis

ii. Intravascular Hemolysis

I. Extravascular Hemolysis 00:01:54

i. Membrane defects

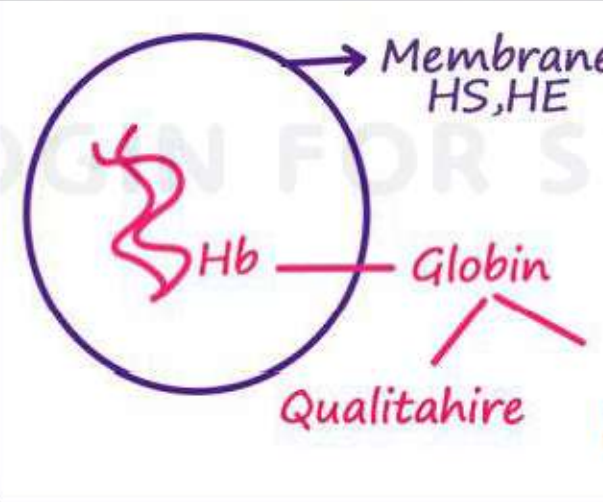

Fig: 1

- Hereditary spherocytosis
- Hereditary elliptocytosis

ii. Globin defects (Haemoglobinopathies)

a. Qualitative defects

- Sickle cell anemia
- Hemoglobin C

b. Quantitative

- α – Thalassemia
- β – Thalassemia

c. Enzyme defects

- G6PD deficiency
- Pyruvate kinase deficiency
- Pyrimidine 5 nucleosidase deficiency
- Lead poisoning causes pyrimidine – 5 nucleosidase deficiencies

d. Antibody defects

- Autoimmune hemolytic anemias

II. Intravascular Hemolysis 00:09:00

a. Paroxysmal Nocturnal Hemoglobinuria (PNH)

- Clinical feature

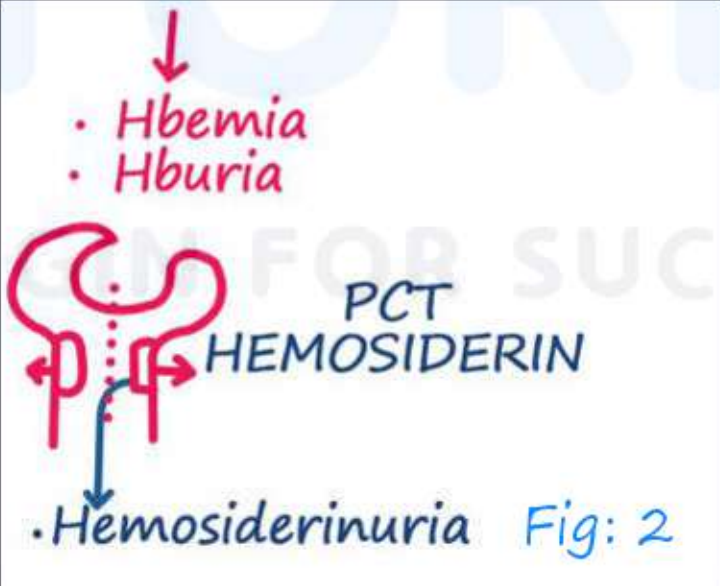

Fig: 2

- Acquired Hemolytic Anemia,elderly - PNH

b. Thrombotic microangiopathy i. Hemolytic uremic Syndrome

i. Hemolytic uremic syndrome

ii. Disseminated Intravascular coagulation

iii. Thrombotic Thrombocytopenic purpura

AfraTafreeh.com

c. Snake bites & Toxins

- G6PD Deficiency Causes Intravascular and Extravascular Hemolysis
- Sickle Cell Anemia also Causes Both Hemolysis But Extravascular More than Intravascular Hemolysis
- Clinical features of Extravascular Hemolysis

i. Splenomegaly

ii. Increase is indirect Bilirubin

iii. Increase is urinary urobilinogen

iv. Increase is fecal urobilinogen

v. Pigmented gall stones

- Clinical Features of Intravascular Hemolysis

i. Hemoglobinemia

ii. Hemoglobinuria

iii. Hemosiderin

iv. lower Back Pain

Reticulocytotic is common in hemolytic Anemia

Hypo proliferative Anemias 00:18:54

i. Aplastic Anemia-hematopoietic No cells are produced

ii. Pure Red cell Aplastic Anemia

- Reticulocyte want increased - Hemolytic Anemia
- Reticulocyte want decreased - Hypo proliferative Anemia
- Reticulocyte want Normal or decreased - Nutritional Anemia

Blood loss Anemia (hemorrhagic Anemia)

i. Acute blood loss

ii. Chronic blood loss

Parameters Useful to Identify Anemic

- Chronic blood loss Parameters Useful to Identify Anemia
- MCV [Mean corpuscular volume]
- It's approximate volume of a line Red cell
- Normal value 92 + 9fL

  <80 fL → Microcytic

  >100 fL → Macrocytic

PCV (packed cell volume / Hematocrit]

- Total volume of all Red Blood cells.
- MCV X RBC = PCV
- Macrocytic cells Packed cell Volume is measured by wintrobe method Microcytic cells packed cell volume is measured by capillary tubes, This is a better method

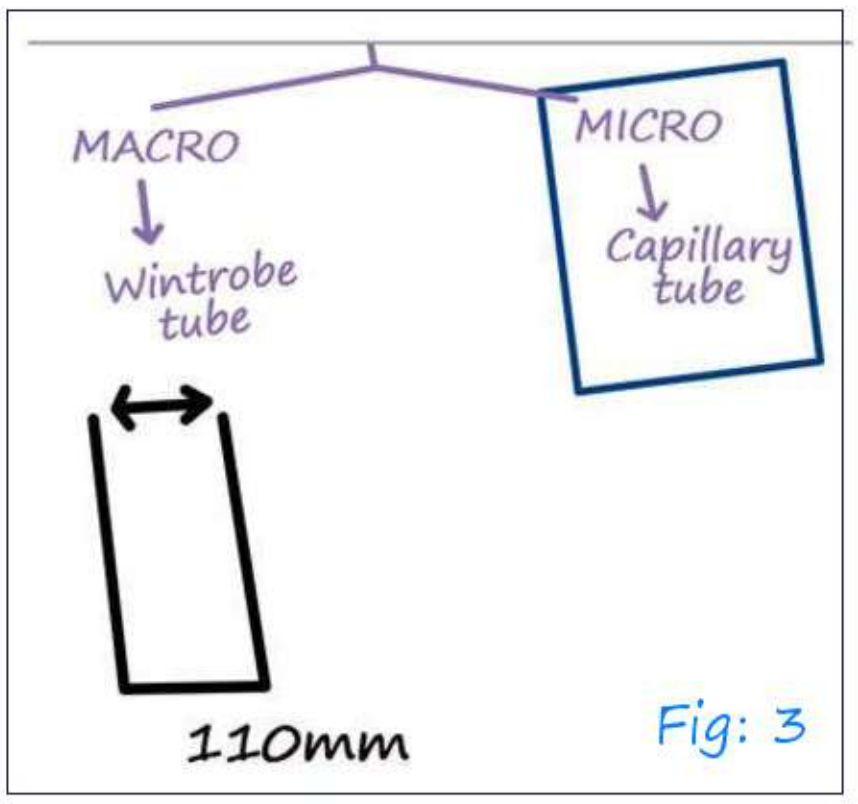

Fig: 3

AfraTafreeh.com

Wintrobe Method

- 110 mm of a the tube is filled with blood, it is centrifuged for 30 mins at speed of 3000 rpm
- Normal PCV-45% (males) 37-42% (Females)

ESR- Erythrocyte sedimentation Rate

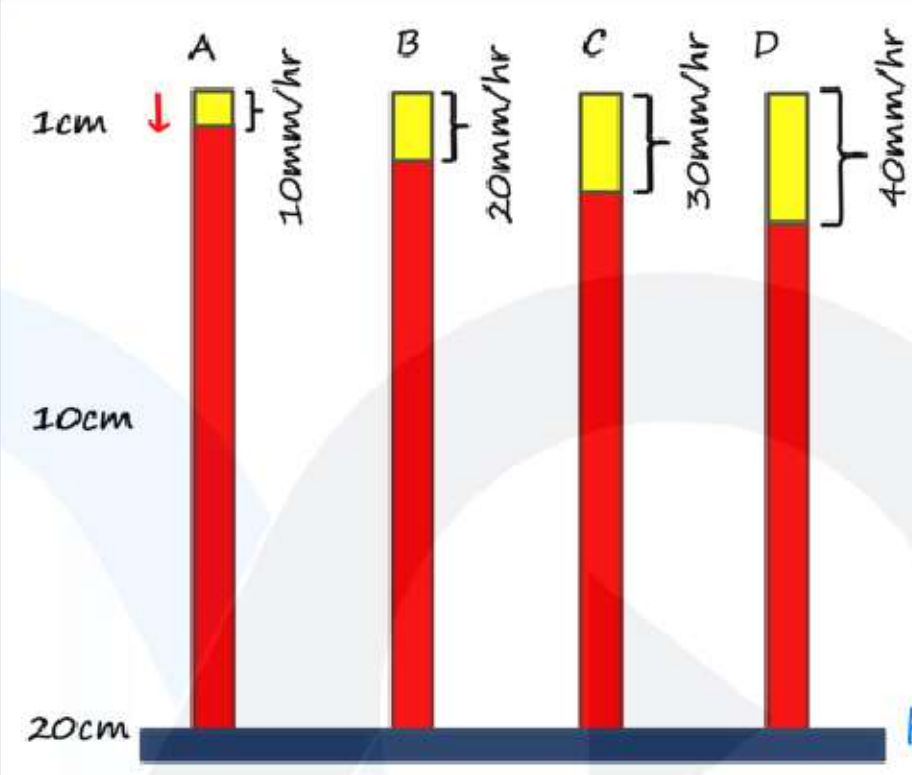

Fig: 4

- It as measured in wintrobe Tube or Westergren's Tube
- Westergren's Tube is the ideal tube
- Normal values Males 3 to 7 mm in one hour
- Females 5 to 9 mm in one hour
- Wintrobe's bone diameter -> 3mm
- Westergren's bone diameter 2.5 mm

Fig: 5

ESR measurement occur in 3 stages.

i. Rolueux formation occurs in 10mm

ii. Sedimentation Formation takes 40min

iii. Packing stage-occurs for 10 min

- Wintrobe uses Anticoagulant - Dipotassium EDTA
- Westergren's uses Anticoagulant-Trisodium citrate (1:4)

Factors Increasing ESR

i. Inflammatory condition - increase fibrinogen increase rolodex formation

ii. Acute Phase Reactants increase ESR except albumin

iii. Decreased viscosity of blood increased ESR

iv. Increased specific gravity increases ESR

- ESR mostly has Prognostic significance.

AfraTafreeh.com
TUTORIALS
LOGIN FOR SUCCESS

- Diagnostic significance of ESR:

  i. Temporal arteritis

  ii. Polymyalgia Rheumatica

  iii. Human Immunodeficiency

  iv. Rheumatoid Arthritis

  v. Tuberculosis

  vi. Multiple myeloma.

APPROACH TO ANEMIA AND UNDERSTANDING MCH, MCHC, RDW (RED CELL PARAMETERS PART – II)

- Approach to Anemia & understanding MCH, MCHC RDW.
- Mean corpuscular Hemoglobin (MCH)
- MCH-Hemoglobin Potential in one RBC
- Normal value 28-32 pg
- MCHC-Hemoglobin present in all RBC's

  Formal → $\frac{Hb}{PCV} = \frac{Hb \times 10}{MCV \times RBC}$

  Normal Value 33-1-5%

  | 32-36% |

- Mean corpuscular Hemoglobin Concentration
  - Megaloblastic Anemia MCHC can be Normal or decreased
  - Spherocytosis-increased MCHC

RDW 00:03:30

- Red cell Distribution width
- It correlates with anisocytosis
- Anisocytosis is a vacation in size of RBC's
- RDW very important in differentiating Iron deficiency Anemia &
- Thalassemia Trait

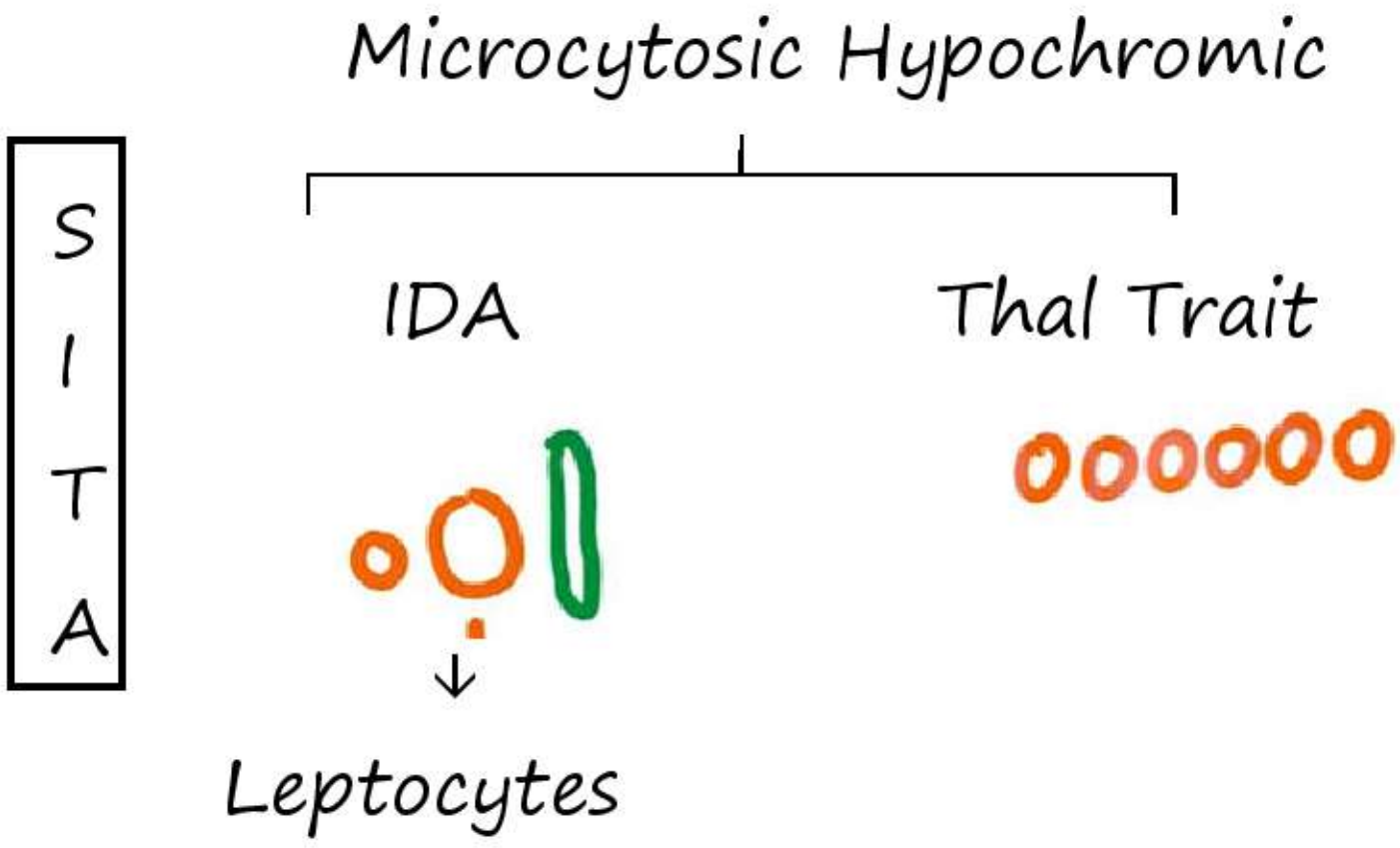

- Normal value of RDW-> 12-14%
- RDW increased in spherocytosis

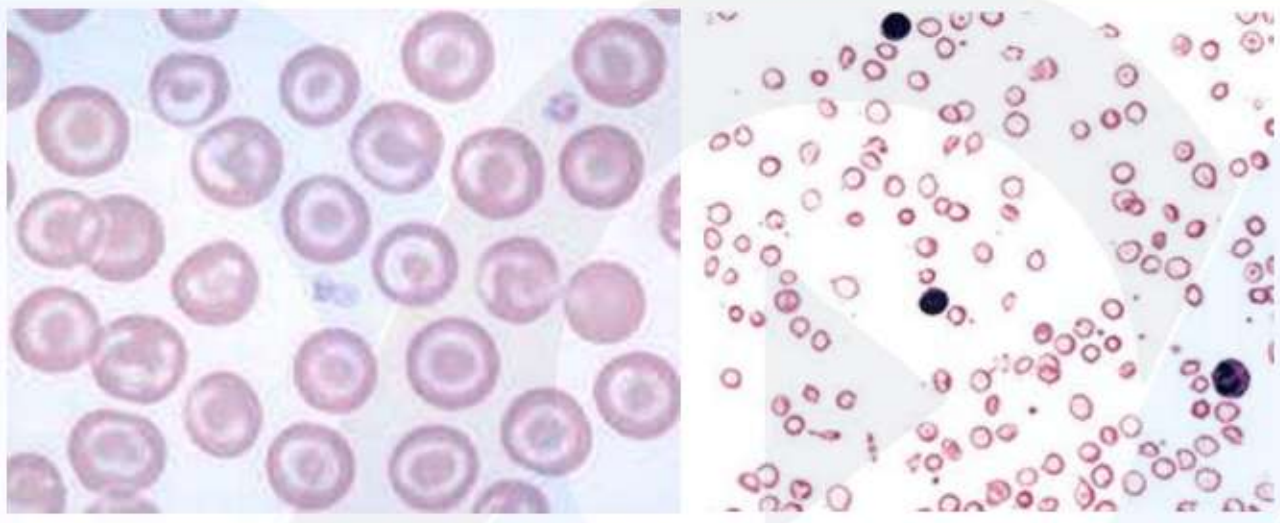
Fig: 1

AfraTafreeh.com

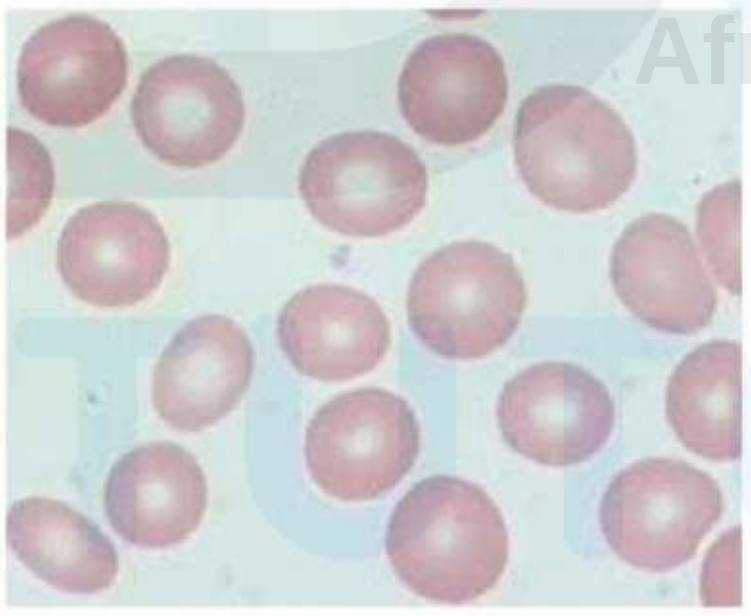
Fig: 2

LOGIN FOR SUCCESS

- MCHC increased in spherocytosis
- Mentzer Index 13 -> Thalassemia
- Mentzer Index> 13 Iron Deficiency Anemia
- RDW increase in iron Deficiency Anemia ORIAL
- RDW Normal in Thalassemia Trait.

AfraTafreeh.com

APPROACH TO ANEMIA WITH EMPHASIS ON APPROACH TO HEMOLYTIC ANEMIA

- Hemolytic Anemia-R/C-N/DECREASE
- Nutritional anemia -R/C-INCREASE
- Hypo proliferative anemia-R/C-DECREASE

Extravascular Hemolysis	Intravascular Hemolysis
i. Serum Haptoglobin level in low but lesser compared to intravascular hemolysis	i. Serum Haptoglobin level in low
ii. Serum Hemopexin normal	ii. Serum Hemopexin level's low
iii. Indirect bilirubin in increased	iii. Methalbuminemia occurs (it can be measured by schumn test)
iv. Gall stones are increased	iv. Hemoglobinuria
v. Splenomegaly present	v. Haemosidenuria
vi. Carbon monoxide level is increased	vi. Low Back Pain commonly present
vii. Fecal urobilinogen increased	vii. No Splenomegaly
viii. Extravascular hemolysis causes	viii. Intravascular Hemolysis Causes
ix. Hereditary spherocytosis	ix. PNH
x. Hereditary elliptocytosis	x. G6PD
xi. G6PD deficiency	xi. Sickle cell
xii. Pyruvate Kinase deficiency	xii. HVS
xiii. Sickle cell	xiii. OLC
xiv. HBC	xiv. TTP
xv. Auto immune Anemia	xv. PCH (Paroxysmal cold hemoglobinuria)

- PCH has a specific antibody-Donath Landsteiner Antibody

Hyperproliferative

- Anemia
- Pure Red Cell Aplastic Anemia.

AfraTafreeh.com
TUTORIALS
LOGIN FOR SUCCESS

AfraTafreeh.com

UNDERSTANDING SICKLE CELL ANEMIA

Genetic

- Point mutation
- Glutamic Acid replaced by Valine on 6th nutrition in β chain
- Adenine replaced by Thiamine which changes the codon and a different amino acid attach

Pathophysiology of Sickle cell Anemia 00:00:05

- Hypoxia leads to RBC' s to turn into sickle cells which on oxygenation turn into normal RBC's, this at first reversible but with repeated cycles leads to membrane damage and sickling becomes irreversible

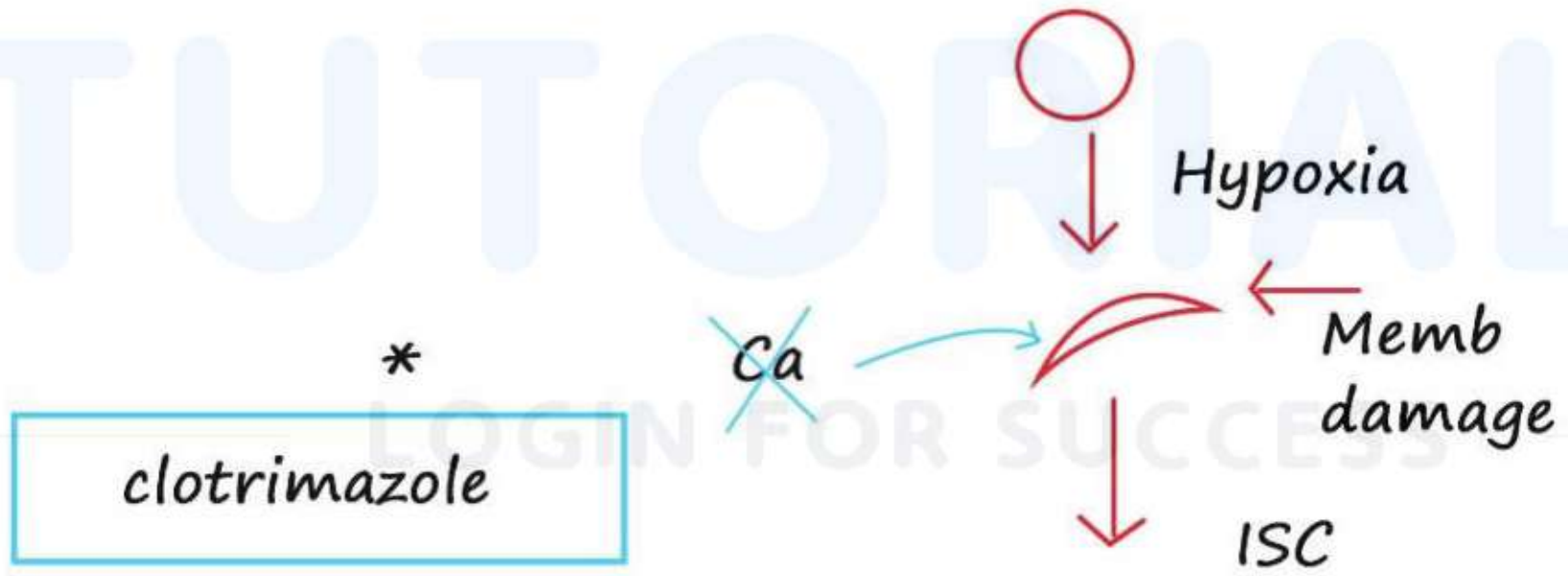

Some drugs like clotrimazole damage Calcium pumps of RBC's which causes Calcium to accumulate in the RBC's and sickling becomes irreversible

- Irreversibly damaged sickle cells cause Phosphatidylserine of the membrane flips outside, cell

becomes more negative at which activates coagulation pathway and thrombosis occurs

- Sickle cells killed in spleen by extravascular hemolysis which causes jaundice which causes jaundice due to increase in indirect bilirubin
- The sickle cells block the venous circulation of spleen which leads to congestion and splenomegaly
- Calcium, Iron, Macrophages accumulate in spleen in the form of "Gonne gandy bodies
- Sickle Cell also occlude arterial circulation of spleen leading to splenic infract which ultimately leads to auto splenectomy
- Sickle cells also undergo intravascular Hemolysis which leads to thrombosis

AfraTafreeh.com

Clinical Features of sickle cell Anemia 00:18:00

i. Vaso occlusive crisis

a. Hand & Feet Syndrome

b. Acute Chest syndrome
   - Child: cause is infarction
   - Adult: cause is infarction

c. vertebral arteries occlusion
   - Fish Mouth Vertebrae

d. Salmonella osteomyelitis

e. Kidney
   - Hyposthenuria – Unable to concentrate
   - Nephrotic syndrome: FSGS Urine

DOC TUTORIALS LOGIN FOR SUCCESS

AfraTafreeh.com

- Papillary Necrosis

• Papillary Necrosis in Renal system Causes D – diabetes mellitus (Most common) O – Obstruction S – Sickle cell Anemia A – Analgesics (Most specific)

f. Medullary carcinoma of kidney
g. Liver
   i. Hemosiderosis
   ii. Anemia
a. Extramedullary Hematopoiesis
   i. Crew Cut skull

Complications of sickle cell Anemia 00:19:57

i. Vascularize Crisis
ii. Myeloblastic crisis
iii. Aplastic crisis
iv. Hemolytic crisis
v. Sequestration crisis

Megaloblastic crisis

- Due to increased turnover of RBC's, there could be folate deficiency
- Treatment is to supplement folic acid

Aplastic Crisis

- It occurs due to parvo virus
- Parvo virus damages colony forming unit of erythroid

Sequestration Crisis

- It occurs in less than 3yrs of age
- There is sequestration of large number of RBC' s in spleen Leads to splenomegaly
- So much sequestration of RBC's Leads to hypovolemic shock
- It is one of the most which leads to death.

AfraTafreeh.com
TUTORIALS
LOGIN FOR SUCCESS

AfraTafreeh.com

PATHOPHYSIOLOGY AND APPROACH TO DIAGNOSIS OF G6PD DEFICIENCY

Inheritance

- It is an X linked recessive disease
- Males affected predominantly

Pathophysiology

G6PD

G6P → 6pG

NADPH

↓

Glutathione reduction

Reduced Glutathione ⇄ Oxidized Glutathione

Glutathione peroxidase

H2O2 → H2O

TUTORIALS
LOGIN FOR SUCCESS

- Absence of G6PD → Absence of NADPH Glutathione peroxidase ineffective
  → increase is H2O2 Free radical injury

Heinz Bodies

- In G6PD deficient cells oxidant will denature globin of Hemoglobin to from Heinz Bodies
- Heinz bodies are stained by supravital stain

- Excess Heinz bodies leads to severely damaged RBC's which undergo intra vascular hemolysis
- They present es Hemoglobinuria and Haemosidenuria
- Less damaged RBC undergo extra vascular hemolysis in spleen and lead to formation of spherocytes.
- BITE CELLS (Degmacytes) RBCs with appearance of bite due to unstained denatured hemoglobin within the cytoplasm
- BITE CELLS are also called hemighost cells

Clinically significant G6PD variants

- B Type → it's a normal variant/mild type, normal enzyme activity
- A + → It has move mobility normal enzyme activity
- A-5 →15% enzyme activity
    - → Its African American origin
    - → There is decreased stability
- Mediterranean → Most common symptomatic variant less than 1% enzyme activity

AfraTafreeh.com

WHO CLASSIFICATION OF G6PN

Class	G6PDactivity	Hemolysis	Most common variants
I	<10%	Chronic	G6PD san diego
II	<10%	Acute	G6PD
III	10-60%	Acute	Mediterranean

AfraTafreeh.com

IV	60-150%	Absent	G6PD A, G6PD
V	Increased		Canton
			G6PD B, G6PD A
			G6PD VERONA

- Orissa & Kerala have high incidence of G6PD deficiency Point mutation at 44th position
- Alanine: Glycine

Clinical Feature of G6PD

- Intermittent Bleeding episodes
- Bleeding episodes triggered by
  i. Infections - Most common triggers
  ii. Drugs - Primaquine, sulfonamides
  iii. FAVA Beans, "FAVISM"
- Peripheral smears - shows BITE CELLS, HEINZ BODIES
- Methaemoglobin Reduction Test

DOC TUTORIALS LOGIN FOR SUCCESS

Diagnosis

- Adding in methylene blue if blood sample Doesn't change to red color it is positive seen G6PD Deficiency test
- Fluorescent spot test
- Investigation of Choice – ELISA

- G6PD deficiency test should be done before administering primaquine.

PATHOPHYSIOLOGY AND APPROACH TO DIAGNOSIS OF G6PD DEFICIENCY

Inheritance

- It is an X linked recessive disease
- Males affected predominantly

Pathophysiology

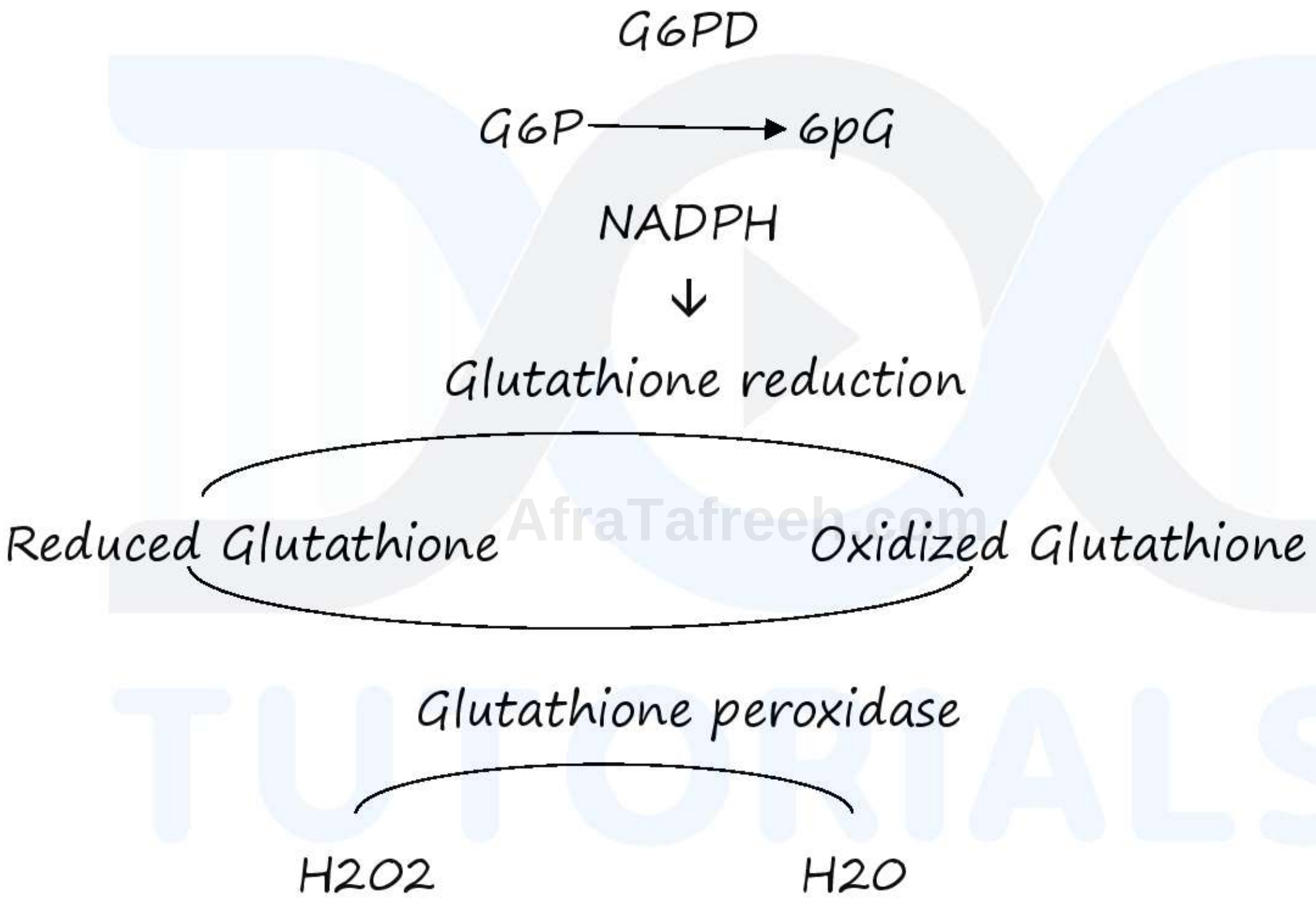

AfraTafreeh.com
TUTORIALS
LOGIN FOR SUCCESS

- Absence of G6PD → Absence of NADPH Glutathione peroxidase ineffective
  → increase is H_2O_2 Free radical injury

Heinz Bodies

- In G6PD deficient cells oxidant will denature globin of Hemoglobin to from Heinz Bodies
- Heinz bodies are stained by supravital stain

AfraTafreeh.com

- Excess Heinz bodies leads to severely damaged RBC's which undergo intra vascular hemolysis
- They present es Hemoglobinuria and Haemosidenuria
- Less damaged RBC undergo extra vascular hemolysis in spleen and lead to formation of spherocytes.
- BITE CELLS (Degmacytes) RBCs with appearance of bite due to unstained denatured hemoglobin within the cytoplasm
- BITE CELLS are also called hemighost cells

Clinically significant G6PD variants

- B Type → it's a normal variant/mild type, normal enzyme activity
- A + → It has move mobility normal enzyme activity
- A-5 →15% enzyme activity
  - → Its African American origin
  - → There is decreased stability
- Mediterranean → Most common symptomatic variant less than 1% enzyme activity

WHO CLASSIFICATION OF G6PN

Class	G6PDactivity	Hemolysis	Most common variants
I	<10%	Chronic	G6PD san diego
II	<10%	Acute	G6PD
III	10-60%	Acute	Mediterranean

IV	60-150%	Absent	G6PD A, G6PD
V	Increased		Canton
			G6PD B, G6PD A
			G6PD VERONA

- Orissa & Kerala have high incidence of G6PD deficiency Point mutation at 44th position
- Alanine: Glycine

Clinical Feature of G6PD

- Intermittent Bleeding episodes
- Bleeding episodes triggered by
  i. Infections - Most common triggers
  ii. Drugs - Primaquine, sulfonamides
  iii. FAVA Beans, "FAVISM"
- Peripheral smears - shows BITE CELLS, HEINZ BODIES
- Methaemoglobin Reduction Test

Diagnosis

- Adding in methylene blue if blood sample Doesn't change to red color it is positive seen G6PD Deficiency test
- Fluorescent spot test
- Investigation of Choice – ELISA
- G6PD deficiency test should be done before administering primaquine.

AfraTafreeh.com

PATHOPHYSIOLOGY AND APPROACH TO DIAGNOSIS OF PNH

Acquired Haemoglobinopathy Genetic

- Most commonly seen in elderly
- PIGA gene codes for GPI anchor proteins,
- 3 types of GPI Anchor protein

i. DAF-Decay Accelerating Facer

ii. MIRL-Membrane inhibitor of reactive lysis

iii. ILLAP-(NAP)

i. DAF [Ca 55]

- It regulation C3 convertase

ii. MIRL [Cd 591

- It regulation C5 convertase
- Defect is PIGA gene leads to con of GPI anchor protein, which leads to aver activation of complements by alternate pathway

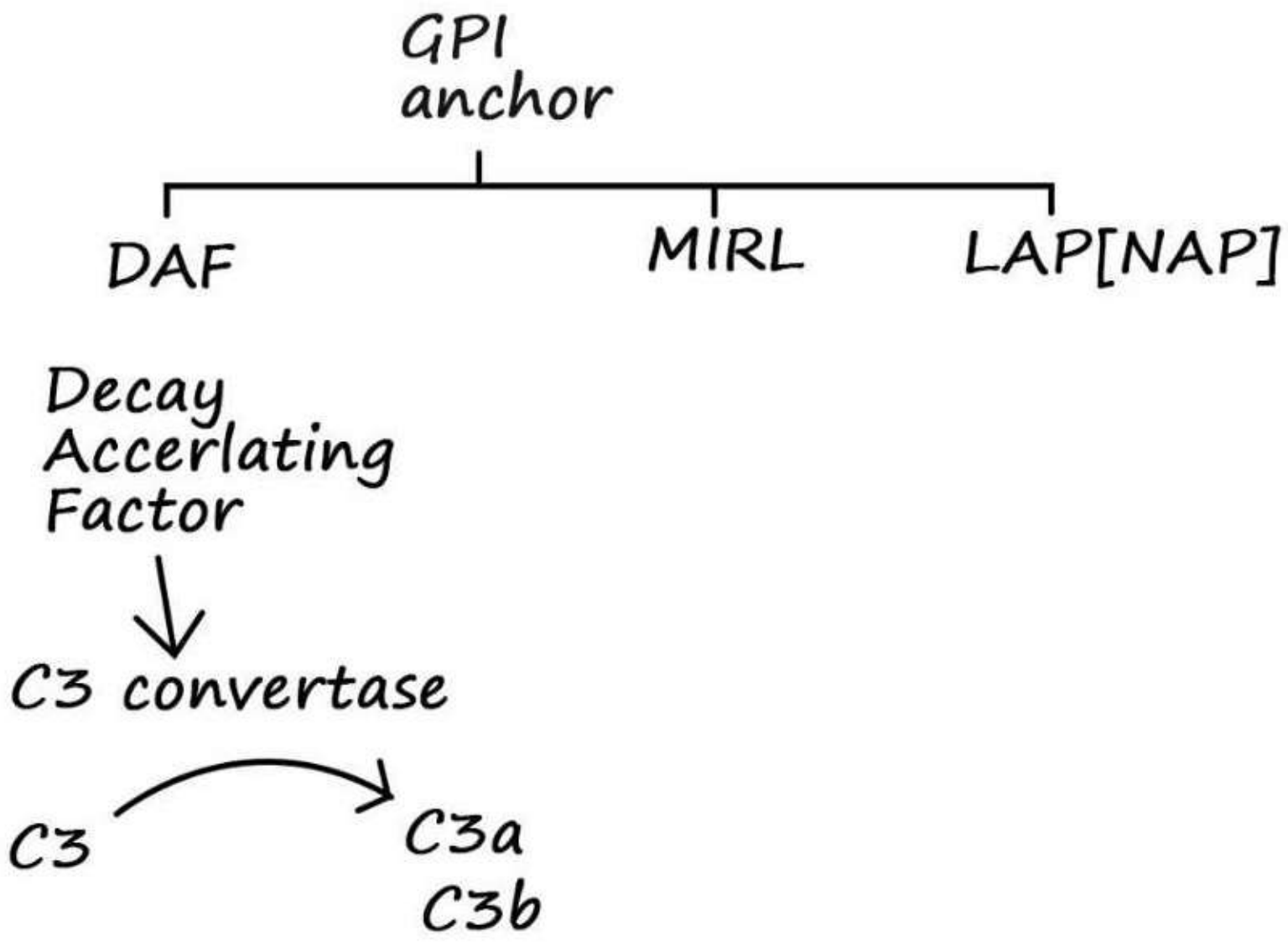

Excess complements lead to

i. Intravascular Hemolysis–Hemoglobinuria, haemosidenuria

ii. Endothelium injury leads to release of NO, which is lost–causing vasoconstriction.

iii. Thrombosis occurs

- PNH and sickle cell anemia both associated with thrombosis but PNH causes more intravascular hemolysis and sickle cell anemia causes more extravascular hemolysis
- Traid of PNH

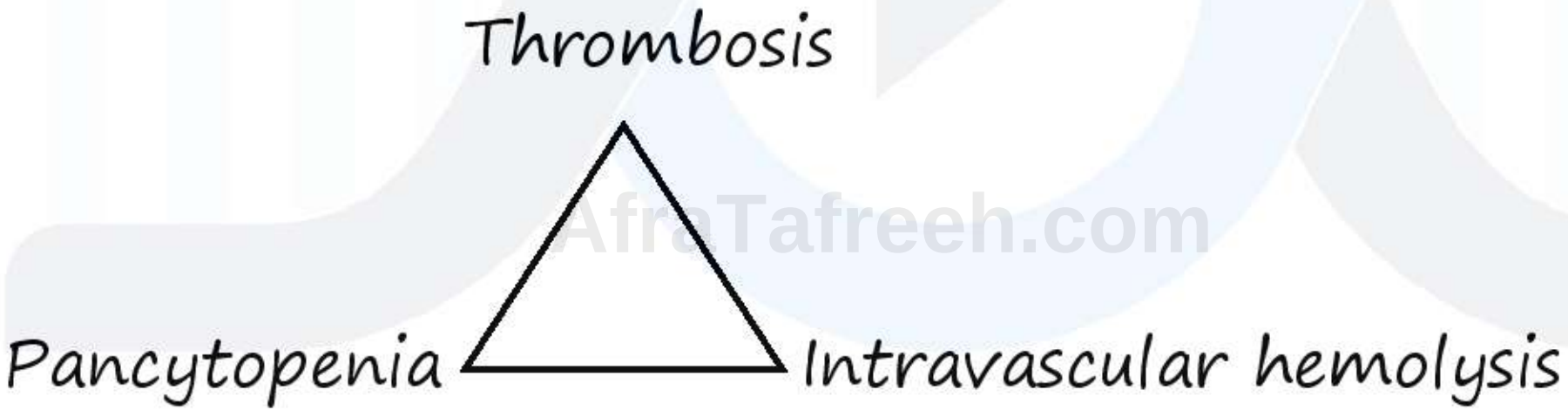

AfraTafreeh.com
TUTORIALS
LOGIN FOR SUCCESS

Complications of PNH
- Progress into Acute myeloid leukemia
- Progress into myelodysplastic syndrome

Clinical Features

- Morning Hemoglobinuria Night acidosis occurs which activate complements & cause intravascular hemolysis
- Mostly occurs is elderly since it is an acquired conduction

AfraTafreeh.com

Investigations

i. Peripheral smear initially normal later reticulocyte count reduces

ii. Bone Marrow Biopsy Early phase-Hypercellular

Later-Hypocellular

Last stage-Aplasia

- Special stains: NAP/ LAP

Screening Test

i. Ham Test/Sucrose lysis Test

- Ham Test is the best screening method

  It is also called Acid Lysis test,

ii. Gelcard Test-New Test

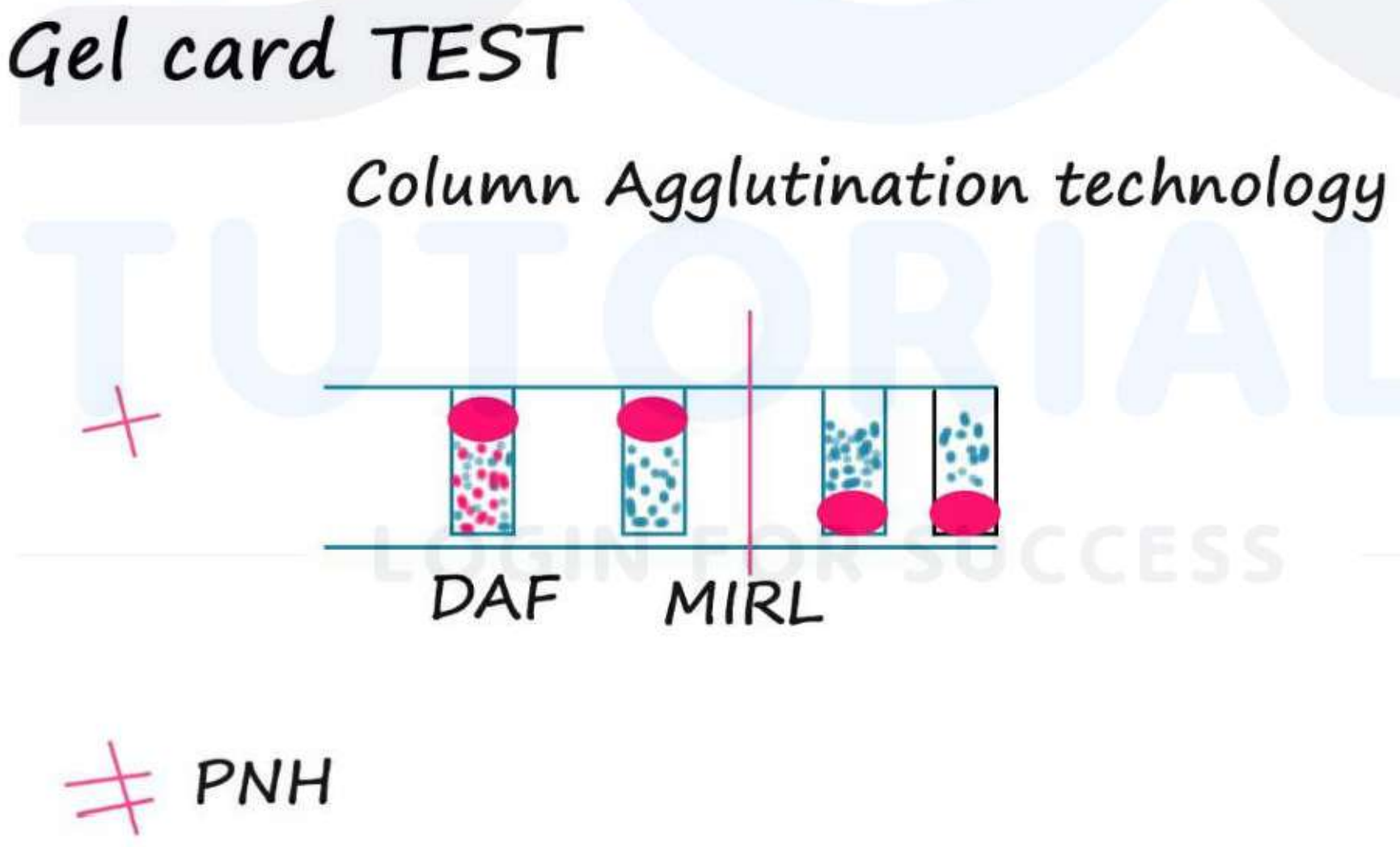

- It is a column Agglutination test

Investigation of Choice for PNH

Flow Cytometry-demonstrating FLAER

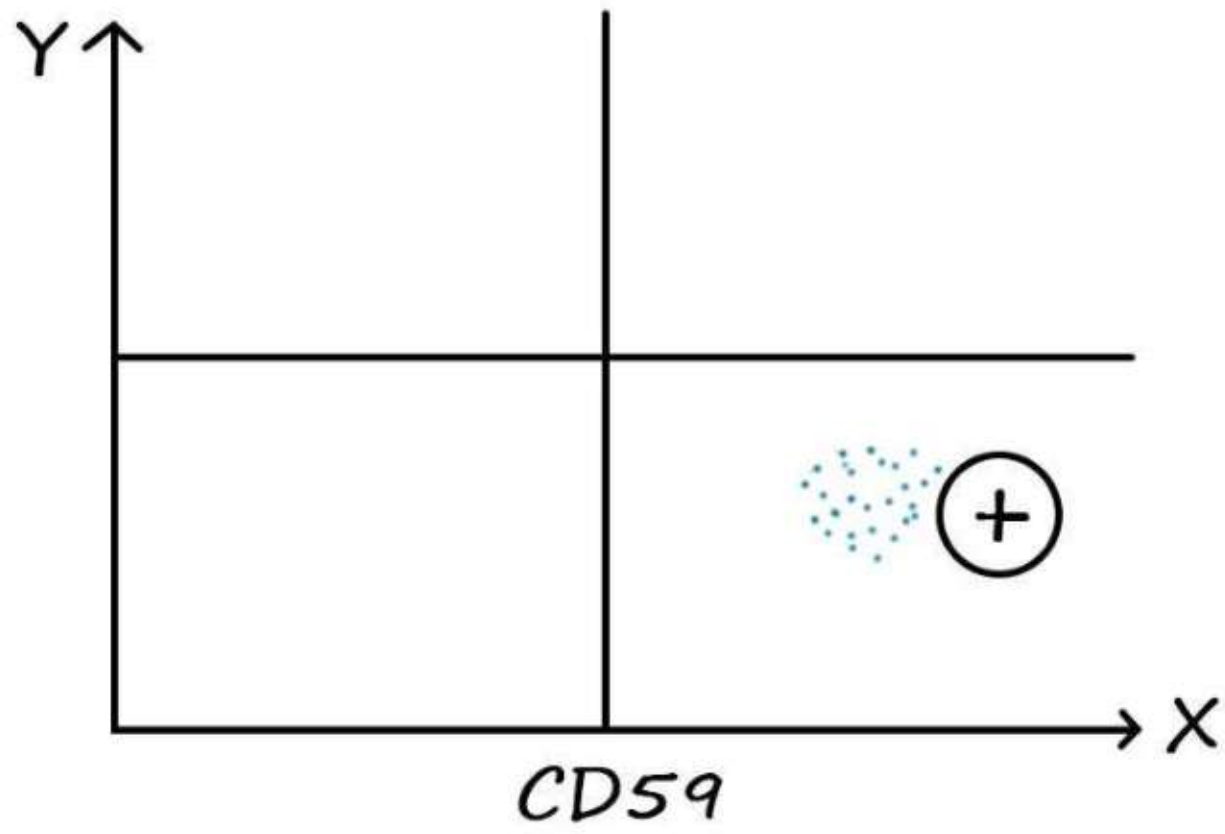

i. Defects Cd 55+ identifies DAF

ii. Defects Cd 59+ identifies MIRL

- Flow cytometry used to

i. Demonstrate absence cd55 & cd 59

ii. Demonstrate FLAER (Fluorescent Aerolysin)

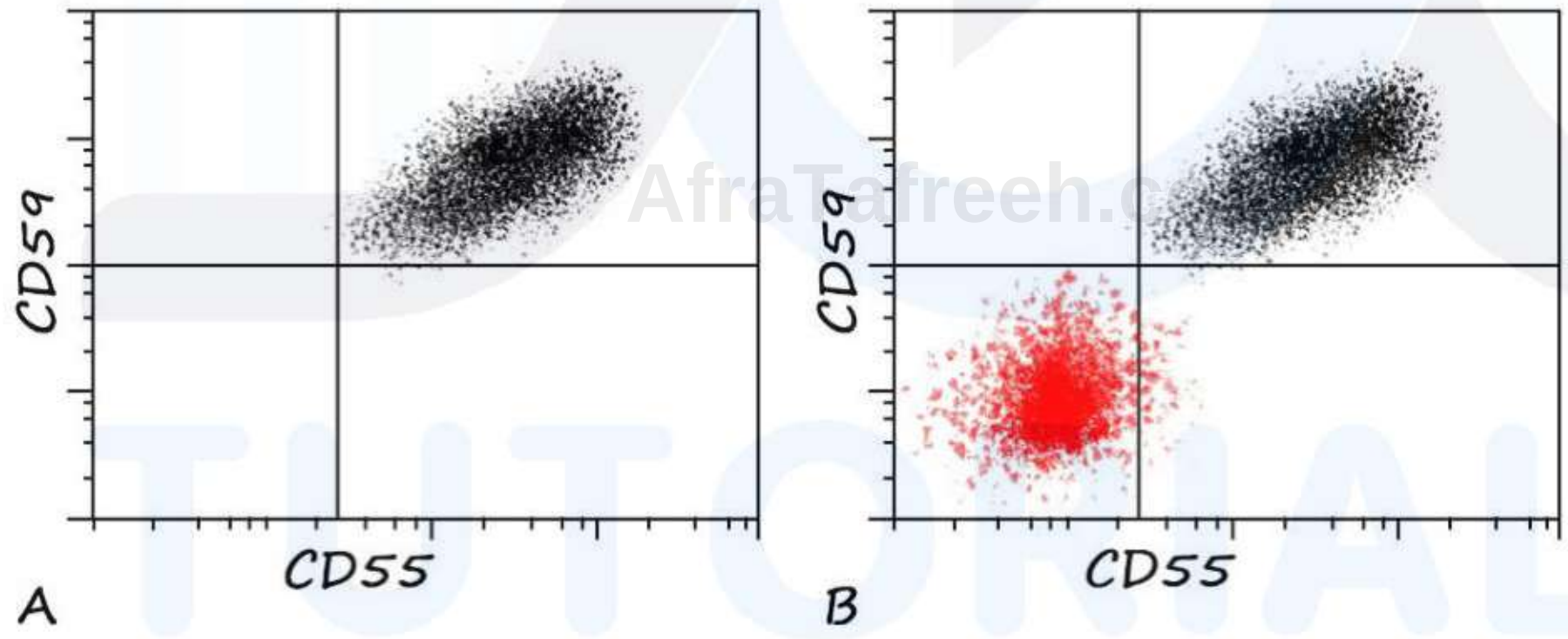

Treatment

- Eculizumab regulation C5 convertase & prevents over activation of complement complication of this drug-meningococcal infection
- PNH-Most common cause of death is thrombosis of hepatic veins (Budd Chiari's syndrome).

AfraTafreeh.com

HYPO PROLIFERATIVE ANEMIAS PLASTIC ANEMIA AND PURE RED CELL APLASIA

- Aplastic Anemia Cause Idiopathic (65%) Drugs
- Virus
- Most common virus Non A Non 8 Non C Non & Hepatitis

Pathophysiology of Aplastic Anemia

i. Intrinsic stem cell Defect.

ii. T cell immune deficiency-Activate THI witch release IFN r & INF Which damage stem cells

Bone Marrow Biopsy Specimen

Normal cells to Fat

1:1

Cells Myeloid: Erythroid

3:1

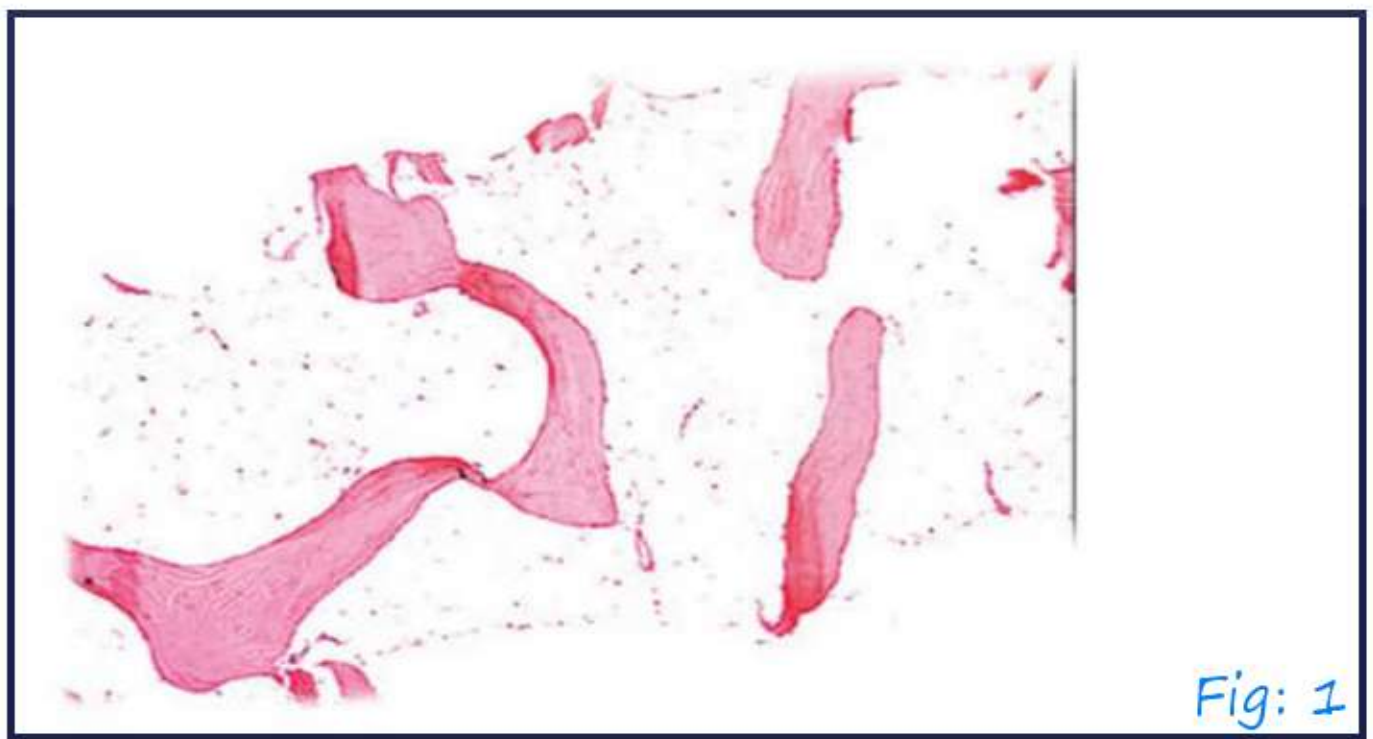

Fig: 1

Diagnosis

i. Peripheral Smear Pancytopenia

Criteria for pancytopenia Hb < 10gm/dl
Platelets < 1 lakh
WBC < 4000/cms

ii. Bone Marrow Aspiration → leads to day top
iii. Bone Marrow Biopsy is hypo cellular
iv. Cheek CD 34 count, if high Rule out leukemia & myelodysplastic syndrome.

- CD 34 count loss Aplastic anemia

Clinical Features

i. Onset insiders with symptoms related to pancytopenia
ii. Splenomegaly clement

AfraTafreeh.com
TUTORIALS
LOGIN FOR SUCCESS

Inheritance of Aplastic anemia

- In Adults

i. Inherited aplastic Anemic syndrome

- inherited Bone marrow failure Syndromes associated with Aplastic Anemic

i. fanconi Anemia- DNA Repair Defect
ii. Dyskeratosis congenita-Telomeres Shortened
iii. Shwachman Diamond syndrome → Exocrine pancreatic Defect
iv. Congenital amegakaryocytic thrombocytopenia

Fanconi Anemia

AfraTafreeh.com

- On adding mitomycin drug, chromosome Shows radial formation
- Diagnostic Criteria for Severe Aplastic Anemia
- Bone marrow cellularity of 25% along with 2 of the following:

i. Neutrophil count < 500ml
ii. Platelet count < 20,000/ml
iii. Acute reticulocyte count of< 60,000 ml

Pure Red Cell Aplasia (Erythroblastopenia)

Pathogenesis & Etiology

i. Parvovirus damages proerythroblast it changes it becomes bigger and shows cytoplasmic protrusions – Giant Proerythroblast with Dog ear cytoplasm
ii. Thymoma & large granular leukemia cause arrest of erythrocyte maturation

Inherited Forms of Red cell Aplastic anemia is called diamond Blackfan Anemia

TUTORIALS
LOOK FOR SUCCESS

Pancytopenia with cellular bone marrow

i. PNH
ii. Myelofibrosis
iii. Hairy cell leukemia
iv. Myelodysplastic syndrome

Pancytopenia with hypo cellular bone marrow

i. Acquired aplastic anemia

ii. anemia

iii. Dyskeratosis congenital

AfraTafreeh.com

TUTORIALS

LOGIN FOR SUCCESS

AfraTafreeh.com

APPOACH TO MICROCYTIC HYPOCHROMIC ANEMIA

Hb

Heme   Globin

Iron + Protoporphyrin

- When hemoglobin appears in RBC Precursors → cell division stops. If due to any reason Hb is not formed properly, the Precursor cells continue dividing forming smaller and less Hemoglobinised RBC → Microcytic Hypo-chromic anemia

Causes of microcytic hypochromic anemia

Hb

Heme   Globin

Iron +	Protoporphyrin	Thalassemia
i. Iron Deficiency anemia	sideroblastic anemia	
ii. Anemia of chronic disease		

Absorption and metabolism of iron

- Site of absorption – Duodenum
- Form of absorption – Ferrous Fe^{2+}

- Ferric to ferrous conversion – By Duodenal cytochrome B
- Ferrous absorbed by Divalent metal transporter 1 which also absorbed other Divalent ions like Cu^{e+} Mn^{2+}
- Storage from – Ferritin
- Released into circulation by ferroportin
- Hephaestin – converts ferrous into ferric from for circulator
- Transferrin – Transports the Ferric iron in circulation

Transferrin Saturation

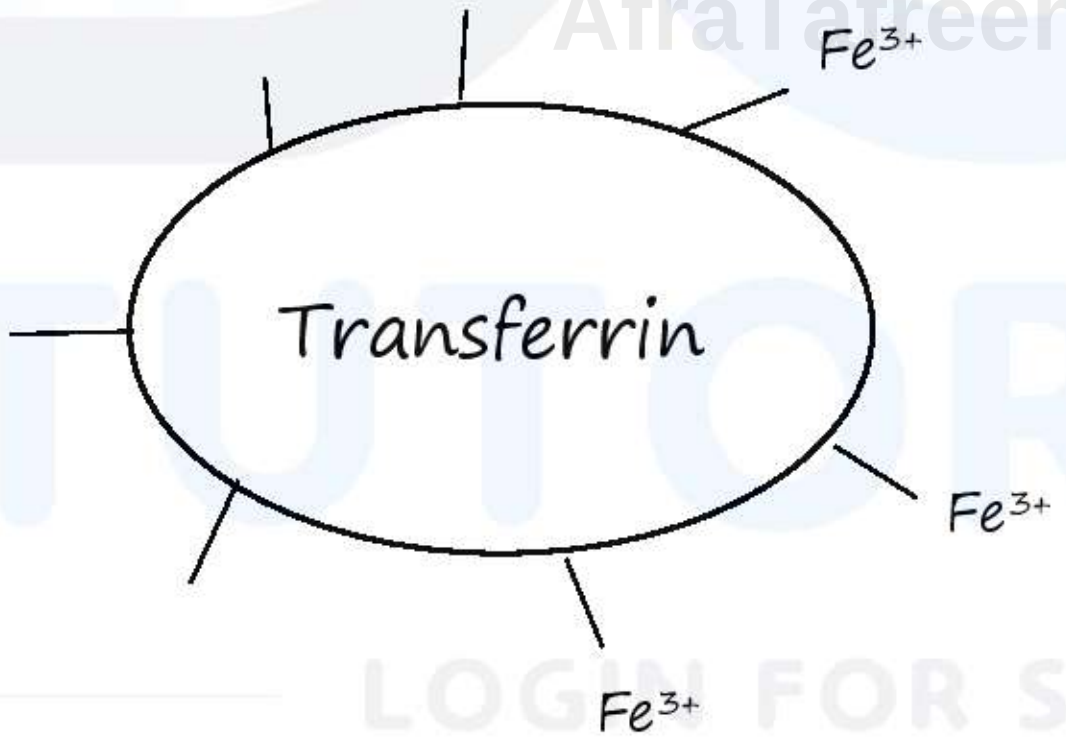

- Normally transferrin is only 1/3rd saturated with Iron i.e. 33% Range Begin 16-50%

Serum Iron, TIBC, VIBC

- TIBC → TS + VIBC
- TIBC = 30% + VIBC

AfraTafreeh.com

Example

- TIBC = 300 mg 1 dl
- Serum Iron = 50-150 mg/dl (-100 mg 1 de) so unbound / unsaturated Iron Binding capacity equals 200 mg/dl

Iron Utilization

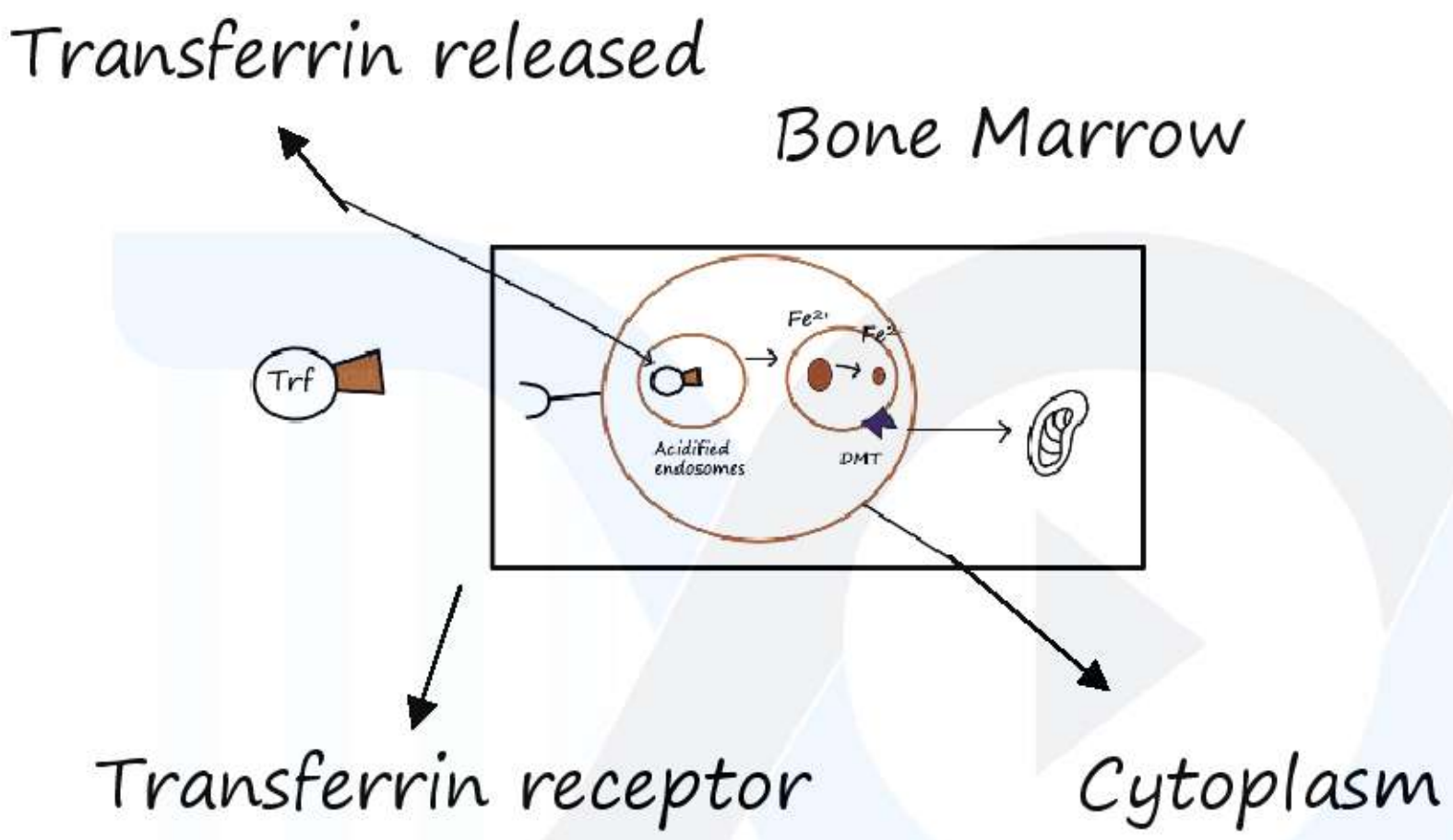

- Transferrin receptor internalizes transferrin bound iron into endosomes
- Acidification of endosomes causes release of transferrin back to circulation and Iron is released by DMT, receptor
  - 80-90% into mitochondria of Erythroid processor
  - 10% Goes to cytoplasm forming ferritin
- Intermediate Erythroblasts have maximum Transferrin receptor while late Erythroblasts lose their Transferrin receptor into circulation as serum transferrin receptor.

- Late erythroblasts lose their transferrin receptor into circulation as serum transferrin receptor.

Level of serum transferrin receptor alpha amount of erythropoiesis

- More the erythropoiesis – more the serum transferrin receptor
- DMT:
  i. Important in absorbing Fe^{2+}
  ii. Releasing Fe^{2+}

Ferroportin receptor

- Macrophages of Bone marrow have ferroportin receptor for release of Iron to Erythroid cells
- Thus BM macrophages are surrounded by erythroid precursors forming erythroid colony
- These macrophages are 'Nurse Cells'
- Placenta also has ferroportin receptor for release of Iron to fetus
- So ferroportin receptors are on
  i. Intestinal cells
  ii. Macrophages
  iii. Placenta

Normal values

- Serum Iron → 50-150% mg ide
- Transferrin saturation → 15-50% (33%)

AfraTafreeh.com

- TIBC → 300 mg/dl

Iron Deficiency anemia 00:39:55

- Serum Iron
- TS decrease
- TIBC increase
- Ferritin decrease (Most sensitive)
- Increase Erythropoiesis

Stages of IDA

I	II	III
• Decrease Ferritin	• Decrease Ferritin • Decrease serum iron • Decrease TS • Increase TIBC • Increase Erythropoiesis • Increase STR • Microcytic hypochromic anemia • Increase RDW • Pencil cells on PS	[Decrease Ferritin … Increase Erythropoiesis] + Symptoms of IDA glossitis koilonychias fatigue

TUTORIALS LOGIN FOR SUCCESS

Peripheral smear in IDA: <u>Anisocytosis</u>

i. Microcytic Hypochromic cells – RBC's smaller than lymphocytes with > 1/3rd pallor.

ii. Leptocyte / Pessary cell – only a rim of Hb seen

iii. Pencil cell – completely pale ovalocytes

iv. Increase RBW

- Examination of BM aspirate on Perl's Prussian blue stain
- Chronic disease persisting for > 1 month
- Excluding anemia due to
  - Renal disease
  - Liver disease
  - Endocrine cause

AfraTafreeh.com

Pathogenesis

Chronic inflammation
Chronic infection
Malignancy

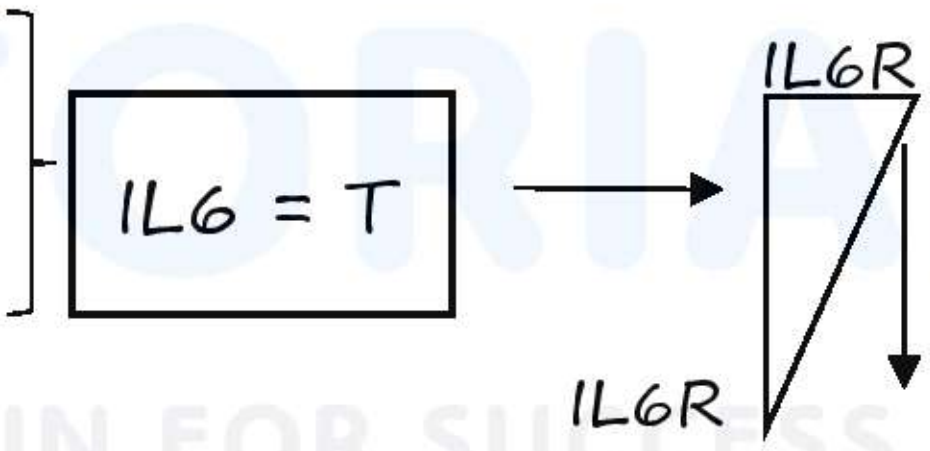

IL6R
Release of Herodian
↓
Blocks ferro portion
↓
Release of Iron from blocked
↓
Parameters
Scrums Iron decrease
TB decrease
TIBC decrease
Ferritin Normal

AfraTafreeh.com

- IL-6 → major interknit in pathogenesis of anemia of chronic disease Hepcidin → Negative controller of Iron metabolism

Serum Iron decrease

TS decrease

IDA	ACD
TIBC ↑↑	TIBC ↓
Ferritin stores ↓	Ferritin stores / normal
STR ↑↑	STR ↓ / Normal

Important topics for AIIMS / Jipmer

Genes regulating Hepcidin

HFE Mutation seen in Hemochromatosis

HFE C 2824 most common mutation in Hemochromatosis

Hemojuvelin

- TMPRSS6 – also known as Matriptase 2 gene
- Responsible for Iron – Refractory Iron Deficiency Anemia [IRIDA]
- TMPRSS6 Mutation causes increased release of Hepcisin from liver
- Absorbed Iron not released from intestine or form ferritin stores
- Serum Iron levels decrease Despite Iron supplements

↓

IRIDA

DMT 1 Mutations 00:55:40

- DMT 1 Function – Iron absorption into intestine release of Fe 2+ from endosomes into mitochondria
- In DMT 1 Mutation – No Fe 2 = reaches mitochondria

↓

No heme synthesis

↓

Microcytic Hypochromic Anemia

Compensatory Release of Iron into circulation: Sr Iron- decrease

TS- decrease

But TIBC- Normal

Hepcidin- decrease

AfraTafreeh.com
TUTORIALS
LOGIN FOR SUCCESS

Atransferrinemia

No Transferrin – decrease Sr Iron

↓ TS

NO iron reaches bone marron

↓

Commendatory increase in iron absorption

Sr Ferritin increase

Presents as iron overload

AfraTafreeh.com

Iron overload conditions

Atransferrinemia	Hemochromatosis
TS decrease	TS increase
Sr Iron decrease	Sr Iron increase
Ferritin decrease	Ferritin increase

ACD:

ACD	IDA	A Transferrinemia	Hemochromatosis
Sr	Sr	TS	TS
Iron	Iron	TIBC	TIBC
TS	TS	Sr Iron ferritin	Sr Iron ferritin
TIBC	TIBC		

DMT 1 Deficiency

- TS increase
- Hepcidin decrease
- Sr Iron increase
- MCH cells.

TUTORIALS
LOGIN FOR SUCCESS

SIDEROBLASTIC ANEMIA

- Sideroblasts-Iron containing precursors.

Pathophysiology

- Defect in Heme production due to
  i. Protoporphyrin defective
  ii. Iron unable to incorporate in Protoporphyrin
- This process of Heme formation occurs in Mitochondria
- Vitamin B6 is required for the production of Heme

Etiology of Sideroblastic Anemia

1. Inherited Causes
   - ALA Synthetase enzyme defective
   - Predominantly X linked defective
2. Acquired Causes
   i. Clonal Causes-Myelodysplastic syndrome with ring sideroblasts
   ii. Reversible
      a. Pyridoxine deficiency
      b. Drugs-Antitubercular drugs
      c. Alcoholism [ALA de]
      d. Lead Poisoning [Pyrimidine 5 nucleotidase defective]

AfraTafreeh.com
TUTORIALS
LOGIN FOR SUCCESS

AfraTafreeh.com

Effects of Lead Poisoning

i. Damages many enzymes that leads to Sideroblastic Anemia.

ii. Affects Pyrimidine 5 Nucleotidase, which leads to wave basophilic stippling

e. Copper deficiency

- Alcoholism most common reversible cause of Sideroblastic Anemia.

Microscopic Findings

I. Normoblasts shows iron accumulation in mitochondria more than 5 granules & it is present around 1/3rd of nucleus leads to formation of Sideroblasts

II. Ringed Sideroblasts identified by Perls Prussian Blue Stain

III. Iron granules present in RBC's and are called Pappenheimer Bodies.

Pappenheimer Bodies seen in

Sideroblastic Anemia

Post Splenectomy

Identified by Peris Prussian Blue Stain

Pathogenesis

- Ineffective erythropoiesis leads to anemia with increases erythropoiesis causing erythroid hyperplasia increased erythropoiesis causing increased iron absorption which accumulates and causes ineffective erythropoiesis.

Laboratory Findings

- Increased Serum Ferritin
- Increased Transferrin Saturation
- Decreased/Normal TIBC
- Iron Stores Increased

Peripheral Smear Findings

i. Anemia

ii. Dimorphic RBC microcytic hypochromic cells and normocytic normochromic cells

High Yield Box

AnkTafreeh.com
TUTORIALS
LOGIN FOR SUCCESS

Dimorphic RBC's
Sideroblastic Anemia
Blood Transfusion
Coexisting iron deficiency
Anemia: Megaloblastic
Anemia

AfraTafreeh.com

iii. Pappenheimer Bodies are seen on Perls Prussian Blue Stain

Bone Marrow Examination 00:27:08

i. Ringed Sideroblasts

- Iron Profiling
- Serum Iron level Increased
- Serum Ferritin Increased
- Serum Transfusion Saturation Increase
- Serum TIBC-Normal/Decreased
- Lead Poisoning-Protoporphyrin Level Increased
- 10% of Sideroblastic Anemia (due to MDS with Ringed sideroblast) can be turn into Leukemia.

TUTORIALS
LOGIN FOR SUCCESS

THALASSEMIA BASICS

- Thalassa means sea because most are were found around meditessanean sea
- Thalassemia-Mediterranean Sea
  -Cooleys Anemia

Pathogenesis

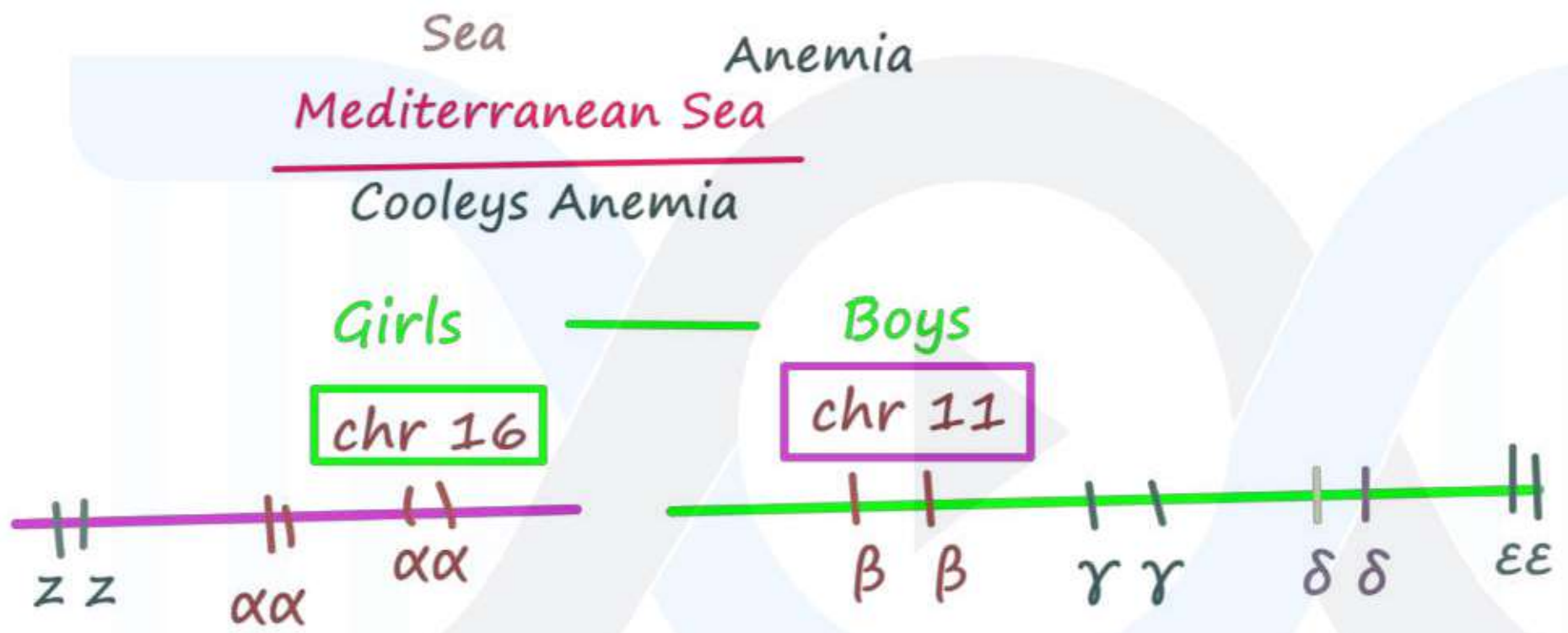

AfraTafreeh.com

- α Chain → 4 genes me rent on chr 16
- β Chain → 2 genes me rent on chr 11
- γ Chain
- δ Chain — Chr 11
- ε Chain
- z Chain→ Chr 16

i. Embryonic Hemoglobin

- Gower i z2 ε_2
- Gower - α2 ε_2
- Portland - z2 γ_2

ii. Fetal Hemoglobin

- HbF – $\alpha_2\ \gamma_2$
- HbF has very strong oxygen affinity

AfraTafreeh.com

iii. Adult Hemoglobin

- HbA-$\alpha2$ $\beta2$ HbA2
- HbA2 -
- HbA (95%) HbA2 (5%) → Adult Hemoglobin

Pathogenesis of Thalassemia

$\beta^{\cdot}$ / $\beta^{\cdot}$ – No alleles of β gene

– β Thalassemia major

β^{+} / β^{+} – β Chain present in less quality

– β Thalassemia minor

– Thalassemia Trait

$\beta^{\cdot}$ / β^{+} – β Thalassemia intermedia

β^{+} / β^{+}

Thalassemia Major 00:00:07

- (90%) Majority of Hemoglobin a2 Tr due to absence of D chain Also namable amount of HbA2 a & is present
- A2γ_2 has many high antigen affinities which leads to hypoxia is tissues this stimulate erythropoiesis and increase Hemoglobin & RBC products leads to formation of a tetramer & causes ineffective erythropoiesis leads to RBC precursors containing inclusions

  i. Howell Jelly Bodies-DNA remnant

  ii. Cabot rings-Mitotic spindles

iii. Basophilic stippling-Ribosome accumulative RBC's-
volume decrease and surface ores increase leads to formation of Target cells.

- RBC's – volume decrease and surface area increase leads to formation of target cells.
- increased erythropoiesis is ineffective which leads to more erythropoiesis
  which cause erythropoiesis of all Bone marrow →
- leads to CREW CUT Appear Ana of skill & Thalassemia facies
- increased erythropoiesis → also causes intramedullary erythropoiesis extramedullary erythropoiesis & excess erythropoiesis is Bone Morrow cause Increased BBCS is peripheral smell
  ↓
  i. microcytic hypochromic RBC
  ii. Nucleated RBC
  iii. target cells
  iv. RBCs with Howell sally Bodies
  v. RBCs with Cabot Rings
  vi. RBCs with basophilic stripling
  vii. marked Red cell Distribution width
- major cause of death of Thalassemia is Candia over loud due to Hemosiderin. tetramers which accumulate Rbc's leads to apoptosis also alters
- BAND 3 me rent in RBC cell men crane which are destroyed in spleen lead to splenomegaly and Assn

AfraTafreeh.com

AfraTafreeh.com

dice Hence, thalassemia is a type of Hemolytic anemia

→ extra vascular Hemolysis

- Reticulocyte count not increased
- proportional to degree of anemia in Thalassemia due to ineffective Erythropoiesis peripheral smear of Thalassemia Minor
- only Target cells are seen some microcytic Hypochromic cells No anisocytosis
- conformation of Thalassemia dragline-HPLC

Individual HbA >95%

HPLC — (N)

- HbF < 1%
- HbA2 < 4%

HPLC OF Thalassemia P+ → HbF > 90%

HbA = 0

HbA2 Variable

Red cells Distribution width Meltzer In den Meltzer In den = MCV Count RBC	Thalassemia Minor Normal < 13	IDA Increased < 13

GENETICS OF BETA THALASSEMIA

- B thalassemia-Non deletional mutation (most common type of mutation)

1st mutation in thalassemia

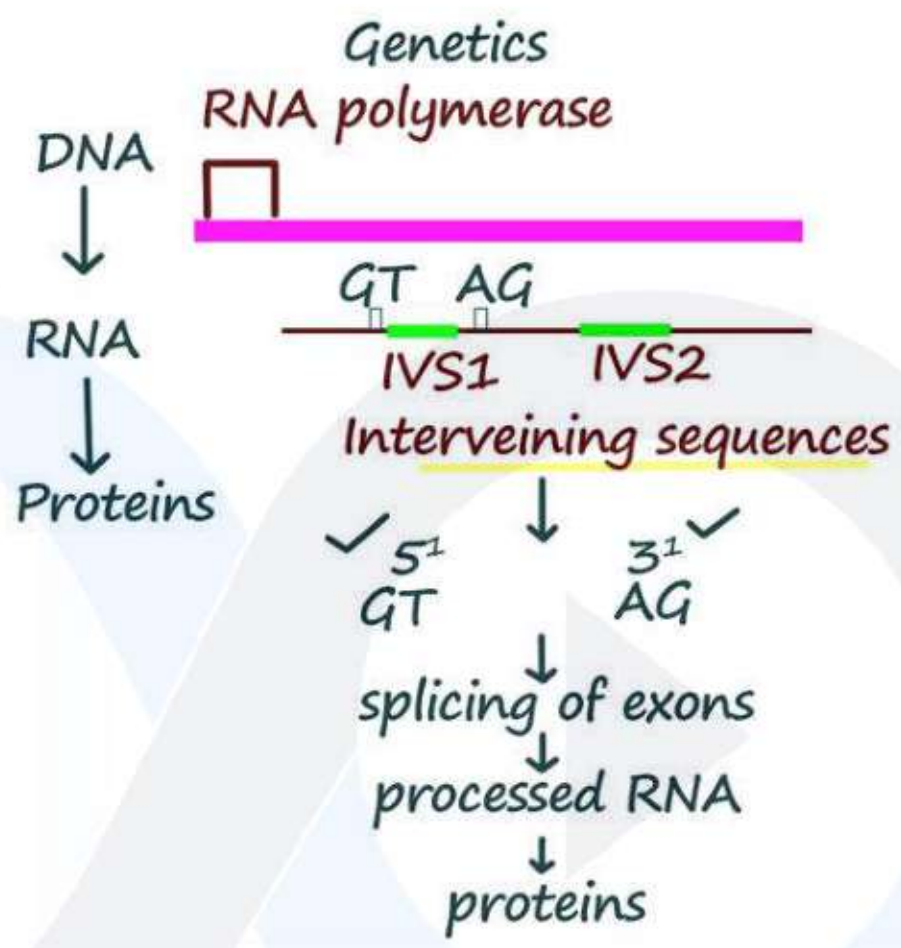

AfraTafreeh.com
TUTORIALS
LOGIN FOR SUCCESS

- Transcription mutation – Mutation in RNA polymers

2nd mutation in thalassemia

- splicing mutation-mutation of intervening segment
- most common mutation in India is intervening segment-1 [guanine is replaced by cysteine]

3rd type of mutation

- Translation mutation it is of 3 types
  a. Initiation codon mutation – ATG leads to beta thalassemia
  b. Termination mutation: - non sense mutation

AfraTafreeh.com

- TAA
- TGA
- TAG

- Leads to beta + thalassemia

c. Frame shift mutation – leads to beta + thalassemia

d. Deletional mutation – 619bp

i. I.V.S – 1, position 5 (G → C) most common

ii. 619 bp deletion

iii. Codon 8/9 frameshift mutation

iv. Codon 41/42 frameshift mutation

v. I.V.S – 1 position 1 (G – T).

TUTORIALS
LOGIN FOR SUCCESS

DIAGNOSIS OF THALASSEMIA IN JIST AND ALKALI DENATURATION TEST

Alkaline denaturation test

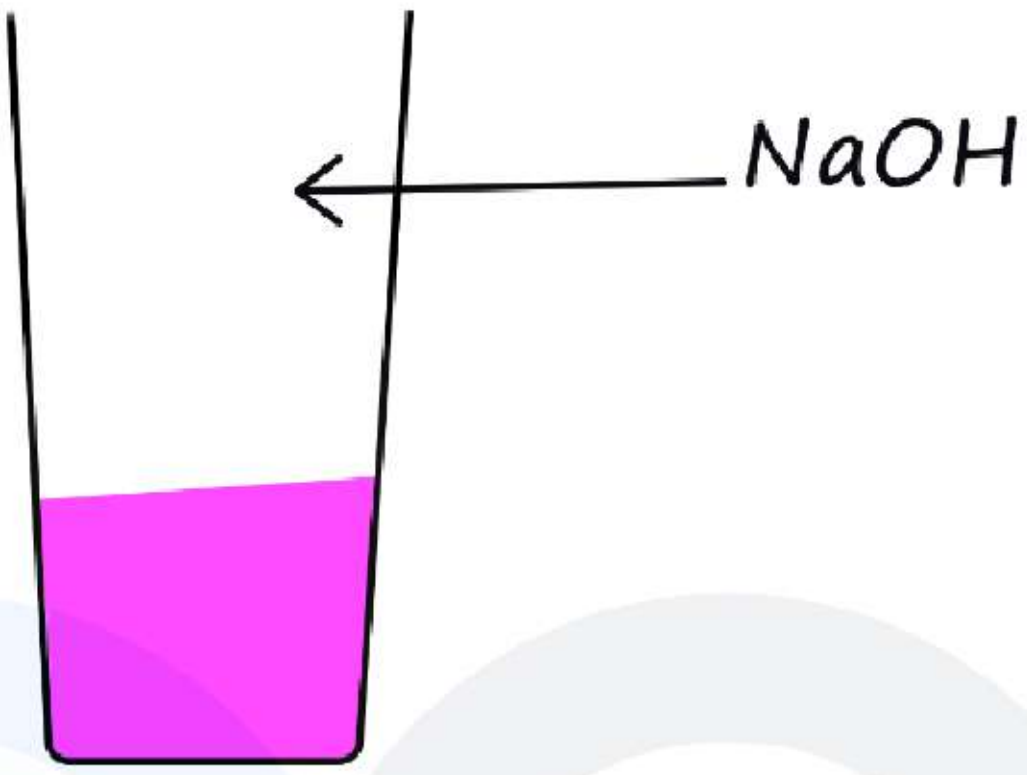

- NaOH added to Blood sample in tent tube
  i. Hb A Destroyed
  ii. Hb F resistance

AfraTafreeh.com

- NH4SO4 added ppt denatured Hb A
- Hb F not precipitated
- Hb F then quantitated in blood sample supernatant

TUTORIALS
LOGIN FOR SUCCESS

NESTROF (Naked Eye Single Tube Red Cell Osmotic Fragility TEST]

- Most common sneezing test for thalassemia
- Blood sample in collected in the test tube & normal saline 0.35% in added
- A plain while paper with a black lie in placed behind test tube
- After 30 min – Black line will be seen in Normal people due to hemoptysis

AfraTafreeh.com

- No black line in indicator of thalassemia since RBC membrane are relatively stable o resistant to lysis
- Beta & Thalassemia minor
- $\alpha 2\ \beta 2$ – 95%
- α 2 gamma 2 – >4%–8%
- Lab Parameters
- HB–7–9 gm %

  RBC count ↑ ↓

  MCV ↓ ↑

Reticulocyte count Normal ↑

- Mentzer Index = $\frac{\text{MCV}}{\text{RBC}}$ count
- Mentzer Index < 13 → Thalassemia Trait
- Mentzer Index > 13 → Iron deficiency anemia

HPLC

- β Thalassemia Trait–HbA2> 4% –8%

Peripheral Smear

- Thalassemia Trait
  - Target cells
  - No anisocytosis
  - RDW n Normal.

ALPHA THALASSEMIA

Alpha Thalassemia 00:00:30

- Genes for alpha chain – chromosome 16
- Most common mutation of → Deletion and thalassemia
- One alpha gene deleted → Asymptomatic
- Two alpha gene deleted → α trait
- Three alpha gene deleted → **β4 tetramers** for
  → Golf ball inclusion
  → HbH disease
- Four alpha gene deleted → **Y4 letrames** formal
  → hydrops fetalis

AfraTafreeh.com

α Thalassemia trait	β Thalassemia trait
MCV ↓ HbA2 ↓	MCV ↓ HbA2 ↑ 74%

- Golf ball inclusion → **β4 tetramers** seen on supra metal stain

Diagnosis of Choice in a Thalessemia

- Gap PCR – Deletion 3.7
  – Deletion 4.2.

AfraTafreeh.com

MACROCYTIC ANEMIA WITH FOCUS ON MEGABLASTIC ANEMIA

MCV > 100fl

Causes

• **Megaloblastic anemia**	• **Non - Megaloblastic anemia**
i. Vit B12 deficiency	i. Liver Diseases
ii. Folic Acid deficiency	ii. Alcoholism
iii. Inherited disorder - Lesch Nyan syndrome - orotic Aciduria	iii. Hypothyroidism
iv. N2O poisoning in Anesthesia	iv. Aplastic anemic

Vitamin B12

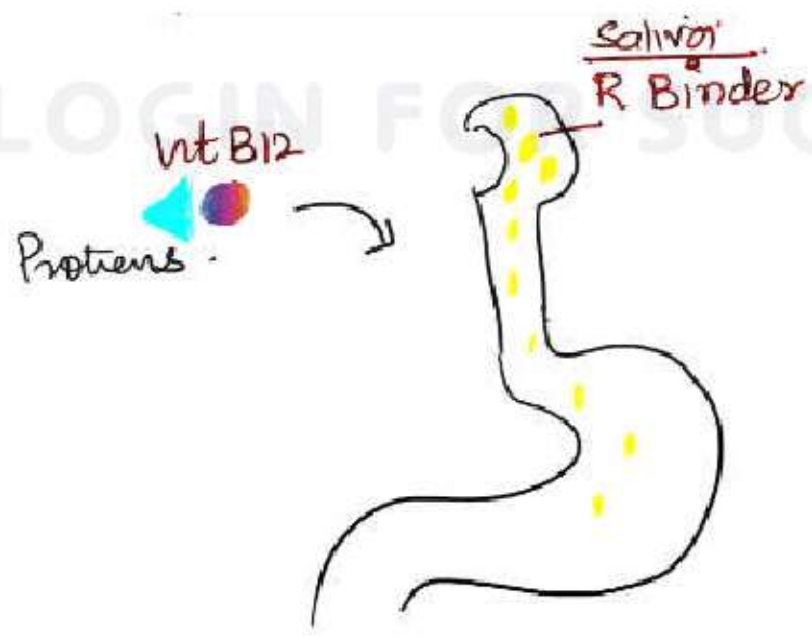

- Sources of vitamin B12 – Animal proteins
- Deficiency of seen in strict vegetarians

In Circulation

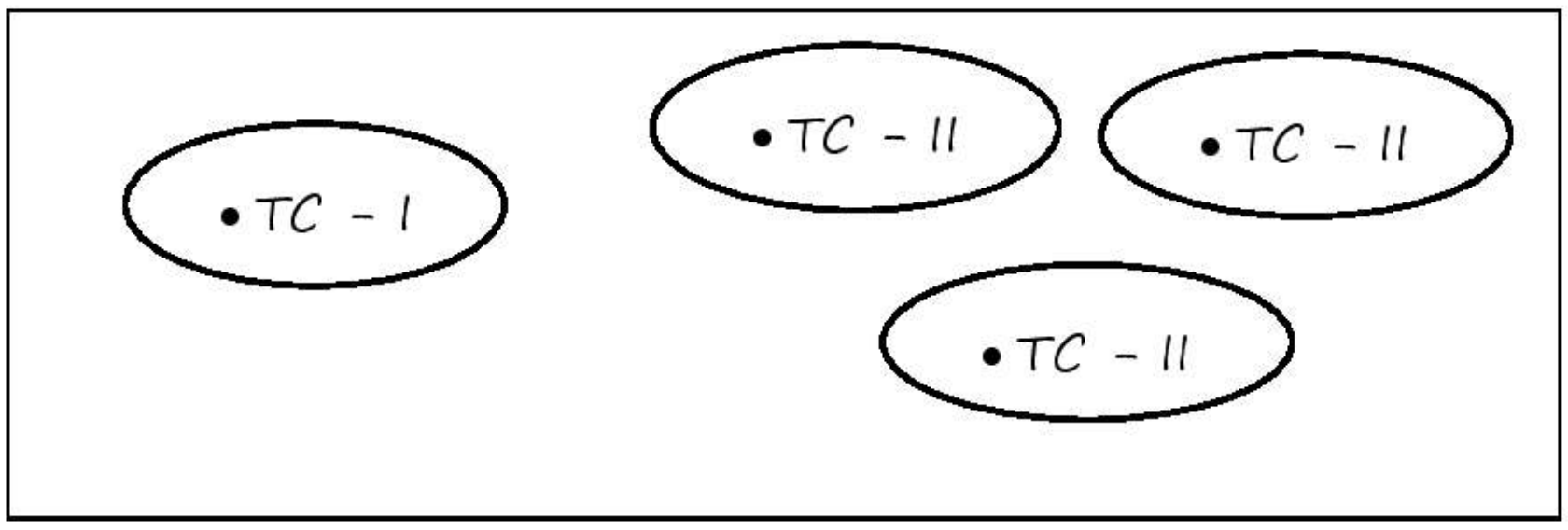

Transcobalamin I	Transcobalamin II
• Alkla Haptocorrin • Secreted Vit B12 very strongly • Function → storage of Vit B12 • R-Binder is a Type of TC-I • In leukocytosis example- in CML, • Increase WBC → so increase Granules of WBC ↓ Increase Vit 812 levels	• Alkla Holotranscobalamin • Major Transport Form • Gives B12 quickly to Tissues Bone Marrow

AfraTafreeh.com
TUTORIALS
LOGIN FOR SUCCESS

AfraTafreeh.com

Utilization of B12 00:14:54

Utilization of B12

In Cytoplasm	In mitochondria
↓	↓
Methylcobalamin	Adenosylcobalamin
↓	↓
Homocysteine →	Methylmalonyl → CoA
Methionine	Succinyl coa

In B12 Deficiency 00:34:05

- Increase Levels of Homocysteine → increase Risk of Thrombosis
- Increase Levels of Methionine → loss of Myelination of cord

↓

Subacute Combined Degeneration of spinal cord

Folic Acid Absorption

- Folate present as poly glutamate in diet
- Poly glutamate Converted to Monoglutamate

↓

Absorbed

↓

5-Methyl THF-circulatory form of folic acid

Role of cobalamine

i. 5 Methyl THF $\xrightarrow{CbL}$ THE

→ Methyl

ii. Adenosyl Cobalomin helps in retaining of folic acid by RBC

- Red cell folate levels are maintained by B12
- In Vit B12 deficiency- RBC folate level Decreases

iii. DNA Formation requires B12 & FA

FOLATE TRAP

- In cobalamin deficiency → Folic acid Trapped as 5-Methyl THF
- No TMP for DNA formation so instead dVMP is incorporated resulting in defective DNA → Highlighted by sieve like chromatin of Blasts in Bone marrow

↓

These defective Cells are Killed in BM

Resulting in Ineffective Erythropoiesis

↓

Howell Jolly Bodies

Cabot Rings.

AfraTafreeh.com
TUTORIALS
LOGIN FOR SUCCESS

AfraTafreeh.com

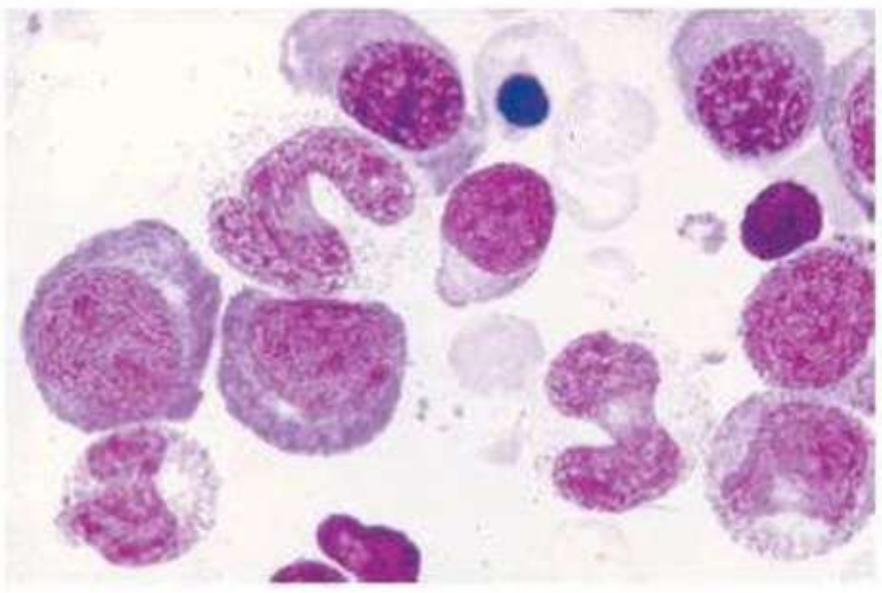

Basophilic Stippling

Fig: 1

Bone Marrow Findings in Megaloblastic anemia Hyper cellular BM

Peripheral Smear findings in Megaloblastic Anemia

- Howell Jolly Bodies
- Cabot Rings
- Basophilic Stippling

  [Most Characteristic]

  Macrocytic Macroovalocyte

  I st Peripheral Smear Finding

WBC

- Hyper-segmented Neutrophils

  Criteria = Atleast 3% Neutrophils showing 5 lobes

  Atleast 1 cell showing 6 lobes

  2nd finding on PS

  Last to disappear after Therapy → 12-14 days after Therapy
- Hyper-segmented Neutrophils are not specific for Megaloblastic anemic also seen in

  i. MDS

ii. POST Chemotherapy

Diagnosis of Chicce 812 levels

- TC-II assays → decrease TC-II Earliest Predictor of 812 deficiency
- B M Iron levels by Perl's Prussian Blue raining if Iron decrease implies Coe Xining
- IDA

Causes

i. Dietary deficiency of B12

ii. Atrophic Gastritis → pH of Stomach altered R. binder does not leave B12

iii. Pernicious Anemia – Ab against parietal cell – M/C (90) / Ab against IF

iv. Exocrine Pancreatic Deficiency → No Proteases to cleave R-binder & B12

v. Resection of Ileum

vi. Diphyllobothrium latum in Ileum

vii. Bacterial Overgrowth Syndrome

Imerslund Grosbeak Syndrome

- Absence of cubulin Receptor
- Presents with Megaloblastic anemia
- Kidney manifestation
- Cubulin Receptors are also present in Kidney normally

AfraTafreen.com

AfraTafreeh.com

Peripheral Smear Images

- Macro ovalocyte → earliest finding

  Nucleated RBC with Sieve like chromatin

Hyperpigmented Neutrophils

Other findings in MA

i. Decrease TC – II (Diagnosis choice) ii. Increase Homocysteine iii. Increase methyl malonyl CoA iv. Decrease methionine v. Reticulocyte count Normal or low	i. Anemia ii. Neurological manifestation (Not reversed even after therapy) iii. Mucosal manifestation

Genetic trophy Rectify

Risk of Gastric Adenocarcinoma

Risk remains even after Therapy

- If in MA – Only Folic acid is supplemented without B12
- The neurological symptoms worsen – Since folate trap increase

Schilling test 00:65:40

- Oral intake of Radiolabeled B12
  - ↓ 2 hour later → i.m injection of vitamin B12 (I.m injection engages TC – I)
  - ↓ Look at level of B12 excretion in urine
    - > 10% — Normal absorption of B12
    - < 10% ↓ Give Radiolabeled B12 with IF
      - > 10% — IF deficiency
      - < 10% Excretion ↓ Radiolabeled B12 + Antibiotics ↓ > 10% excretion ↓ Bacterial overgrowth syndrome

FIGLU TEST

- For amino glutamic acid

Histidine
↓
FIGLU
↓ Folic acid
Glutamic acid

TUTORIALS LOGIN FOR SUCCESS

AfraTafreeh.com

- Procedure → after loading done of histidine

  ↓

  Increase Excretion of FIGLU in urine implies <u>FA deficiency</u>

- This test is also positive in B12 def

  So cannot differentiate between FA and B12 def

Folic Acid Def	B12 Def
Sr FA decrease Red cell folate decreases	Sr FA normal Red cell folate decreases

TUTORIALS
LOGIN FOR SUCCESS

RED CELL INCLUSIONS

Erythropoiesis:

Proerythroblast

↓

Basophilic Normoblast

Polychromatic Normoblast

Orthochromatic Normoblast

↓

Reticulocyte

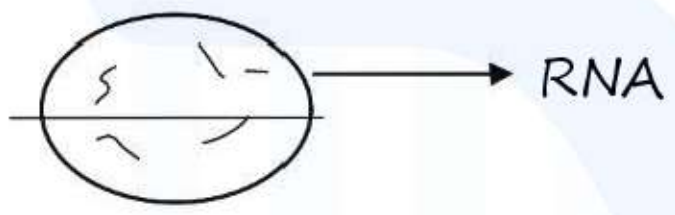

↓

Spleen (Culling and Pitting).

↓

Mature RBC

AfraTafreeh.com

Stains & RBC Inclusions

- Should be done immediately

  Example: i. New Methylene Blue

  ii. Brilliant Cresol Blue

Supravital Stairs

RNA ↓ Reticulocyte	Denatured Hemoglobin ↓ Heinz bodies in GEPD deficiency	Beta 4 Inclusion ↓ HbH Inclusion in

AfraTafreeh.com

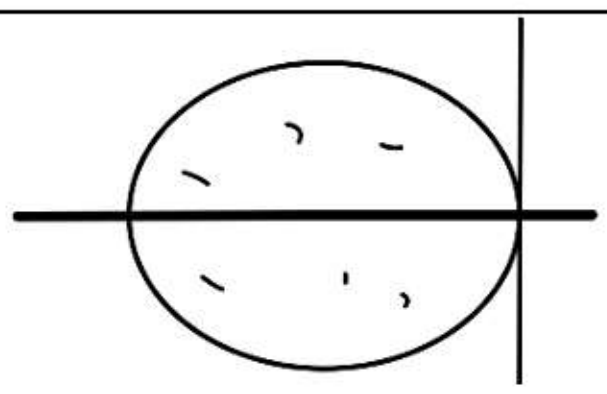 • Lesser the dots • More mature the RBC • Minimum 2 dots should be seen	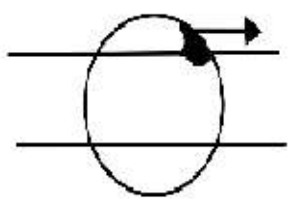 Denatured Hemoglobin	Alpha Thalassemia 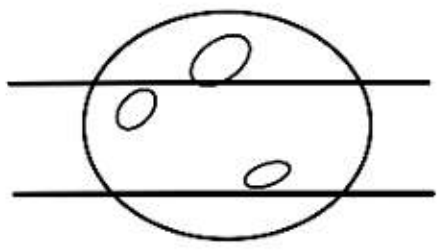 Golf ball like inclusions

Romanowsky Stain 00:03:06

- Methylene Blue & Eosin in acetone free Methanol (Since acetone damages membrane of Red Cells)
- Methylene Blue-Azure dye/ Basic dye Binds with acidic contents of Nucleus of cell imparting Blue color
- Acidic Dye Binds with basic components like cytoplasmic proteins

Romanowsky Stain

Nuclear Remnant called Howell Jolly Bodies 	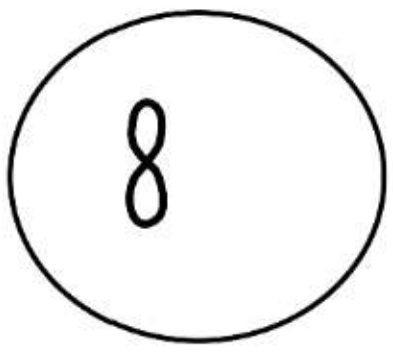 **<u>Cabot Rings</u>** Figure of 8 shaped	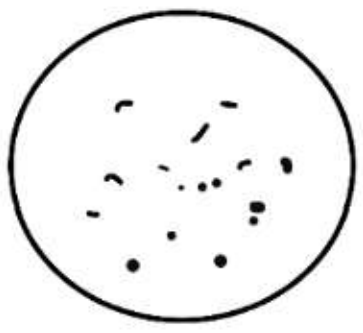 • Basophilic Stippling or Punctuate Basophilia

Cause: - -Splenic Hypofunction -Asplenia -Ineffective Erythropoiesis	inclusions in RBC Cabot Rings are remnants of mitotic Spindle seen in Megaloblastic anemic	• Polyribosomes in RBC - Fine ↓ In Ineffective erythropoiesis - Coarse ↓ Lead Poisoning Lead Inhibits Pyrimidine 5 nucleosidase

Crystals in Hbc – Hemoglobinopathy

(Replacement of Glutamic acid by Lysine at Beta 6 chain)

Hbc: Glutamic acid → Lysine

Sickle Cell Anemia Glutamic Acid → Valine at Beta 6

HbSC → Compound Heterozygote

Hbs & Hbc Both sickle cell and Crystals in Blood

AfraTafreeh.com
TUTORIALS
LOGIN FOR SUCCESS

Normal Siderablasts in Bone Marrow

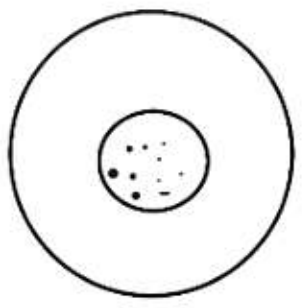

Iron Contained in Nucleus

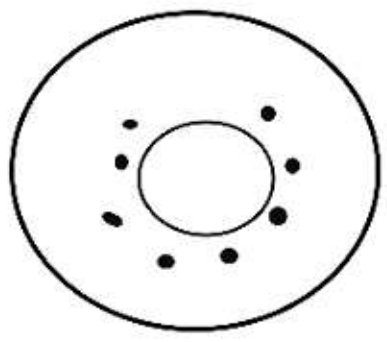

<u>Ringed Sideroblasts</u>

Iron accumulated in Perinuclear location

Criteria: – >5 Iron Granules

– Should cover > 1/3 of Nuclear parameter

AfraTafreeh.com

MDS with Ringed Sideroblasts

criteria:

- >15% Ringed Sideroblasts
- In Presence of SF301 mutation only 5% ringed Sideroblasts needed.

  SF3β1 → Hallmark mutation of Ringed Sideroblasts

  Special stain used → Perl's Prussian Blue

when these Ringed Sideroblasts exit Bone marrow a mature RBCs with less of Nucleus, the iron inclusions are called papenheimer

Summary of Red Cell Inclusions 00:32:39

Romanowsky Stain	Supravital Stain	Special stain
• Howell Jolly bodies • Basophilic stippling • Cabot rings	• HbH • Reticulocyte • Heinz Bodies	• HbC • Ringed sideroblast in Bone Marrow (SF3β1 mutation) • Pappenheimer bodies in peripheral blood

Note on Doble bodies

- Inclusions in WBC
- There are dilated endoplasmic reticulum

May Hegglin Anomaly

- MYH9 gene defect giant platelets + Dohle body inclusions

Update

- Romanowsky stain in commonly used at PH 6.8
- Schuffner Dots of malarial parasite (P.vivxx) are stained by Romanowsky stain at PH 7.2.

AfraTafreeh.com
TUTORIALS
LOGIN FOR SUCCESS

AfraTafreeh.com

RED CELL MEMBRANE ABNORMALITIES – I

Red Cell Membrane Abnormalities

Decrease Surface area/Vol spherocytes

Target cell

Surface area/Vol increase

Absolute
↓
- Adding phospholipid \ Cholesterol
- Usually happens in obstructive liver diseases

Relative
↓
- Volume decreases
- Surface increases
- Thalassemia, Severe IDA

Acanthocyte

- Outer lipid layer increases (inner lipid layer is normal)
- Increase cholesterol accumulation → liver disease
- Increase sphingomyelin accumulation → A beta lipo – protein

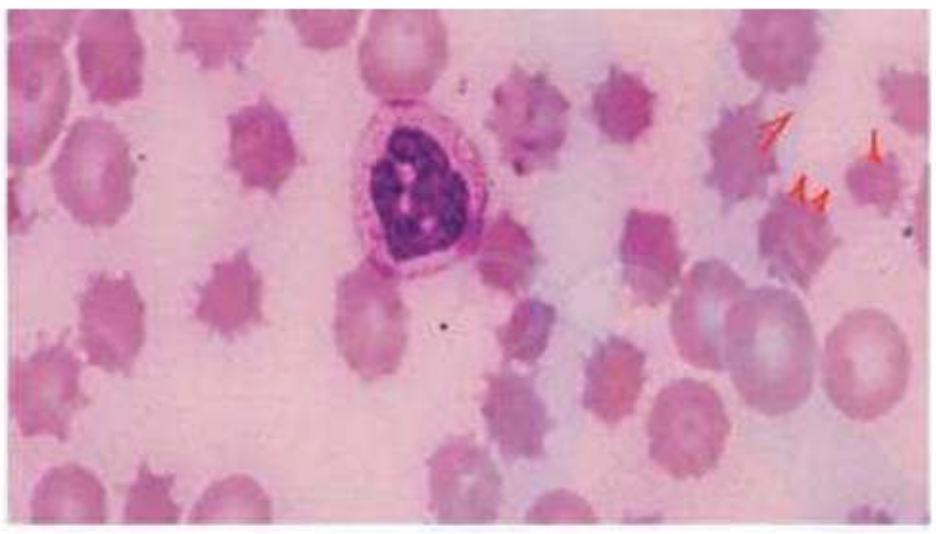

Fig: 1

Stomatocytes

- Irregular spikes coming in

- Inner lipid layer increases (outer lipid layer is normal)
- Vinca, alkaloids, alcoholism, cation permeability disorders.

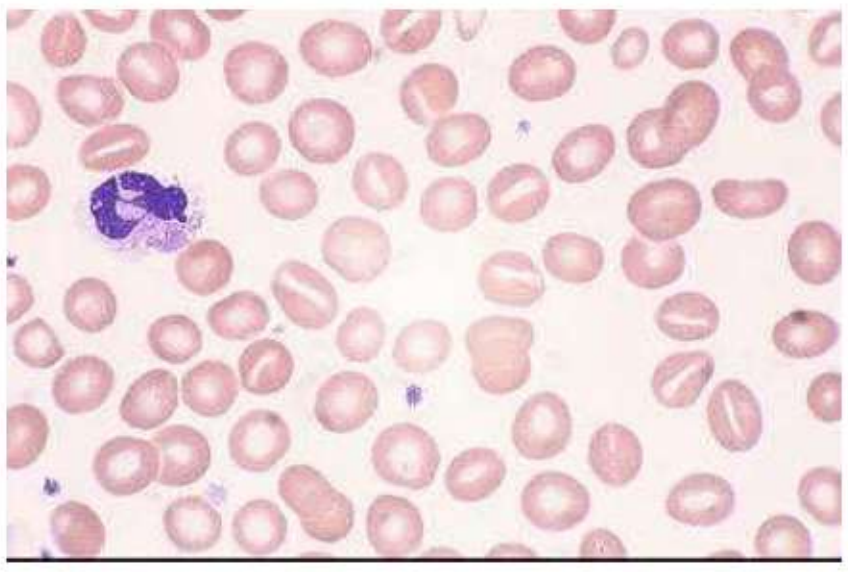
Fig: 2

AfraTafreeh.com
TUTORIALS
LOGIN FOR SUCCESS

AfraTafreeh.com

AUTOIMMUNE HEMOLYTIC ANEMIA – I

AIHA

Cold acting / Active Abs	Warm Acting / Active Abs
• Active below core body temperature • Usually, IgM Abs ↓ activates complements ↓ MAC ↓ presents with intravascular hemolysis	• Active at core body temperature @ 37°c • Usually, IgG Abs ↓ Do not activate complements

Cold Agglutinin Disease (CAD) 00:06:03

Pathogenesis:

- Complements has DAF – Controls C_3 convertase
- MIRL – Controls C_5 convertase forms MAC
- Till MIRL is present in the body, prevents activation of C_5 convertase and leads to formation of MAC
- As the complements are activated in IgMAb, a special complement called C_3b will be coated on cells.

- AS MIRL is present, not needed for activation of MAC, so intra vascular Hemolysis doesn't occur
- C_3 b converts into Cad, liver has Cid receptors which then eats up the complement coated red cells, which causes extra vascular hemolysis.

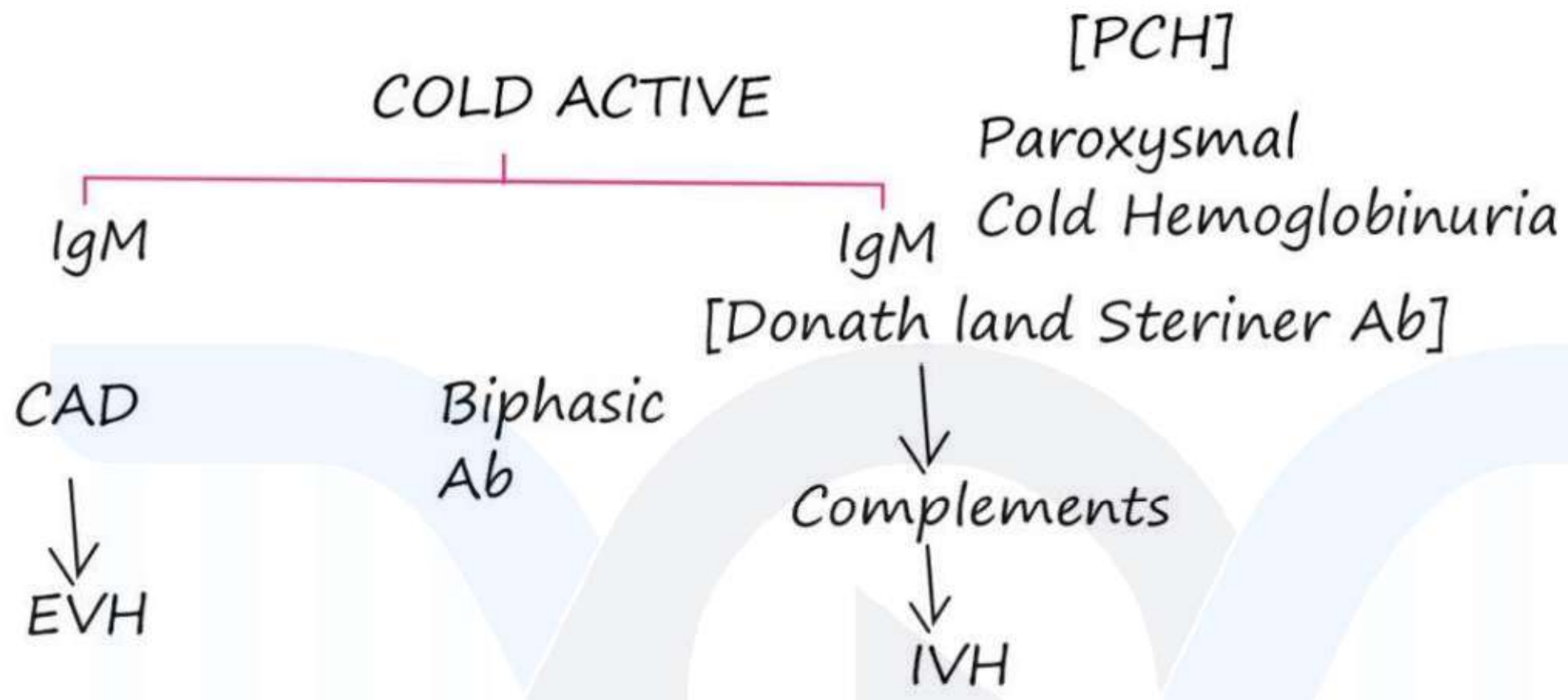

Paroxysmal Cold Hemoglobinuria (PCH)

- PAg
- Caused by syphilis/Measles
- Forms Spherocytes, as surface area/volume decreases
- Shows Erythrophagocytosis
- Presence of Intra Vascular Hemolysis so, pr presents with hemoglobinuria & hemoglobinemia pain in back & dark color urine

AfraTafreeh.com

Cold Active

	CAD	PCH	Cryoglobulinemia
Ab	IgM Fix Complements	IgG Fix Compleme nts	Forma immune complexes in cold
Ag	I/i	P	Do not bind with RBC
Presents	EVH	IVH	Vasculitis

CAD, PCH, Cryoglobulins – presents with – Raynaud–Phenomenon
– Acro–Cyonosis
– livido–Recticulosis

- "I" turned antigenic by Mycoplasma
- "I" is turned antigenic by infectious mononucleosis
- CLL chronic Lymphoproliferative disease can cause CAD

Clinical Manifestations 00:22:25

CAD	PCH
IgM	IgG
Agglutinates	Forms Spherocytes

by machine-coulter RBC-Very low MCV-Very high MCH-Very high	
Warm the sample RBC – Normal MCV, MCH – Normal	Erythrophagocytosis
Diagnosis: COOMB's Test	Intra Vascular Hemolysis

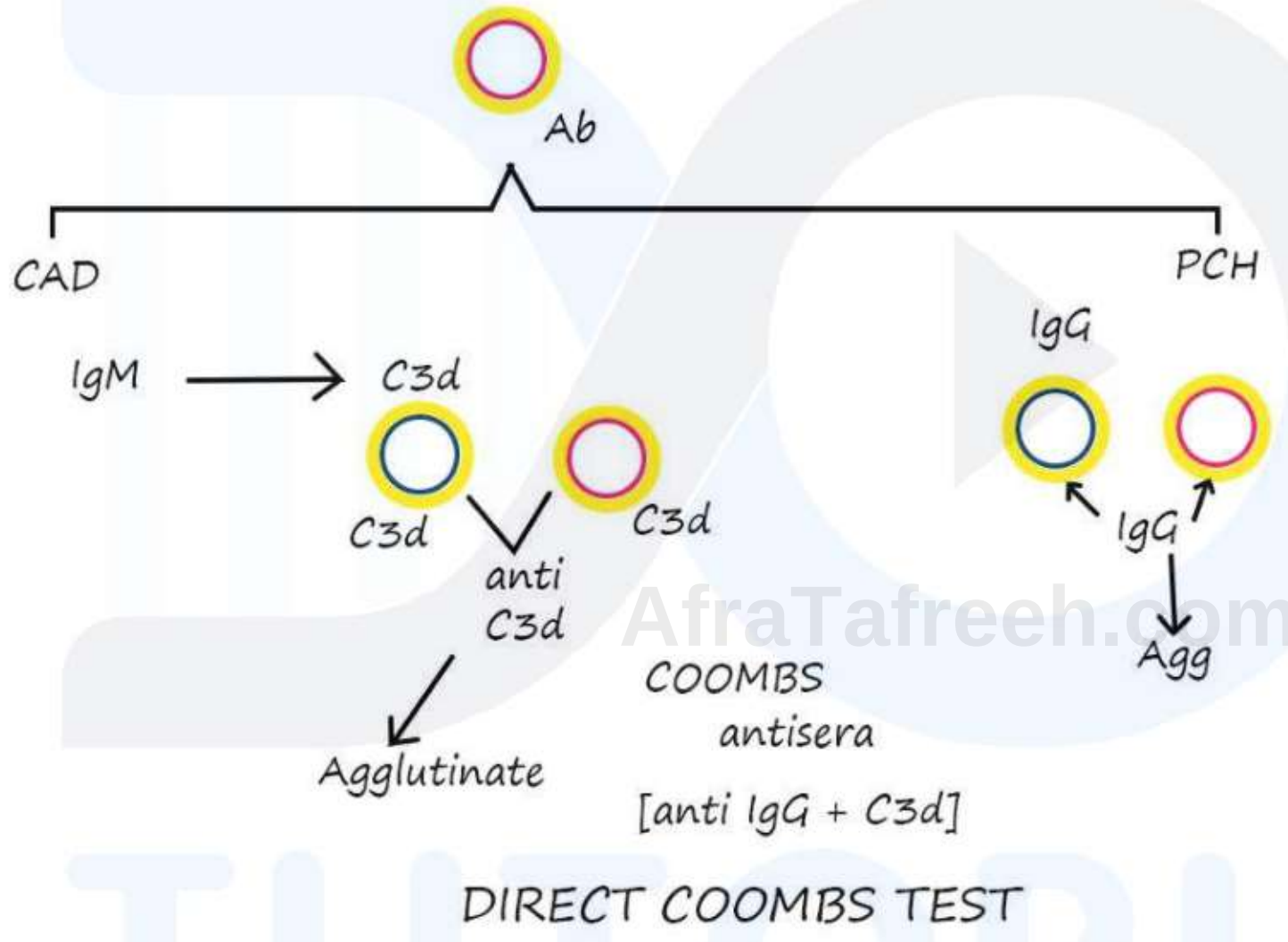

AfraTafreeh.com
TUTORIALS
LOGIN FOR SUCCESS

Agglutination

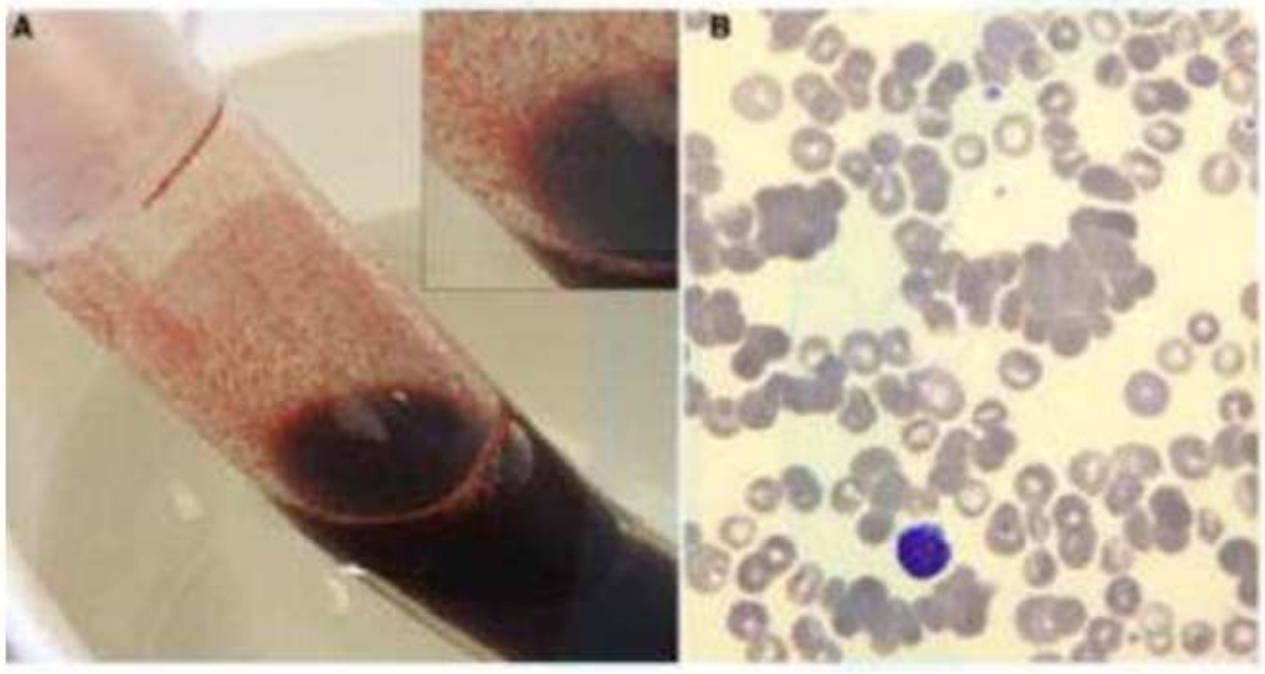

Fig: 1

AfraTafreeh.com

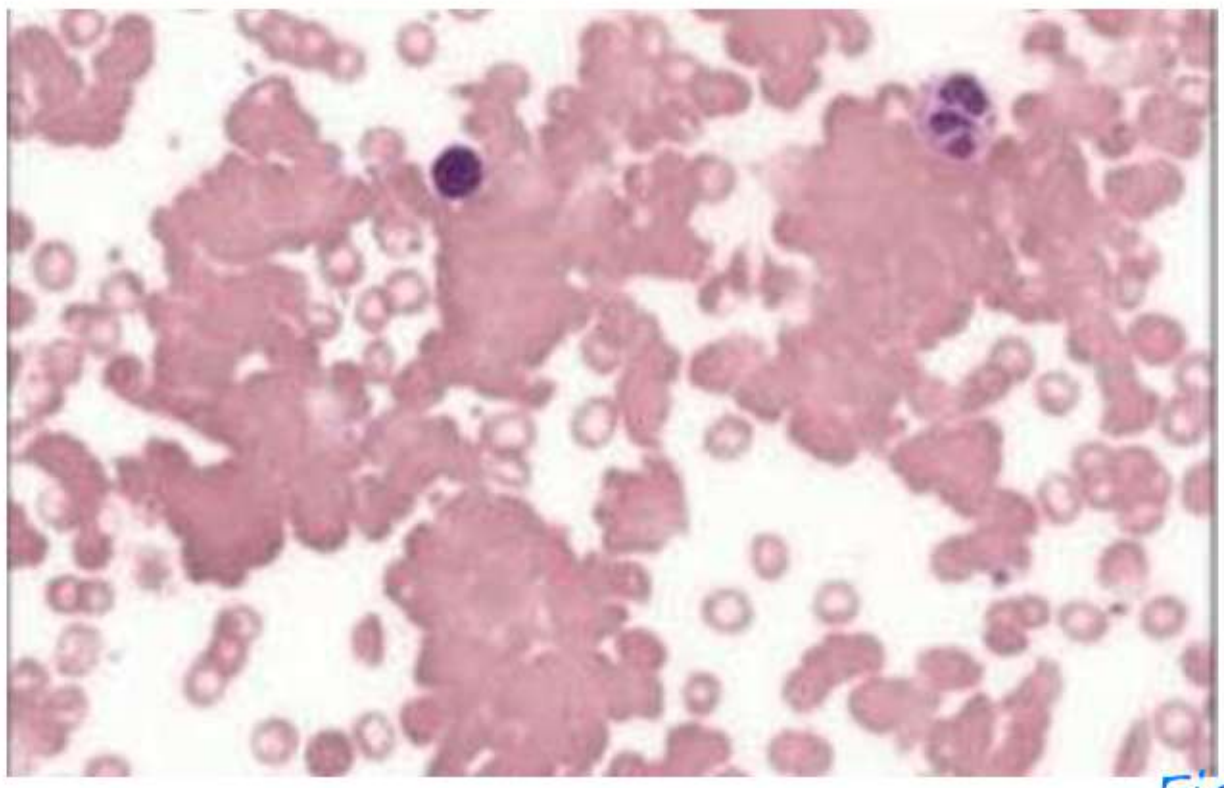

Fig: 2

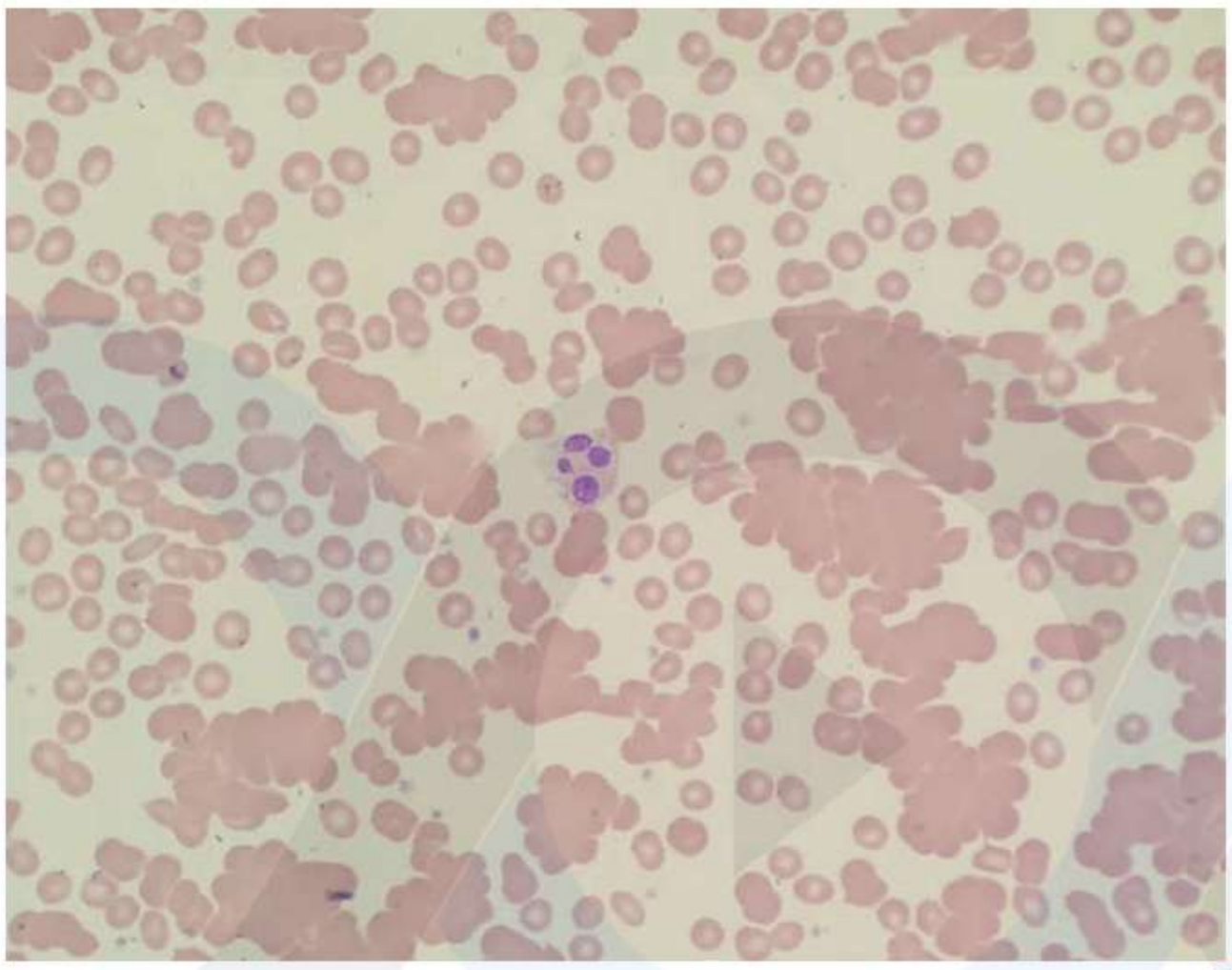

Fig: 3

Warm Acting/Active

Incomplete Ab's warm AIHA

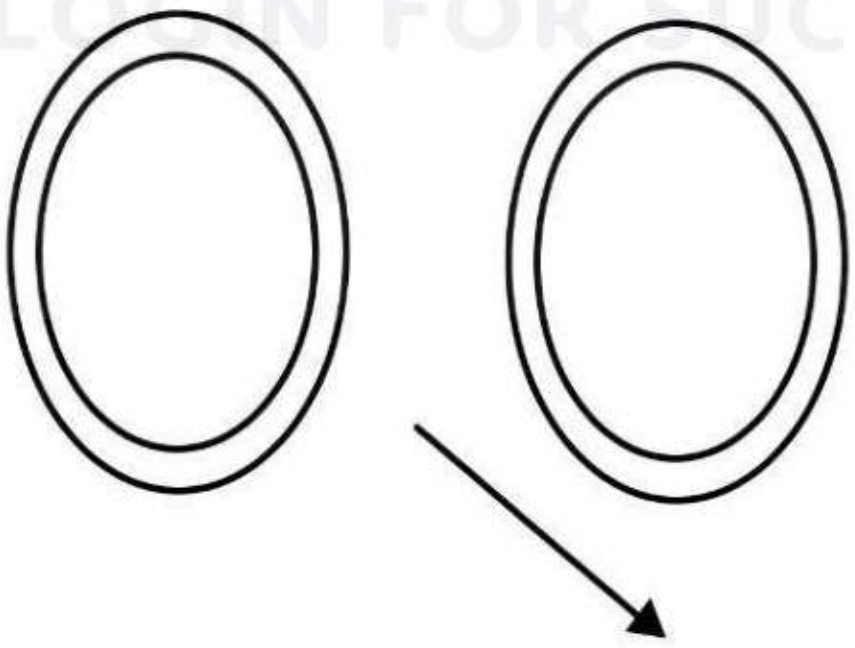

Spleen decreases surface area / volume

Manifestation

- Spherocytes → Coomb's test

  Positive → ALHA   Negative → Hereditary Spherocytosis
- Jaundice
- Splenomegaly

MBS:

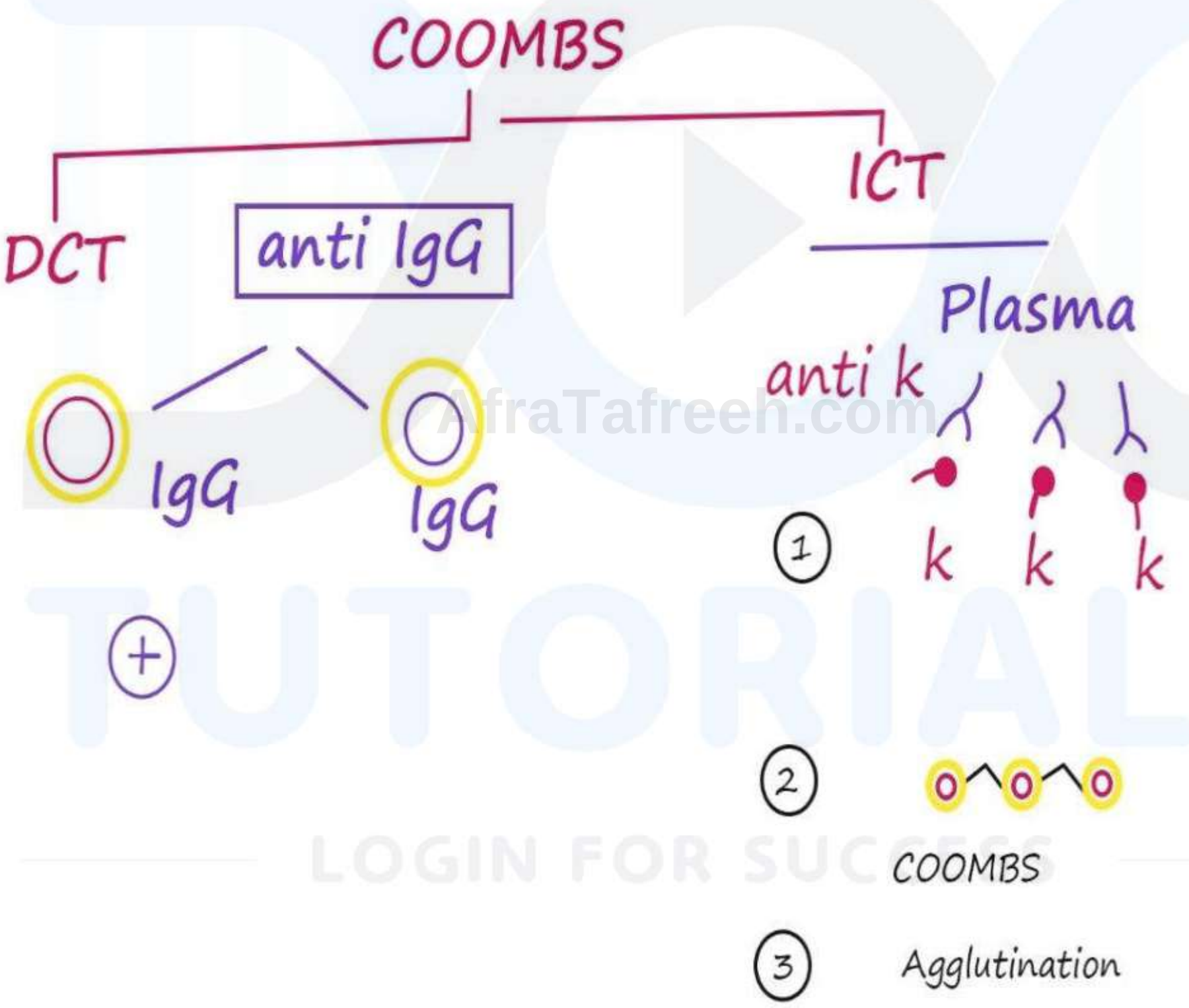

Warm AIHA can be cause of – Infections
- Drugs
- Malignancies – CLPD (CLL)

AfraTafreeh.com

MBS Syndrome

HITP + AIHA

Drug induced HA

Adsorption	NeoAg	Autoimmune
Is formed first drugs	- Ab's formed, which binds both Ab's and RBC's	- Drug does not bind to RBC but triggers auto-antigen formation -commonly by methyl DOPA



Fig: 4
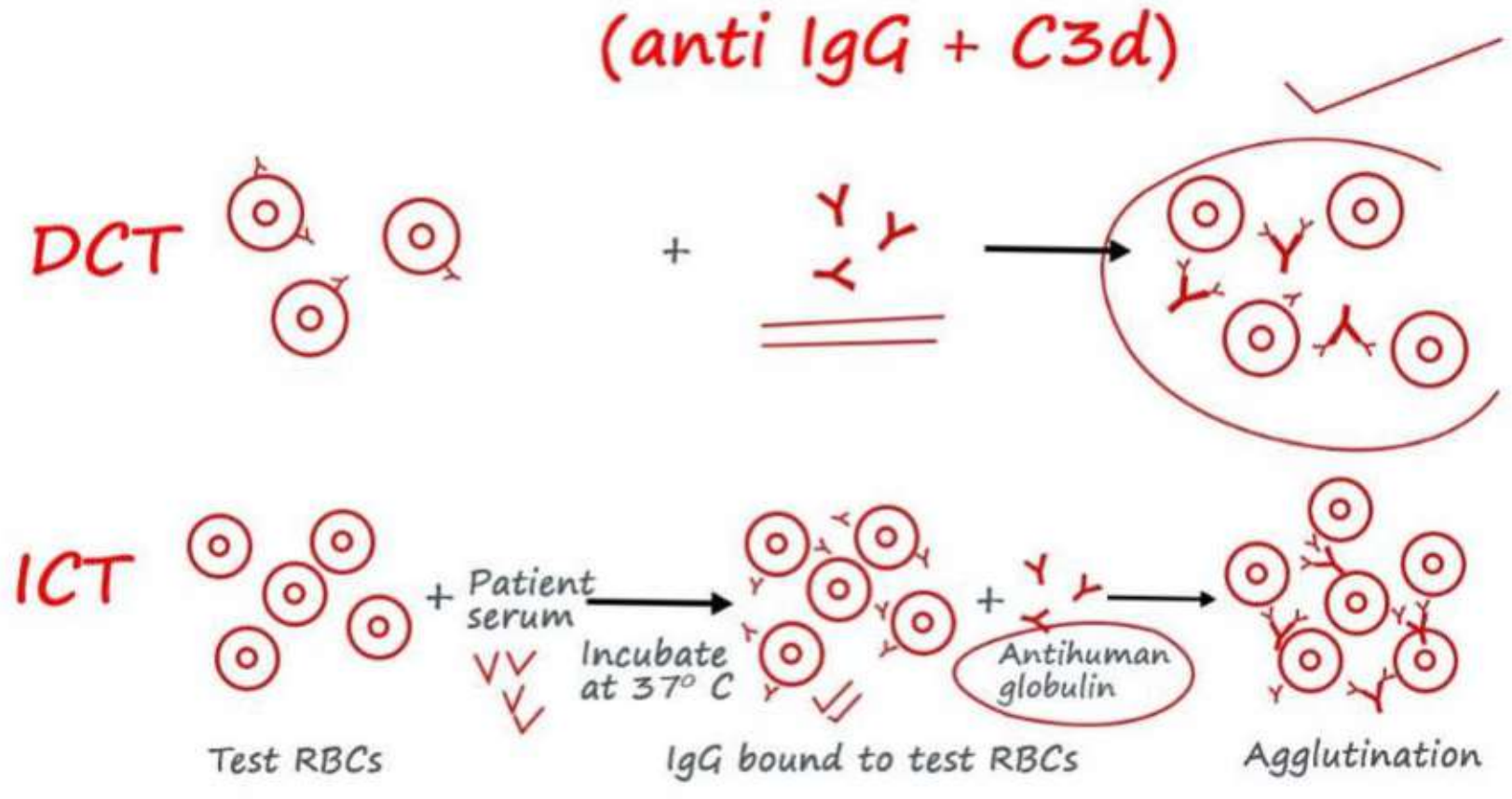
Coomb's Test: